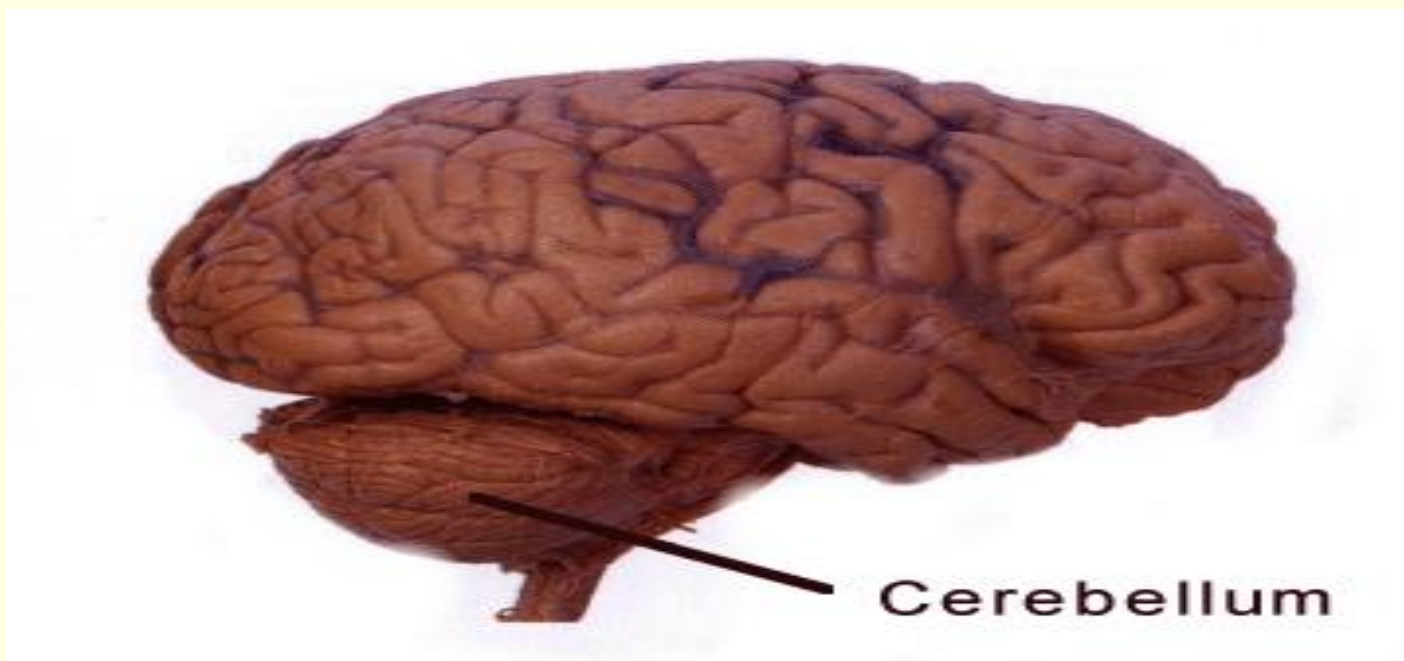


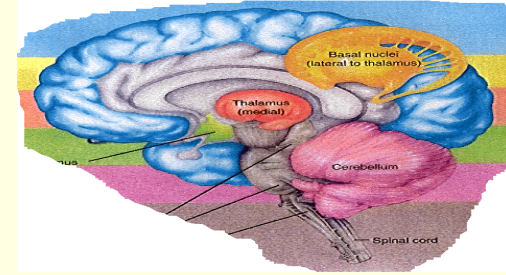
CEREBELLUM



Prof. Sultan Ayoub Meo

MBBS, Ph.D (Pak), M Med Ed (Dundee), FRCP (London),
FRCP (Dublin), FRCP (Glasgow), FRCP (Edinburgh)
Professor and Consultant, Department of Physiology,
College of Medicine, King Saud University, Riyadh, KSA

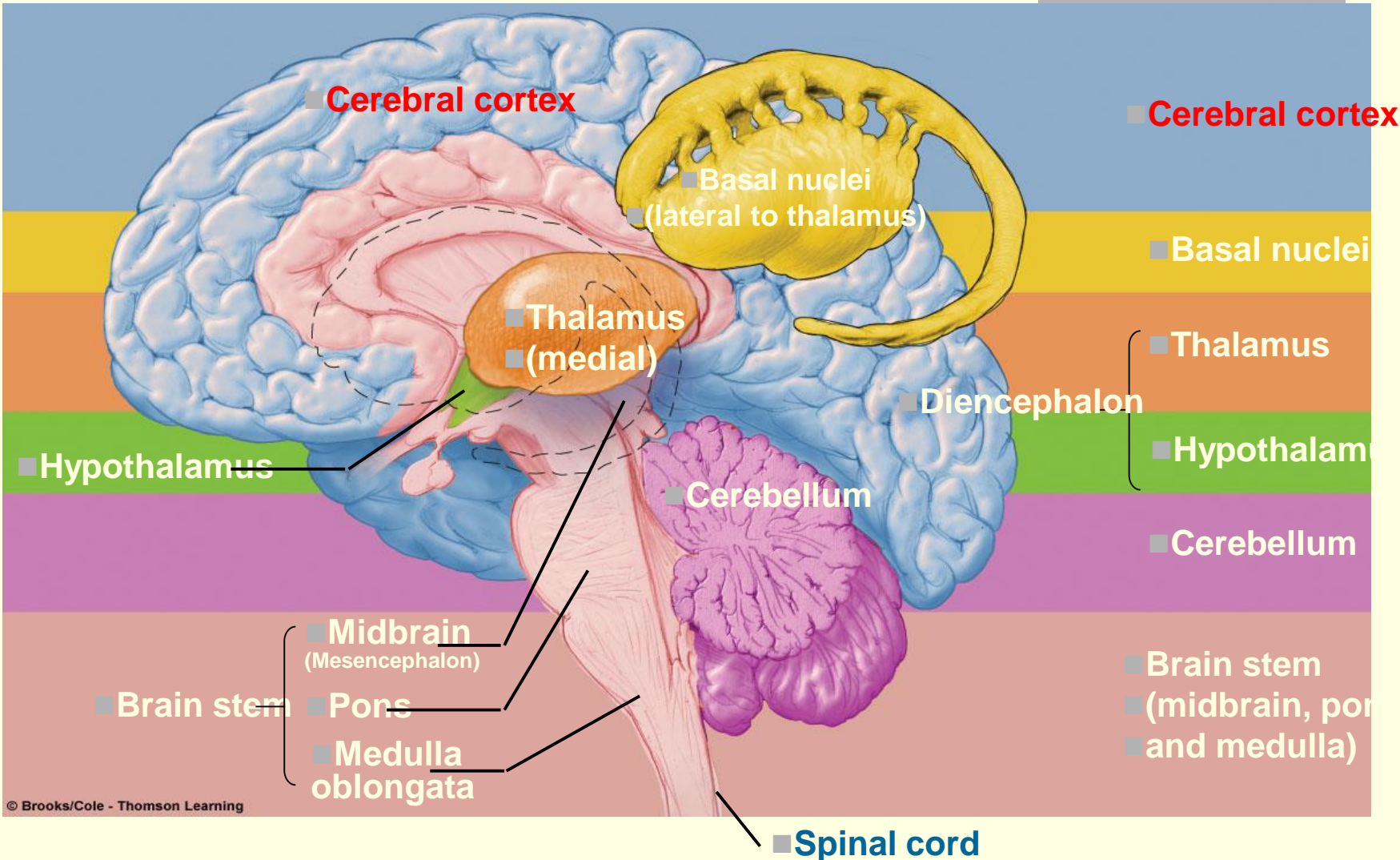
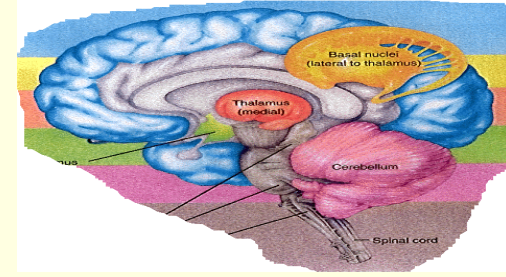
CEREBELLUM



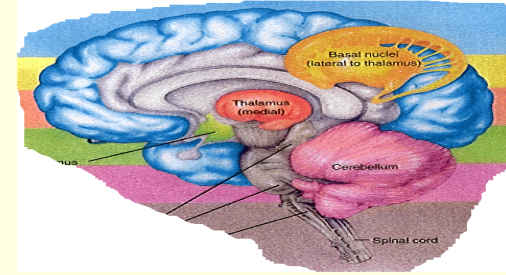
Lecture Objectives

- Describe the divisions of the cerebellum
- Describe the functional divisions of the cerebellum (vestibulocerebellum, spinocerebellum and cerebrocerebellum).
- Understand cell types / nuclei of the cerebellum
- Understand the functions of cerebellum in regulation of movement, tone and balance.
- Understand the abnormalities associated with cerebellar disease: Cerebellar nystagmus , changes in muscle tone , ataxia , drunken gait , scanning speech , dysmetria (past-pointing), intention tremor , rebound phenomenon and diadochokinesia

CEREBELLUM

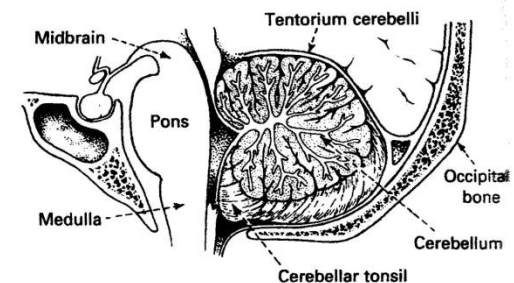


CEREBELLUM



CEREBELLUM: Cerebellum is derived from a Latin word means "little brain." Cerebellum is the largest part of the hind brain, lies behind the pons and medulla Oblongata.

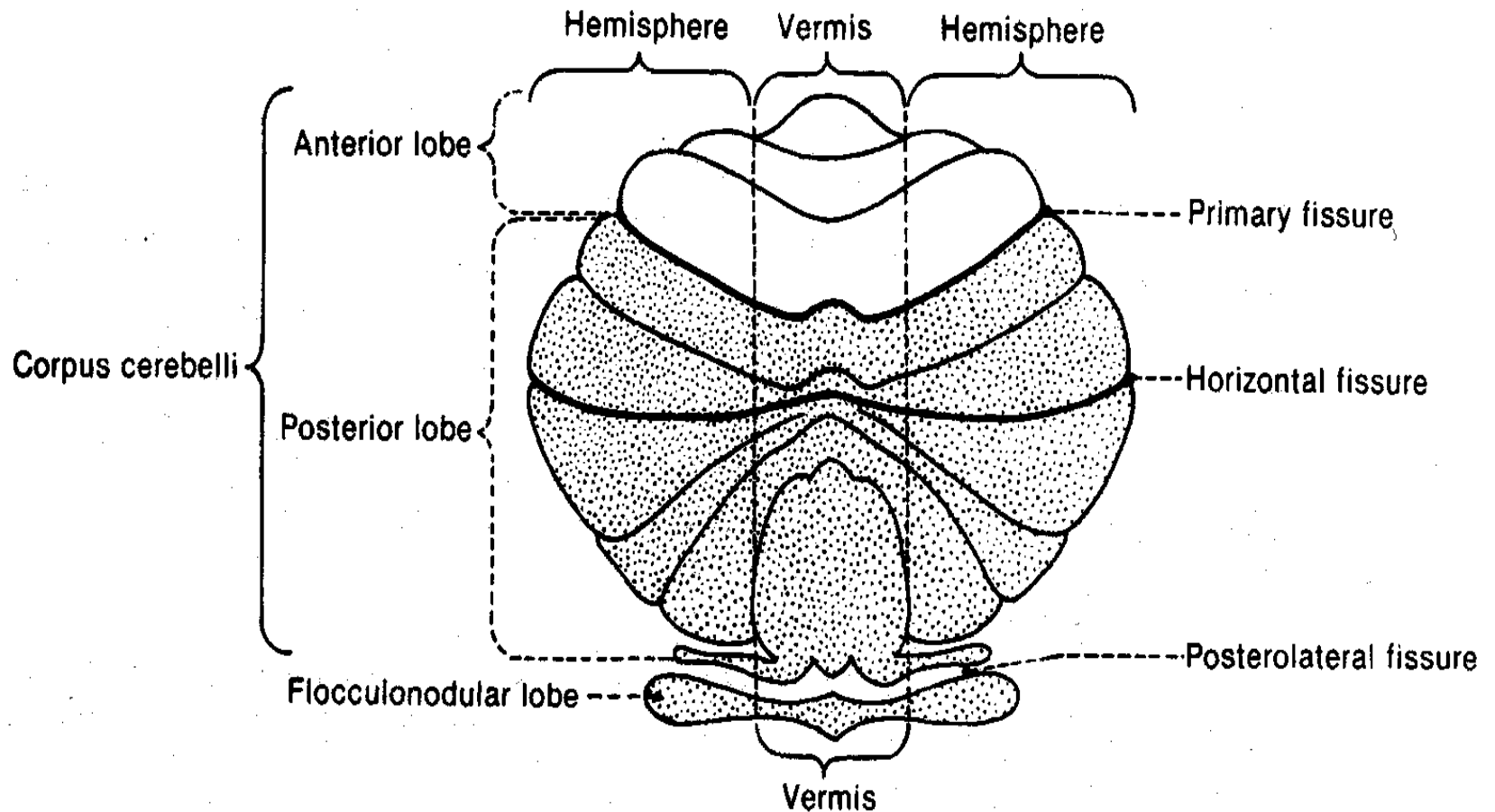
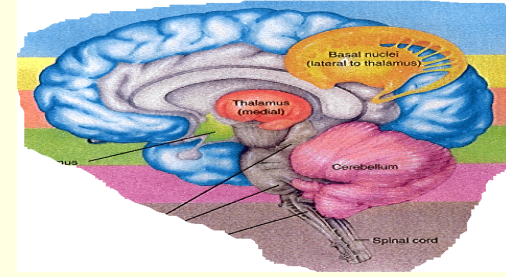
- **Shape:** Oval shaped, with an approximate weight is 150 gm
- **Location:** Situated in the posterior cranial fossa
- **Anteriorly:** 4th ventricle, pons, and medulla oblongata
- **Superiorly:** Covered by tentorium cerebelli
- **Postero-inferiorly:** Squamous occipital



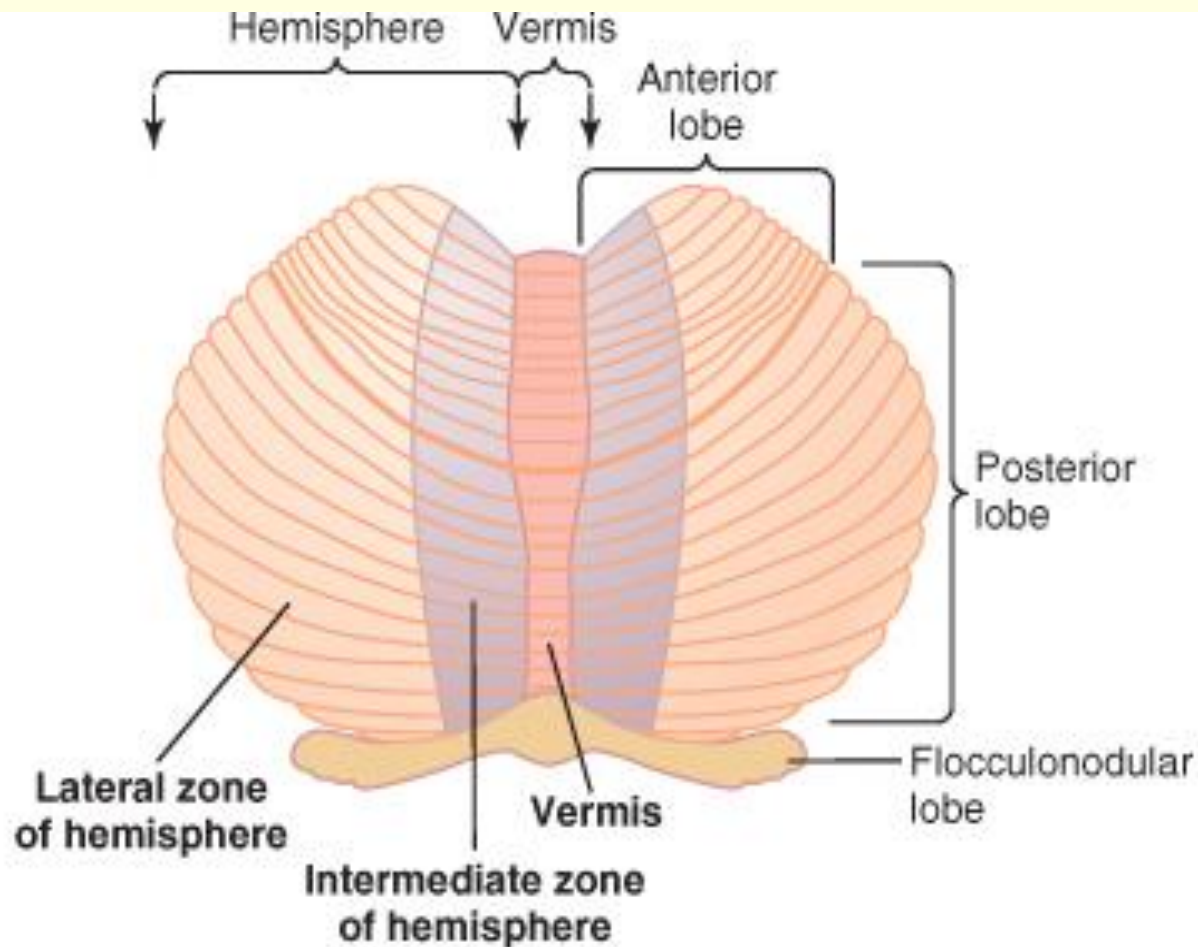
CEREBELLUM: THE RULE OF 3

3 lobes	<ul style="list-style-type: none">•Floculonodular Lobe•Anterior lobe•Posterior lobe
3 Cortical Layers	<ul style="list-style-type: none">•Molecular layer•Purkinje cell layer•Granular layer
3 purkinje's cells afferent paths	<ul style="list-style-type: none">•Mossy fibers•Climbing fibers•Aminergic fibers
3 pairs of deep nuclei	<ul style="list-style-type: none">•Fastigial•Interposed(globose & emboliform)•Dentate
3 pairs of peduncles	<ul style="list-style-type: none">•Superior (pri.output)•Middle (pri.Input)•Inferior (pri.Input)
3 functional division	<ul style="list-style-type: none">•Vestibulocerebellum•Spinocerebellum•Cerebrocerebellum

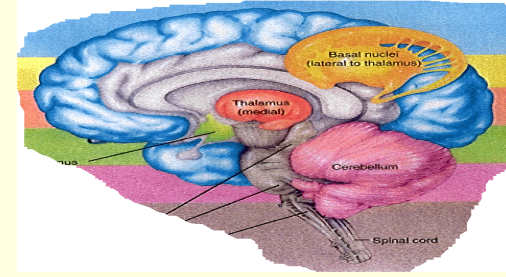
PHYSIOLOGICAL ANATOMY OF THE CEREBELLUM



PHYSIOLOGICAL ANATOMY OF THE CEREBELLUM



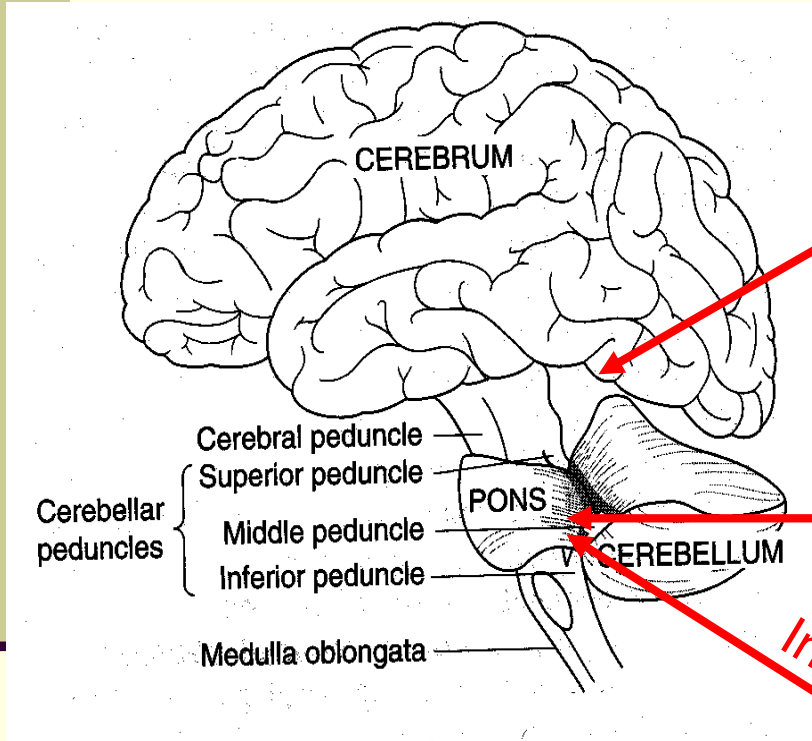
CEREBELLUM



The cerebellum is anatomically and physiologically divided into three parts:

- **Paleocerebellum:** Anterior lobe [Spinocerebellum]
- **Neocerebellum:** Posterior lobe [Cerebrocerebellum]
- **Archicerebellum:** Flocculonodular lobe [Vestibulocerebellum]

CEREBELLAR PEDUNCLES: CARRY AFFERENTS FROM WHERE?



Superior Cerebellar Peduncle

Inputs to the Cerebellum from the cerebrum

Middle Cerebellar Peduncle

Inputs to the Cerebellum from from the Pons

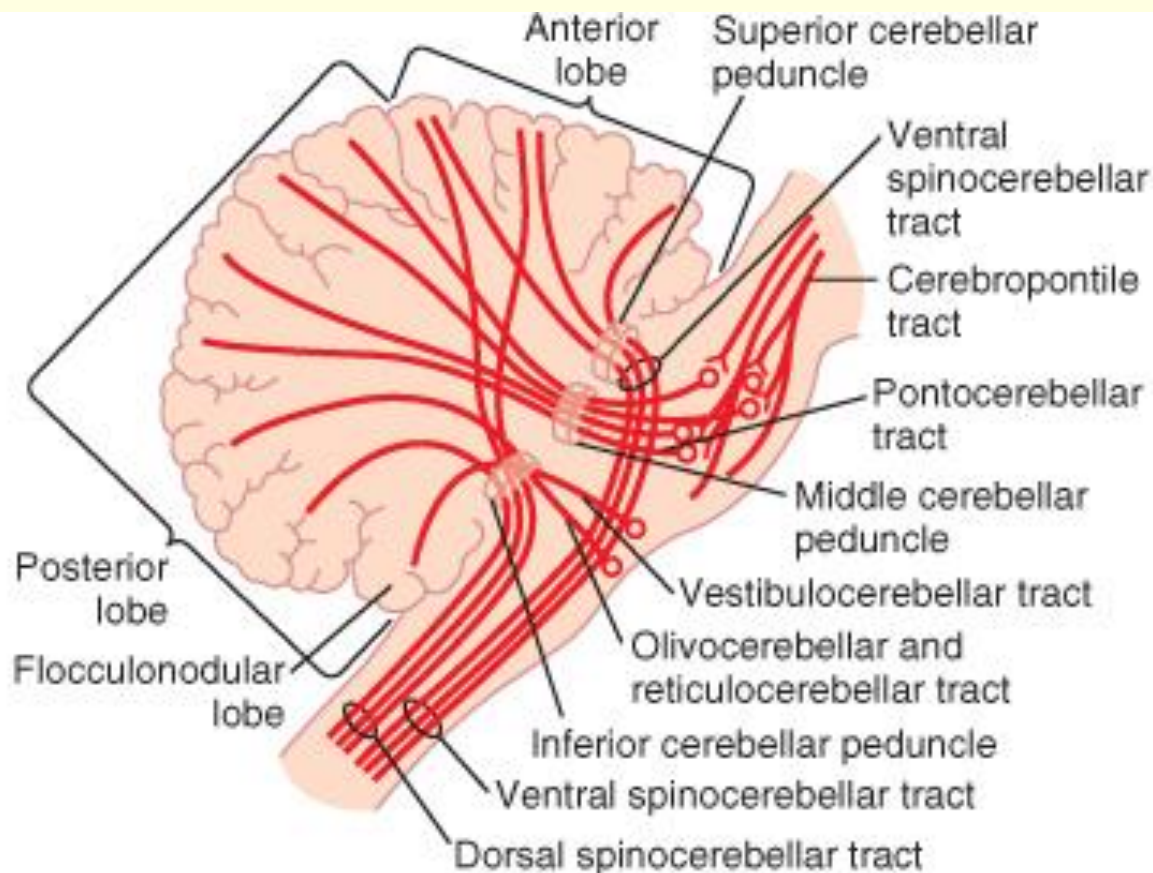
Inferior Cerebellar Peduncle

Inputs to the Cerebellum from the Medulla Oblongata

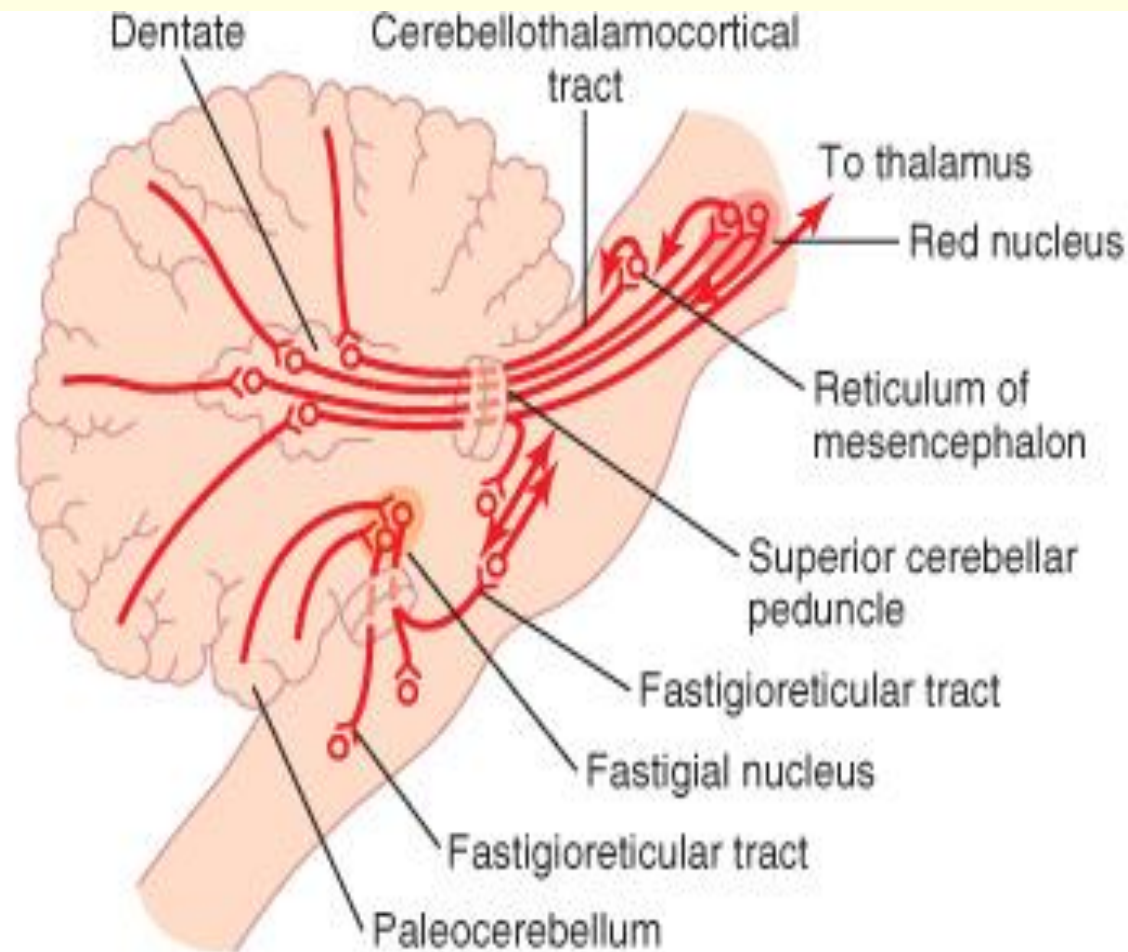
PRINCIPAL AFFERENT TRACTS TO THE CEREBELLUM

AFFERENT TRACTS	TRANSMITS
Vestibulocerebellar	Vestibular impulses from labyrinths, direct & via vestibular nuclei.
Dorsal Spinocerebellar	Proprioceptive & exteroceptive impulses from the body.
Ventral Spinocerebellar	Proprioceptive & exteroceptive impulses from the body.
Cuneocerebellar	Proprioceptive impulses, especially from the head and neck.
Tectocerebellar	Auditory & visual impulses via inferior and superior colliculi.
Pontocerebellar	Impulses from motor and other parts of cerebral cortex via pontine nuclei.
Olivocerebellar	Proprioceptive input from whole body via relay in inferior olive.

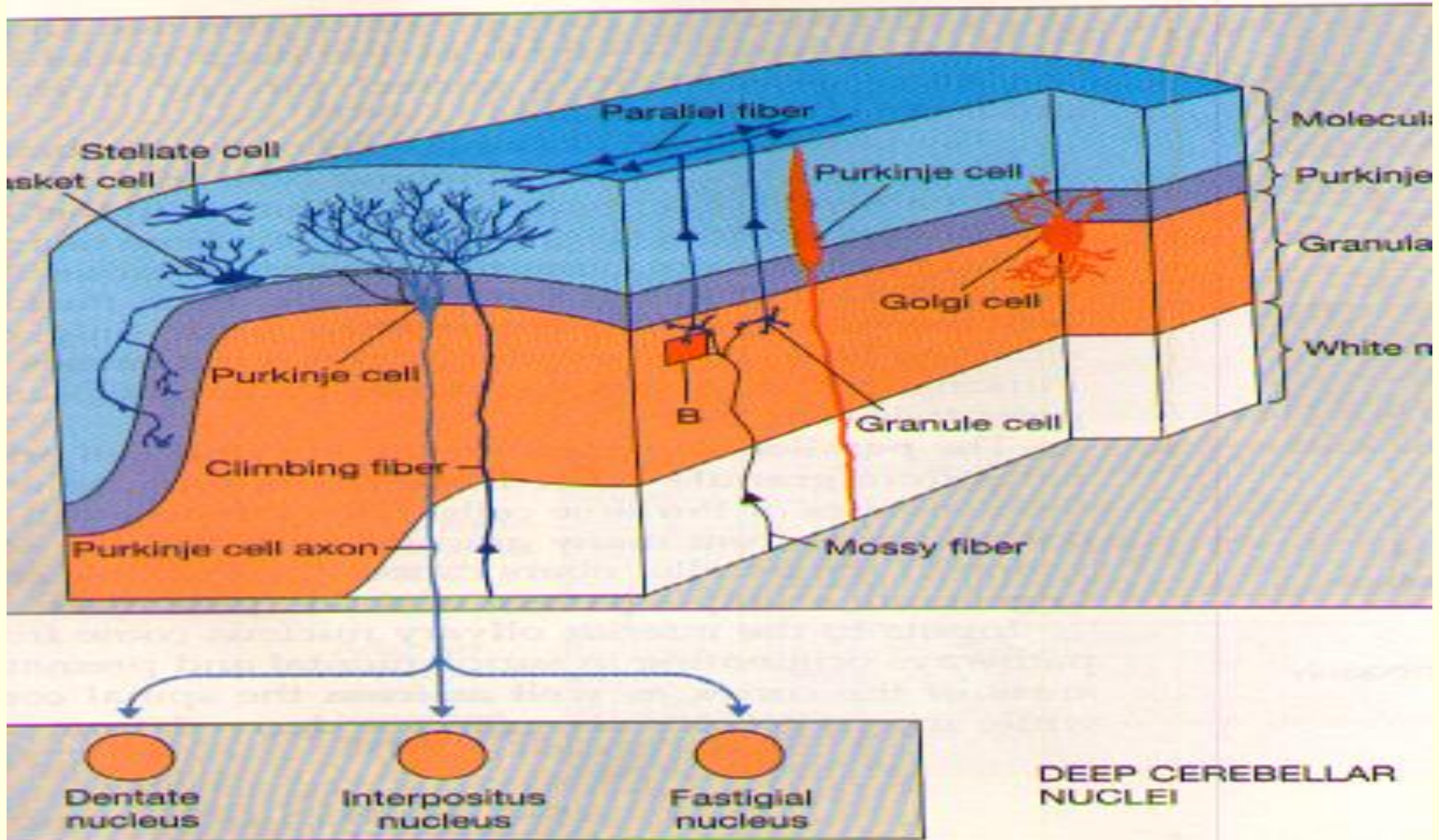
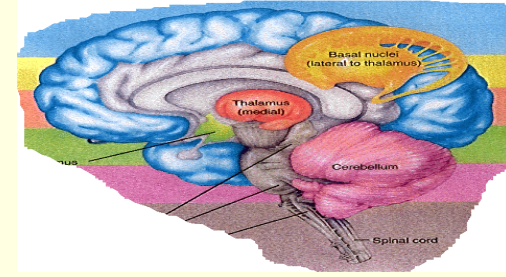
PRINCIPAL AFFERENT TRACTS TO THE CEREBELLUM



PRINCIPAL EFFERENT TRACTS TO THE CEREBELLUM



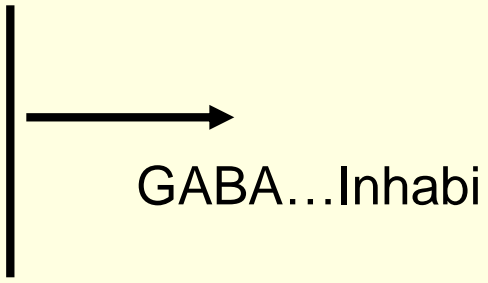
TYPES OF THE CELLS IN THE CEREBELLUM



CEREBELLUM LAYERS

The cerebellum has an external cerebellar cortex separated by white matter from the deep cerebellar nuclei as follows:

Cerebellar Cortex

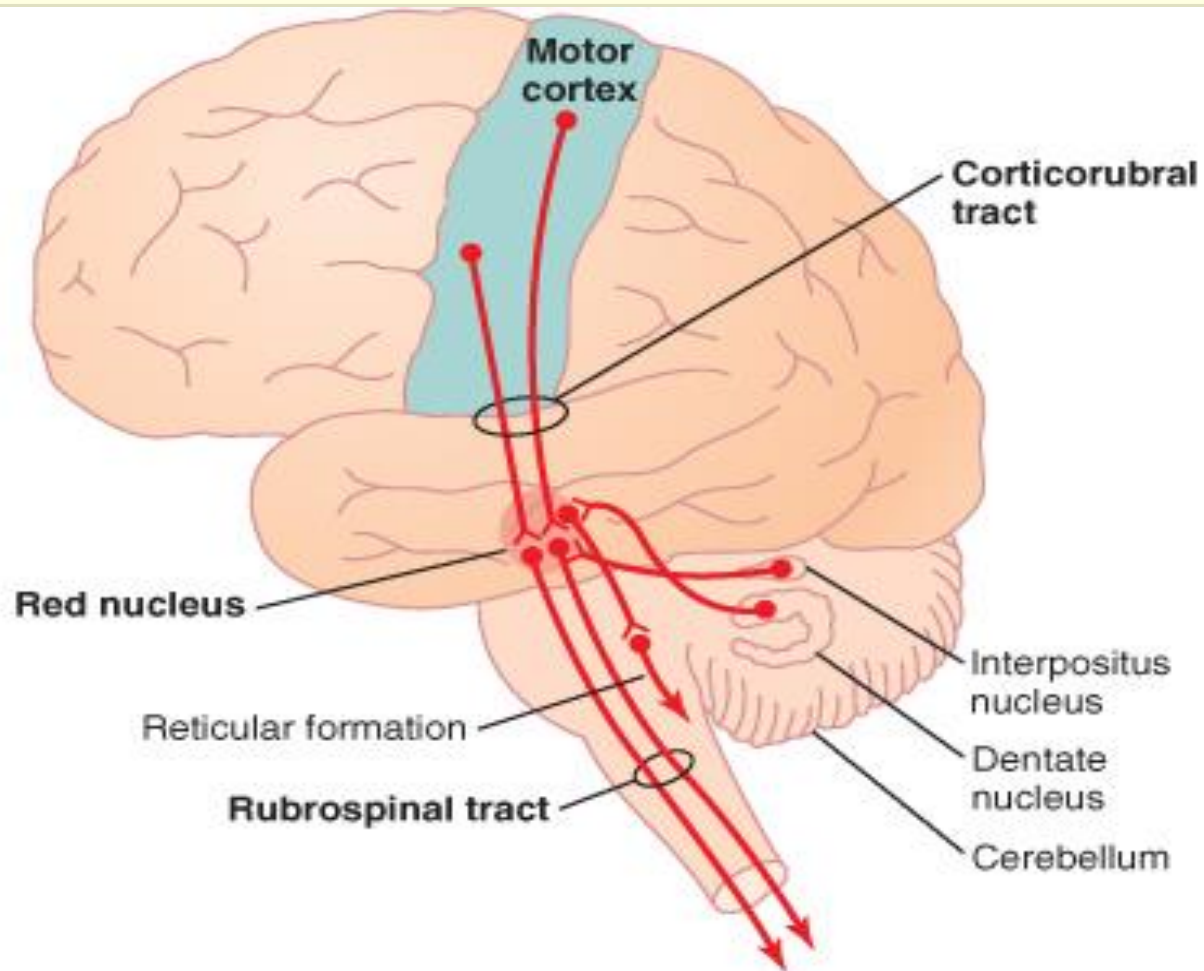
- Molecular Layer
 - Purkinje Cell Layer
 - Granular Layer
- Purkinje cells
 - Basket cells
 - Golgi cells
 - Stellate cells
- 
- GABA...Inhabi

Cerebellar Nuclei

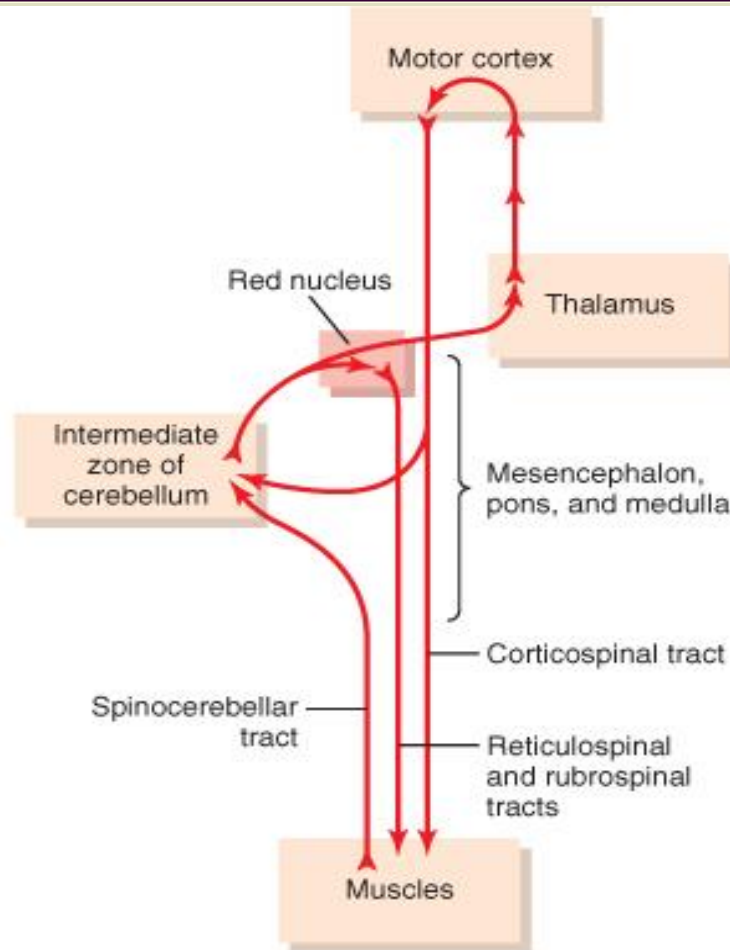
- Dentate Nucleus
 - Globose Nucleus
 - Emboliform Nucleus
 - Fastigial Nuclei
- Granular cells → Glutamate...Exci
 - Stellate cells: Taurine.....Inhabi

Note: [Globose and Emboliform also known as interpositus nucleus]

NUCLEI OF THE CEREBELLUM

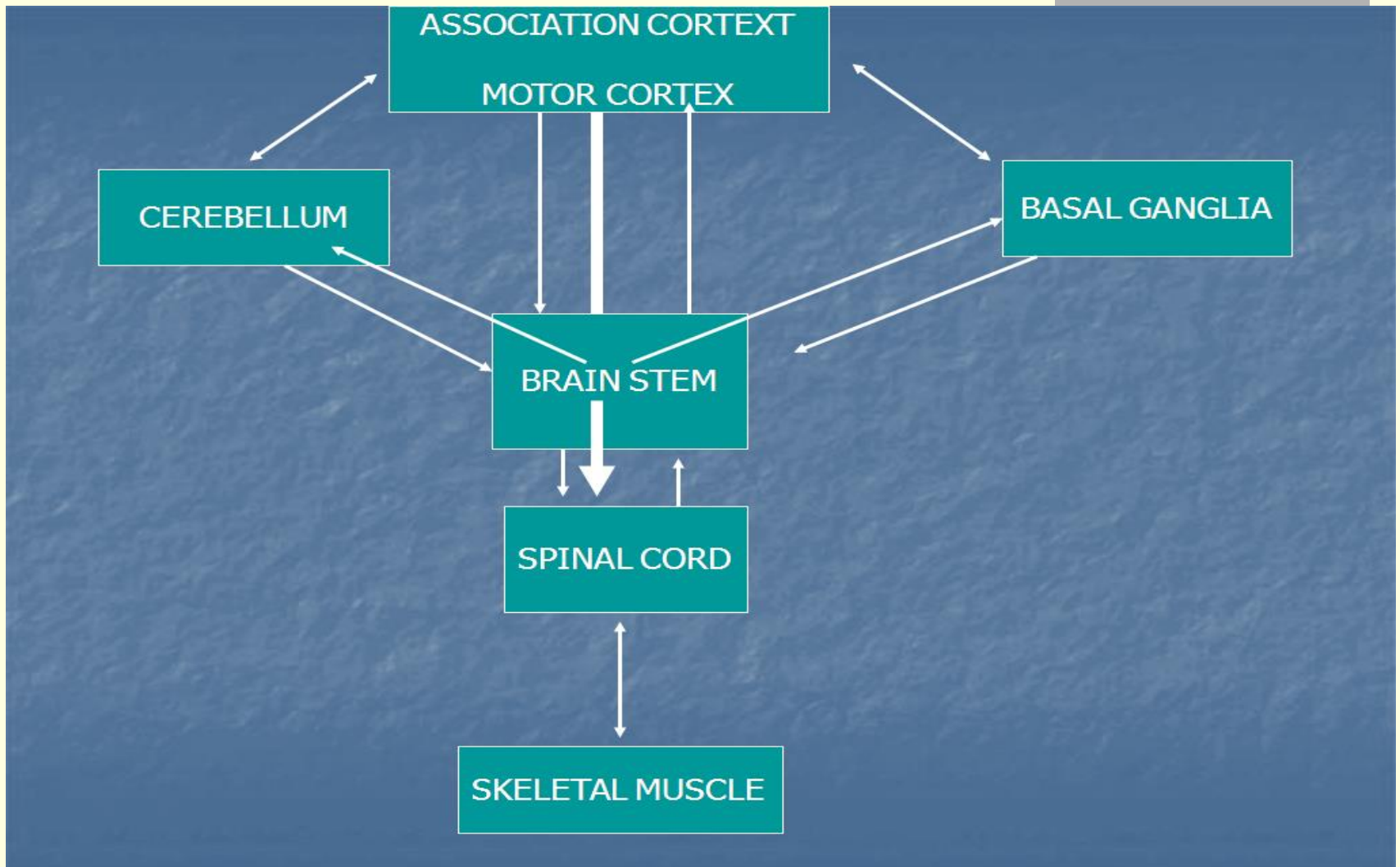


CEREBELLUM AND VOLUNTARY MOTOR CONTROL



Cerebral and cerebellar control of voluntary movements, involving especially the intermediate zone of the cerebellum.

CONNECTIONS OF THE CEREBELLUM

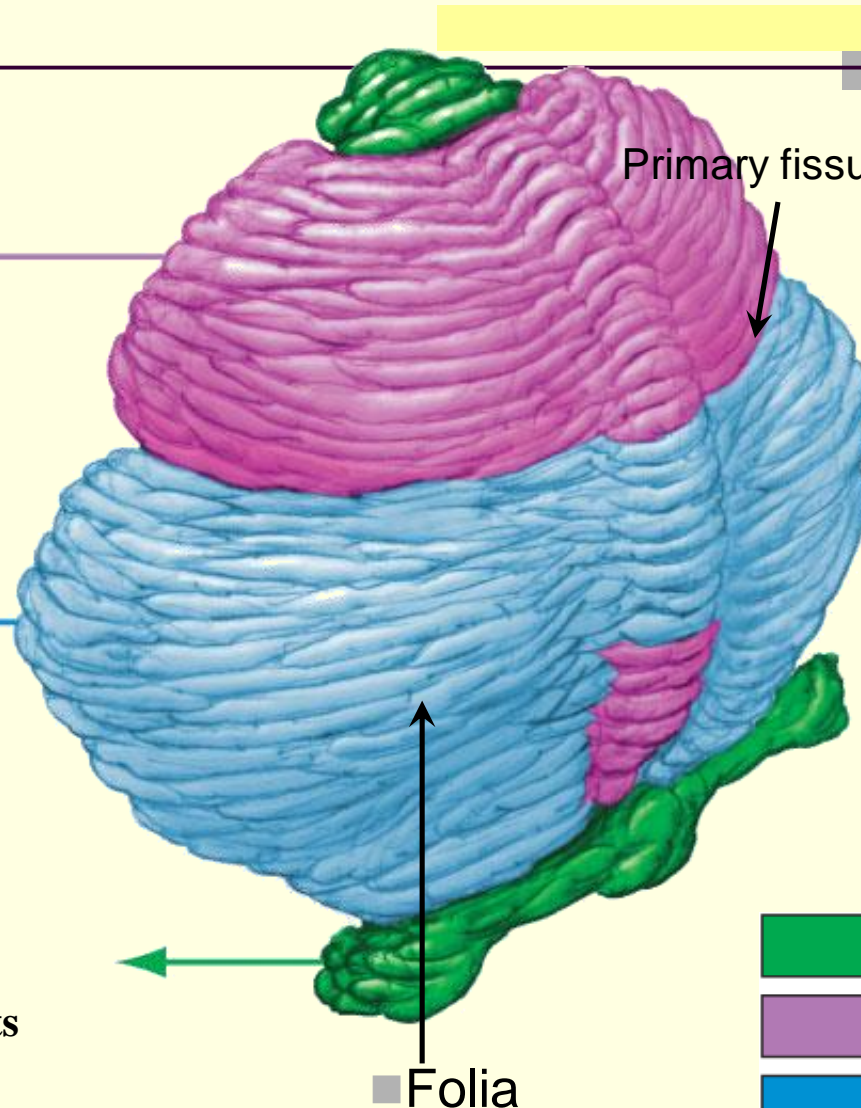


CEREBELLUM

It makes the movements smooth and coordinated

It interacts with motor cortex in planning & programming of movements.




Maintenance of balance, control of eye movements



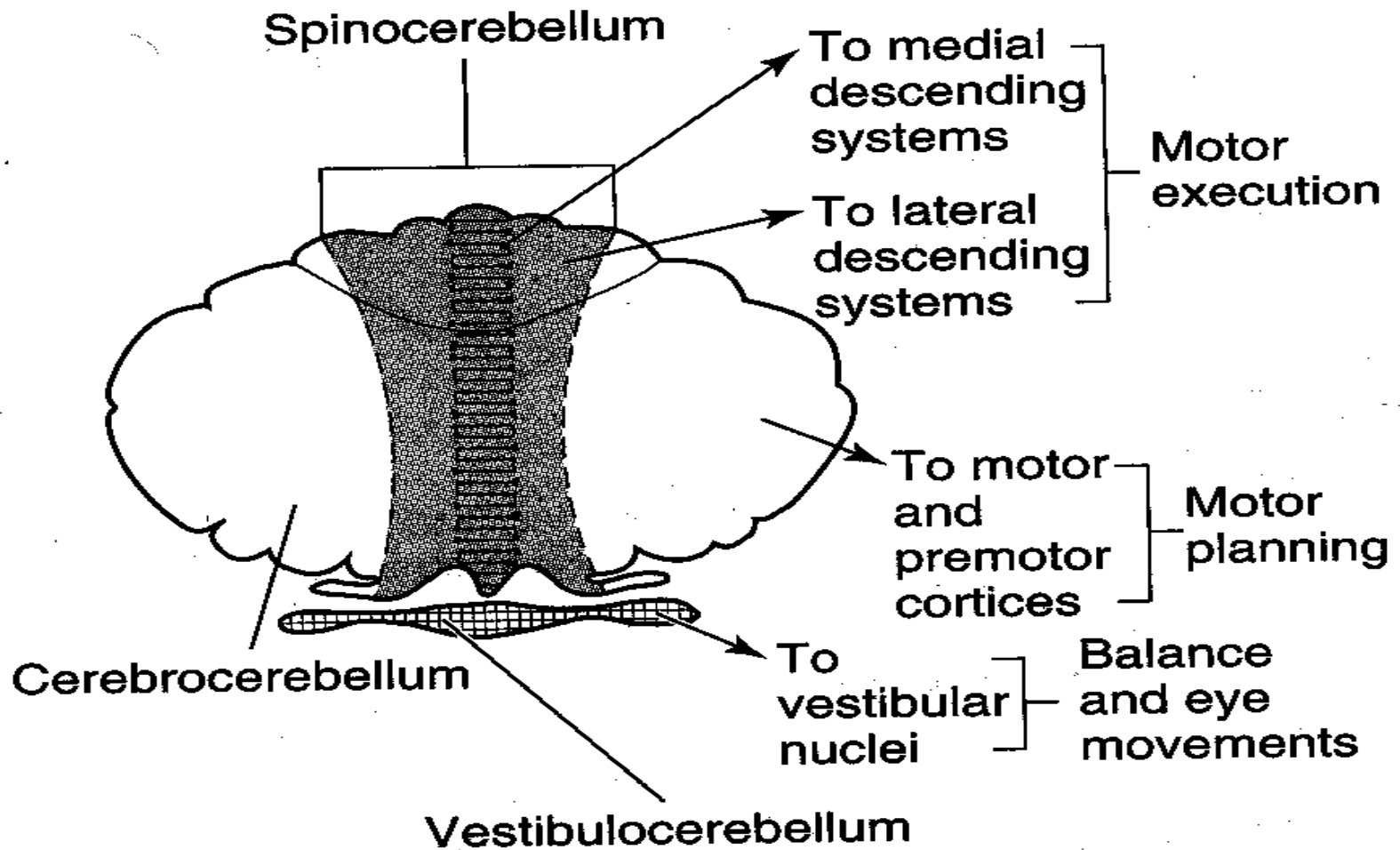
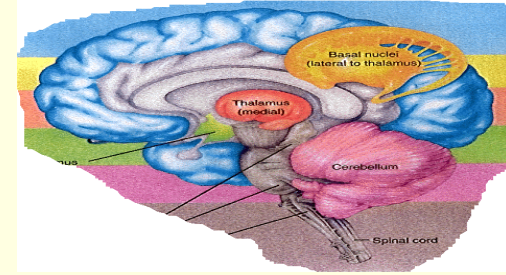
Anterior Lobe

Posterior Lobe

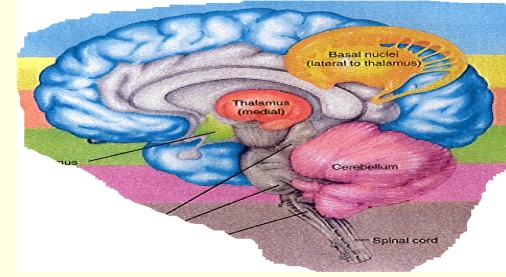
Flocculo-Nodular Lobe (FN lobe)

-  Vestibulocerebellum
-  Spinocerebellum
-  Cerebrocerebellum

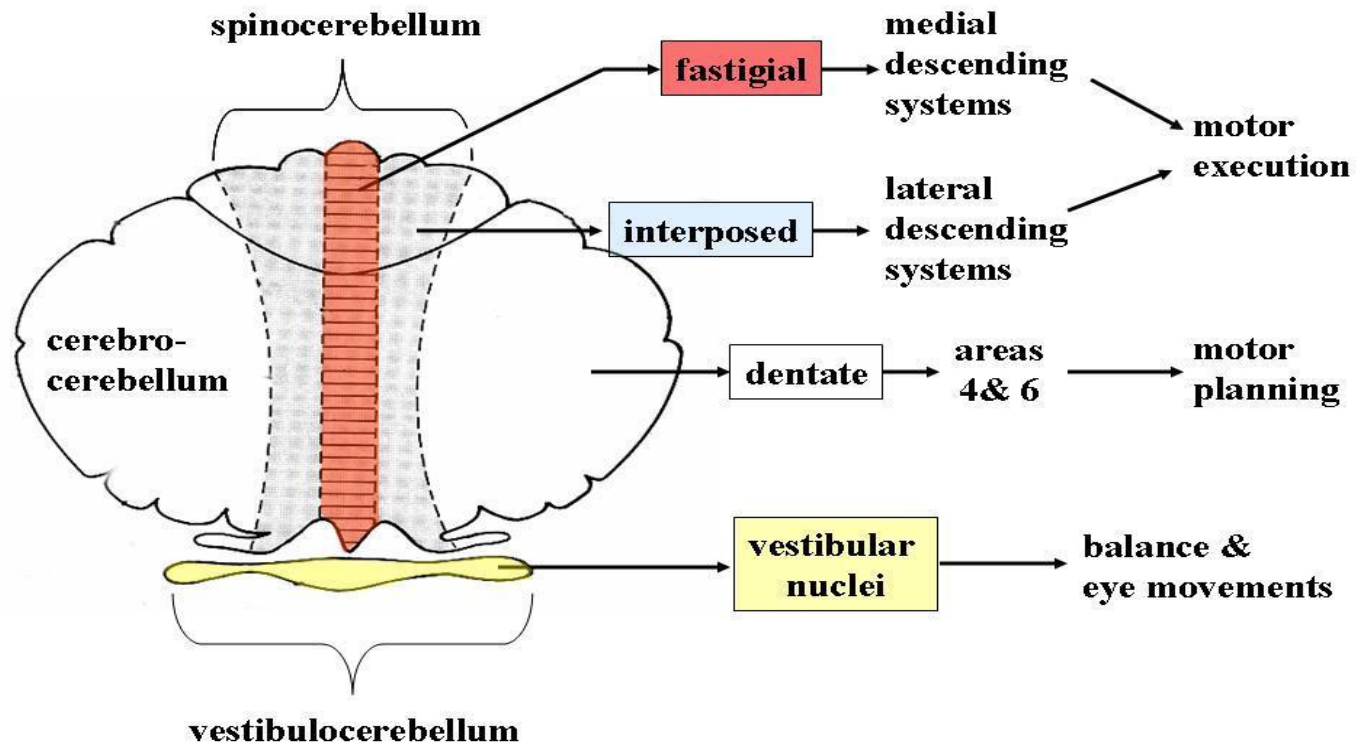
FUNCTIONAL DIVISION OF THE CEREBELLUM



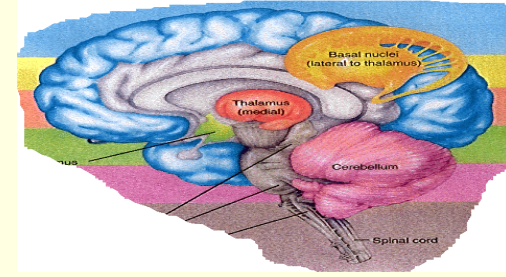
FUNCTIONAL DIVISION OF THE CEREBELLUM



Cerebellar Output



SUMMARY: FUNCTIONS OF CEREBELLUM



Cerebellum Lobe	Nuclei	Cortex	Inputs	Outputs	Function
Paleocerebellum	Interposed; Fastigial	Vermis & Medial portions of Cerebellar hemispheres	Spinal and brainstem paths	SCP to Red Nucleus; Fastigial to RF	Muscle tone, posture & coordination of movements
Neo-cerebellum	Dentate	Lateral portions of Cerebellar Hemisphere	Corticopontine/ pontocerebellar	SCP	Planning and executive of voluntary & skilled hand movements
Archi cerebellum	Fastigial	Flocculonodular	Vestibular nuclei	Vestibular nuclei; RF	Balance, equilibrium

CLINICAL FEATURES / TESTS RELATED TO CEREBELLUM

Ataxia	Reeling, wide-based gait
Decomposition of movement	Inability to correctly sequence fine, coordinated acts
Dysarthria	Inability to articulate words correctly, with slurring and inappropriate phrasing
Dysdiadochokinesia	Inability to perform rapid alternating movements
Dysmetria	Inability to control range of movement
Hypotonia	Decreased muscle tone
Nystagmus	Involuntary, rapid oscillation of the eyeballs in a horizontal, vertical, or rotary direction, with the fast component maximal toward the side of the cerebellar lesion
Scanning speech	Slow enunciation with a tendency to hesitate at the beginning of a word or syllable
Tremor	Rhythmic, alternating, oscillatory movement of a limb as it approaches a target (intention tremor) or of proximal musculature when fixed posture or weight bearing is attempted (postural tremor)


FINGER NOSE TEST



While the examiner holds his finger at arm's length from the patient. Patient touches her nose and then touches the examiner's finger. After several sequences, the patient is asked to repeat the exercise with her closed eyes.

A patient with a cerebellar disorder tends to miss the target.

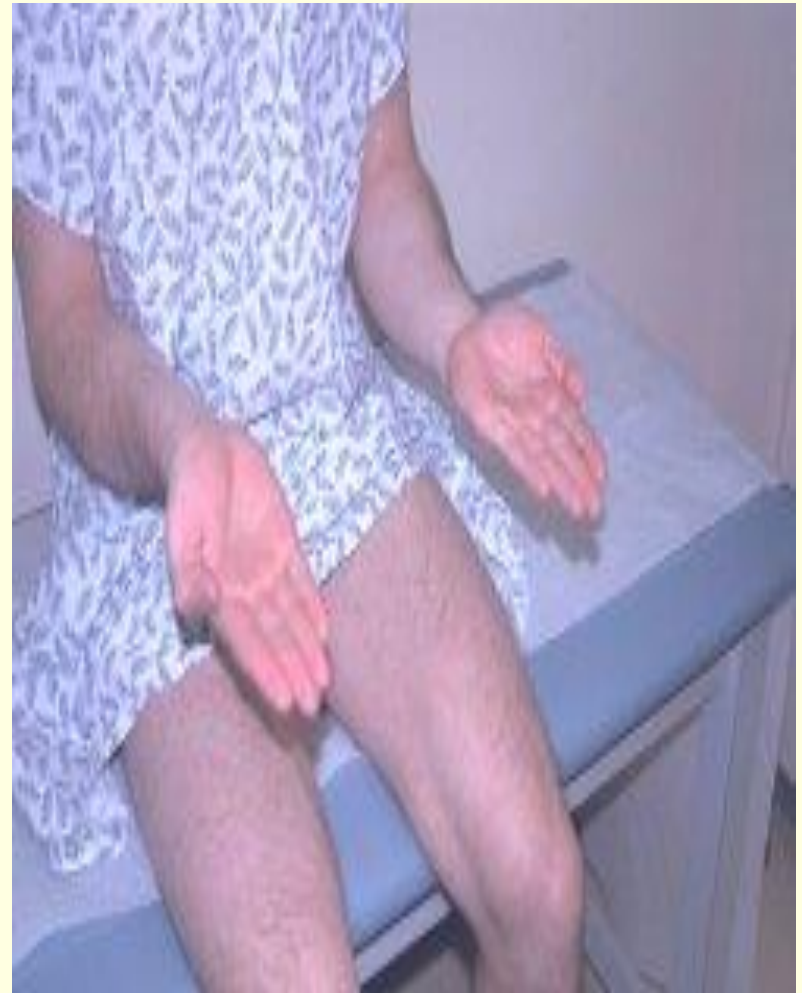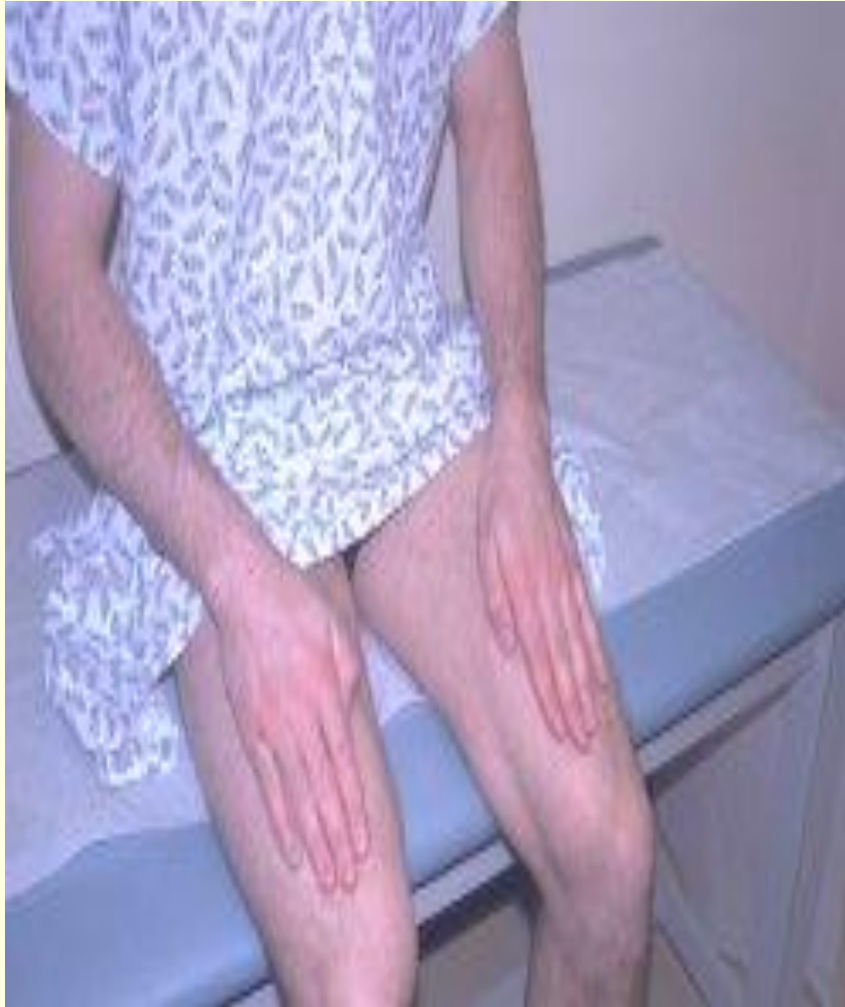FINGER NOSE TEST



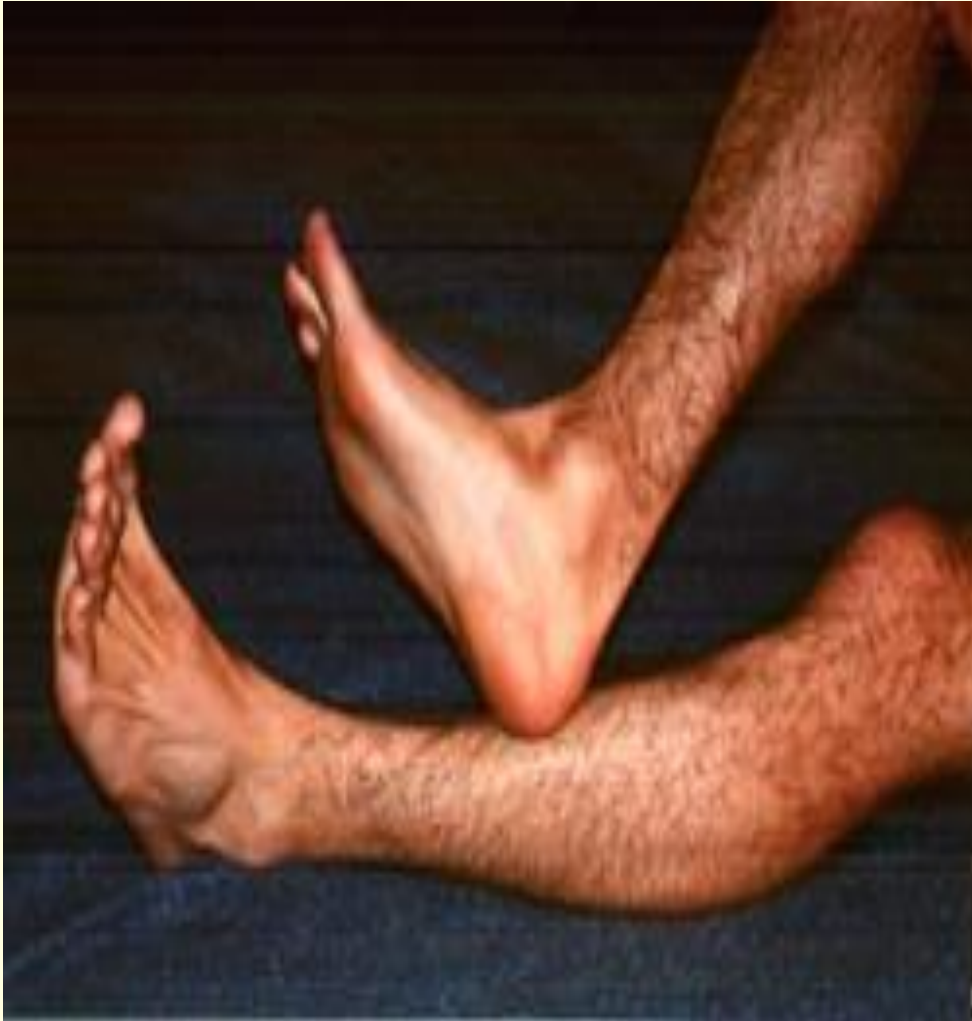DYSDIADOCHOKINESIS: RAPIDLY ALTERNATING MOVEMENTS

Dysdiadochokinesis: Inability to perform rapidly alternating movements. Is called dysdiadochokinesia. It is usually caused by multiple sclerosis in adults and cerebellar tumors in children. Patients with other movement disorders (e.g. Parkinson's disease) may have abnormal rapid alternating movement testing secondary to akinesia or rigidity, thus creating a false impression of dysdiadochokinesia.

DYSDIADOCHOKINESIS: RAPIDLY ALTERNATING MOVEMENTS



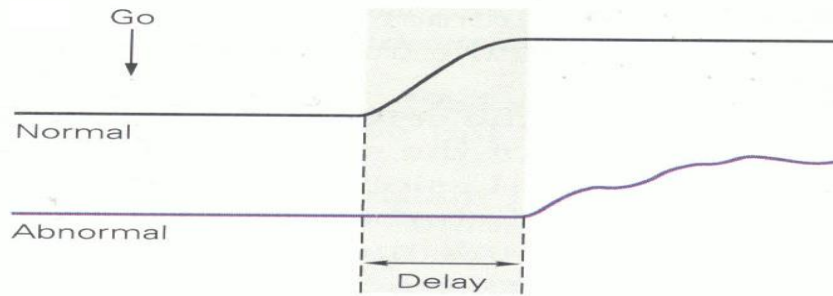
HEEL TO SHIN TEST



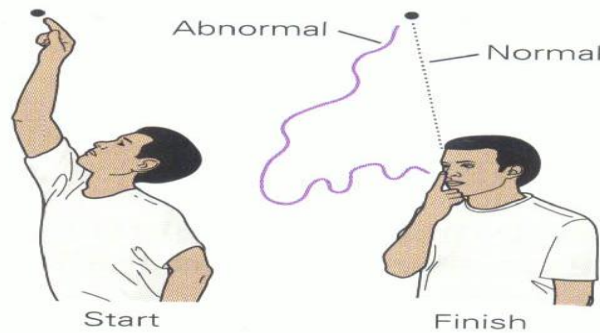
The heel to shin test is a measure of coordination and may be abnormal if there is loss of motor strength, proprioception or a cerebellar lesion.

If motor and sensory systems are intact, an abnormal, asymmetric heel to shin test is highly suggestive of an ipsilateral cerebellar lesion.

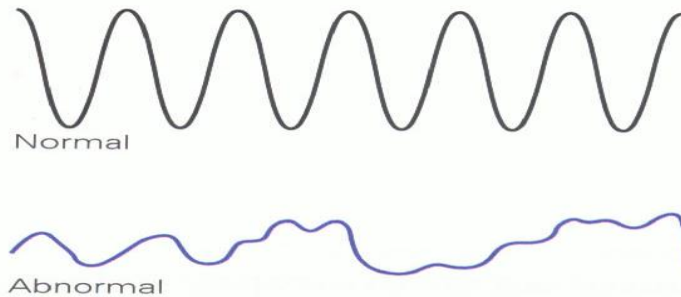
CEREBELLAR SIGNS



Response delays
Hypometria &



Ataxia



Incoordination/ rapid alternating
movements (disdiadocho kinesia)

THANK YOU

