

**GNB**

Pathology  
2019

**Peptic Ulcer Disease**

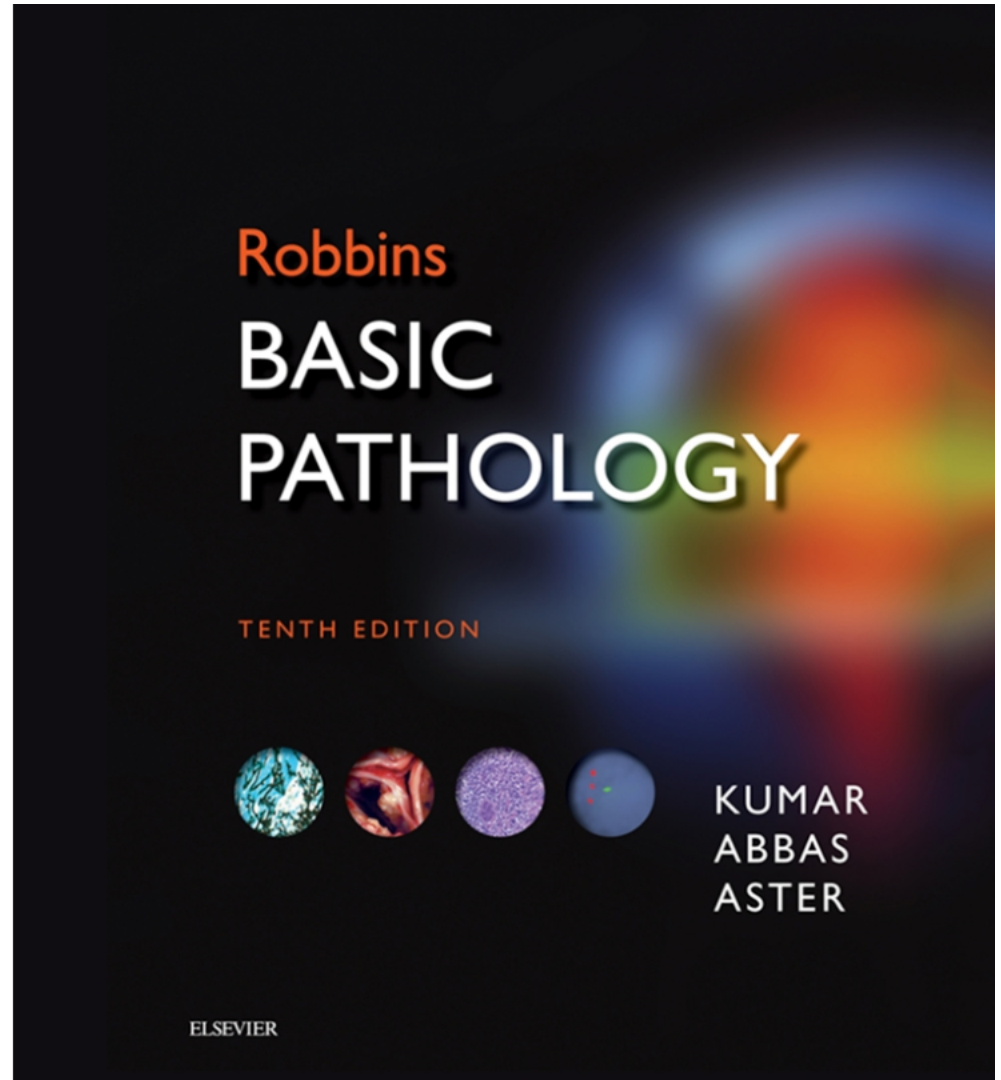
Dr. Maha Arafah  
Dr. Ahmed Al Humaidi

# Objectives

1. Define ulcer and erosion
2. Describe the following aspects of acute gastric ulcers:
  - a. Pathogenesis
  - b. Pathology
  - c. Clinical features
3. Describe the following aspects of chronic peptic ulcers:
  - a. Pathogenesis (*H pylori*, NSAID, Z-E syndrome)
  - b. Clinical features
  - c. Pathology (gross and microscopic features)
  - d. Complications (bleeding, perforation, obstruction)

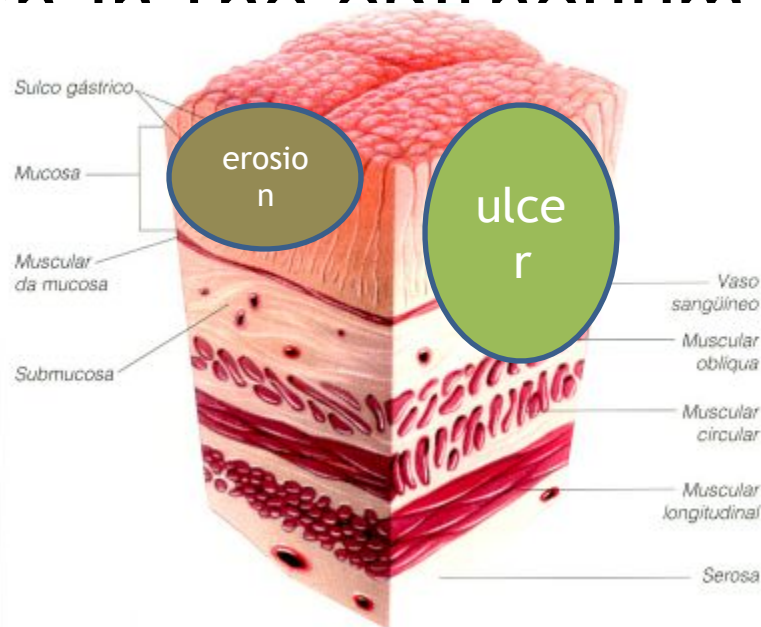
# Book

Basic pathology, 10<sup>th</sup> edition:  
page 598 -603



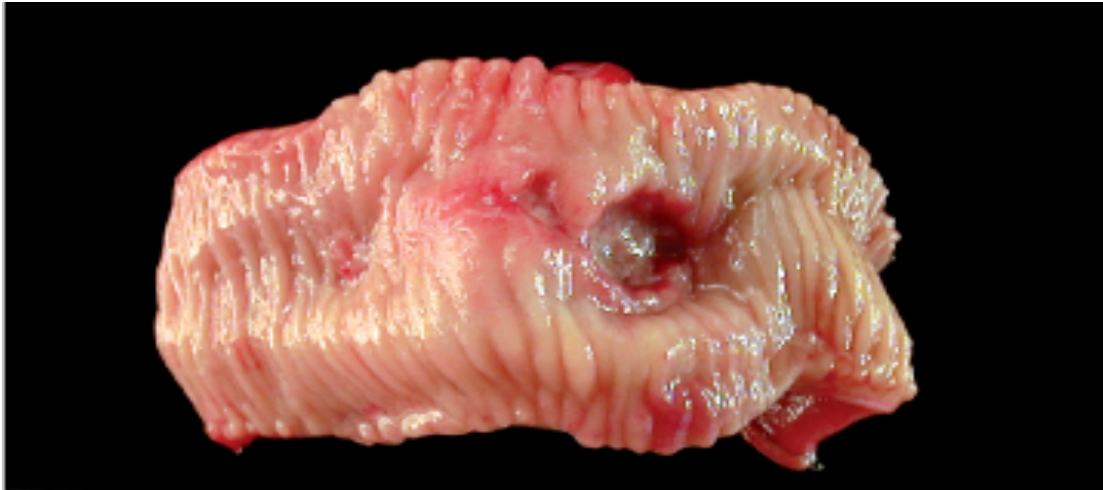# 1. Define ulcer and erosion

- **Ulcer:** a breach in the mucosa of the alimentary tract extending through muscularis mucosa into submucosa or deeper.
- **Erosion:** is a breach in the epithelium of the mucosa only.

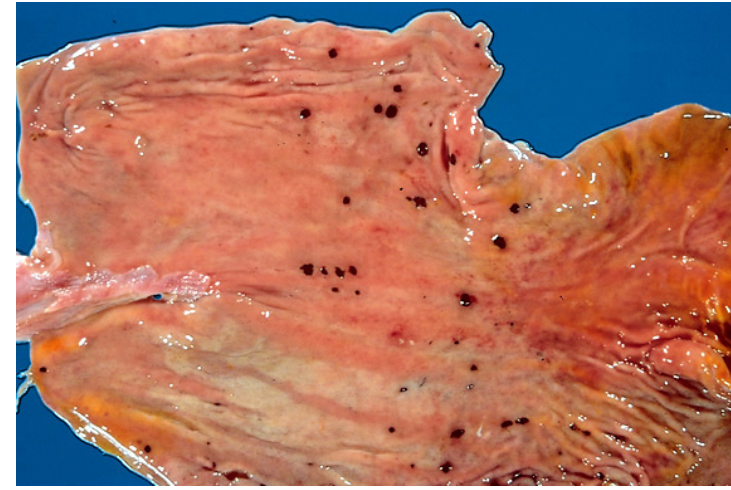


# Ulcer

1. *Chronic Peptic ulcer*
2. *Stress ulcers (acute peptic ulcers)*



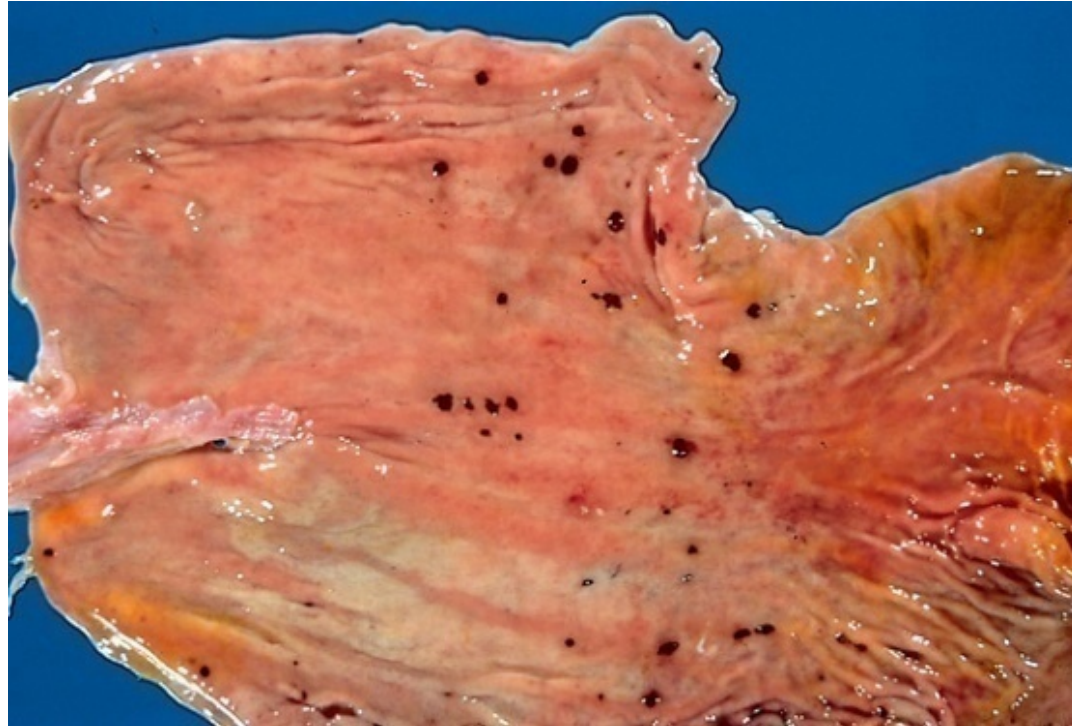
*Chronic peptic ulcer*



*Acute gastric ulcers*

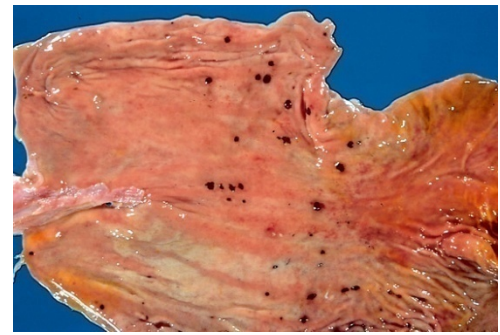
## Acute peptic ulcers

- Acutely developing gastric mucosal defects that may appear after severe stress



# Acute gastric ulcers

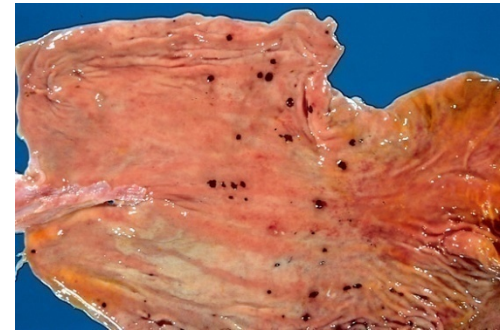
## Acute peptic ulcers Pathophysiology



- As part of an acute *gastritis*
- As a complication of a severe *stress response*
- As a result of extreme *hyperacidity*.

## Acute peptic ulcers

### Pathophysiology



- As part of an acute *gastritis*

acute response to an irritant 'chemical' injury by drugs e.g. NSAID or alcohol

- As a complication of a severe *stress*

severe burns (Curling's ulcer)

major trauma (Stress ulcer)

cerebrovascular accidents (Cushing ulcer)

- As a complication of *hyperacidity*  
Zollinger-Ellison syndrome



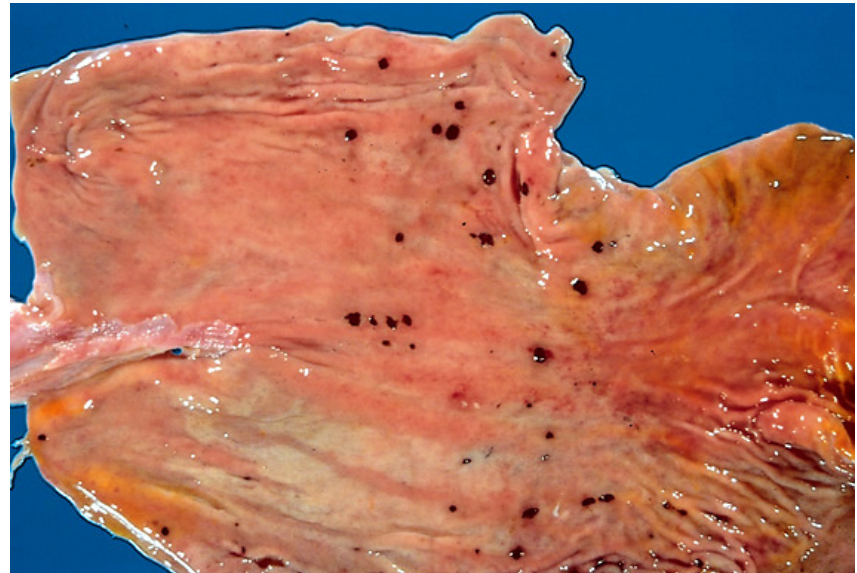
## Acute peptic ulcers

Location: Acute stress ulcers are found anywhere in the stomach

Morphology: They range in depth from very superficial lesions (erosion) to deeper lesions that involve the entire mucosal thickness (true ulceration)

Clinical findings:

- a. Hematemesis
- b. Melena
- c. Iron deficiency



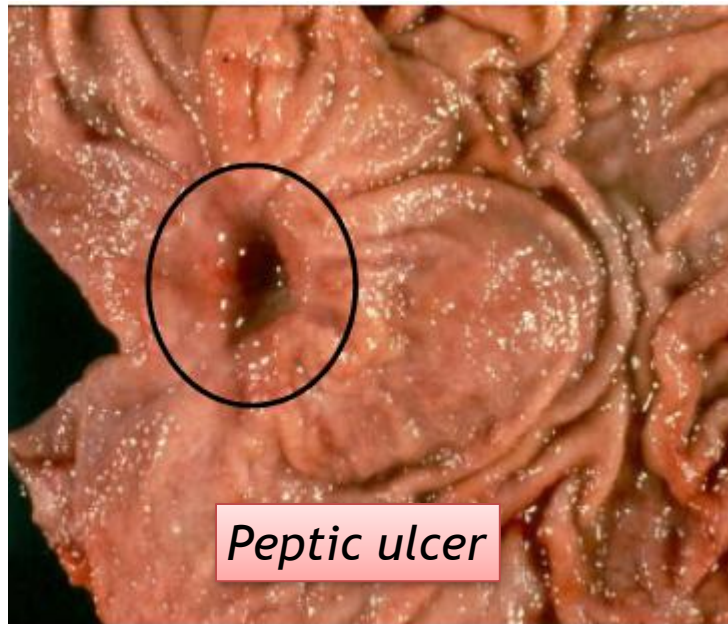
Prognosis: The gastric mucosa can recover completely if the person does not die from the primary disease

# Chronic Peptic Ulcer

## Chronic Peptic Ulcer

Peptic ulcers are chronic, recurring lesions that occur most often in middle-aged to older adults without obvious precipitating conditions, other than chronic gastritis.

Chronic Peptic Ulcers are most often solitary



# Pathophysiology of Chronic Peptic Ulcer

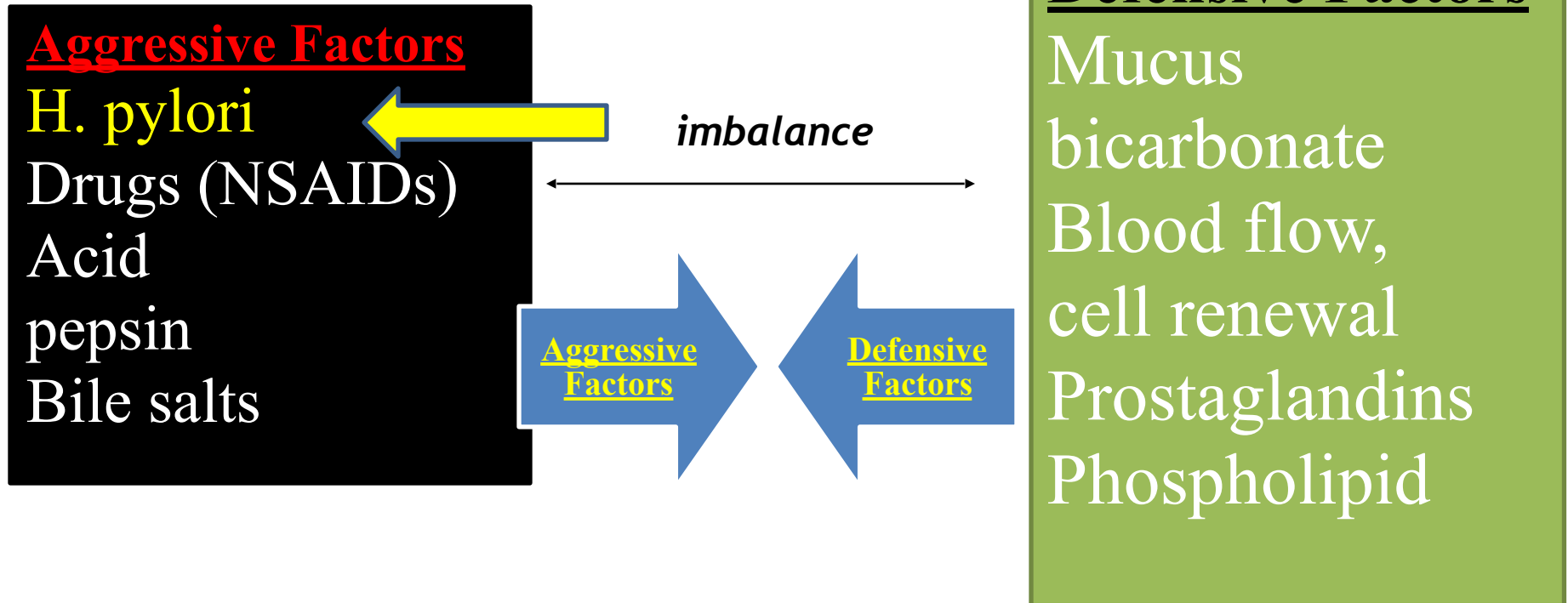
The diagram consists of two blue arrows pointing towards each other, meeting at a central point. The left arrow is labeled 'Aggressive Factors' and the right arrow is labeled 'Defensive Factors'. The text is in a yellow, serif font.

**Aggressive  
Factors**

**Defensive  
Factors**

# Chronic gastric ulcers

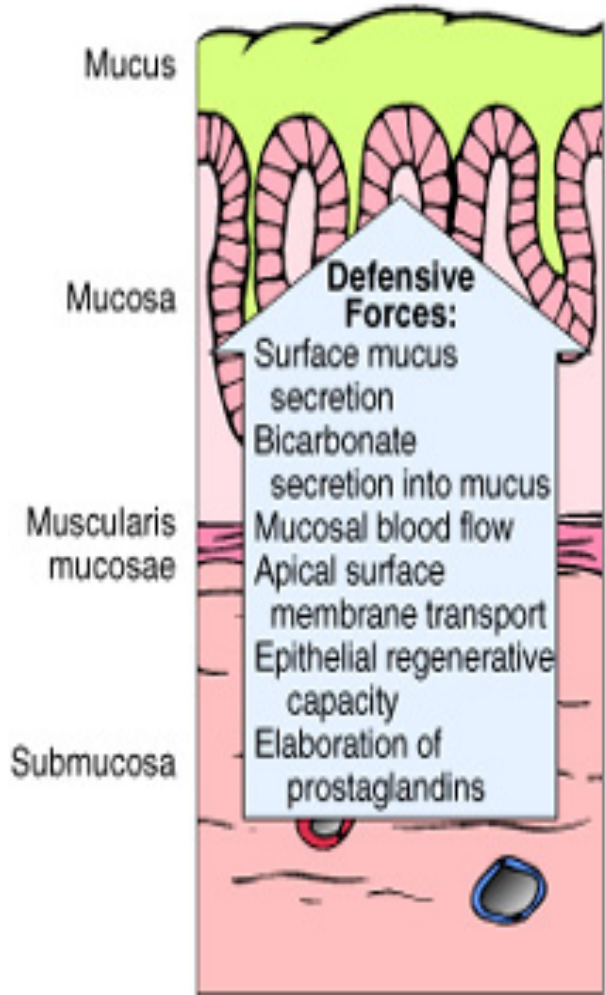
## Pathophysiology



# Chronic gastric ulcers

NORMAL

**Damaging Forces:**  
Gastric acidity  
Peptic enzymes



**Defensive Forces:**  
Surface mucus secretion  
Bicarbonate secretion into mucus  
Mucosal blood flow  
Apical surface membrane transport  
Epithelial regenerative capacity  
Elaboration of prostaglandins

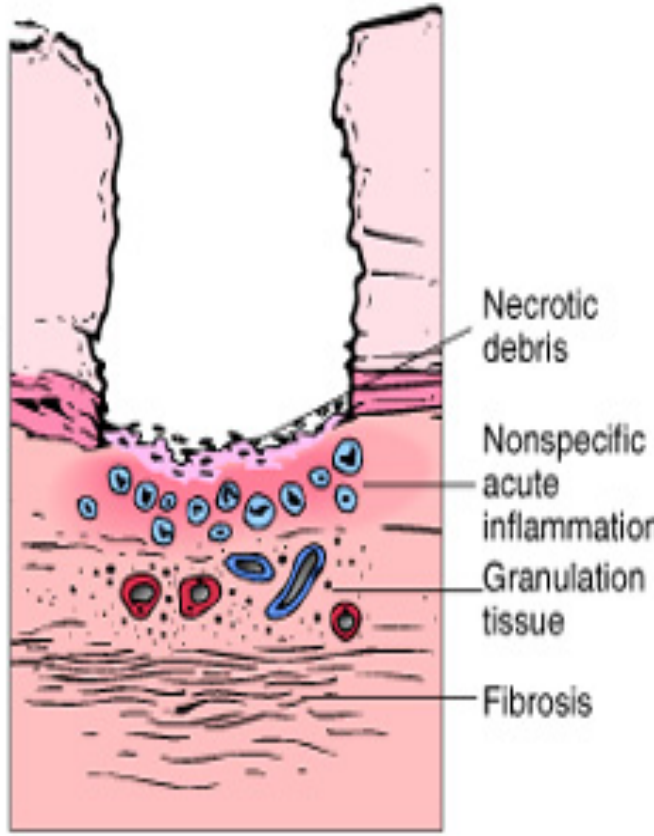
INCREASED DAMAGE

*H. pylori* infection  
NSAID  
Aspirin  
Cigarettes  
Alcohol  
Gastric hyperacidity  
Duodenal-gastric reflux

OR  
**IMPAIRED DEFENSES**

Ischemia  
Shock  
Delayed gastric emptying

PEPTIC ULCERATION



## Pathophysiology of Chronic Peptic Ulcer

### Helicobacter pylori infection

H. pylori infection of gastric mucosa is present in 100% of patients with duodenal ulcer and 70% of those with gastric ulcer. H pylori infection is a major factor in the pathogenesis of peptic ulcer.

H. pylori induces an intense inflammatory and immune response with increased production of **proinflammatory cytokines**.

H. pylori secretes a **urease** that breaks down urea to form toxic compounds such as ammonium chloride and monochloramine.

**Thrombotic occlusion of surface capillaries** is promoted by a bacterial platelet-activating factor. Other antigens, **including lipopolysaccharides**, recruit inflammatory cells to the mucosa. The chronically inflamed mucosa is more susceptible to acid-peptic injury and peptic ulceration.

In addition, chronic inflammation of the mucosa is possibly important in the pathogenesis of gastric carcinoma and a low-grade gastric lymphoma, also known as MALToma (MALT: Mucosa-Associated Lymphoid Tissue).

*interleukin-1,  
interleukin-6,  
interleukin-8 and  
tumor necrosis  
factor*

## Pathophysiology of Chronic Peptic Ulcer

### Other causes:

NSAID and aspirin stop prostaglandin synthesis  
The protective effects of prostaglandins: enhanced bicarbonate secretion and increased vascular perfusion.

High-dose corticosteroids, which suppress prostaglandin synthesis and impair healing.

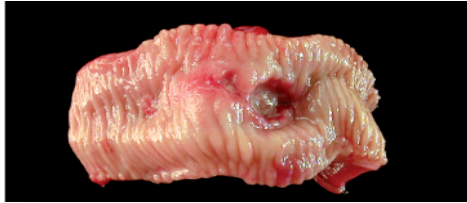
Cigarette smoking: impairs mucosal blood flow and healing

Chronic renal failure, and hyperparathyroidism: associated with hypercalcemia: stimulates gastrin production and therefore increases acid secretion

Psychological stress (can increase gastric acid secretion)



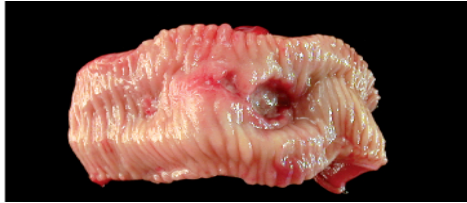
# Chronic gastric ulcers



## Chronic peptic ulcer Peptic Ulcer Disease Locations

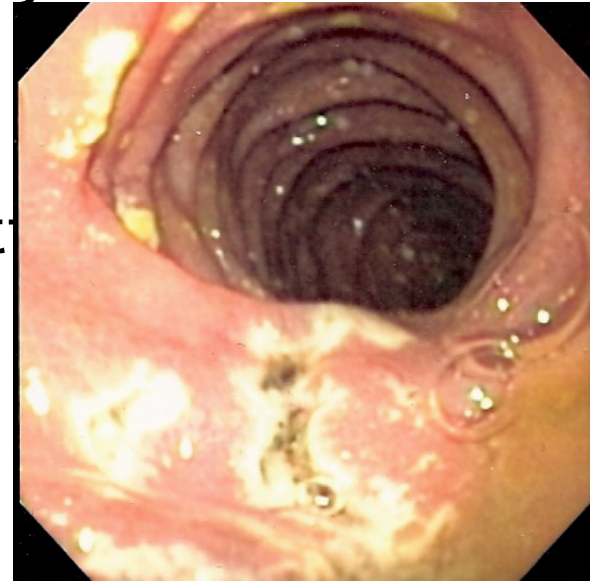
- May occur in any portion of the GI tract exposed to acidic gastric juices
- 98% located in **first portion of duodenum or stomach**, ratio duodenum : stomach = 4:1

# Chronic gastric ulcers

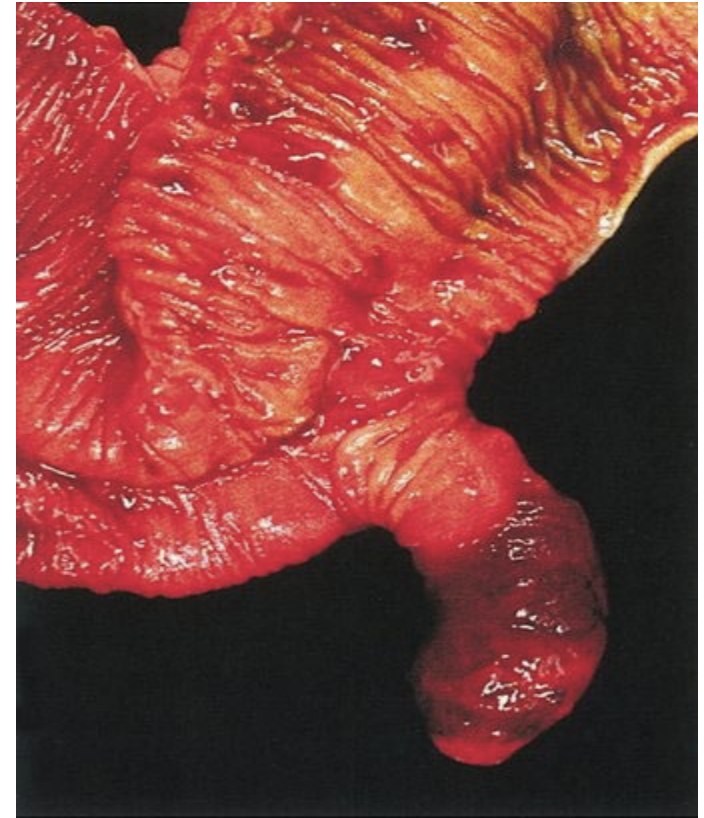
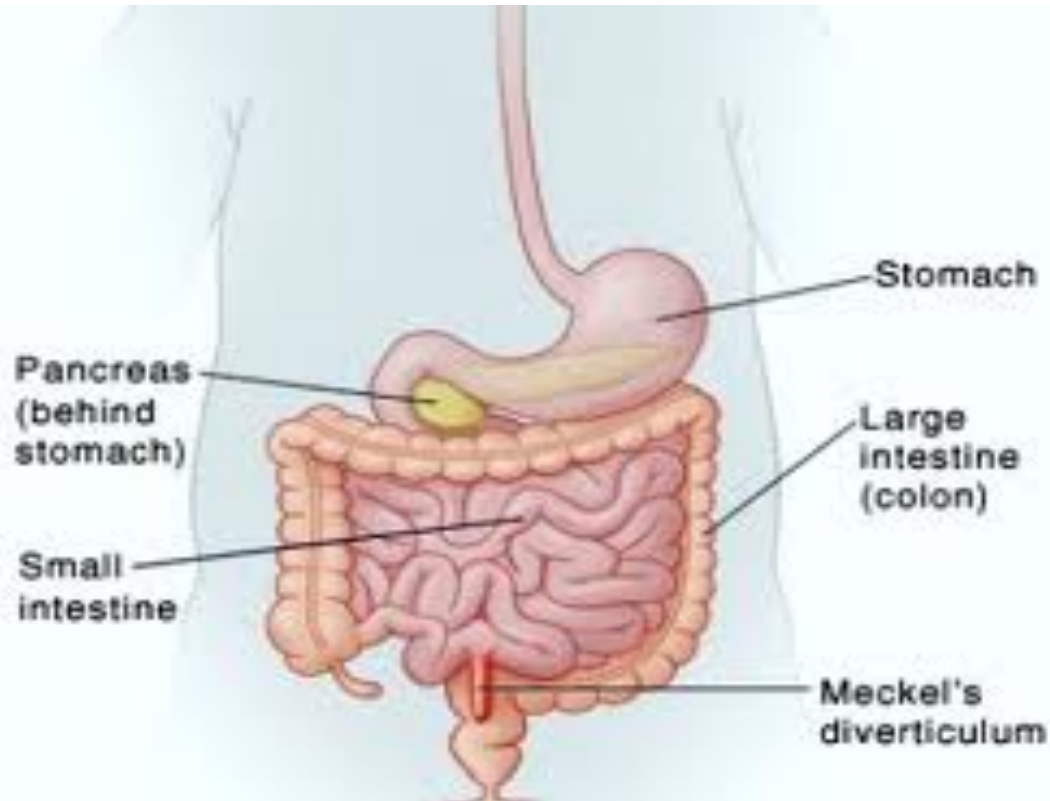


## Chronic peptic ulcer Peptic Ulcer Disease Other Locations

- *Esophagus..... as a result of GERD or acid secretion by ectopic gastric mucosa.*
- *Gastric mucosa within a Meckel diverticulum can result in peptic ulceration of adjacent mucosa.*
- *In Zollinger-Ellison syndrome: multiple peptic ulcerations in the stomach, duodenum, and even the jejunum.*



## *Meckel diverticulum*



most common congenital abnormality of the small intestine  
caused by an incomplete obliteration of the vitelline duct

# Gastric ulcers

□ The mucosal defences against acid attack consist of:

1. Mucus-bicarbonate barrier
2. The surface epithelium.

## Peptic Ulcer Disease Gastric ulcers

□ The mucosal defences against acid attack consist of:

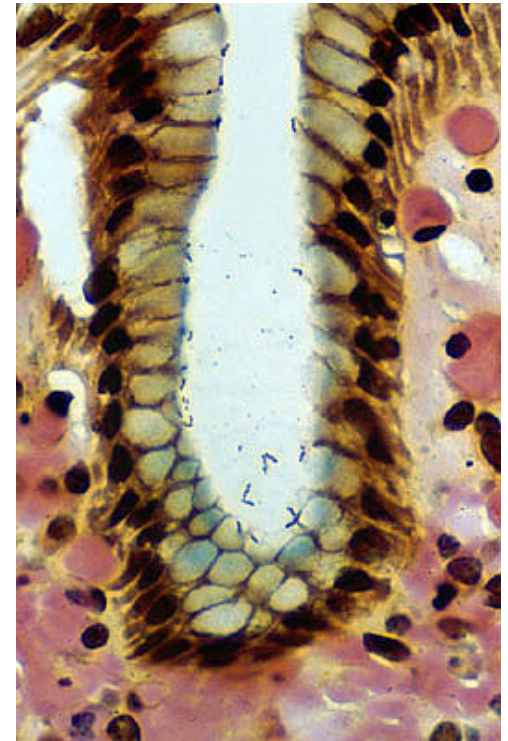1. **Mucus-bicarbonate barrier**

Duodeno-gastric reflux  
(bile)

2. **The surface epithelium.**

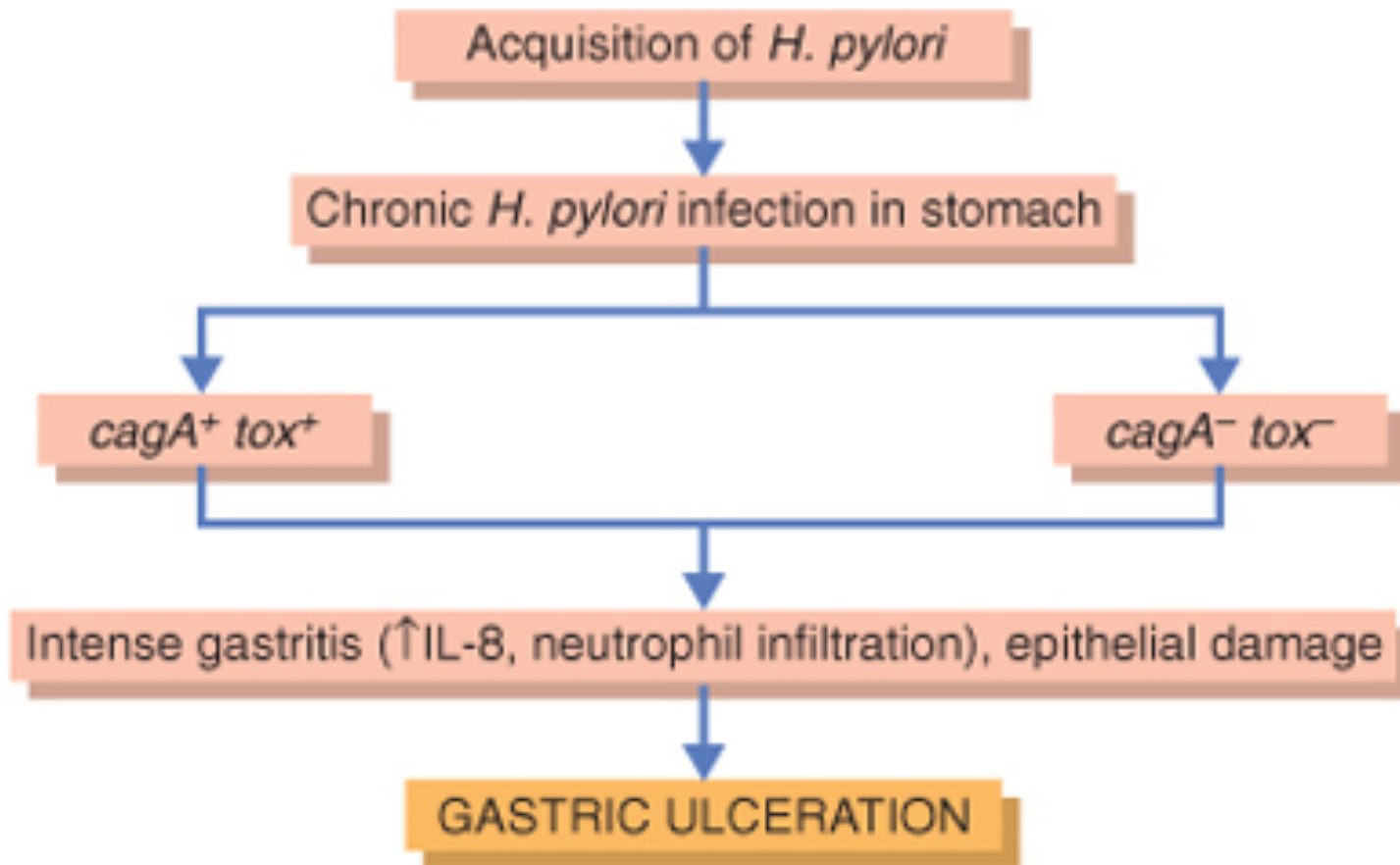
A. **NSAIDs** (blocking the synthesis of the prostaglandins)

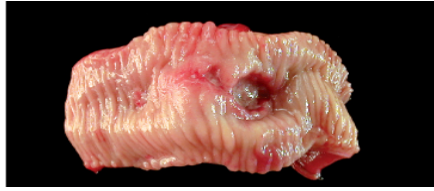B. ***H. pylori* infection**, (cytotoxins and ammonia)



In Peptic ulcers of the stomach, breakdown of mucosal defence is much more important than excessive acid production.

## Pathophysiology of Chronic Peptic Ulcers in Stomach





## Peptic Ulcer Disease Duodenal ulcers

Pathophysiology

Increased production of acid assumes more importance in the pathogenesis of duodenal ulceration

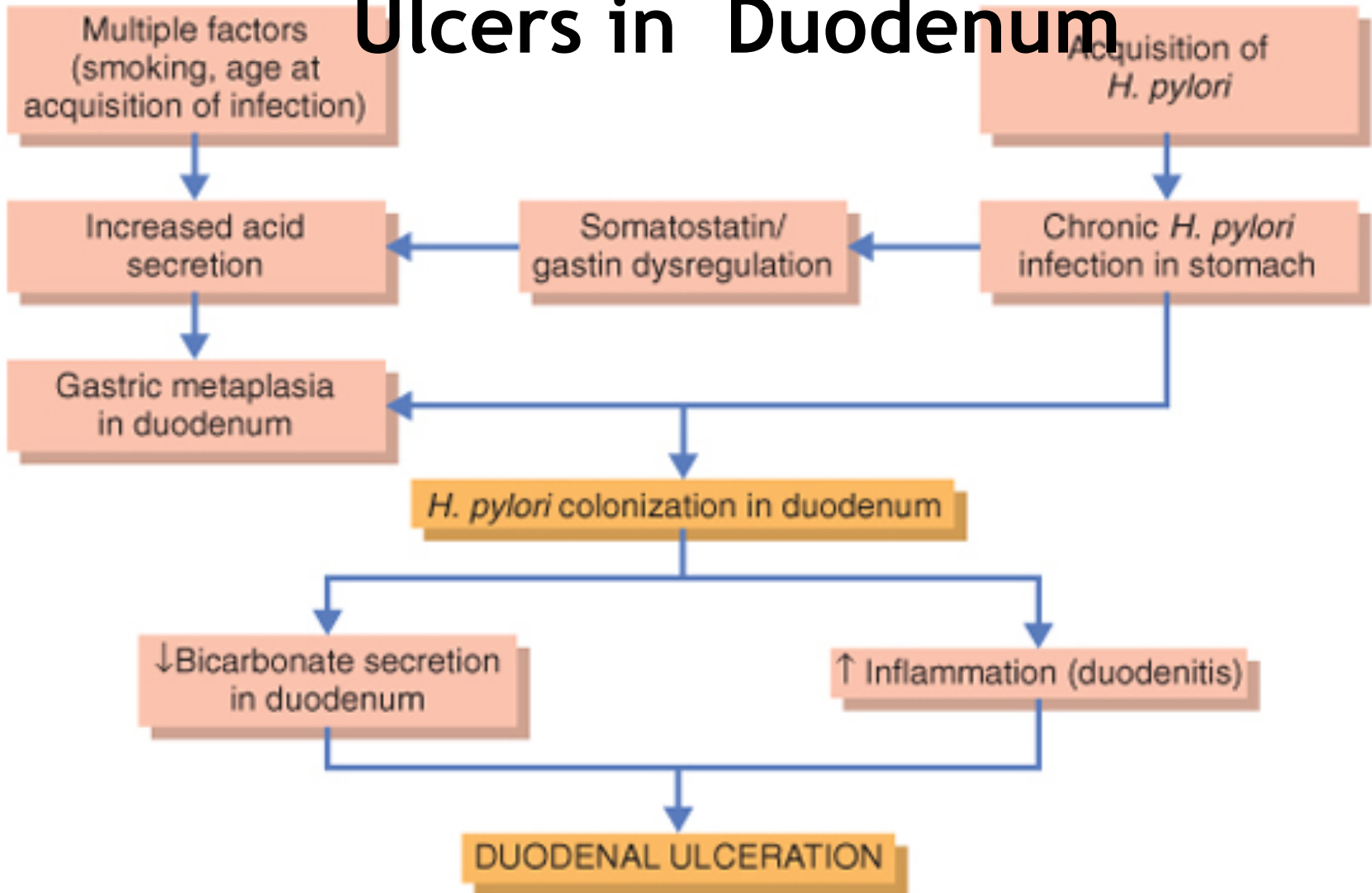
*H. pylori*-infected individuals secrete 2-6 times as much acid as non-infected controls

*Helicobacter Pylori* does not colonise normal duodenal epithelium  
*Helicobacter* is involved in duodenal ulceration because there is gastric metaplasia in response to excess acid. Gastric metaplasia paves the way for colonisation by *Helicobacter*

Increased production of acid + *Helicobacter P* = Duodenal ulcers

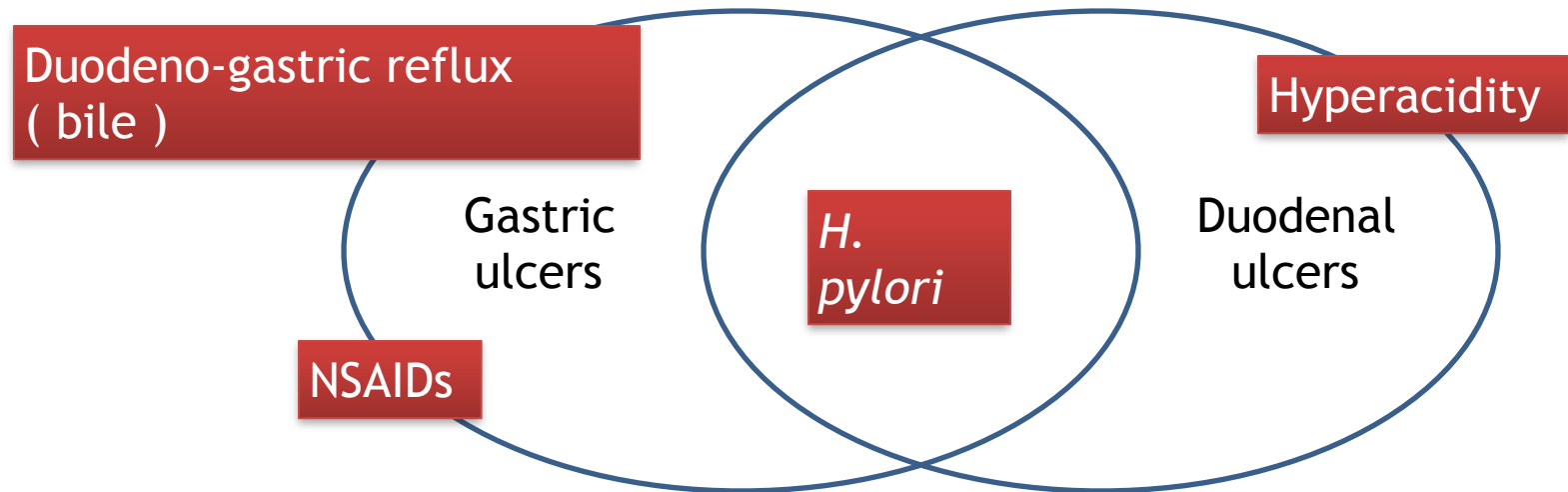


## Pathophysiology of Chronic Peptic Ulcers in Duodenum





## Chronic Peptic Ulcer Disease Pathophysiology

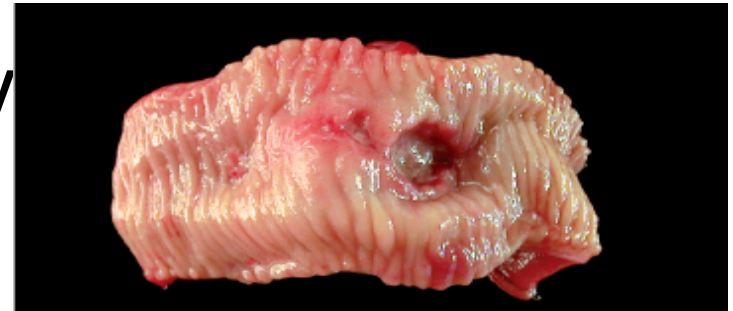

*H. pylori* infection of the pyloric antrum is present in nearly all patients with chronic duodenal ulcer and approximately 75% of patients with chronic gastric ulcer.

Although more than 70% of individuals with PUD are infected by *H. pylori*, fewer than 20% of *H. pylori*-infected individuals develop peptic ulcer.

## Morphology

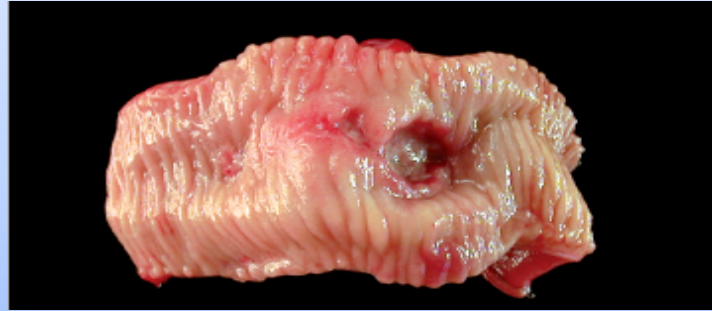
- Gross
- usually less than 20 mm in diameter but they may > 100 mm in diameter.
- The classic peptic ulcer is a round to oval, clean, sharply punched-out defect



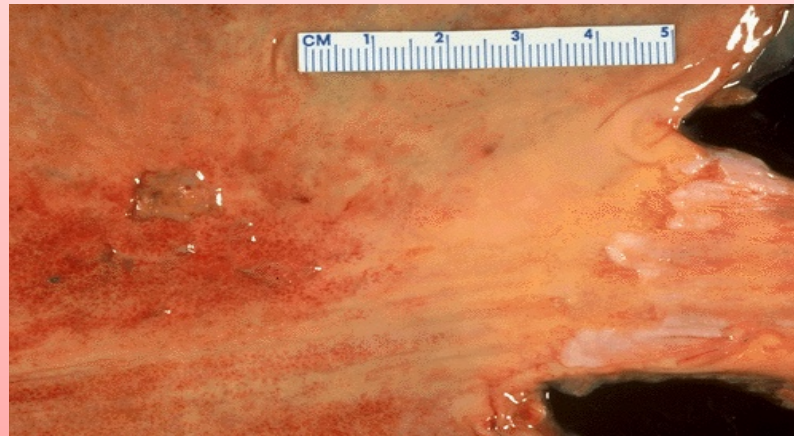
Benign peptic ulcer

# Chronic gastric ulcers Morphology

- Duodenal ulcers usually occur within a few centimeters of the pyloric valve at the anterior duodenal wall.



- Gastric peptic ulcers are predominantly located near the interface of the body and antrum at lesser curvature

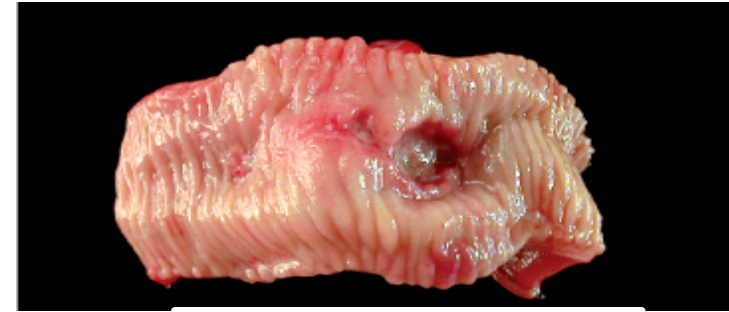

## Morphology

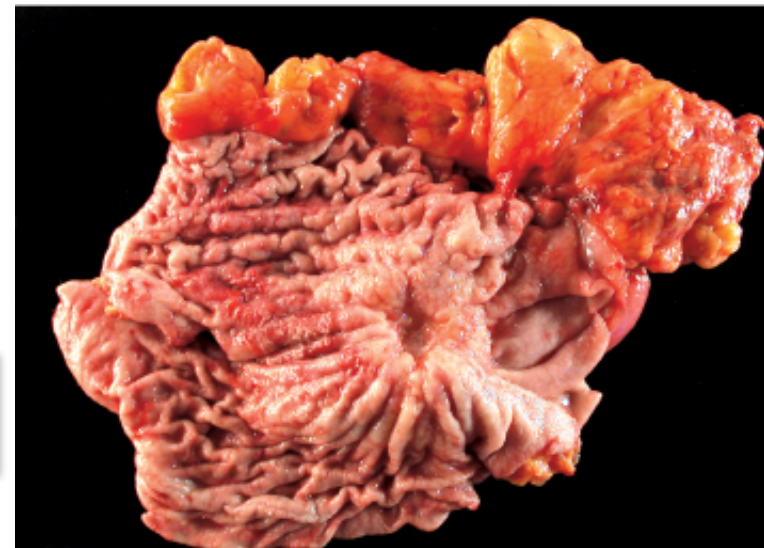- Gross
- Round shallow, sharply demarcated punched out defect with straight walls, surrounded by hyperemia
- In contrast, heaped-up margins are more characteristic of cancers

Most gastric ulcers are benign.  
Small percentage may be malignant, reason for biopsy

Duodenal ulcers are never malignant  
(reason for not taking a biopsy)

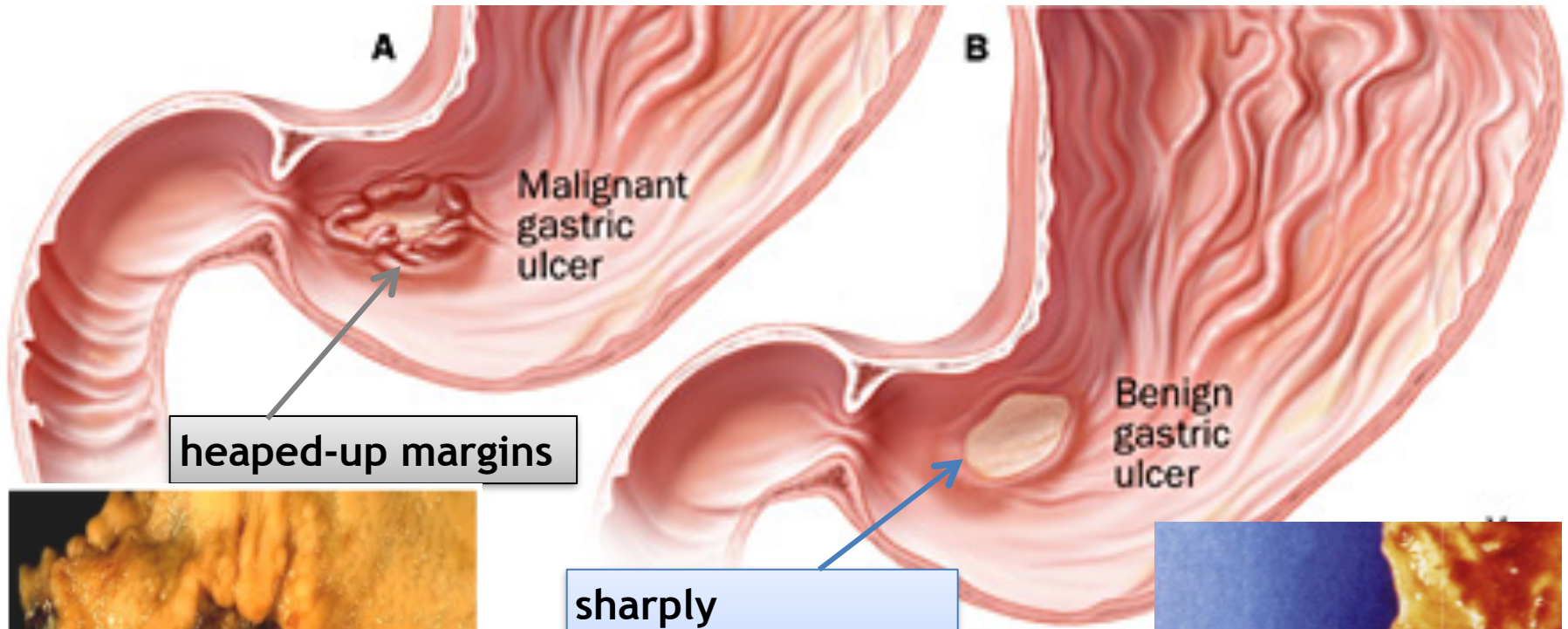


Benign peptic ulcer



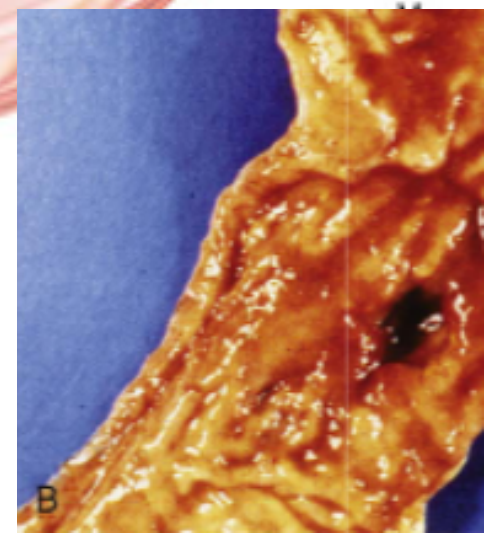
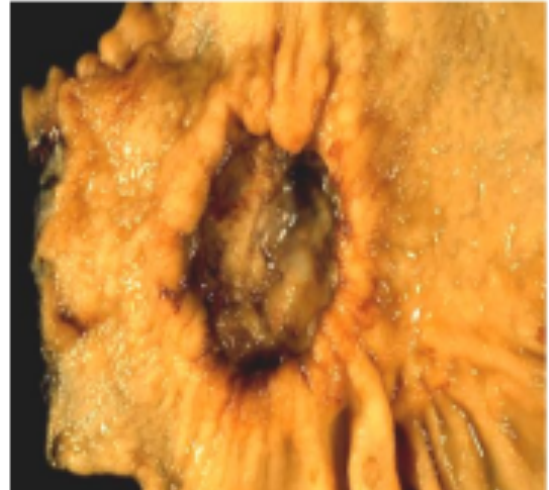
Malignant peptic ulcer

# Chronic gastric ulcers



heaped-up margins

sharply demarcated punched out defect

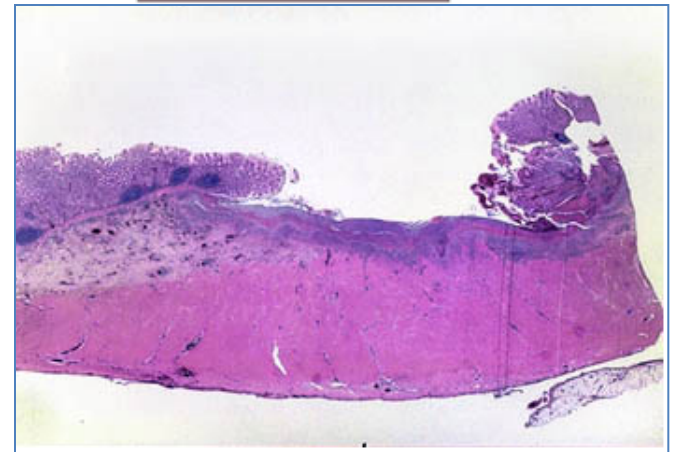
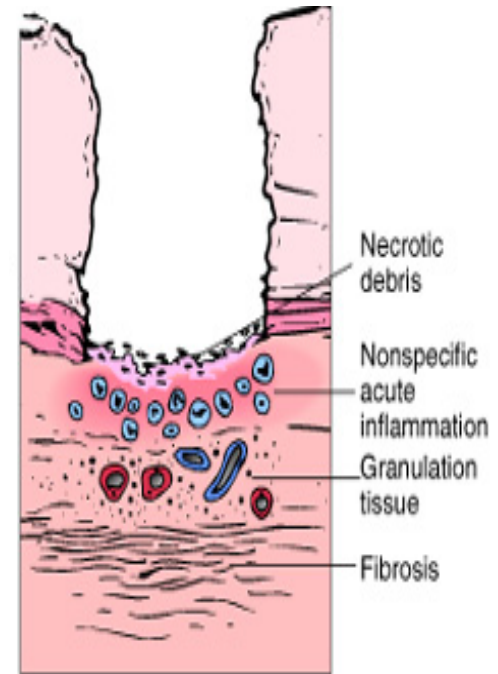




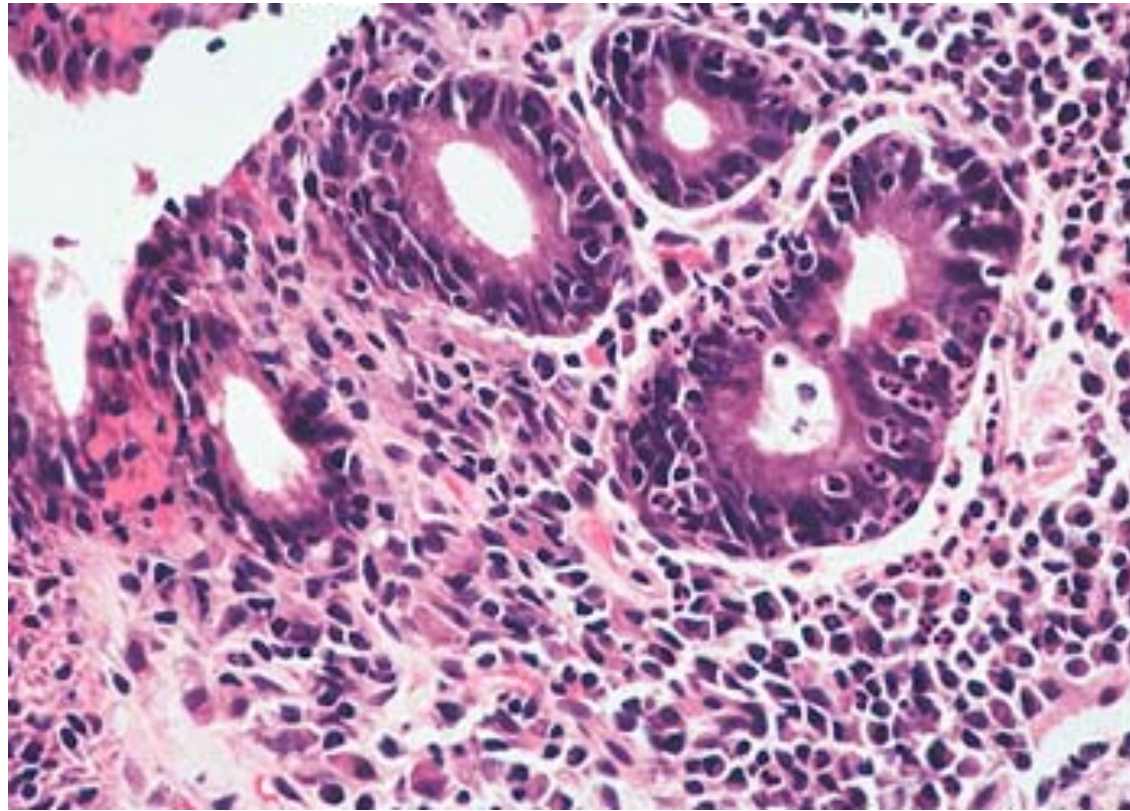
## Morphology

### Microscopy

- the base consists of necrotic tissue and polymorph exudate overlying inflamed granulation tissue which merges with mature fibrous (scar) tissue.

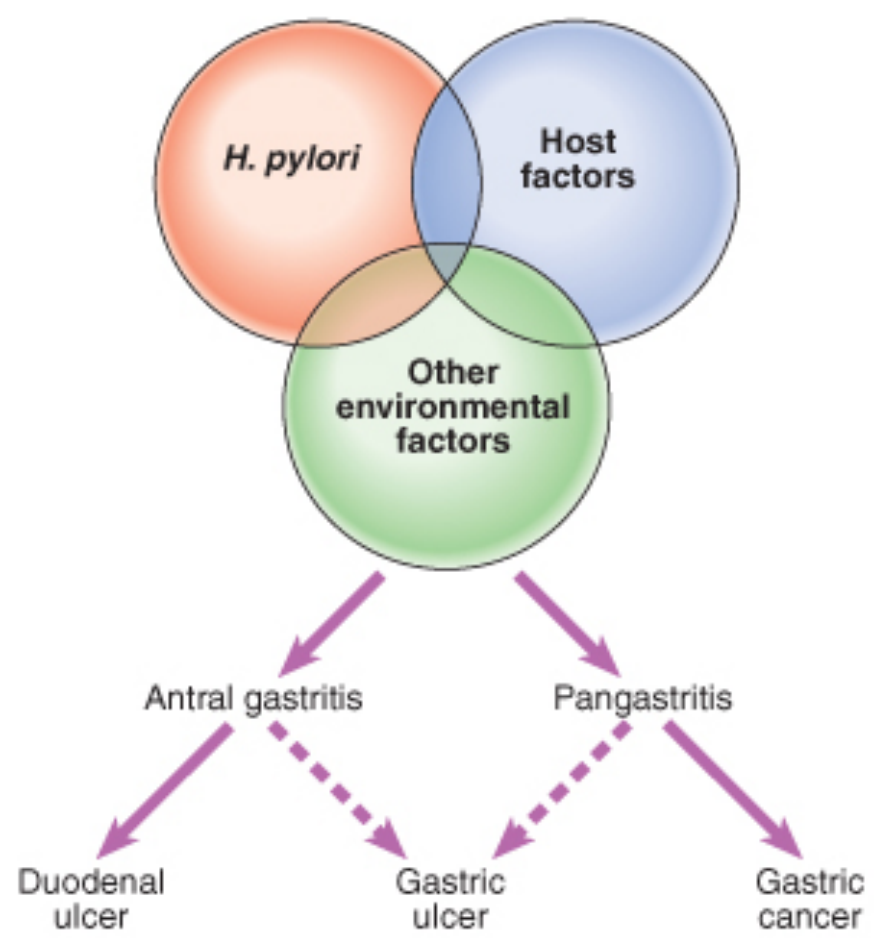


# Chronic gastric ulcers



The presence of neutrophils within the gastric glands signifies active inflammation and, most of the time, the presence of *H pylori*.

# Chronic gastric ulcers





## Clinical features

- Epigastric pain (the most common symptom)
  - Gnawing or burning sensation
  - Occurs 2-3 hours after meals
  - Relieved by food or antacids
  - Patient awakens with pain at night.

Some present with complications such as *iron deficiency anemia, frank hemorrhage, or perforation.*

## Complications of Chronic Peptic Ulcers

- **Hemorrhage.**
- **Penetration.** The ulcer penetrates the full thickness of the stomach or duodenal wall, progressing into adherent underlying tissue, e.g. the pancreas or liver.
- **Perforation.** This leads to peritonitis.
- **Fibrous stricture.** In the stomach, ulcers may cause pyloric stenosis.
- **Malignant change.** This is extremely uncommon.

# Chronic gastric ulcers

## Early Gastric Carcinoma



Exophytic



Flat or depressed



Excavated

## Advanced Gastric Carcinoma



Exophytic



Linitis plastica



Excavated

# Therapy

Current therapies for PUD are aimed at

- I. *H. pylori* eradication : Antibiotic
- II. Acid suppression
  - a) Proton pump inhibitors
  - b) H2 blockers



Case scenario: A woman with intermittent severe epigastric pain

A 49-year-old secretary presents to medical outpatients with a 7-month history of epigastric pain. She had been widowed in the last year, her husband having died of cancer. The patient had been left to support two children. She had recently become a vegetarian to cut down on meat costs. She smokes five cigarettes per day but does not drink alcohol. She has been treated with Gaviscon (antacids) by her GP, but this has not controlled the symptoms. In the clinic, she complains of epigastric pains which are sharp and burning and radiate her subcostal margin to the right. The pain is worse at night and is relieved by food. On examination, there is epigastric tenderness and clinical signs of anaemia.

1. What are the possible causes of this clinical presentation?

This patient would appear to have a stress-related duodenal ulcer that is not responding to existing treatment. Ulcer repair is compromised by the high levels of stress and poor diet, due to financial constraints. Cigarette smoking will also be contributory. The differential diagnosis includes gastric ulceration with or without reflux esophagitis and, although atypical, biliary disease should be considered.

## 2. What are the predisposing causes?

Gastric and duodenal ulcers have many similarities but differ in epidemiology, natural history, outcome and management. **Duodenal ulceration** is thought to be a consequence of an imbalance between damaging effects of acid and pepsin attack on the mucosal defenses of the duodenum. The pH of the duodenal lumen is decreased more frequently and for longer periods in patients with duodenal ulceration, and these patients also empty food from their stomachs at a greater rate, so that after a meal there is less food available to buffer the secreted acid as it passes

into the lumen of the duodenum. Taking NSAIDs and stress have also been associated with duodenal mucosal ulceration. There are also strong links with smoking and alcohol intake. There are four major factors that account for the tendency of duodenal ulcer patients to hypersecrete acid and pepsin:

1. Increased parietal cell mass.
2. Increased stimulation of acid secretion
3. Increased parietal cell sensitivity to stimulants.
4. Loss of inhibitory control of acid secretion.



### 3. What are the major complications?

The major complication is **perforation** of a vessel with subsequent **gastro-intestinal haemorrhage**. This can present as either hematemesis, melena or iron deficiency anemia. Depending upon the direction of rupture, perforation can cause severe pain, **collapse and peritonitis**. Posterior perforation may cause mid-back pain. Other complications include **fibrosis and adhesions**

#### 4. What investigations should be performed?

Fiberoptic endoscopy is the investigation of choice as it allows any ulcer observed to be

biopsied to exclude neoplastic disease and to confirm or refute the presence of *Helicobacter*

*pylori*. Blood counts should be performed to exclude anemia from previous bleeding.

5. What changes might an endoscopic biopsy show if there was ulceration of the gastric or duodenal mucosa?

The histological features include an acute and/or chronic inflammatory cell infiltrate within the glandular or surface epithelium and lamina propria, often with lymphoid aggregate formation.

Regenerative changes are sometimes observed in the surface epithelium.

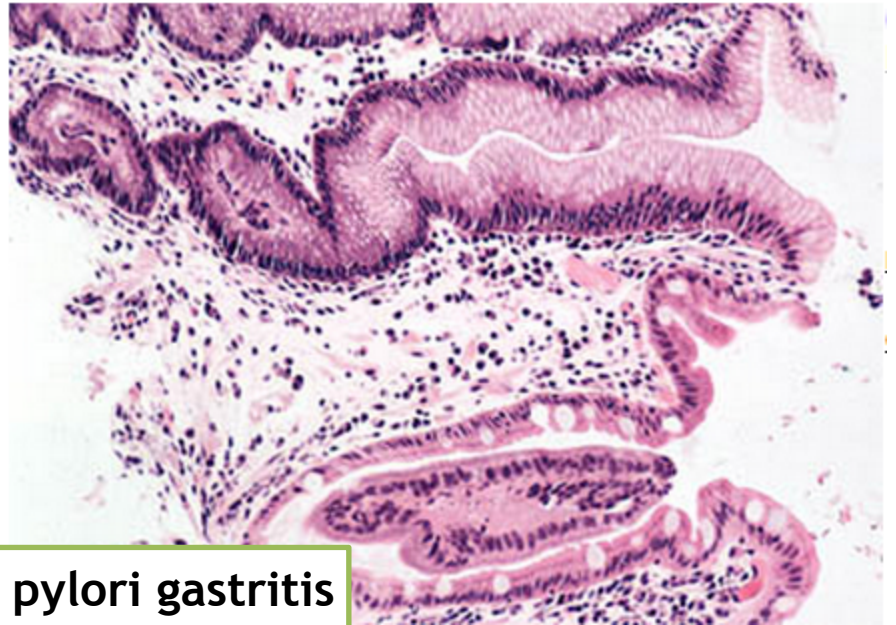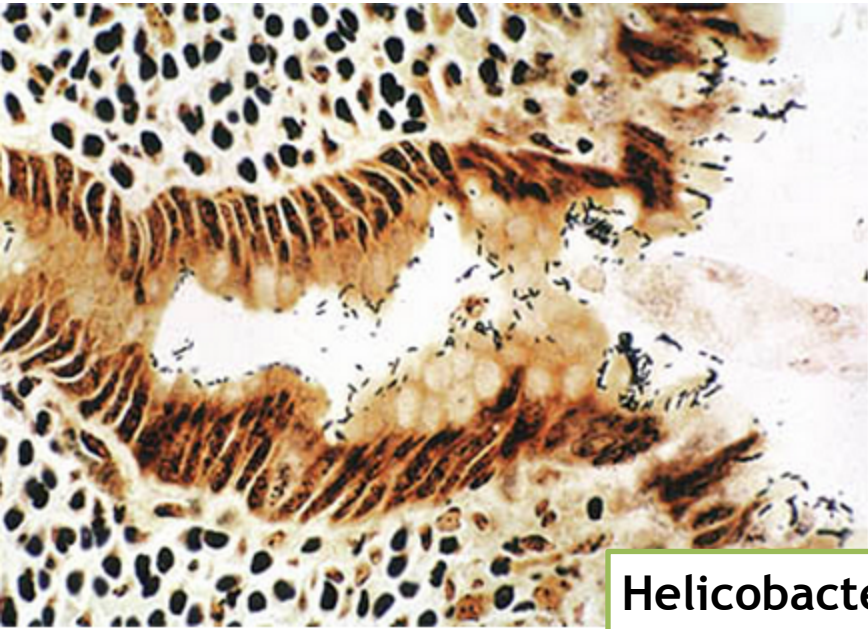
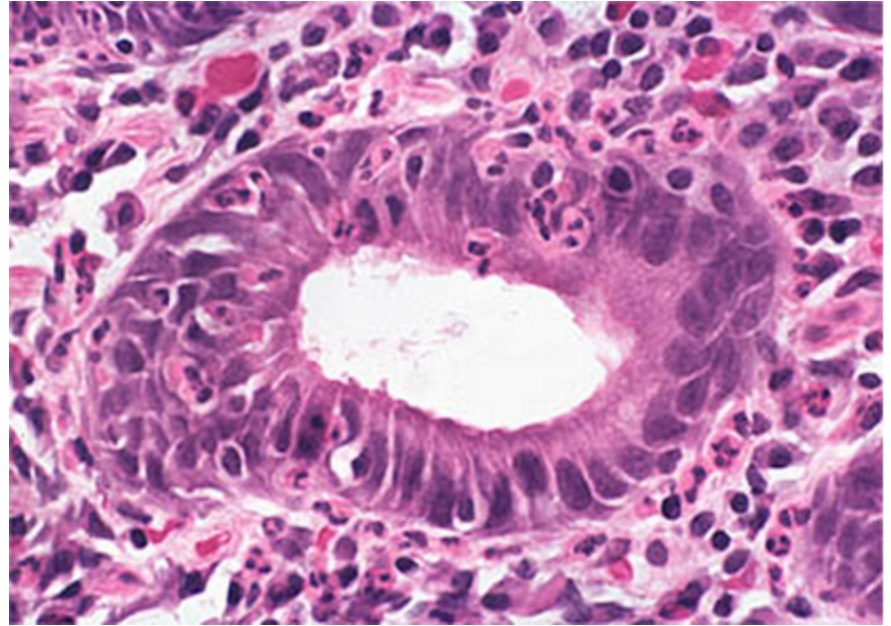
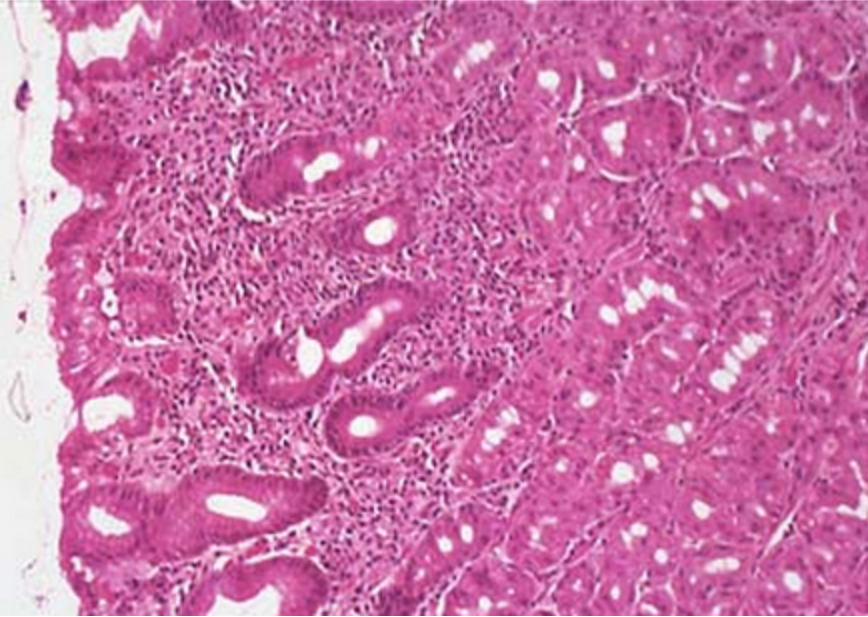
In the stomach, small intestinal metaplasia may be observed and goblet cells are also frequently located in these metaplastic areas.

Gland atrophy, often quite marked, is also a feature of chronic gastritis, especially when *H. pylori* infection is identified.

The presence of dysplasia should be sought and carefully excluded.

Finally, special stains may reveal the presence of *H. pylori* in the surface mucosa.

**Helicobacter pylori gastritis**



**Helicobacter pylori gastritis**



## Helicobacter pylori

### *Cytokines released:*

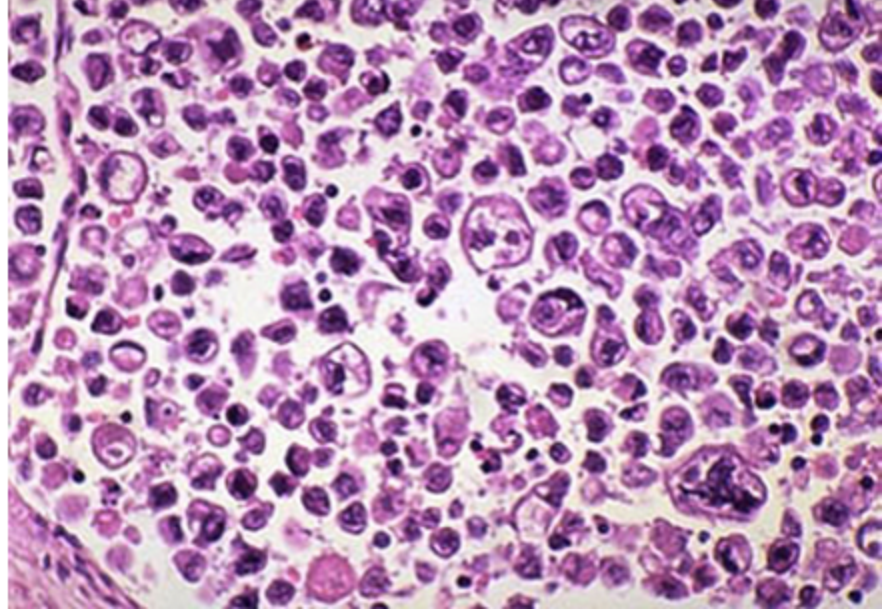
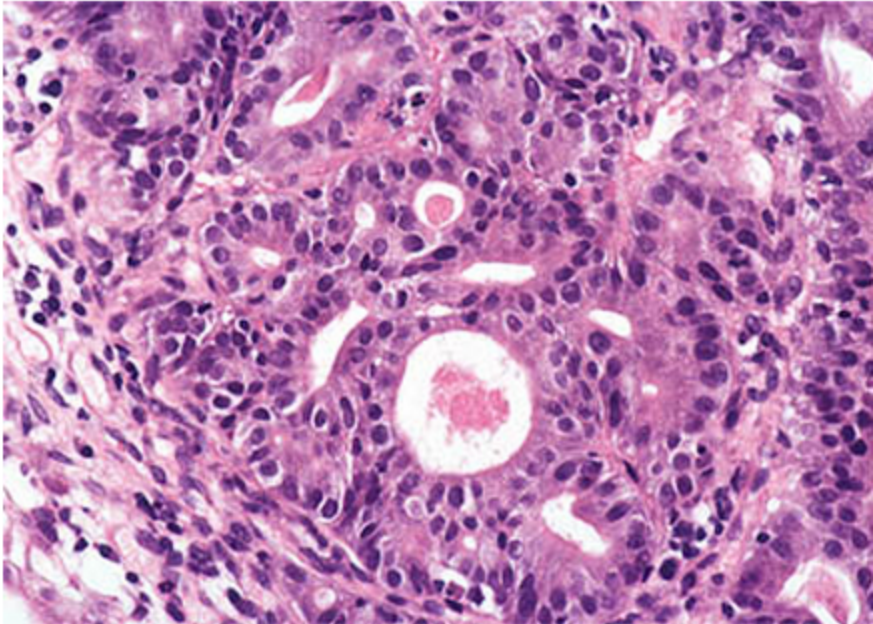
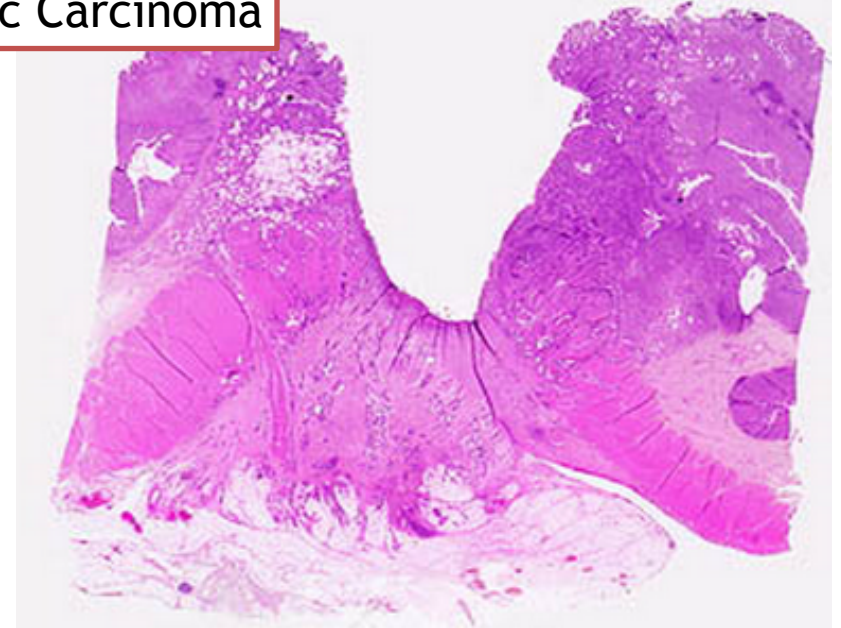
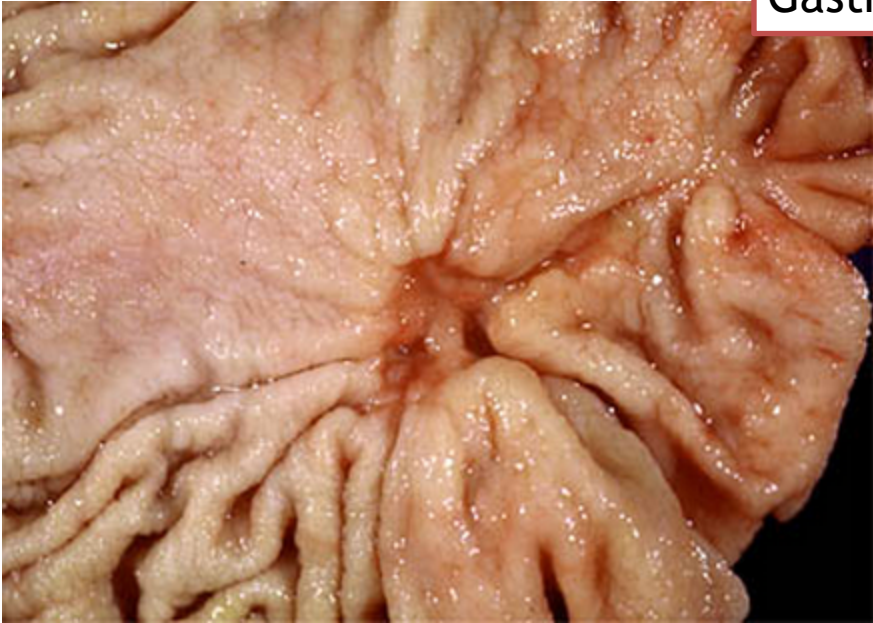*interleukin-1, interleukin-6, interleukin-8 and tumor necrosis factor*

*Virulence factors include flagella for motility, urease production (making ammonia), and bacterial adhesins. Organisms that express cytotoxin-associated antigen (CagA) usually also have a cassette of 29 associated genes (the so-called **Cag pathogenicity island**) that promotes inflammation and tissue damage. One of the most important of these is the vacuolating toxin (VacA), which is a gene product that causes direct cell injury*

**Are these organisms present in the duodenum?**

*No. The H. pylori organisms live in gastric mucus and inflict duodenal damage via cytokine and toxin production.*

Gastric Carcinoma



**Do chronic peptic ulcers of duodenum  
undergo malignant transformation?**

**No.**



What is the relationship between chronic gastritis, *Helicobacter pylori*, chronic peptic ulcer, gastric carcinoma and a low-grade gastric lymphoma?

Chronic infection, especially with *H pylori*, represents the most common form of chronic gastritis. The mucosa shows an intense acute and chronic inflammatory infiltrate and progressive atrophy of the mucosal glands. Patients secrete excess acid and have a low intragastric pH. *H pylori* is also associated with gastric and duodenal ulcer disease and with gastric cancer. *H pylori* infection of gastric mucosa is present in 100% of patients with duodenal ulcer and 70% of those with gastric ulcer. *H pylori* infection is a major factor in the pathogenesis of peptic ulcer.

*H pylori* induces an intense inflammatory and immune response and increased production of proinflammatory cytokines. *H pylori* secretes a urease that breaks down urea to form toxic compounds such as ammonium chloride and monochloramine. Thrombotic occlusion of surface capillaries is promoted by a bacterial platelet-activating factor. Other antigens, including lipopolysaccharides, recruit inflammatory cells to the mucosa. The chronically inflamed mucosa is more susceptible to acid-peptic injury and peptic ulceration. In addition, chronic inflammation of the mucosa is possibly important in the pathogenesis of gastric carcinoma and a low-grade gastric lymphoma, also known as MALToma (MALT = Mucosa-Associated Lymphoid Tissue).

# What are the complications of chronic peptic ulcers?

The complications of peptic ulcer disease are:

- (1) bleeding
  - (2) perforation
  - (3) penetration into an adjacent viscus
  - (4) obstruction from edema or from scarring of the pylorus or duodenum
  - (5) intractable pain.
- Malignant transformation does not occur in duodenal ulcers and is extremely rare in gastric ulcers.

# Describe acute gastric ulcers

- Acute ulcers are multiple, small, circular mucosal defects that typically measure less than 1 cm. The ulcer base is stained dark brown by acid digestion of extravasated blood. In an ulcer, necrosis involves the entire thickness of the mucosa. When the necrosis involves only the superficial mucosa, the lesion is an erosion. Acute gastric ulcers are usually not associated with fibrosis, which characterizes a chronic peptic ulcer. Acute, or stress, ulcers are most commonly encountered in patients with shock, burns, sepsis, intracranial conditions, and aspirin. About 1% to 4% of patients admitted to hospital intensive care units acutely develop superficial gastric erosion or ulcers, which may be associated with lethal bleeding. The most important determinant of clinical outcome is the ability to correct the underlying condition(s).
- **Are acute gastric ulcers associated with *Helicobacter pylori*?**  
No.