

GIT BLOCK

PATHOLOGY PRACTICAL

Prepared by:

- *Prof. Ammar Al Rikabi*
- *Dr. Sayed Al Esawy*

Head of Pathology Department: Dr. Hisham Al Khalidi

Objectives:

At the end of these practical sessions, the students will be able to:

- **Recognize, describe and understand the morphological appearance (both macroscopic and microscopic) of some of the common diseases of the GIT, hepatobiliary system and pancreas.**

Contents:

Gross pathology and histopathology section pictures of the following:

1-Salivary glands:

- Pleomorphic adenoma of the salivary gland.

2-Esophagus:

- Reflux oesophagitis/GERD.
- Barrett's oesophagus.
- Squamous carcinoma of the oesophagus.

3-Stomach:

- Chronic gastric ulcer.
- Gastritis: Helicobacter-induced.
- Adenocarcinoma of the stomach.

4-Small intestine:

- Chronic duodenal ulcer.
- Celiac disease.
- Carcinoid tumor.

Contents Cont'd:

5- Large intestine:

- Crohn's disease.
- Ulcerative colitis.
- Adenomatous polyp of the rectum/colon.
- Familial polyposis.
- Adenocarcinoma of the colon.

6- Hepatobiliary system:

- Chronic hepatitis.
- Hepatic cirrhosis.
- Hepato-cellular carcinoma.
- Chronic cholecystitis with stones.

7- Pancreas:

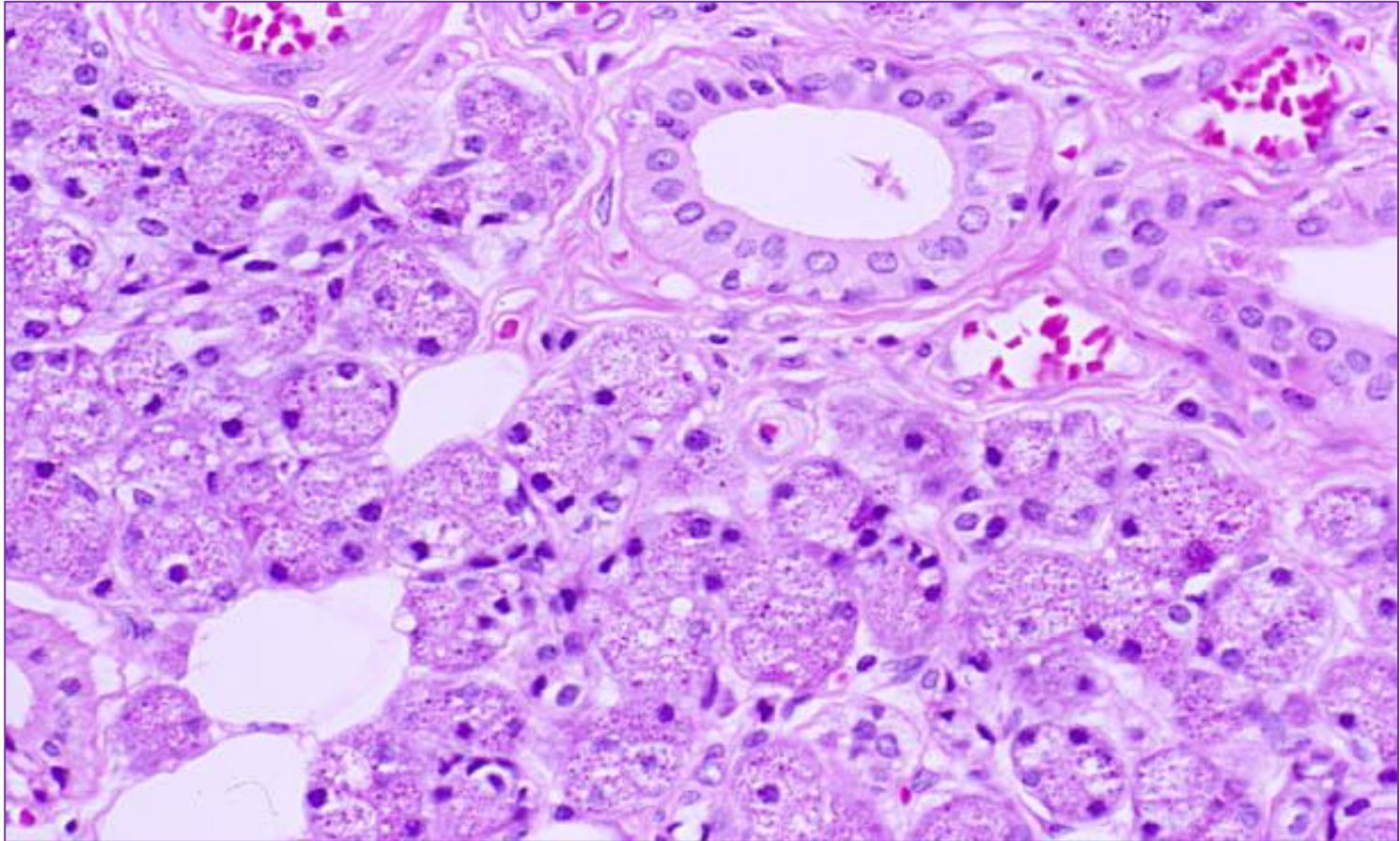
- Chronic pancreatitis.
- Pancreatic adenocarcinoma.



***FIRST
PRACTICAL***

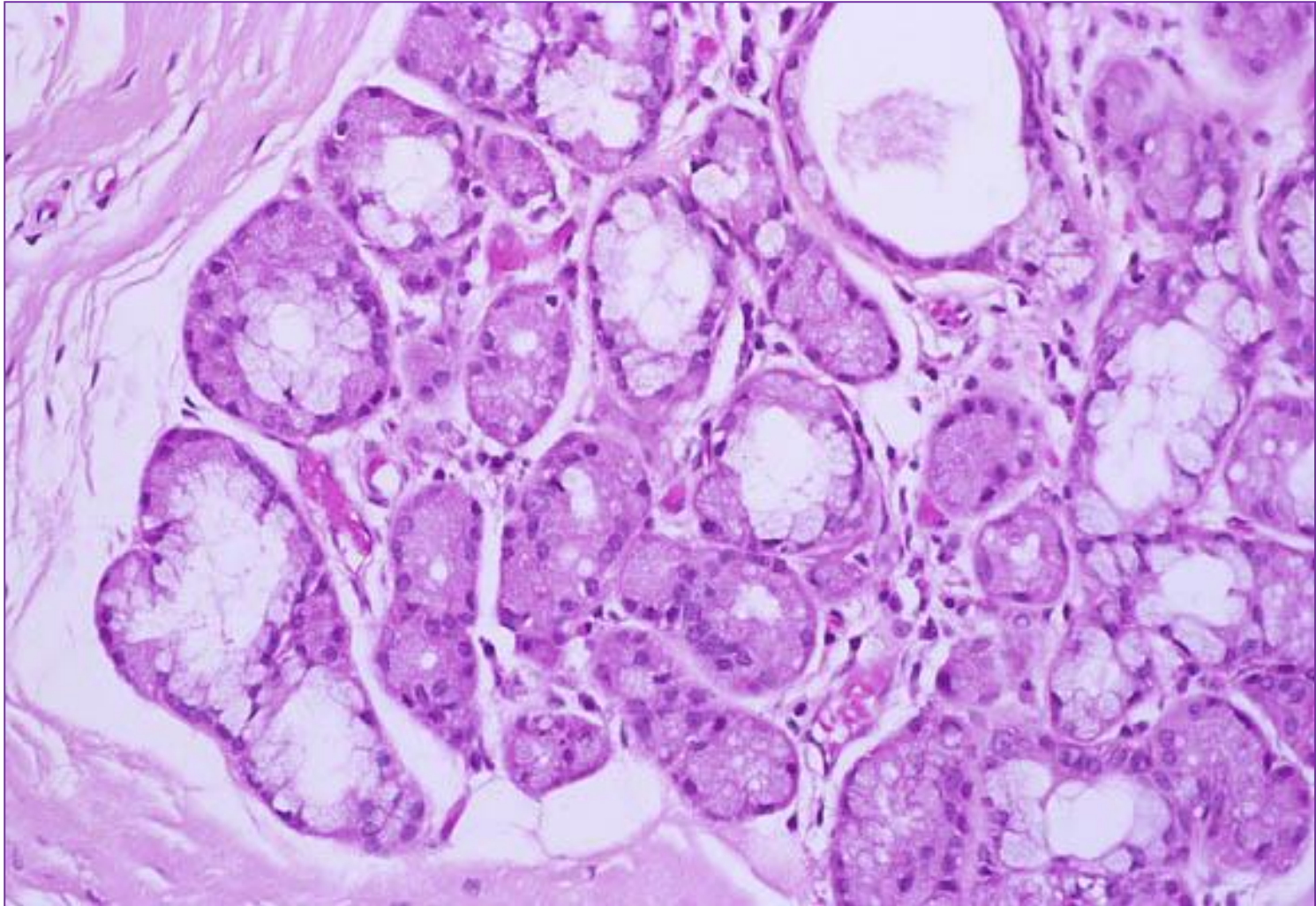
SALIVARY GLAND

Parotid Gland – Normal Histology

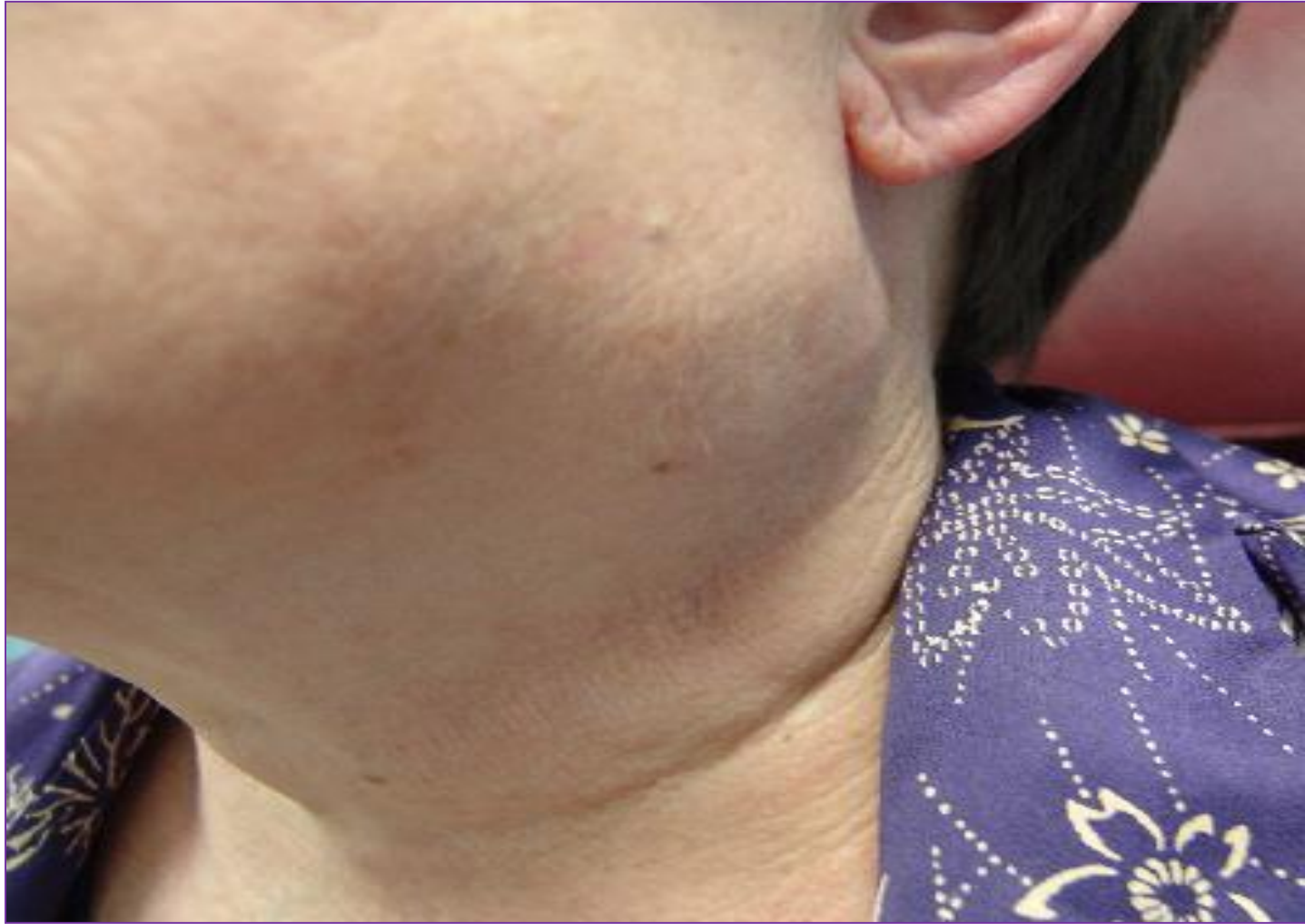

Clusters of large, pale-staining mucous cells occasionally are present in the parotid gland, but the acini are overwhelmingly of serous type. Each serous acinus is composed of several pyramidal-shaped cells with basal nuclei and basophilic cytoplasmic granules.

Salivary Gland – Normal Histology

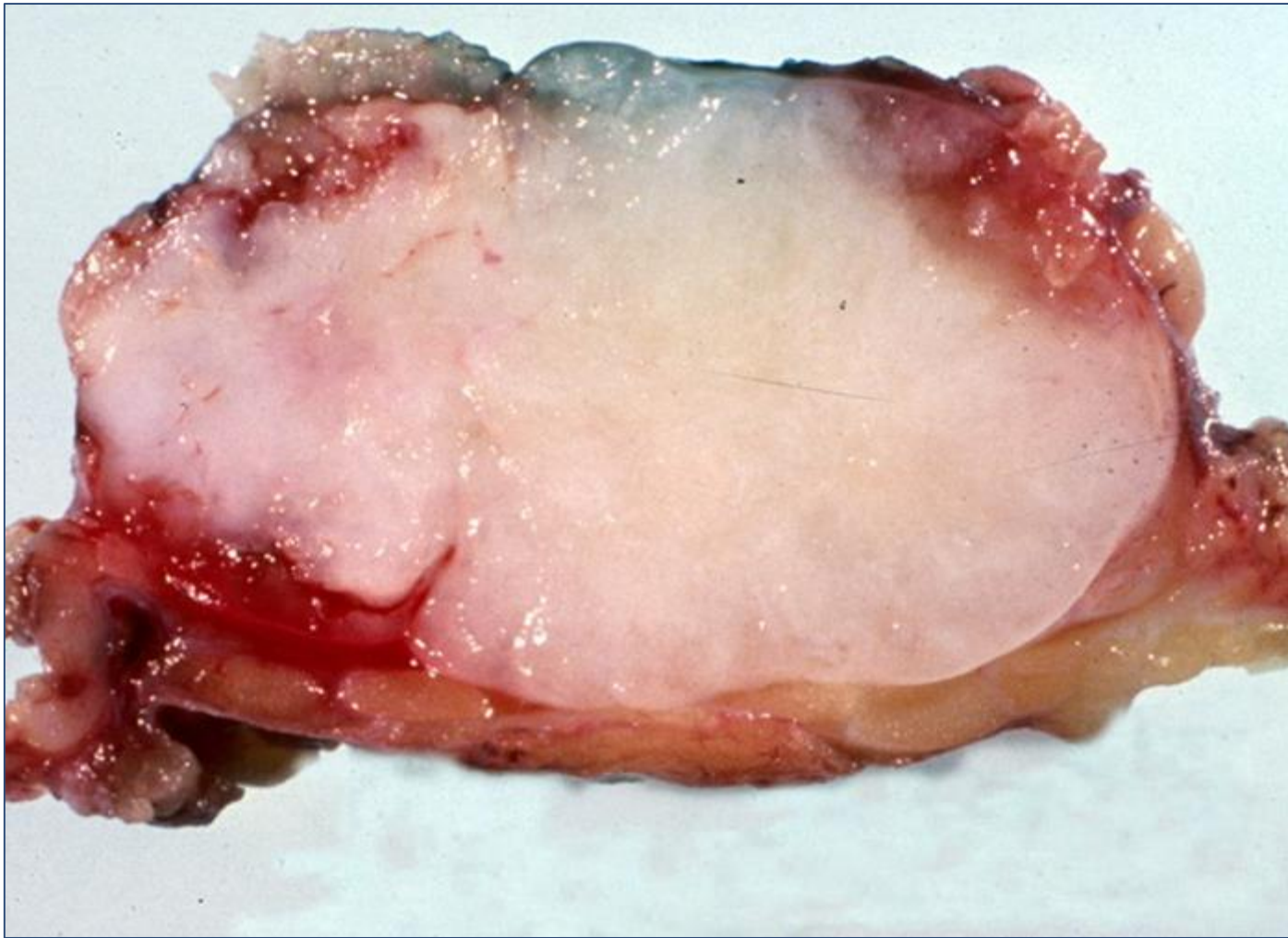


PAROTID GLAND SWELLING – Clinical

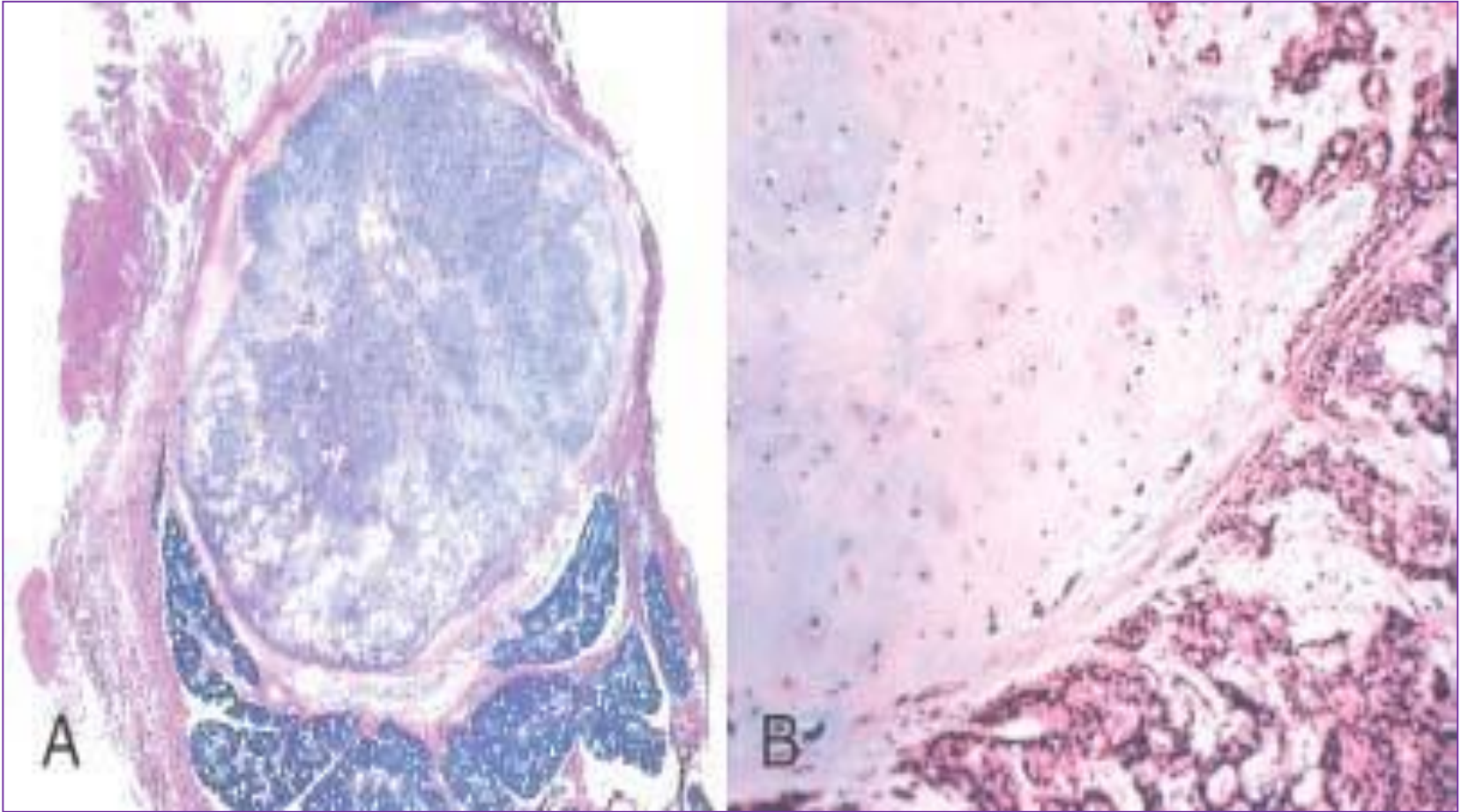


The classic place for any visible parotid swelling or tumor is present between the tip of the ear and the tip (angle) of the mandible

PLEOMORPHIC ADENOMA (MIXED TUMOR) - Gross

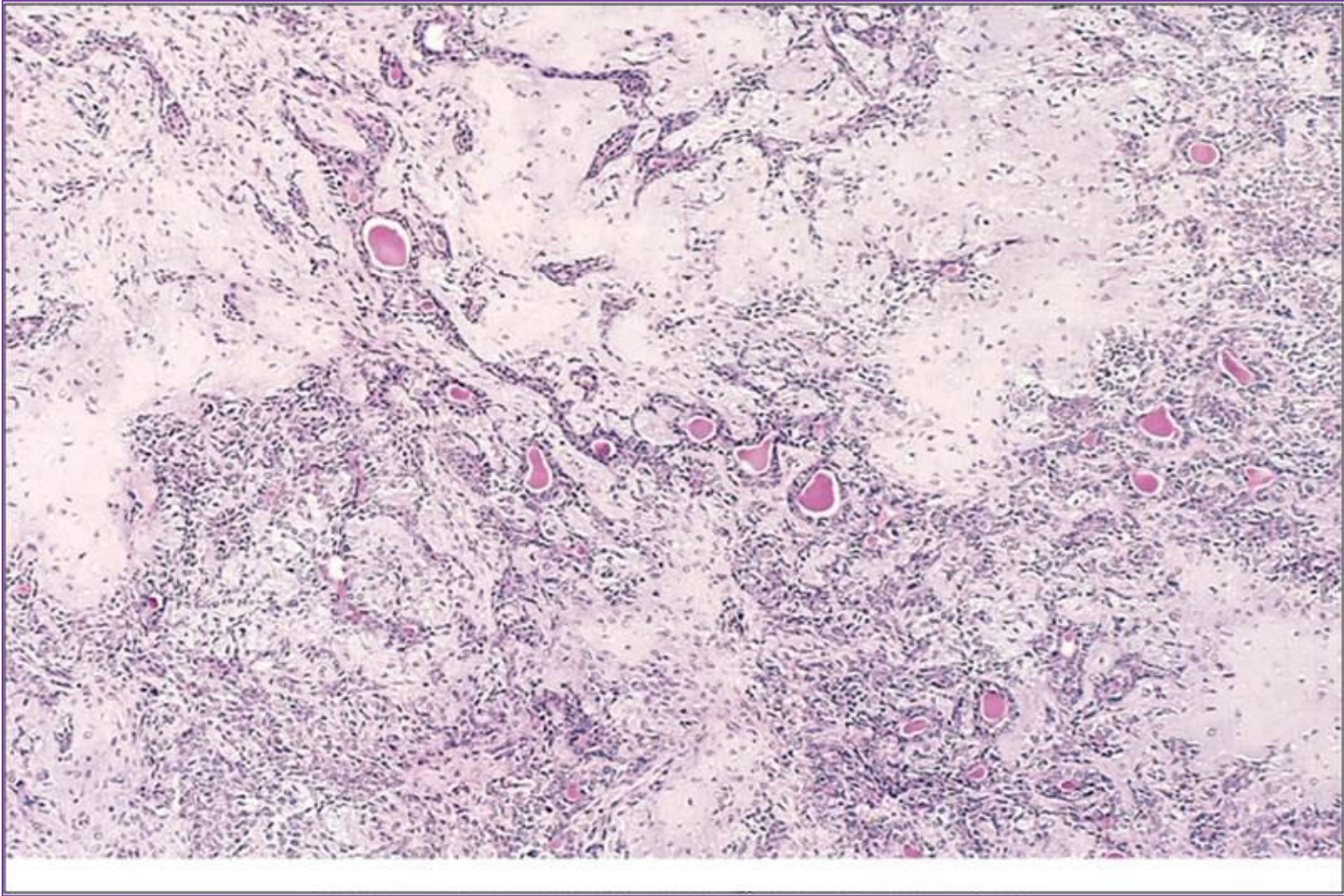


PLEOMORPHIC ADENOMA (MIXED TUMOR)



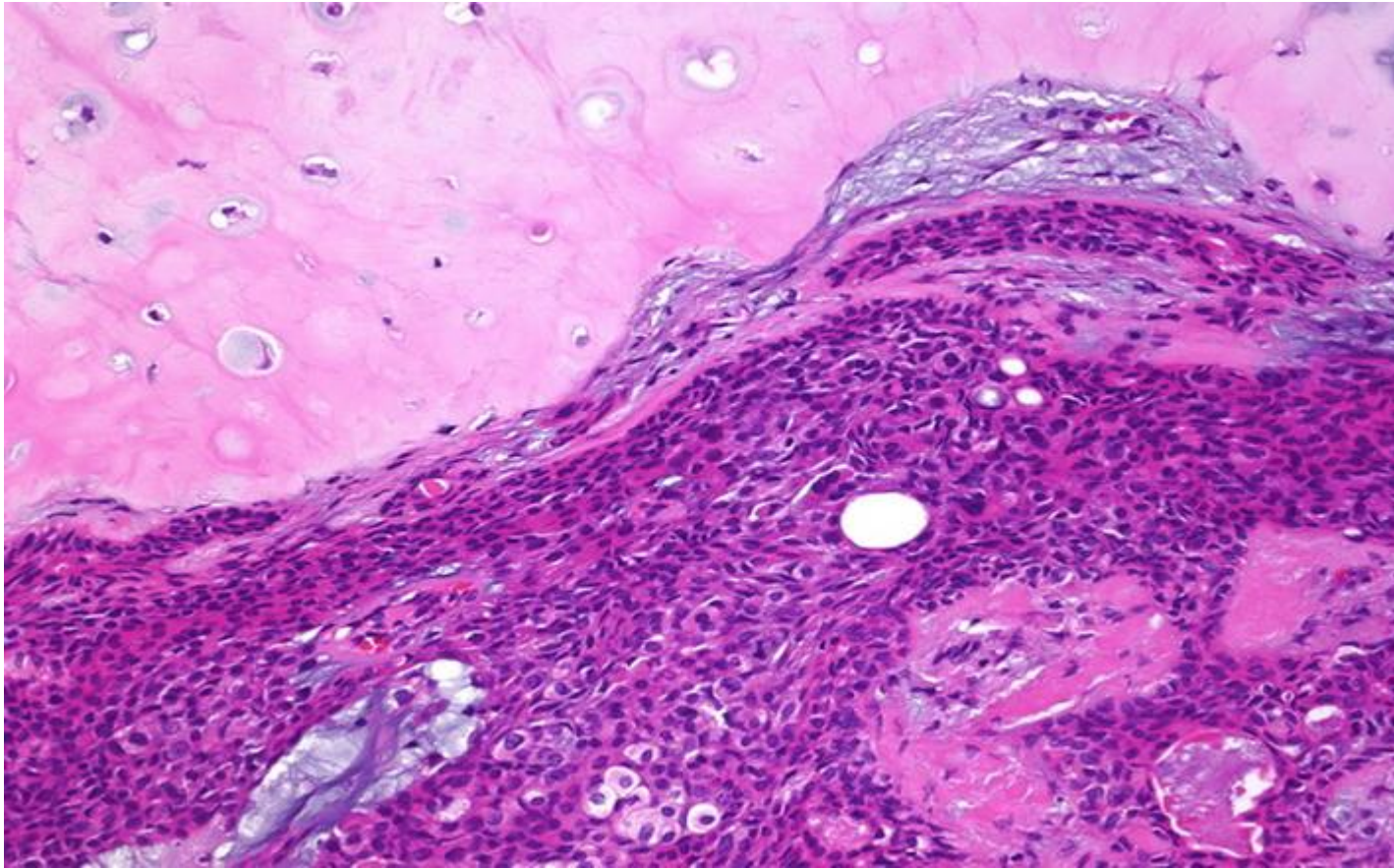
Mixed tumors are generally benign, have BOTH connective tissue (i.e., usually cartilagenous) components as well as glandular components, hence the name pleomorphic or mixed, they generally look and feel like little round soft cartilage balls.

PLEOMORPHIC ADENOMA - Microscopically



Mixed tumor of the parotid gland contains epithelial cells forming ducts, myoepithelial cells and chondromyxoid stroma

PLEOMORPHIC ADENOMA - Microscopically



Tumour shows mixed cellular components like epithelial, myoepithelial, chondriod and myxoid elements. Epithelial areas shows small ducts, acini and strands or sheets of cells. Myxoid areas are formed of loose myxomatous tissue and chondroid areas consist of pale blue matrix.

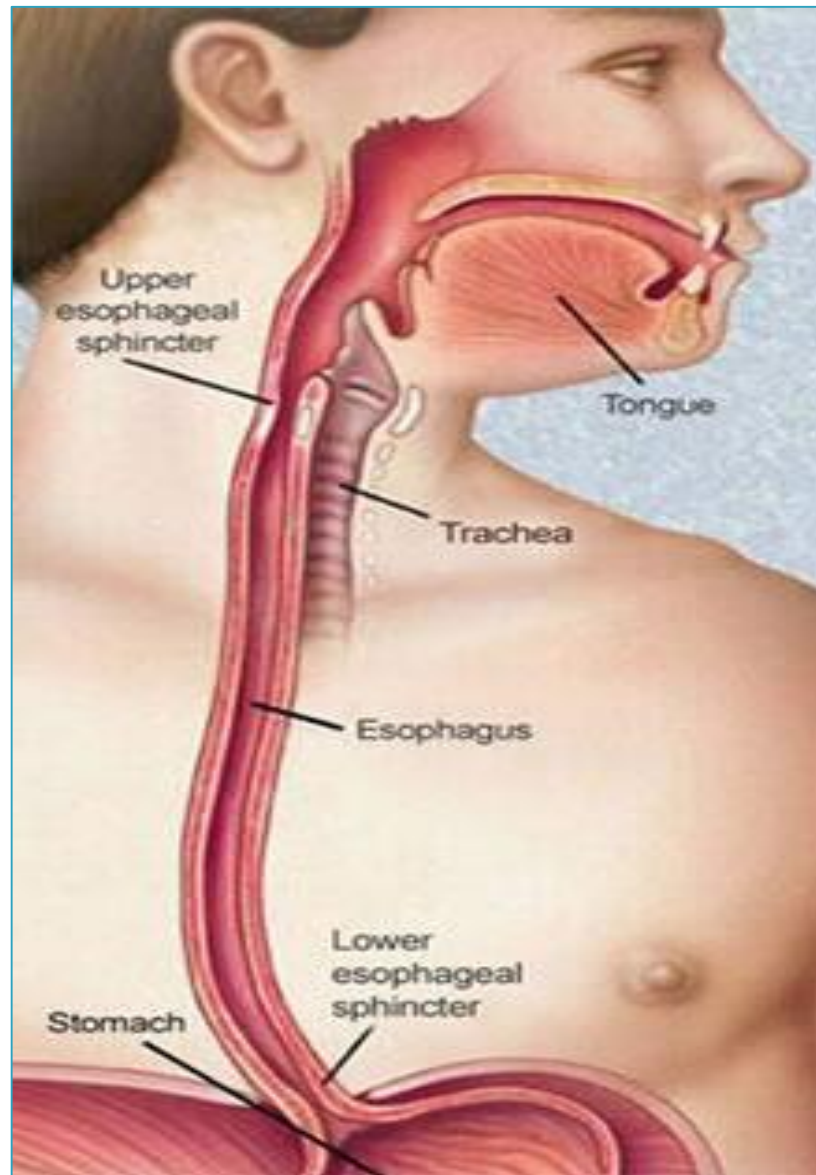


ESOPHAGUS

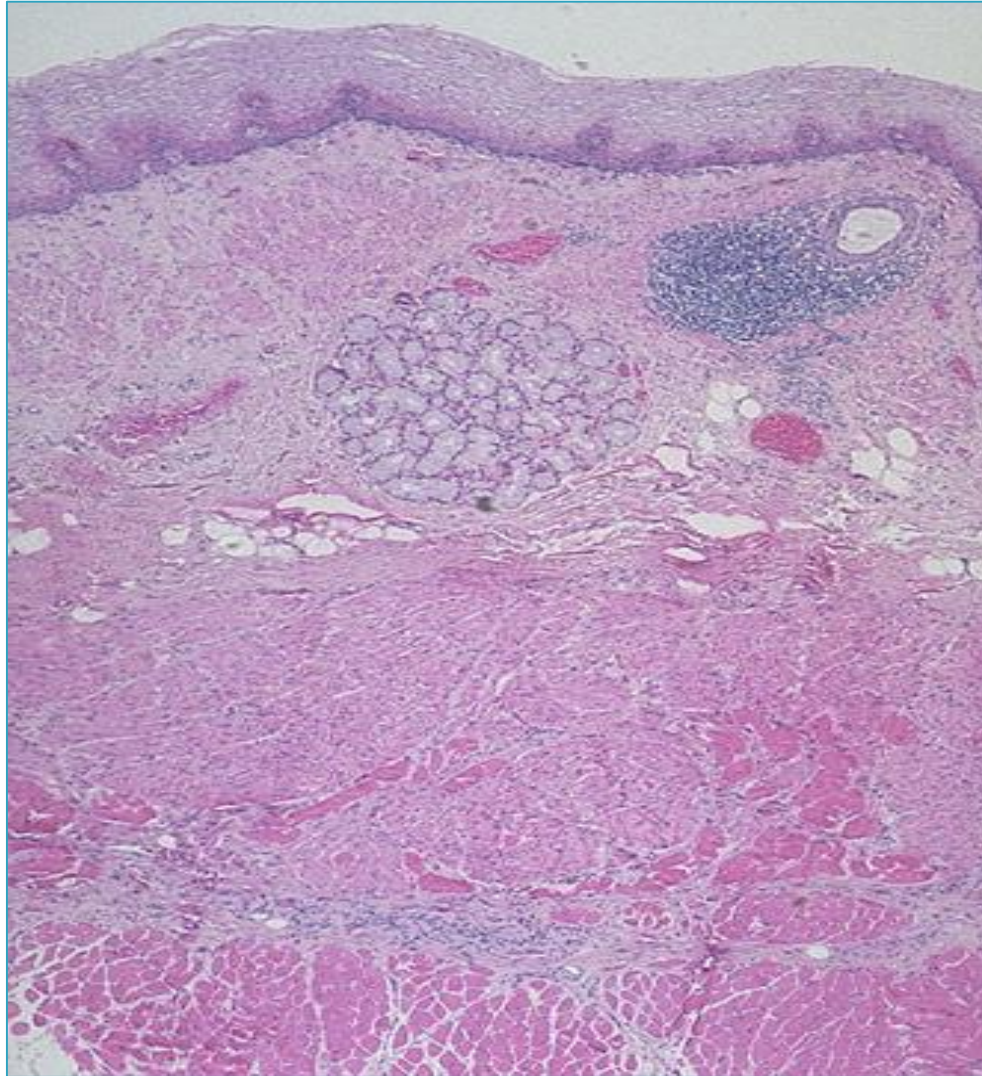


Normal anatomy and histology

Anatomy of the Esophagus

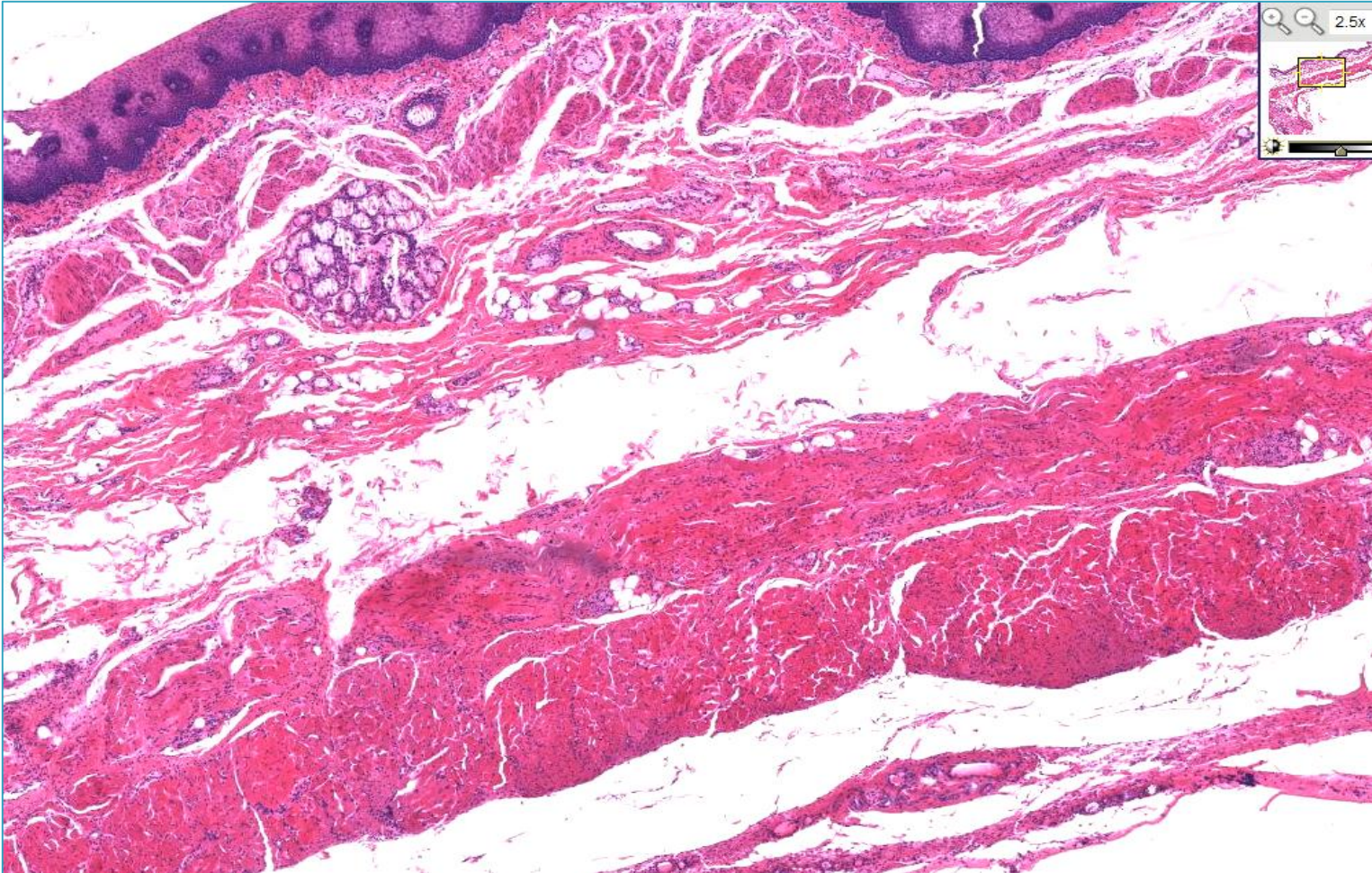


Histology of Normal Esophagus



This is normal esophageal squamous mucosa at the left, with underlying submucosa containing mucus glands and a duct surrounded by lymphoid tissue. The muscularis mucosa is at the left.

Histology of Normal Esophagus



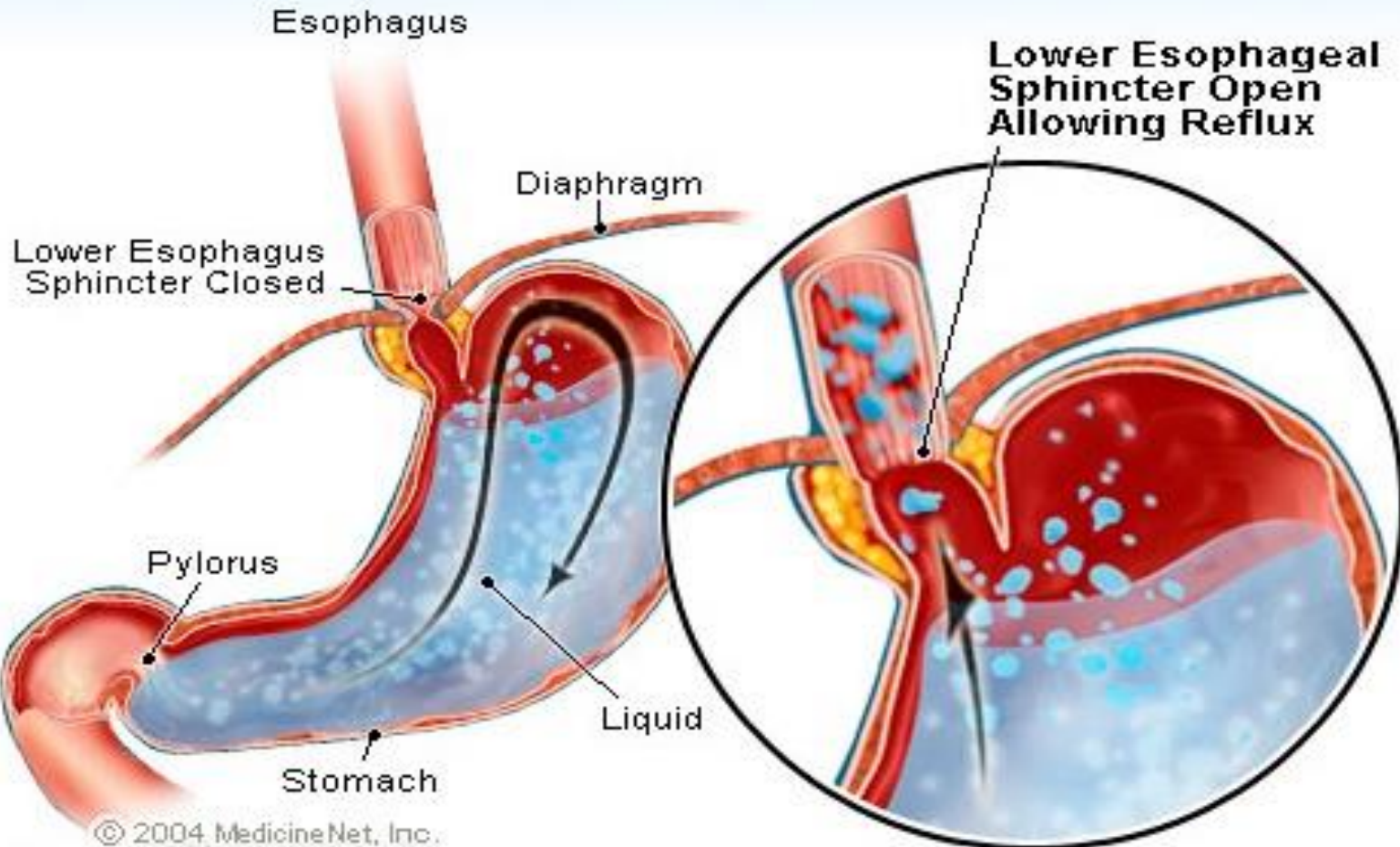
This section shows normal esophageal squamous mucosa at the upper, with underlying submucosa containing mucus glands and a duct surrounded by lymphoid tissue. The muscularis externa is at the lower.



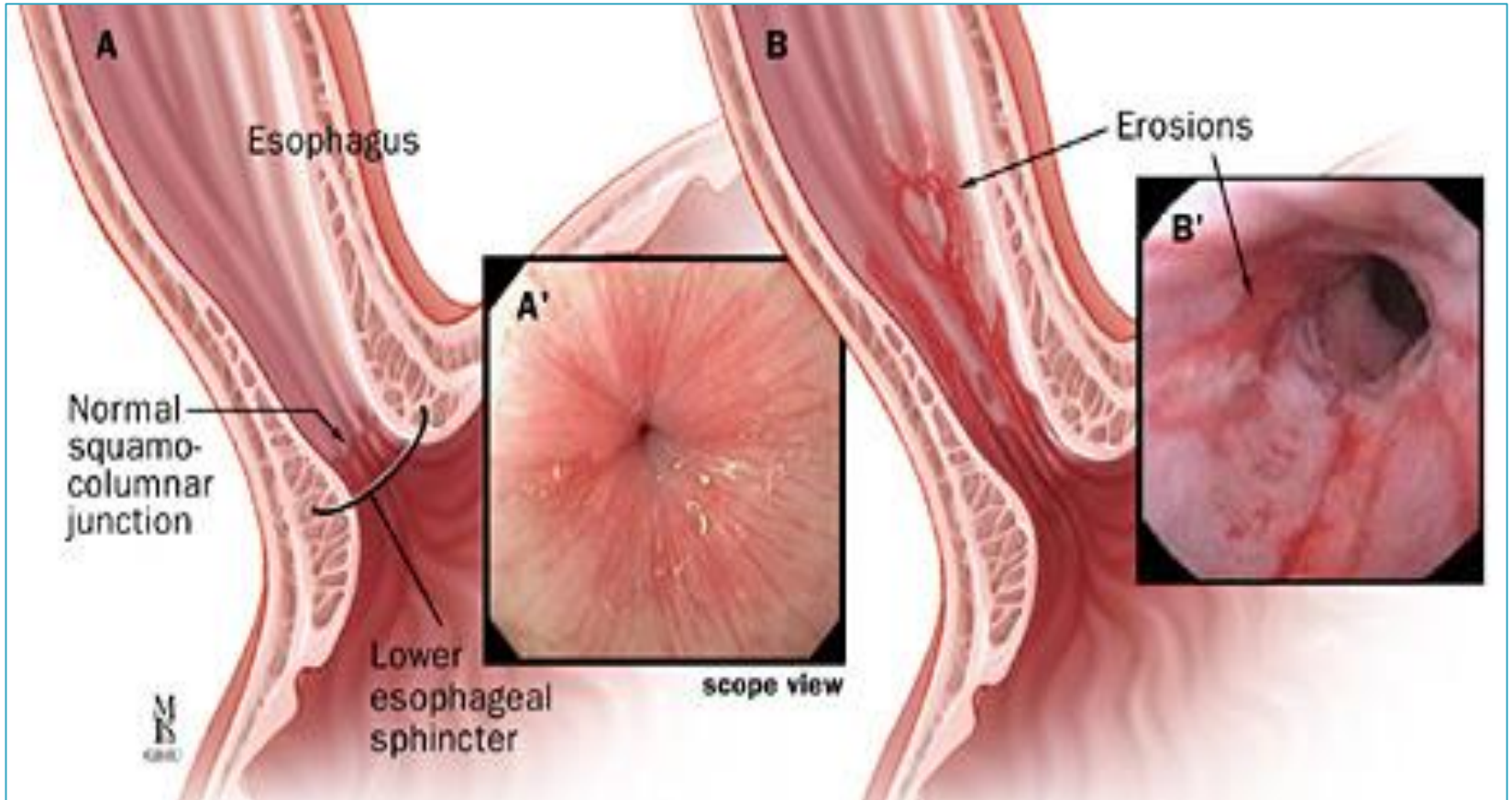
Gross and histopathology

GASTROESOPHAGEAL REFLUX DISEASE (GERD)

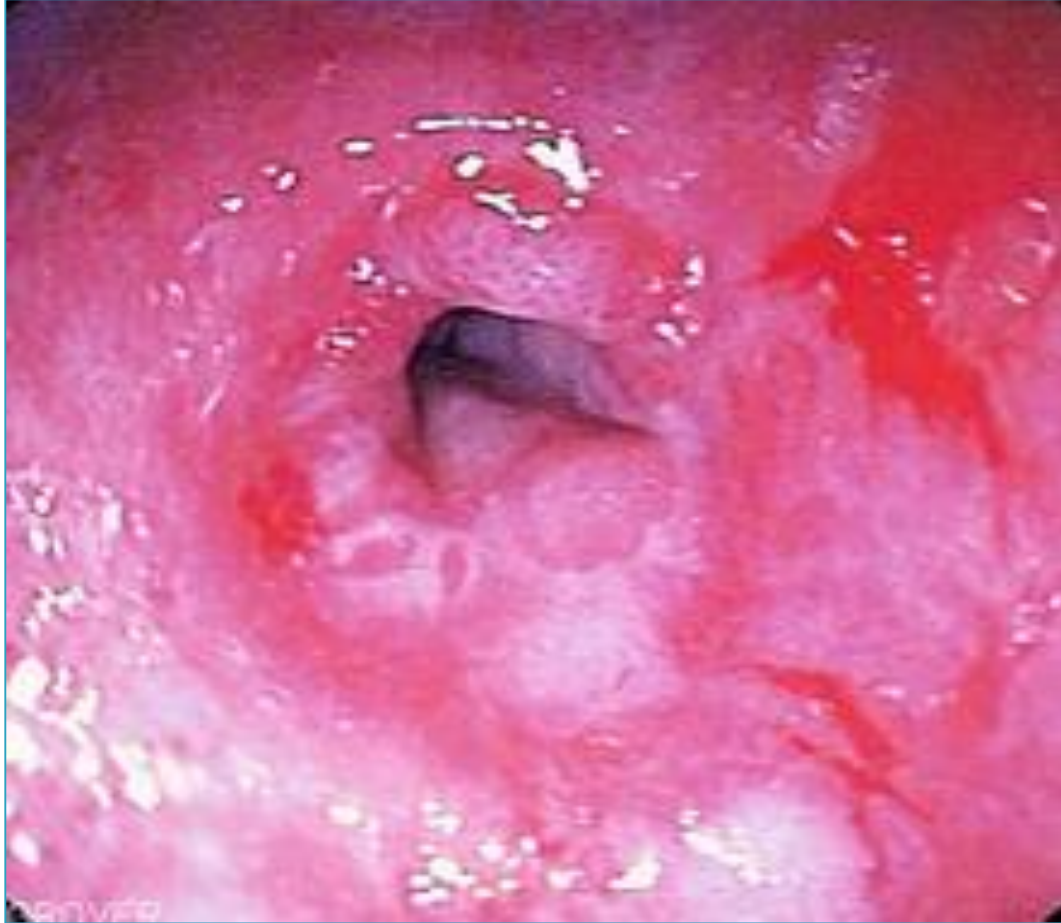Gastroesophageal Reflux



GASTROESOPHAGEAL REFLUX DISEASE (GERD)

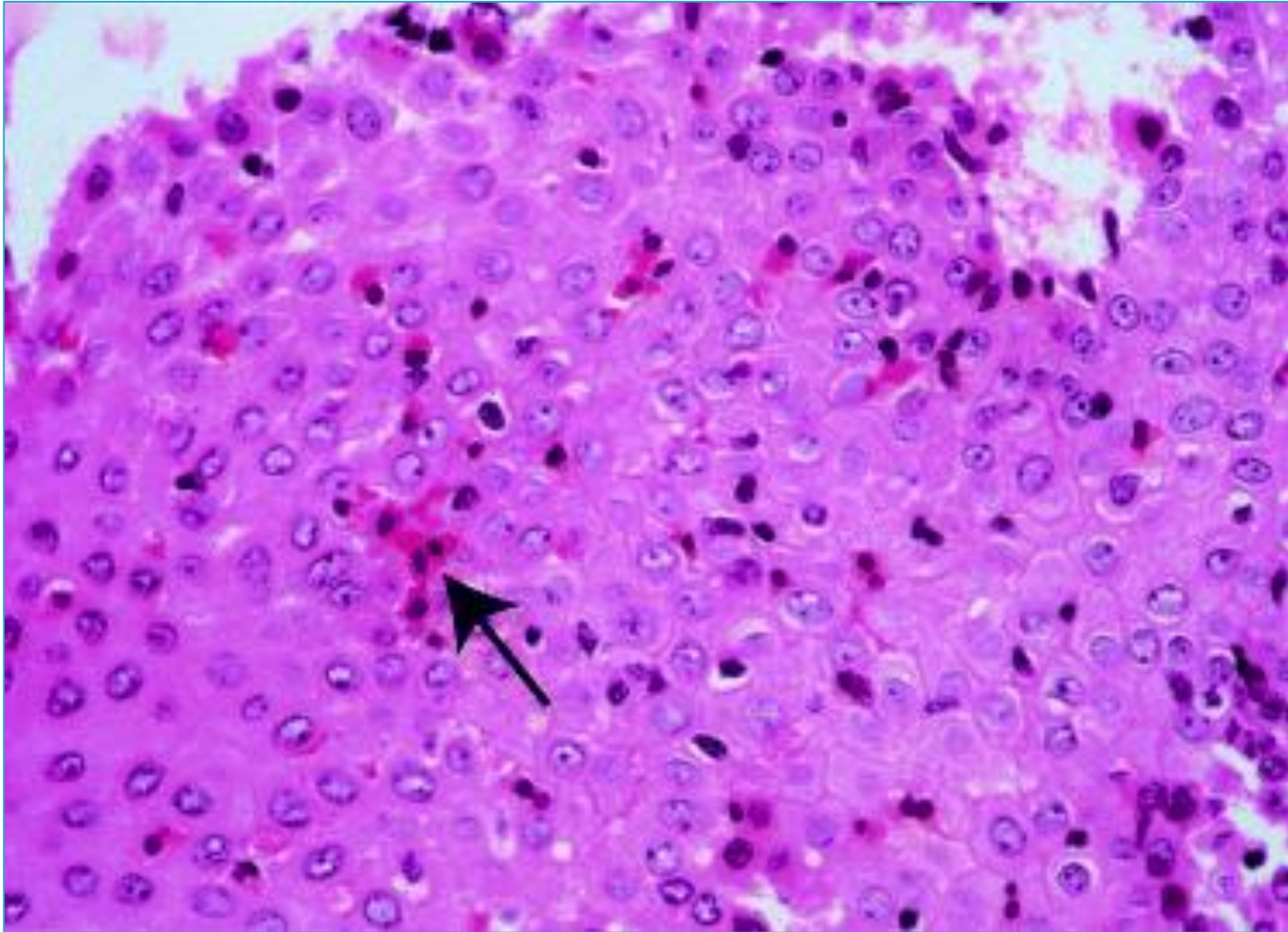


GERD – Endoscopy view



Reflux esophagitis – necrosis of esophageal epithelium causing ulcers near the junction of the stomach and esophagus

GERD – Microscopically HPF

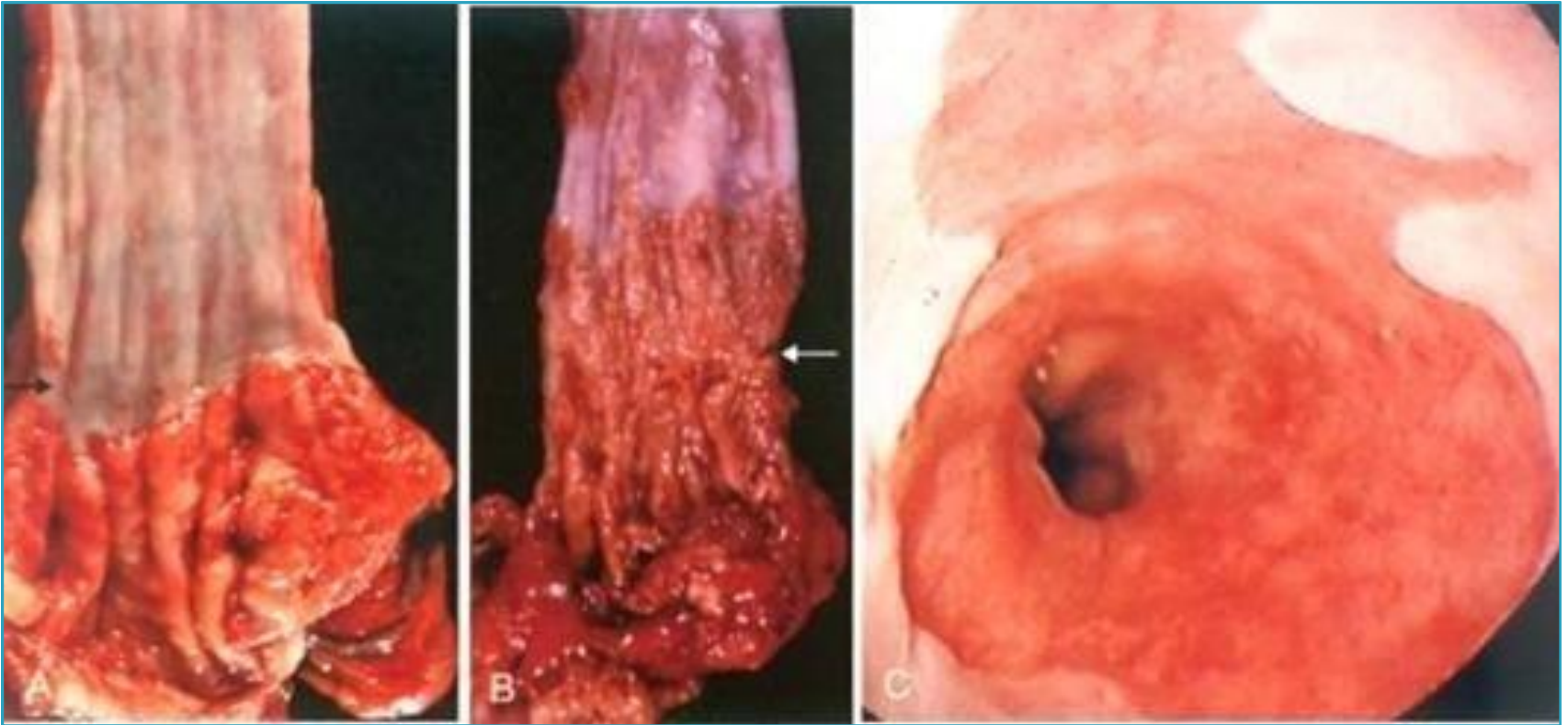


Intraepithelial eosinophils (arrow) and basal cell hyperplasia (high power, H/E stain).

GASTROESOPHAGEAL REFLUX DISEASE (GERD)

- **Inflammatory Cells:**
 - *Eosinophils*
 - *Neutrophils*
 - *Lymphocytes*
- **Basal zone hyperplasia**
- **Lamina Propria papillae elongated and congested**

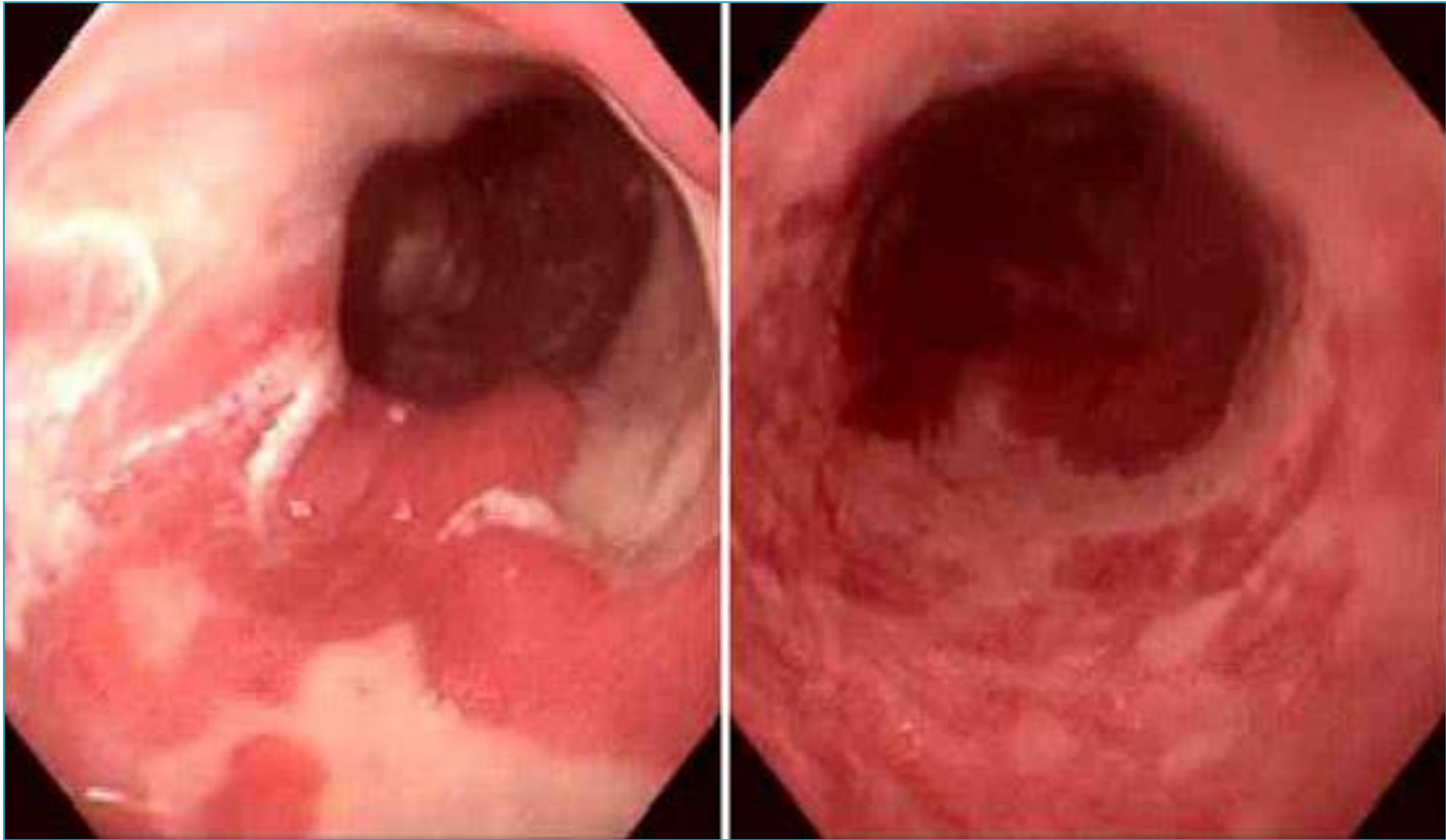
BARRETT'S ESOPHAGUS



Intestinalized metaplastic mucosa is at risk for glandular dysplasia.

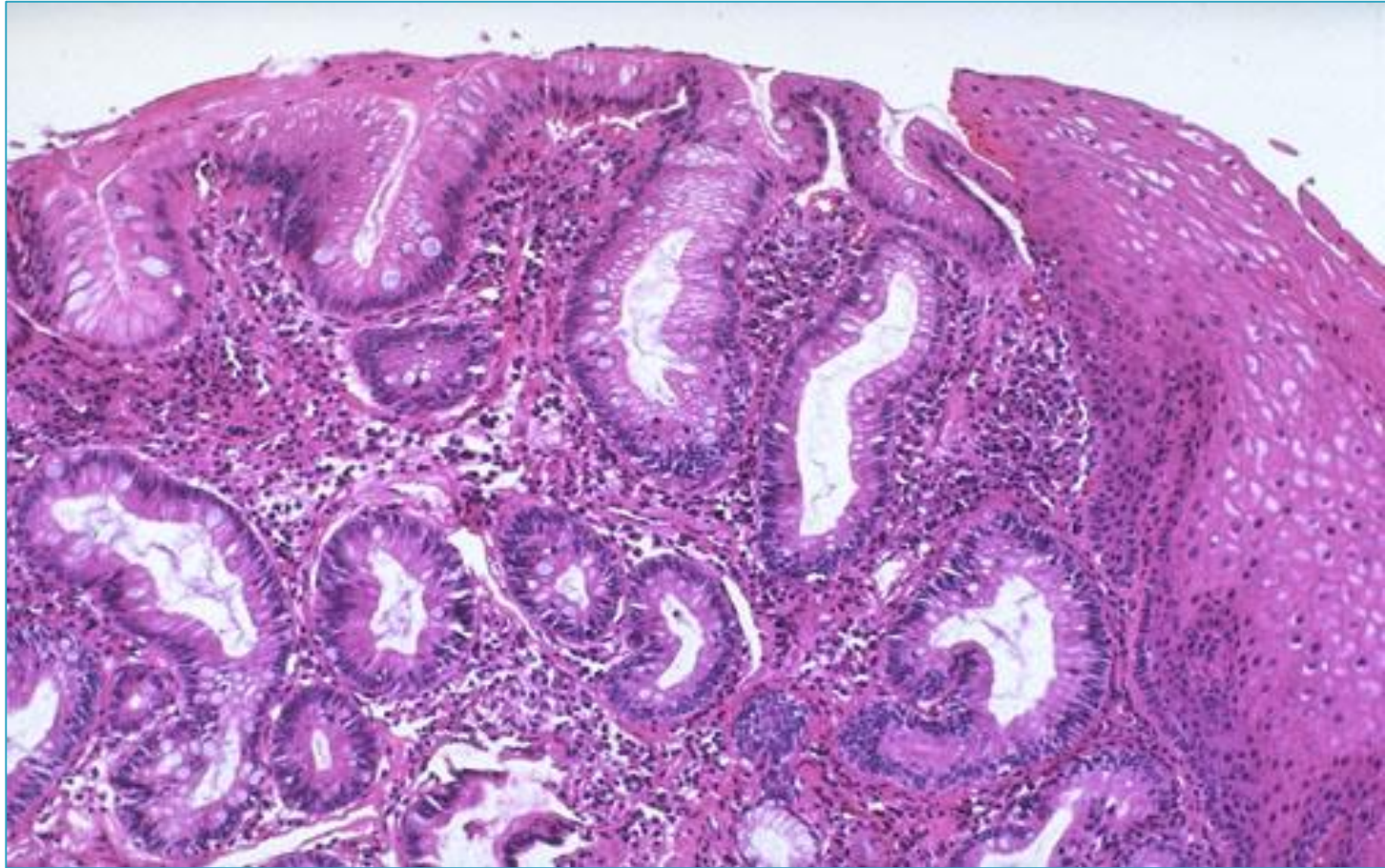
Searching for dysplasia when BARRETT's is present is of utmost importance. Most/All adenocarcinomas arising in the esophagus arise from previously existing BARRETT's . Newly named Columnar lined esophagus

Barrett's Esophagus – Endoscopic view



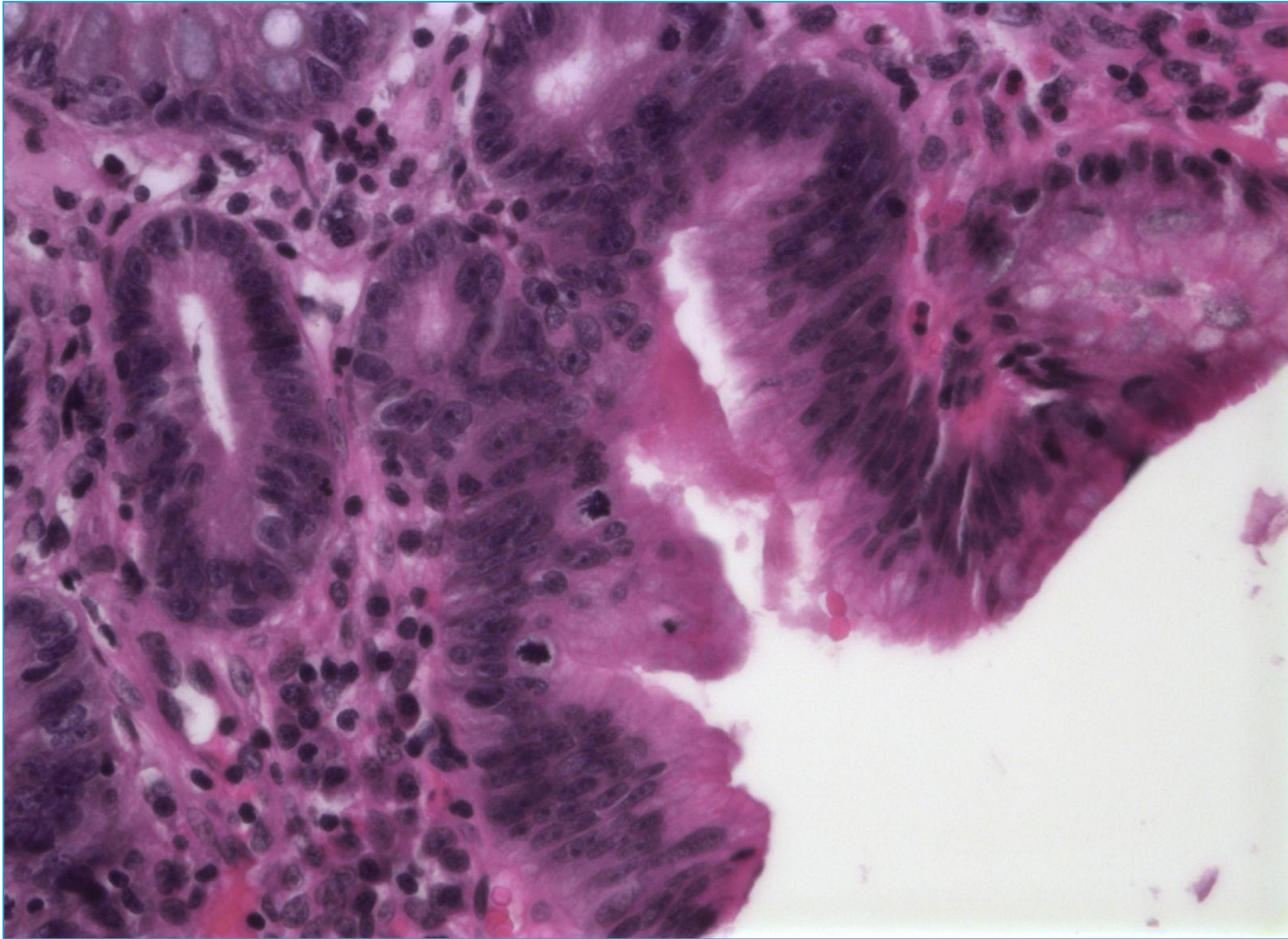
These two endoscopic views demonstrate Barrett esophagus areas of mucosal erythema of the lower esophagus, with islands of normal pale esophageal squamous mucosa.

Barrett's esophagus – Microscopic view



There is gastric-type mucosa above the gastroesophageal junction. Note the columnar epithelium to the left and the squamous epithelium at the right. Typical Barrett's mucosa shows intestinal metaplasia with chronic inflammation (note the goblet cells in the columnar mucosa).

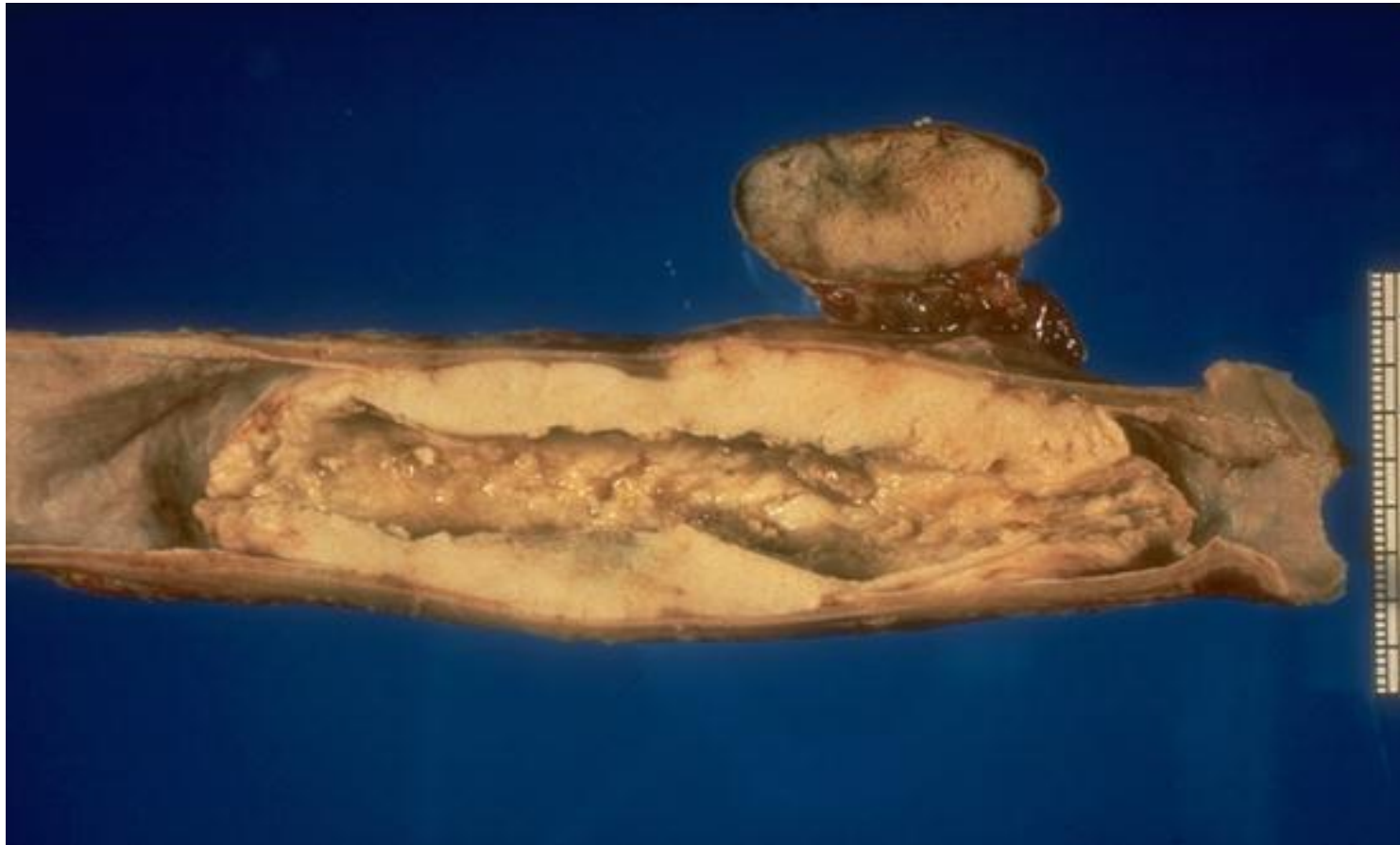Glandular "Dysplasia" - HPF





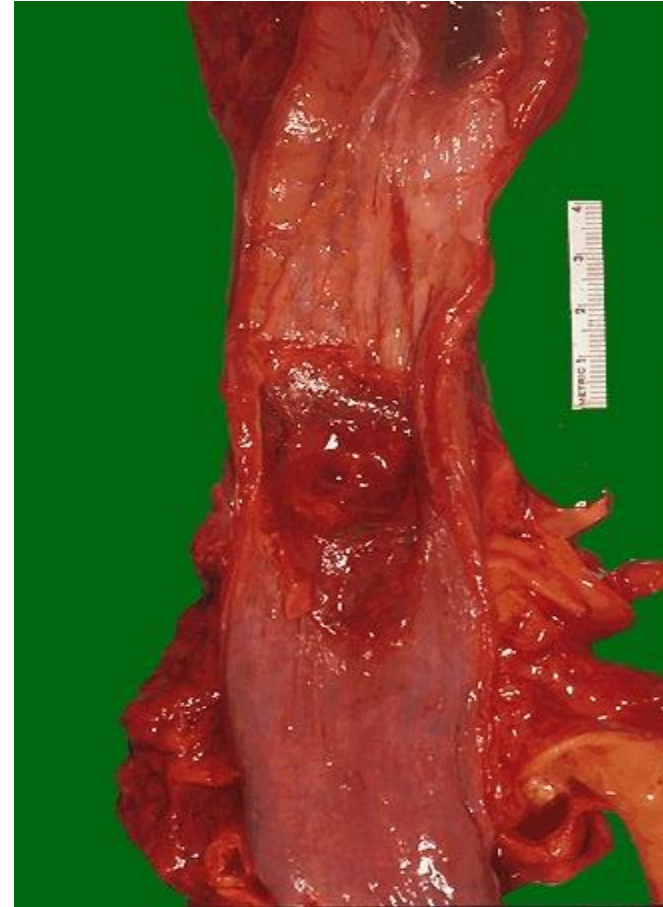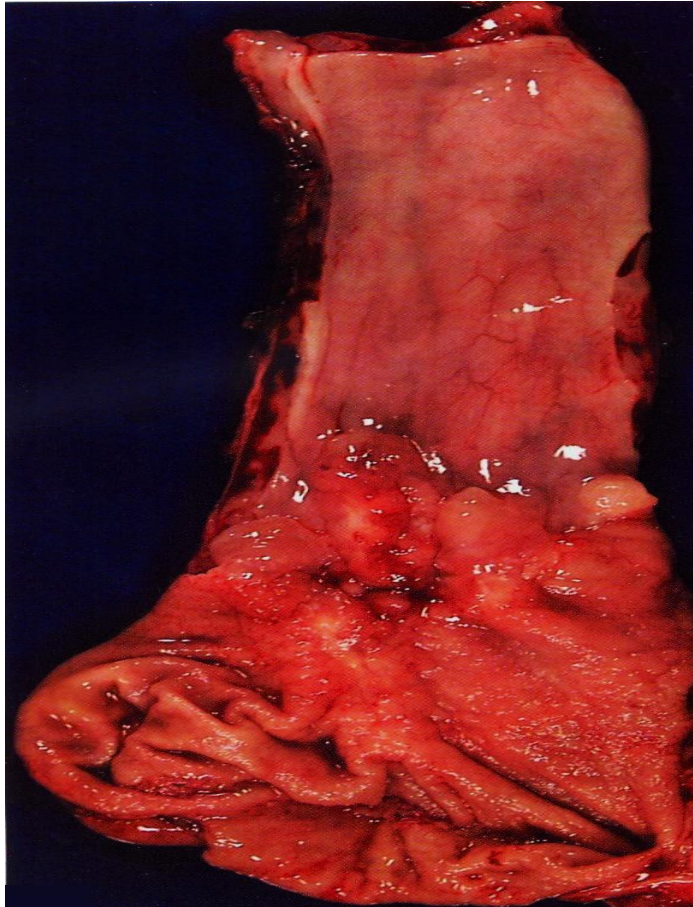
Carcinoma of the esophagus

Carcinoma of the Esophagus - Gross



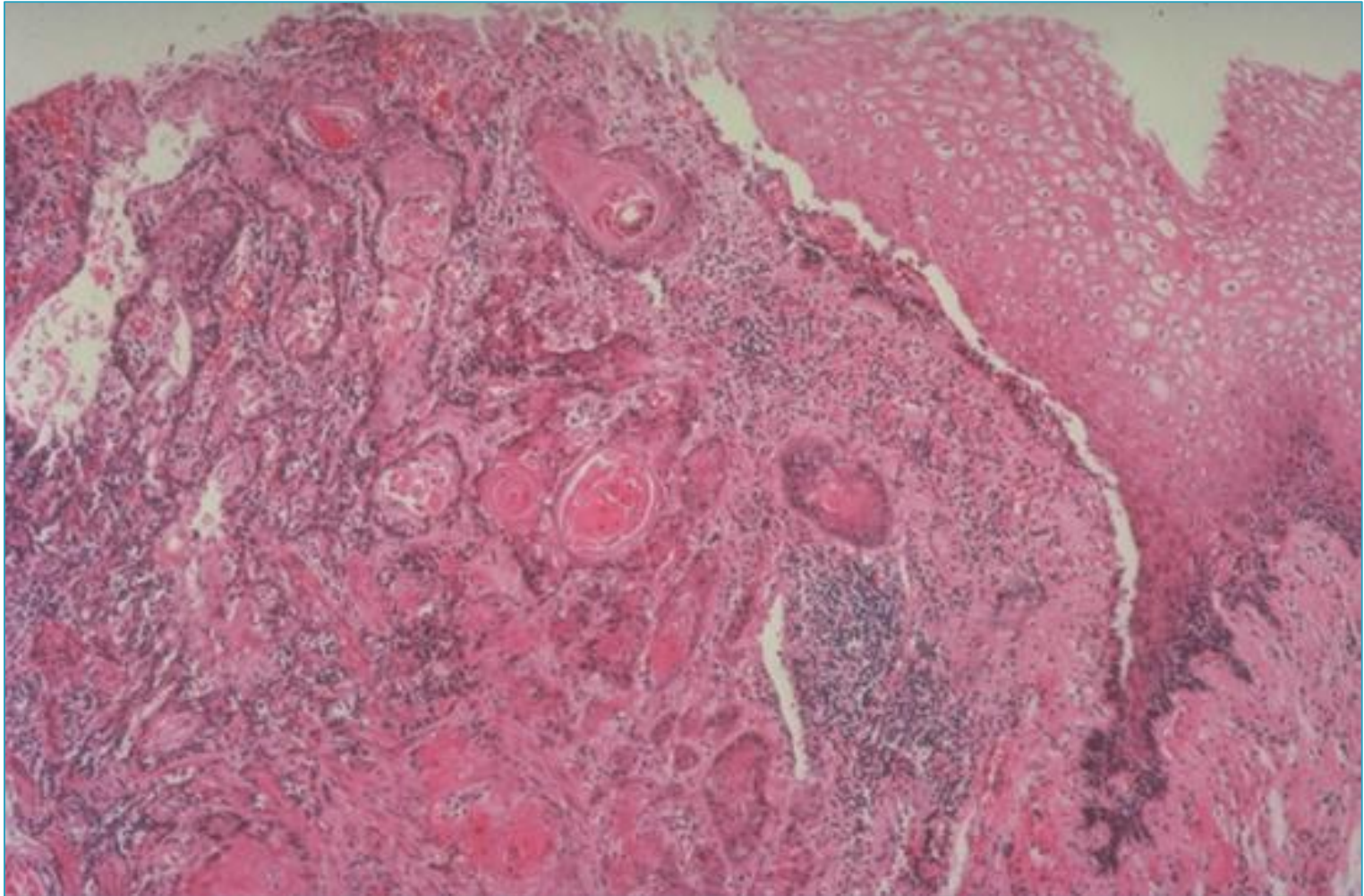
This gross photograph illustrates a squamous cell carcinoma of the esophagus in a patient who presented with progressive dysphagia. The oval structure adjacent to the esophagus represents metastatic squamous cell carcinoma within a lymph node.

Carcinoma of the Esophagus - Gross



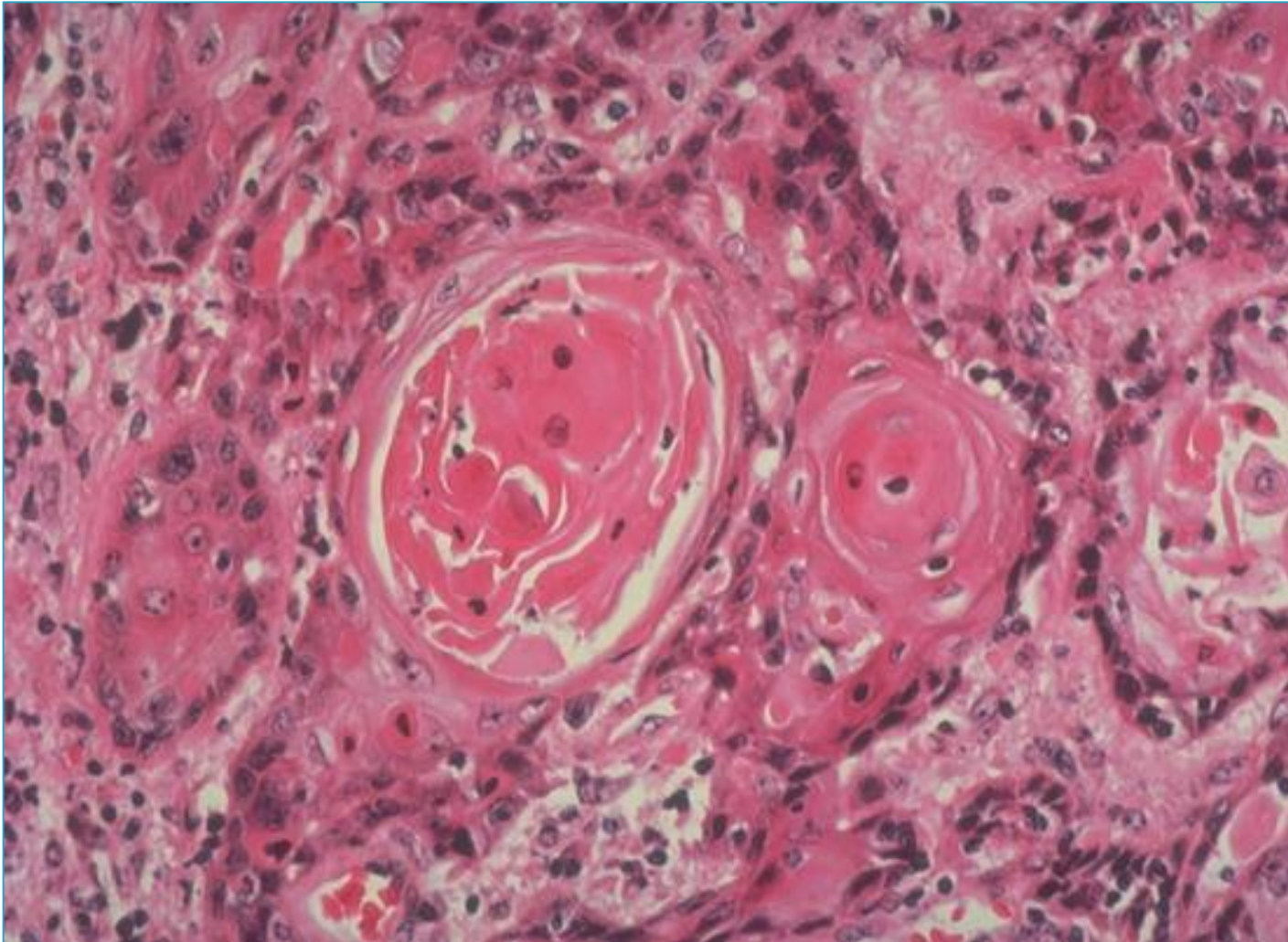
This irregular reddish, ulcerated exophytic mid-esophageal mass as seen on the mucosal surface is a squamous cell carcinoma. Endoscopic views of an ulcerated mid-esophageal squamous cell carcinoma causing luminal stenosis .

Squamous Cell Carcinoma of the Esophagus - LPF



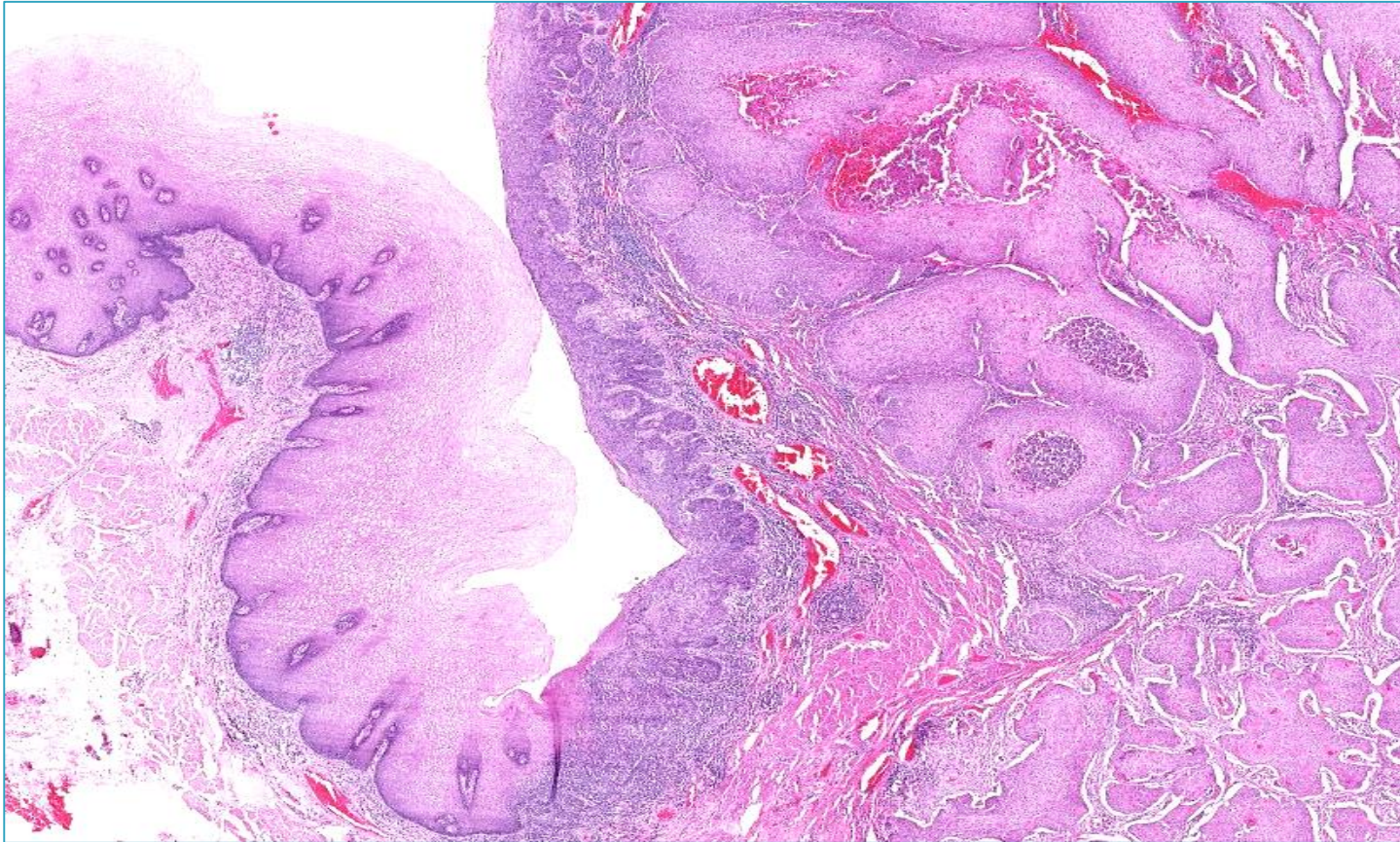
Infiltrating nests of neoplastic cells

Squamous Cell Carcinoma of the Esophagus - HPF



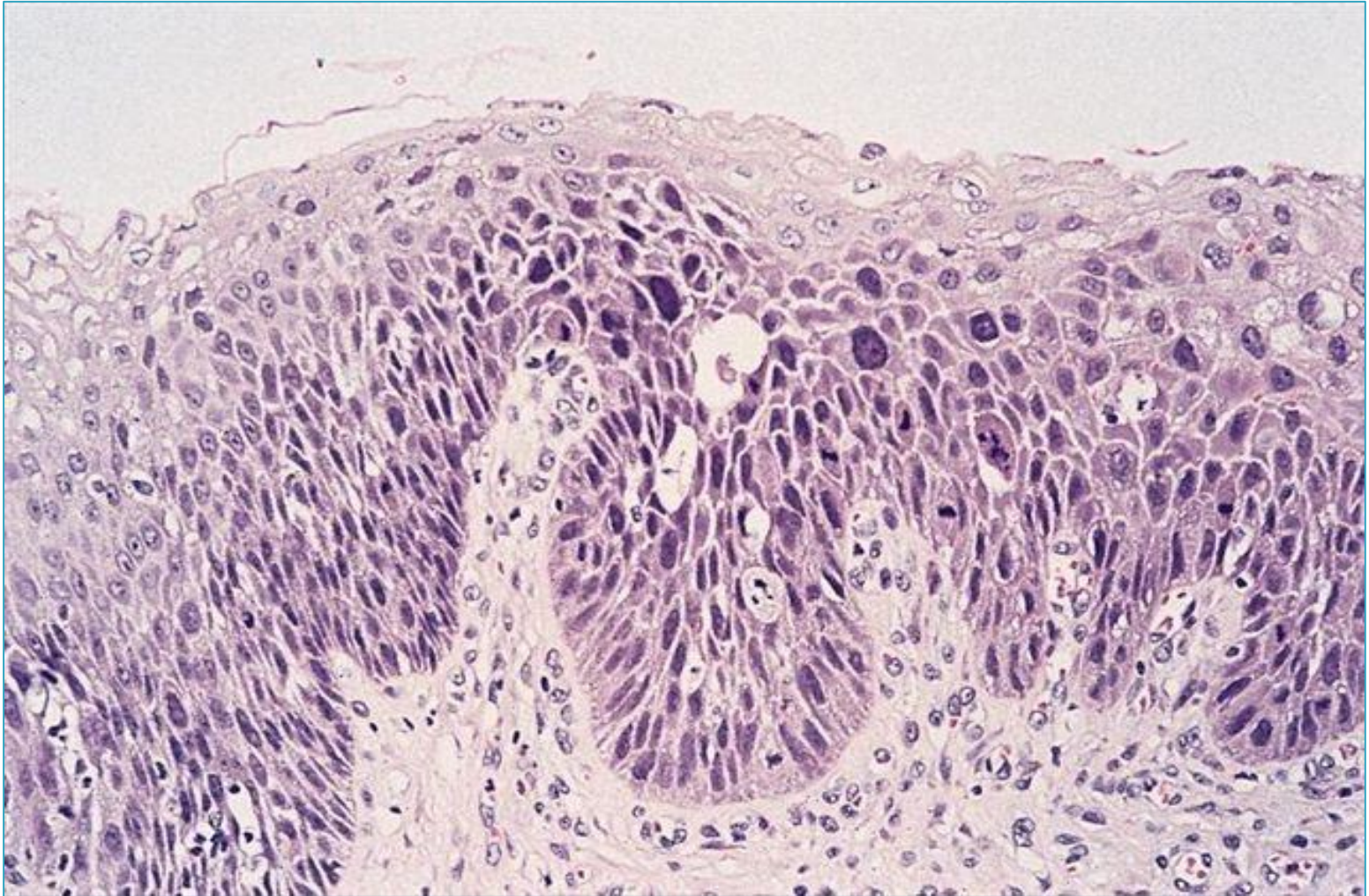
Solid nests of neoplastic cells having abundant pink cytoplasm and distinct cell borders

Squamous Dysplasia of the Esophagus - LPF



There are atypical squamous cells with disorganized architecture and abnormal differentiation within the epithelium. These features are obvious in high grade dysplasia. The nuclei are larger and more hyperchromatic than normal, and there is increased mitotic activity

Squamous Dysplasia of the Esophagus - HPF



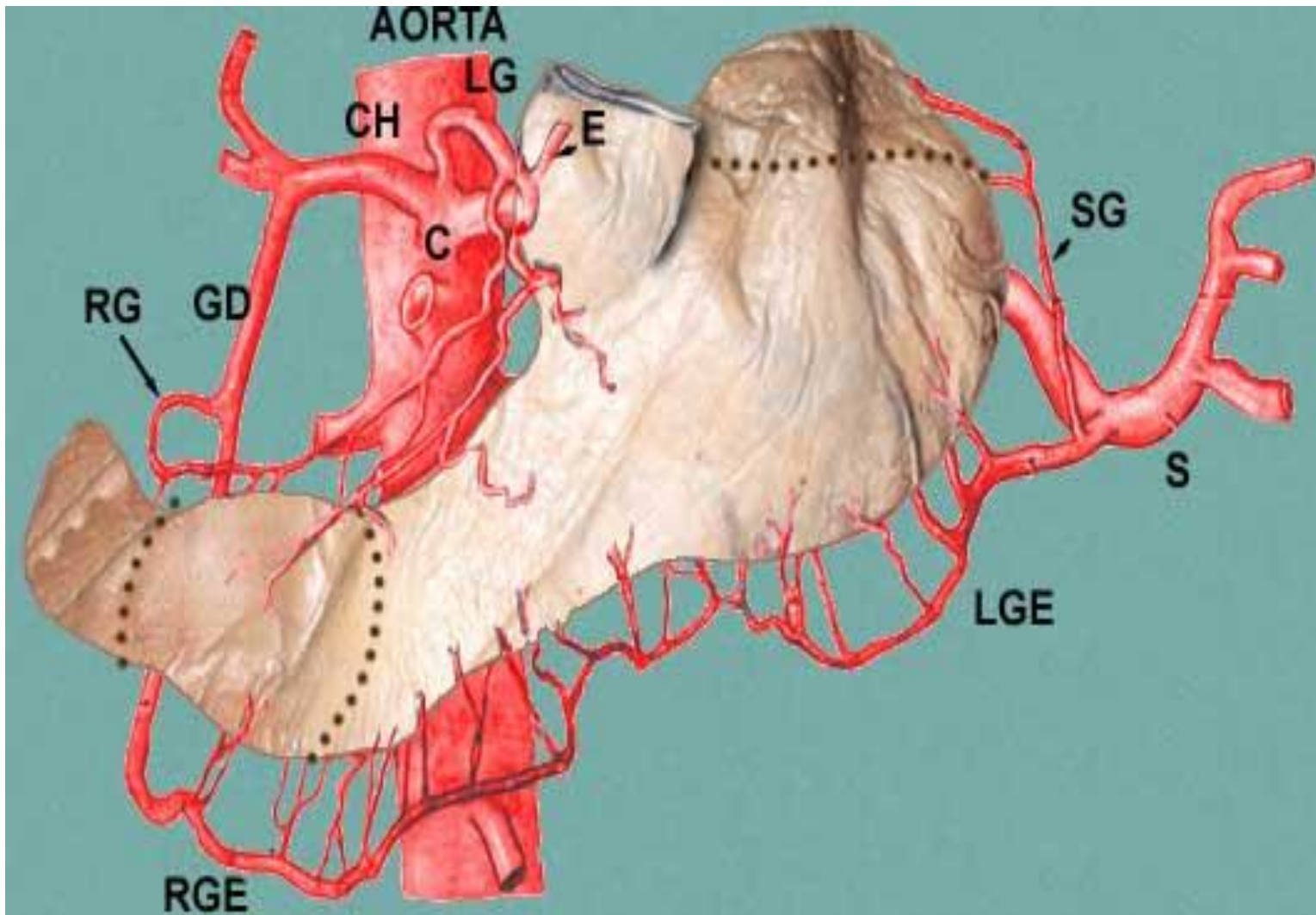
Squamous dysplasia of the esophagus may develop with time into squamous cell carcinoma



STOMACH

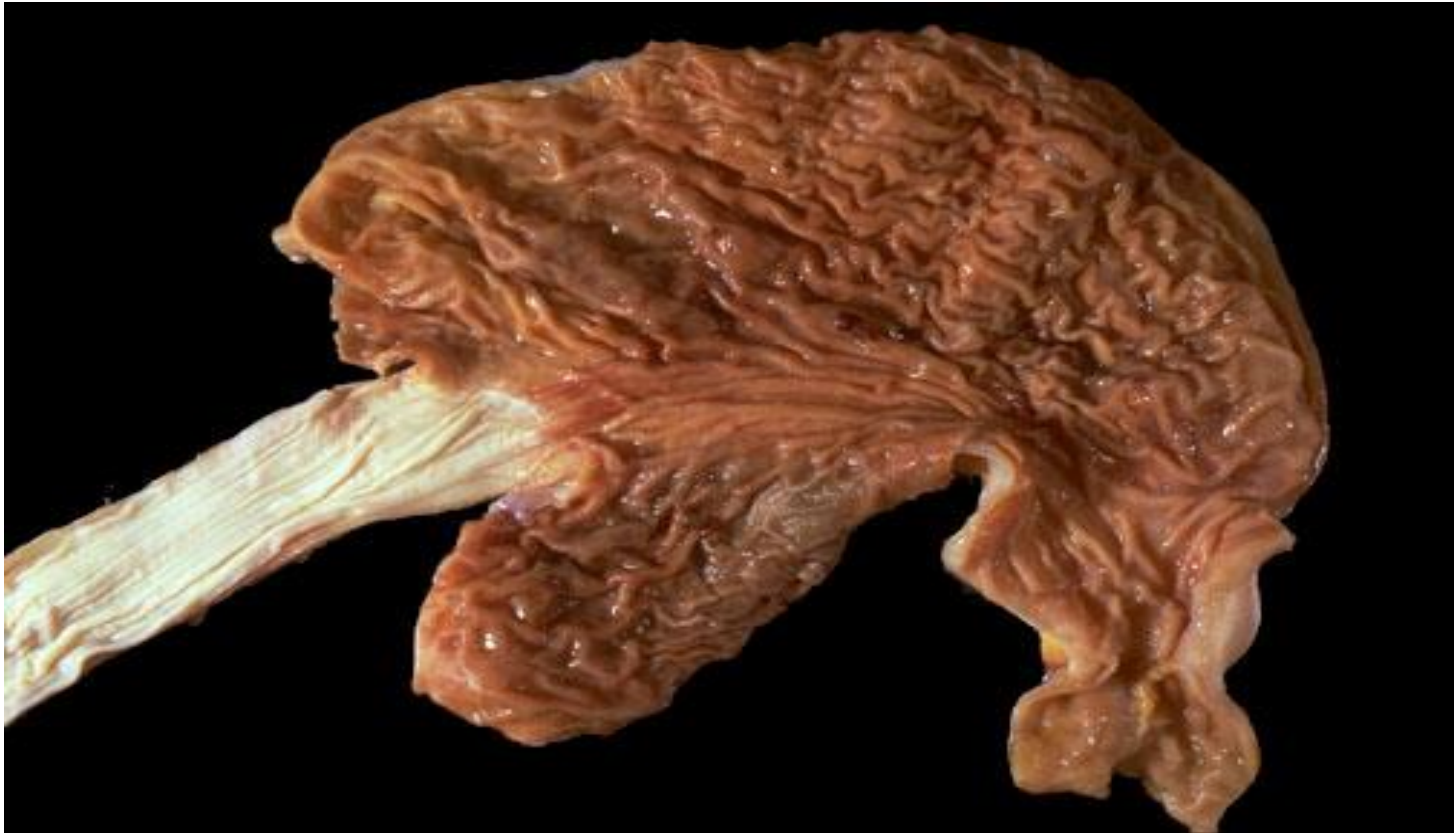***Normal anatomy and
histology***

Vasculature of the Stomach



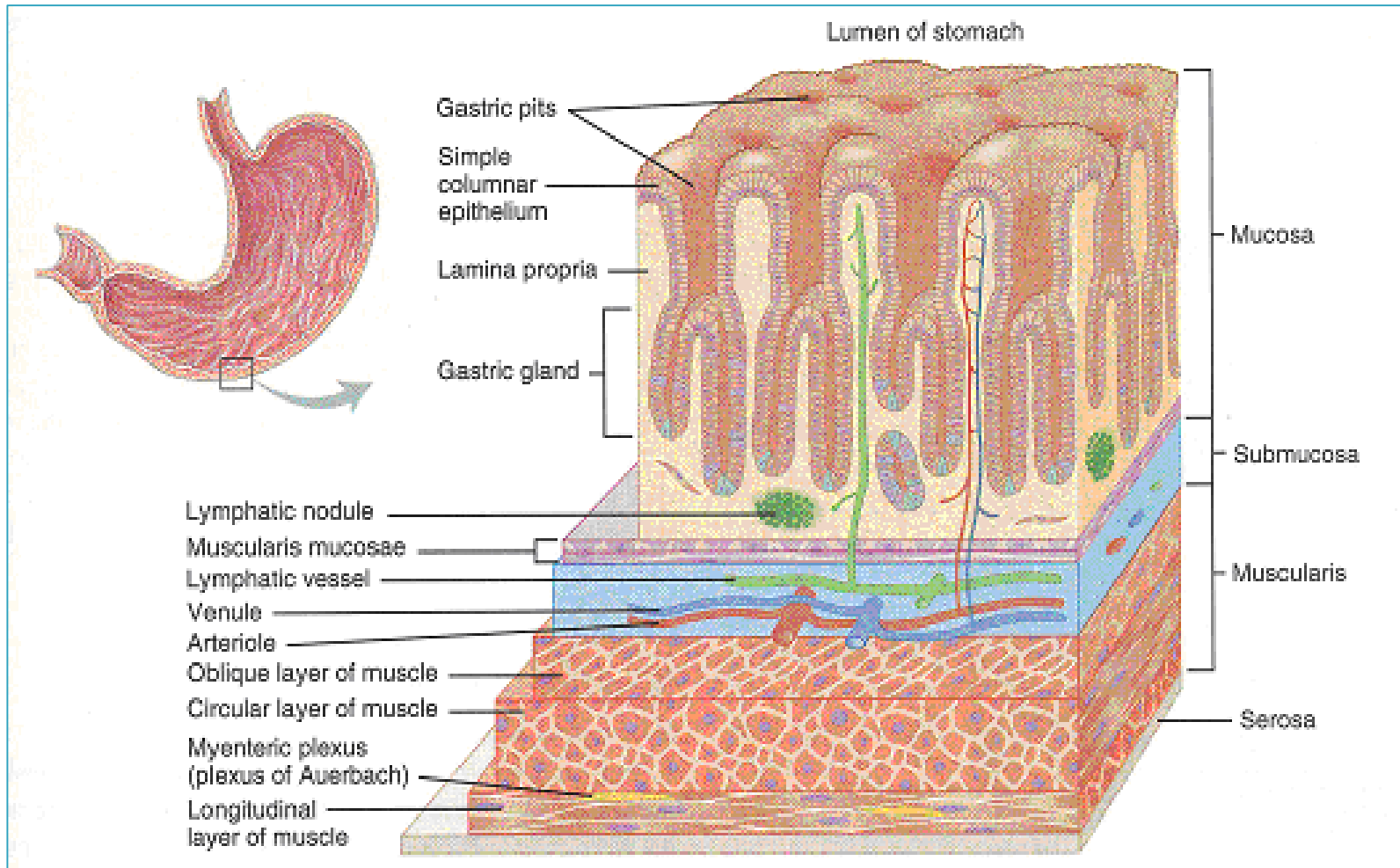
***ALL 3 classic branches of the celiac axis supply the stomach:
Common hepatic, left gastric, and splenic***

Stomach : Normal Endoscopic View



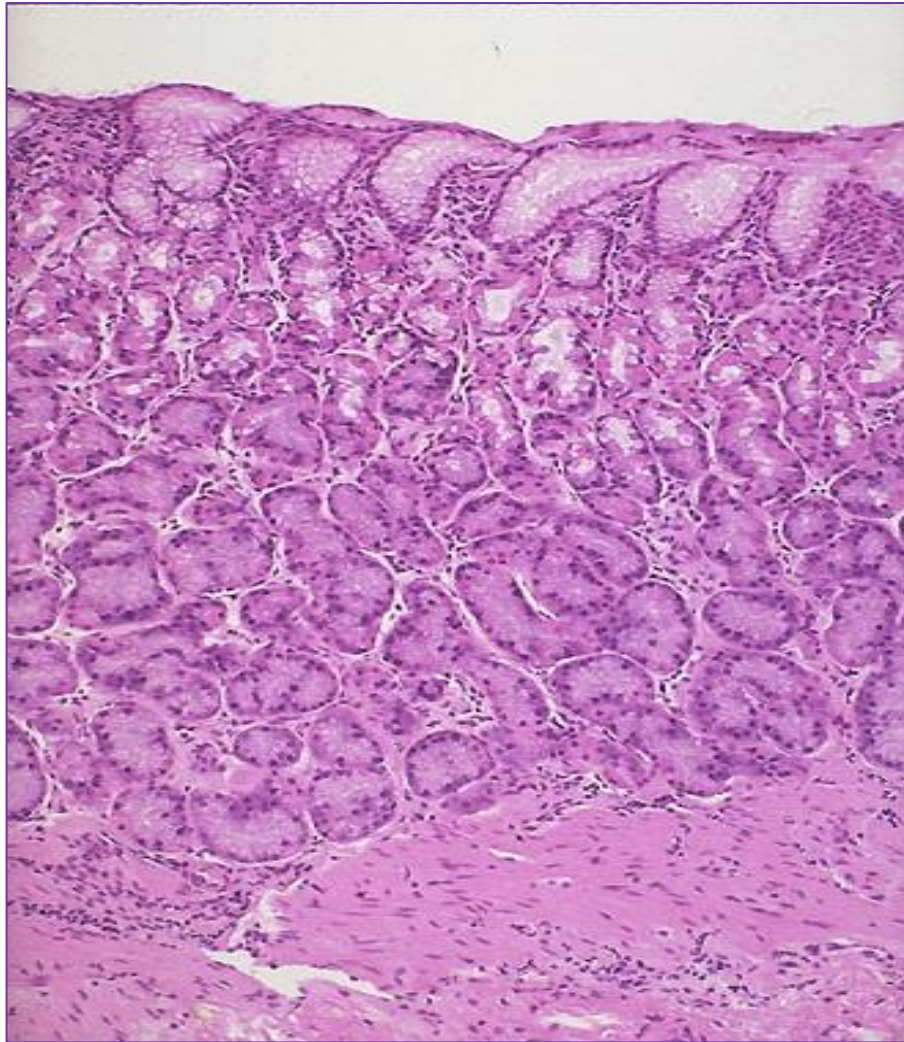
This is the normal appearance of the stomach, which has been opened along the greater curvature. The esophagus is at the left. In the fundus can be seen the lesser curvature. Just beyond the antrum is the pylorus emptying into the first portion of duodenum is at the lower right.

Histology of the Stomach - Diagram



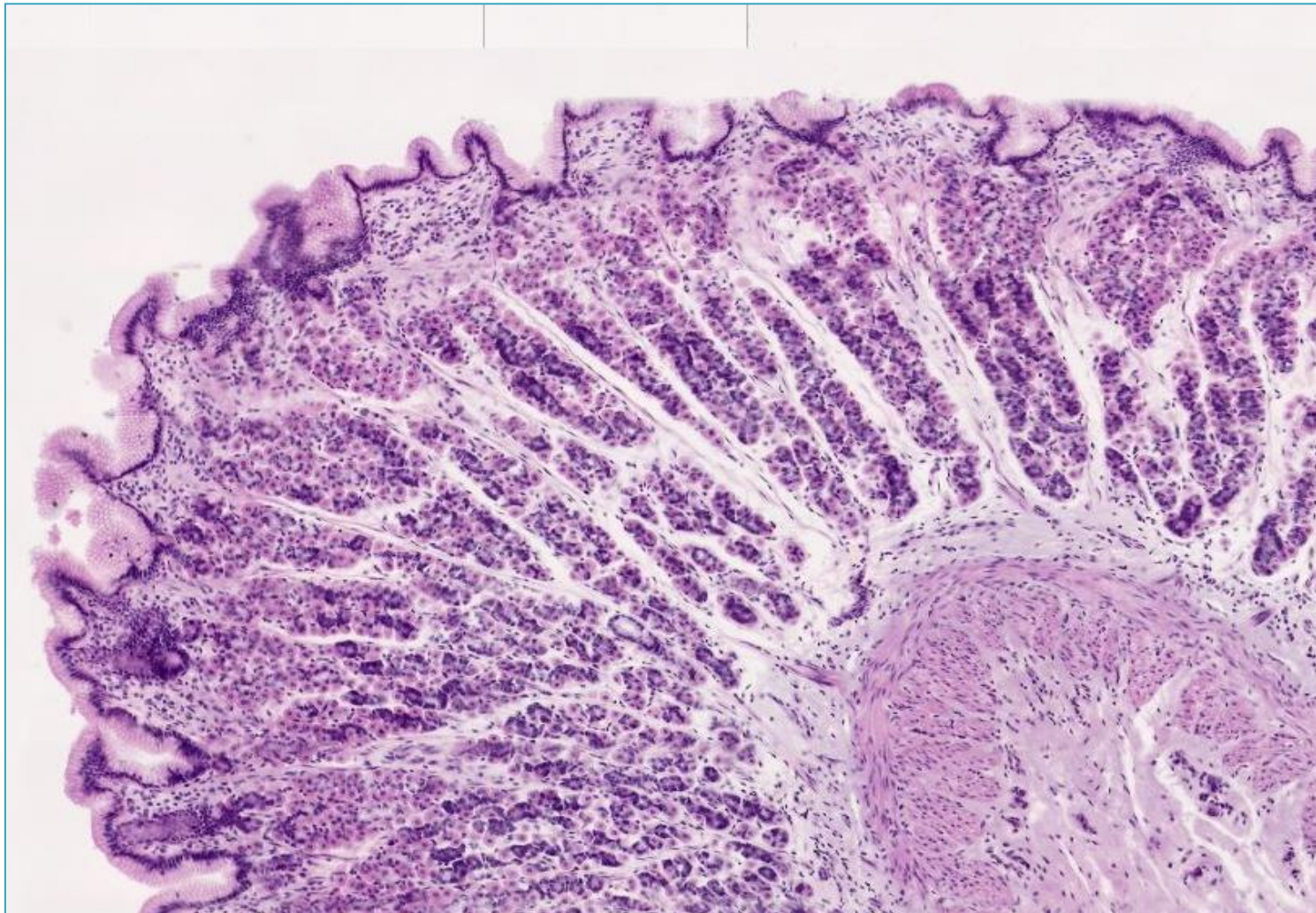
If you think of the acid production in the stomach to be ONLY in the mid-BODY, and the proximal and distal ends as chiefly mucous to protect the esophagus and duodenum from the harsh acid, then you will understand the histology.

Stomach Fundus - Normal MPF



This is the normal appearance of the gastric fundal mucosa, with short pits lined by pale columnar mucus cells leading into long glands which contain bright pink parietal cells that secrete hydrochloric acid.

Histology of acid-producing cells in the Stomach



Body with numerous chief and parietal (acid producing) cells.

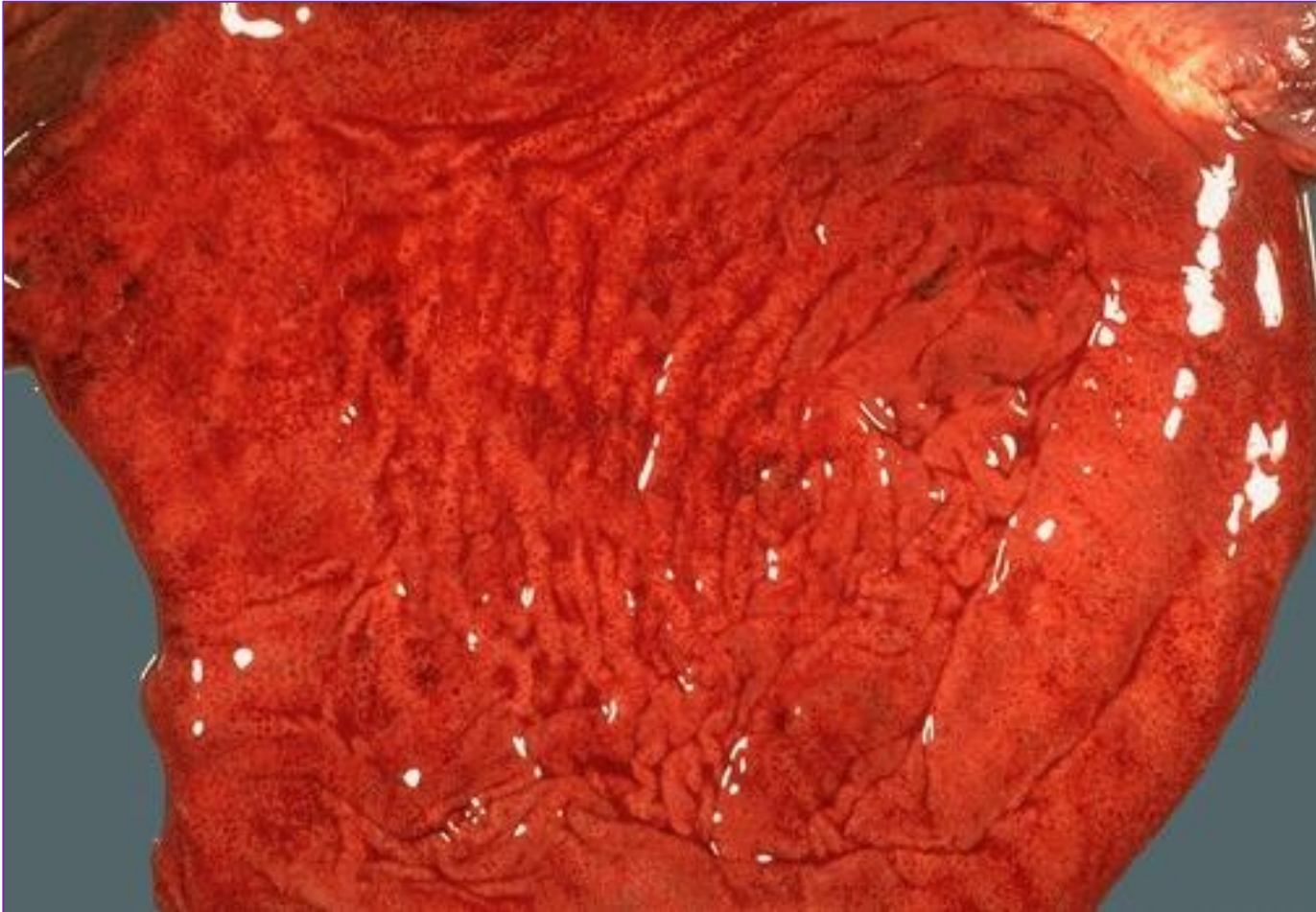


Gross and histopathology



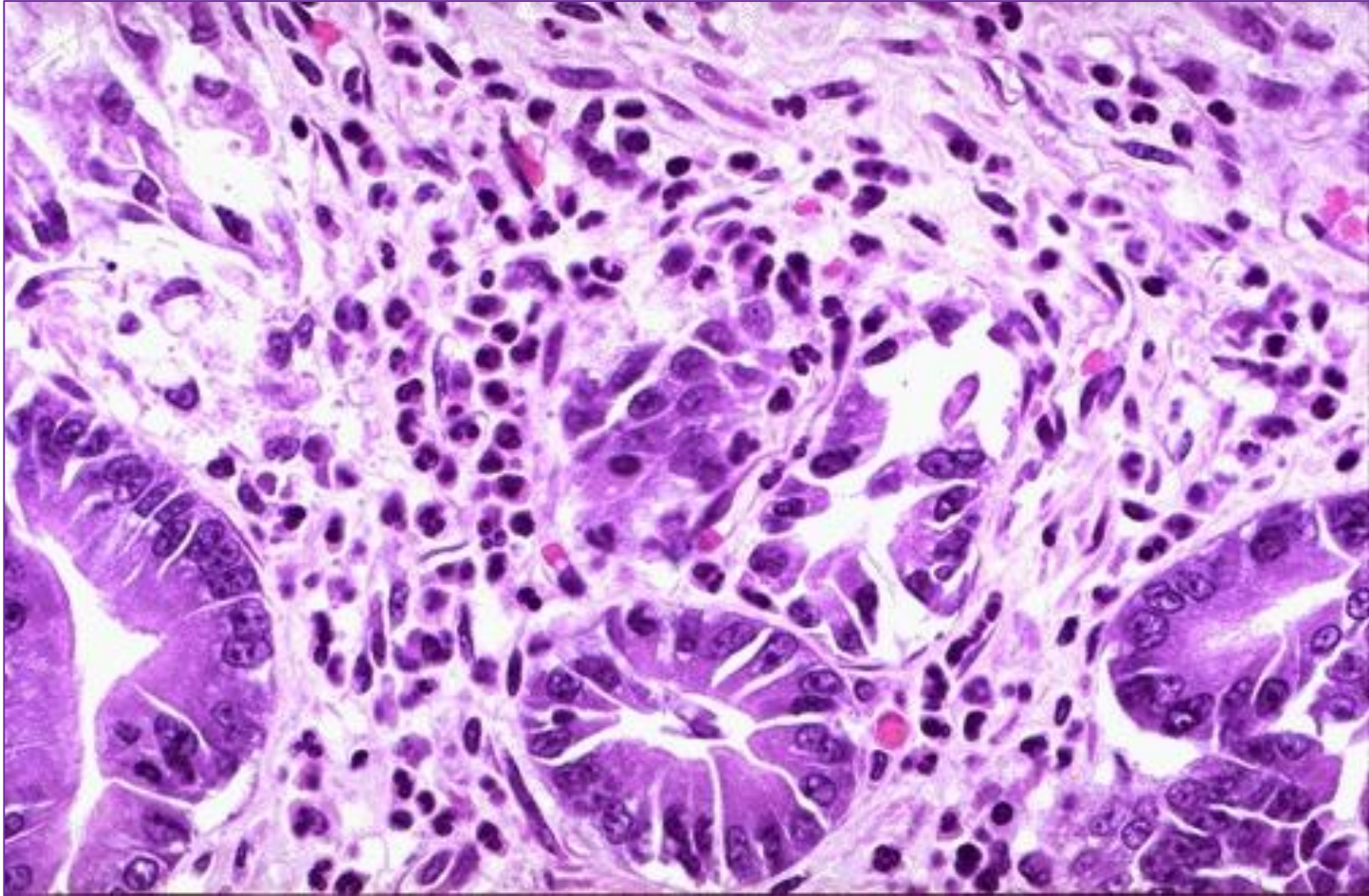
ACUTE GASTRITIS

Acute Gastritis – Gross endoscopic view



This is a more typical acute gastritis with a diffusely hyperemic gastric mucosa. There are many causes for acute gastritis: alcoholism, drugs, infections, etc.

Acute Gastritis - HPF



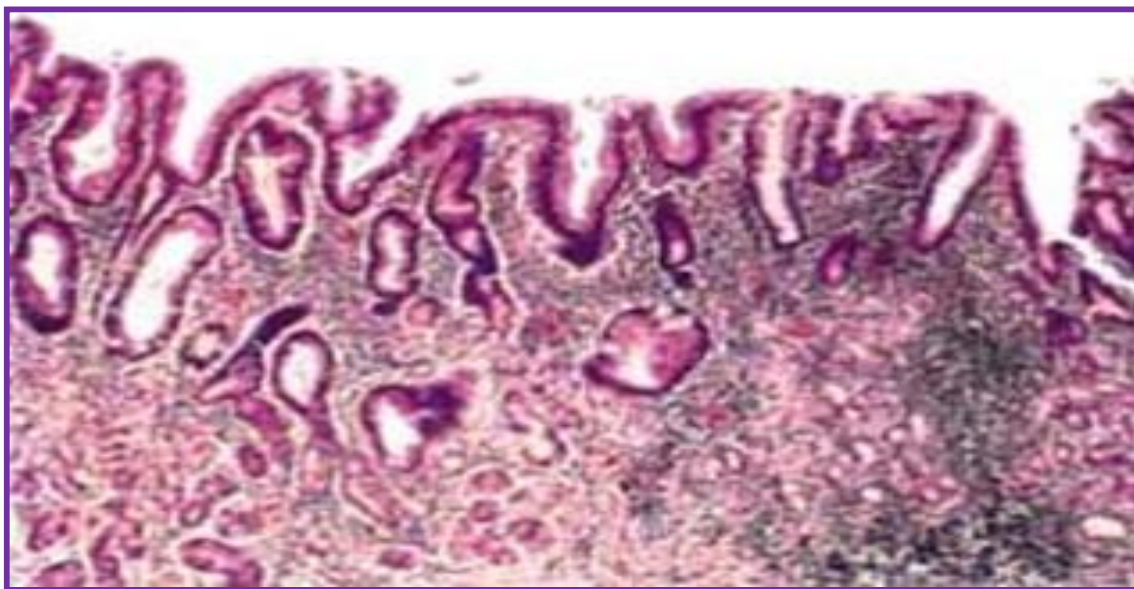
Acute gastritis: At high power, gastric mucosa demonstrates infiltration by neutrophils..



CHRONIC GASTRITIS

Chronic Gastritis

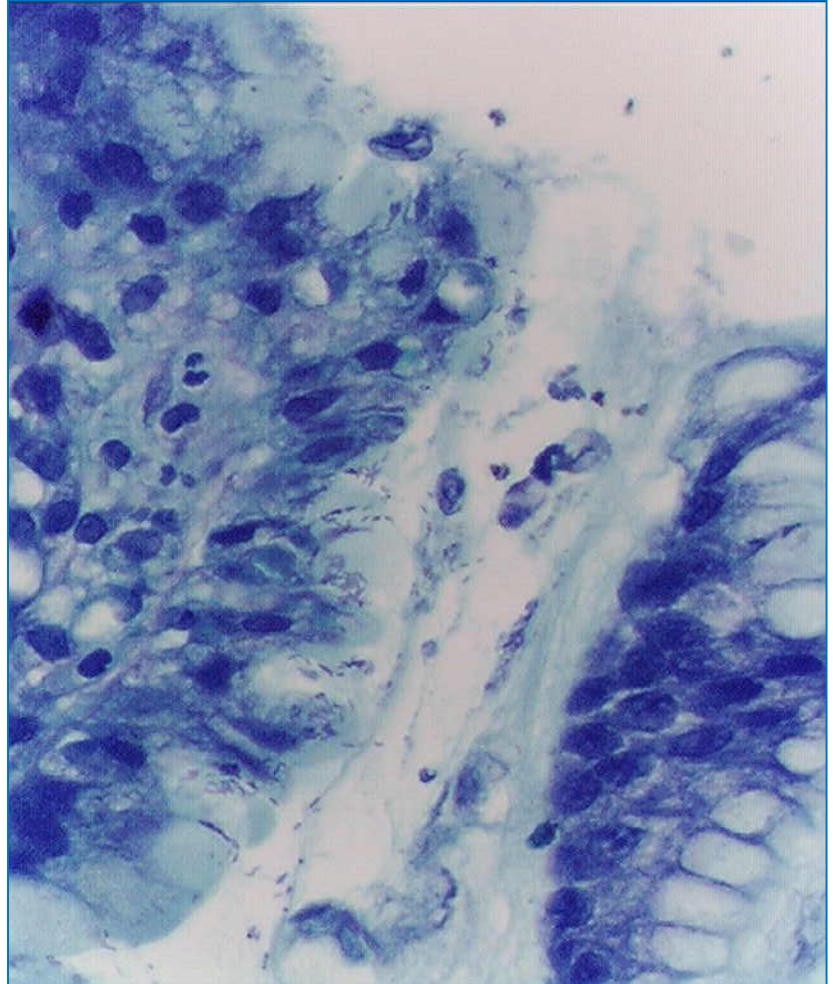
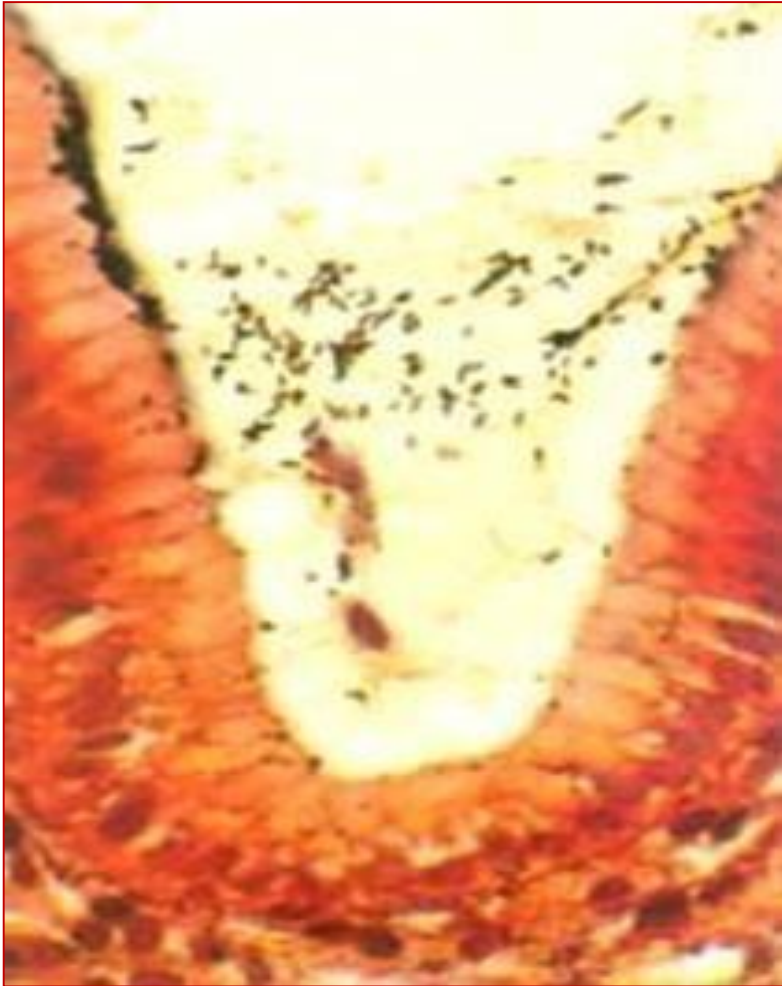- ***CHRONIC, NO EROSIONS, NO HEMORRHAGE***
- ***PERHAPS SOME NEUTROPHILS***
- ***LYMPHOCYTES, LYMPHOID FOLLICLES***
- ***REGENERATIVE CHANGES***
 - ***METAPLASIA (Intestinal)***
 - ***ATROPHY : Mucosal Hypoplasia, "thinning"***
 - ***DYSPLASIA***





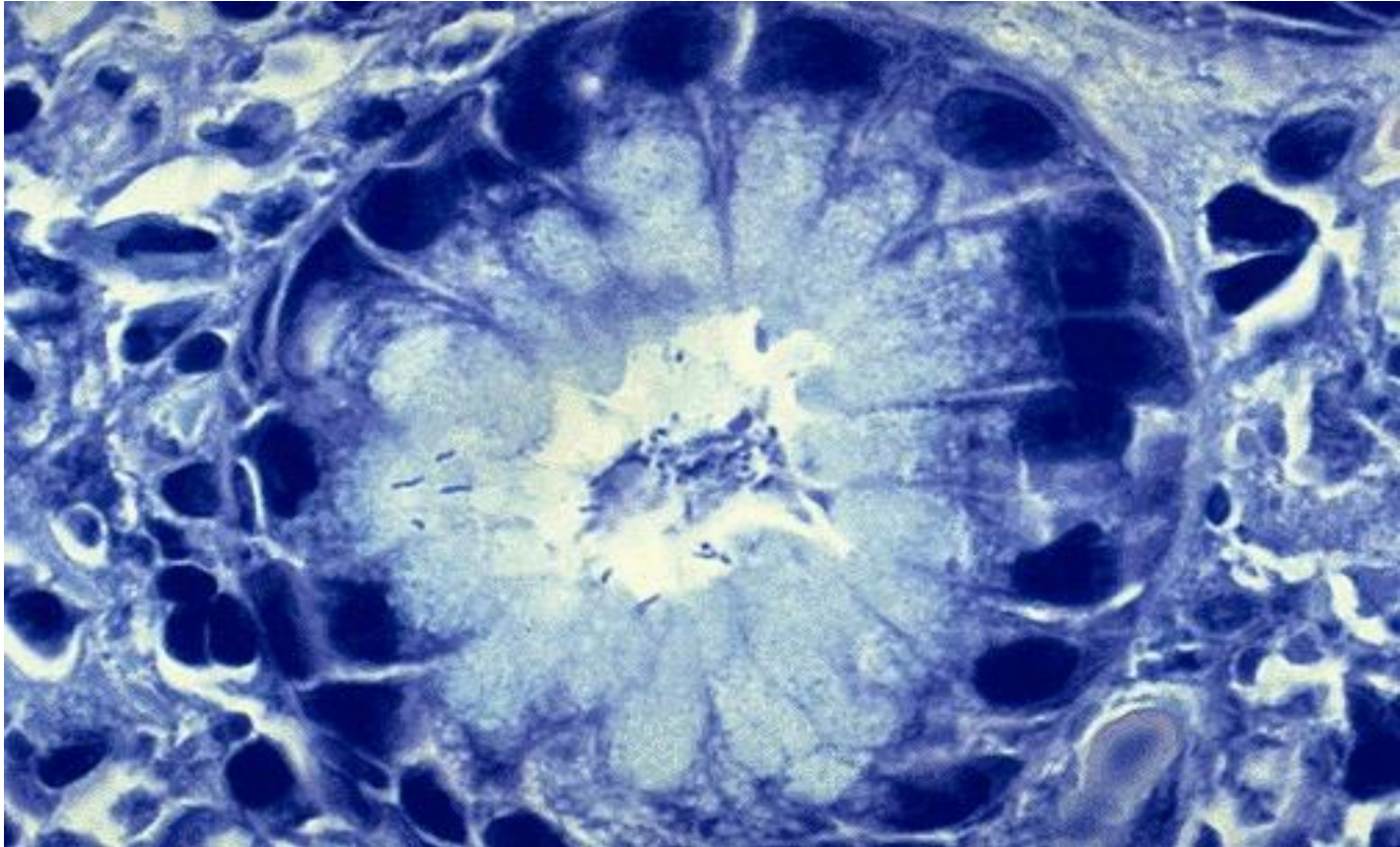
GASTRITIS : ***Helicobacter-induced***

Helicobacter pylori



***Helicobacter pylori*, gastric biopsy:
Silver stain on left, Giemsa stain on right.**

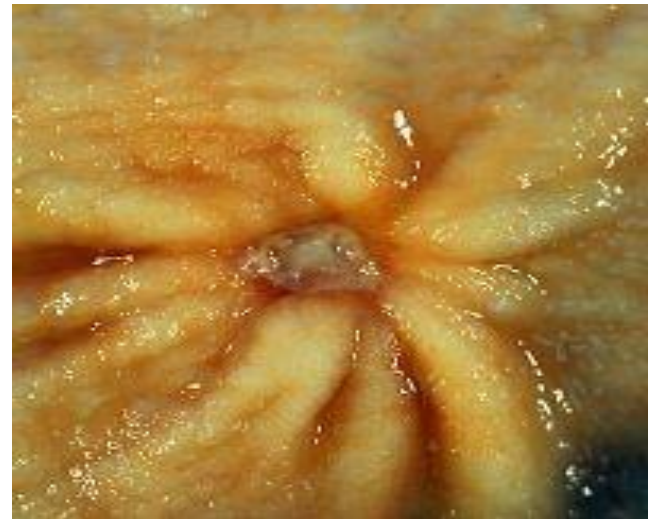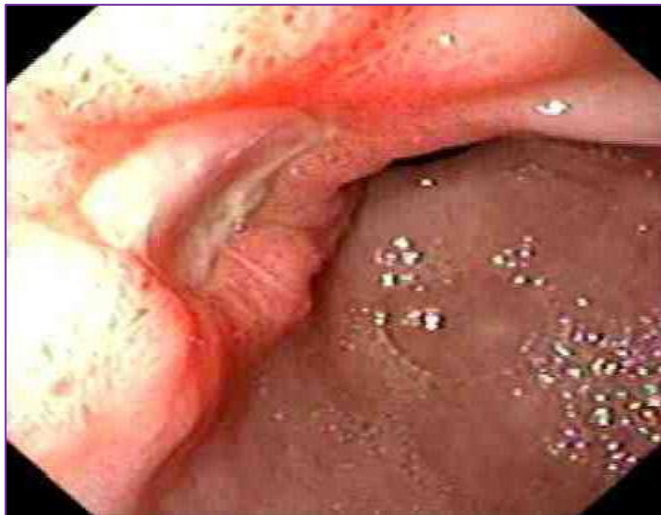
Helicobacter pylori in stomach – Microscopic view



Gastritis is often accompanied by infection with Helicobacter pylori. This small curved to spiral rod-shaped bacterium is found in the surface epithelial mucus of most patients with active gastritis. The rods are seen here with a methylene blue stain

Peptic Ulcers

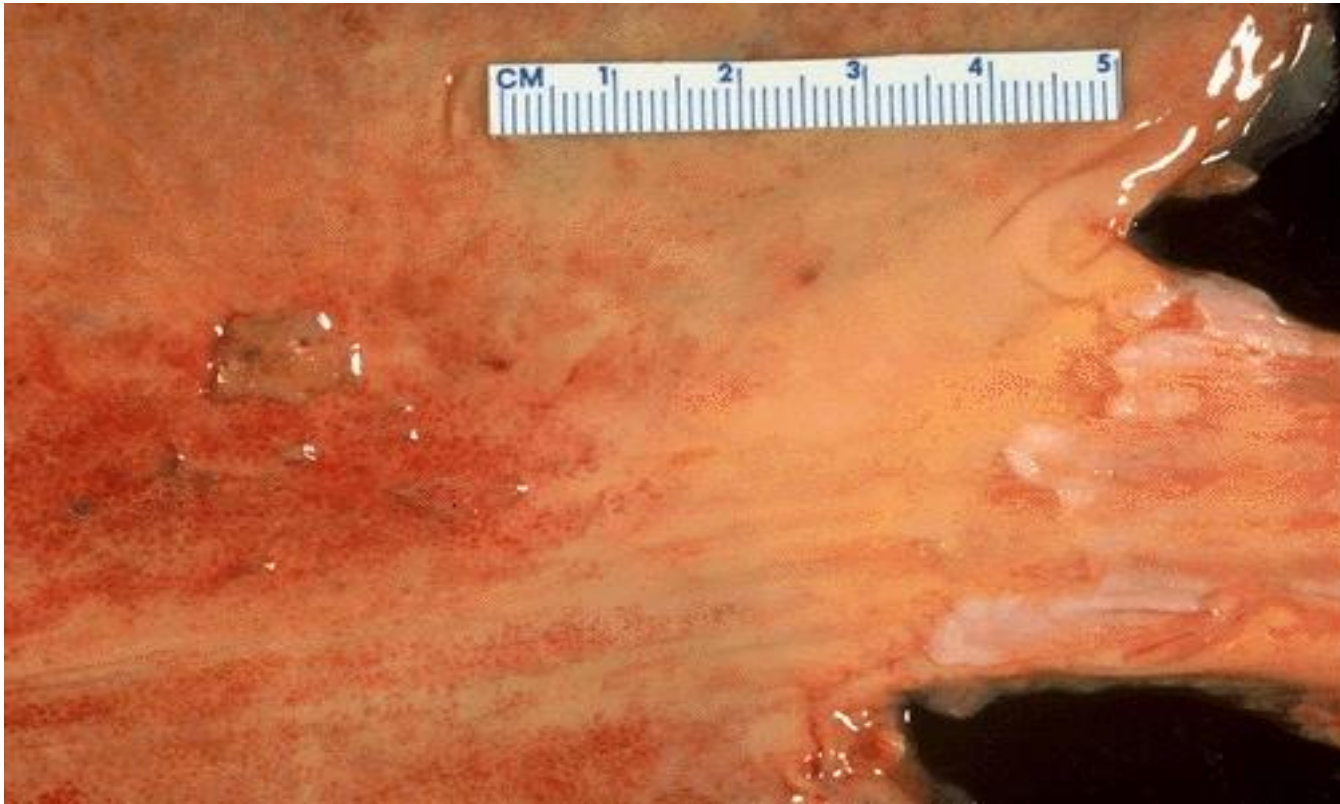
- “PEPTIC” implies acid cause/aggravation
- Ulcer vs. Erosion (muscularis mucosa intact)
- Mucosa → Submucosa → Muscularis → Serosa
- Chronic, solitary (usually), adults
- 80% caused by *H. pylori*
- NSAIDs
- Stress





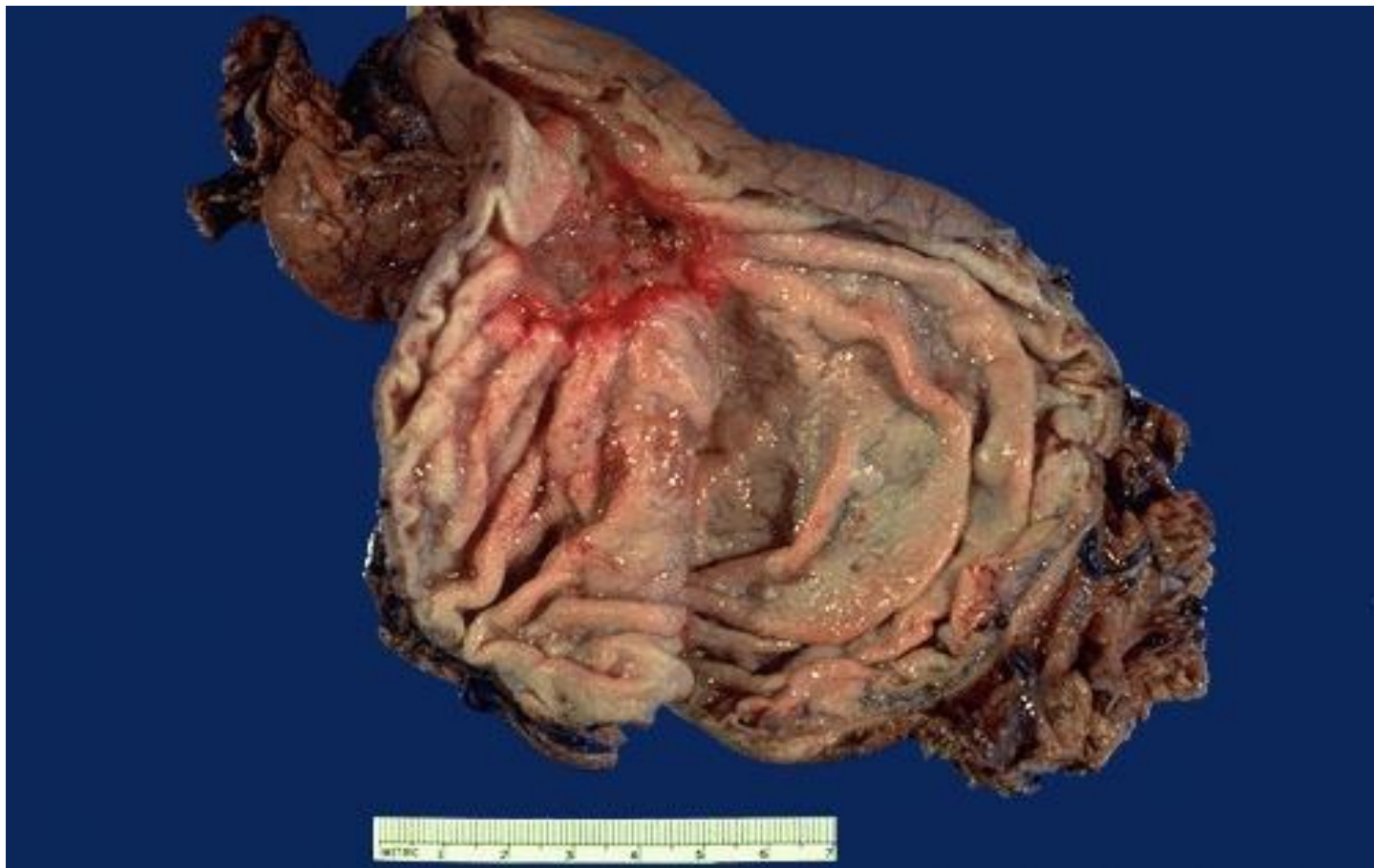Acute gastric ulcer

Acute Gastric Ulcer : Benign , Gross



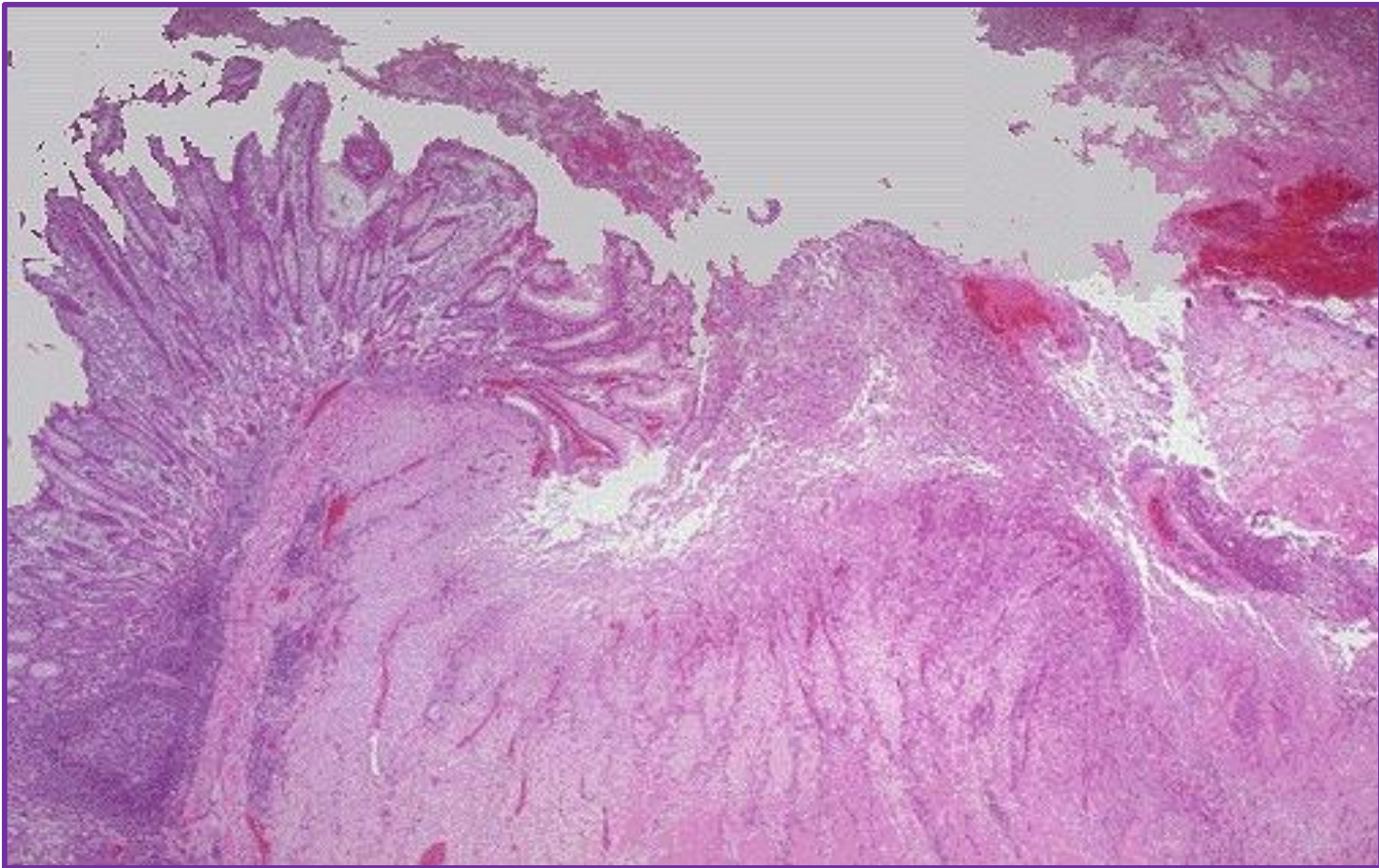
A 1 cm acute gastric ulcer is shown here in the upper fundus. The ulcer is shallow and sharply demarcated, with surrounding hyperemia. It is probably benign. However, all gastric ulcers should be biopsied to rule out a malignancy.

Acute Gastric Ulcer : Malignant , Gross



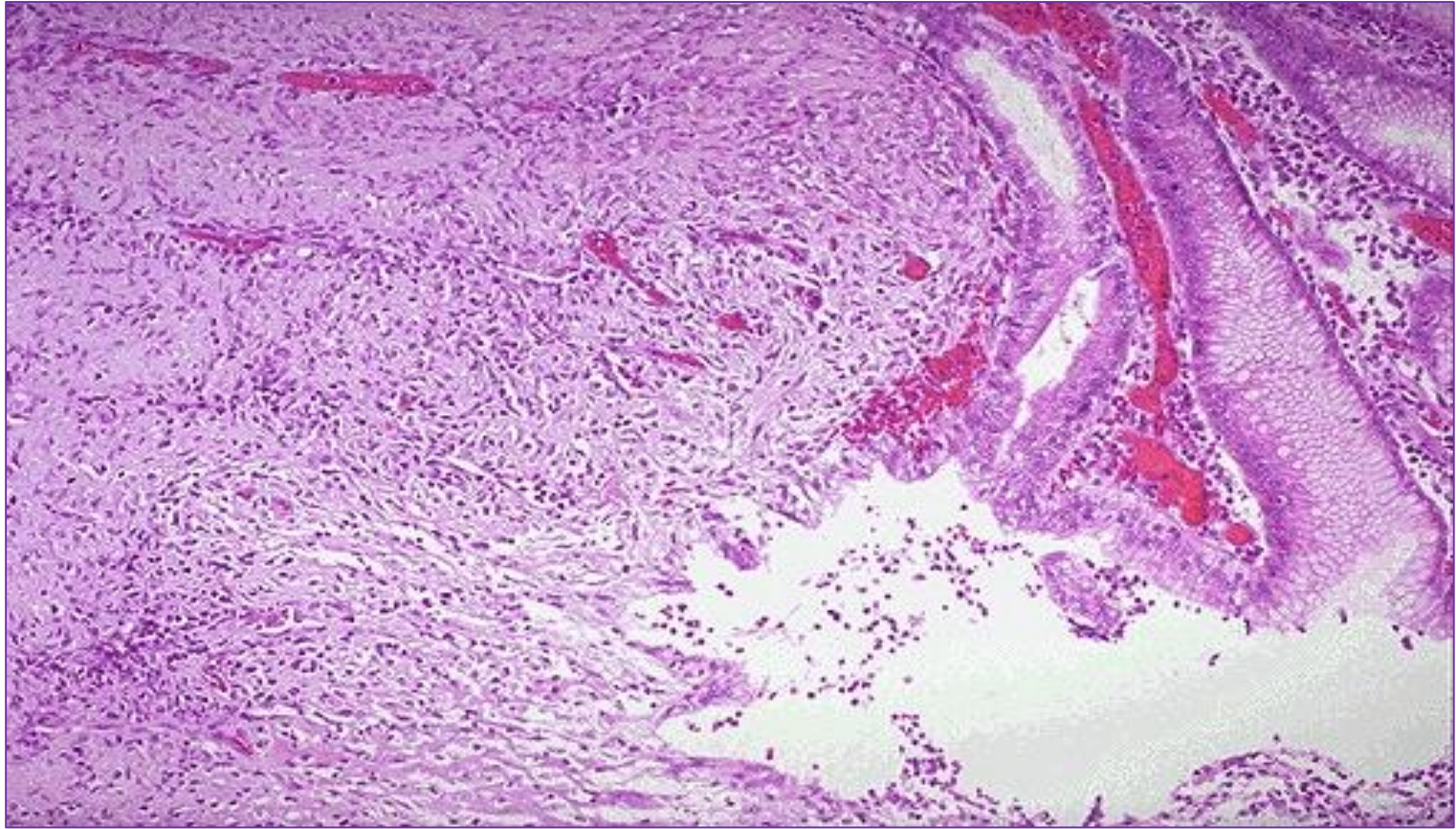
Here is a much larger 3 x 4 cm gastric ulcer that led to the resection of the stomach shown here. This ulcer is much deeper with more irregular margins. Complications of gastric ulcers (either benign or malignant) include pain, bleeding, perforation, and obstruction.

Acute Gastric Ulcer – LPF



Microscopically, the ulcer here is sharply demarcated, with normal gastric mucosa on the left falling away into a deep ulcer whose base contains inflamed, necrotic debris. An arterial branch at the ulcer base is eroded and bleeding.

Acute Gastric Ulcer – HPF

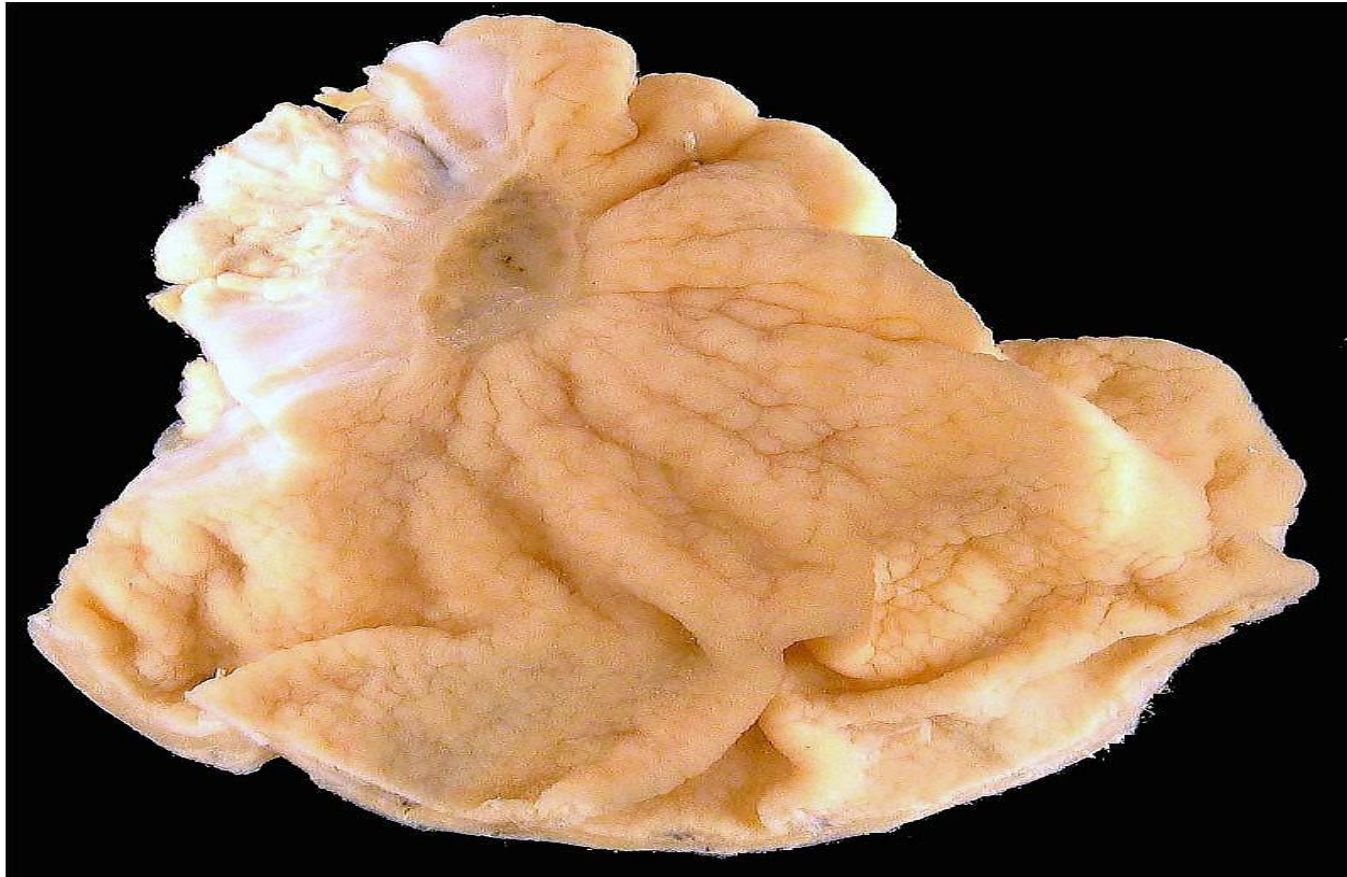

The mucosa at the upper right merges into the ulcer at the left which is eroding through the mucosa. Ulcers will penetrate over time if they do not heal. Penetration leads to pain. If the ulcer penetrates through the muscularis and through adventitia, then the ulcer is said to "perforate" and leads to an acute abdomen.



Chronic gastric ulcer

Chronic Gastric Ulcer - Gross



The specimen consists of an irregular portion of gastric wall. The ulcer is oval in shape and deeply penetrating. Necrotic debris covers the base. The specimen has been cut to show the submucosa, muscle coat and adventitial connective tissues in the region of the ulcer

Chronic Gastric Ulcer: Microscopic

Cellular Debris:

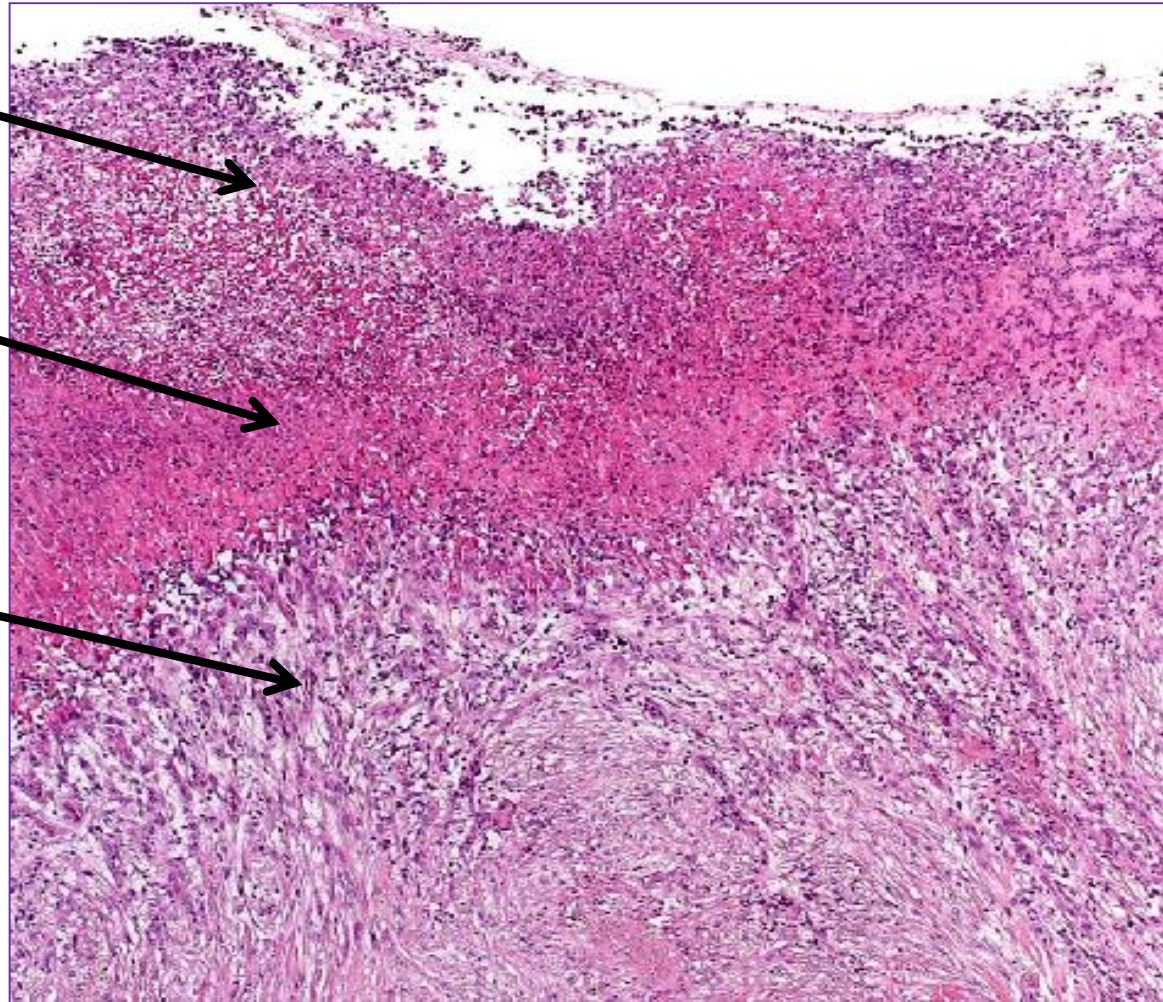
Numerous viable and degenerate polymorphs.

Fibrinoid Necrosis:

Inflammatory cells and granulation tissue.

Granulation Tissue:

Variable sized capillary channels are separated by fibroblastic connective tissue heavily infiltrated with lymphocytes, neutrophils, and eosinophils.

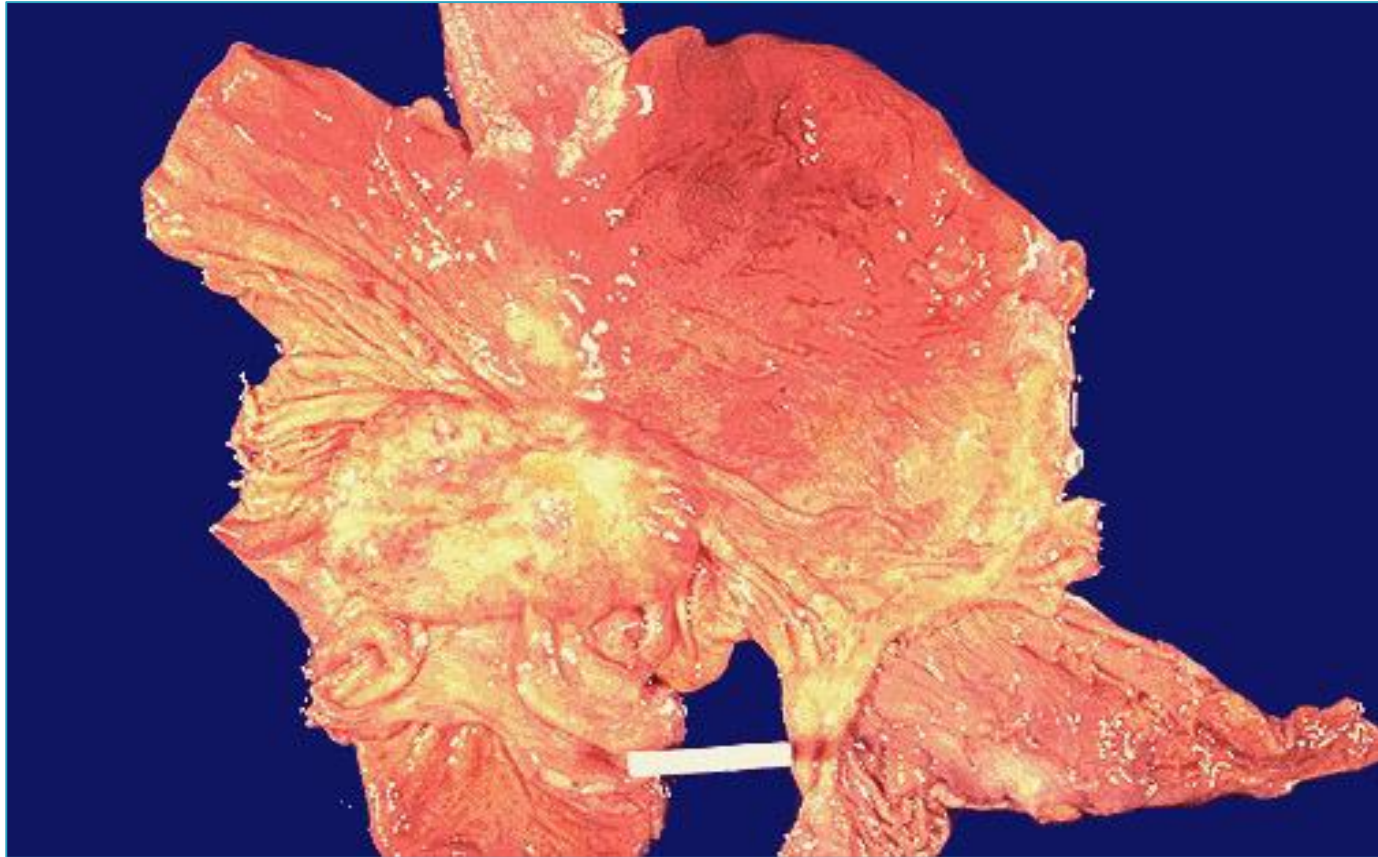


Microscopic examination shows the typical features of a chronic peptic ulcer. The ulcer is located in the antrum



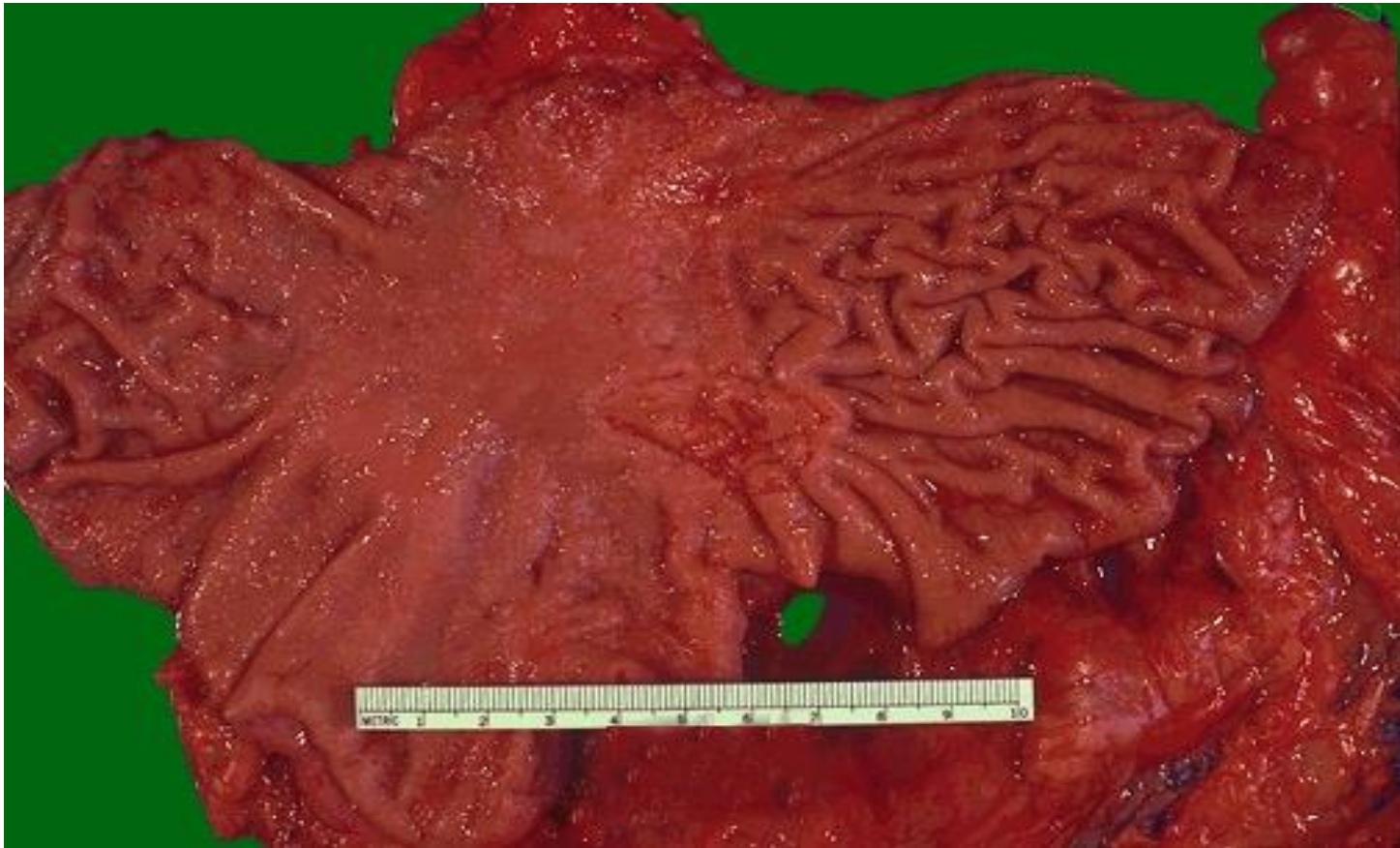CARCINOMA OF THE STOMACH

Gastric Adenocarcinoma - Gross



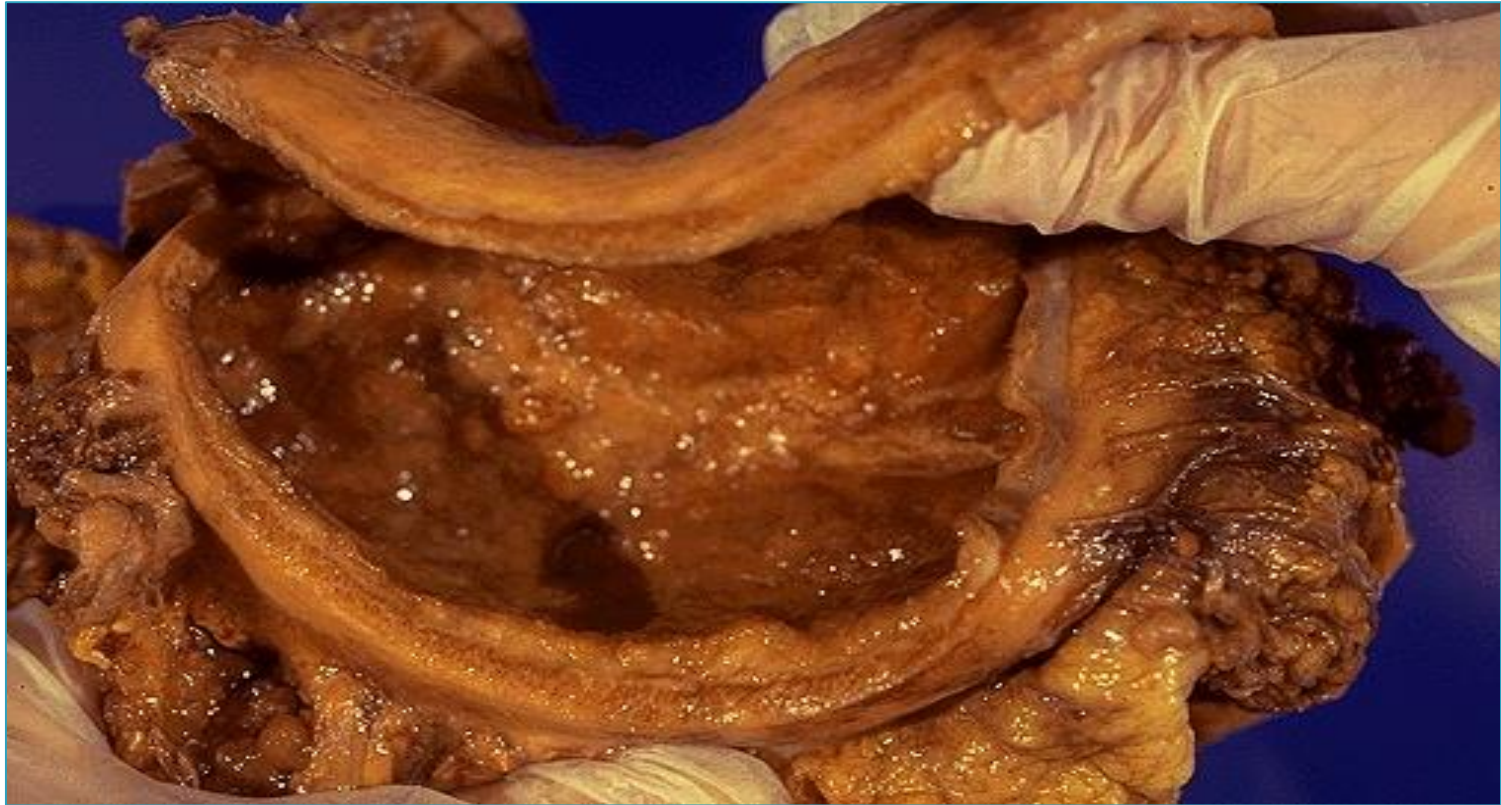Gastric Neoplasia is not uncommon. Here is a gastric adenocarcinoma. ALL gastric ulcers and ALL gastric masses must be biopsied, because it is not possible to tell from gross appearance alone which are benign and which are malignant

Gastric Adenocarcinoma with ulcer - Gross



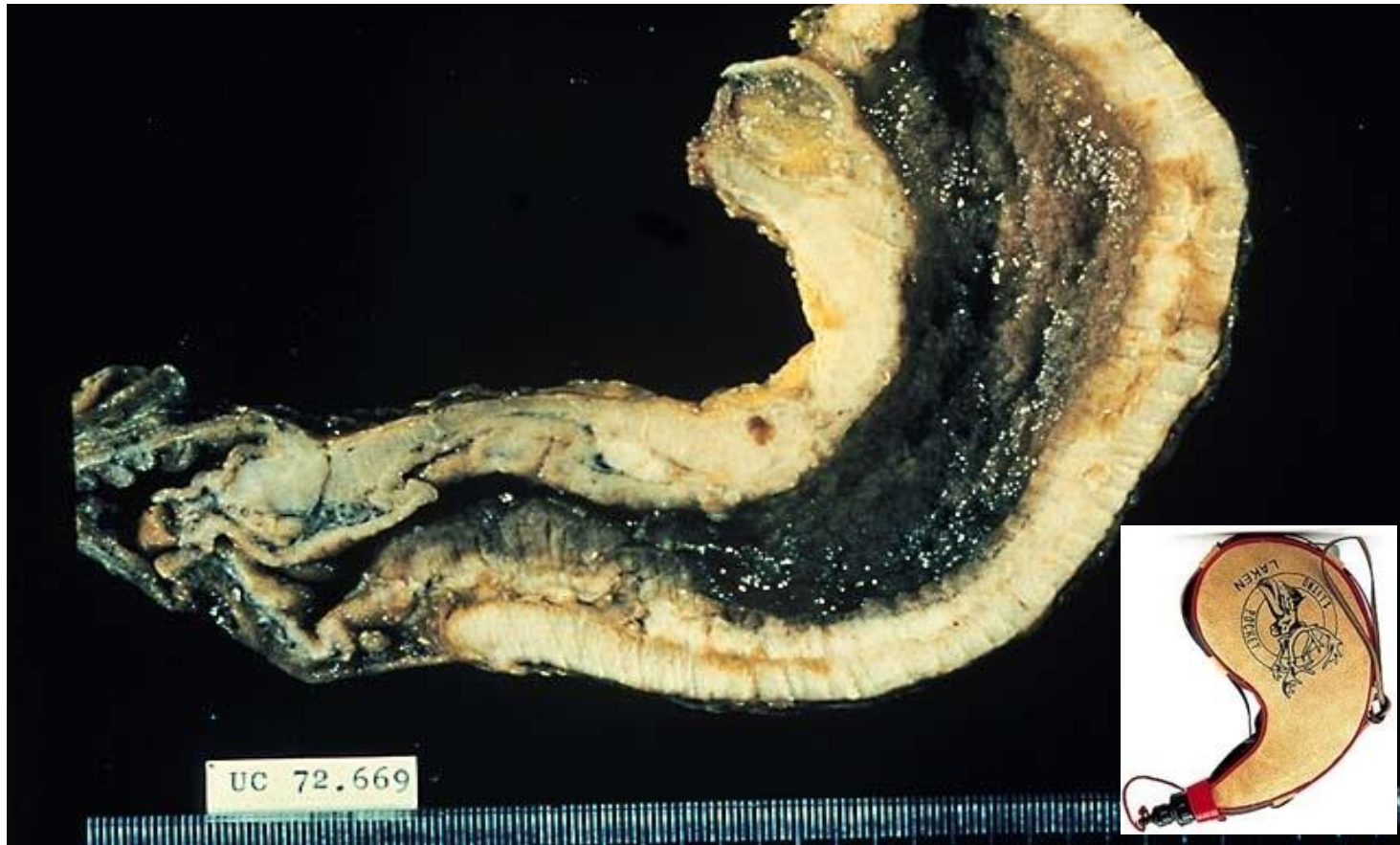Here is a gastric ulcer in the center of the picture. It is shallow and is about 2 to 4 cm in size. This ulcer on biopsy proved to be malignant, so the stomach was resected as shown here

Gastric Adenocarcinoma ; Linitis Plastica- Gross



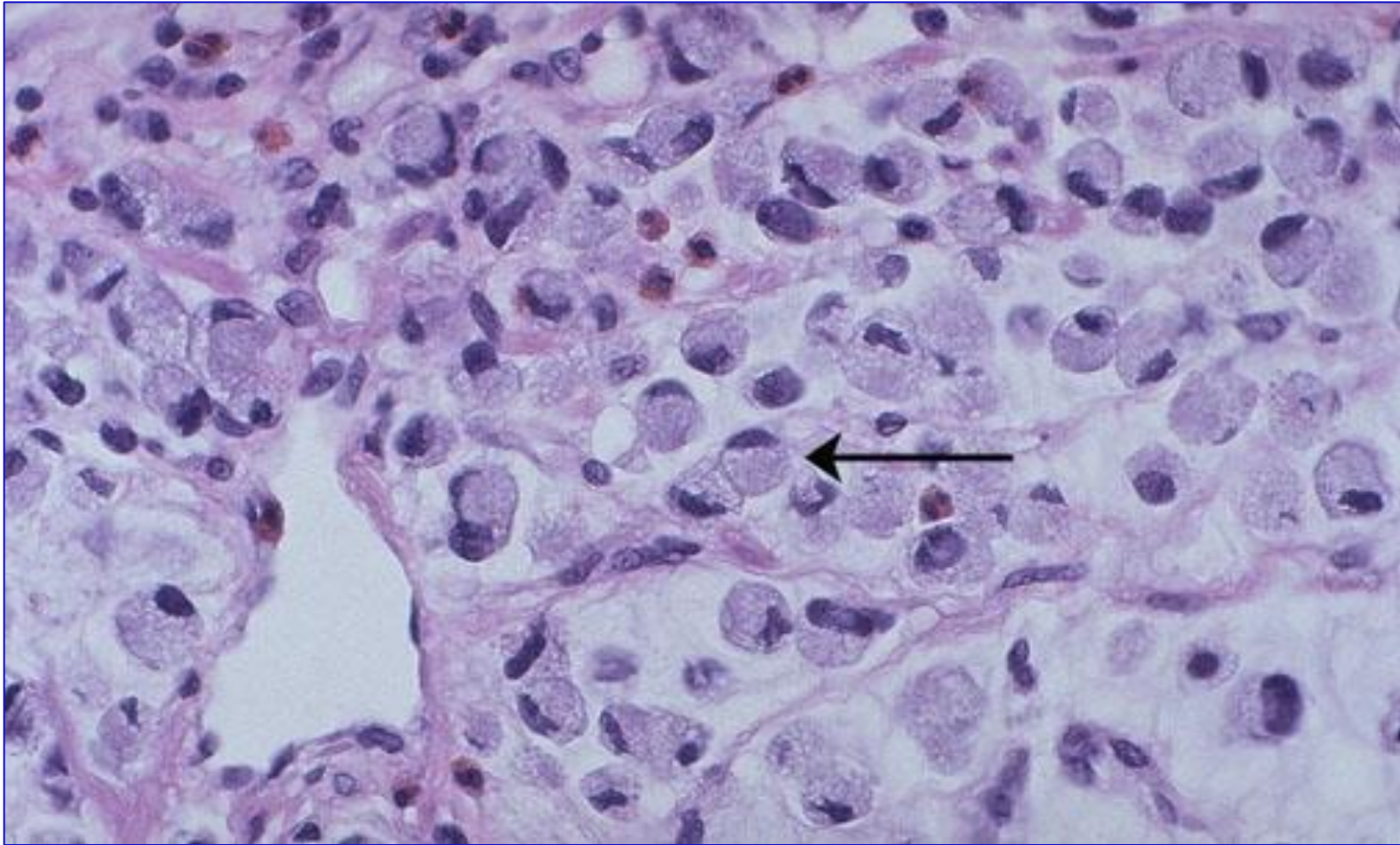
An example of Linitis Plastica, a diffuse infiltrative gastric adenocarcinoma which gives the stomach a shrunken "leather bottle" appearance with extensive mucosal erosion and a markedly thickened gastric wall. This type of carcinoma has a very poor prognosis

Gastric Adenocarcinoma; Lentis Plastica- Gross



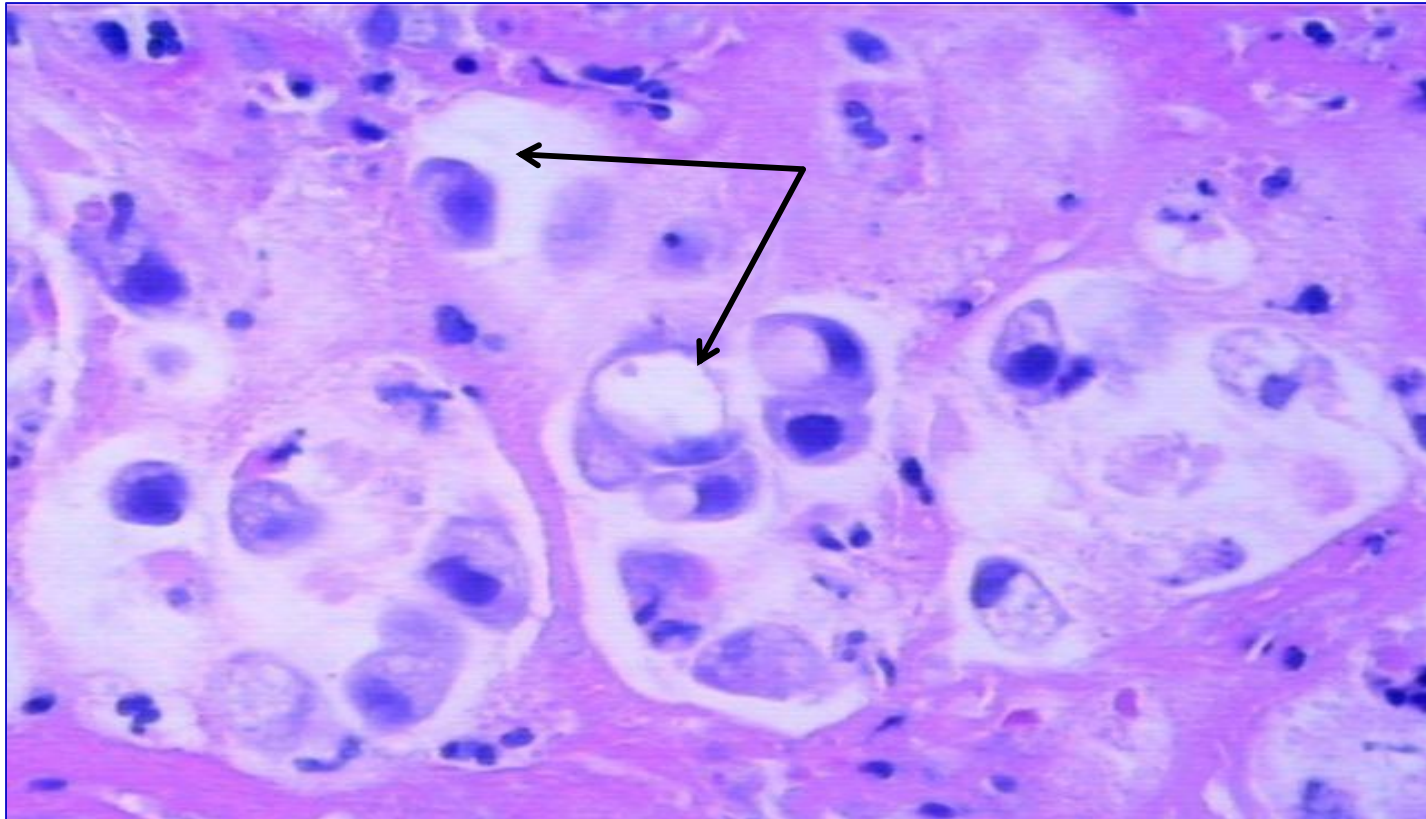
The LINITIS PLASTICA is the most spectacular, and most feared, of all gastric adenocarcinomas. It grows diffusely through all layers of the stomach, greatly thickening its wall, and giving the stomach a classic leather bottle appearance. It has a horrible prognosis.

Gastric Adenocarcinoma- Signet Ring Cell -HPF



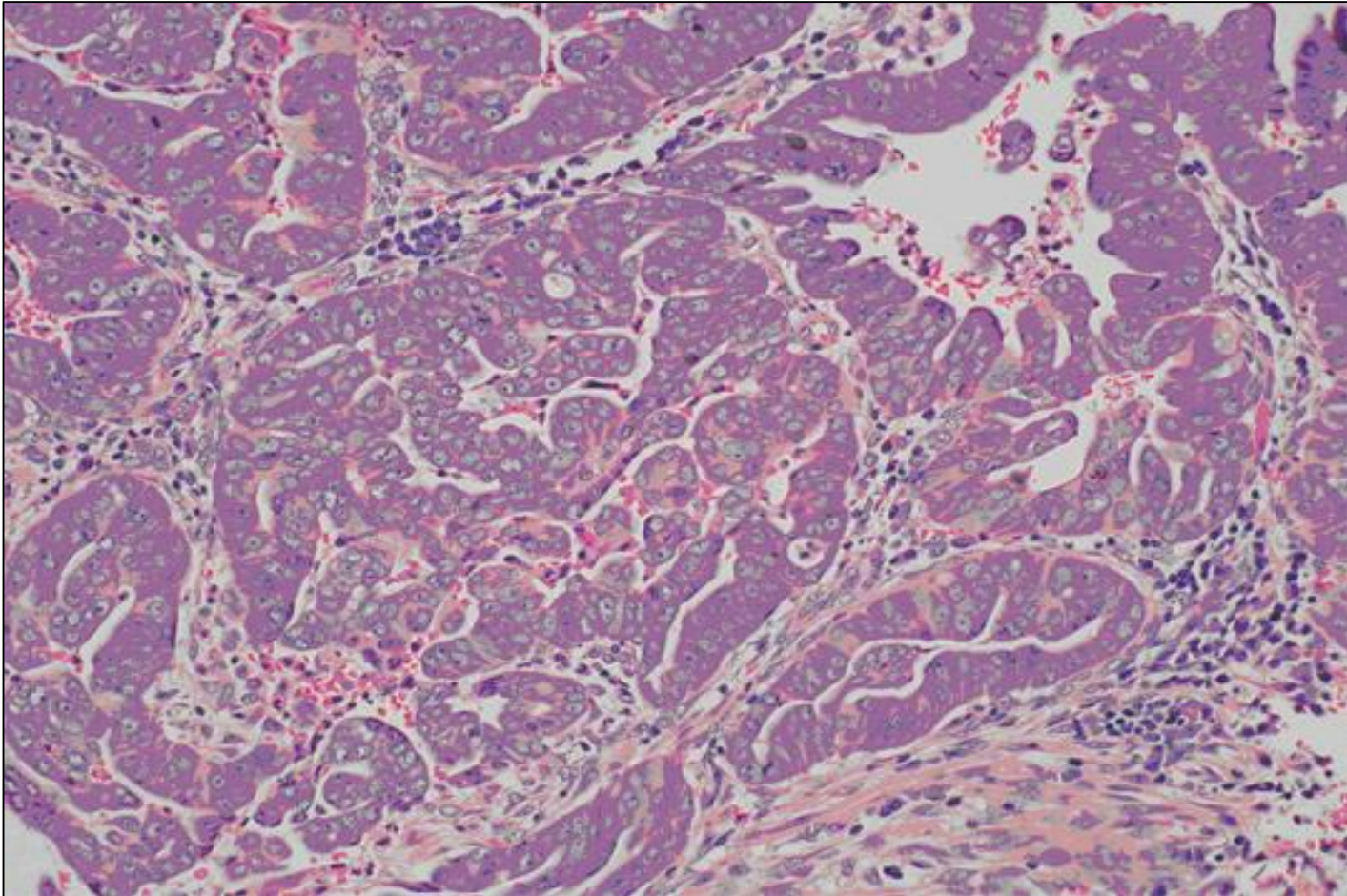
This is a signet ring cell pattern of adenocarcinoma in which the cells are filled with mucin vacuoles that push the nucleus to one side, as shown at the arrow.

Gastric Adenocarcinoma- Signet Ring Cell - HPF



Signet ring cells are poorly differentiated adenocarcinoma cells, and are often seen with Lentis Plastica. Those large "holes" in the cytoplasm represents intracellular mucin which push the nucleus to the periphery giving the cell signet ring appearance .

Gastric Adenocarcinoma- Intestinal type



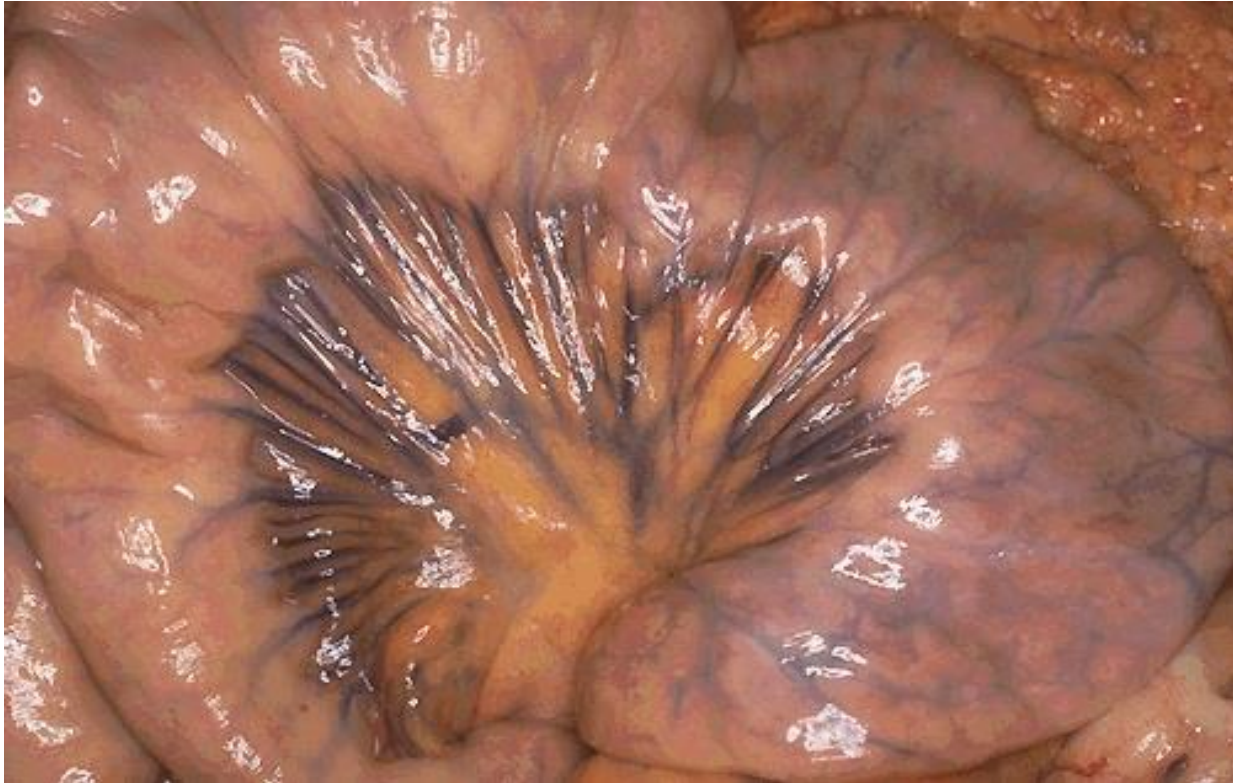
Photomicrograph of a poorly differentiated intestinal type adenocarcinoma of the stomach



SMALL INTESTINE

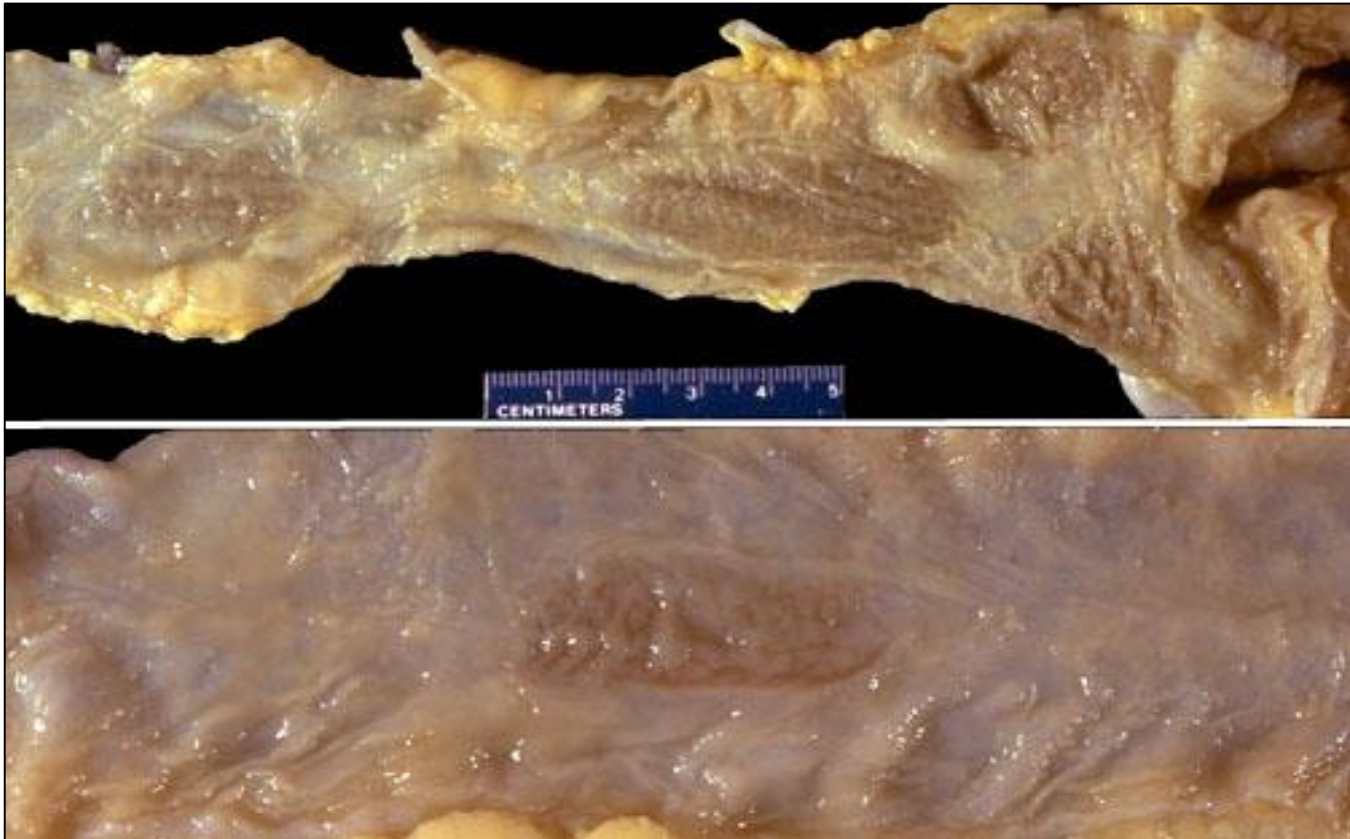
***Normal Anatomy and
Histology***

Small Intestine – Normal Anatomy



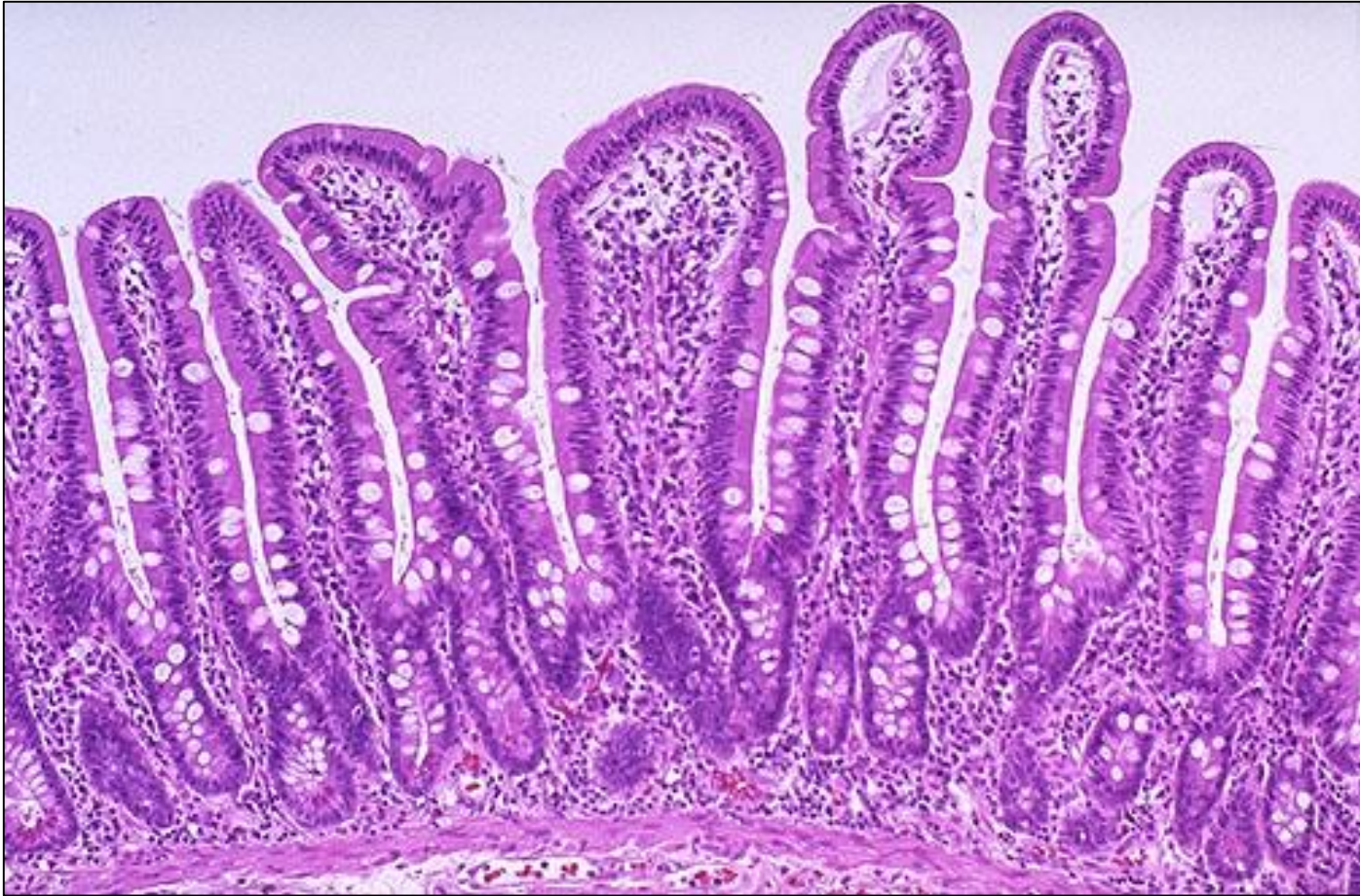A loop of bowel attached via the mesentery. Note the extent of the veins. Arteries run in the same location. Thus, there is an extensive anastomosing arterial blood supply to the bowel, making it more difficult to infarct. Also, the extensive venous drainage is incorporated into the portal venous system heading to the liver

Terminal ileum – Normal endoscopic view



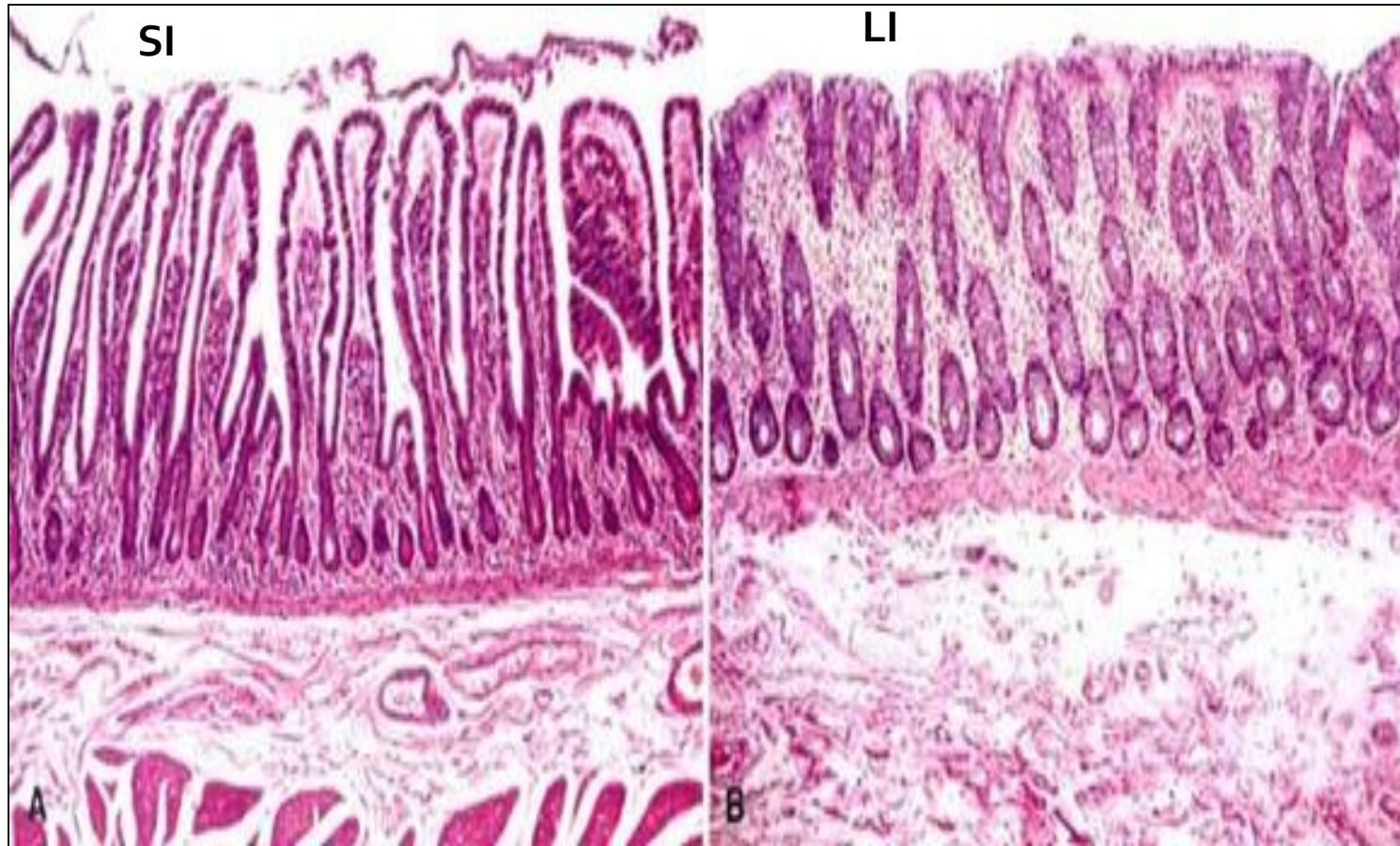
This is the normal appearance of terminal ileum. In the upper frame, note the ileocecal valve, and several darker oval Peyer's patches are present on the mucosa. In the lower frame, a Peyer's patch, which is a concentration of submucosal lymphoid tissue, is present. Note the folds are not as prominent here as in the jejunum, as evidenced by the colonoscopic view below

Intestinal Mucosa– Normal Histology



This is the normal appearance of small intestinal mucosa with long villi that have occasional goblet cells. The villi provide a large area for digestion and absorption.

Small Intestine (SI) vs Large Intestine (LI)

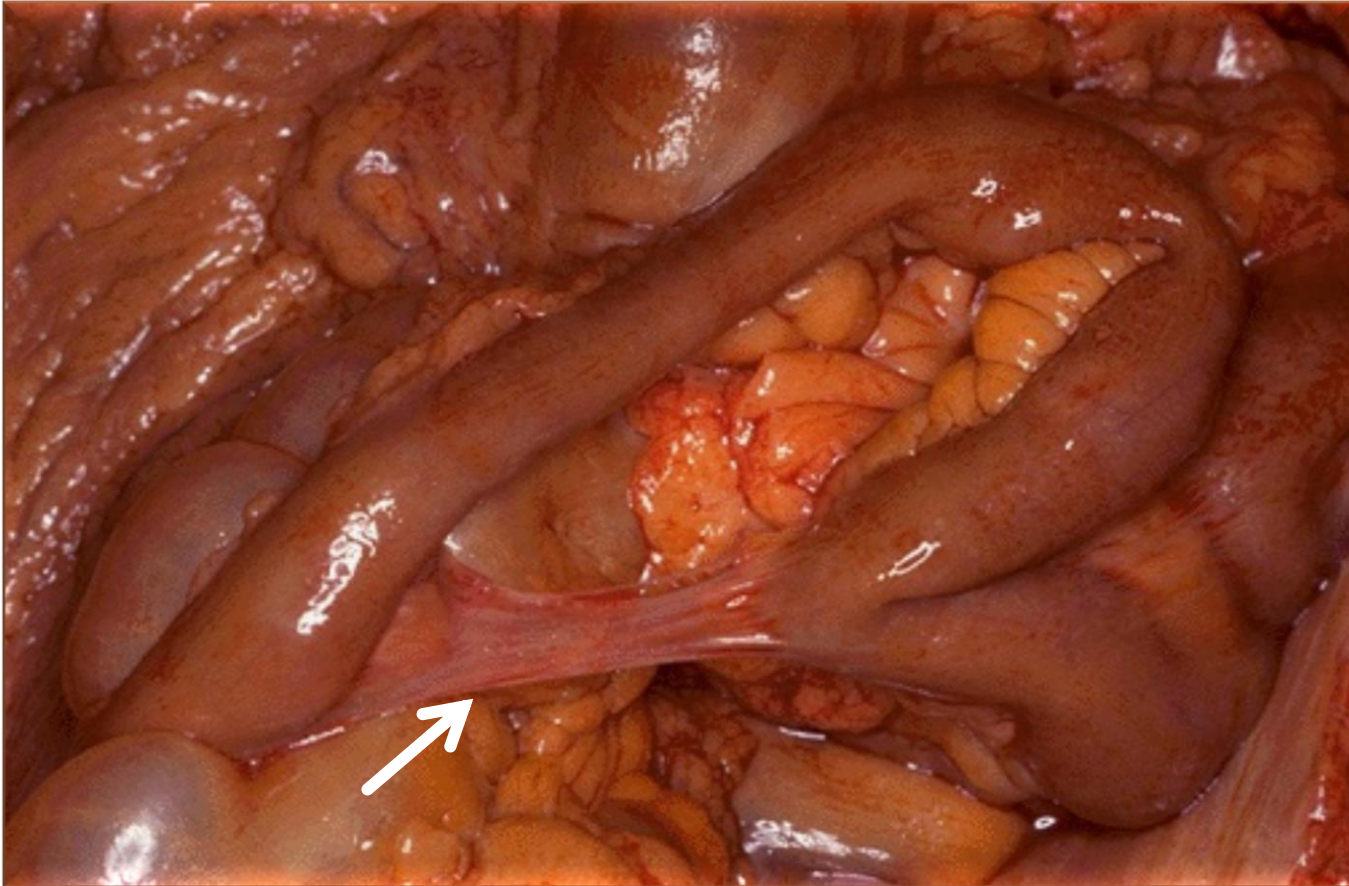


SI has a "villous" or "papillary", i.e., hairy surface appearance, while the LI has a configuration similar to the stomach, i.e., "pits and glands"



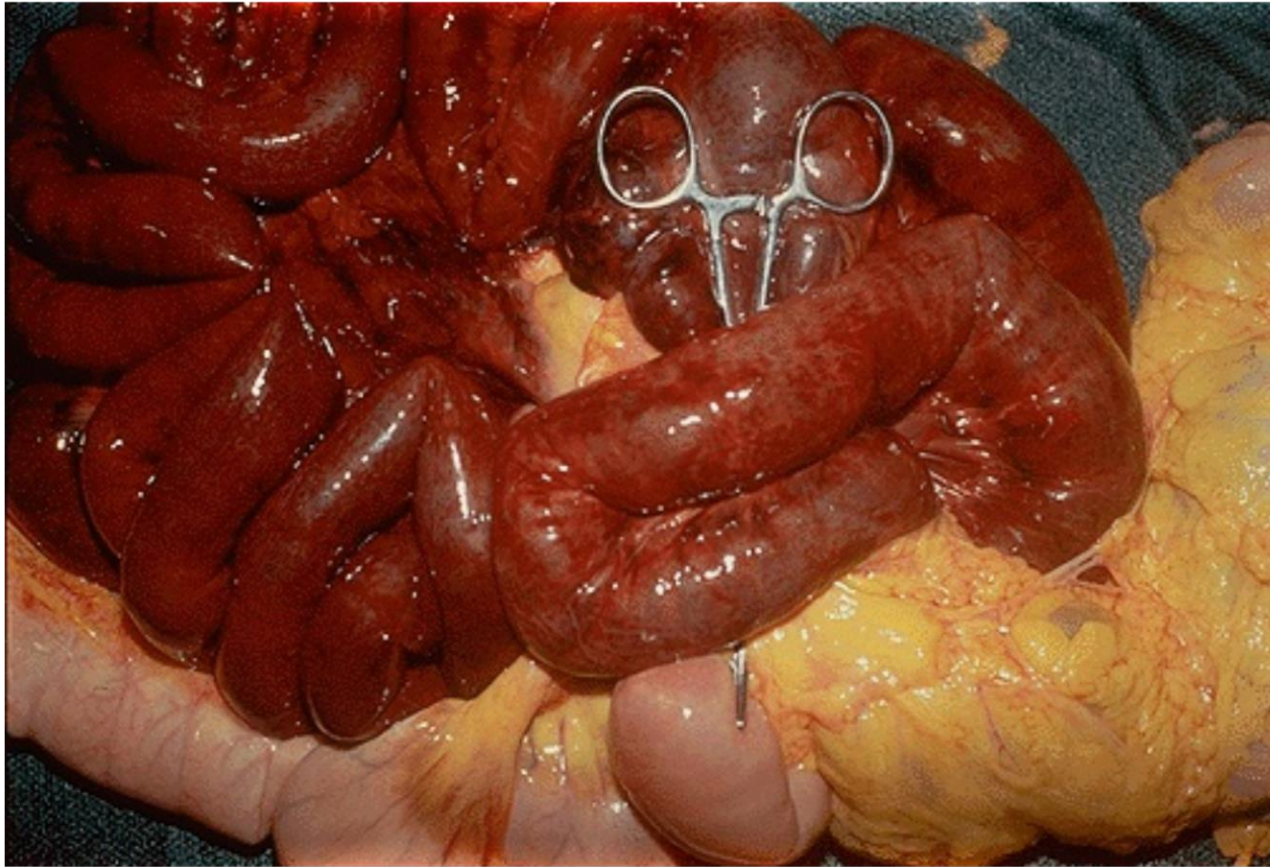
Gross and histopathology

Adhesions, peritoneum, small intestine - Gross



This is an adhesion between loops of small intestine. Such adhesions are typical following abdominal surgery. More diffuse adhesions may also form following peritonitis.

Small intestinal infarction - Gross



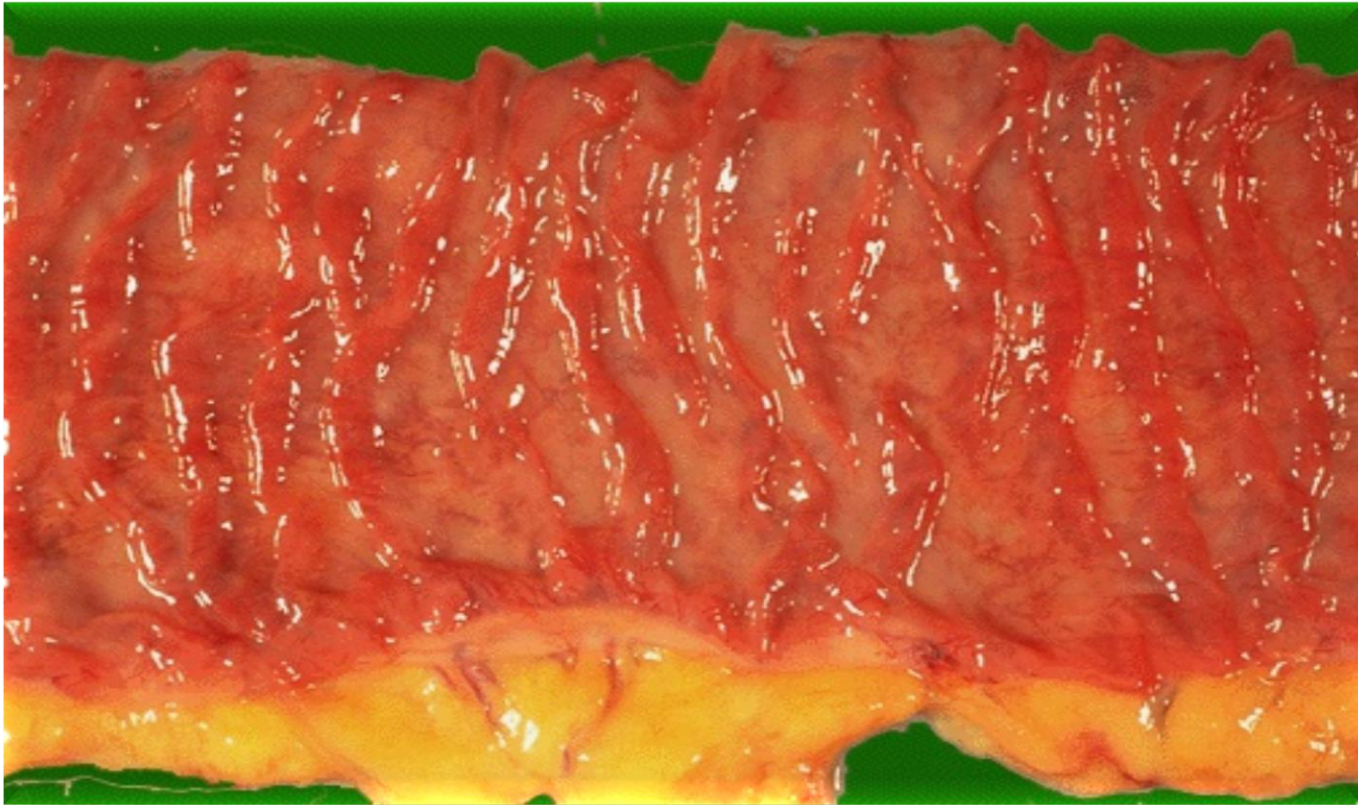The dark red infarcted small intestine contrasts with the light pink viable bowel. The forceps extend through an internal hernia in which a loop of bowel and mesentery has been caught. This is one complication of adhesions from previous surgery. The trapped bowel has lost its blood supply.

Ischemic Enteritis - Gross



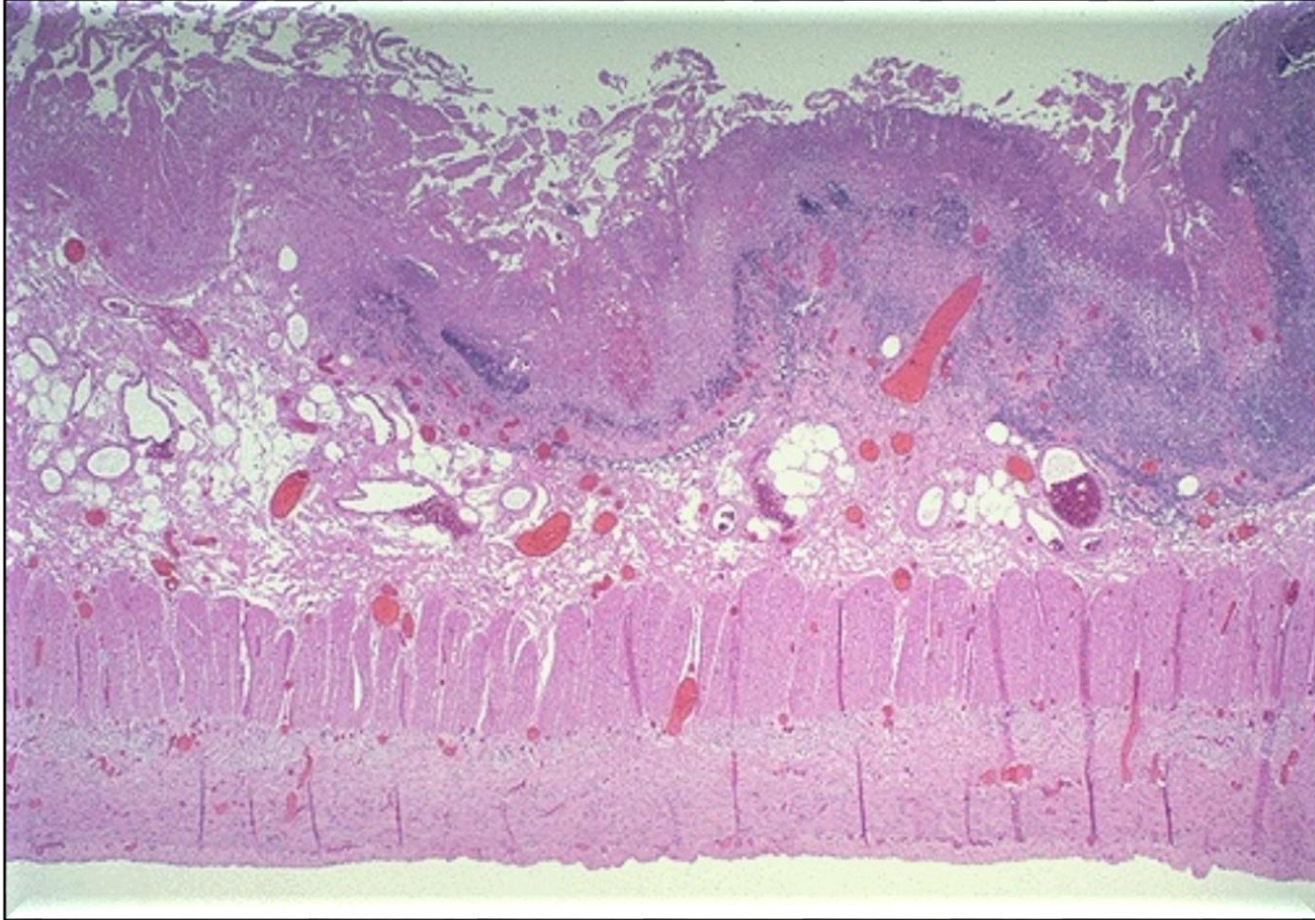The small intestinal mucosa demonstrates marked hyperemia as a result of ischemic enteritis. Such ischemia most often results from hypotension (shock) from cardiac failure, from marked blood loss, or from loss of blood supply from mechanical obstruction (as with the bowel strangulated in a hernia or with volvulus or intussusception). If the blood supply is not quickly restored, the bowel will infarct.

Ischemic Enteritis – Gross [ENDOSCOPY]



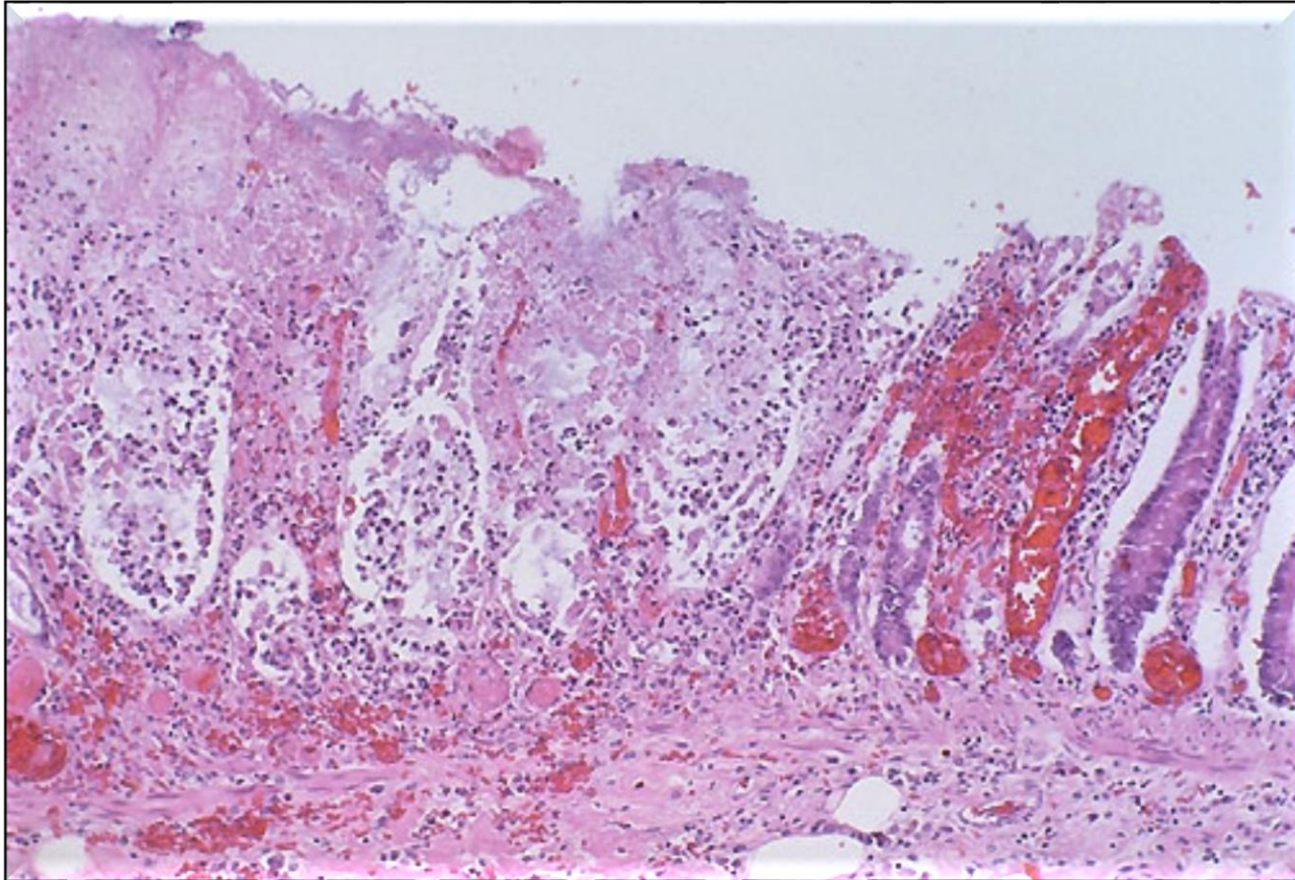
On closer inspection, early ischemic enteritis involves the tips of the villi. In general, bowel is hard to infarct from atherosclerotic vascular narrowing or thromboembolization because of the widely anastomosing blood supply. Thus, most cases of bowel ischemia and infarction result from generalized hypotension and decreased cardiac output.

Ischemic Enteritis – LPF




The mucosal surface of the bowel seen here shows early necrosis with hyperemia extending all the way from mucosa to submucosal and muscular wall vessels. The submucosa and muscularis, however, are still intact.

Ischemic Enteritis – MPF



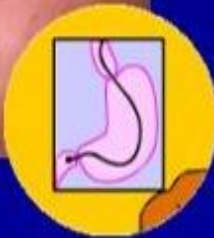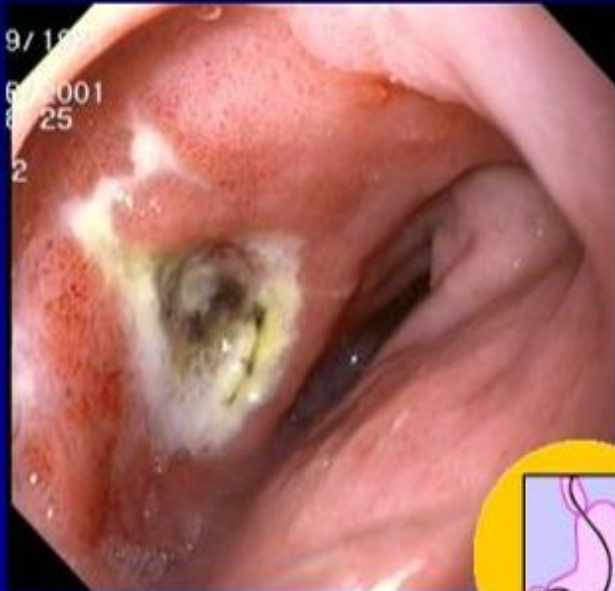At higher magnification with more advanced necrosis, the small intestinal mucosa shows hemorrhage with acute inflammation in this case of ischemic enteritis.



Chronic duodenal ulcer

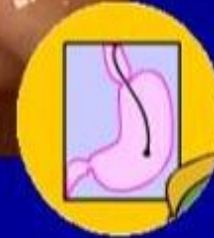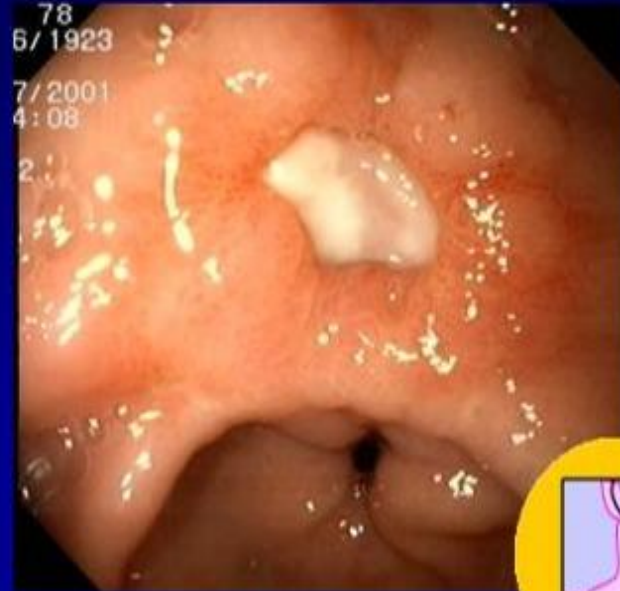Chronic Duodenal Ulcer vs Gastric ulcer – Gross

Duodenal Ulcer (DU)



The white base of the ulcer is marked by a blackish area signaling a recently bleeding vessel

Gastric Ulcer (GU)

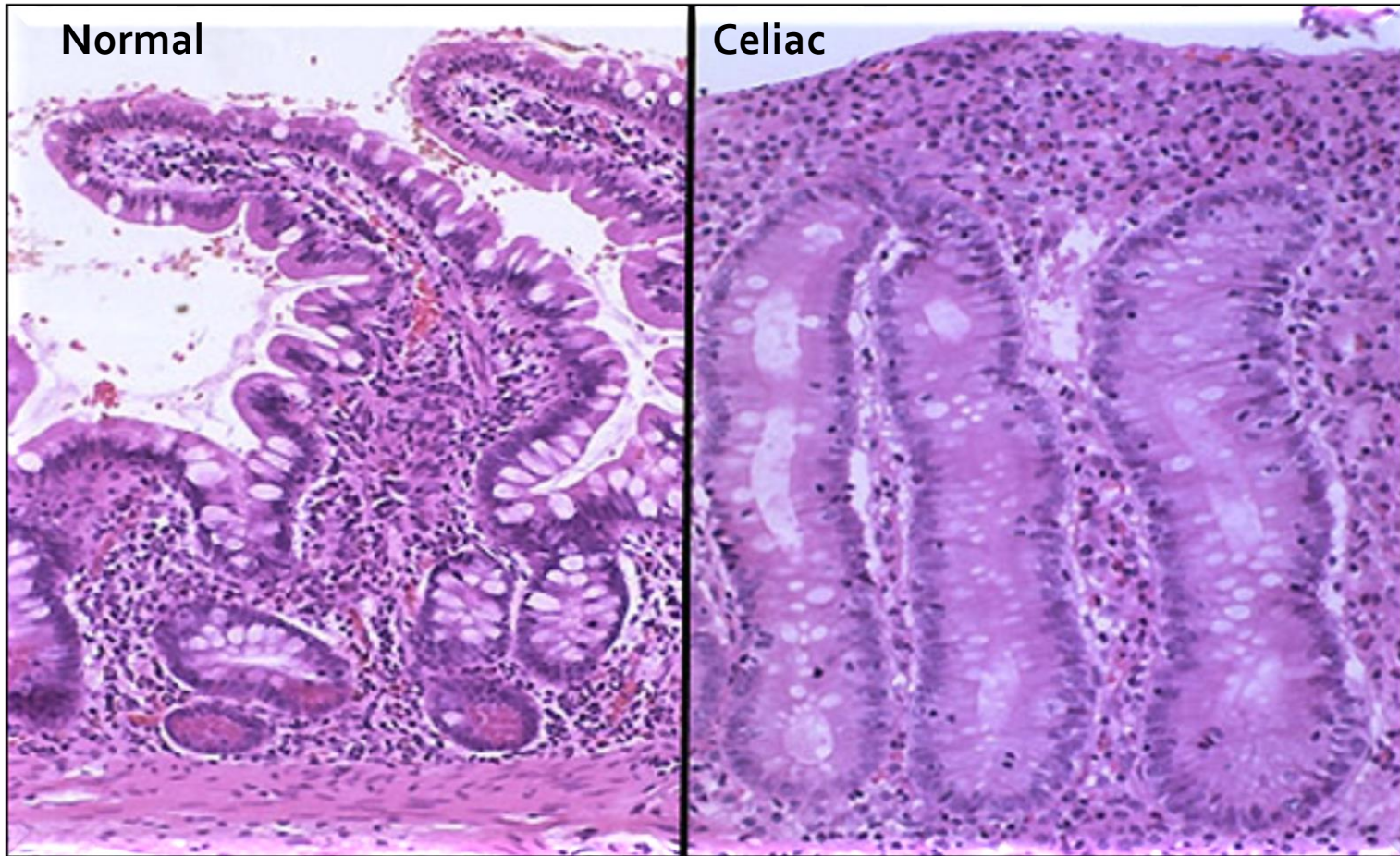


The ulcer has a clean white base and some swelling around its edges



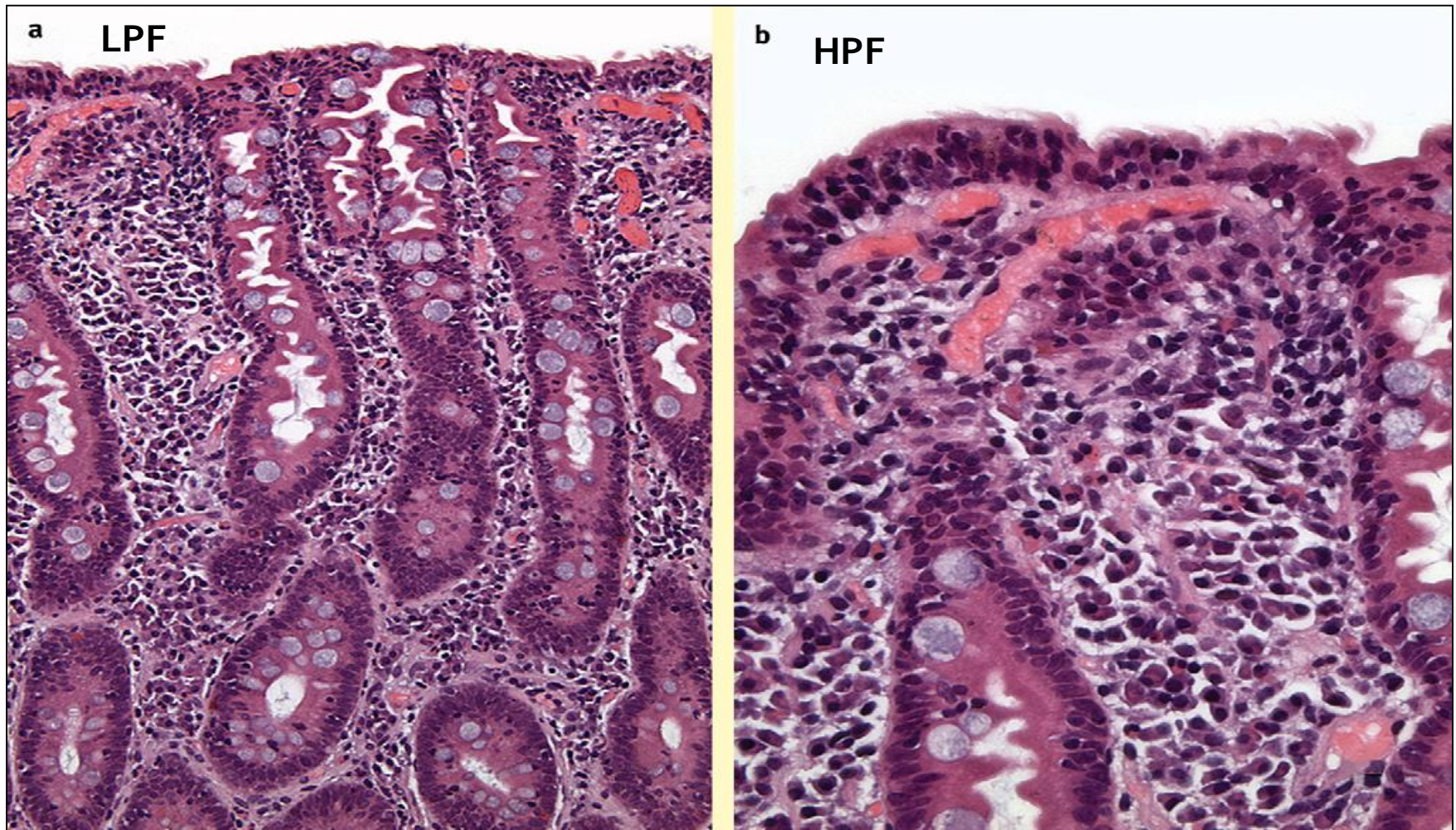
Celiac disease

Normal vs Celiac Disease (Sprue) – LPF



Normal small intestinal mucosa is seen at the left. The mucosa involved by celiac disease (sprue) at the right has blunting and flattening of villi. Celiac disease most often becomes apparent either in infancy, or in young to middle age adults.

Celiac Disease (Sprue) – LPF & HPF



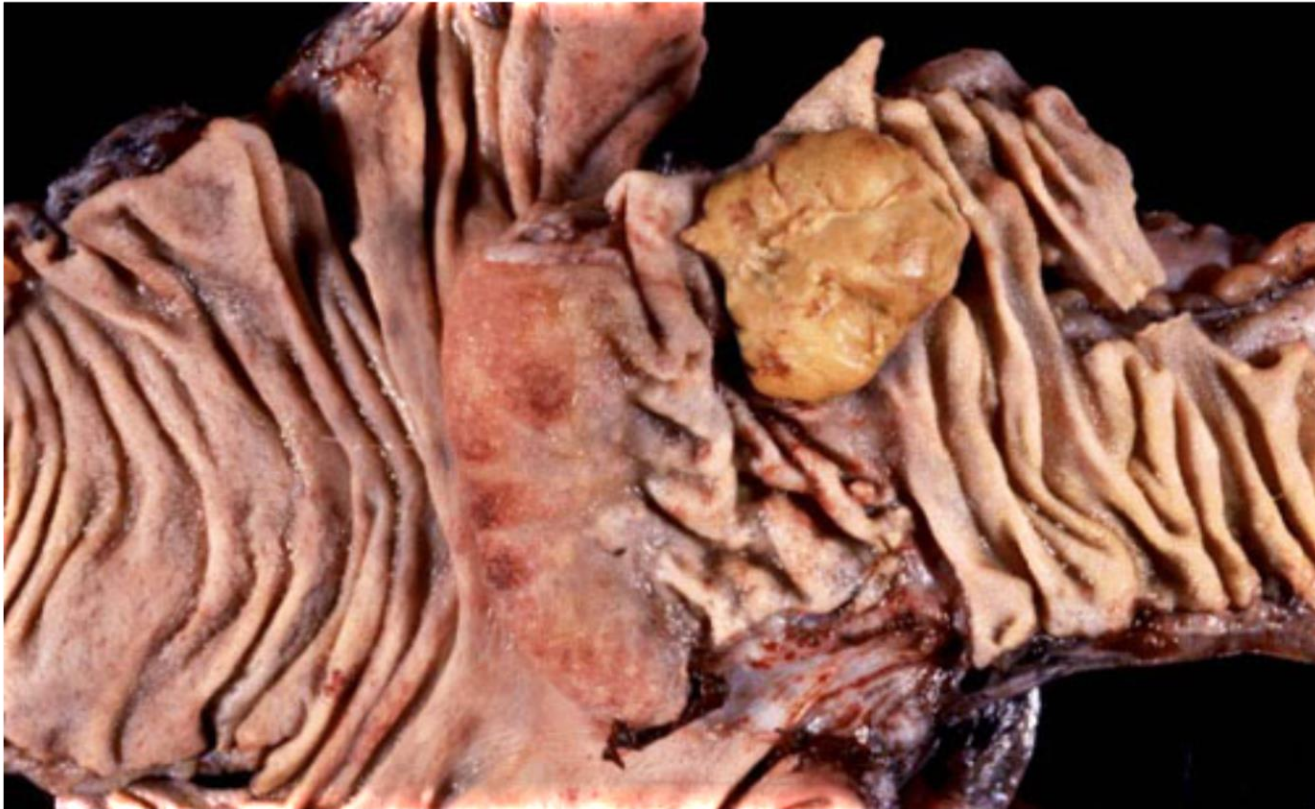
Low-power view of fully developed sprue-type changes. Note the elongated crypts with complete lack of villi.

High-power view showing damaged surface epithelium with large numbers of intraepithelial lymphocytes.



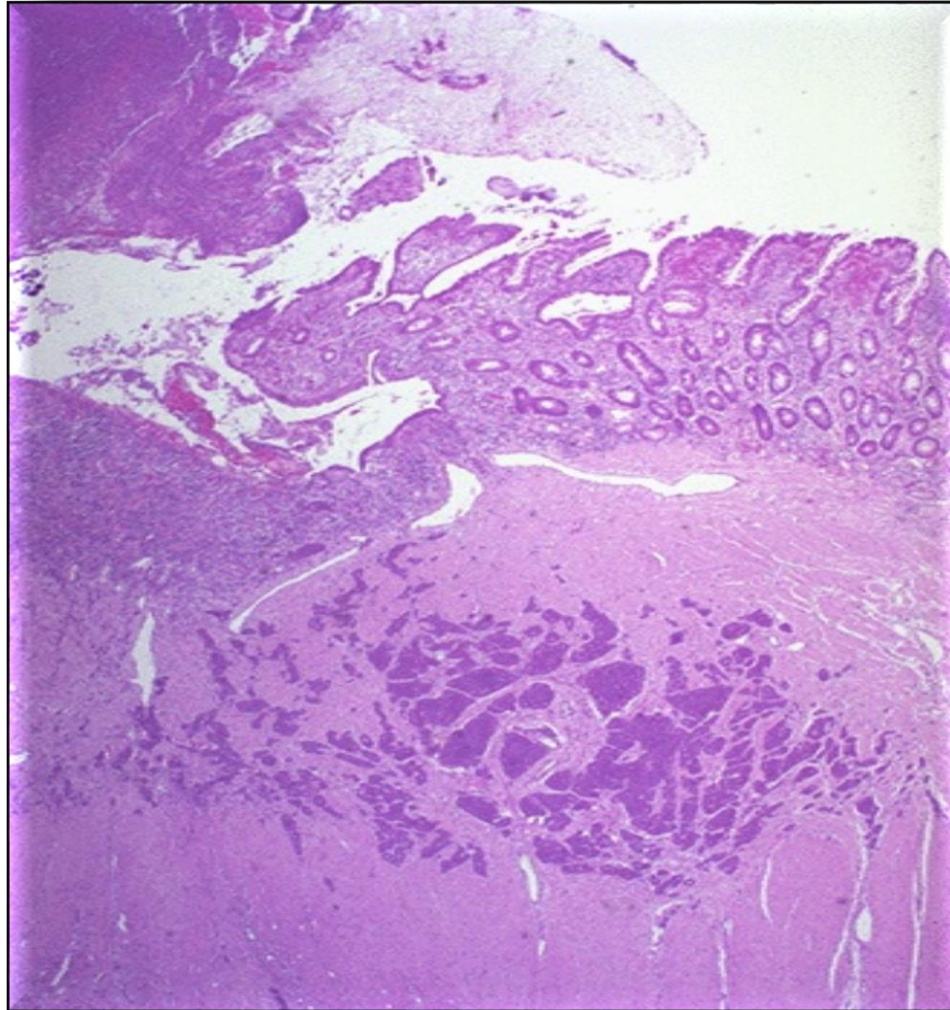
Carcinoid tumor of Small Intestine

Carcinoid tumor of small intestine - Gross



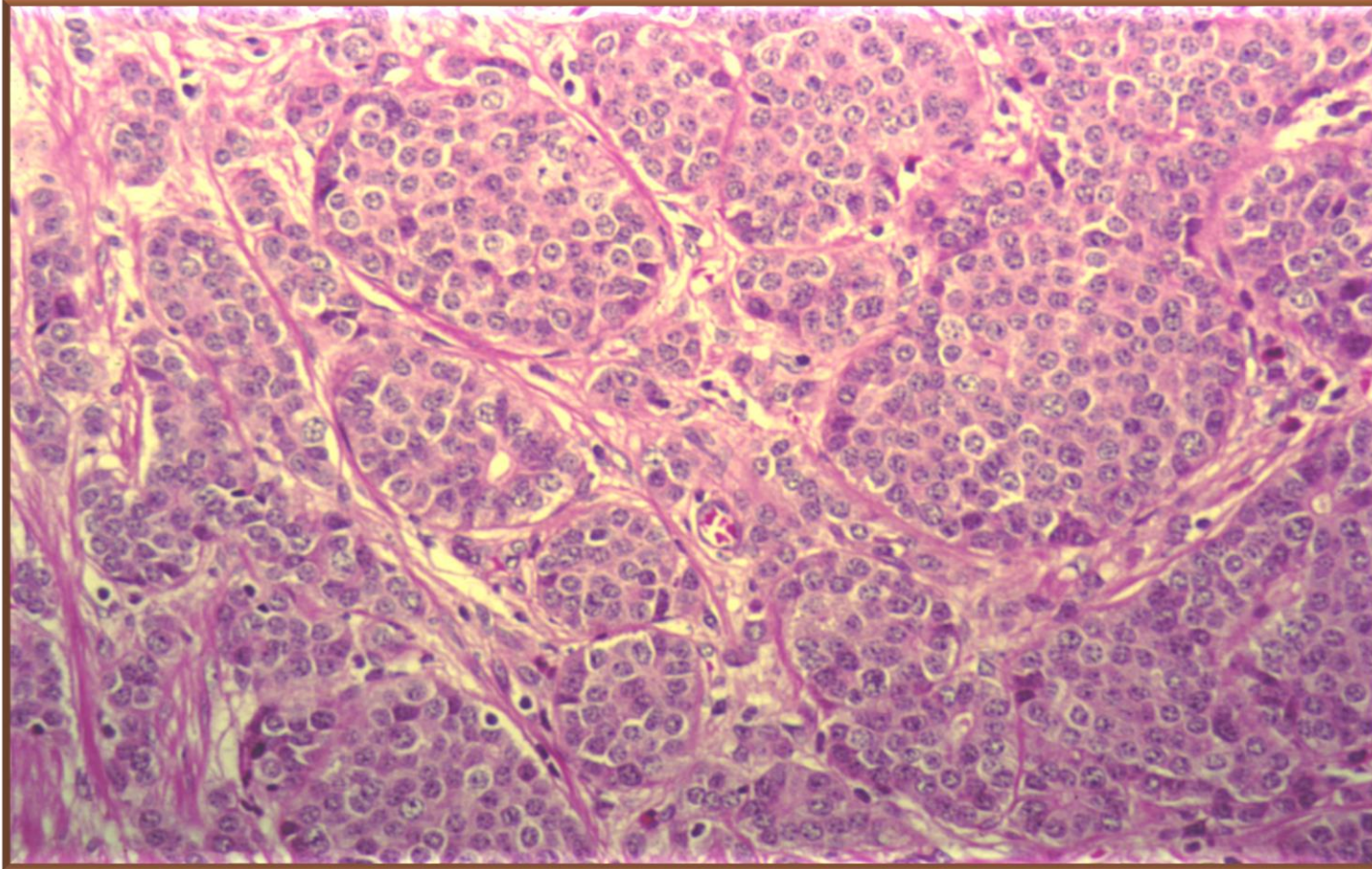
Neoplasms of the small intestine are uncommon. Benign tumors can include leiomyomas, fibromas, neurofibromas, and lipomas. Seen here at the ileocecal valve is another tumor that has a faint yellowish color. This is a carcinoid tumor. Most benign tumors are incidental submucosal lesions, though rarely they can be large enough to obstruct the lumen.

Carcinoid tumor of small intestine - LPF



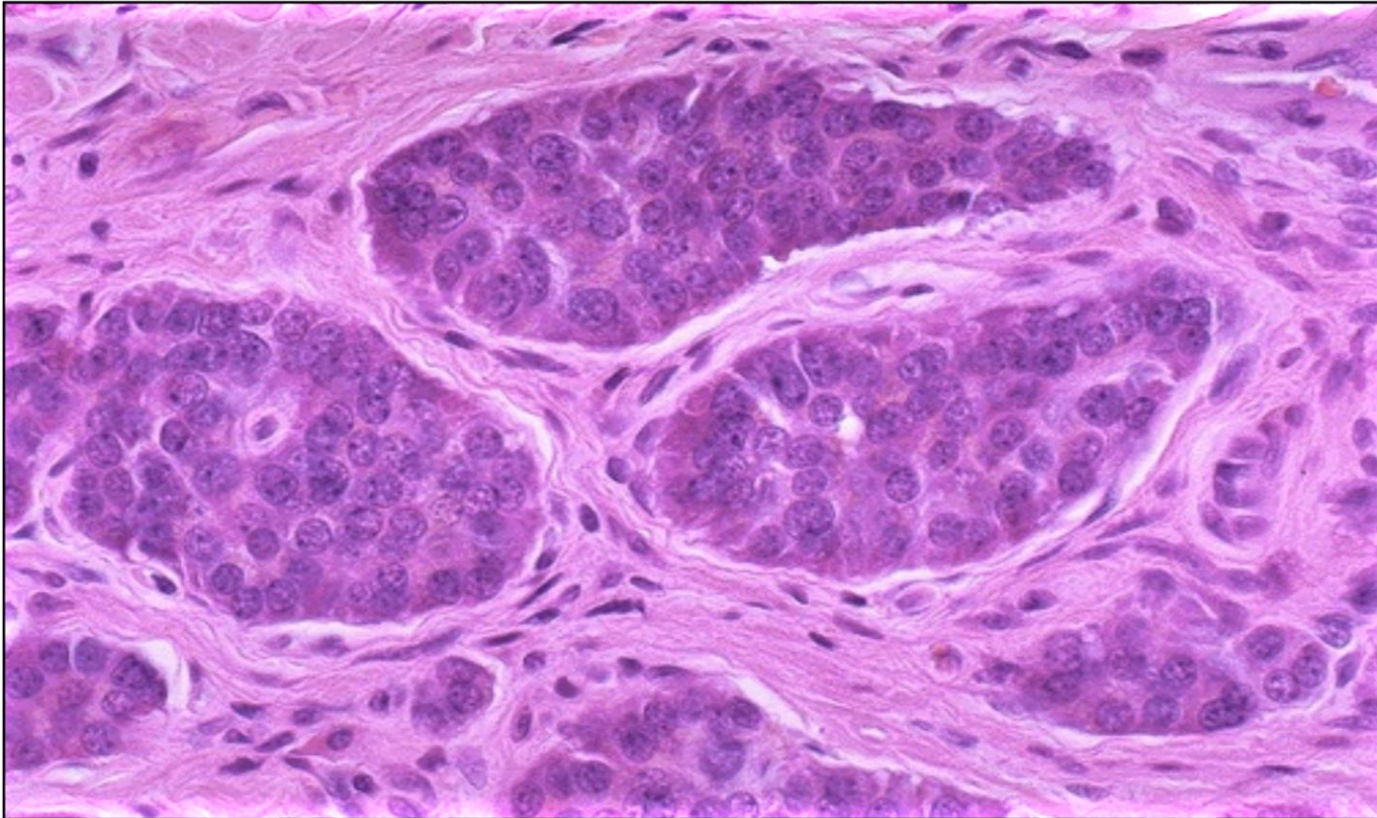
The carcinoid tumor is seen here to be a discreet, though not encapsulated, mass of multiple nests of small blue cells in the submucosa.

Carcinoid tumor of small intestine - MPF



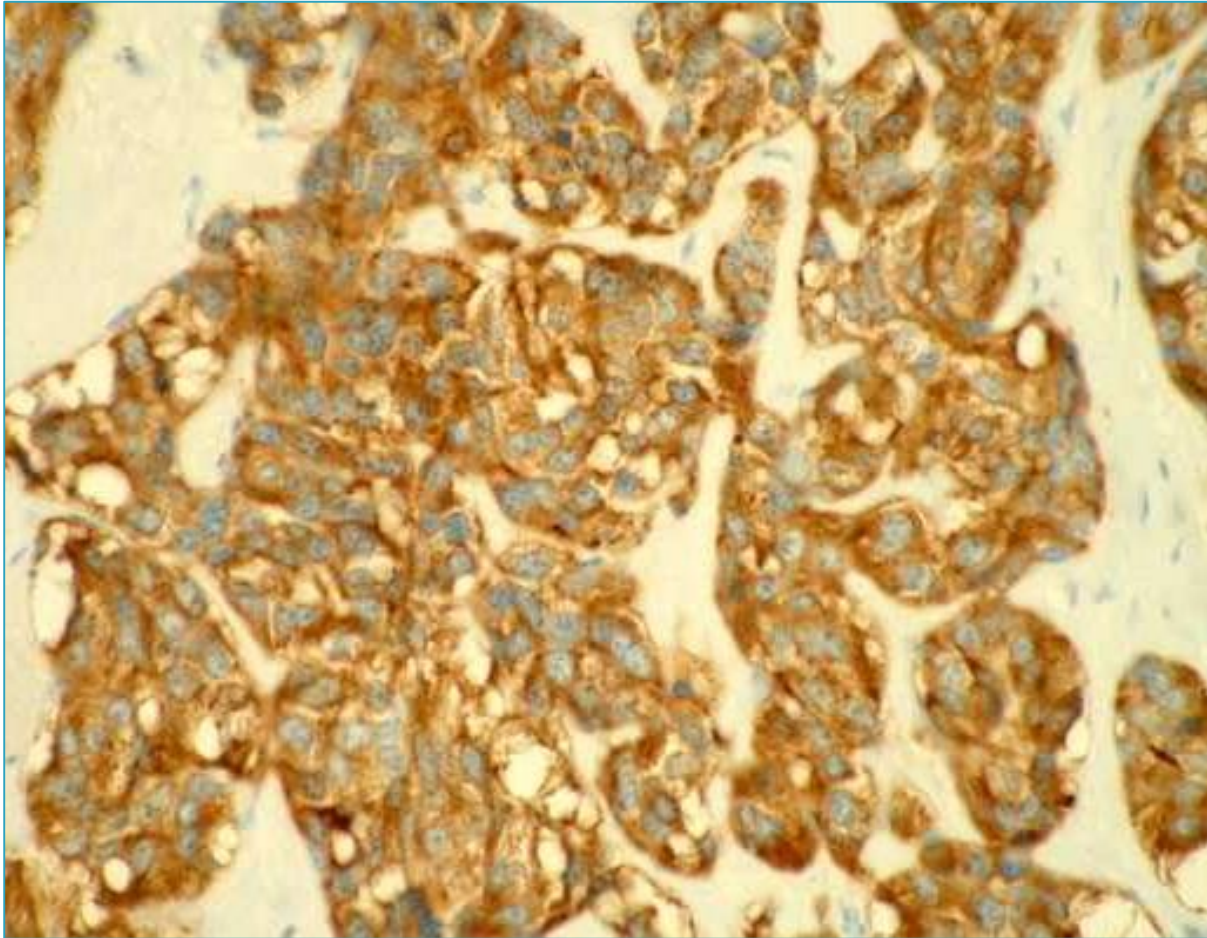
Tumour consists of alveolar groups and clumps of small uniform polygonal cells having centrally placed round nuclei and abundant granular cytoplasm.

Carcinoid tumor of small intestine - HPF



At high magnification, the nests of carcinoid tumor have a typical endocrine appearance with small round cells having small round nuclei and pink to pale blue cytoplasm. Rarely, a malignant carcinoid tumor can occur as a large bulky mass. Metastatic carcinoid to the liver can rarely result in the carcinoid syndrome.

Carcinoid tumor of small intestine – IHC stain

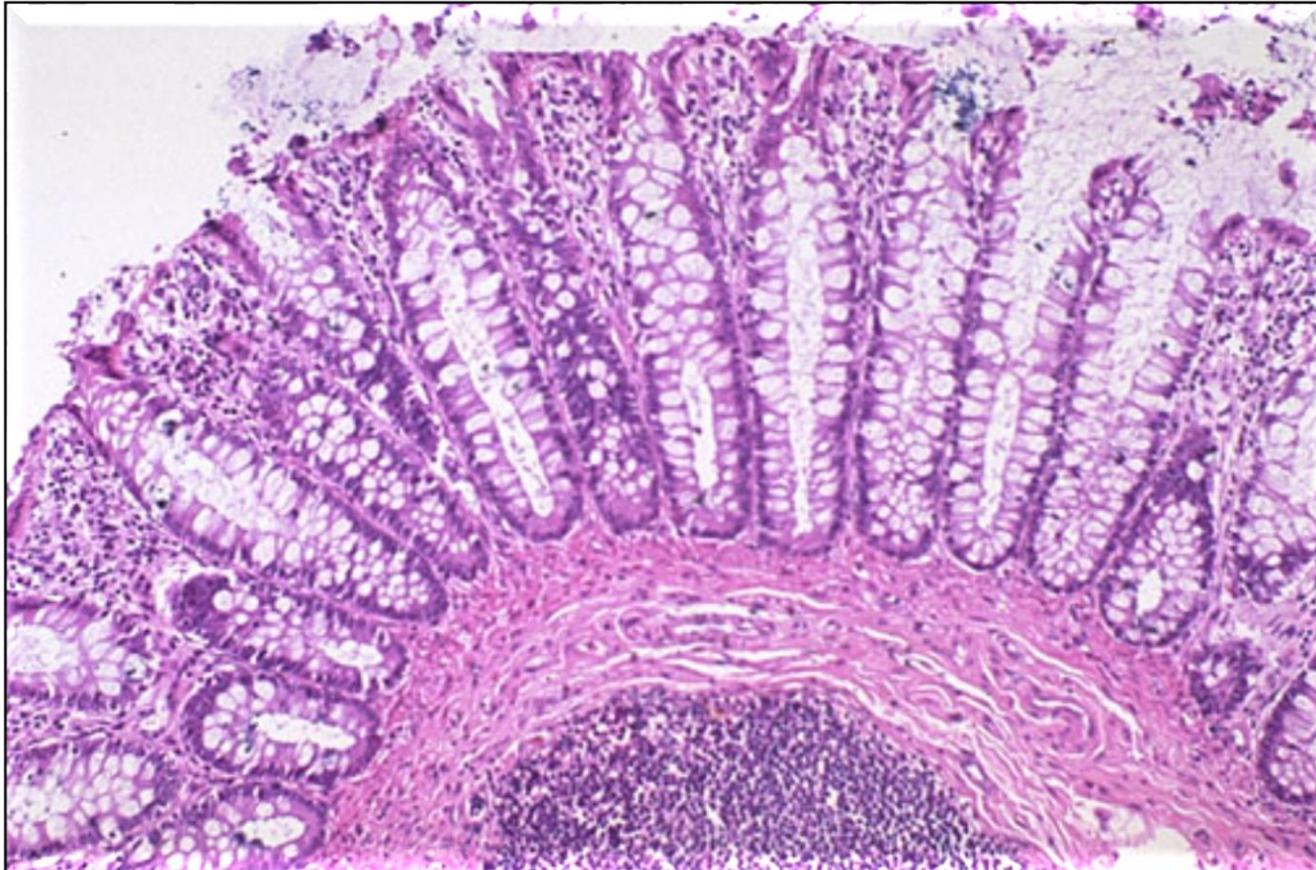


Carcinoid tumor showing strong positive staining with the synaptophysin immunohistochemical stain (IHC stain). This finding confirms the neuroendocrine nature of this neoplasm.



LARGE INTESTINE

Normal mucosa of large intestine

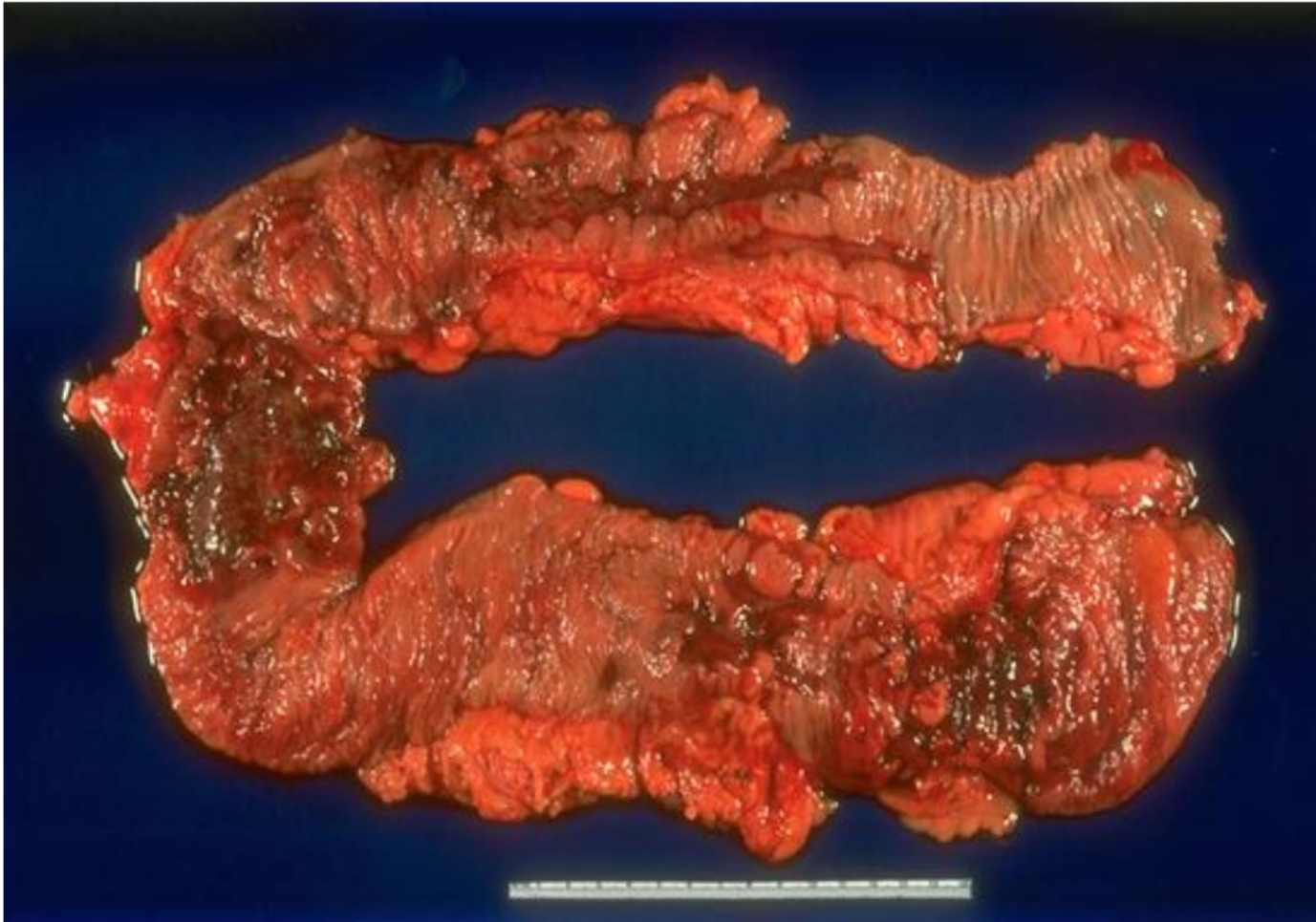

This is normal colonic mucosa. Note the crypts that are lined by numerous goblet cells. In the submucosa is a lymphoid nodule. The gut-associated lymphoid tissue as a unit represents the largest lymphoid organ of the body



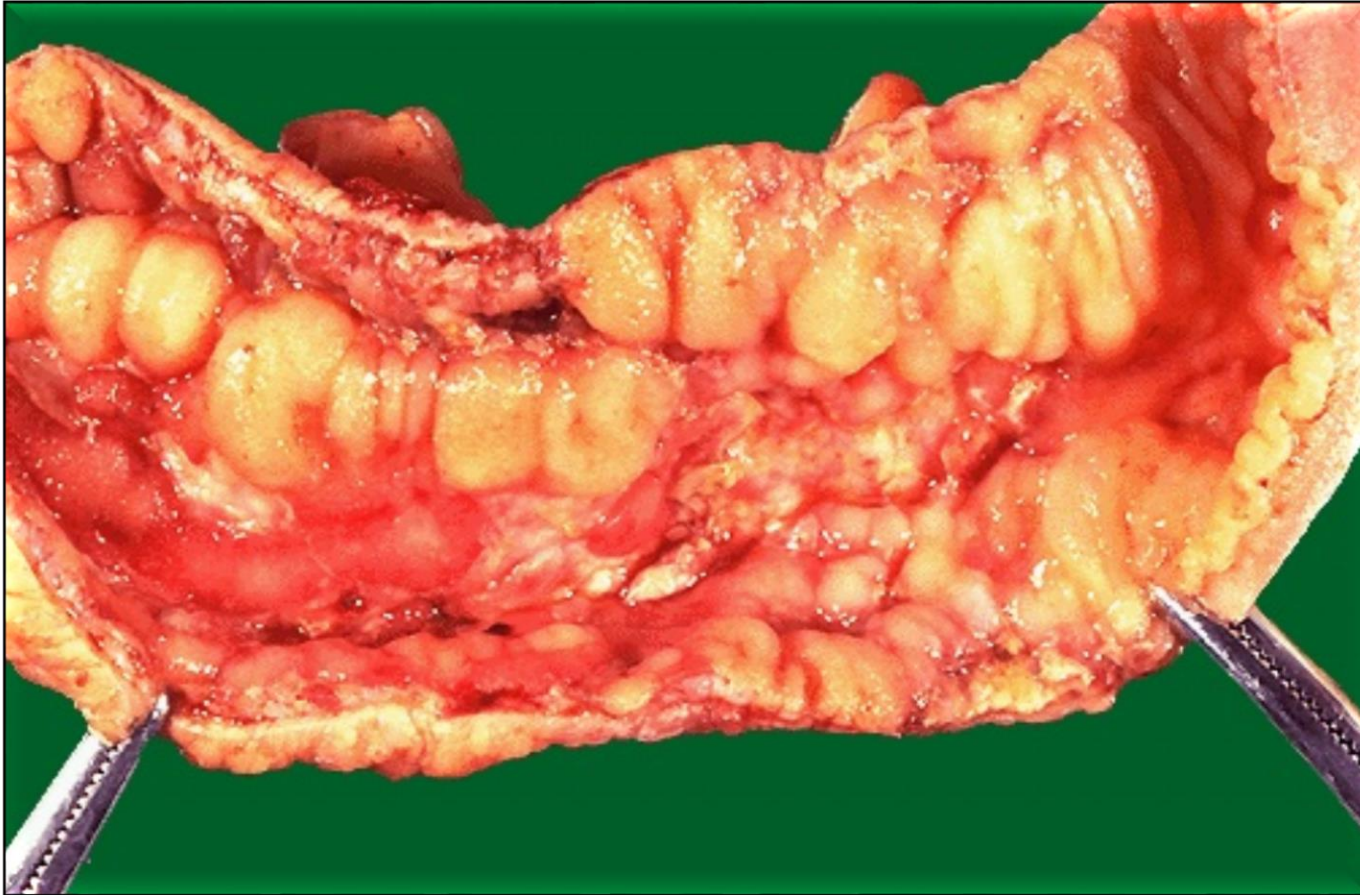
Crohn's disease

Crohn's Disease- Gross



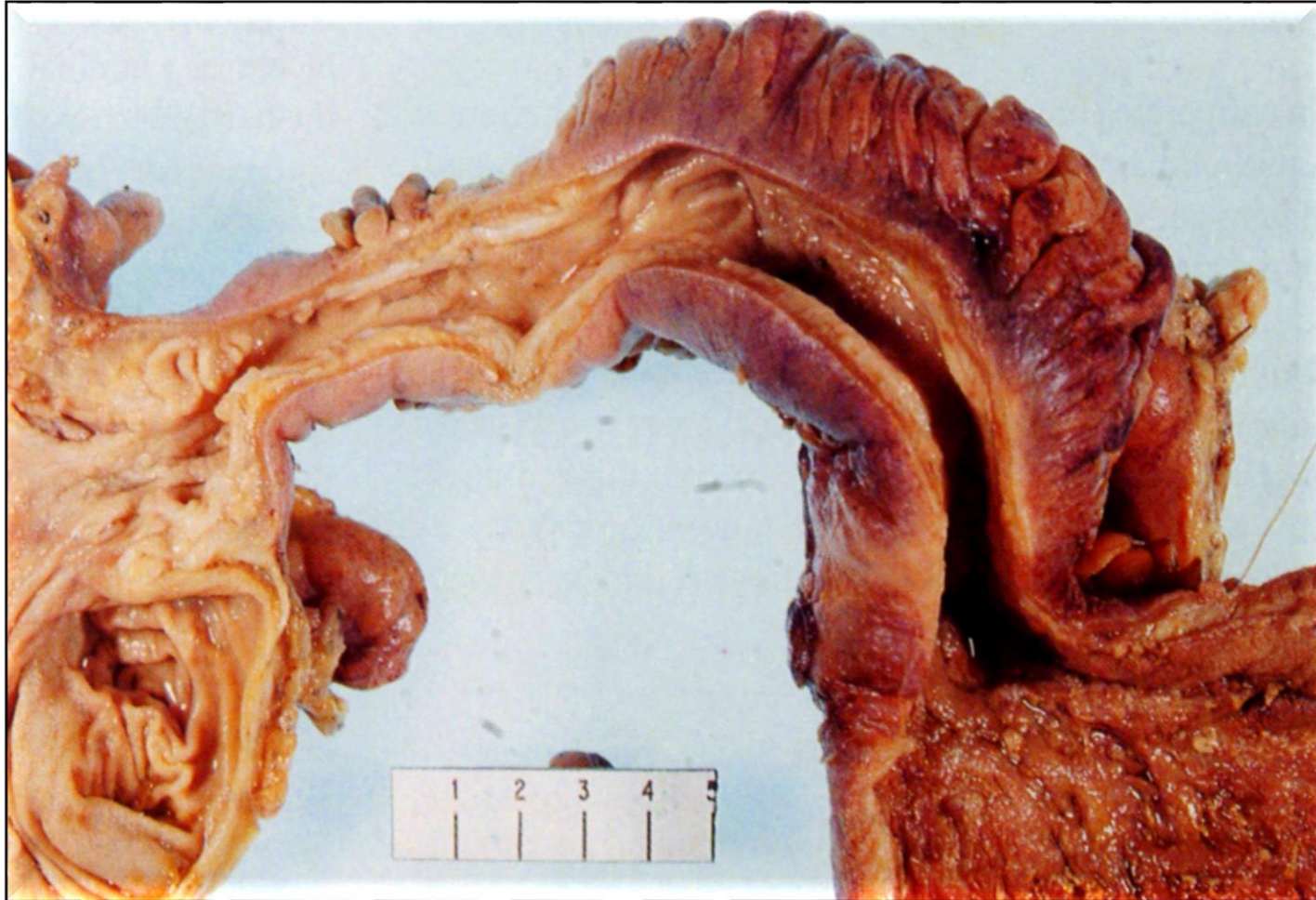
Here the inflammation has produced large, irregularly shaped to rake-like ulcers that are separated from each other by mucosa that appears close to normal.

Crohn's Disease- Gross



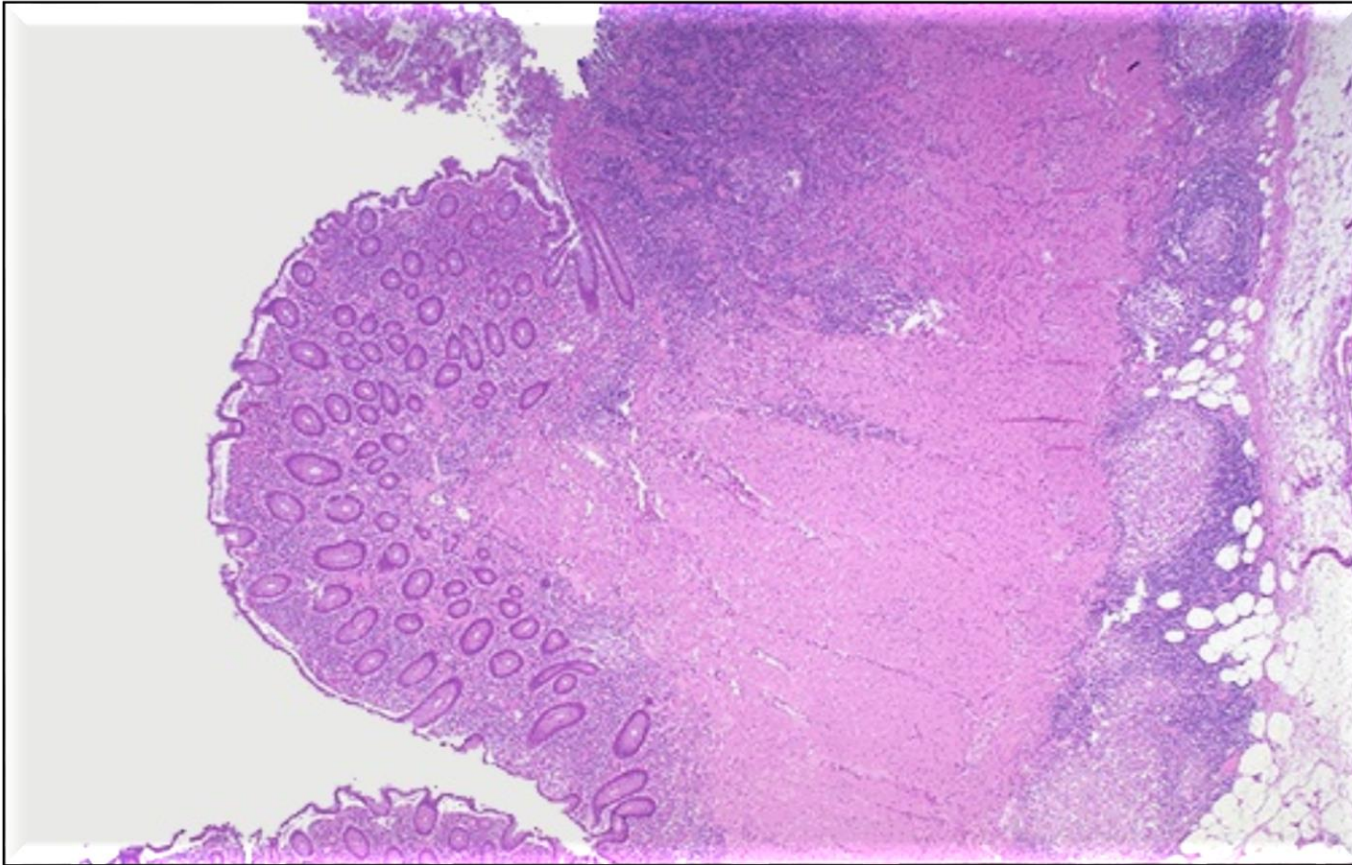
This is another example of Crohn's disease involving the small intestine. Here, the mucosal surface demonstrates an irregular nodular appearance with hyperemia and focal superficial ulceration.

Crohn's Disease vs Normal Colon



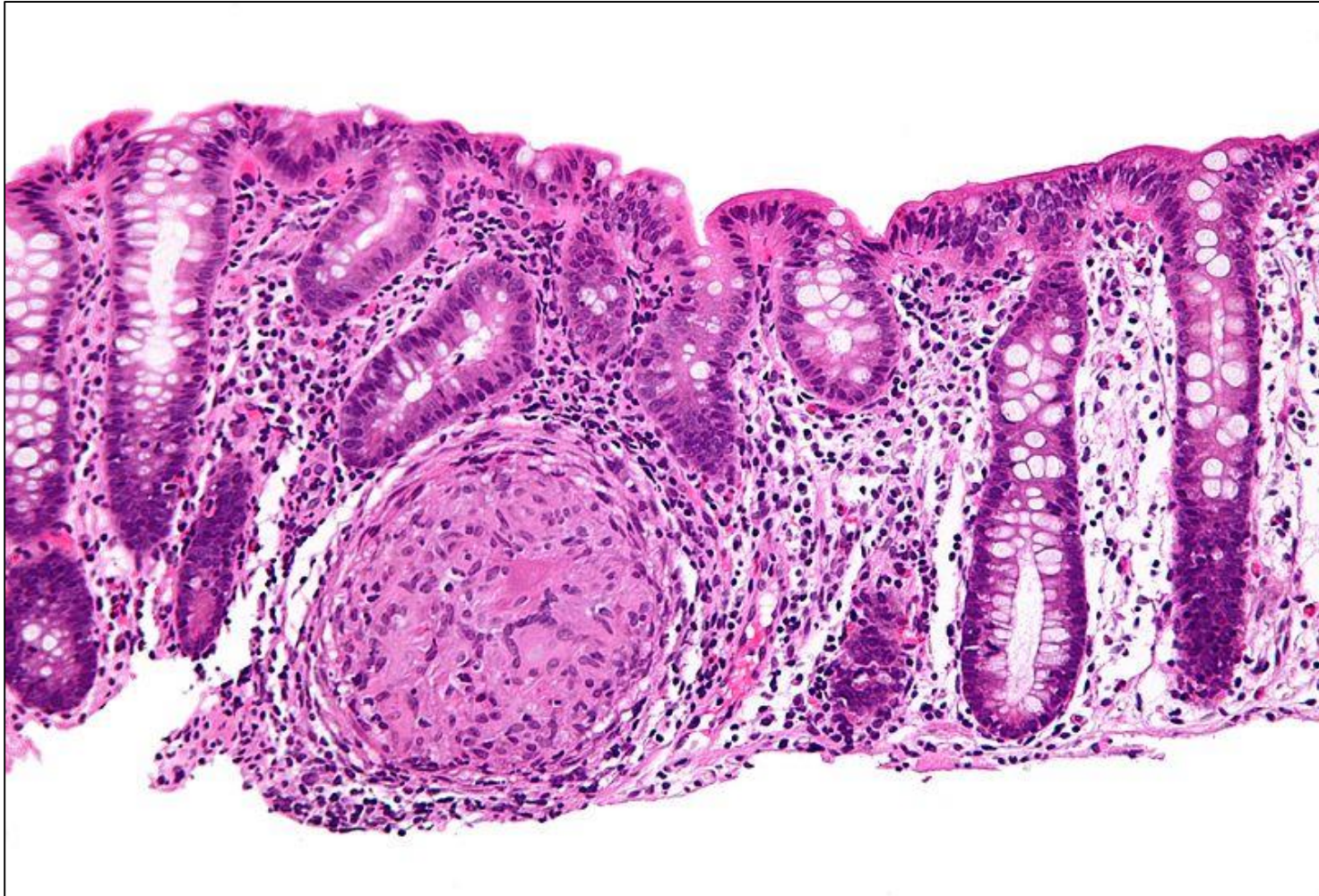Section of large bowel shows alternating normal and ulcerating mucosa

Crohn's Disease- LPF



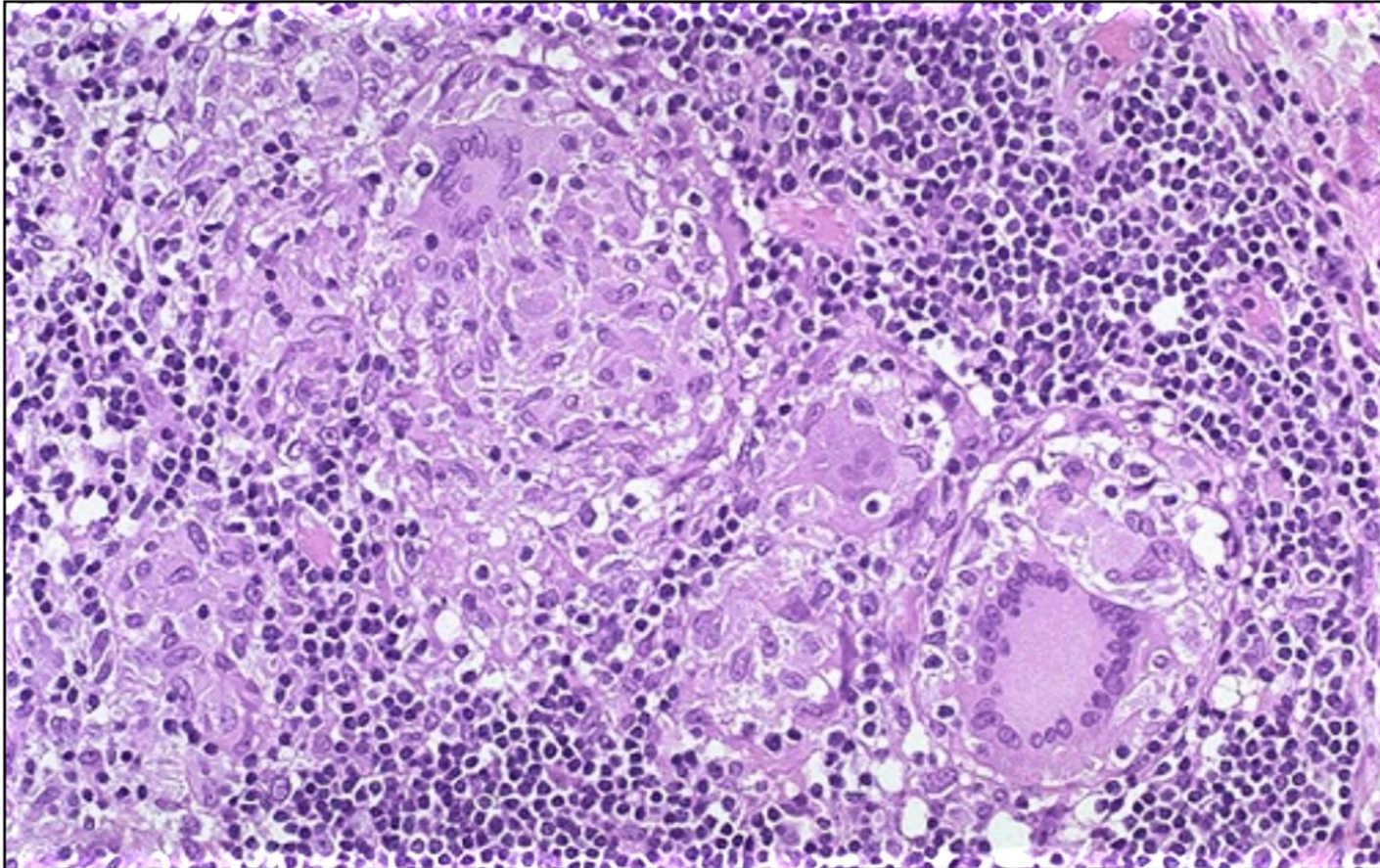
Microscopically, Crohn's disease is characterized by transmural inflammation. Here, inflammatory cells (the bluish infiltrates) extend from mucosa through submucosa and muscularis and appear as nodular infiltrates on the serosal surface with pale granulomatous centers.

Crohn's Disease- HPF



All layers of intestinal wall show transmural chronic inflammatory cell infiltrate, lymphoid aggregates and mild fibrosis. Few Non-necrotizing epithelioid granuloma are seen.

Crohn's Disease- HPF

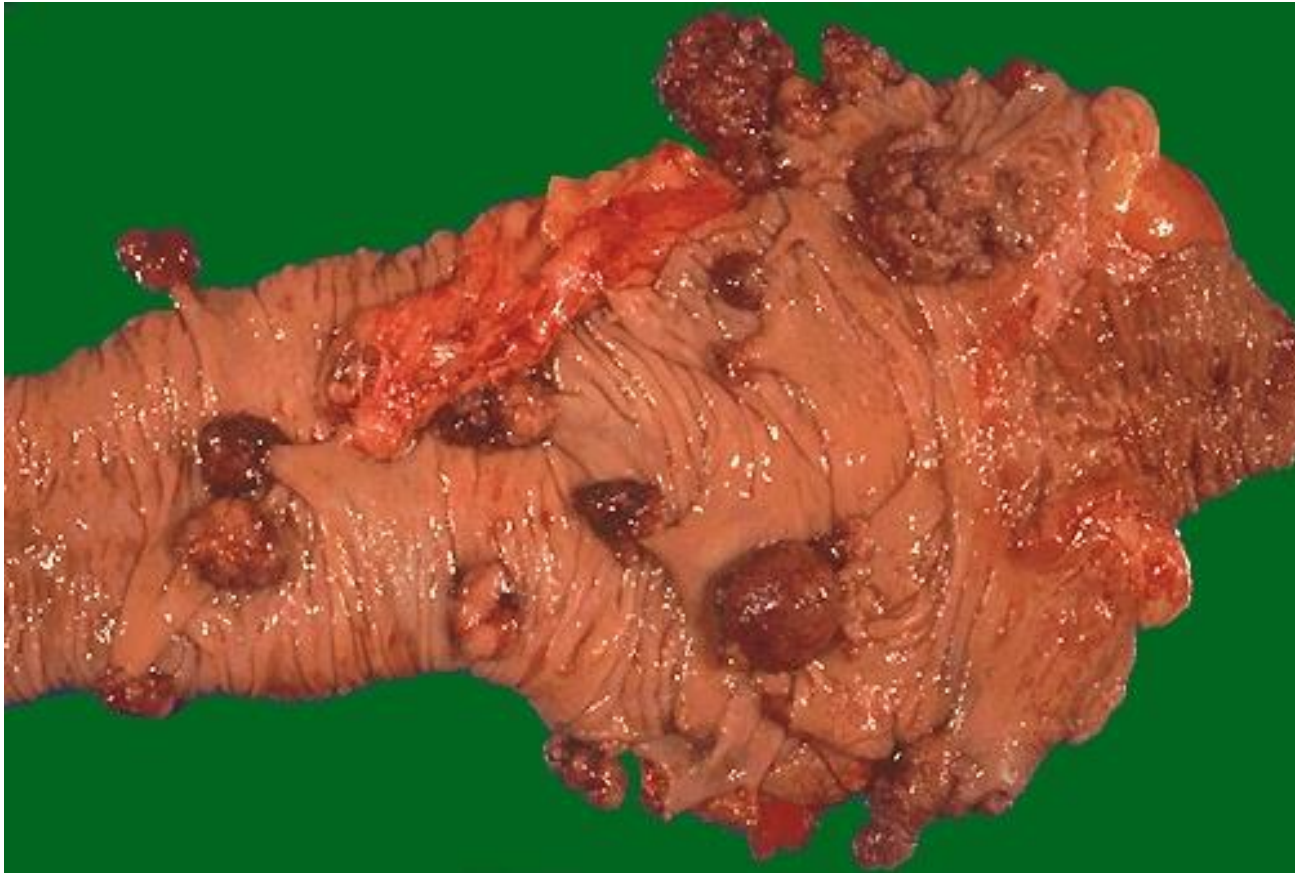


At high magnification the granulomatous nature of the inflammation of Crohn's disease is demonstrated here with epithelioid cells, giant cells, and many lymphocytes. Special stains for organisms are negative.



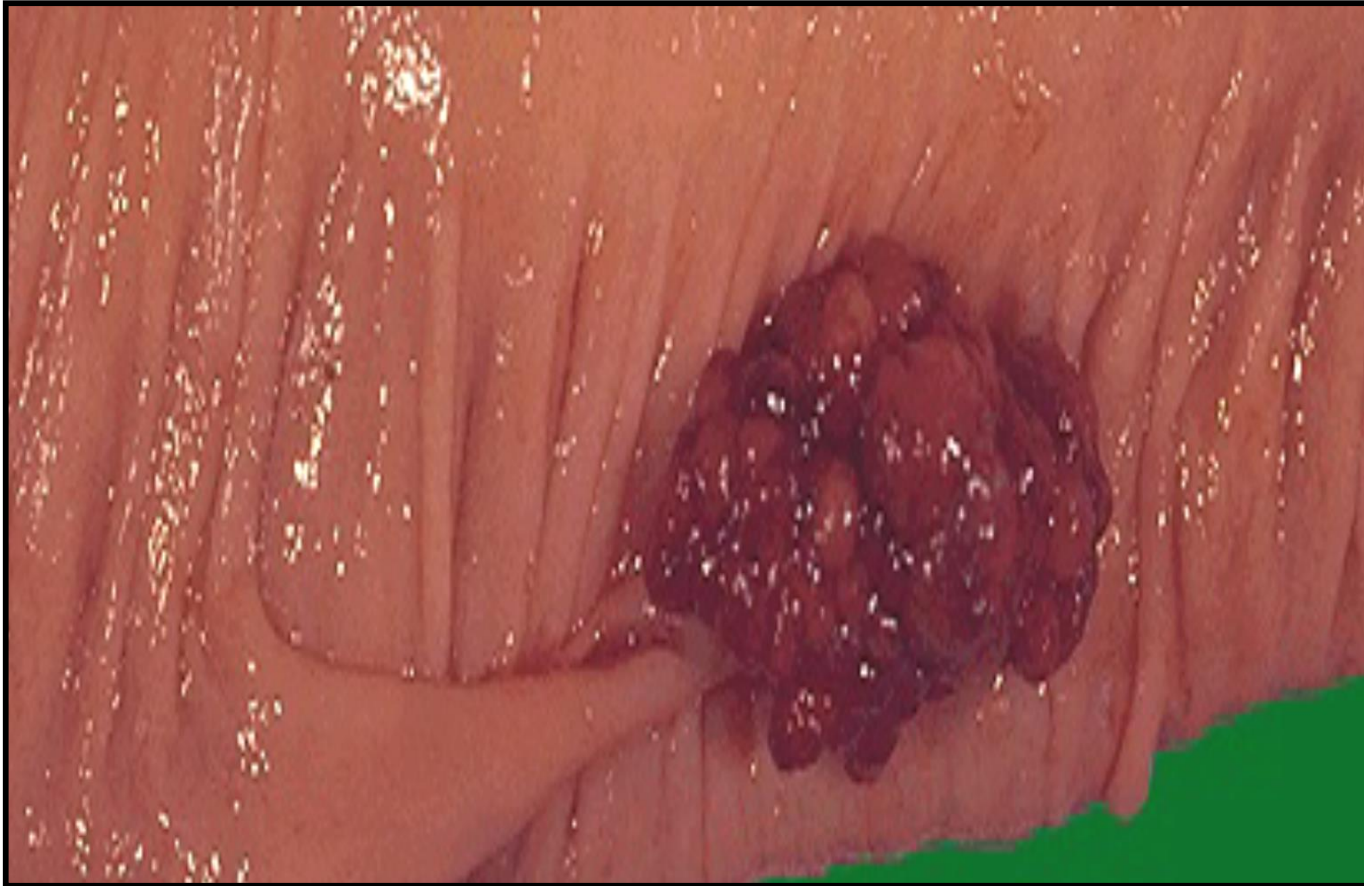
Adenomatous polyps of rectum / colon

Adenomatous polyp of the colon - Gross



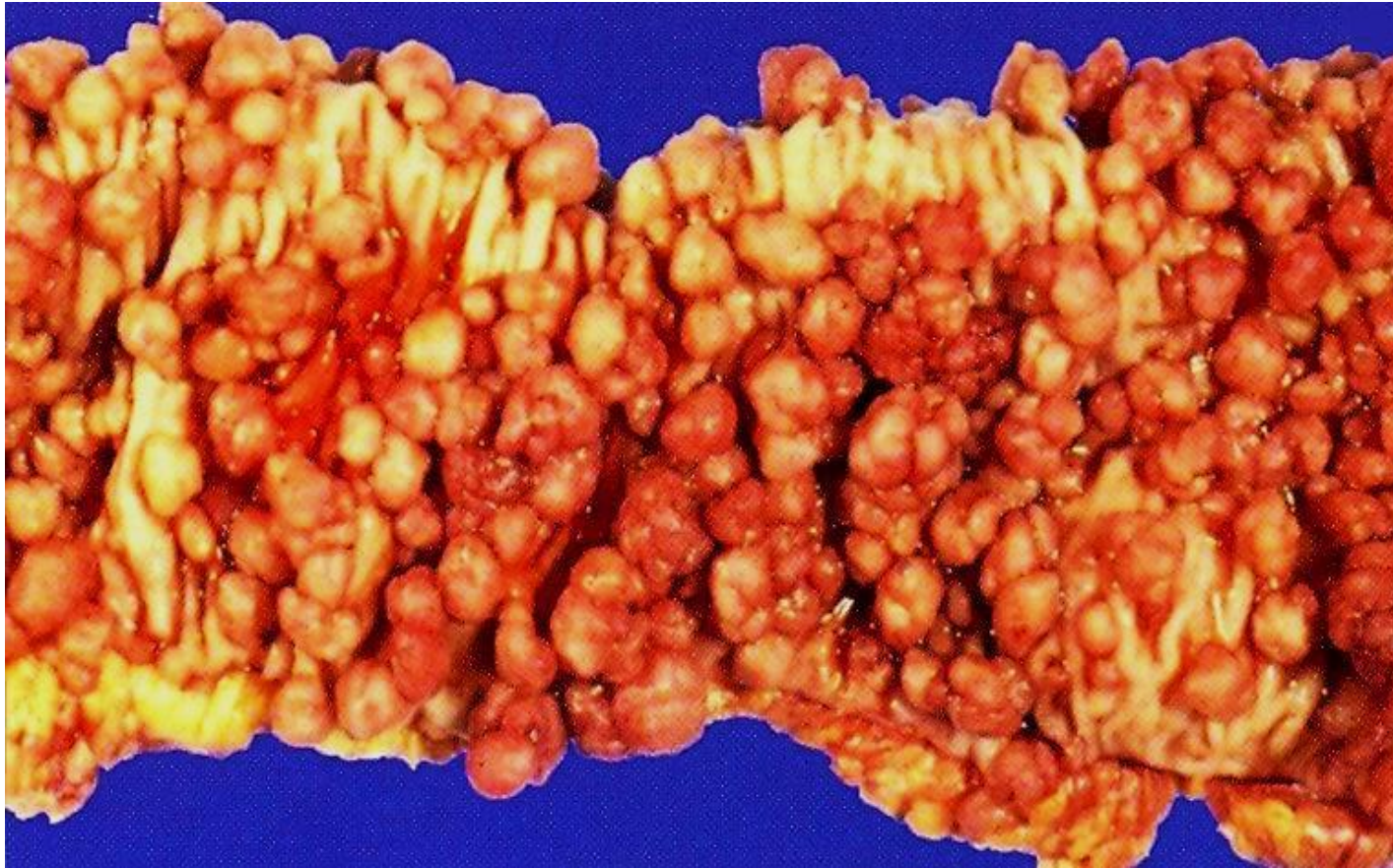
Multiple adenomatous polyps (tubulovillous adenomas) of the cecum are seen here in a case of familial adenomatous polyposis, a genetic syndrome in which an abnormal genetic mutation leads to development of multiple neoplasms in the colon

Adenomatous polyp of the colon - Gross



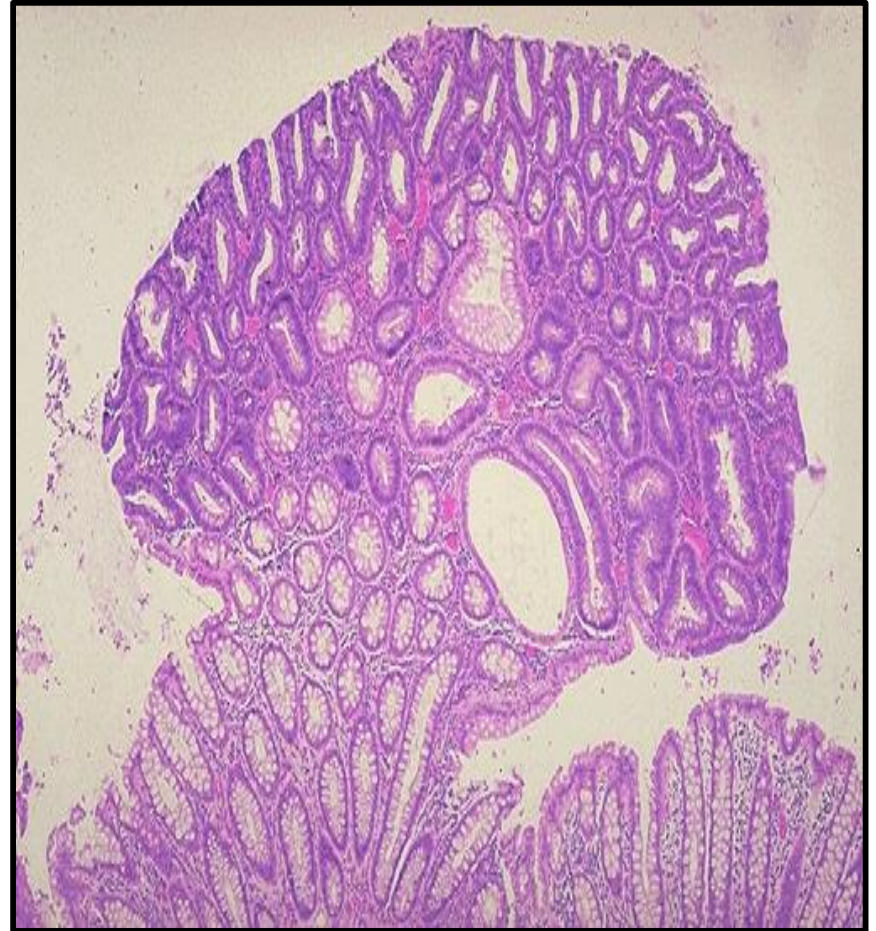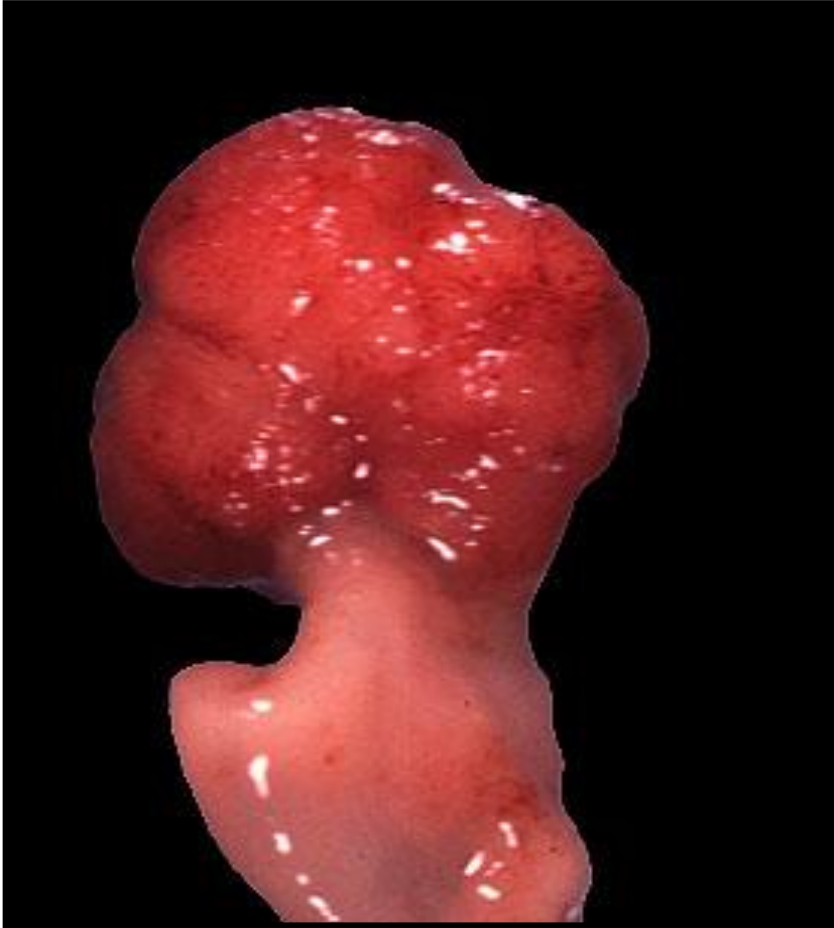This adenomatous polyp has a hemorrhagic surface (which is why they may first be detected with stool occult blood screening) and a long narrow stalk. The size of this polyp--above 2 cm--makes the possibility of malignancy more likely, but this polyp proved to be benign

Familial polyposis of the colon - Gross



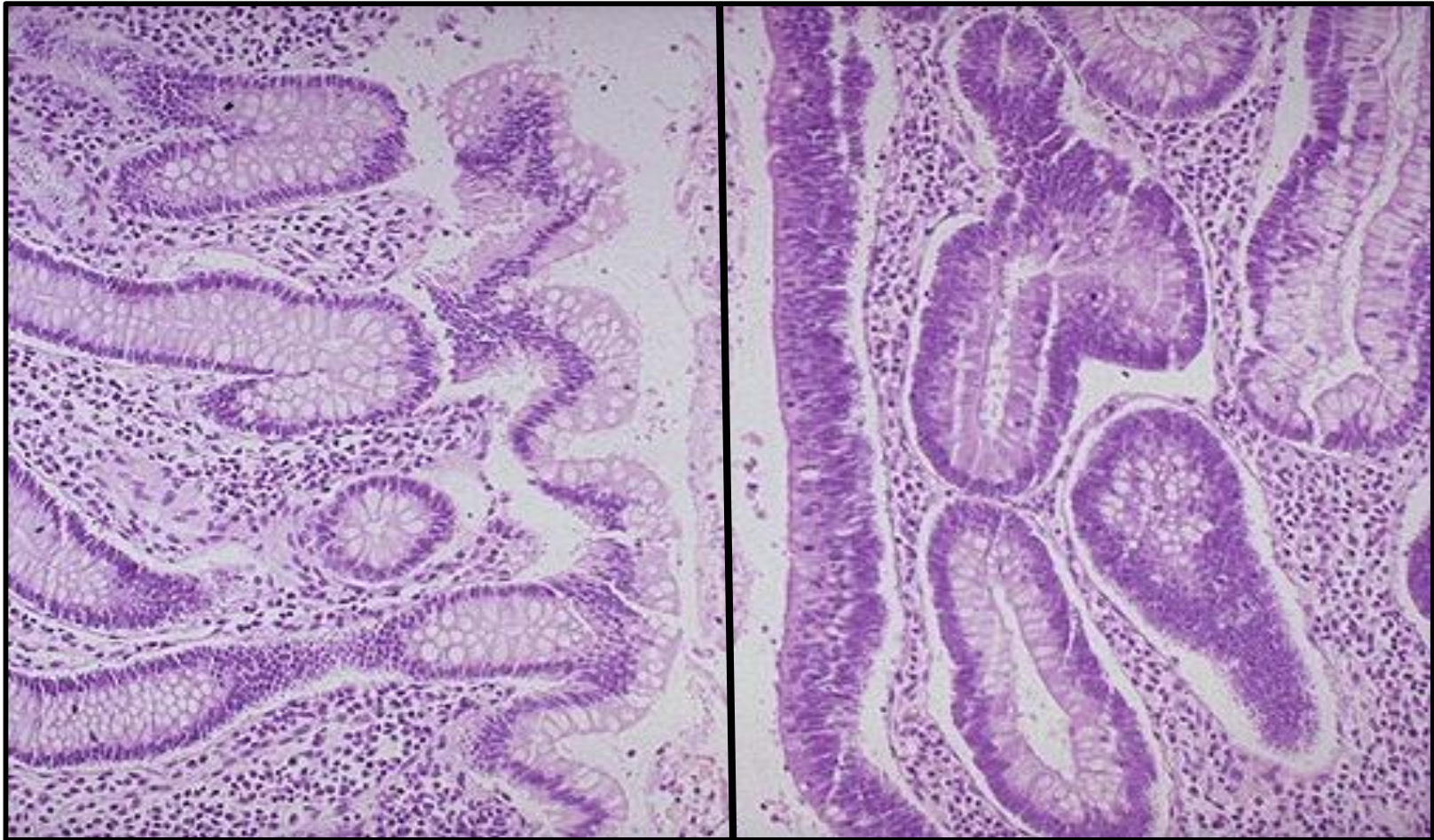
It is caused by mutations of the adenomatous polyposis coli , or APC gene . The major complication is development of adenocarcinoma of the colon.

Adenomatous polyp of the colon - LPF



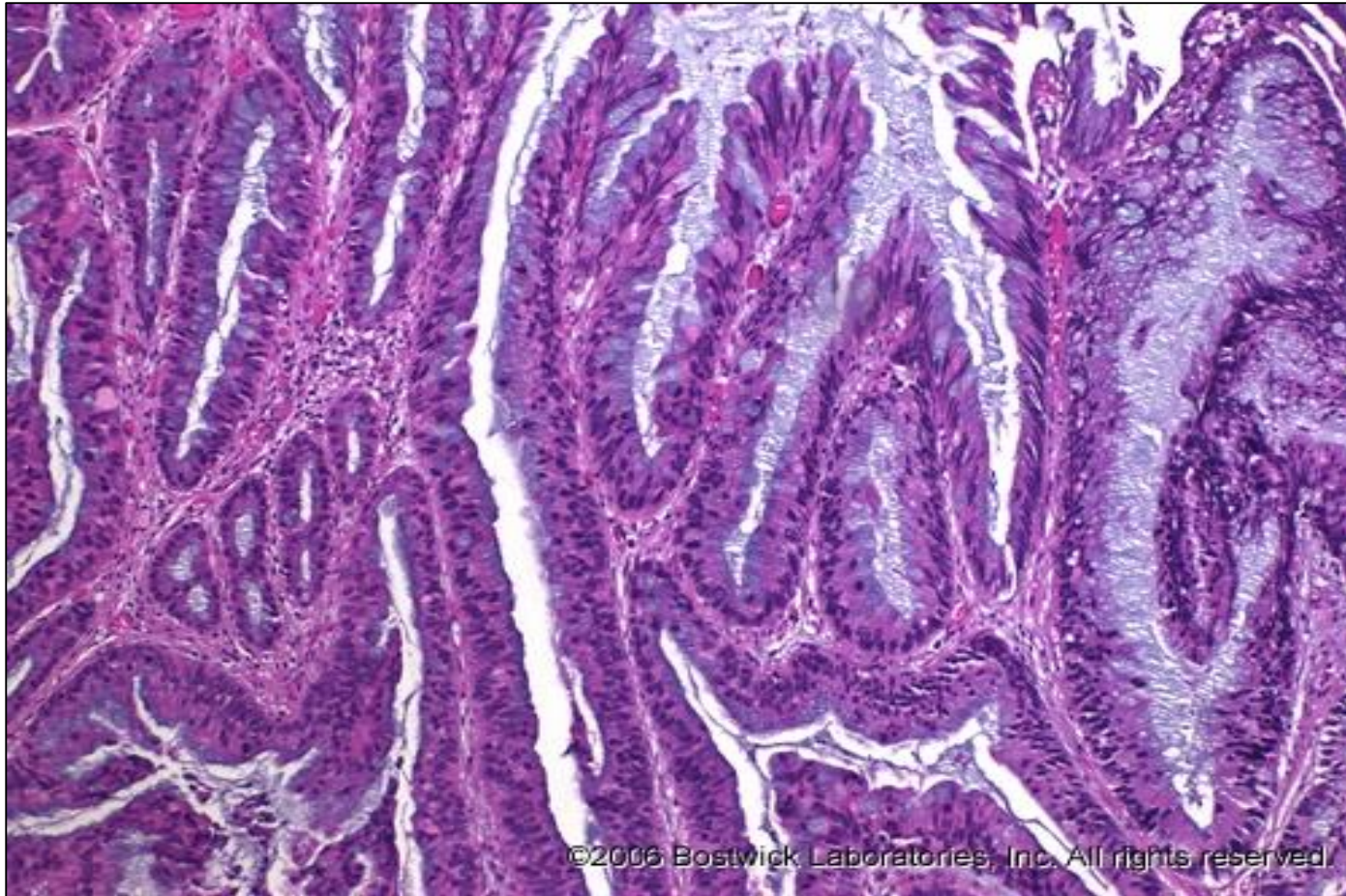
This small adenomatous polyp (tubular adenoma) on a small stalk is seen microscopically to have more crowded, disorganized glands than the normal underlying colonic mucosa. Goblet cells are less numerous and the cells lining the glands of the polyp have hyperchromatic nuclei

Normal vs Adenomatous polyp of the colon - MPF



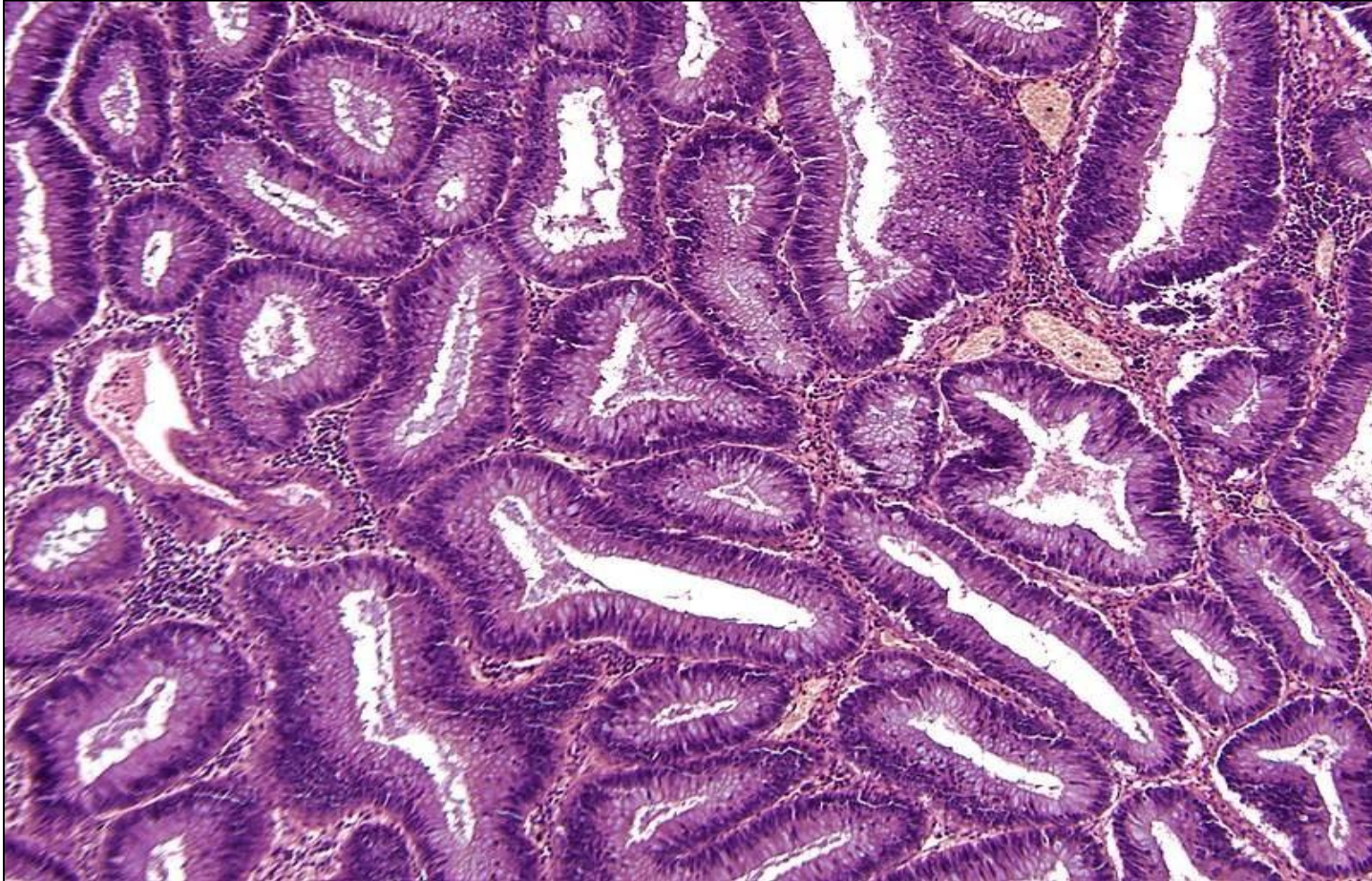
A microscopic comparison of normal colonic mucosa on the left and that of an adenomatous polyp (tubular adenoma) on the right is seen here. The neoplastic glands are more irregular with darker (hyperchromatic) and more crowded nuclei

Adenomatous Polyp (Villous) - MPF



Villous adenomas behave more aggressively than tubular adenomas. They have a HIGHER rate of developing into frank adenocarcinomas than the "tubular" patterns.

Adenomatous Polyp (Tubular) - MPF

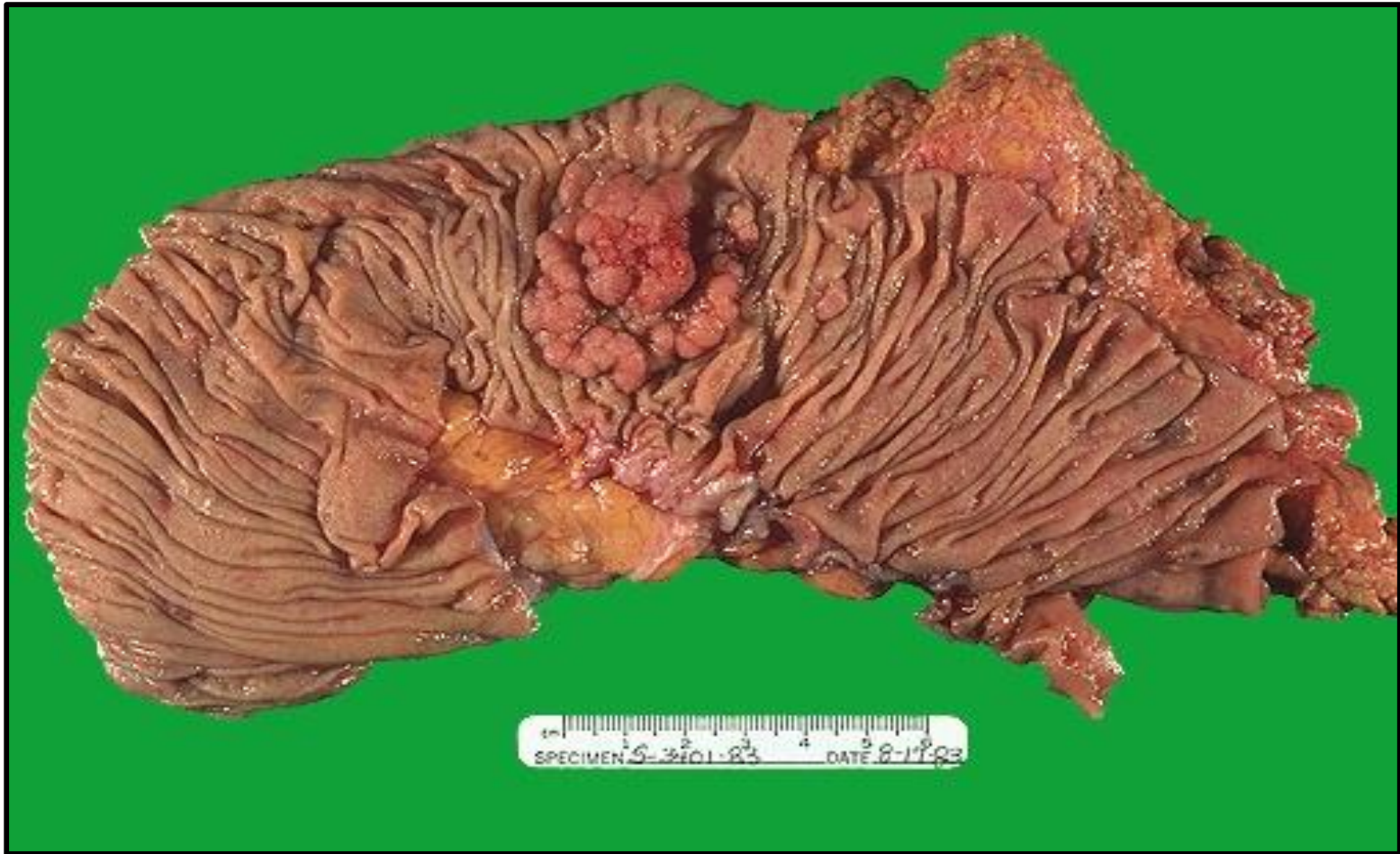

TUBULAR adenoma with crowded dysplastic glands and chronic inflammation.



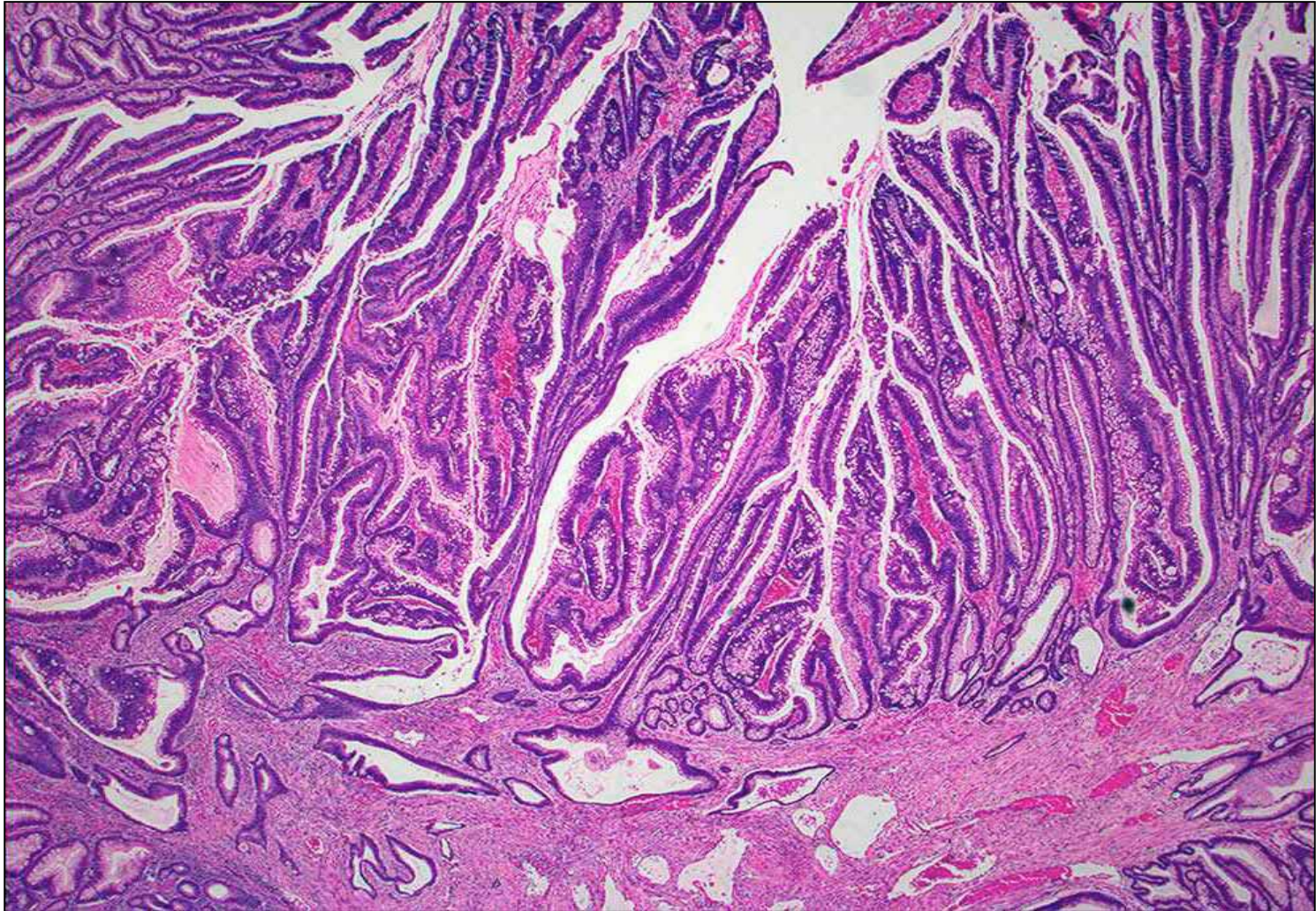
Adenocarcinoma of the large intestine

Adenocarcinoma of the Colon - Gross



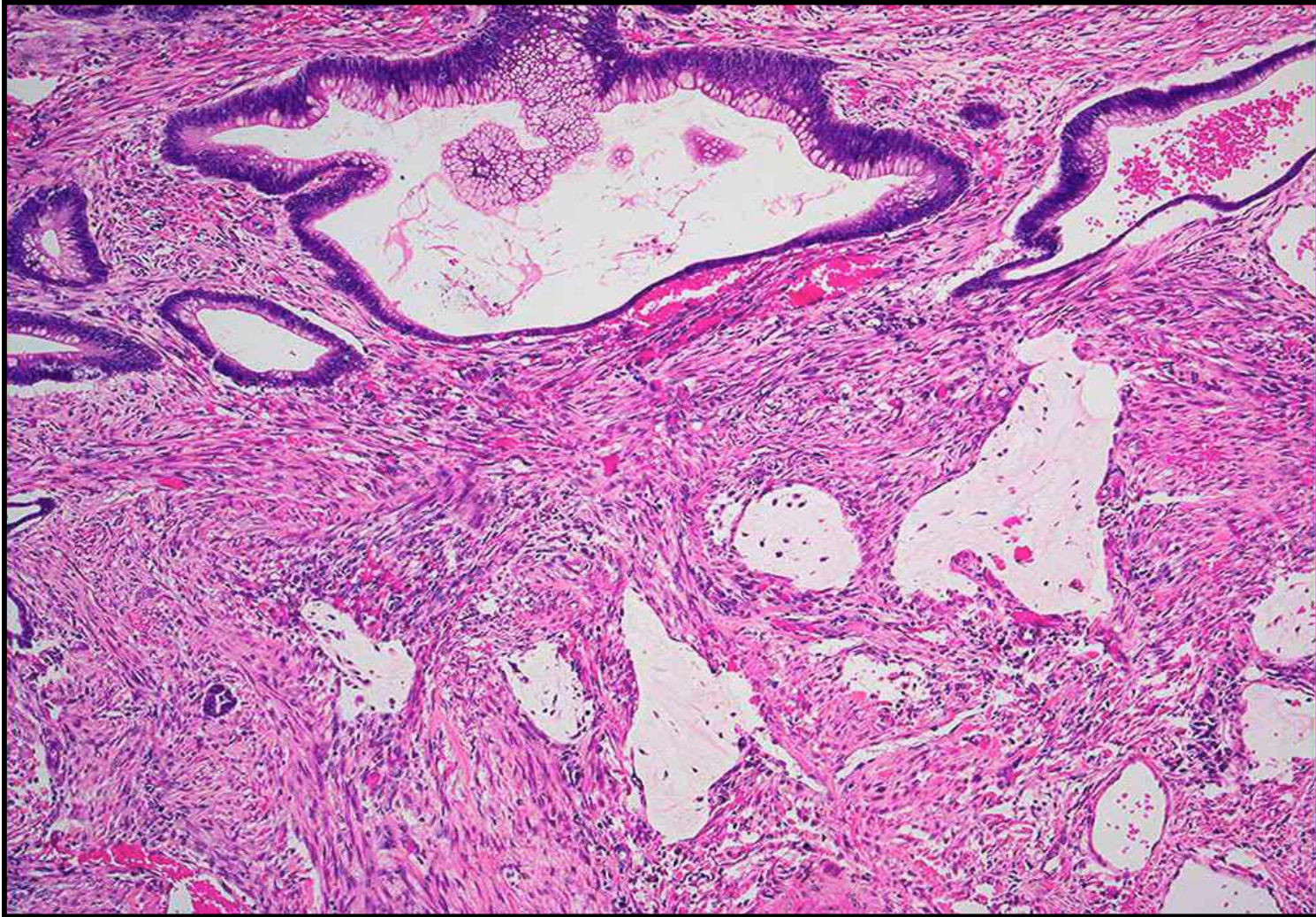
This is an adenocarcinoma arising in a villous adenoma. The surface of the neoplasm is polypoid and reddish pink. Hemorrhage from the surface of the tumor creates a guaiac positive stool. This neoplasm was located in the sigmoid colon

Adenocarcinoma of the Colon - LPF



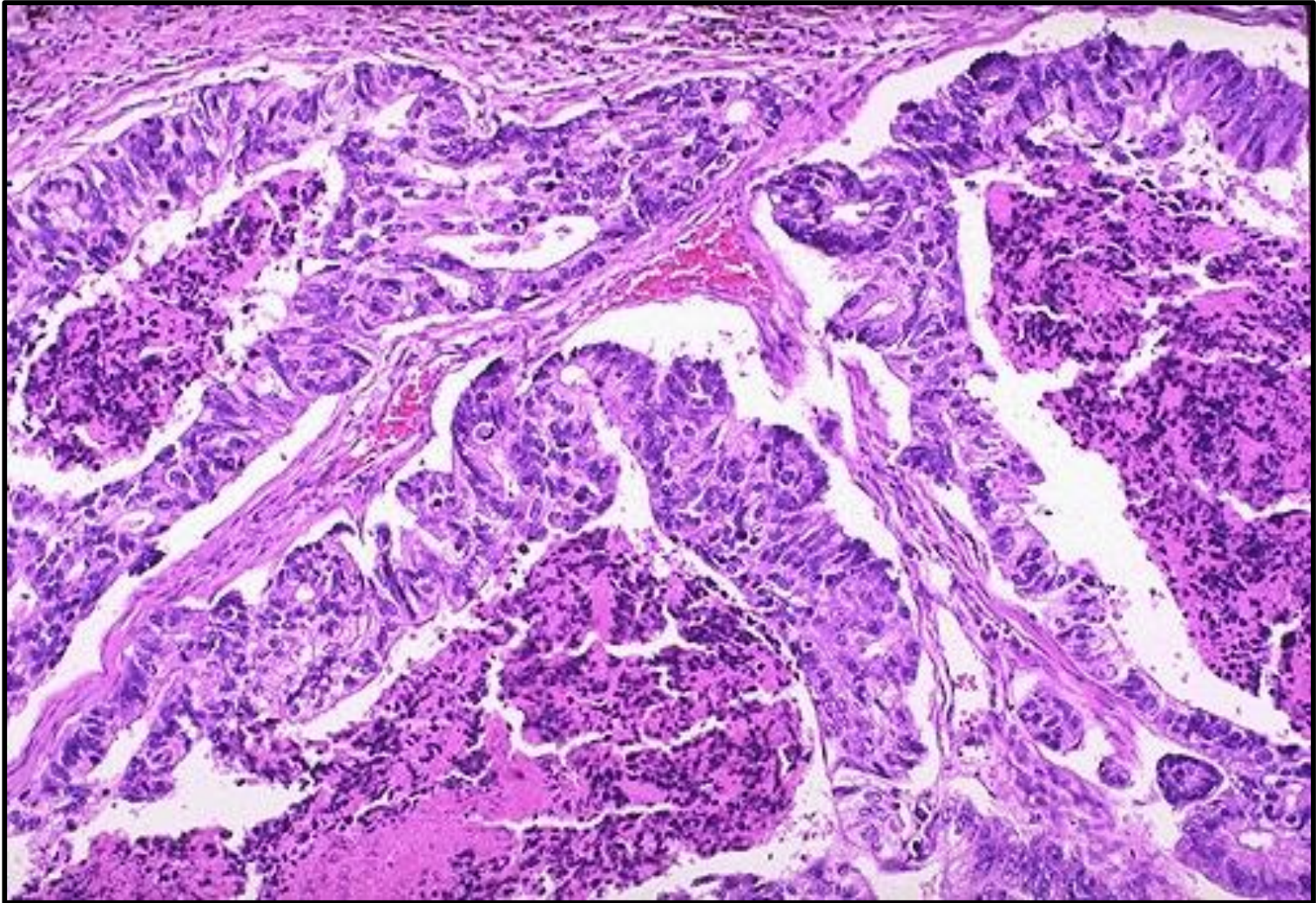
Tumour consists of crowded irregular malignant acini separated by thin fibrovascular stroma.

Adenocarcinoma of the Colon - LPF



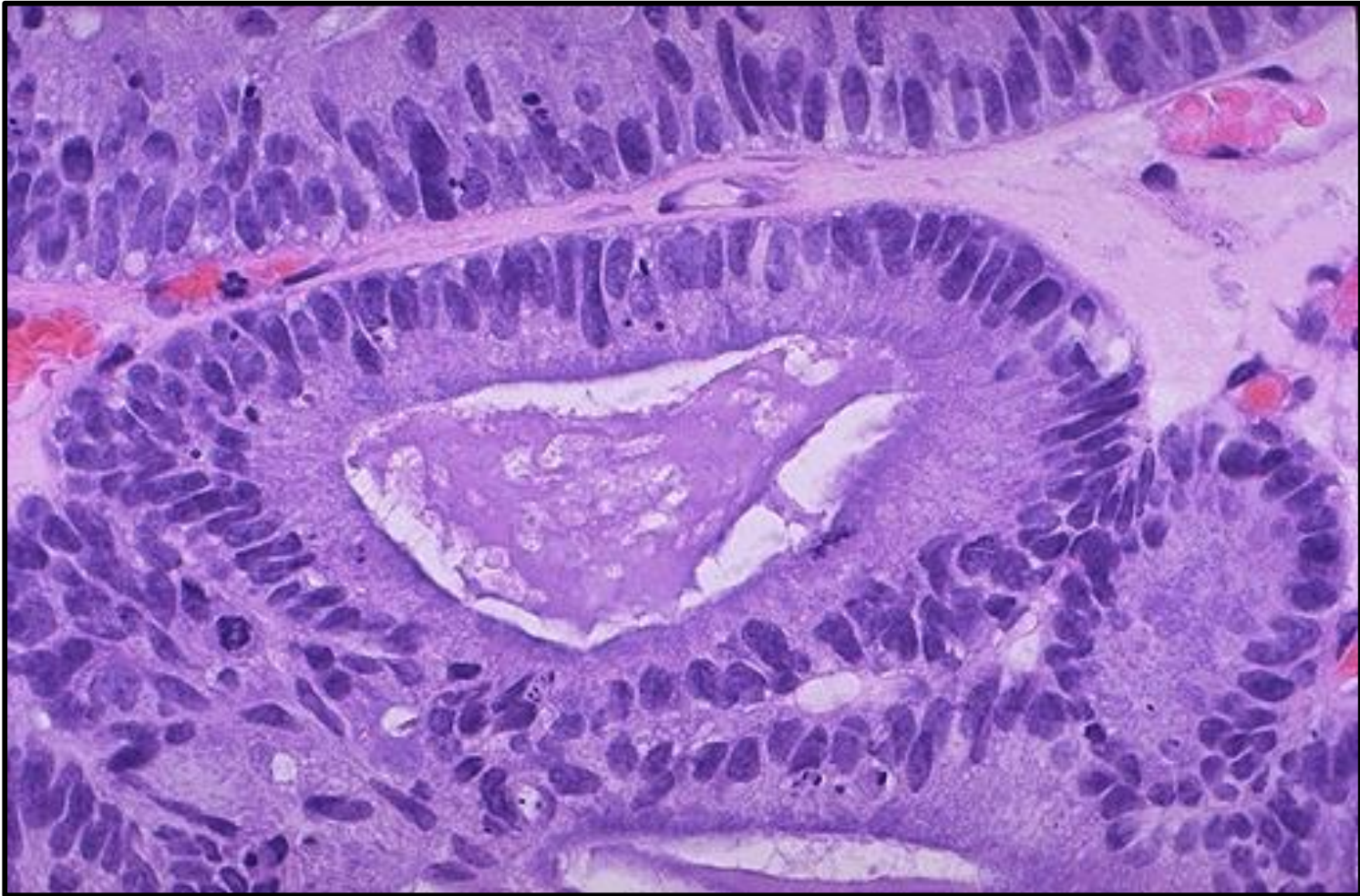
The acini are lined by one or several layers of neoplastic cells showing pleomorphism, hyperchromatism and few mitoses.

Adenocarcinoma of the Colon - MPF



Here is an adenocarcinoma in which the glands are much larger and filled with necrotic debris.

Adenocarcinoma of the Colon - HPF

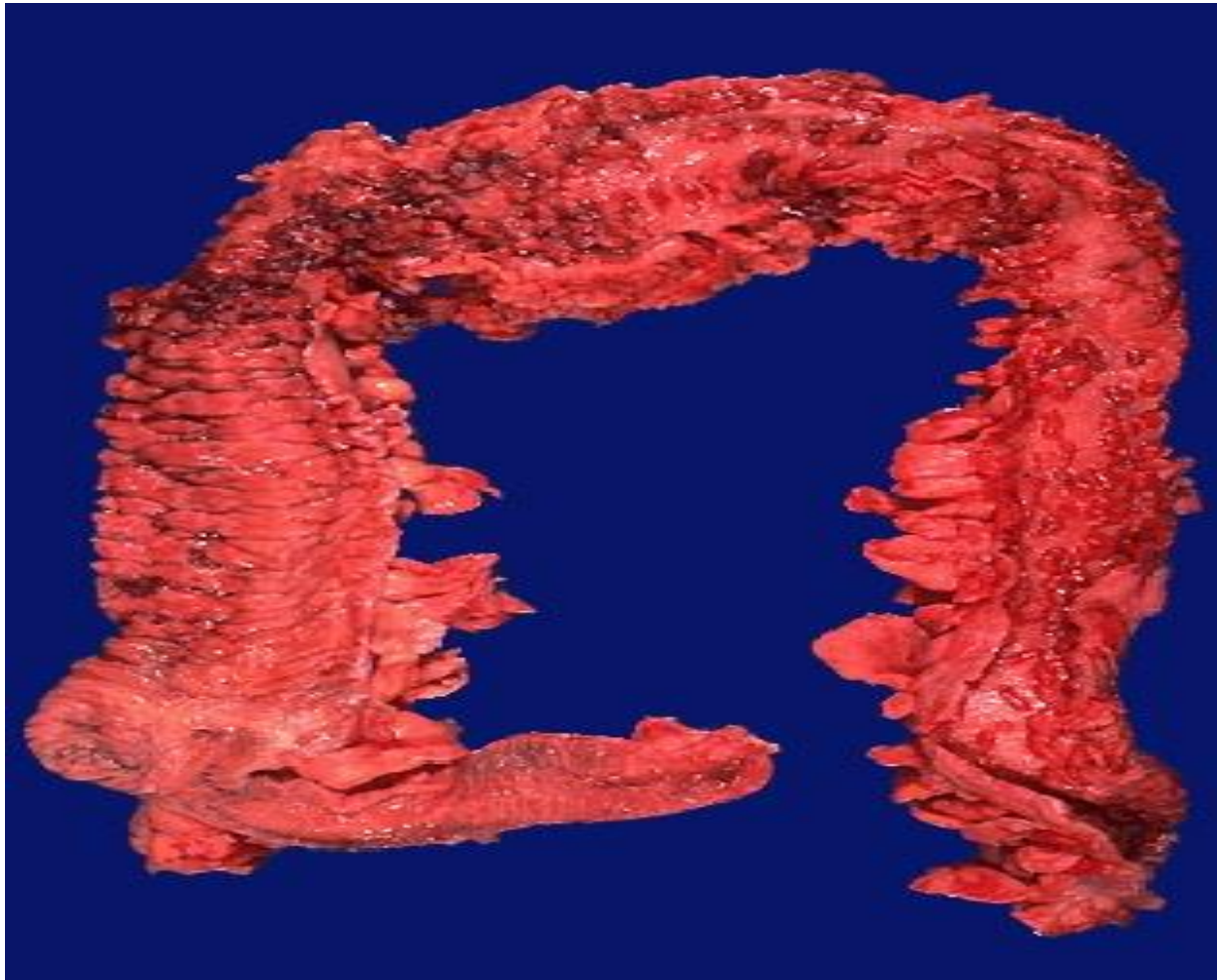


At high magnification, the neoplastic glands of adenocarcinoma have crowded nuclei with hyperchromatism and pleomorphism. No normal goblet cells are seen



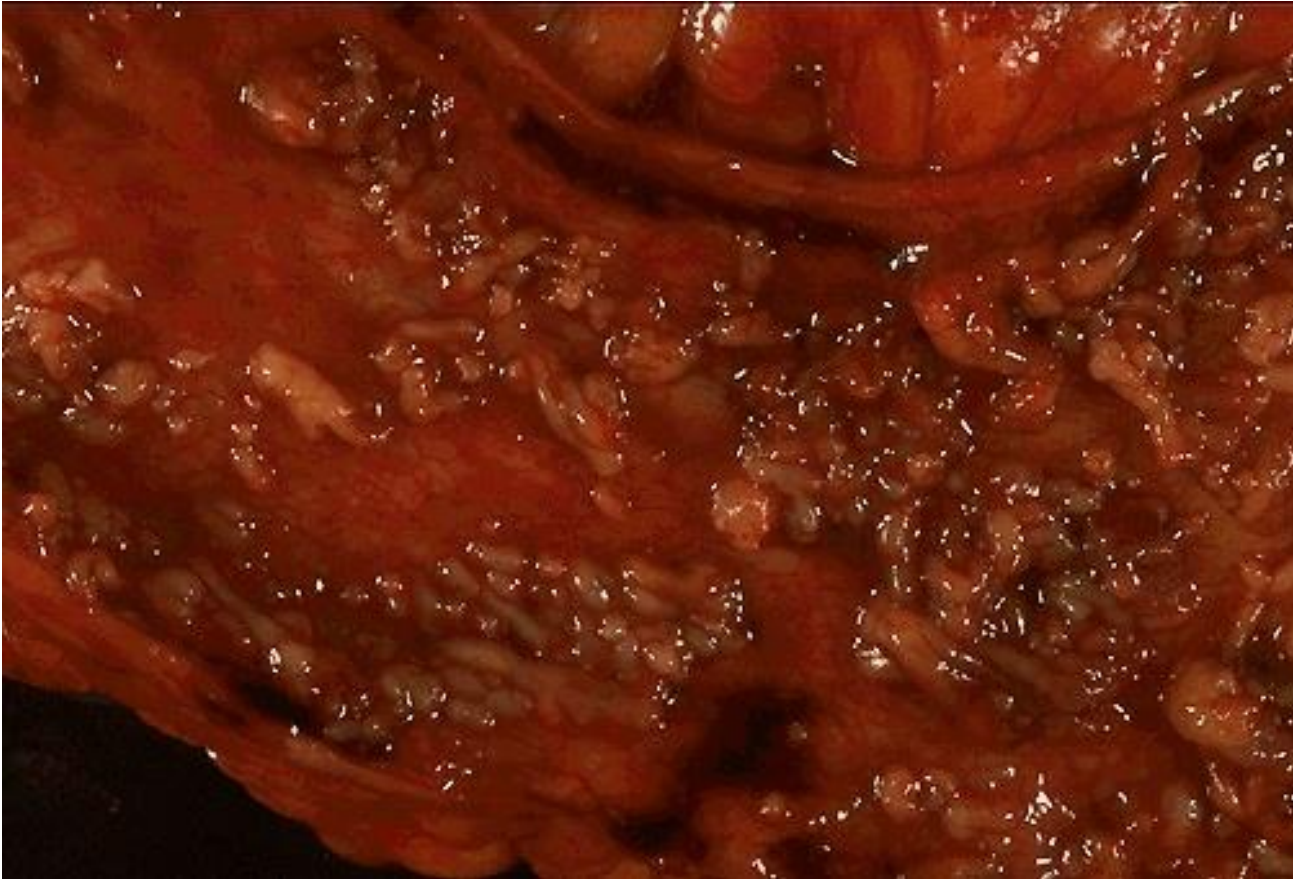
Ulcerative colitis

Chronic Ulcerative Colitis - Gross



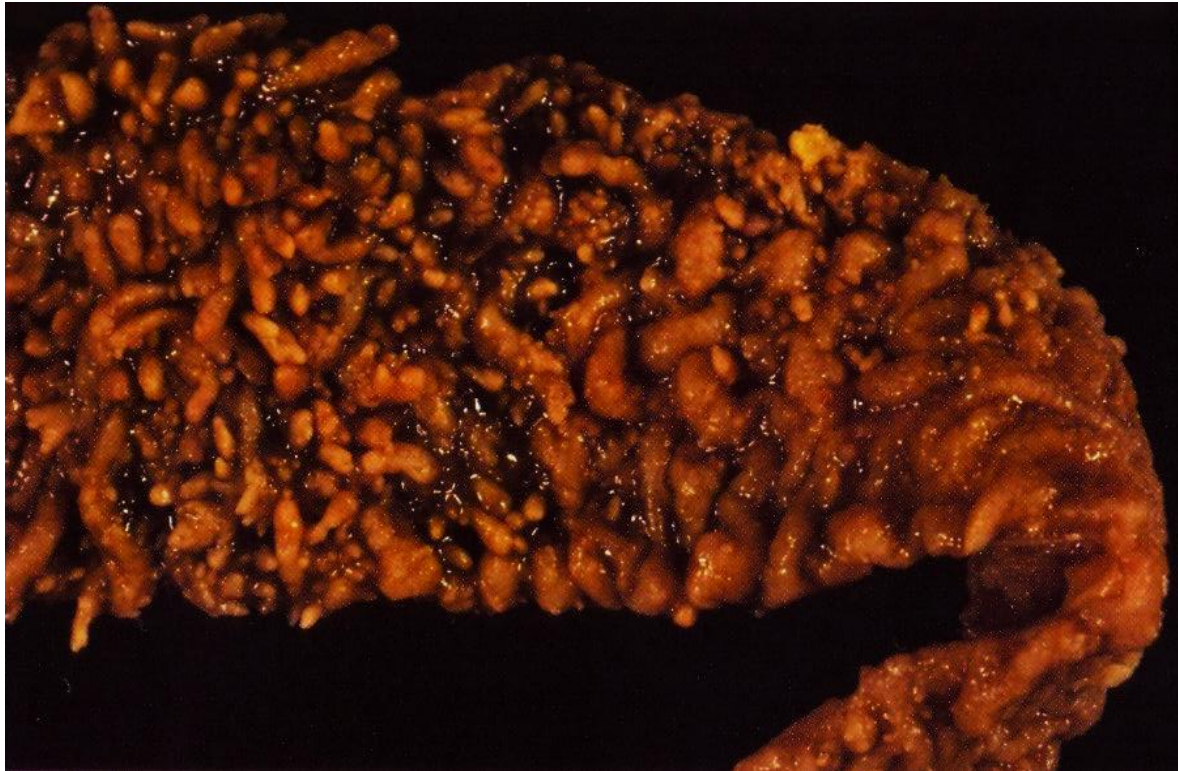
The most intense inflammation begins at the sigmoid colon (Right) and extends upward and around to the ascending colon. At the lower left is the ileocecal valve with a portion of terminal ileum that is not involved.

Pseudopolyps - Gross



Pseudopolyps are seen here in a case of severe ulcerative colitis. The remaining mucosa has been ulcerated away and is hyperemic.

Pseudopolyps - Gross

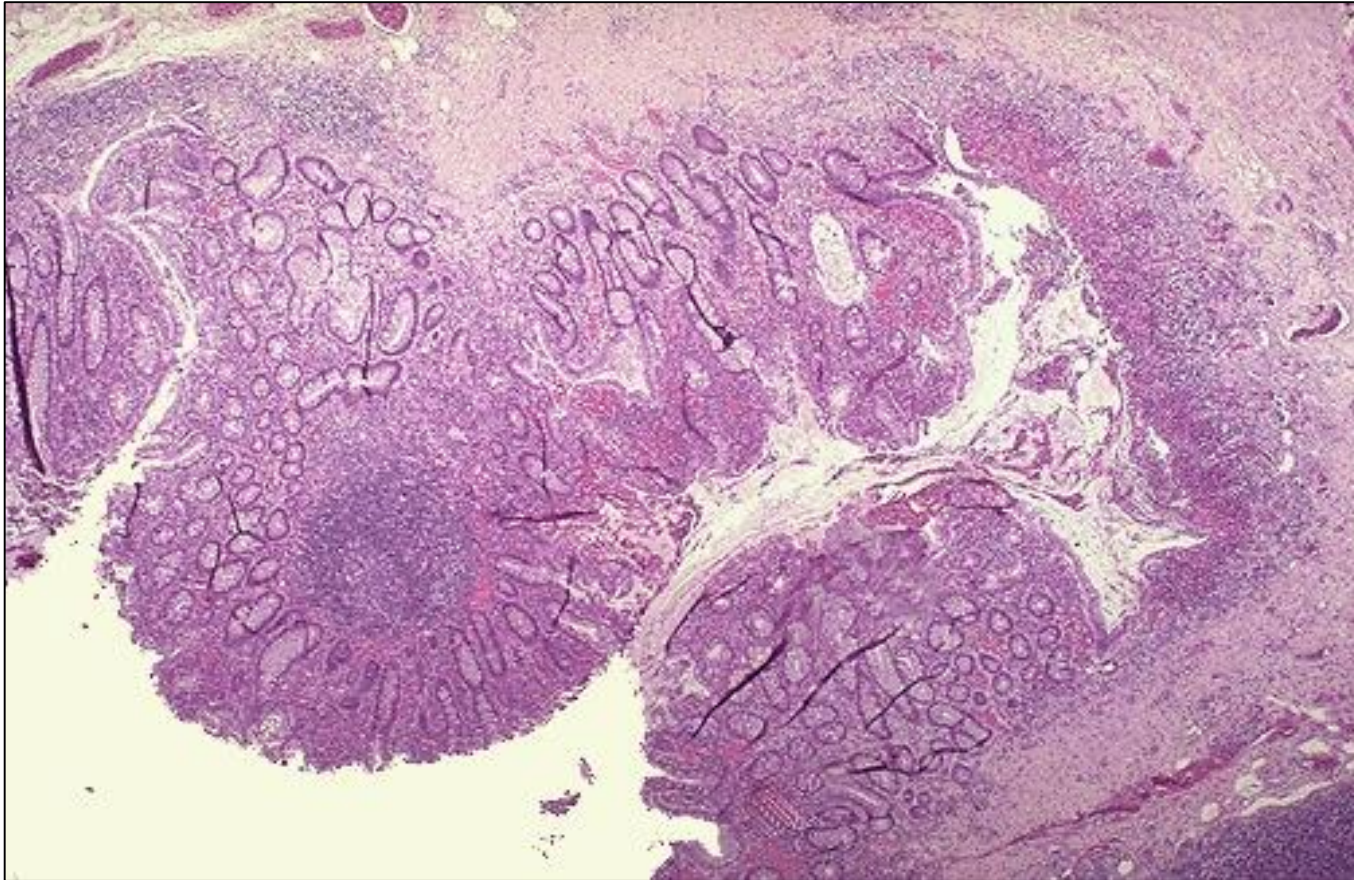


Complications

- Toxic megacolon
- Erythema nodosum
- Adenocarcinoma

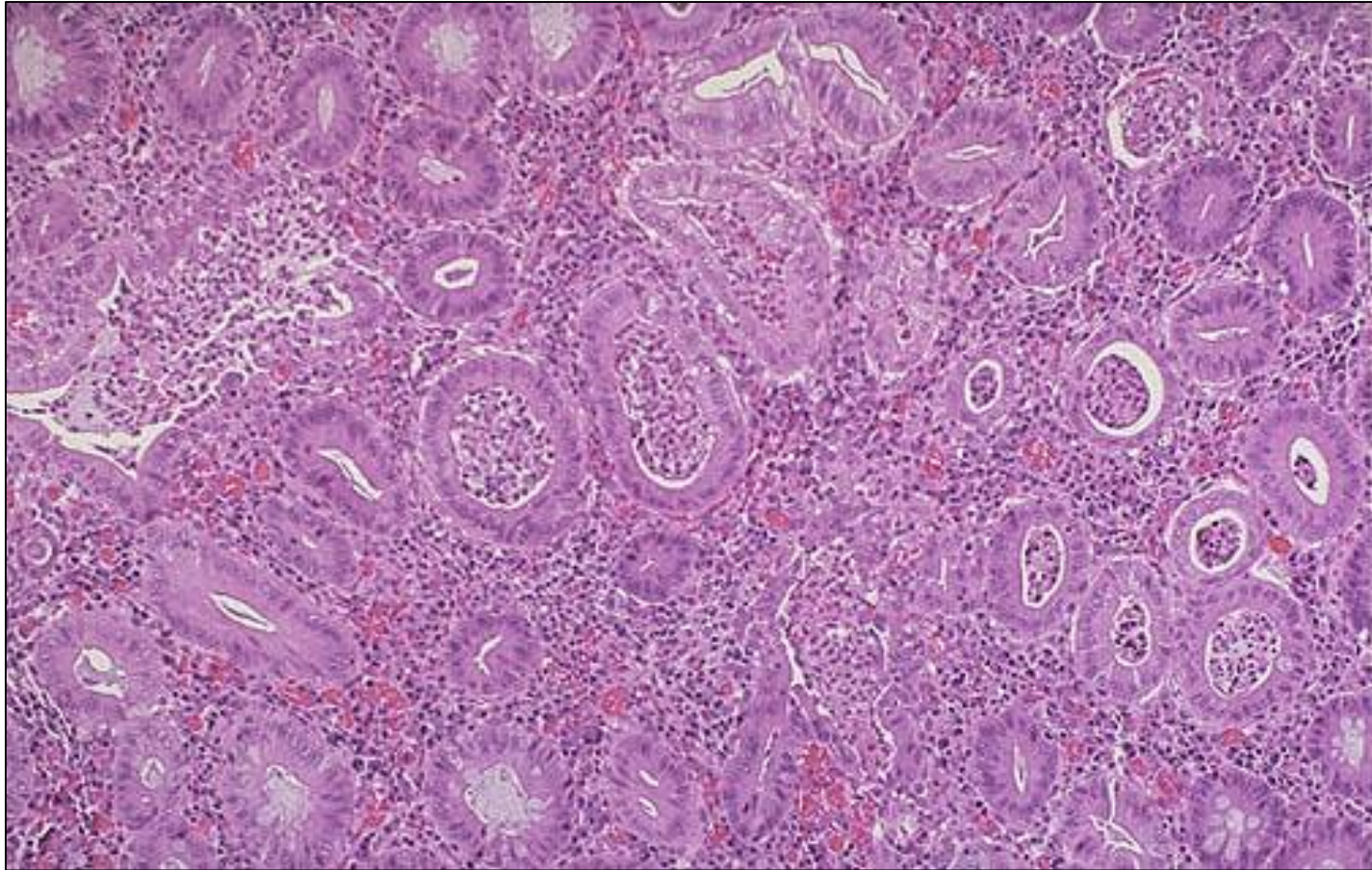
*The picture shows pseudo polyps formation .
Toxic mega colon, glandular dysplasia and
adenocarcinoma are the main complications .*

Chronic Ulcerative Colitis - LPF



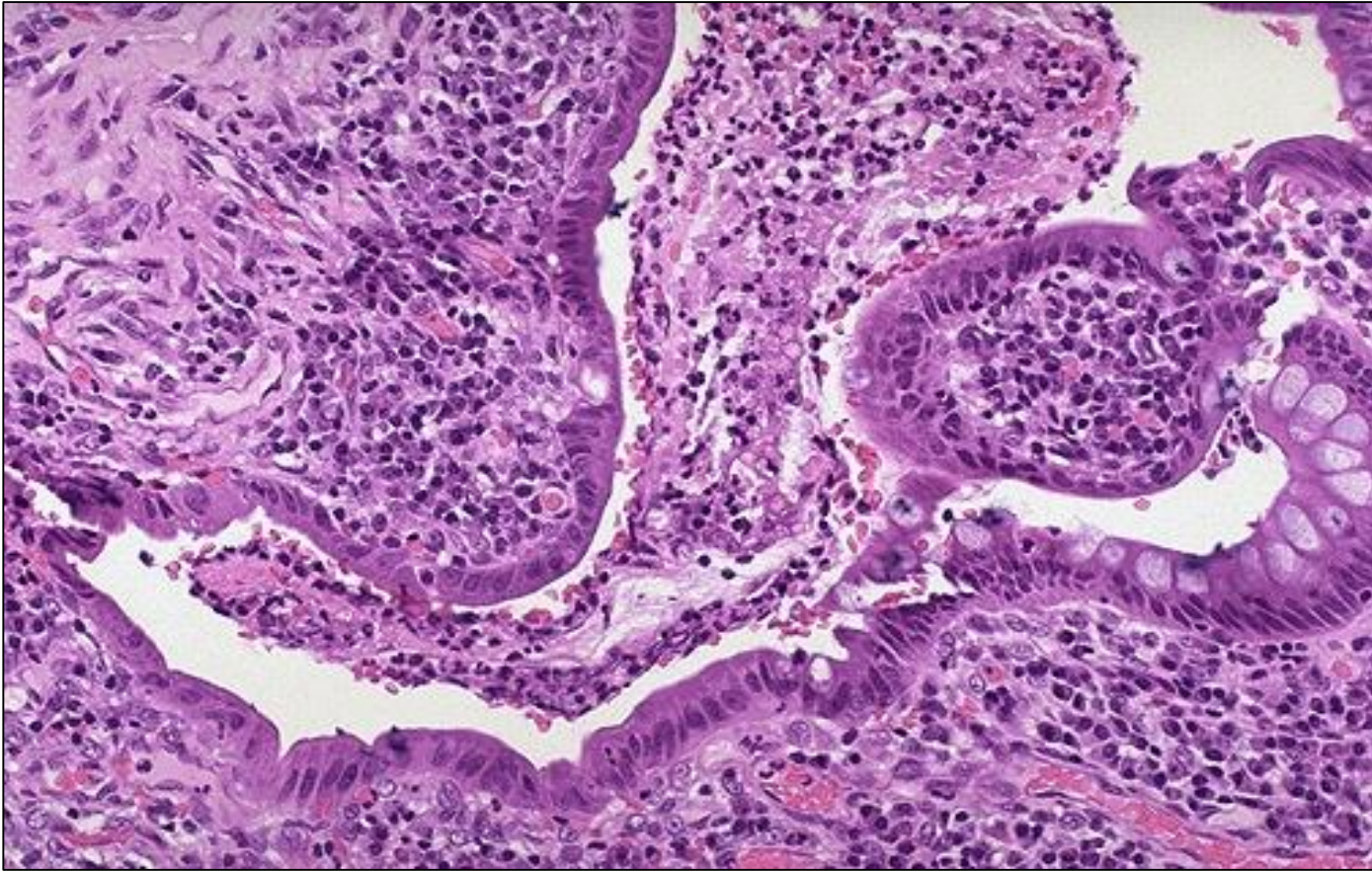
Microscopically, the inflammation of ulcerative colitis is confined primarily to the mucosa. Here, the mucosa is eroded by an ulcer that undermines surrounding mucosa.

Ulcerative Colitis with Crypt Abscesses - MPF



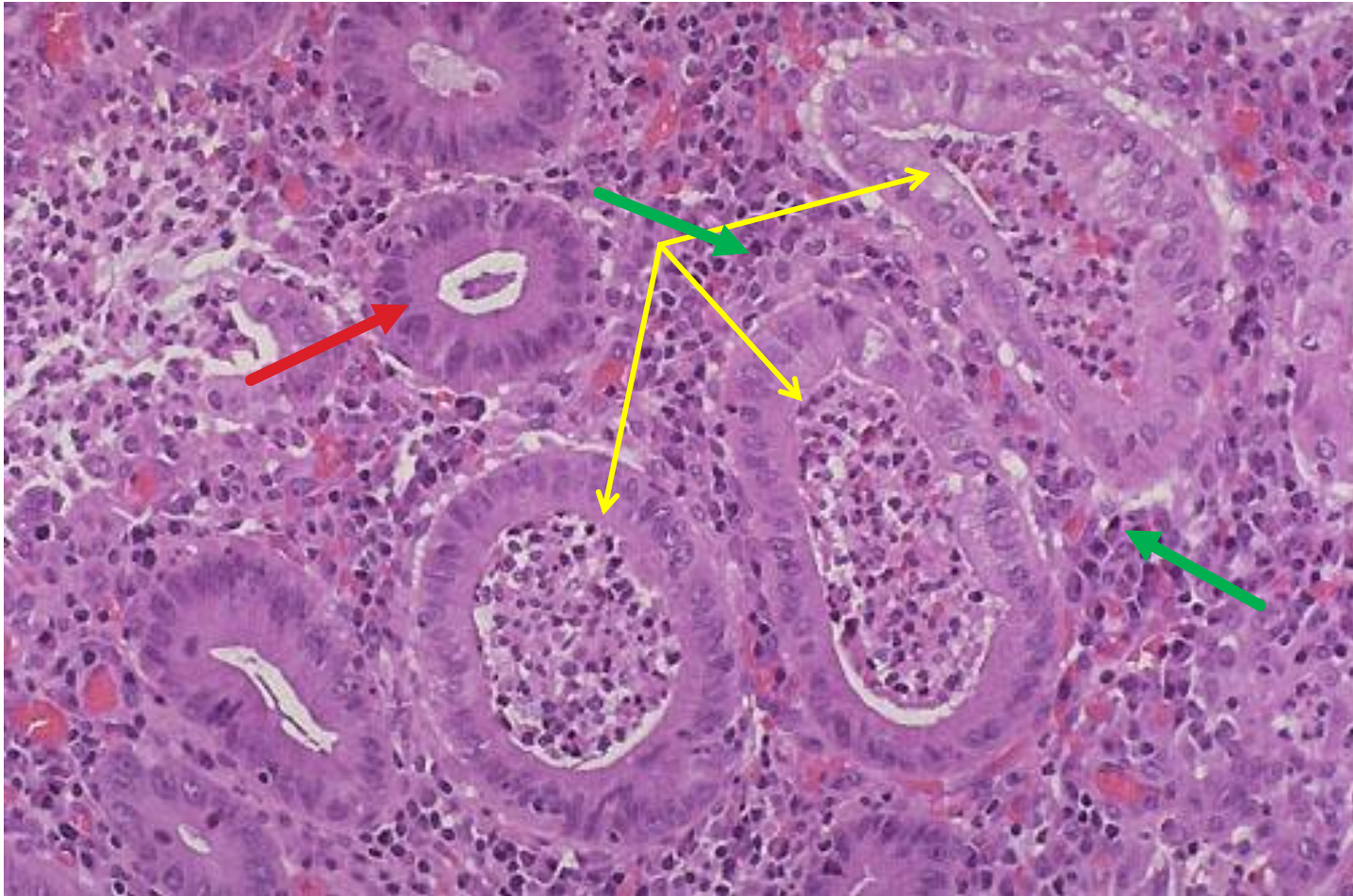
The colonic mucosa of active ulcerative colitis shows "crypt abscesses" in which a neutrophilic exudate is found in glandular lumens. The submucosa shows intense inflammation. The glands demonstrate loss of goblet cells and hyperchromatic nuclei with inflammatory atypia.

Chronic Ulcerative Colitis - HPF



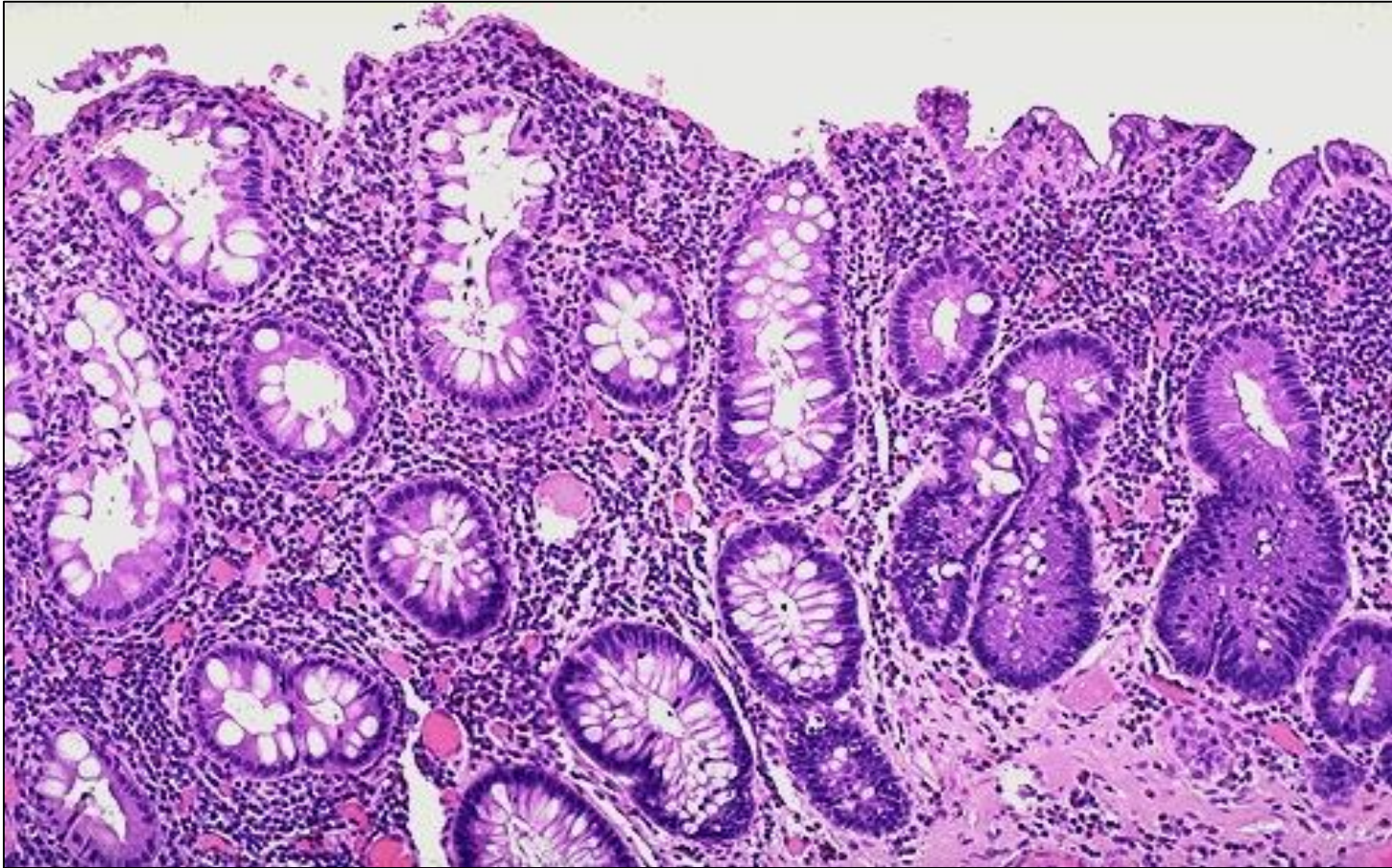At higher magnification, the intense inflammation of the mucosa is seen. The colonic mucosal epithelium demonstrates loss of goblet cells. An exudate is present over the surface. Both acute and chronic inflammatory cells are present

Ulcerative Colitis with Crypt Abscesses - HPF

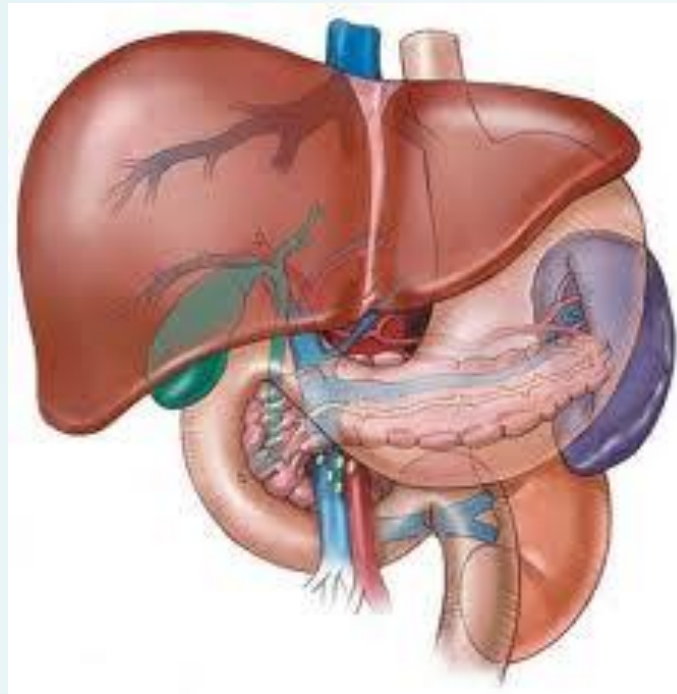


Crypt abscesses (neutrophilic exudate is found in glandular lumens) are a histologic finding more typical with ulcerative colitis. The submucosa shows intense inflammation with **plasma cells**. The glands show **depletion of goblet cells**.

Chronic Ulcerative Colitis with Dysplasia- MPF



Over time, there is a risk for adenocarcinoma with ulcerative colitis. Here, more normal glands are seen at the left, but the glands at the right demonstrate dysplasia, the first indication that there is a move towards neoplasia.



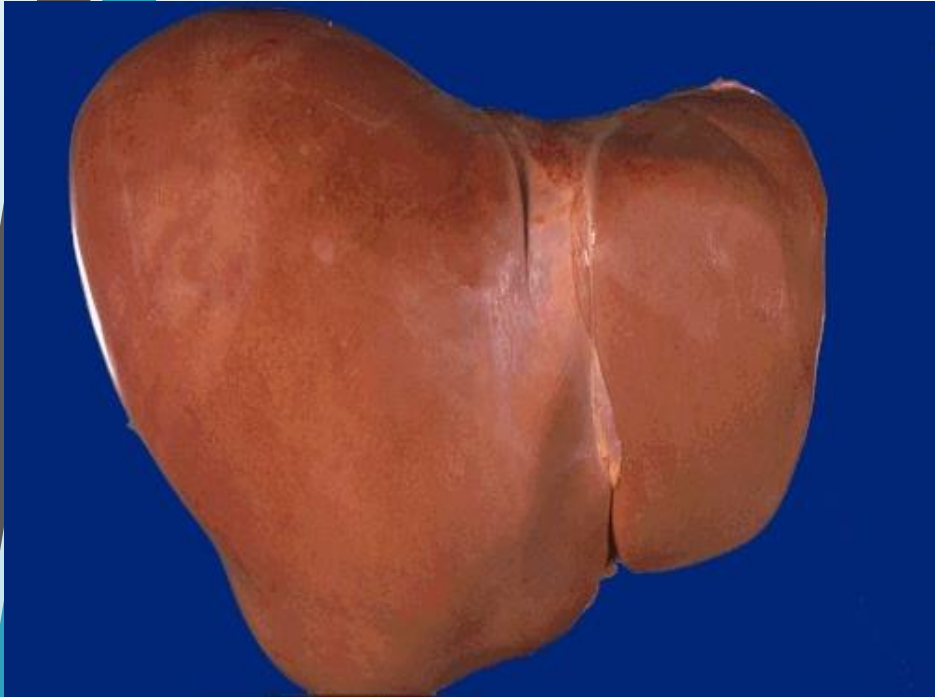
Hepatobiliary system



Normal anatomy and histology

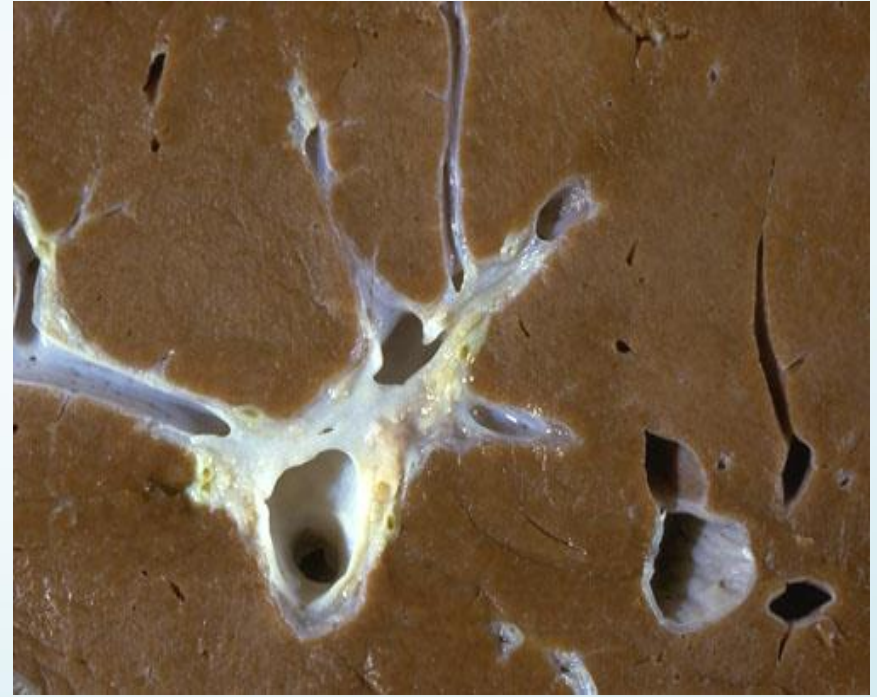Normal Liver anatomy - Gross & Cut surface

External surface

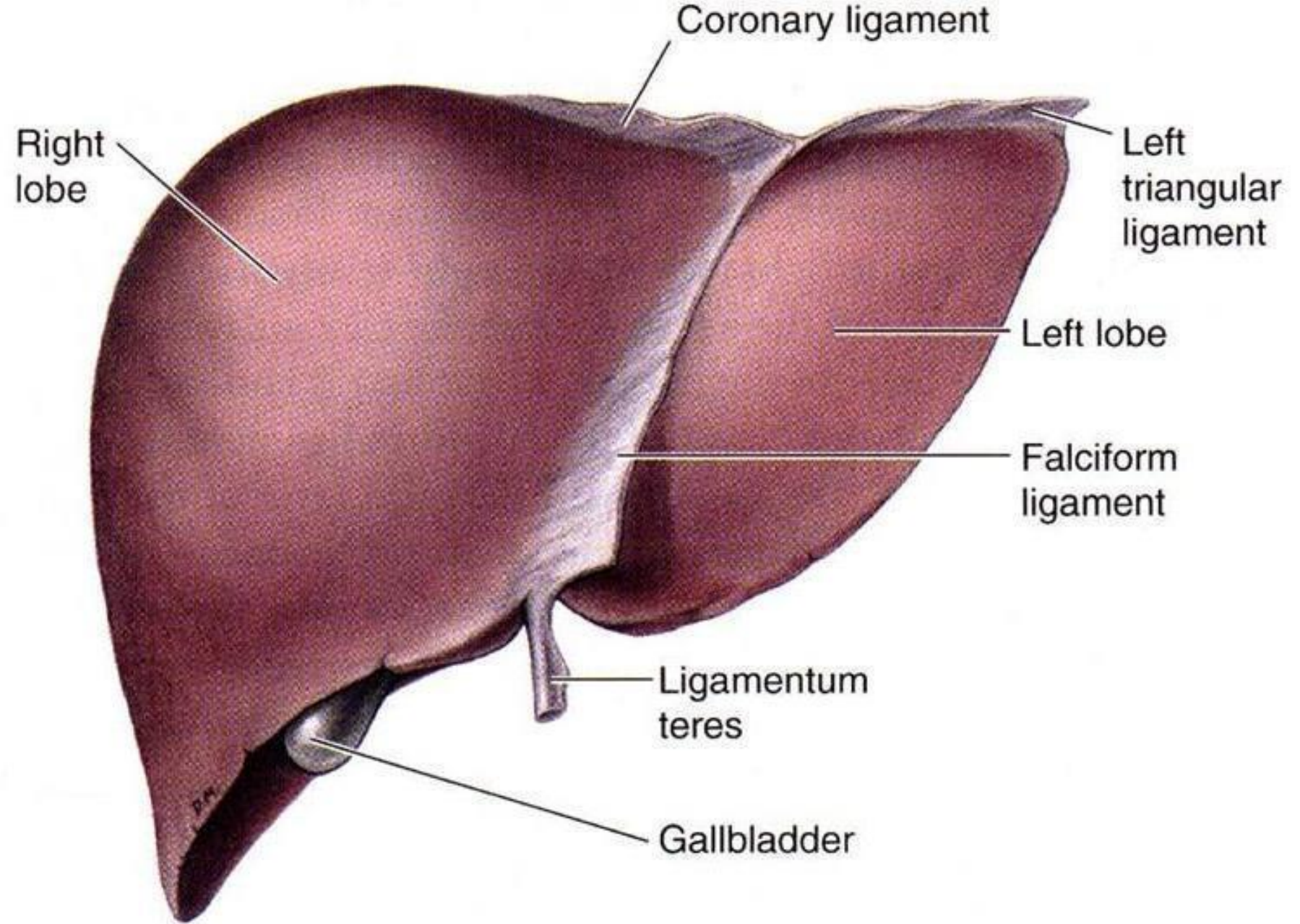


This is the external surface of a normal liver. The color is brown and the surface is smooth. A normal liver is about 1200 to 1600 grams.

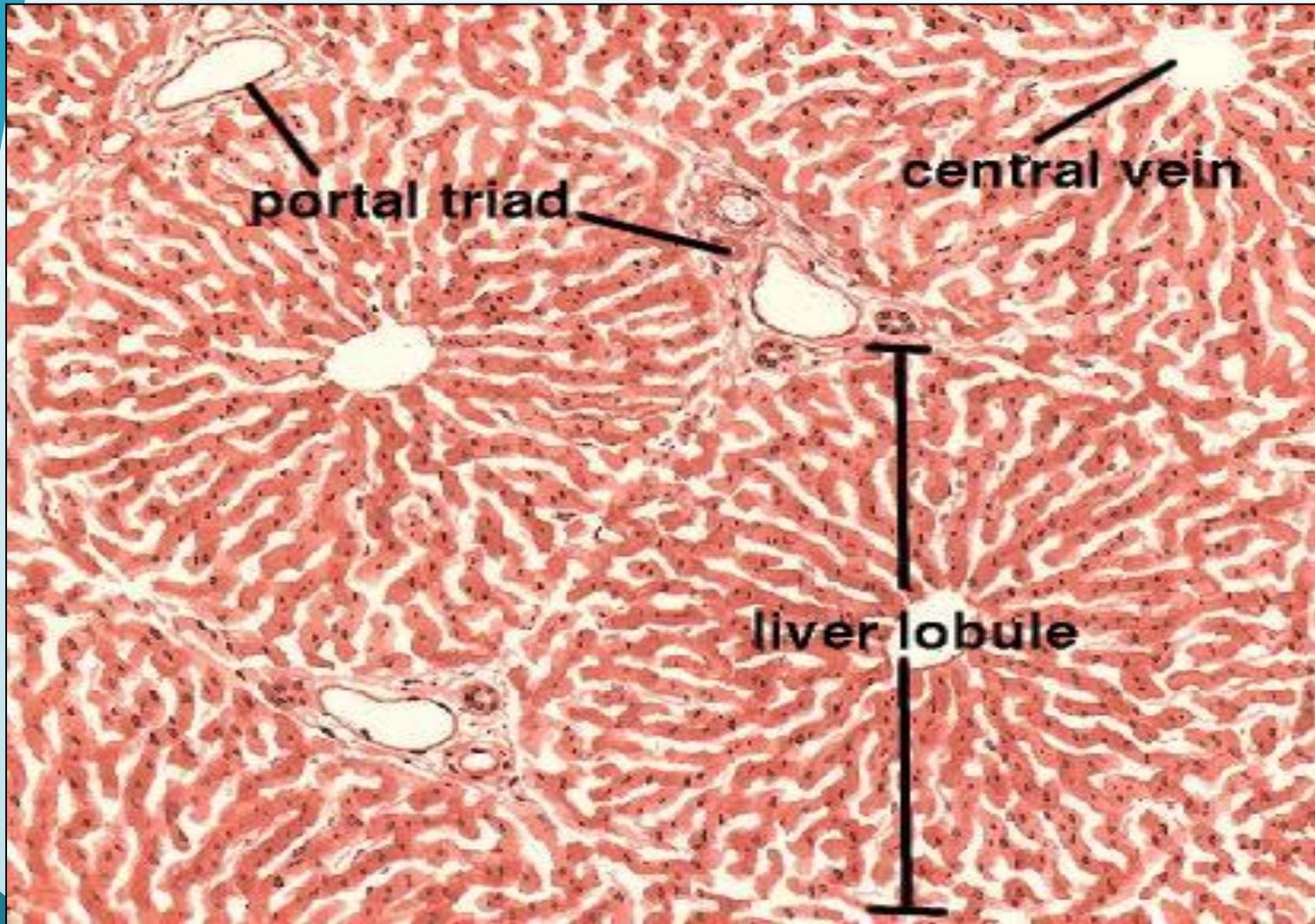
Cut surface



Near the hilum, note the portal vein, which branches at center left, with accompanying hepatic artery and bile ducts. At the lower right is a branch of hepatic vein

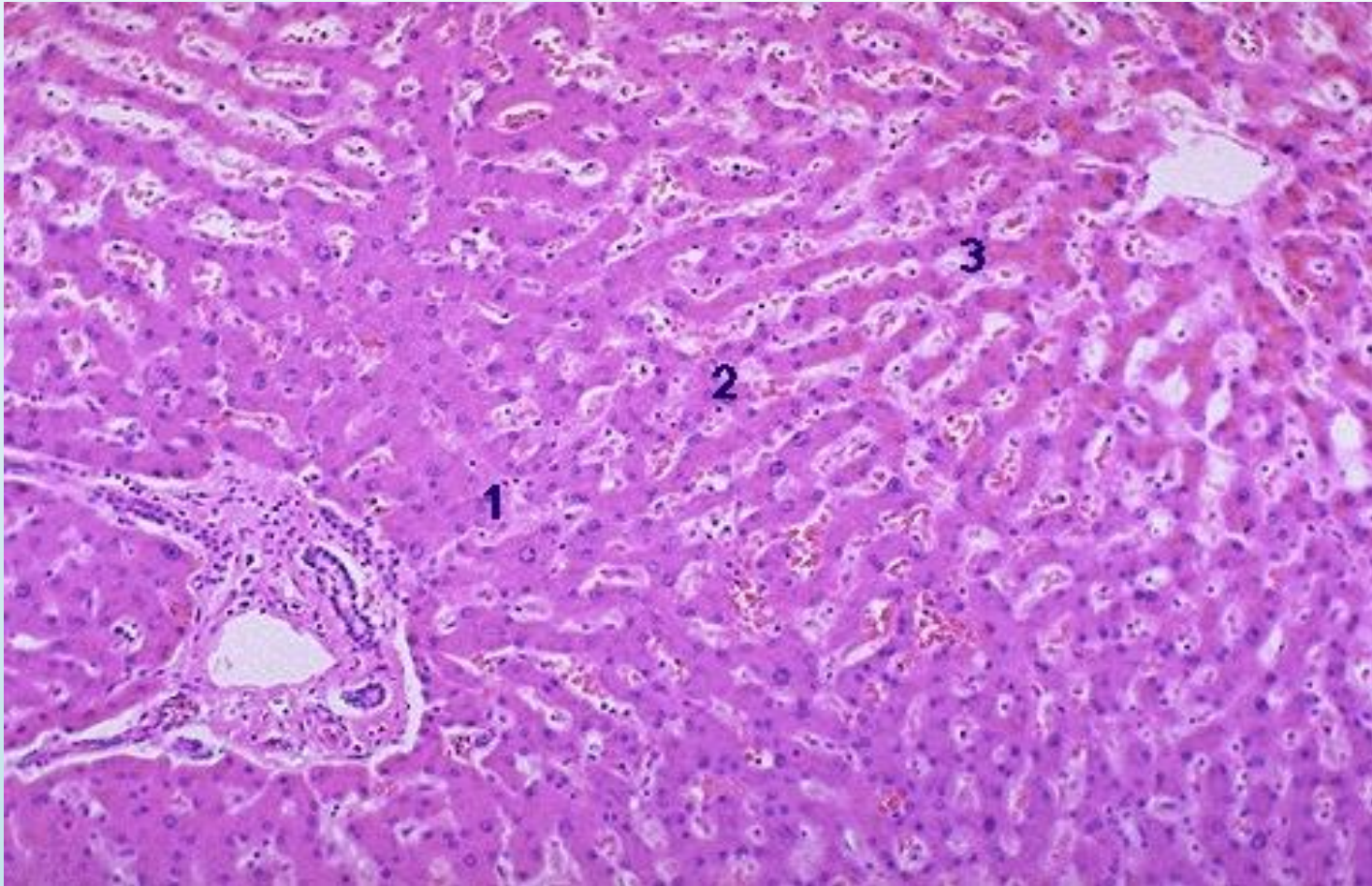


Normal Liver Histology - Gross



The classical view of liver tissue from a liver biopsy, H&E stained

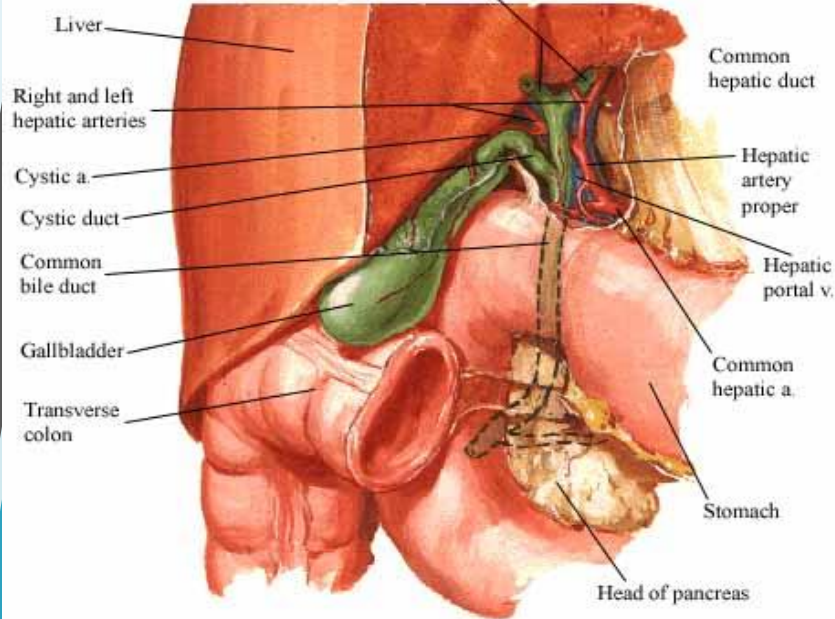
Normal Liver Histology



Liver is divided histologically into lobules. The center of the lobule is the central vein. At the periphery of the lobule are portal triads. Functionally, the liver can be divided into three zones, based upon oxygen supply.

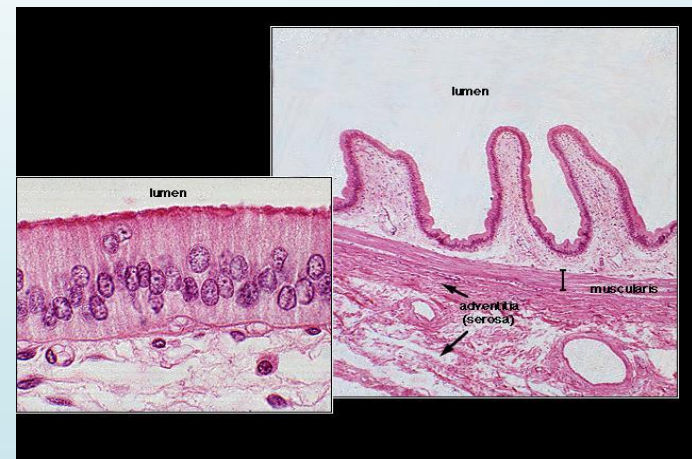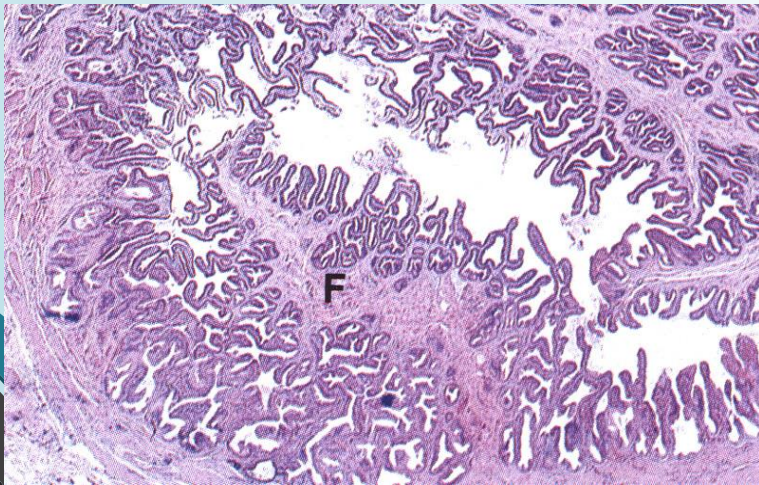
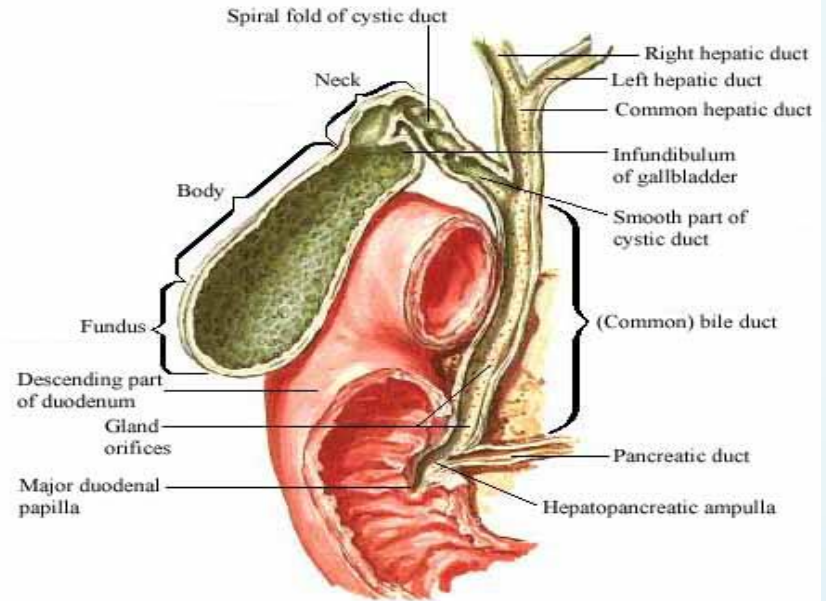
Gallbladder and Extrahepatic Bile Ducts

Right and left hepatic ducts



Gallbladder and Extrahepatic Bile Ducts

Sectioned



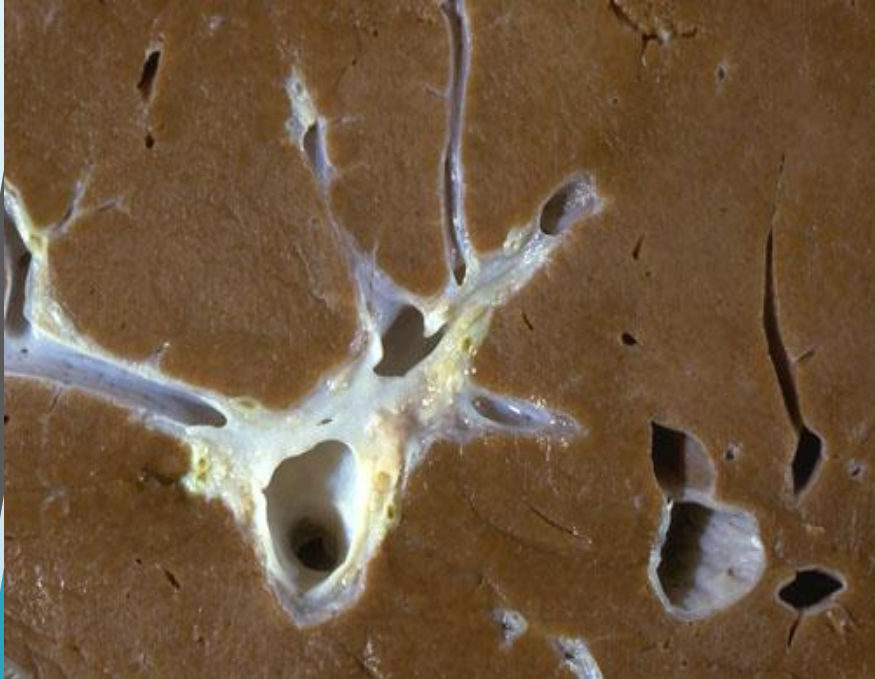


Gross and histopathology

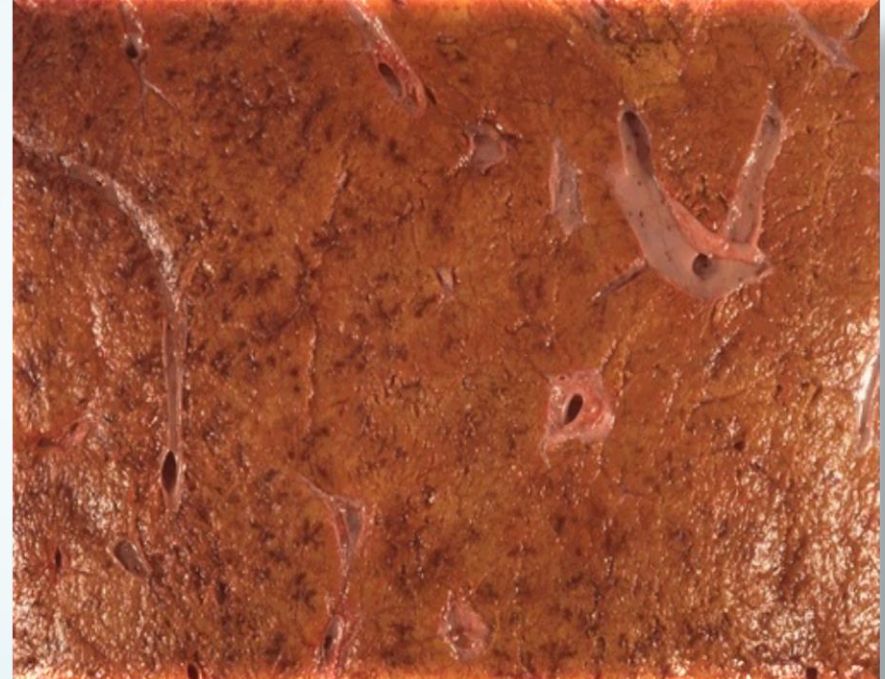

Chronic VIRAL hepatitis (HBV & HCV)

Cut Section of Normal Liver & Ch. Hepatitis

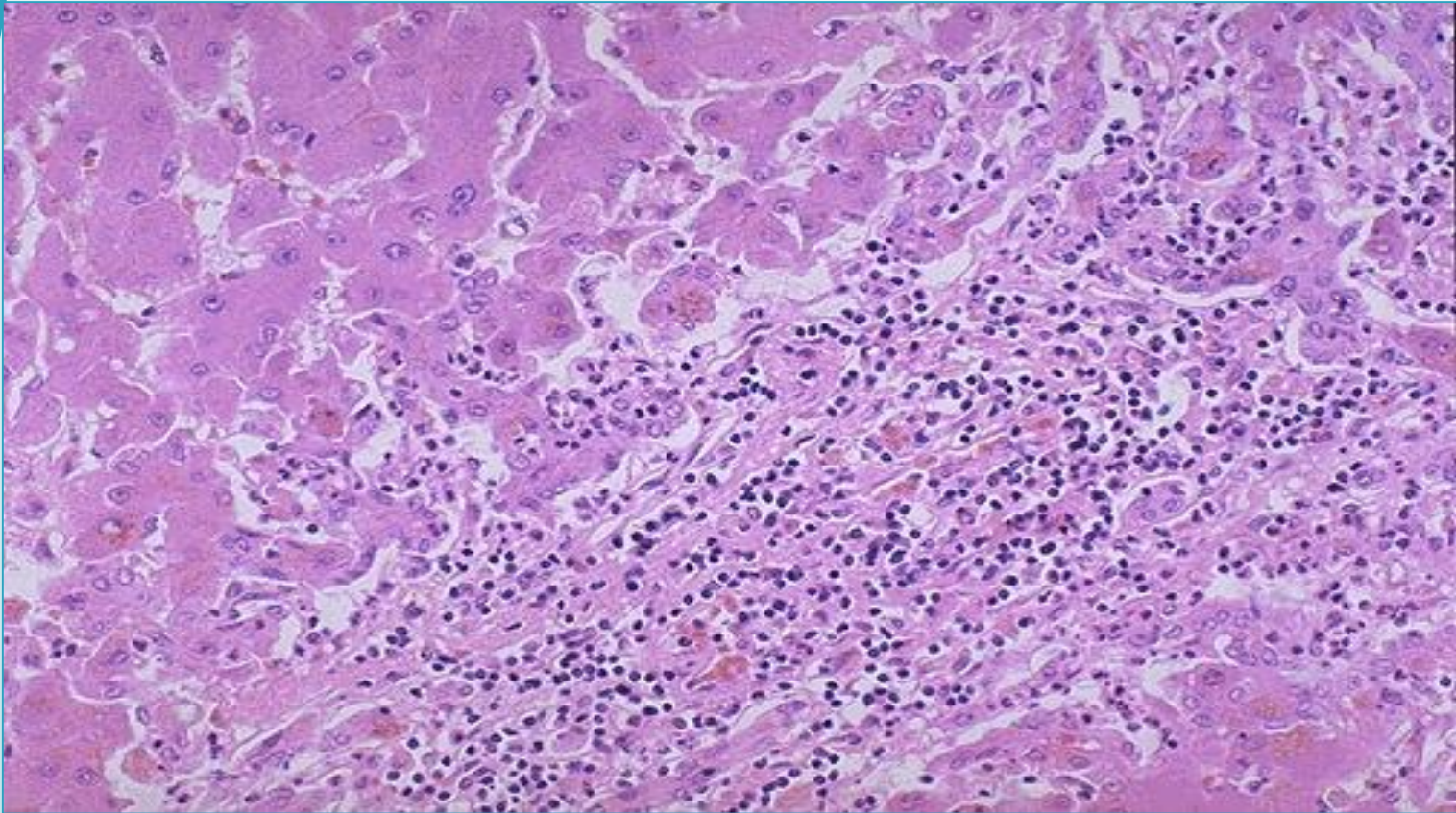


Normal Liver: has a brown color. Near the hilum here, note the portal vein carrying blood to the liver, which branches at center left, with accompanying hepatic artery and bile ducts. At the lower right is a branch of hepatic vein draining blood from the liver to the inferior vena cava.



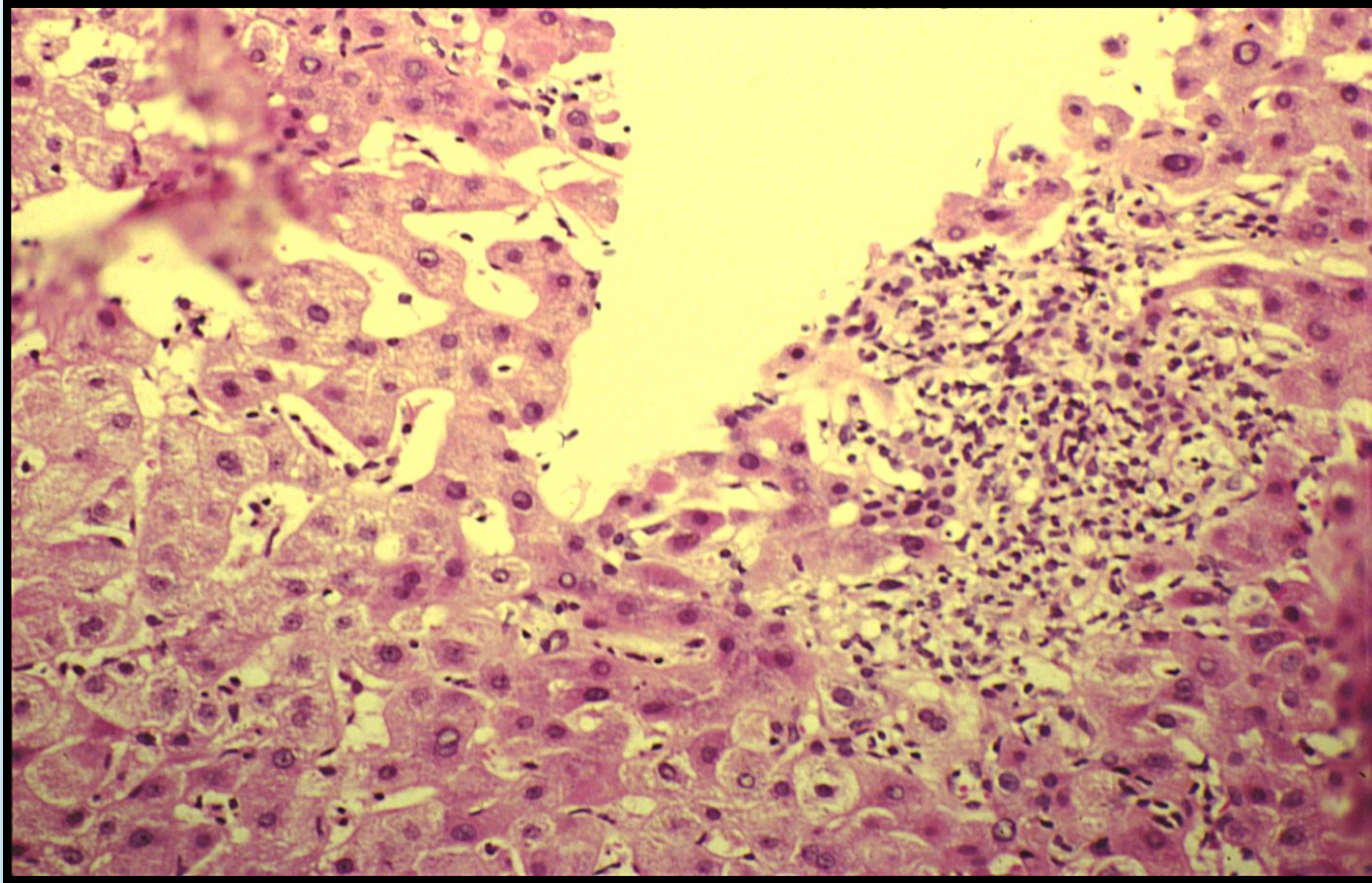
Chronic Hepatitis: The necrosis and lobular collapse is seen here as areas of hemorrhage and irregular furrows and granularity on the cut surface of the liver.

Chronic Viral Hepatitis B – Microscopic view



Viral hepatitis leads to liver cell destruction. A mononuclear inflammatory cell infiltrate extends from portal areas and disrupts the limiting plate of hepatocytes which are undergoing necrosis, the so-called "piecemeal" necrosis of chronic active hepatitis. In this case, the hepatitis B surface antigen (HBsAg) and hepatitis B core antibody (HBcAb) were positive.

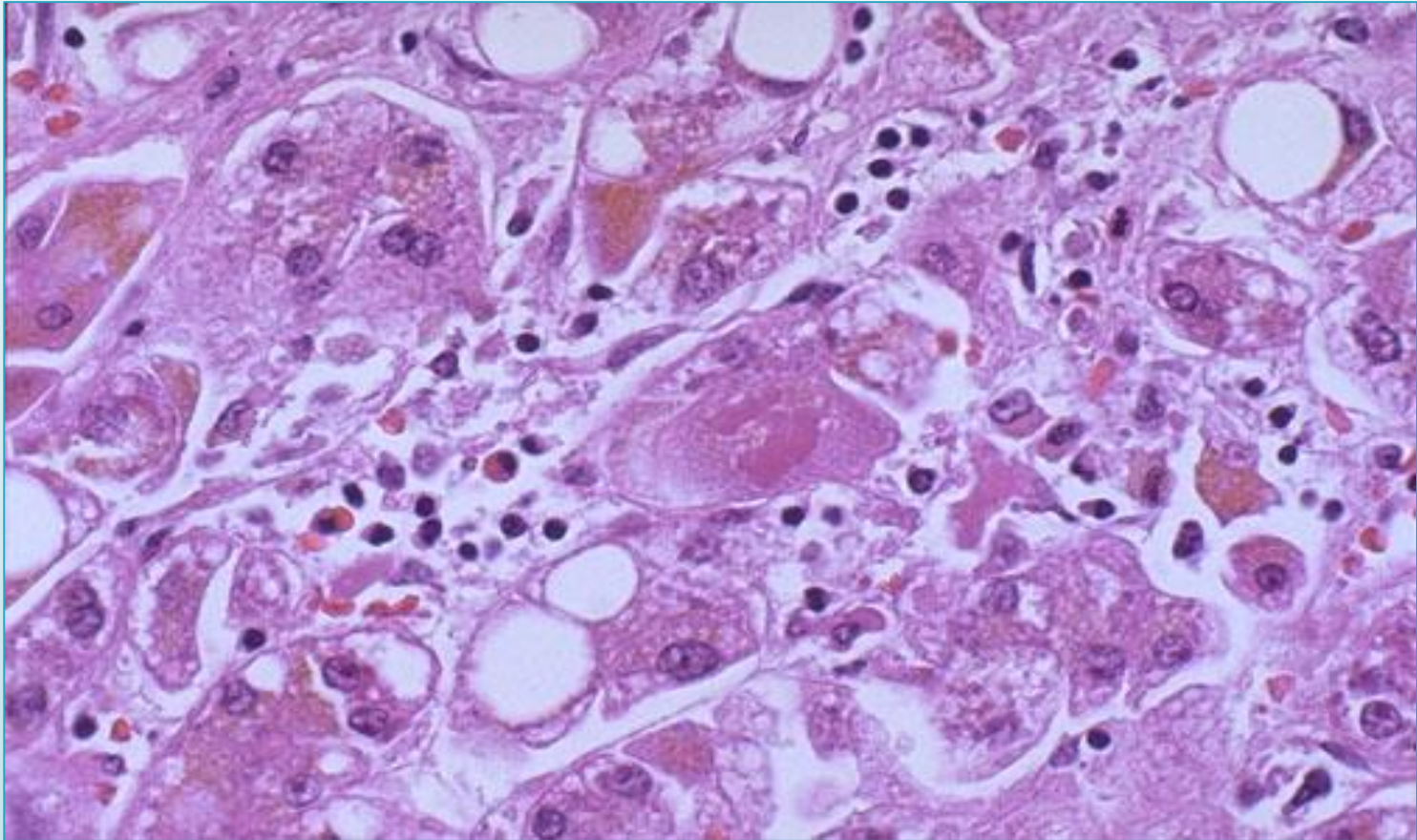
Chronic Viral Hepatitis B – HPF



Moderate chronic inflammatory cells infiltration consisting of lymphocytes and histiocytes in both portal tracts and liver parenchyma. Piecemeal necrosis, hepatocytes swelling and "spotty" hepatocytes necrosis are also noticed.

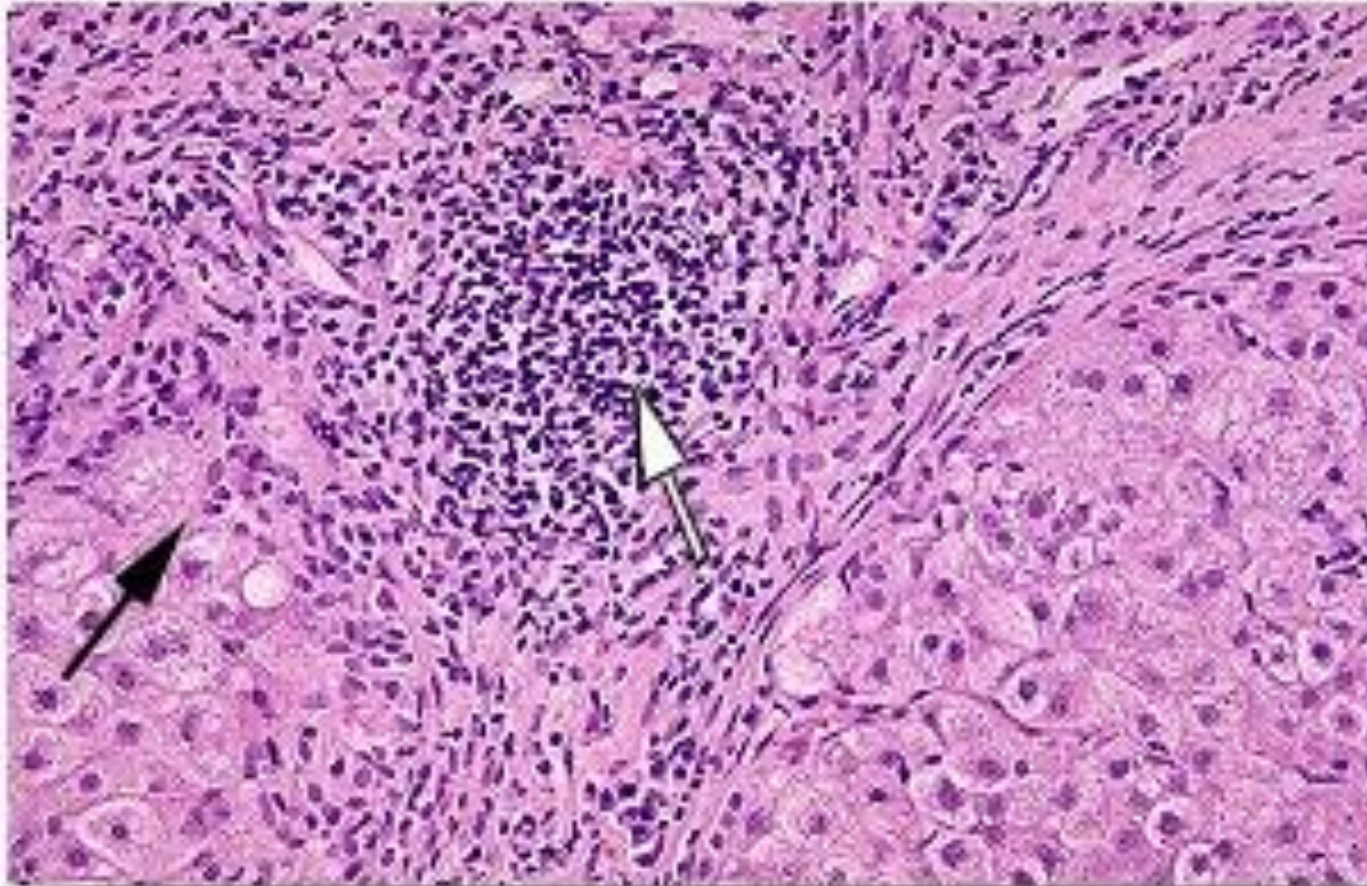
No evidence of cirrhosis or malignancy noted

Chronic Viral Hepatitis C – HPF



This is a case of viral hepatitis C, which in half of cases leads to chronic liver disease. The extent of chronic hepatitis can be graded by the degree of activity (necrosis and inflammation) and staged by the degree of fibrosis. In this case, necrosis and inflammation are prominent, and there is some steatosis as well.

Portal Inflammation in Chronic Hepatitis - HPF

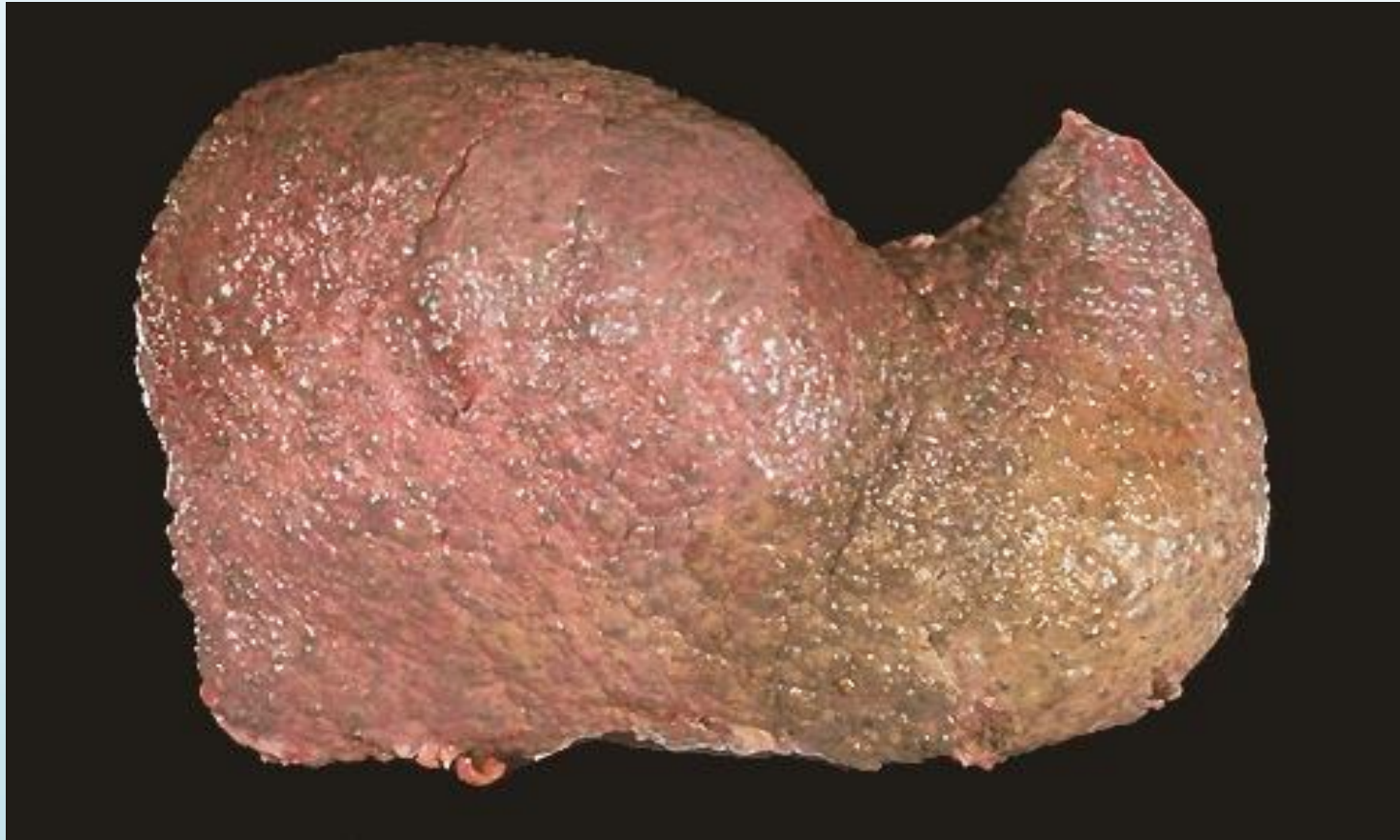

More severe portal infiltrates with sinusoidal infiltrates also



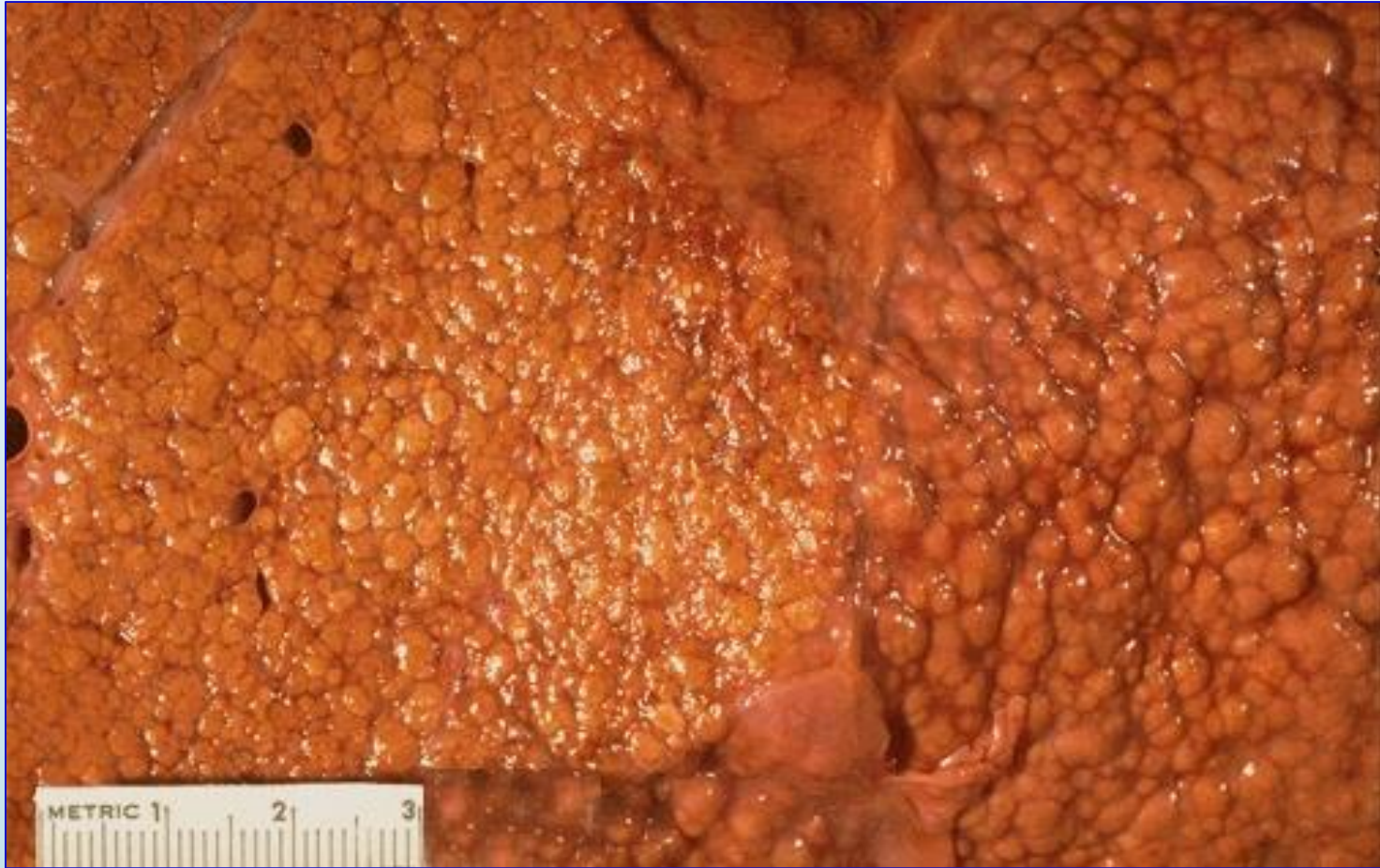Hepatic cirrhosis

Micronodular Hepatic Cirrhosis - MRI



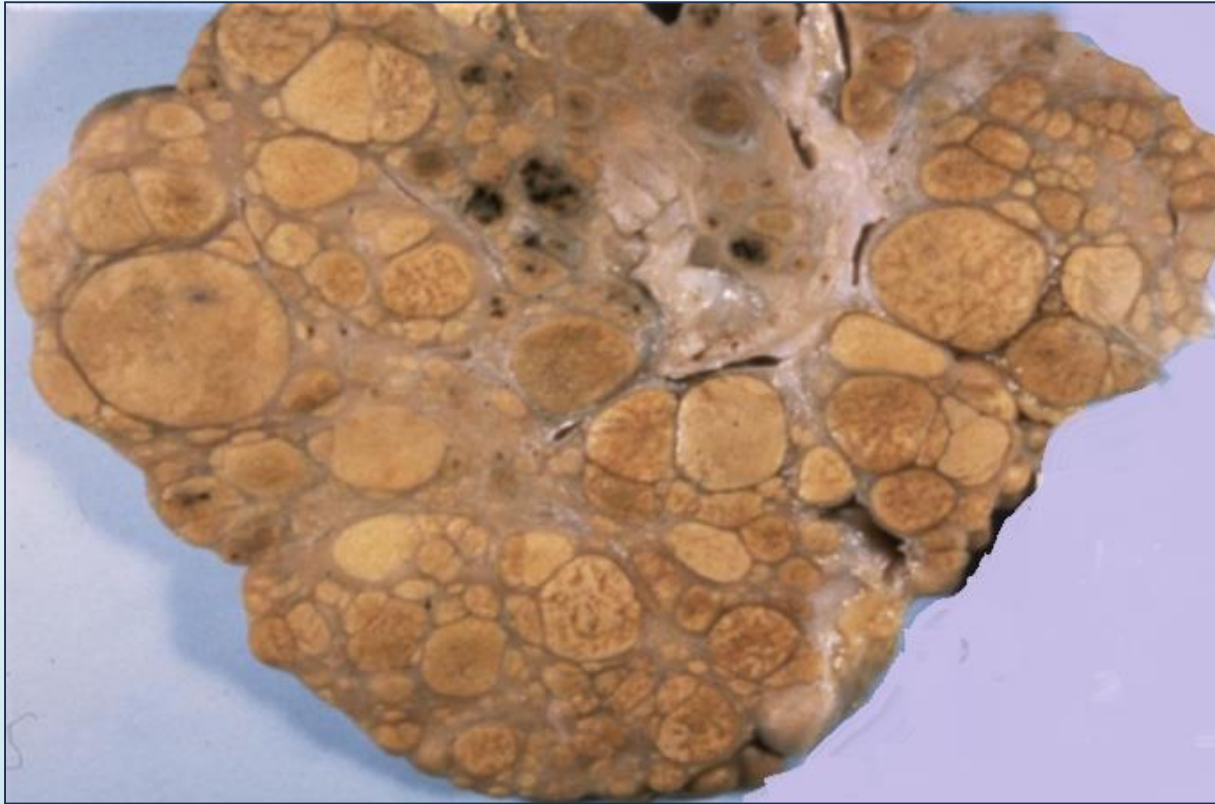
This is an example of a micronodular cirrhosis. The regenerative nodules are quite small, averaging less than 3 mm in size. The most common cause for this is chronic alcoholism. The process of cirrhosis develops over many years.

Micronodular cirrhosis with fatty liver- Gross



A close-up view of a micronodular cirrhosis in a liver with fatty change demonstrates the small, yellow nodules. Micronodular cirrhosis may also be seen with Wilson's disease, primary biliary cirrhosis, and hemochromatosis.

Hepatic Macronodular Cirrhosis – Gross

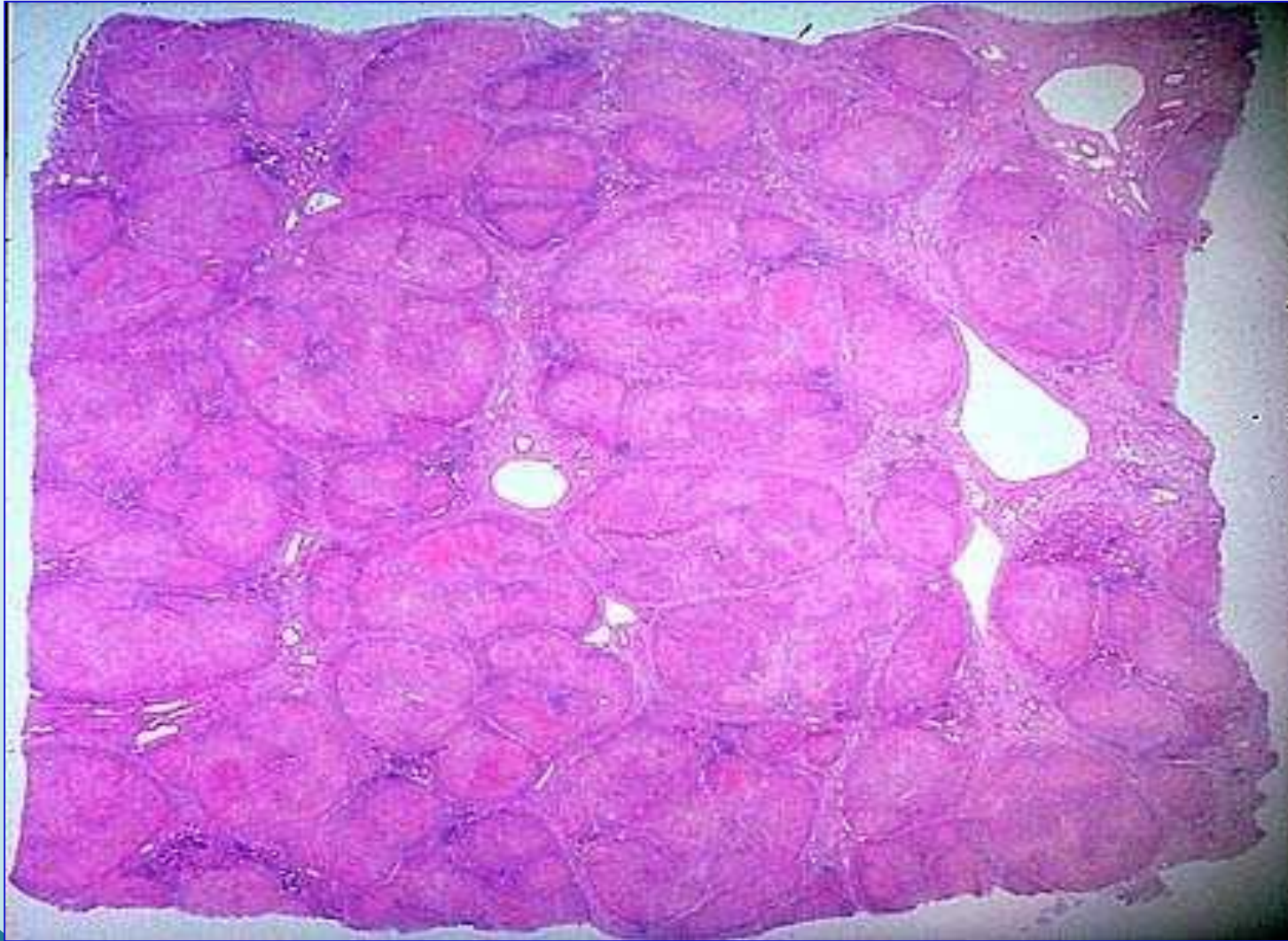


Gross picture shows multiple nodules of variable sizes with fibrosis.

Complications:

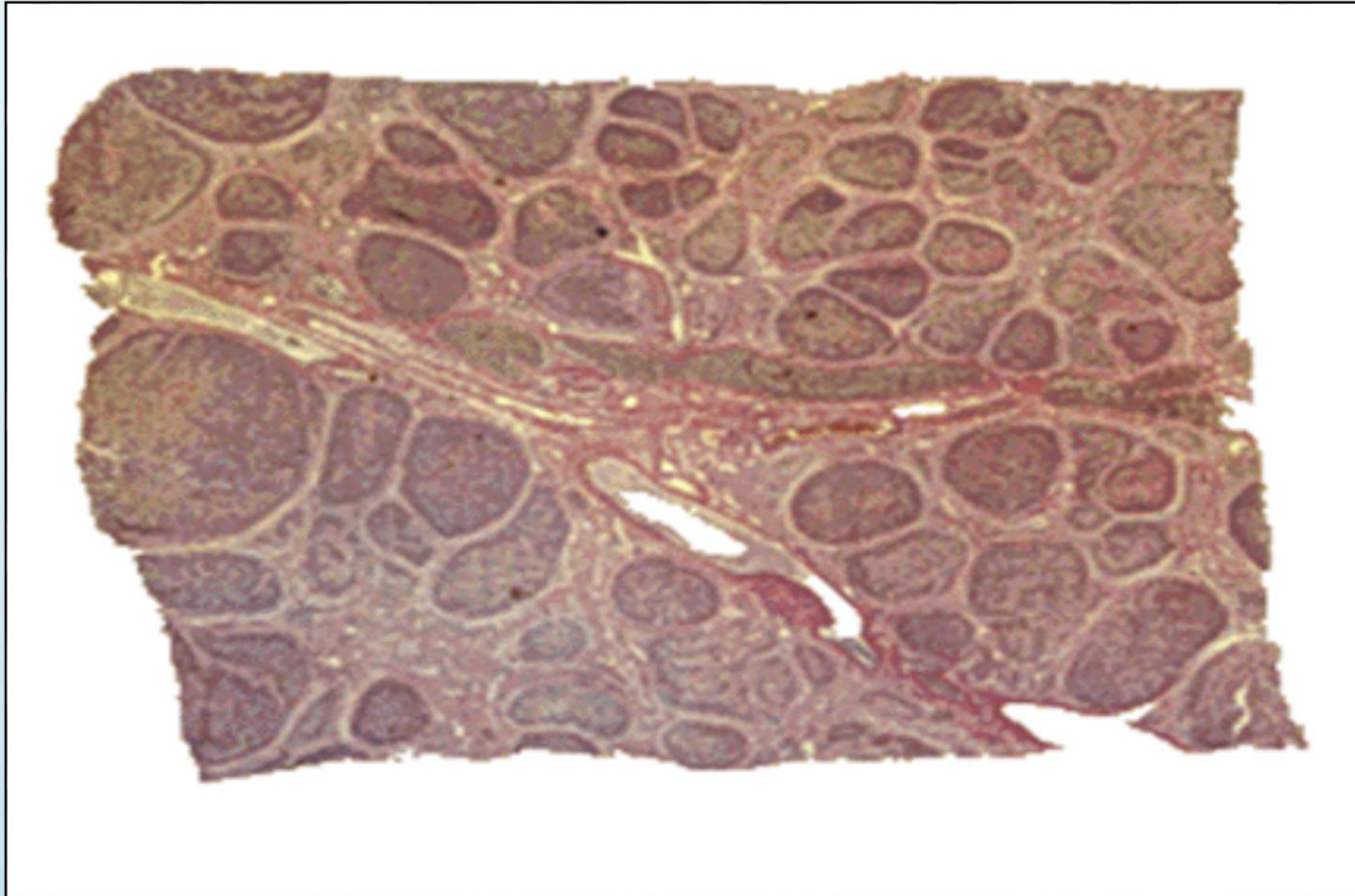
- Portal hypertension
- Oesophageal varices
- Hepatic failure
- Liver cell dysplasia and carcinoma
- Gynaecomastia

Hepatic cirrhosis – LPF



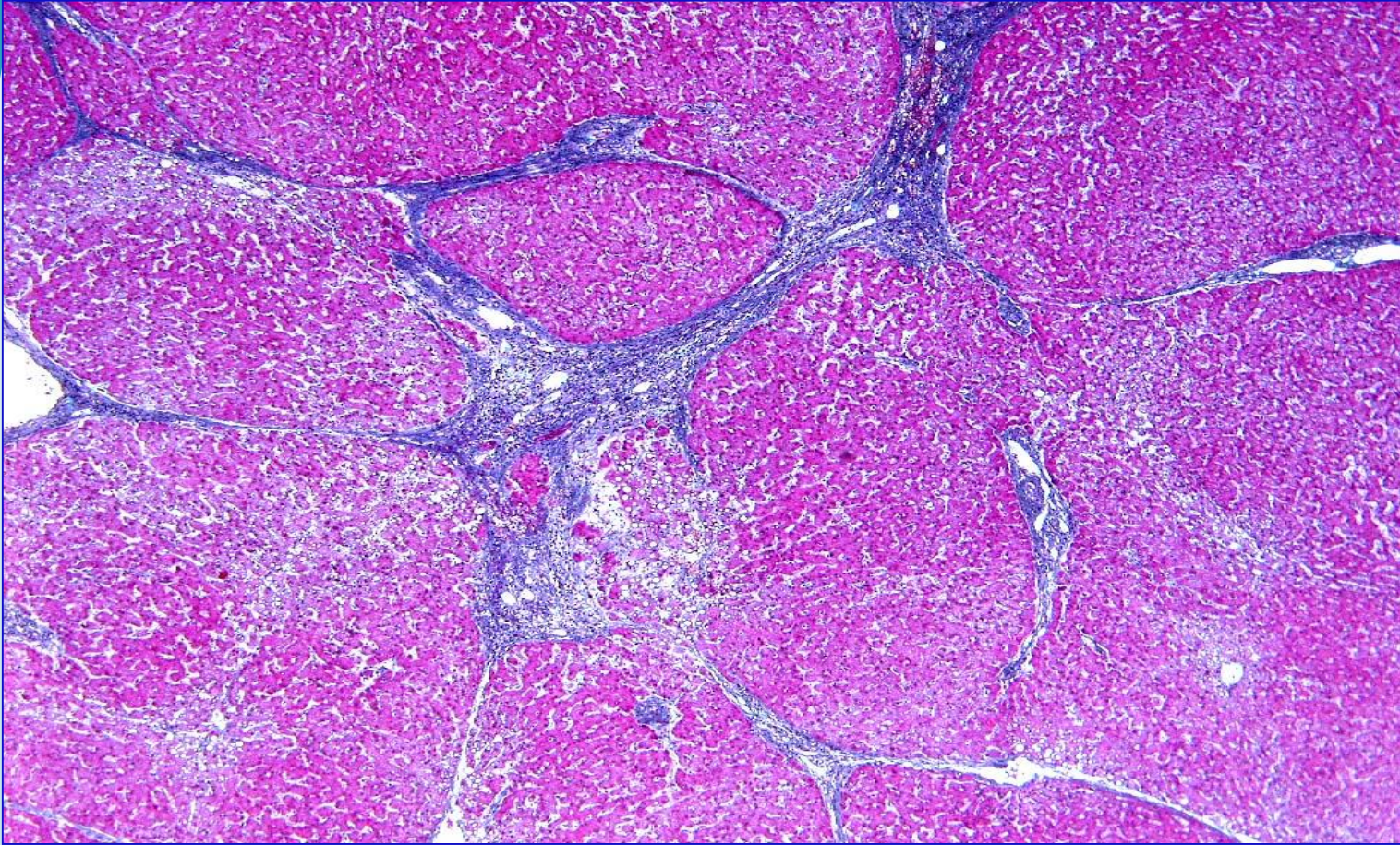
Irregular nodules separated by Portal to Portal fibrous bands

Hepatic cirrhosis – LPF



- *The parenchyma shows darker tan nodules of varying sizes.*
 - *These nodules are composed of hepatocytes.*
 - *The paler areas in between are collagen.*

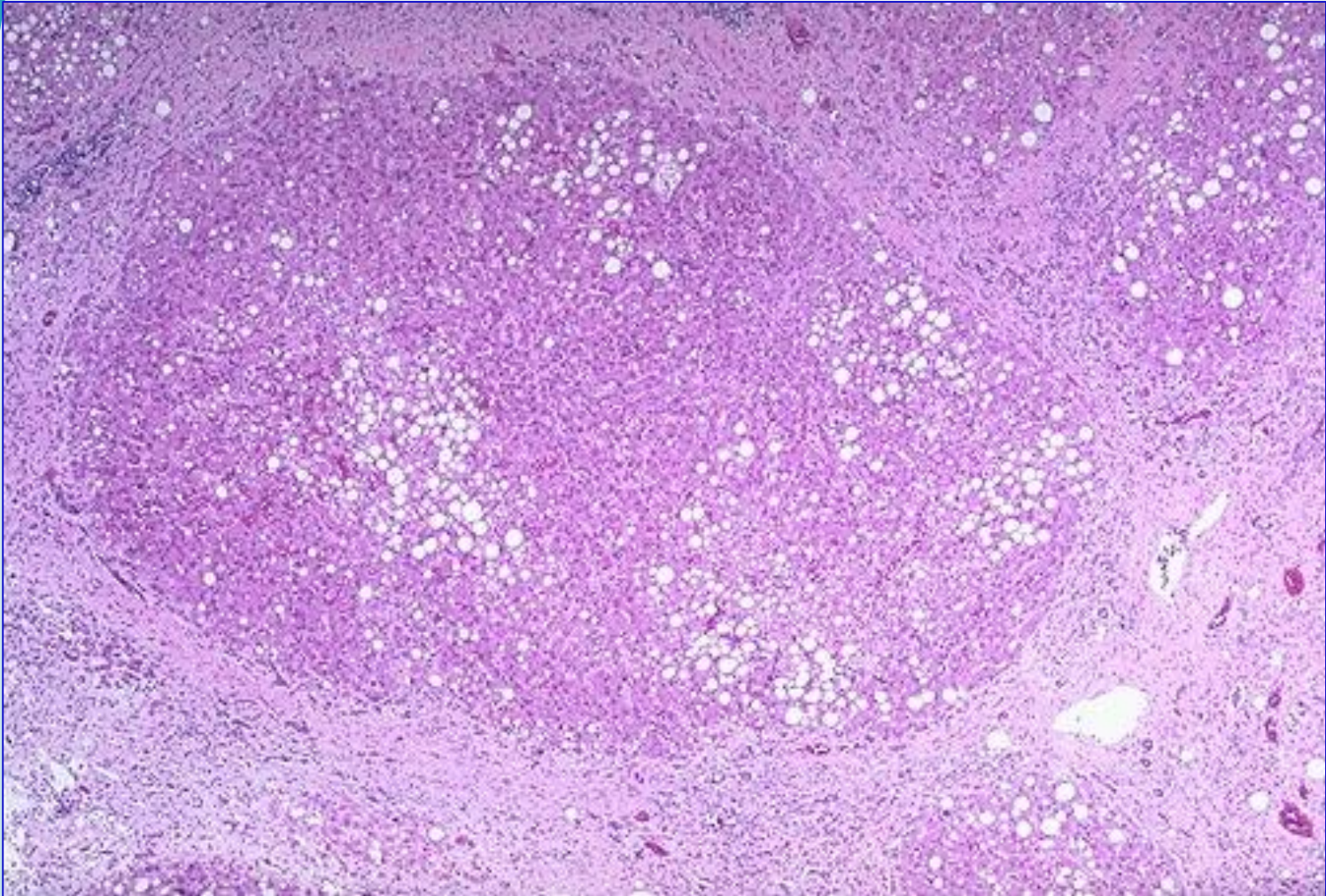
Cirrhosis – Masson trichrome stain



Loss of lobular architecture and formation of *regenerative hepatic nodules* of variable size and shape, surrounded by *fibrosis*.

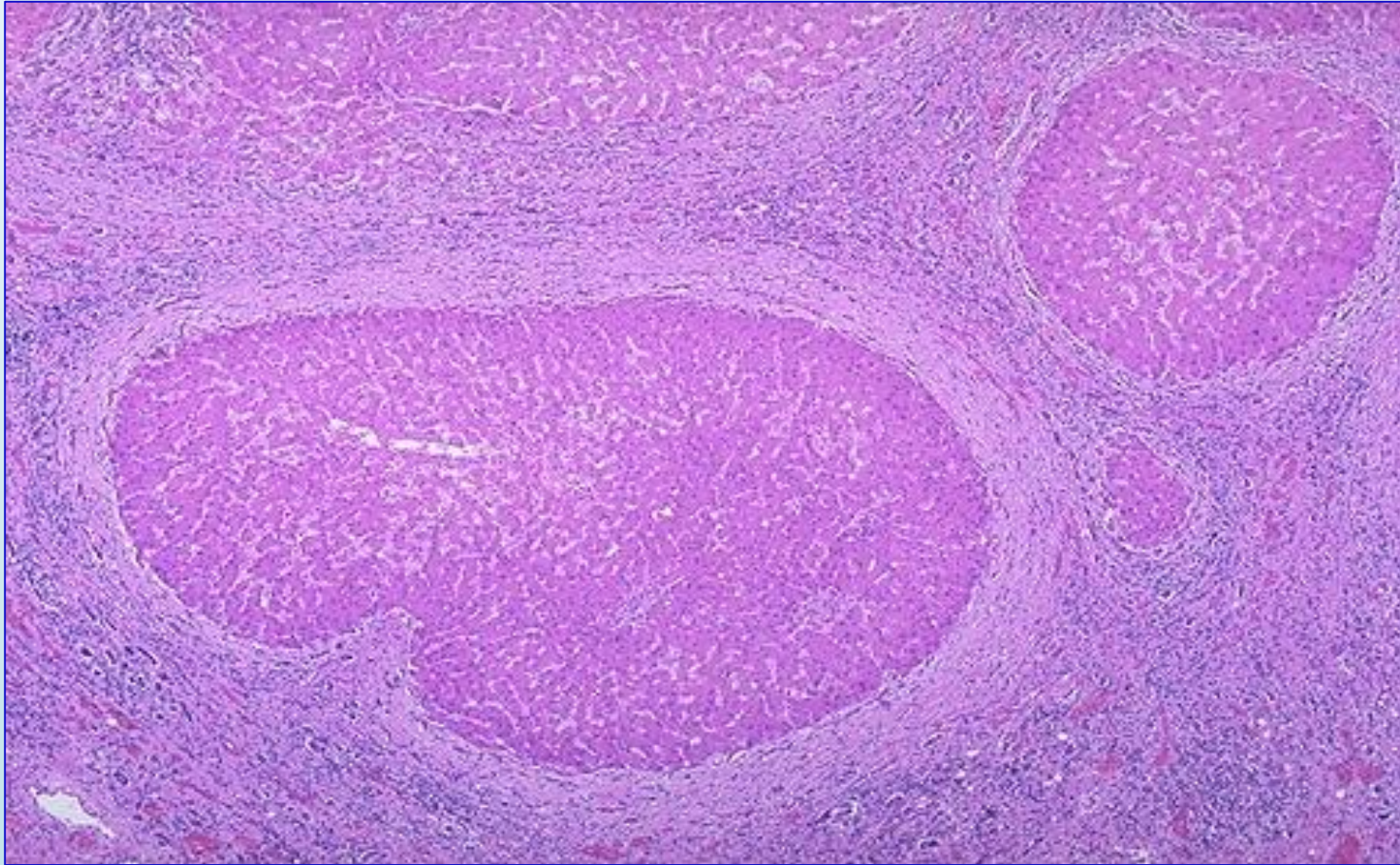
Each nodules consists of liver cells without any arrangement and with no central vein. Large number of proliferated bile ducts and chronic inflammatory cells are present in fibrous tissue.

Micronodular cirrhosis with fatty liver- LPF



Micronodular cirrhosis is seen along with moderate fatty change. Note the regenerative nodule surrounded by fibrous connective tissue extending between portal regions.

Hepatic cirrhosis – LPF

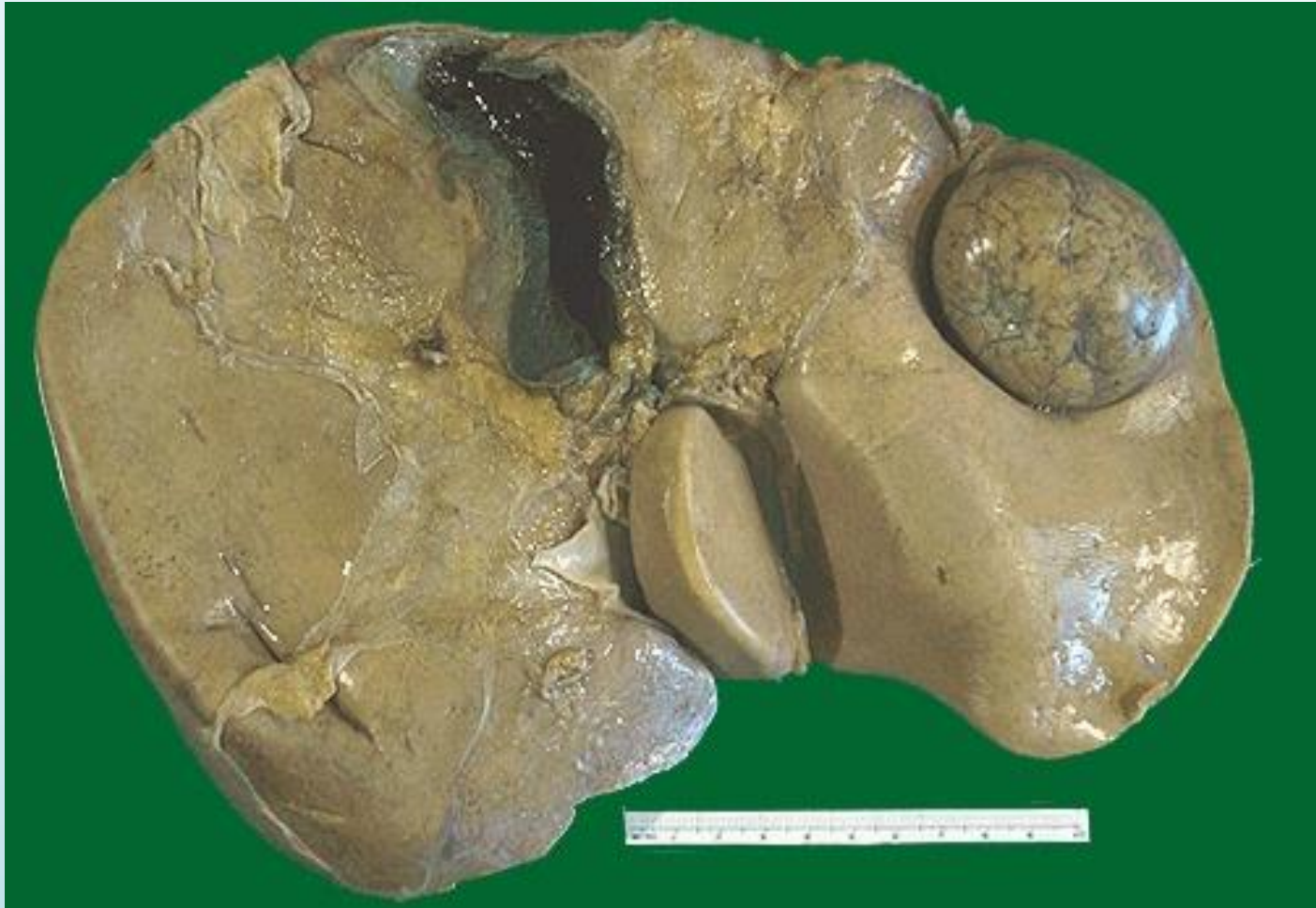

Microscopically with cirrhosis, the regenerative nodules of hepatocytes are surrounded by fibrous connective tissue that bridges between portal tracts. Within this collagenous tissue are scattered lymphocytes as well as a proliferation of bile ducts



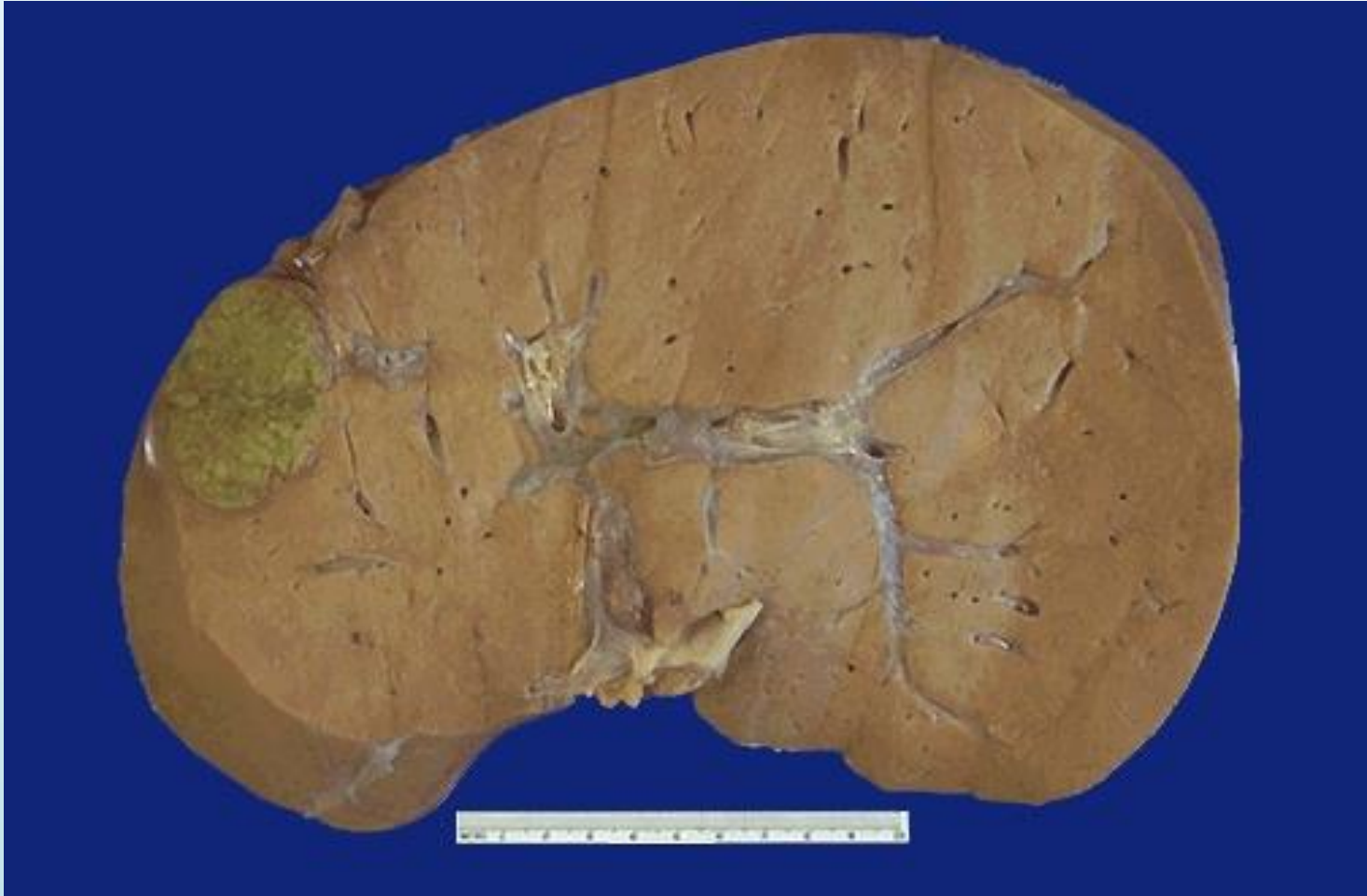HEPATIC ADENOMA

Hepatic Adenoma - Gross



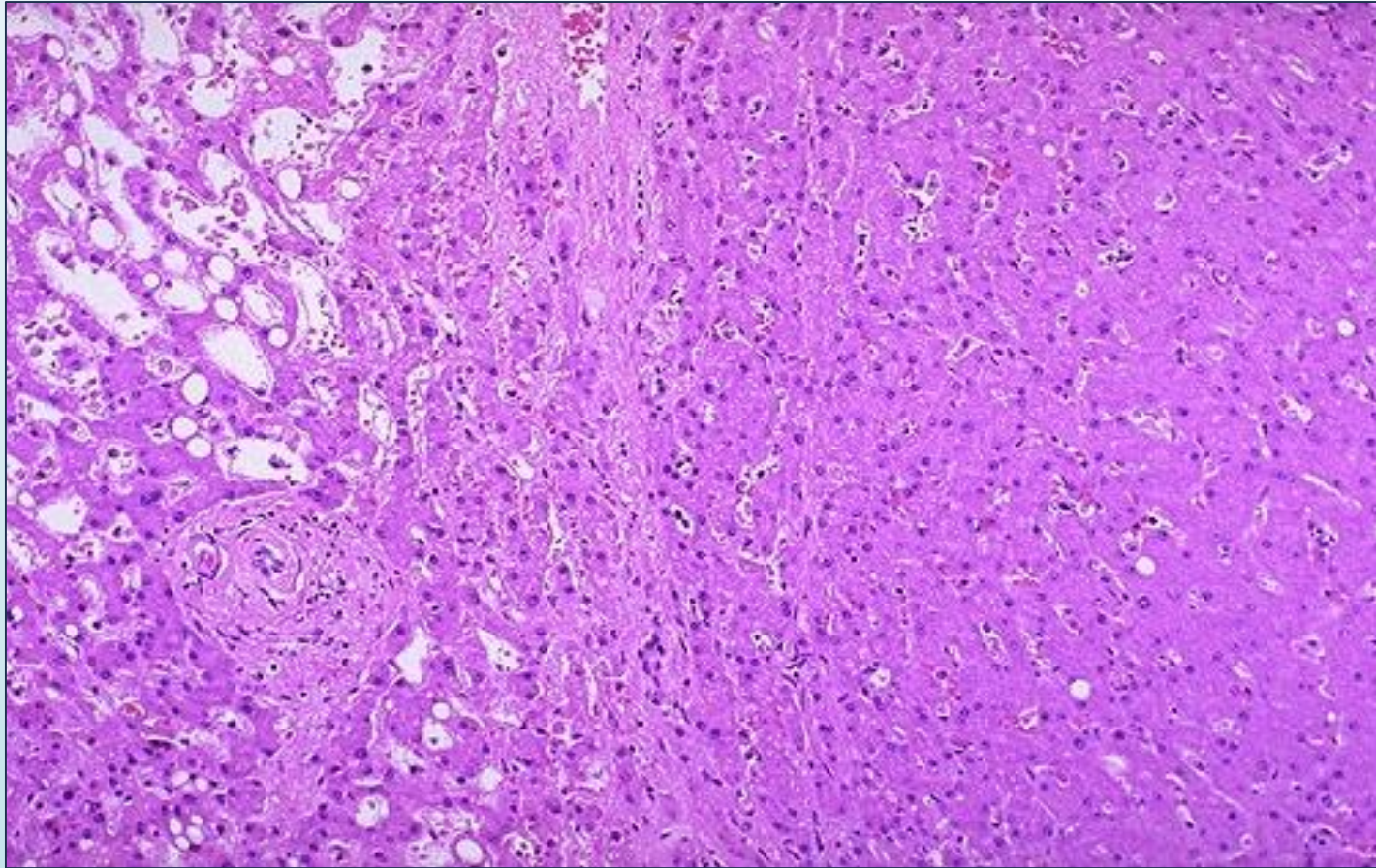
At the upper right is a well-circumscribed neoplasm that is arising in liver. This is an hepatic adenoma.

Hepatic Adenoma – Cut Section Gross



The cut surface of the liver reveals the hepatic adenoma. Note how well circumscribed it is. The remaining liver is a pale yellow brown because of fatty change from chronic alcoholism.

Hepatic Adenoma – Microscopic view

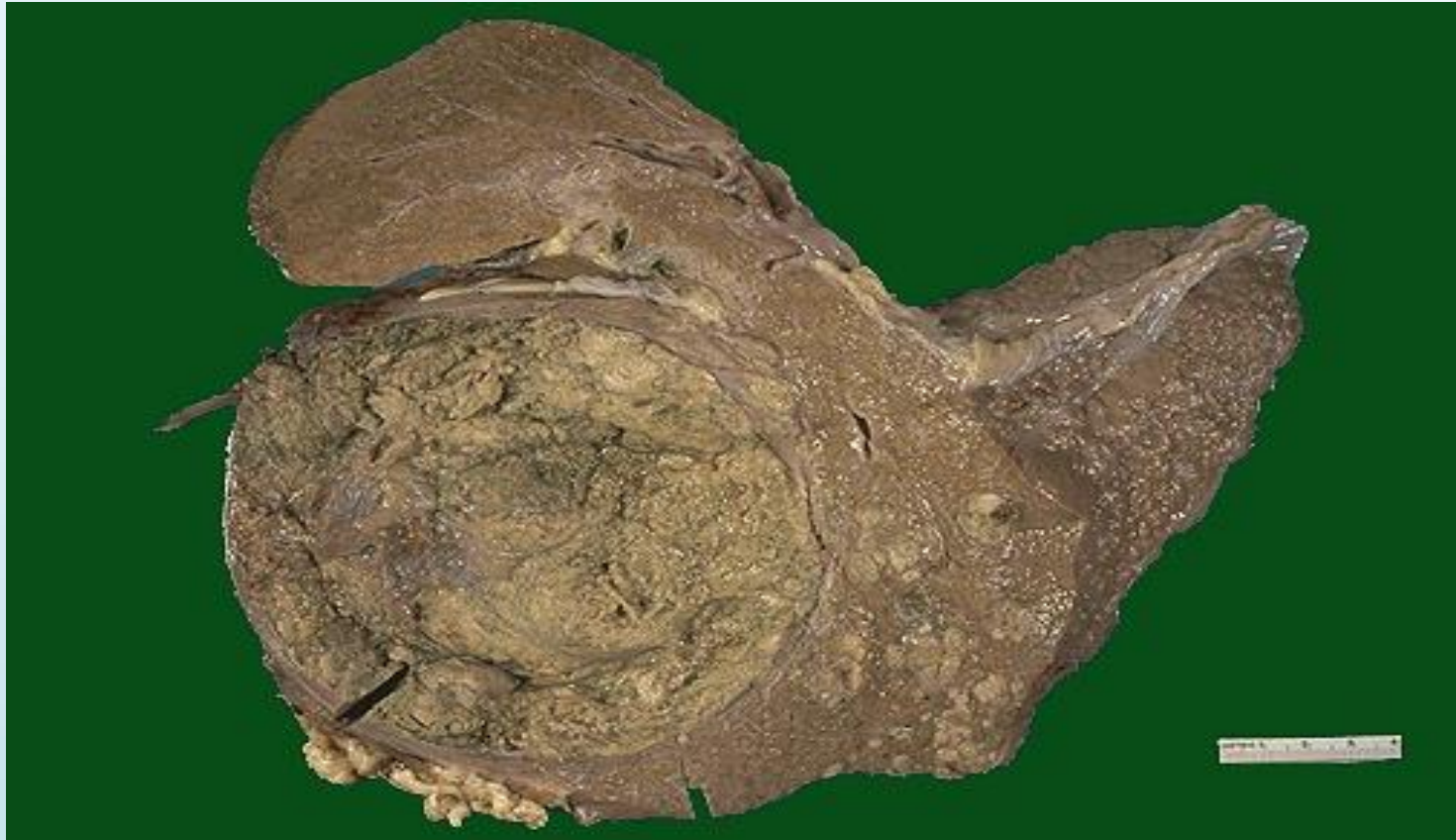


Normal liver tissue with a portal tract is seen on the left. The hepatic adenoma is on the right and is composed of cells that closely resemble normal hepatocytes, but the neoplastic liver tissue is disorganized hepatocyte cords and does not contain a normal lobular architecture.



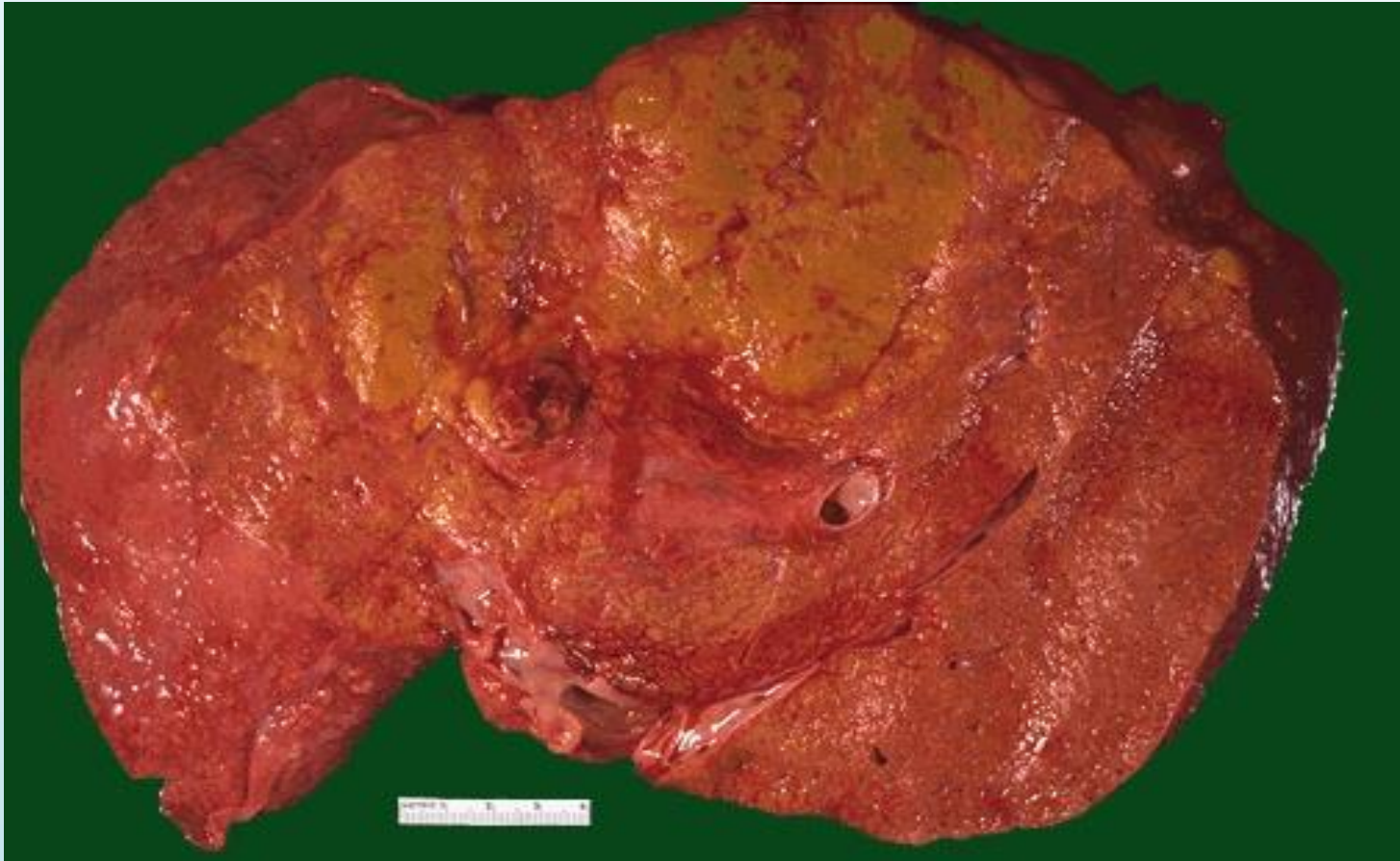HEPATOCELLULAR CARCINOMA

Hepatocellular Carcinoma - Gross



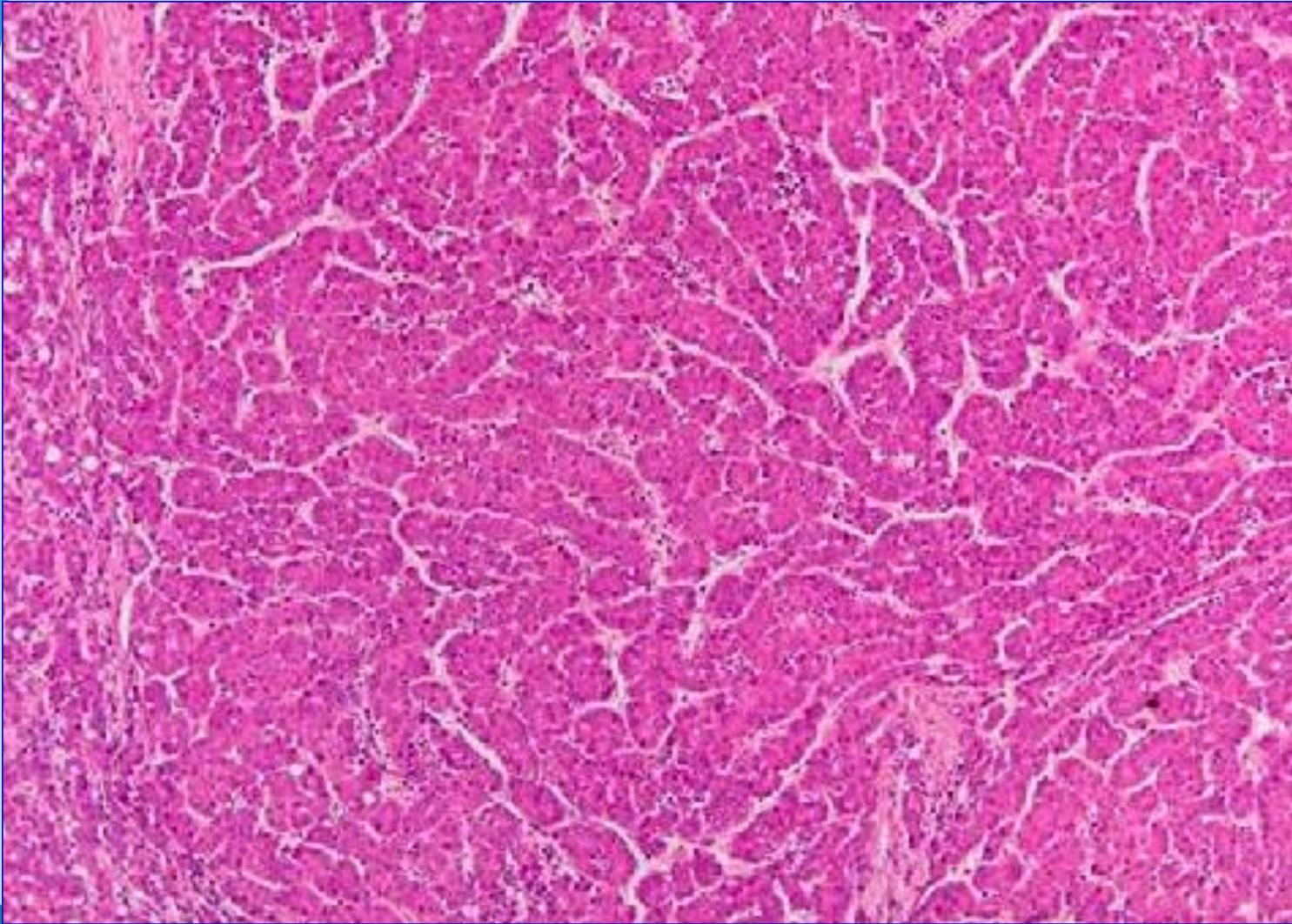
Here is an hepatocellular carcinoma. Such liver cancers arise in the setting of cirrhosis. Worldwide, viral hepatitis is the most common cause, but in the U.S., chronic alcoholism is the most common cause. The neoplasm is large and bulky and has a greenish cast because it contains bile. To the right of the main mass are smaller satellite nodules.

Hepatocellular Carcinoma - Gross



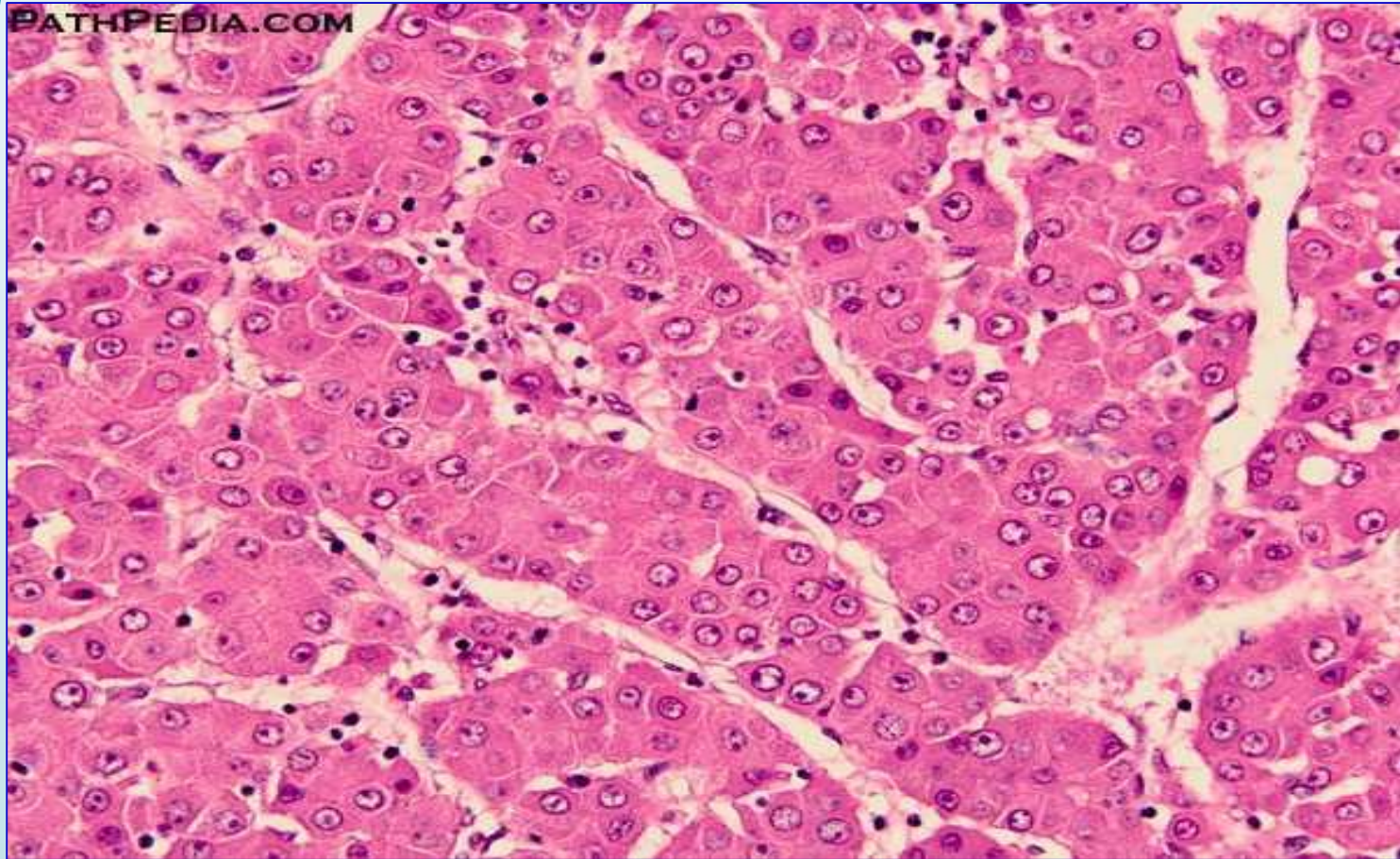
Here is another hepatocellular carcinoma with a greenish yellow hue. One clue to the presence of such a neoplasm is an elevated serum alpha-fetoprotein. Such masses may also focally obstruct the biliary tract and lead to an elevated alkaline phosphatase

Hepatocellular Carcinoma - LPF



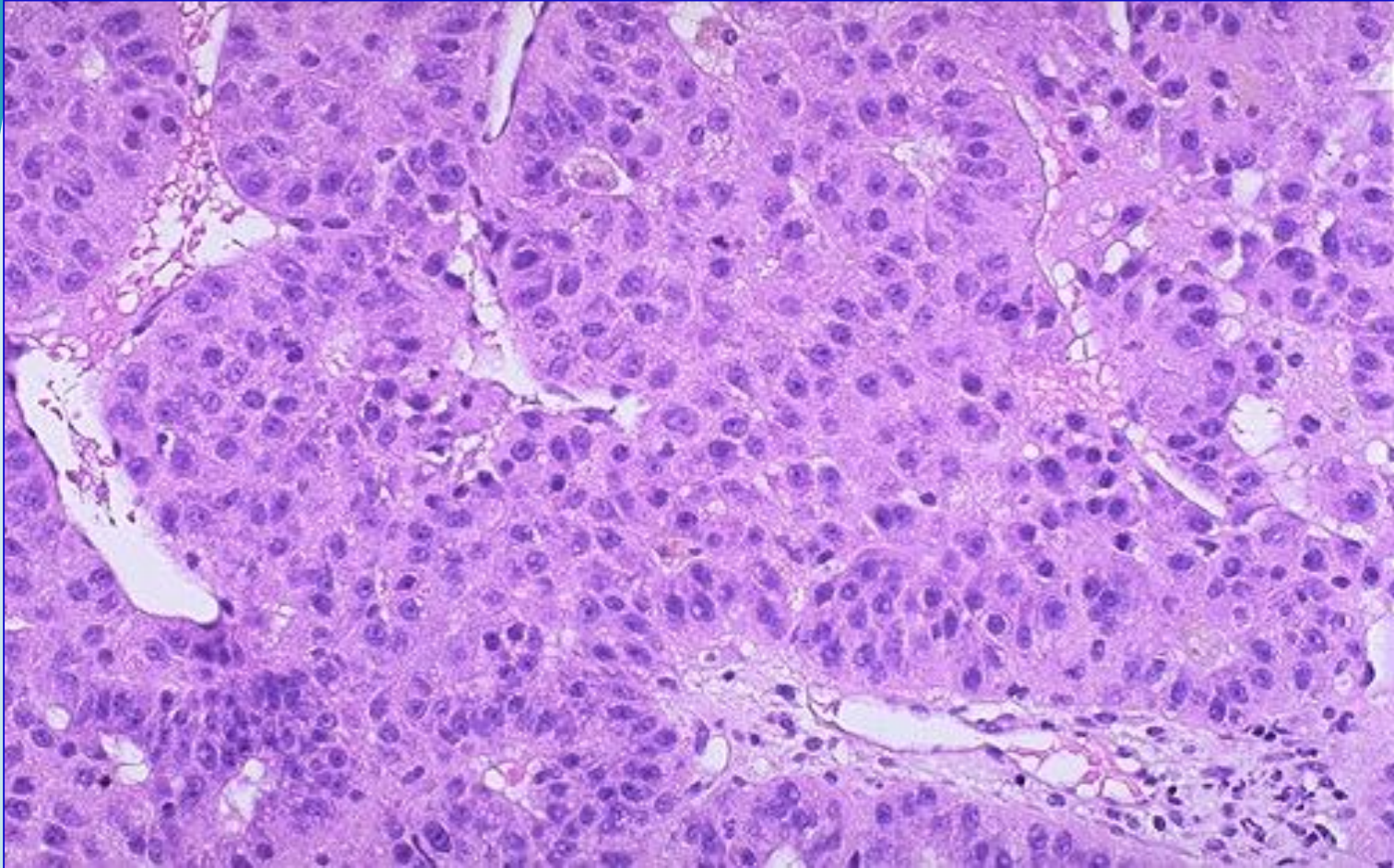
This example of well-differentiated HCC shows a trabecular pattern with intervening sinusoids.

Hepatocellular Carcinoma - MPF



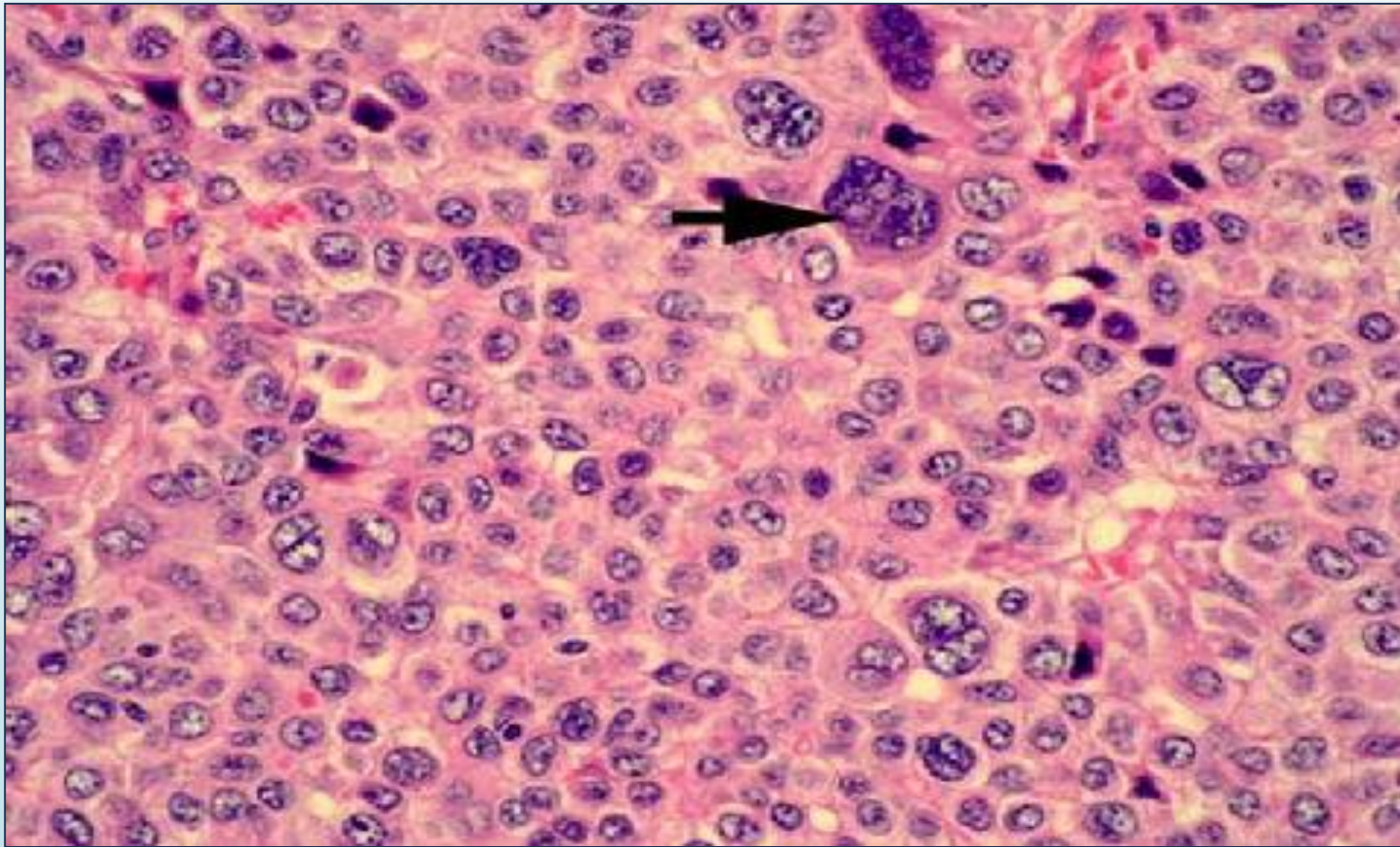
The key to the identification of HCC is its resemblance to hepatocytes, the presence of more than 2-3 cell-thick hepatocellular plates/cords, nuclear atypia, and absence of portal tracts. Note the hepatic plates are separated from each other by sinusoids.

Hepatocellular Carcinoma - MPF




Note that this hepatocellular carcinoma is composed of liver cords that are much wider than the normal liver plate that is two cells thick. There is no discernable normal lobular architecture, though vascular structures are present.

Hepatocellular Carcinoma - Microscopic



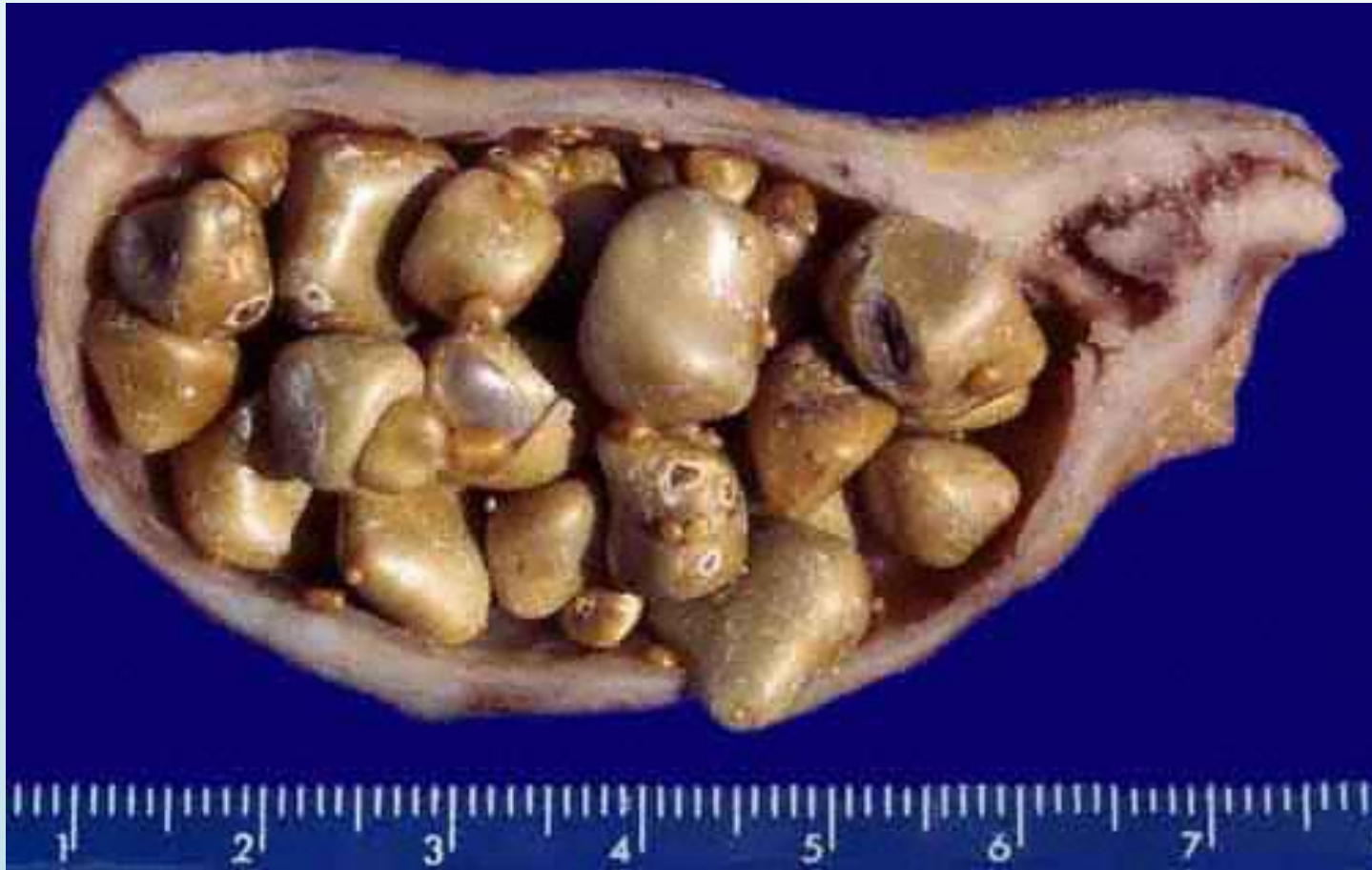Anaplastic tumor giant cells can be seen in poorly differentiated HCC (arrow). Mitoses are numerous.

Malignant liver cells are pleomorphic, binucleated or forming giant cells with hyperchromatic nuclei.



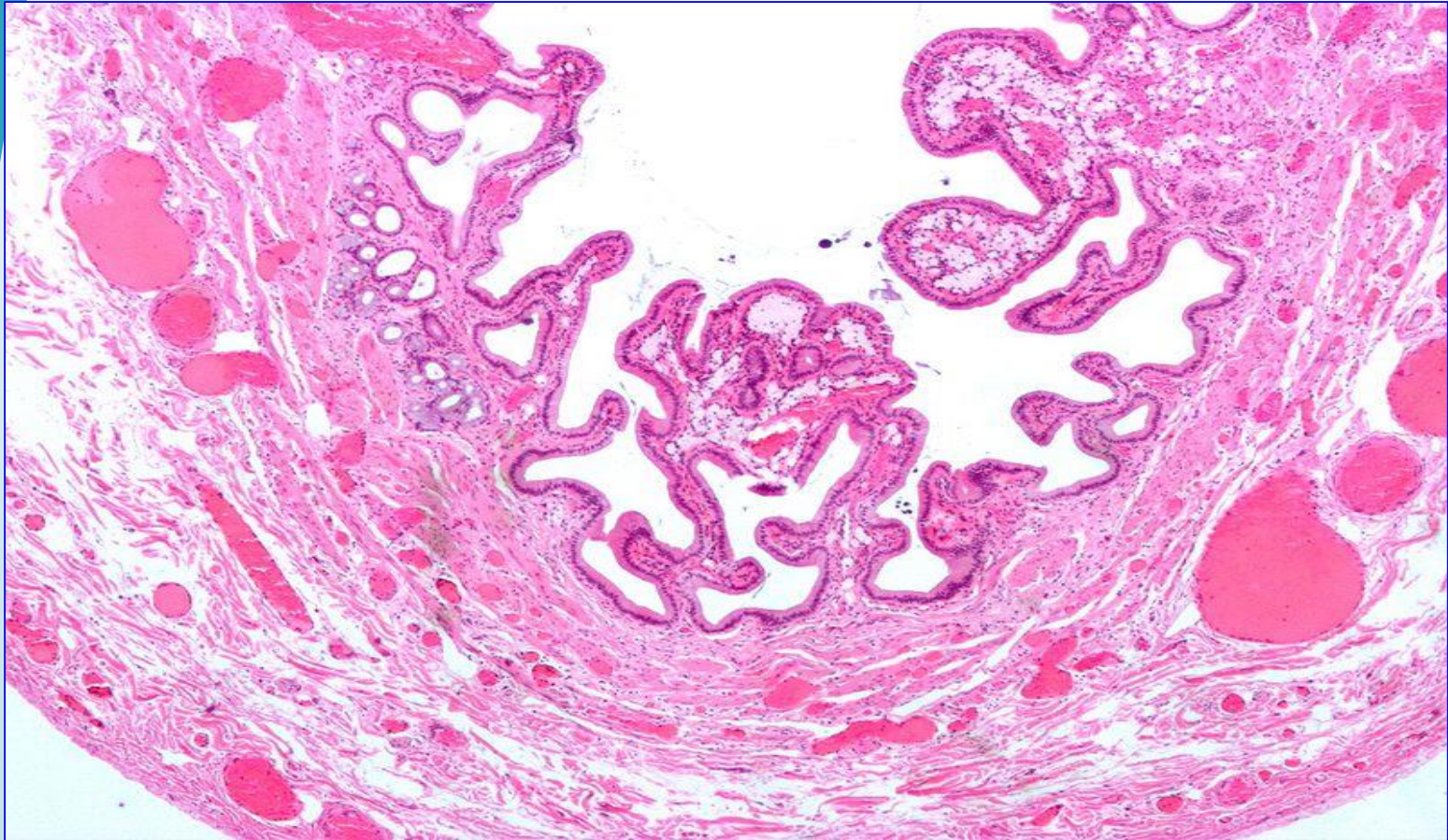
CHRONIC CHOLECYSTITIS WITH STONES

Chronic Cholecystitis with Gall stones - Gross



Gross appearance of gallbladder after sectioning longitudinally. Notice thickness of gallbladder wall, abundant polyhedral stones and small papillary tumor in the cystic duct.

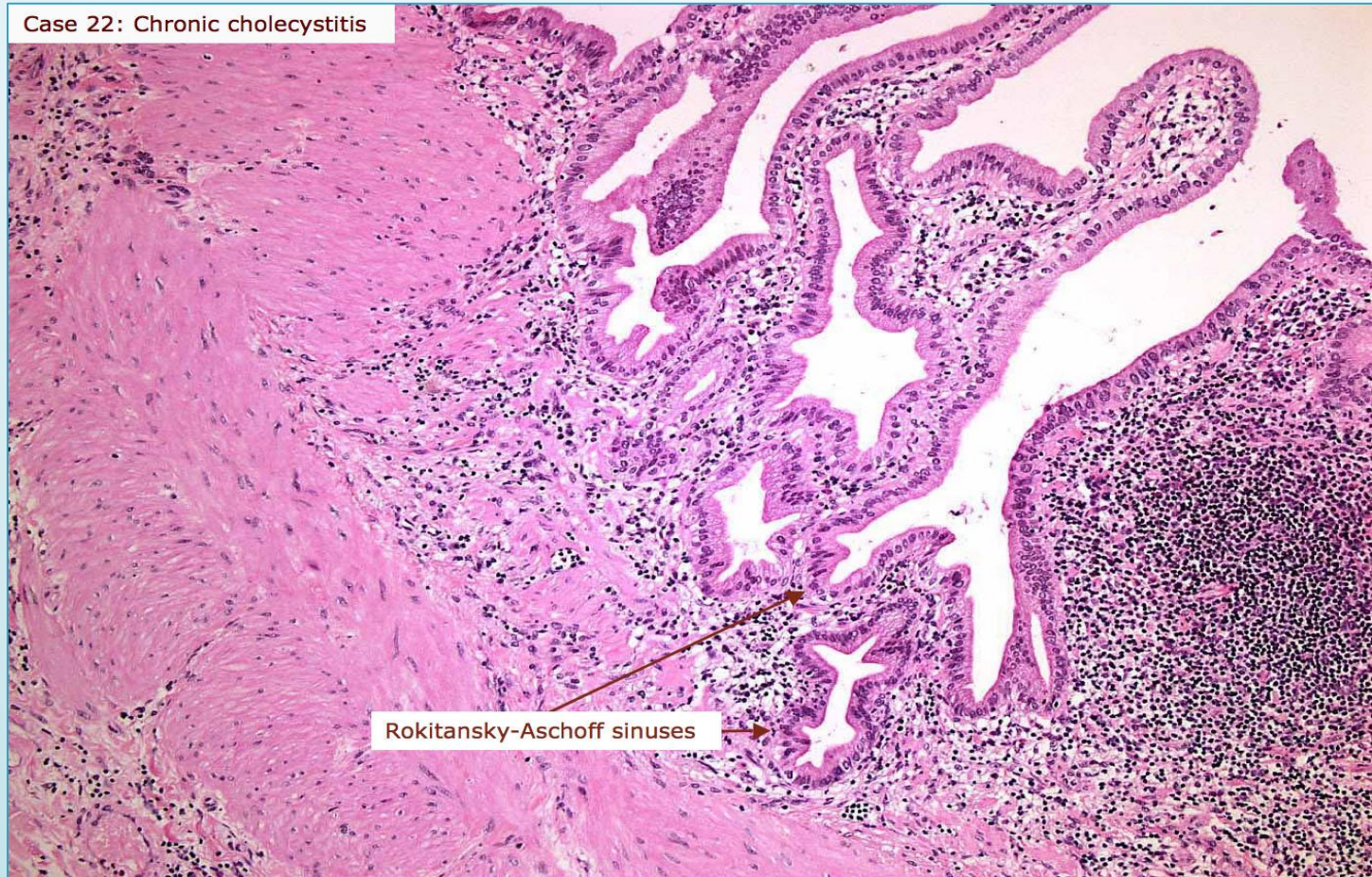Chronic Cholecystitis – Microscopic view



Dead lipid laden macrophages (foam cells) are seen in the finger-like projections into the gallbladder lumen. It should be apparent that this is gallbladder, as no muscularis mucosae is present (as elsewhere in the gastrointestinal tract). The blood vessels are congested and the subserosa edematous.

Chronic Cholecystitis – Microscopic view

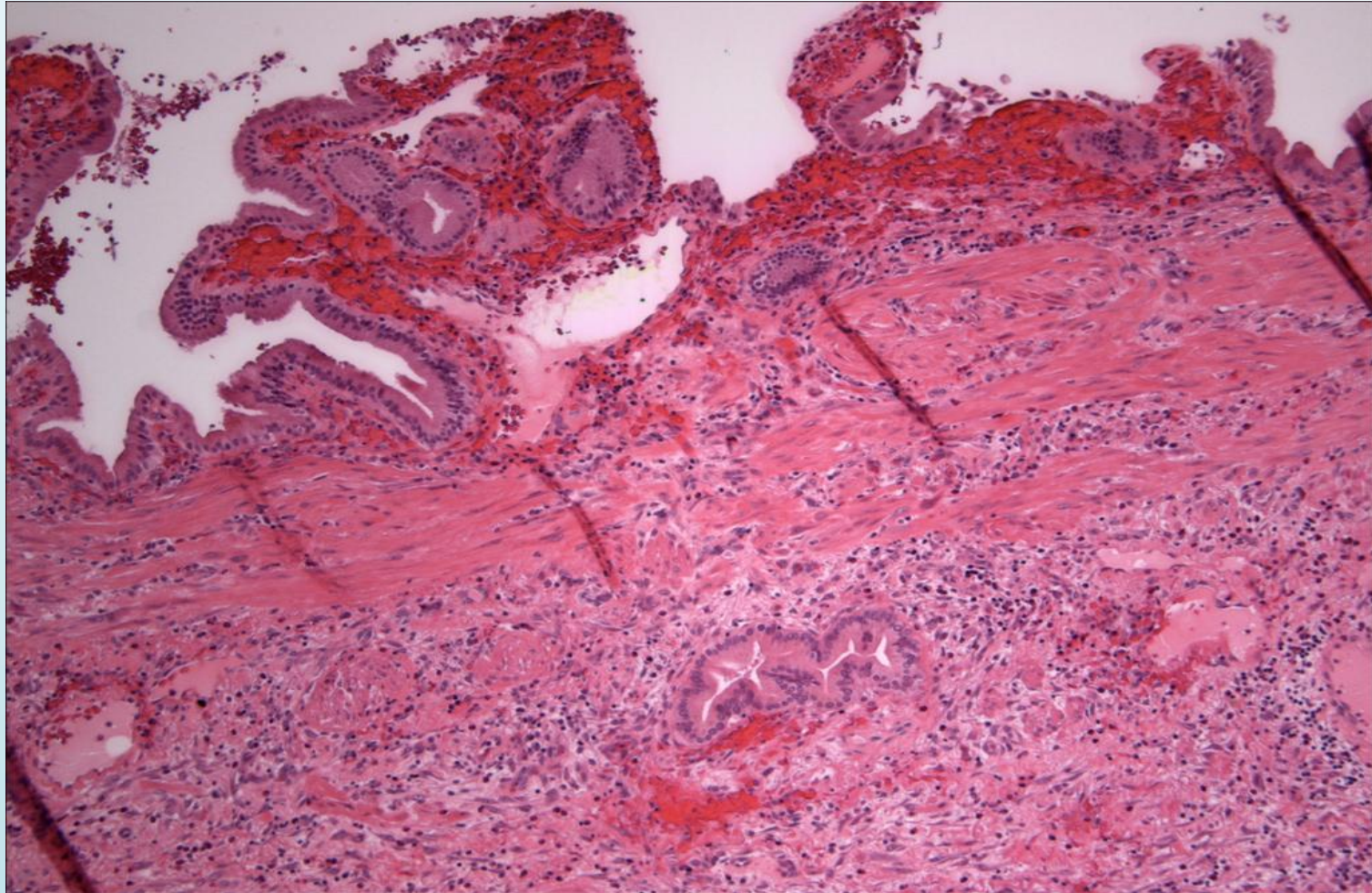
Case 22: Chronic cholecystitis



***Irregular mucosal folds and foci of ulceration in mucosa.
Wall is penetrated by mucosal glands which are present in
muscle coat (Rokitansky- Aschoff sinuses).***

All layers show chronic inflammatory cells infiltration and fibrosis.

Chronic Cholecystitis – Microscopic view



***Mucosa wall is penetrated by mucosal glands which are present in muscle coat (Rokitansky- Aschoff sinuses).
All layers show chronic inflammatory cells infiltration and fibrosis.***

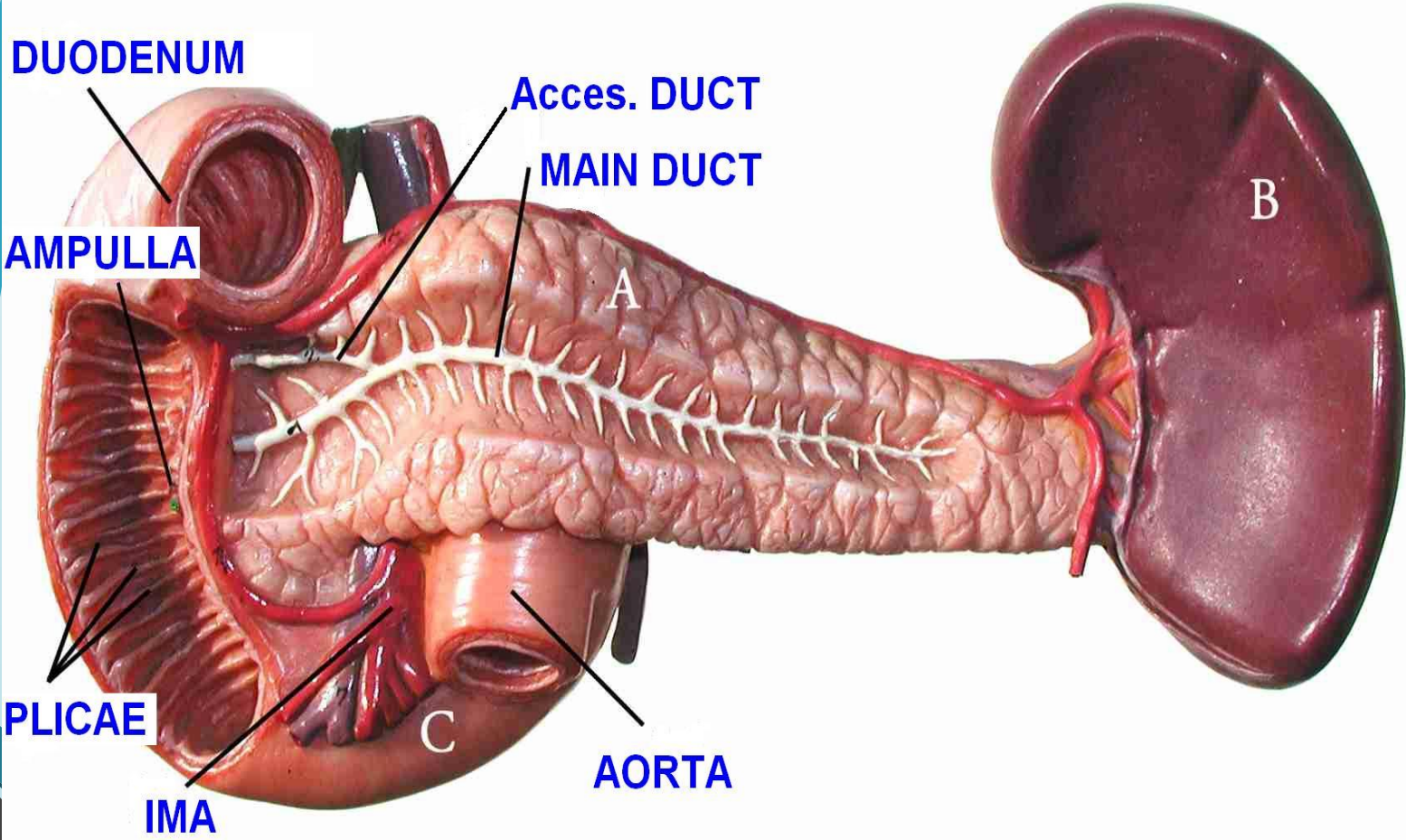


PANCREAS

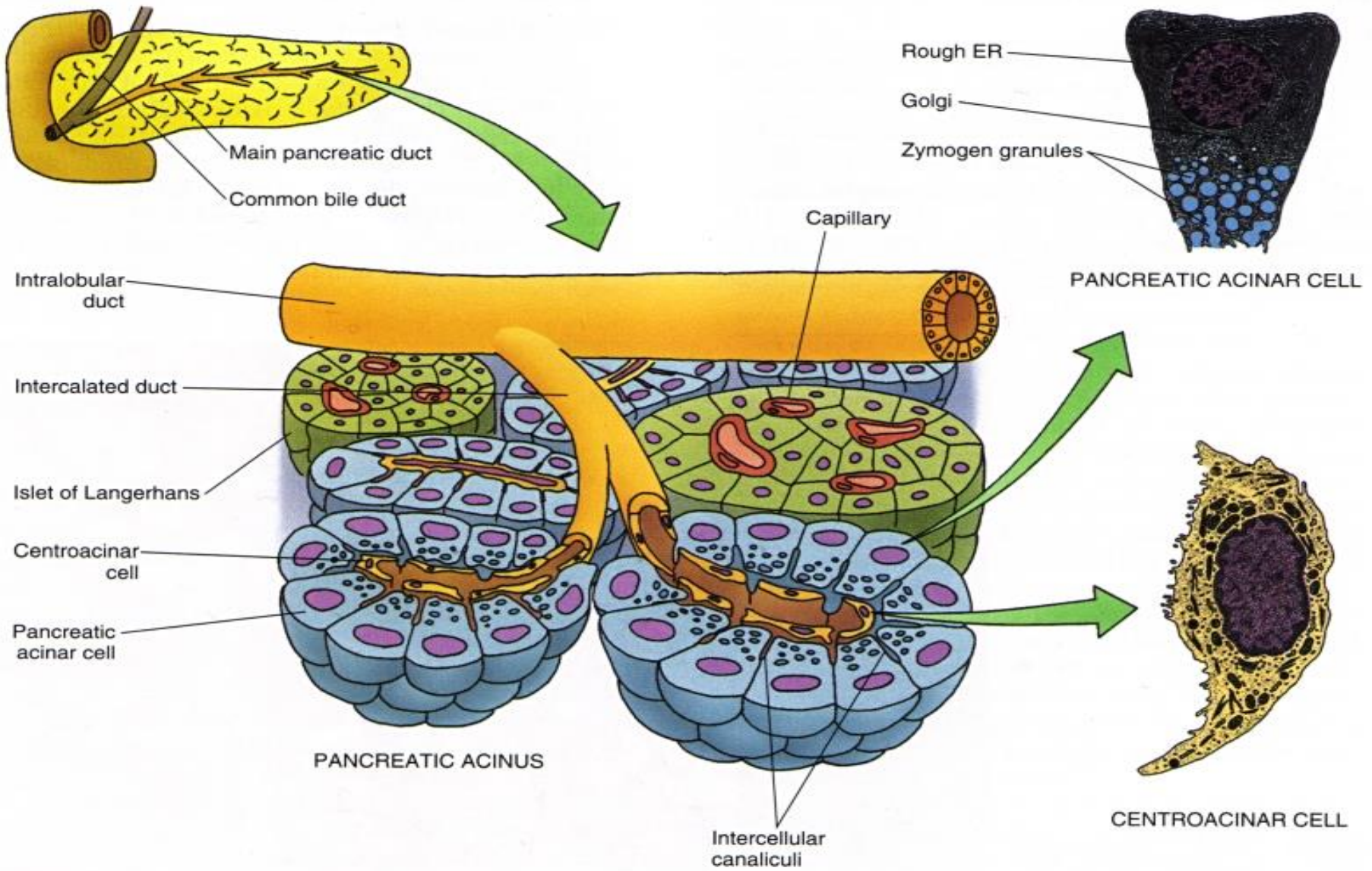


Normal anatomy & histology

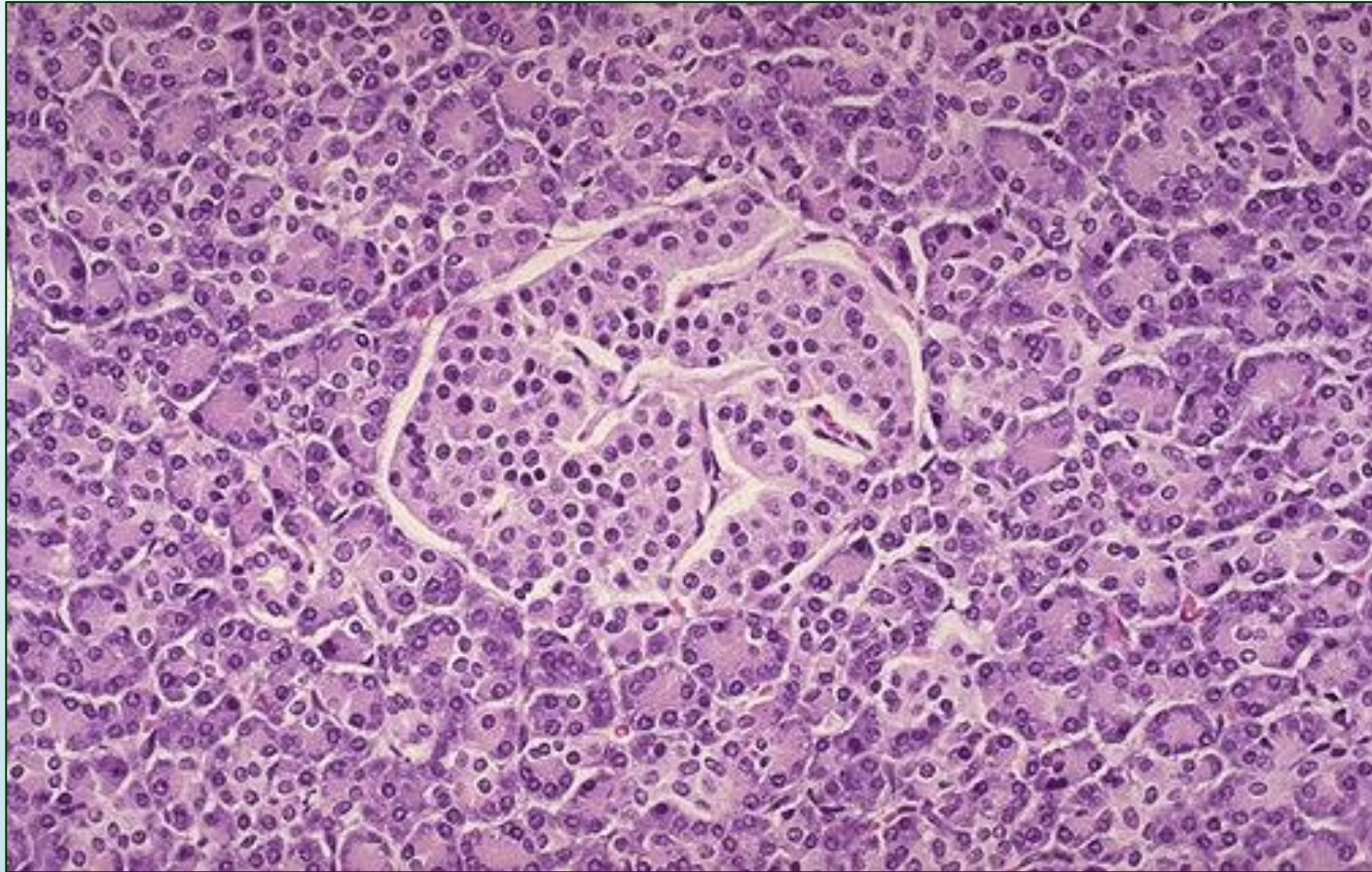
PANCREAS – Normal Anatomy



PANCREAS – Normal Histology (Diagram)

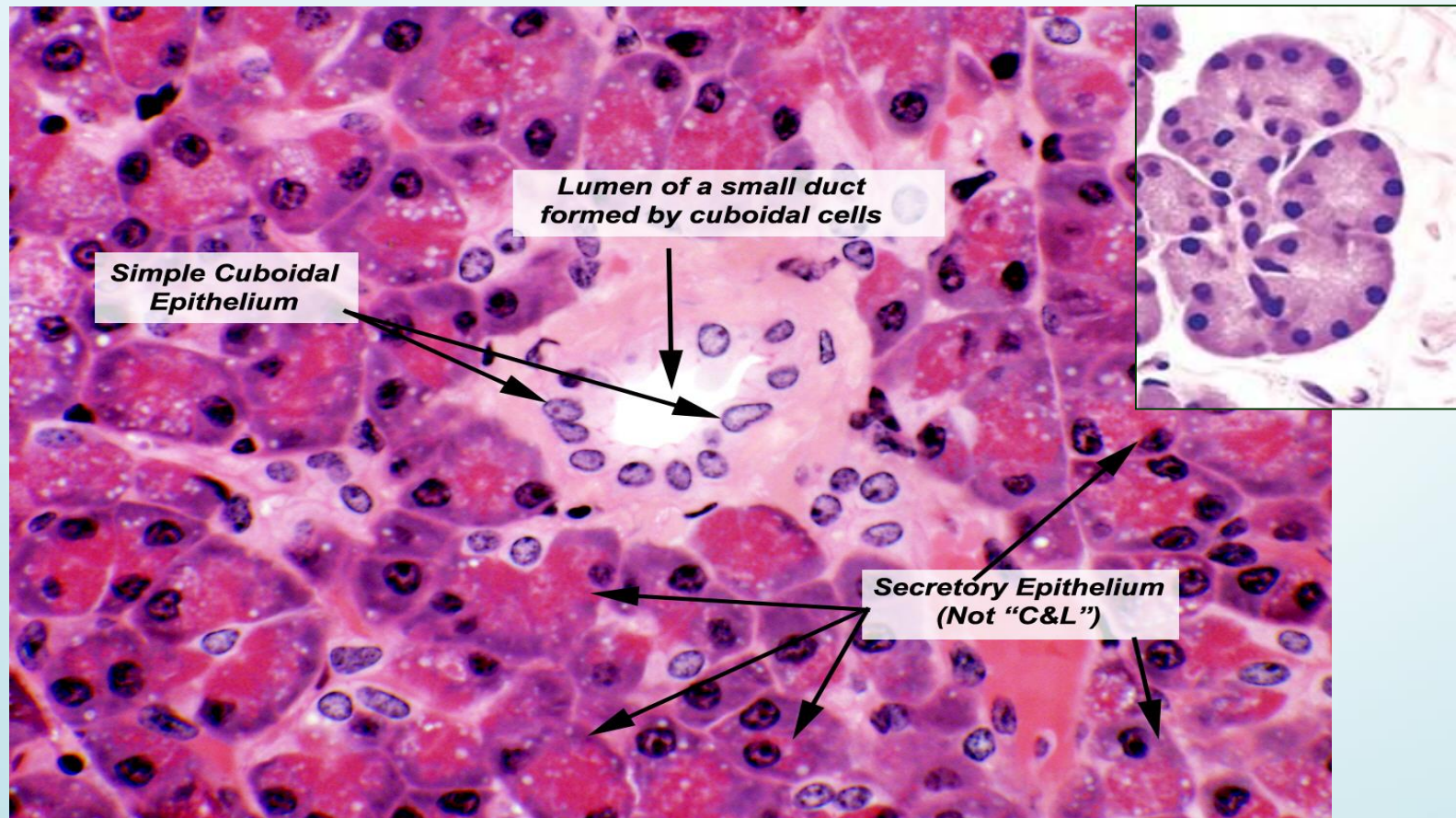


PANCREAS – Normal Histology -LPF



Here is a normal pancreatic islet of Langerhans surrounded by normal exocrine pancreatic acinar tissue. The islets contain alpha cells secreting glucagon, beta cells secreting insulin, and delta cells secreting somatostatin.

PANCREAS – Normal Histology -HPF



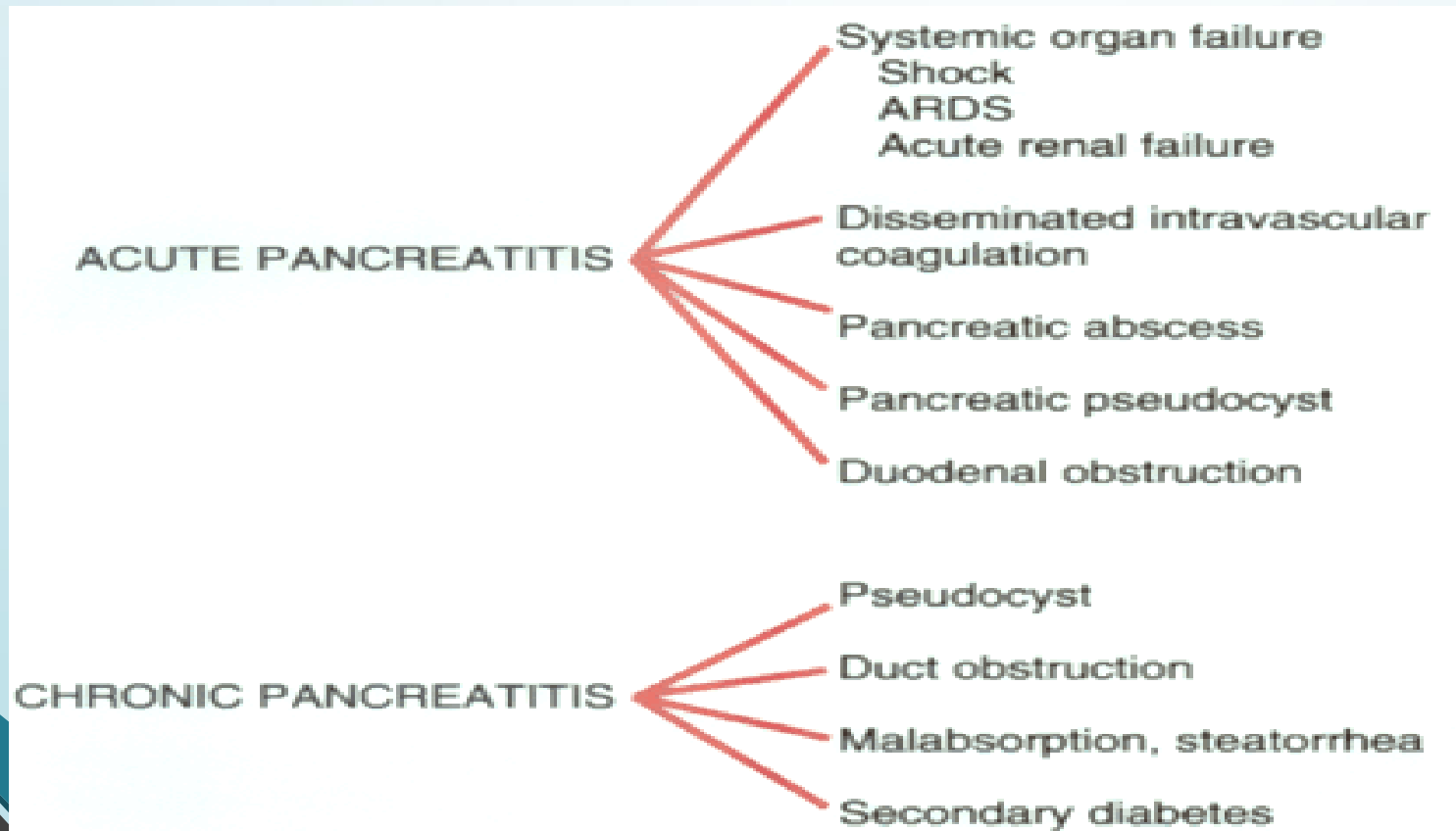
This section of pancreas shows a small duct in the center of the field. The wall of the duct is made of simple cuboidal epithelium. Exocrine gland ducts of this type are made of cuboidal cells arranged like bricks in a wall. As the duct enlarges there may be a transition from cuboidal to a columnar shape



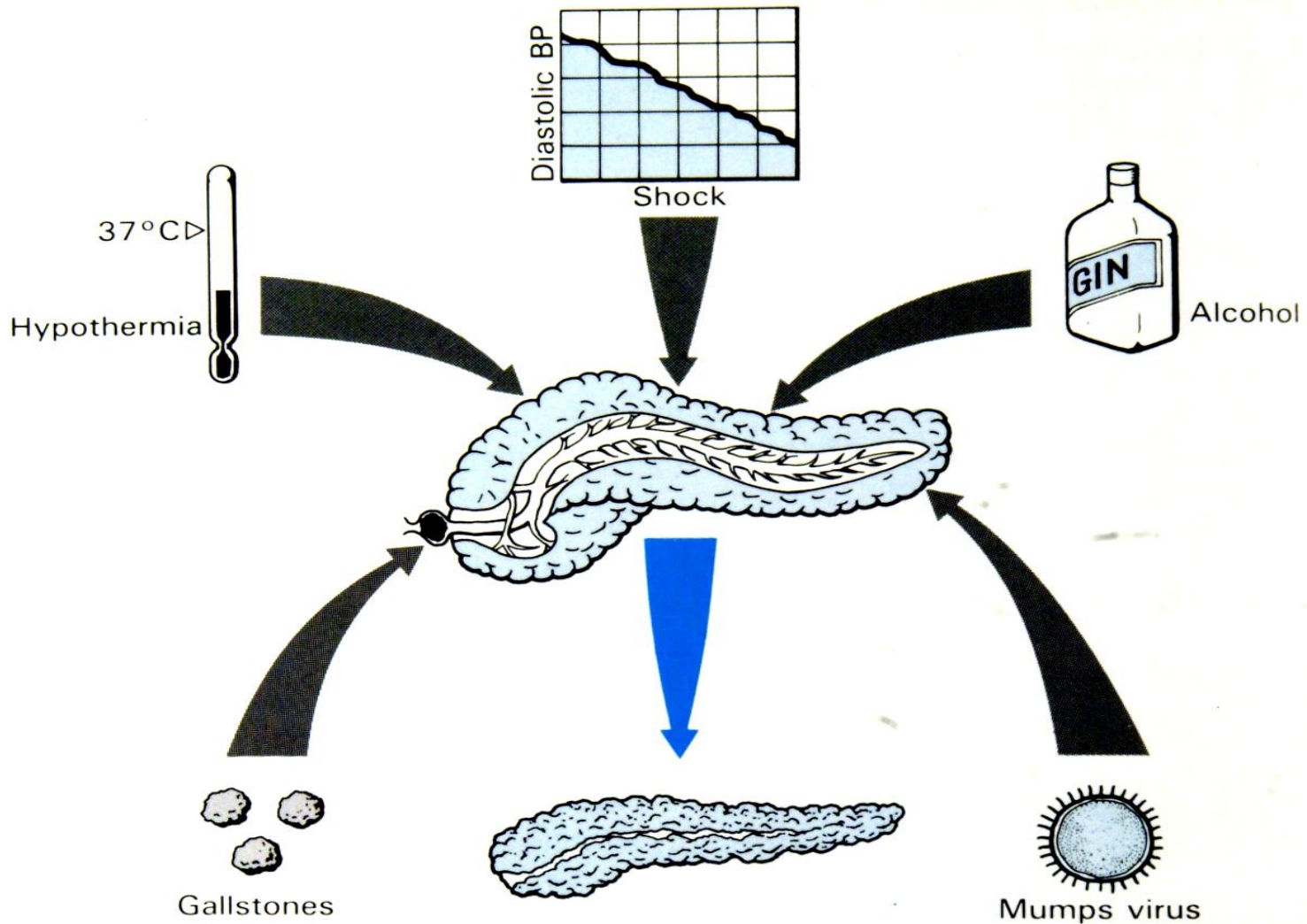
GROSS & HISTOPATHOLOGY

PANCREATITIS - Types

- **ACUTE** (Very serious)
- **CHRONIC** (Calcifications, Pseudocyst)



PANCREATITIS – Common causes





Acute pancreatitis

ACUTE PANCREATITIS - Causes

- ***Alcoholism***
- ***Bile reflux***
- ***Medications (thiazides)***
- ***Hypertriglyceridemia, hypercalcemia***
- ***Acute ischemia***
- ***Trauma, blunt, iatrogenic***
- ***Genes: PRSS₁, SPINK₁***
- ***Idiopathic, 10-20%***

ACUTE PANCREATITIS – Clinical Features

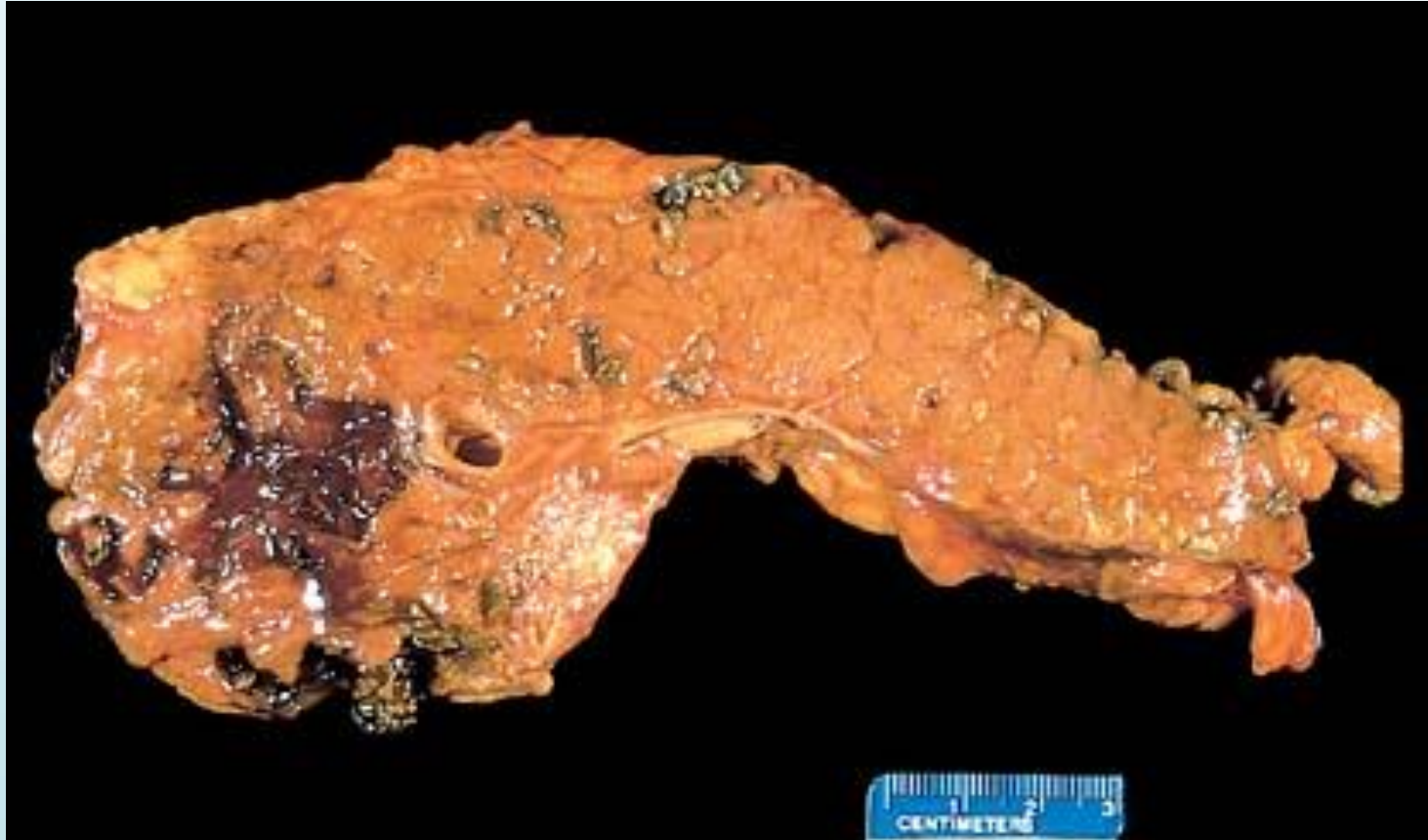- *SEVERE ABDOMINAL PAIN*
- *Extreme Emergency Situation*
- *High Mortality*

- *The MOST important lab test is.....?????*
 - ➔ *α – AMYLASE estimation*

ACUTE PANCREATITIS – Consequences

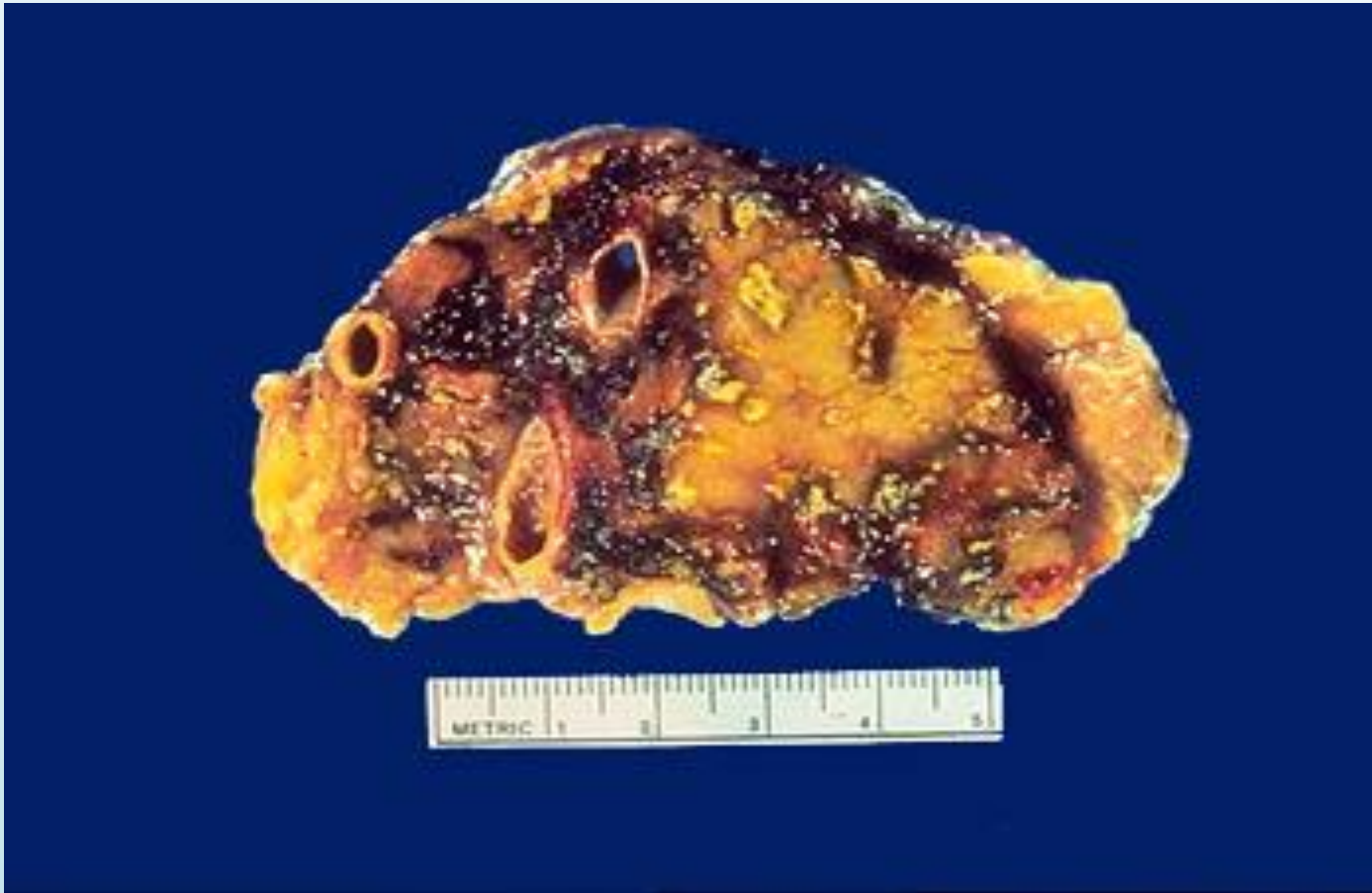- *EDEMA*
- *FAT NECROSIS*
- *ACUTE INFLAMMATORY INFILTRATE*
- *PANCREAS AUTODIGESTION*
- *BLOOD VESSEL DESTRUCTION*
- *"SAPONIFICATION"*

ACUTE PANCREATITIS – Gross



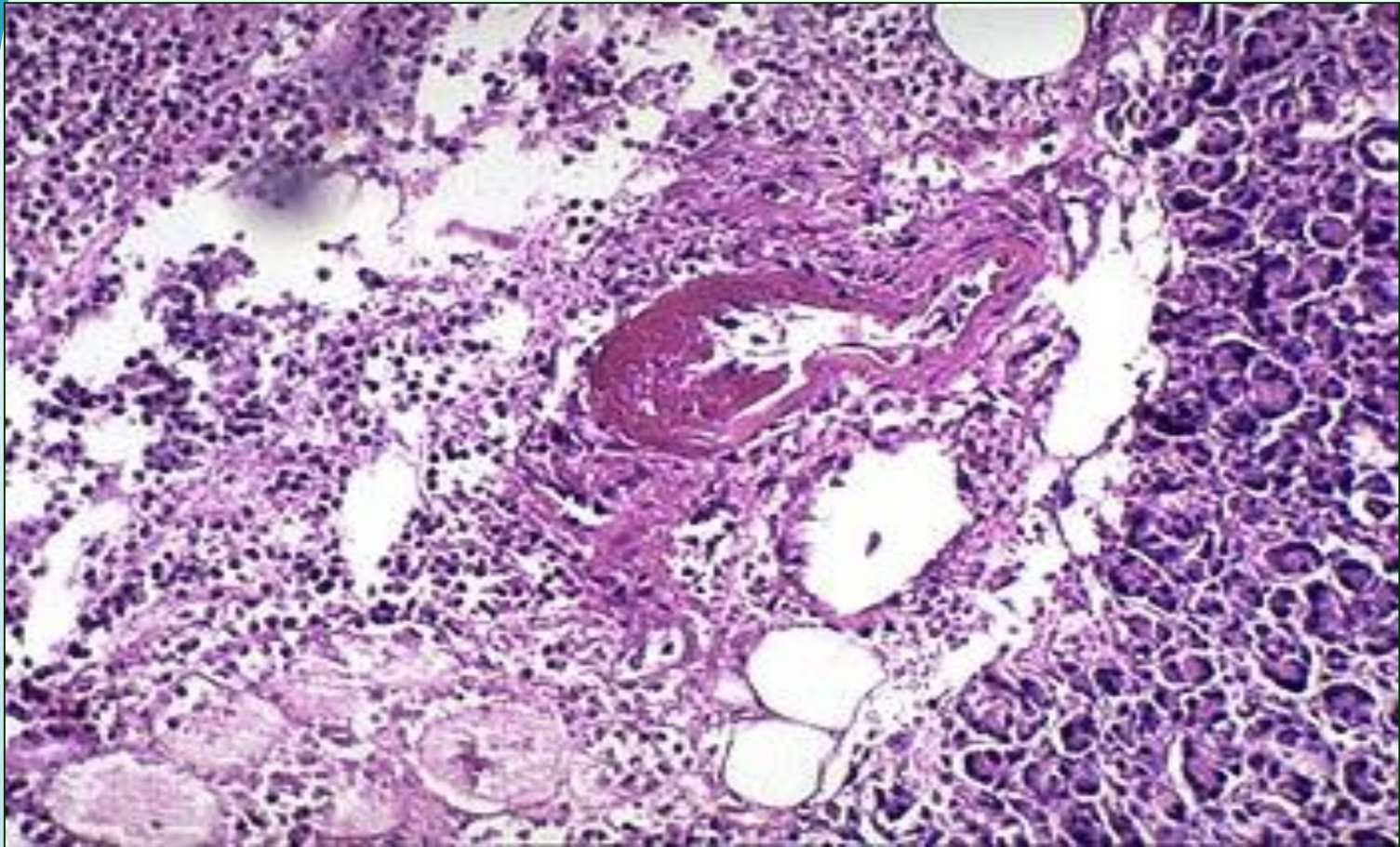
Acute Pancreatitis : Fat necrosis appears as chalky white calcium soaps.

ACUTE PANCREATITIS – Gross



In severe acute pancreatitis, black areas of hemorrhage are present within the pancreas as well as chalky, yellow-white areas of fat necrosis. Pancreatic parenchyma is soft and gray-white due to necrosis

ACUTE PANCREATITIS – LPF

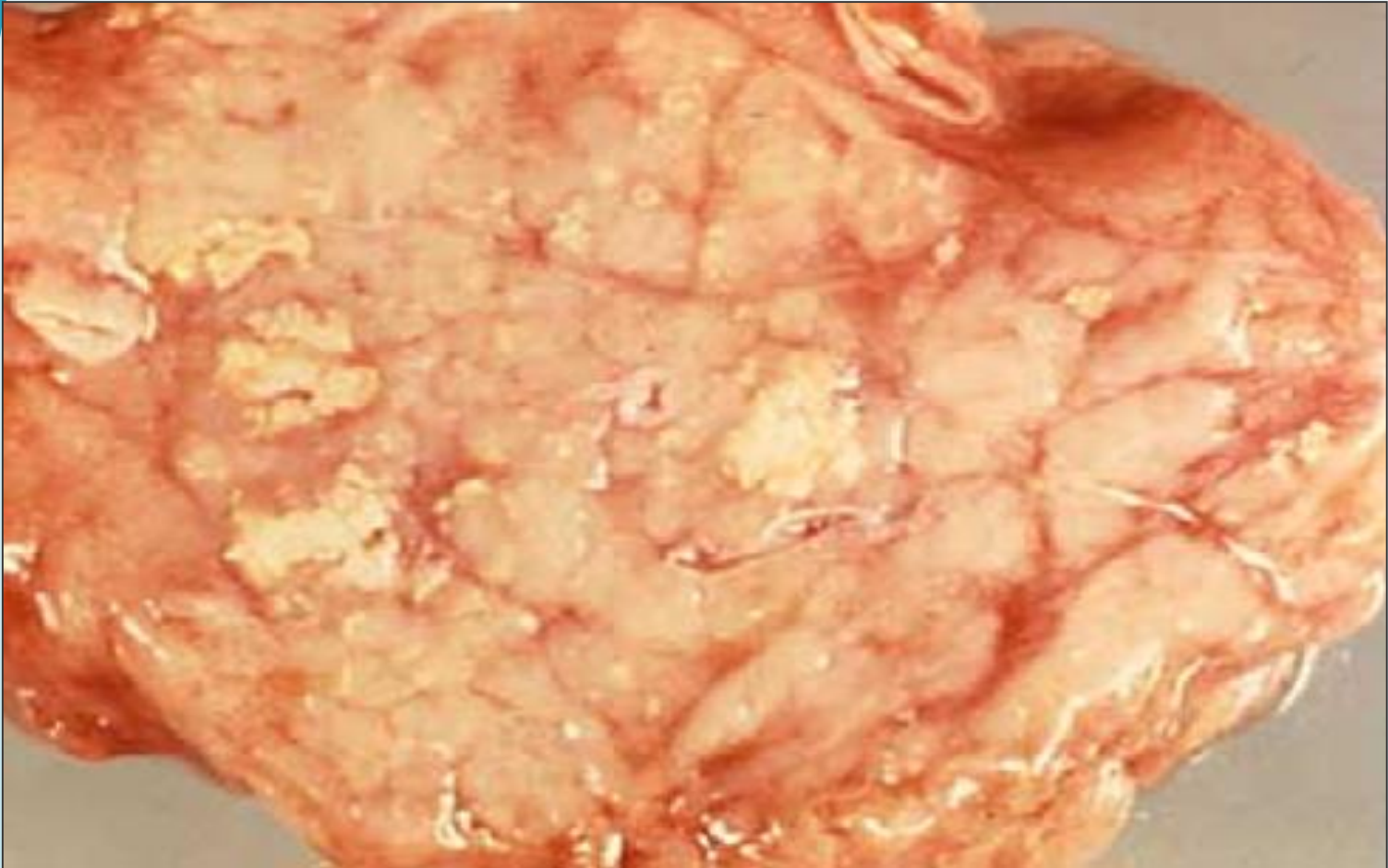


Severe acute pancreatitis shows an area of acute inflammation with necrosis. Within the necrotic area is a blood vessel showing fibrinoid necrosis of the vessel wall leads to severe, hemorrhagic, acute pancreatitis. Common causes of acute pancreatitis are alcoholism , gall stones impaction , traumatic , hereditary and idiopathic .



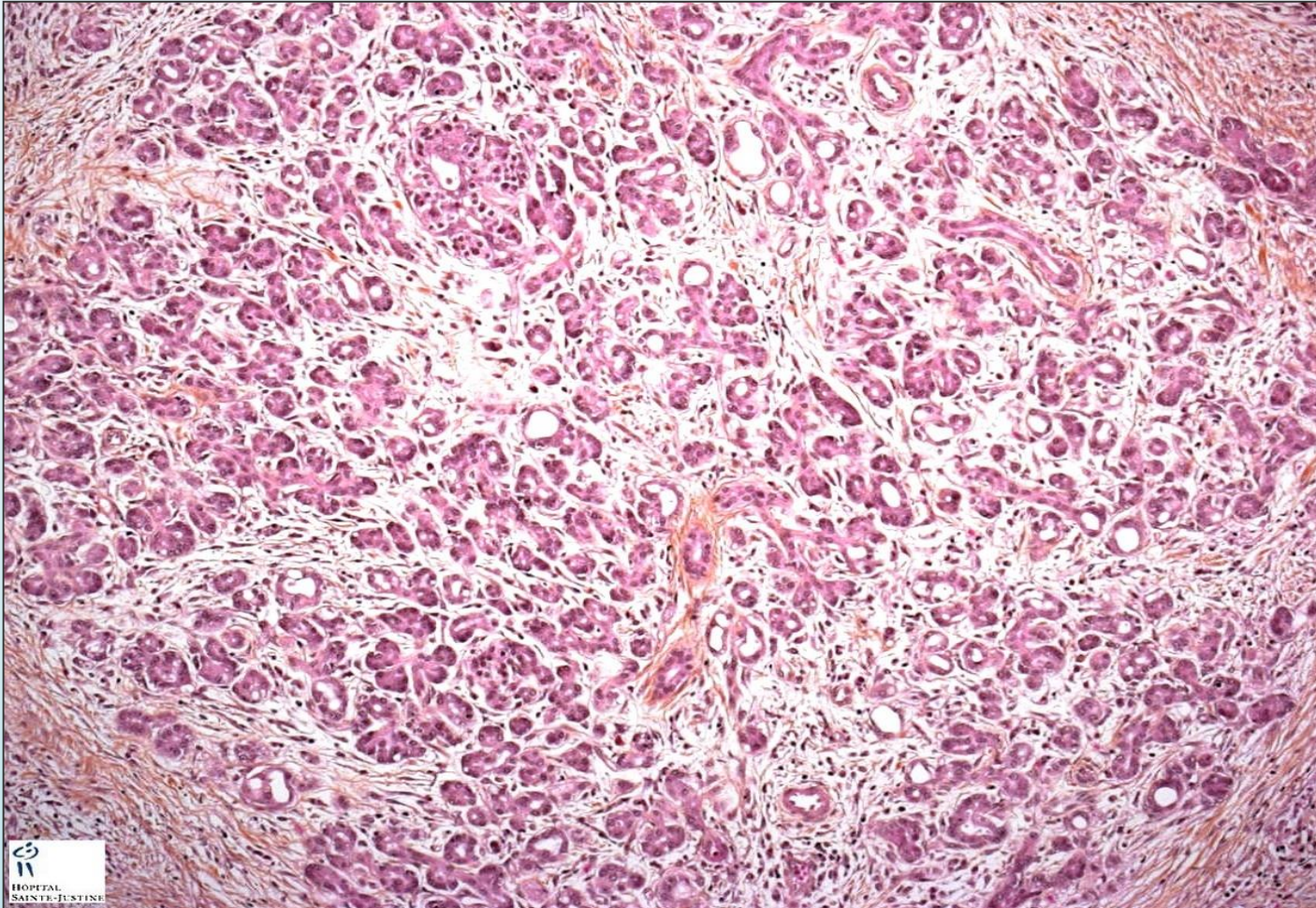
Chronic pancreatitis

CHRONIC PANCREATITIS – GROSS



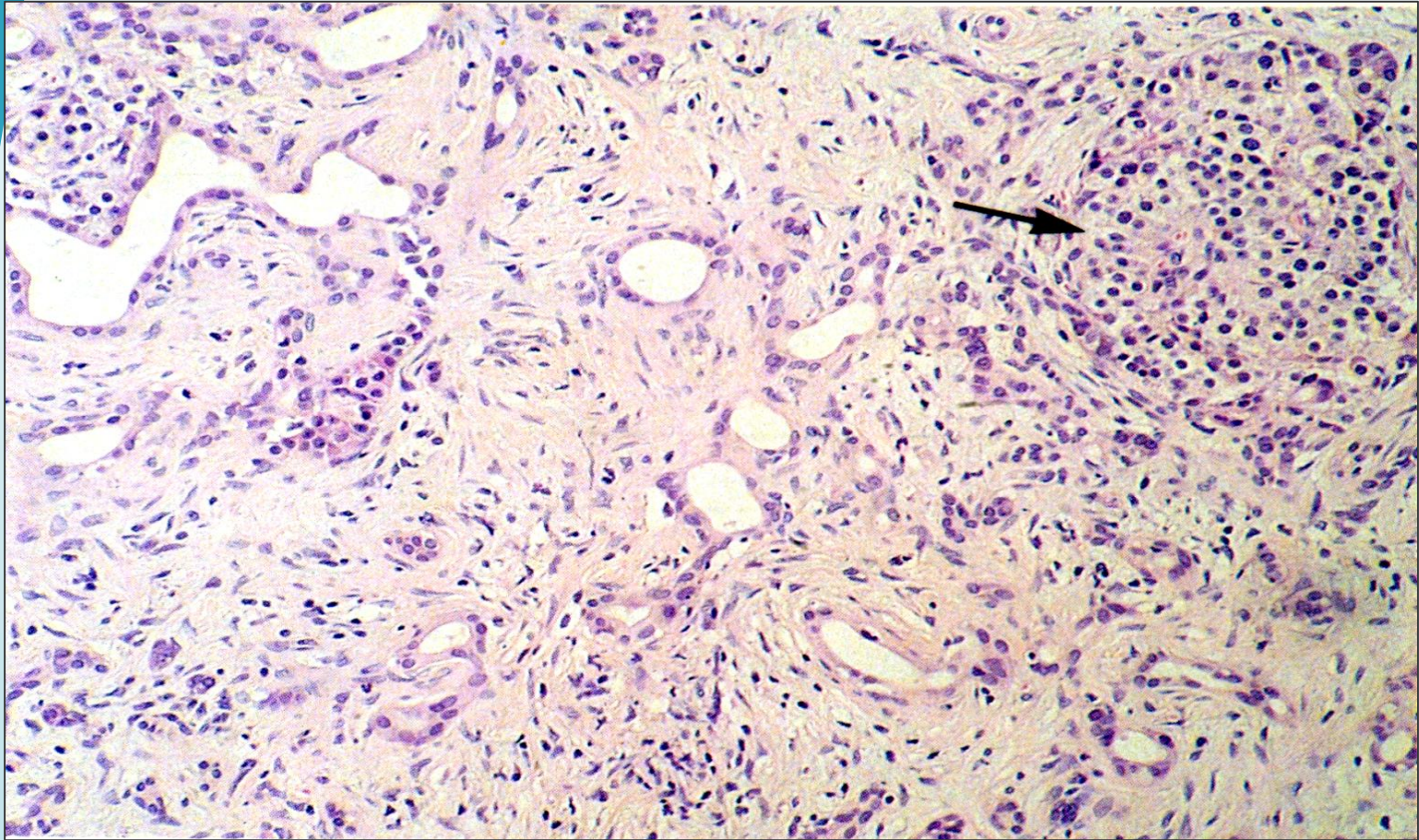
Find the "soap", find the calcium. Calcium deposition is secondary to fat necrosis and dystrophic calcification . Possible causes of chronic pancreatitis are gall stones , alcoholism, tropical , hereditary and idiopathic .

CHRONIC PANCREATITIS – LPF



Unfortunately dense fibrosis is a feature BOTH of chronic pancreatitis as well as adenocarcinoma.

CHRONIC PANCREATITIS – LPF



Chronic Pancreatitis: parenchymal fibrosis, chronic inflammatory infiltrate and reduced number and size of acini with variable dilatation of pancreatic ducts and relative sparing of islets of langerhans (arrow)

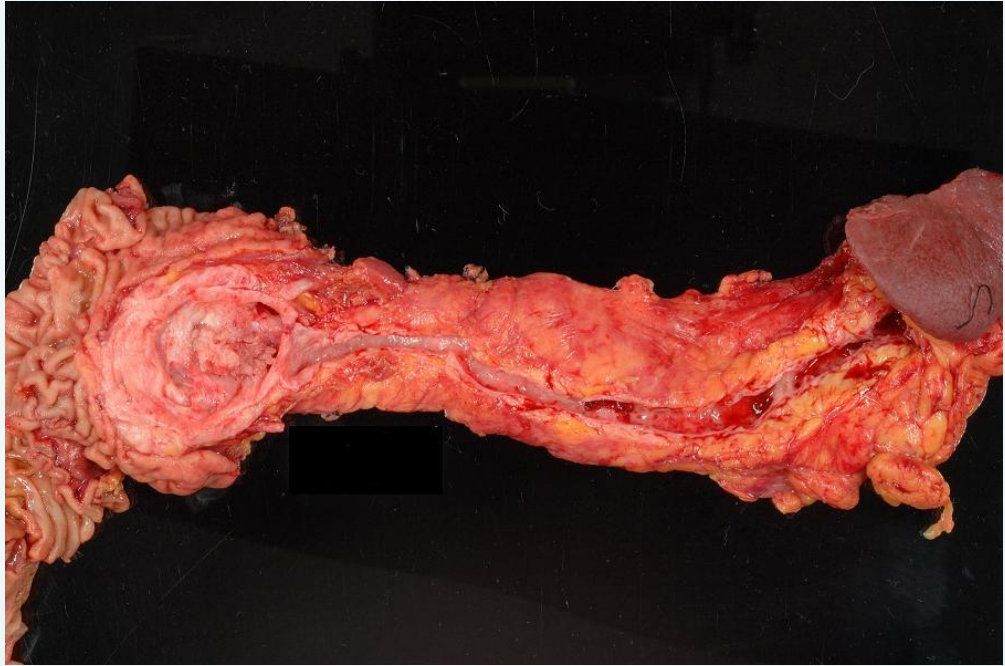


Pancreatic adenocarcinoma

PANCREATIC ADENOCARCINOMA – Gross

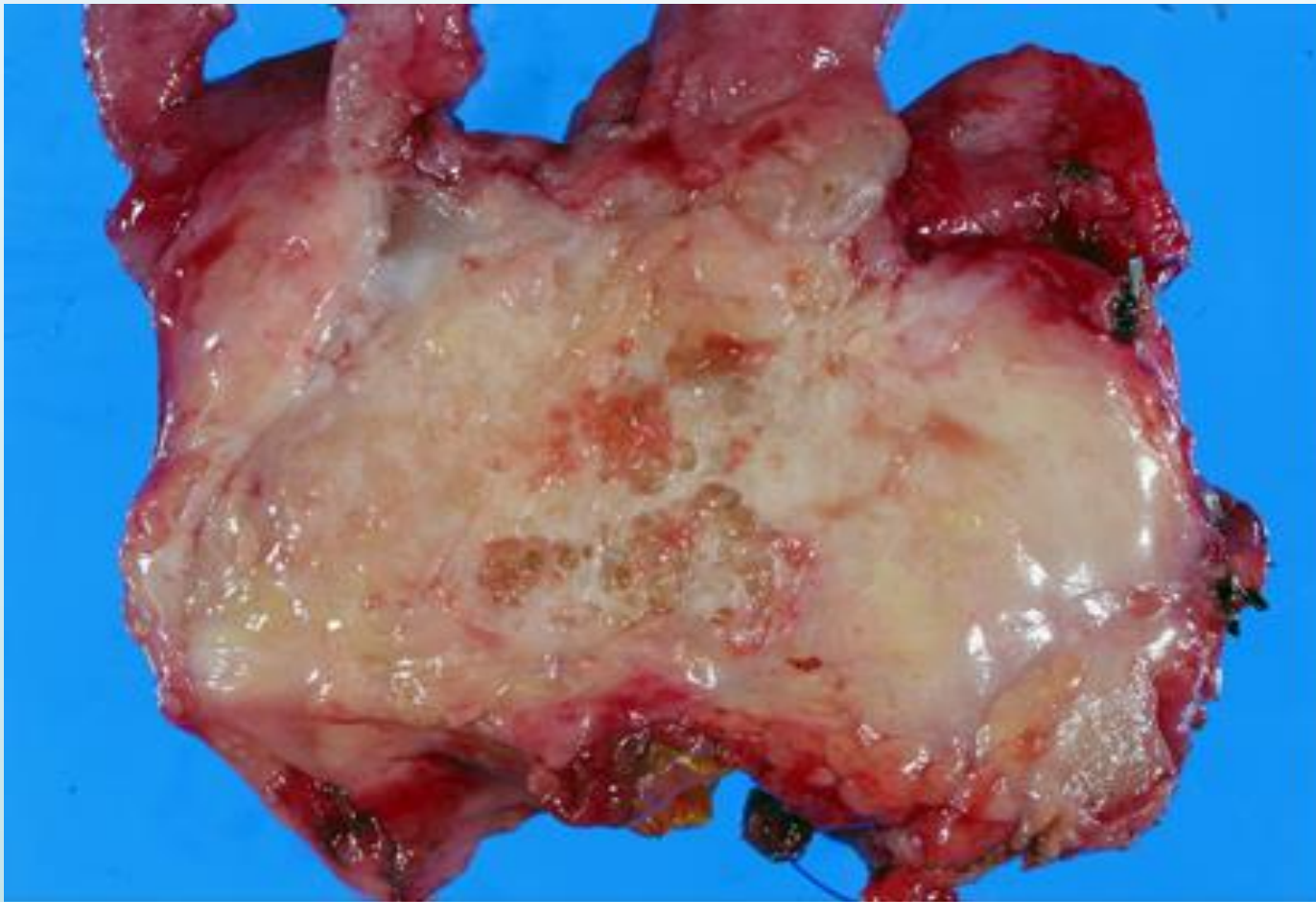
predispose to PANCREATIC ADENOCARCINOMA:

- Chronic pancreatitis
- Diabetic mellitus
- Smoking
- Germline mutation in BRCA2.



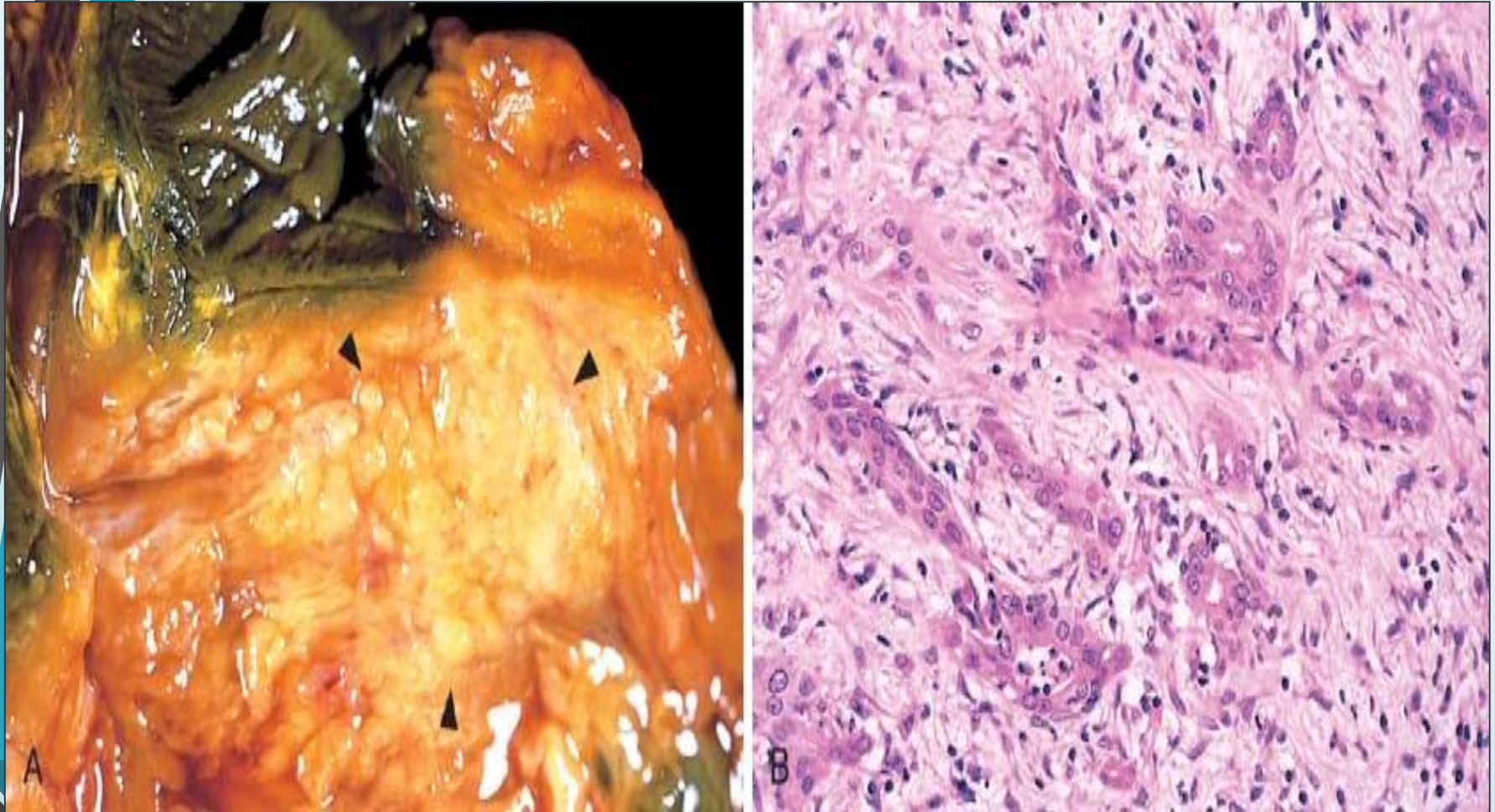
Horizontal section of pancreas showing a well circumscribed tumor nodule at the head of pancreas. Note the presence of a dilated main pancreatic duct. Part of the duodenum is seen on the left and the spleen on the right side.

PANCREATIC ADENOCARCINOMA – Cut surface



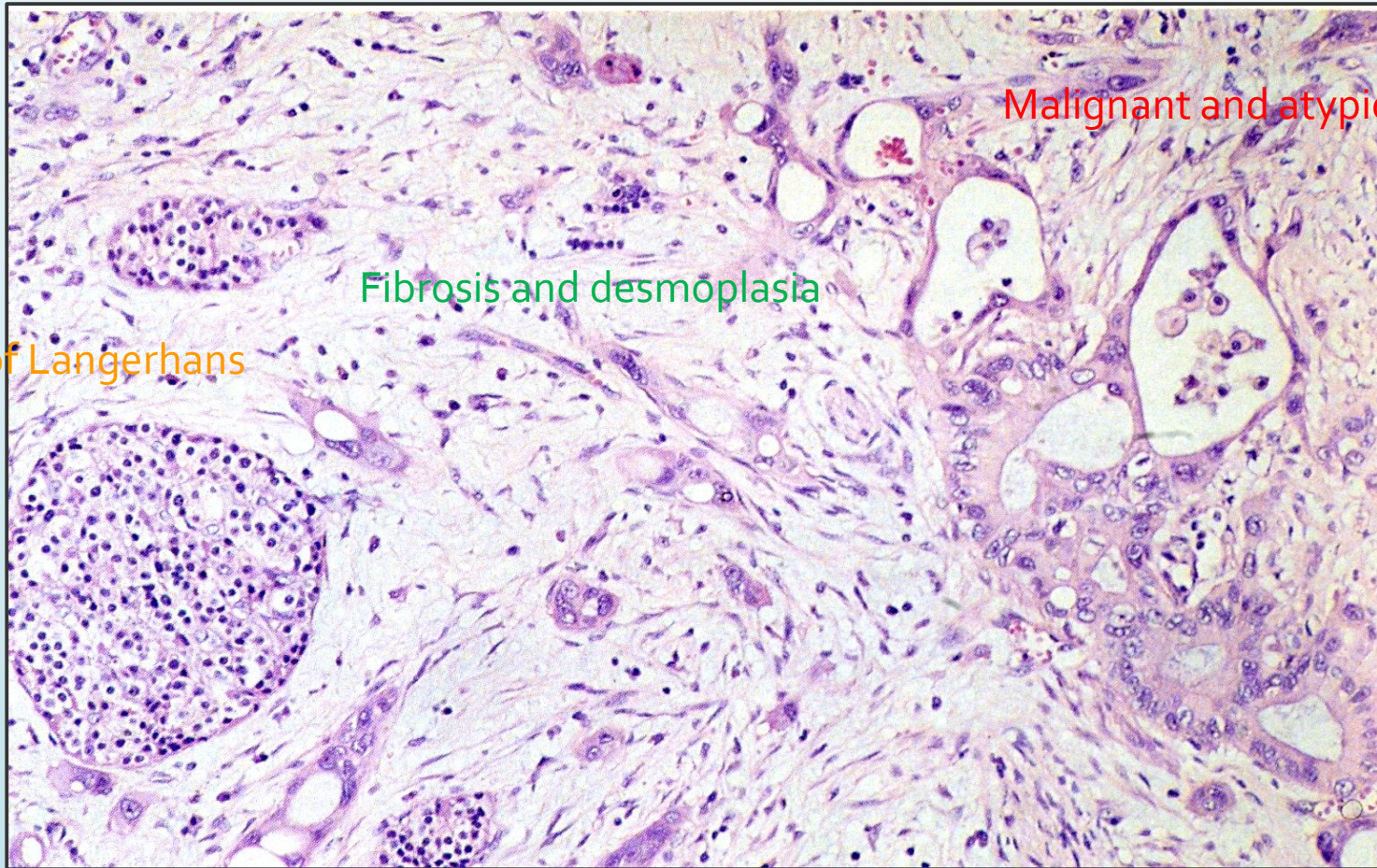
Gross appearance of large duct type ductal adenocarcinoma. A microcystic pattern with cysts measuring from millimeters up to 1 cm.

PANCREATIC ADENOCARCINOMA – Gross & LPF



***Gross picture shows ill defined pale and firm pancreatic mass (left).
Microscopic picture shows malignant glands or acini surrounded by
desmoplastic fibrous stroma (right) .***

PANCREATIC ADENOCARCINOMA – LPF



Malignant and atypical glands

Fibrosis and desmoplasia

Islet of Langerhans

Deeply infiltrative growth pattern with irregular shape and distribution , Desmoplasia , Marked nuclear pleomorphism with nucleoli, Loss of polarity and Mitotic figures

THE END