



Endocrine Block ***Pathology Practical***

Prepared by: • *Prof. Ammar Al Rikabi*
• *Dr. Sayed Al Esawy*

Head of Pathology Department: Dr. Hisham Al Khalidi

Objectives:

At the end of the practical sessions of the endocrine block, the students will be able to:

- Identify the gross macroscopic picture of thyroid and suprarenal nodules.
- Describe the microscopic picture of thyroid adenomas and carcinomas.
- Recognize the histopathological changes found in thyroid and suprarenal tumors.

CONTENTS:

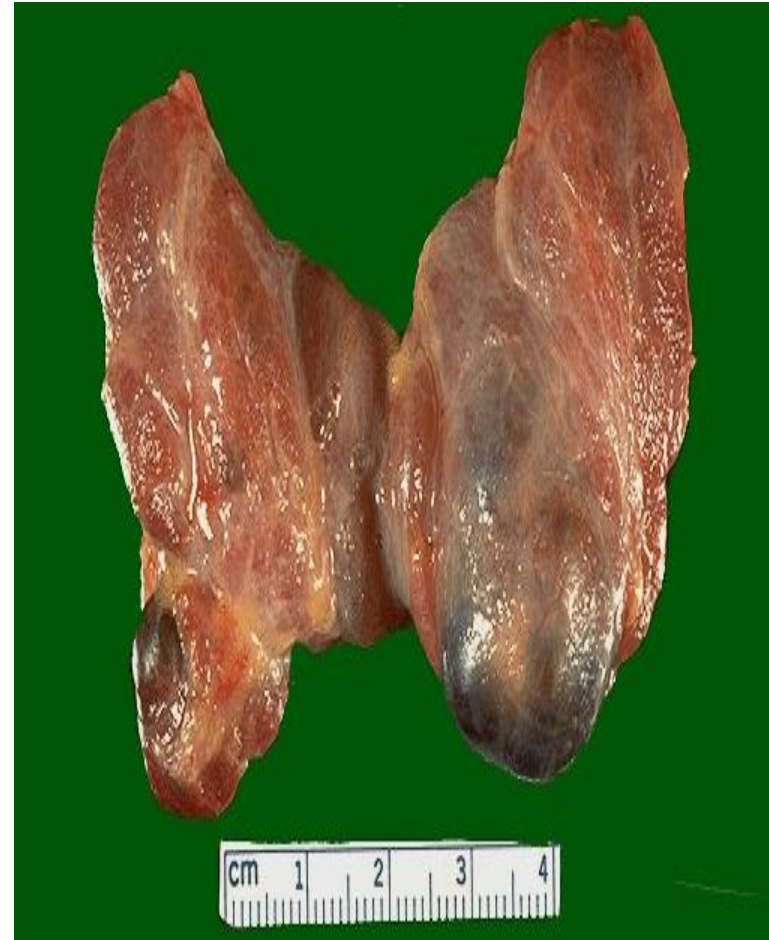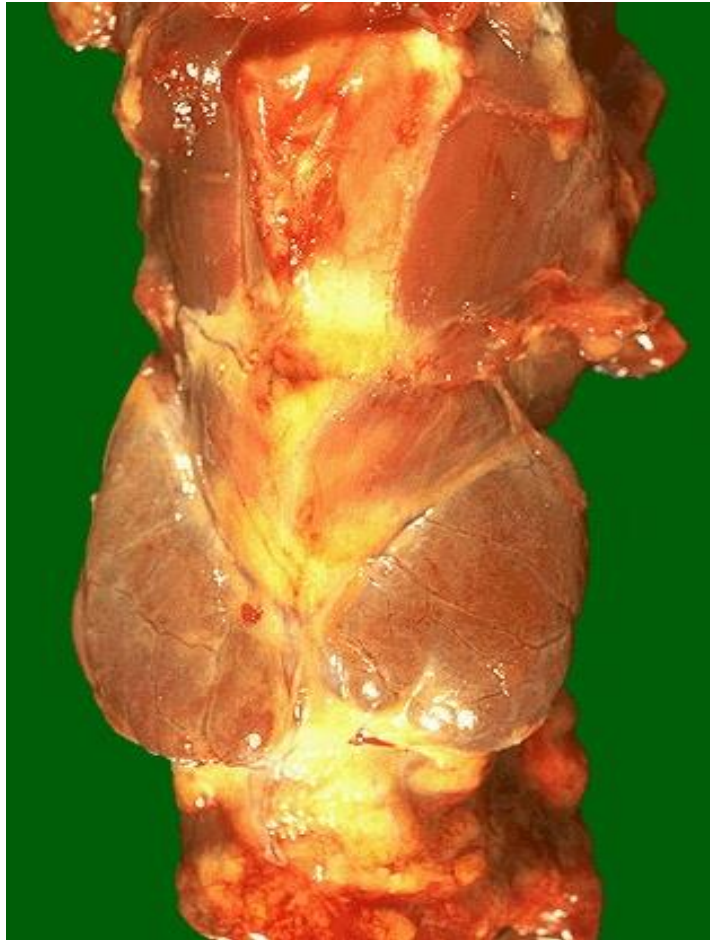Gross pathology and histopathology section pictures of:

- (1) Multinodular goiter.
- (2) Hashimoto's thyroiditis.
- (3) Papillary thyroid carcinoma.
- (4) Addison's disease.
- (5) Cushing syndrome.
- (6) Follicular adenoma.
- (7) Pheochromocytoma.



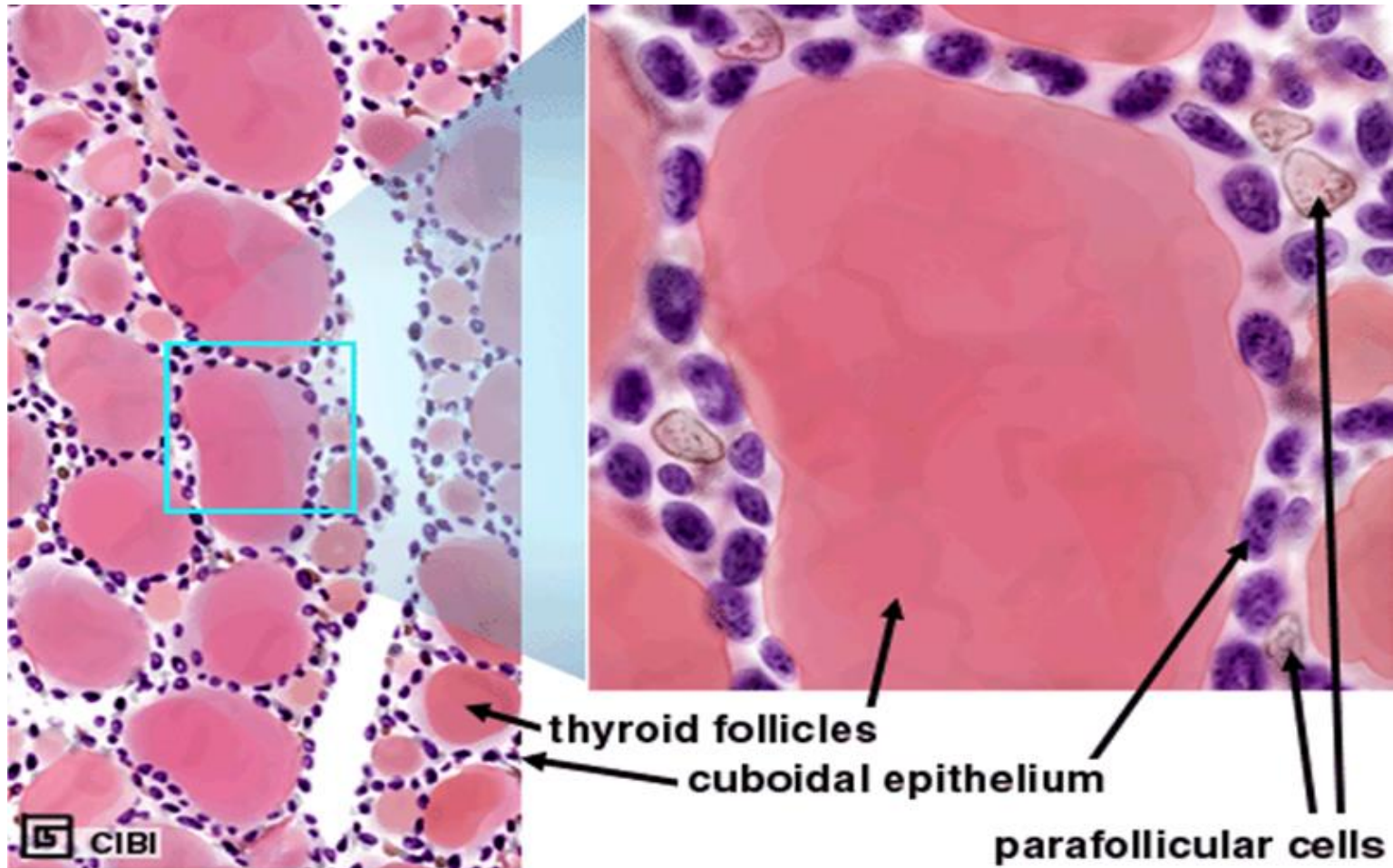
Normal Anatomy & Histology

Normal anatomy of thyroid gland



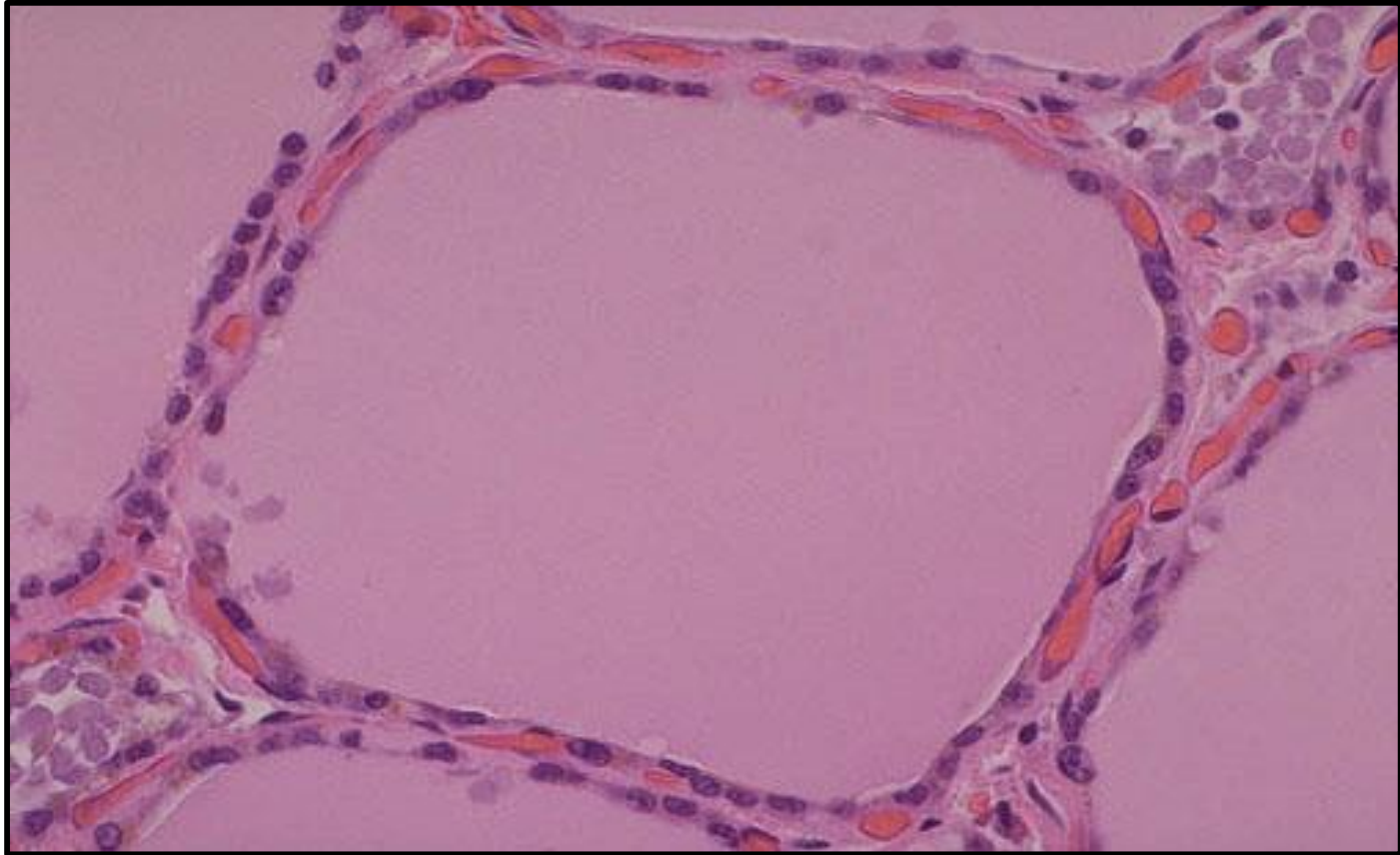
The normal appearance of the thyroid gland (15-25 g) on the anterior trachea of the neck. The thyroid gland has a right lobe and a left lobe connected by a narrow isthmus. A normal thyroid cannot easily be palpated on physical examination

Normal Histology of Thyroid gland – LPF&HPF



Normal thyroid seen microscopically consists of follicles lined by a cuboidal epithelium and filled with pink, homogenous colloid. The follicles vary somewhat in size. The interstitium, which may contain "C" cells, is not prominent.

Normal Histology of Thyroid gland - HPF



This normal thyroid follicle is lined by a cuboidal follicular epithelial cells that can add or subtract colloid depending upon the degree of stimulation from TSH (thyroid stimulating hormone) released by the pituitary gland. As in all endocrine glands, the interstitium has a rich vascular supply into which hormone is secreted.

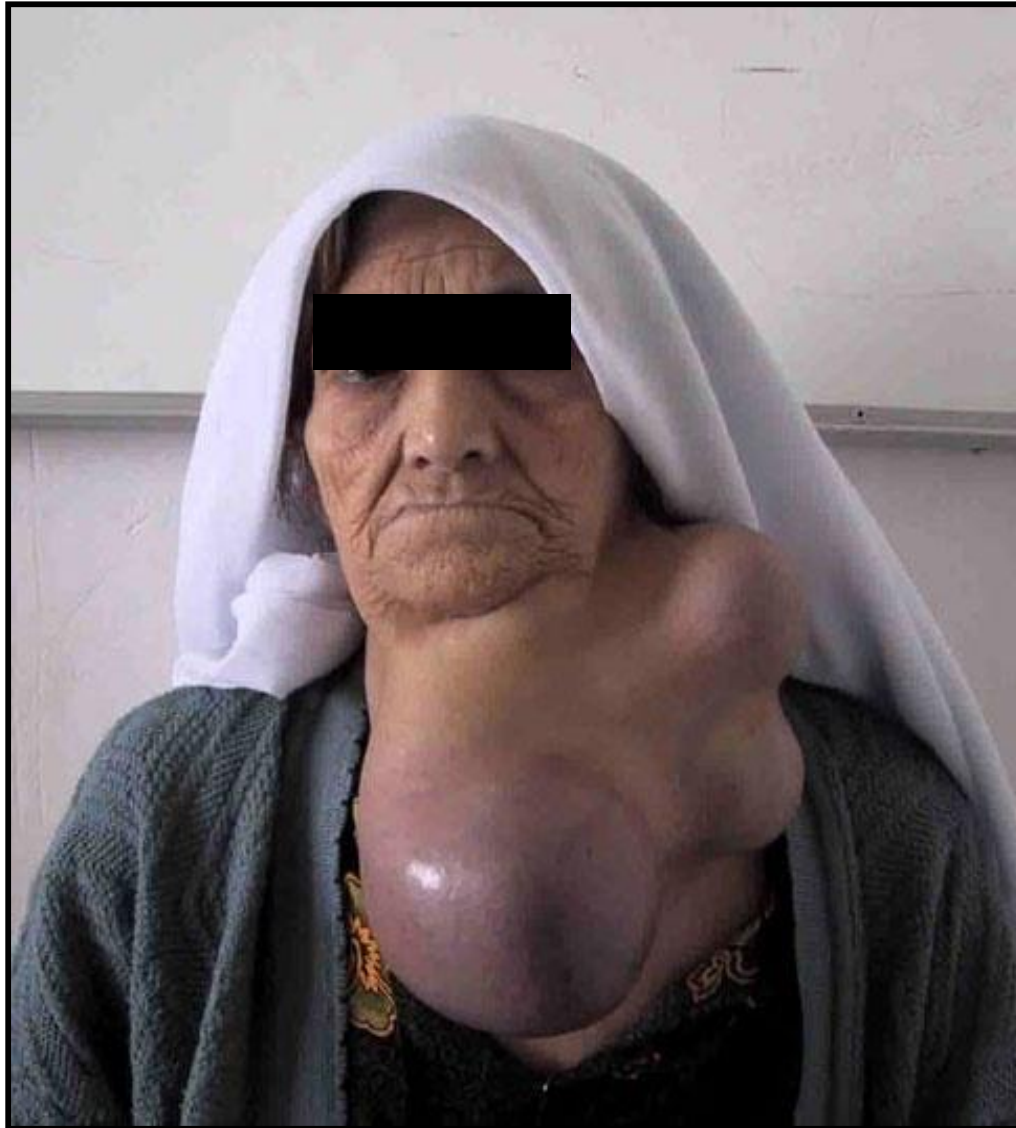

Gross and Histopathology

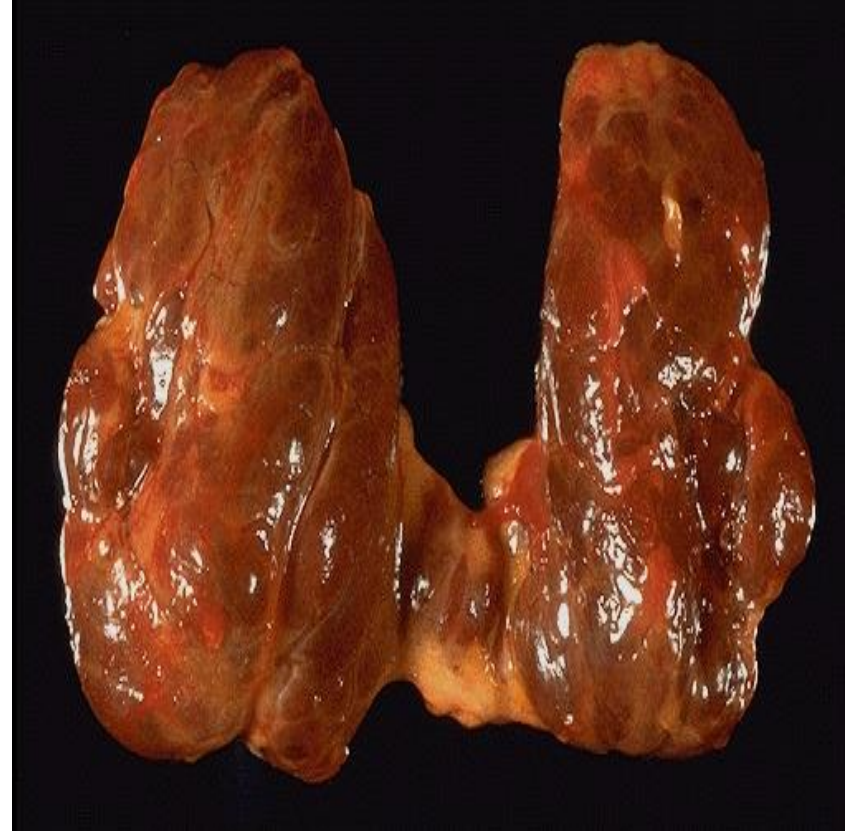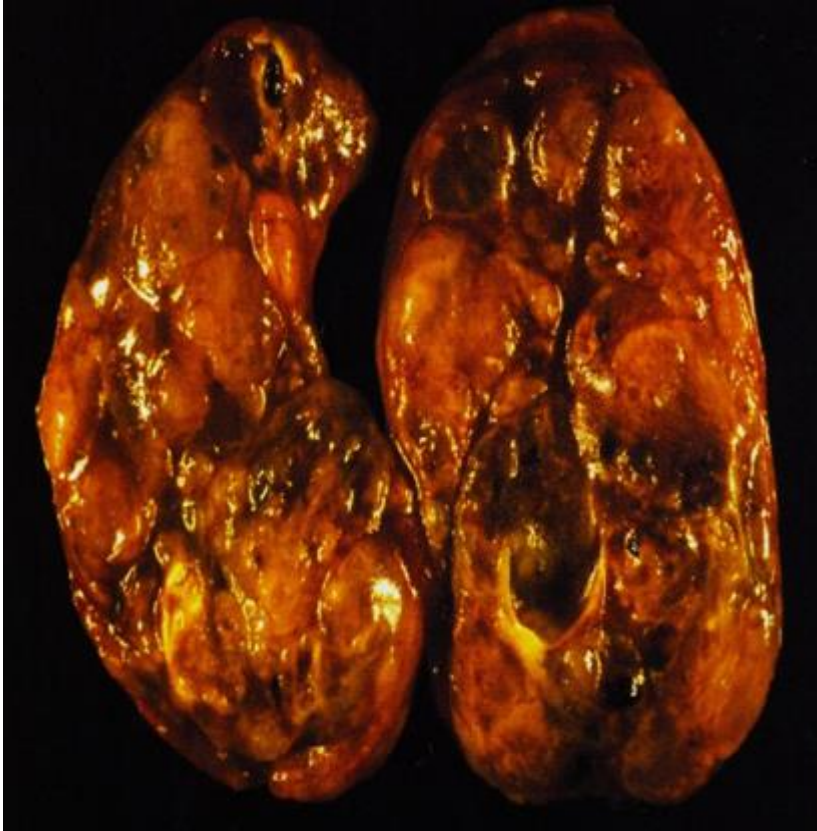


1- Multinodular Goiter

Multinodular Goiter – Clinical

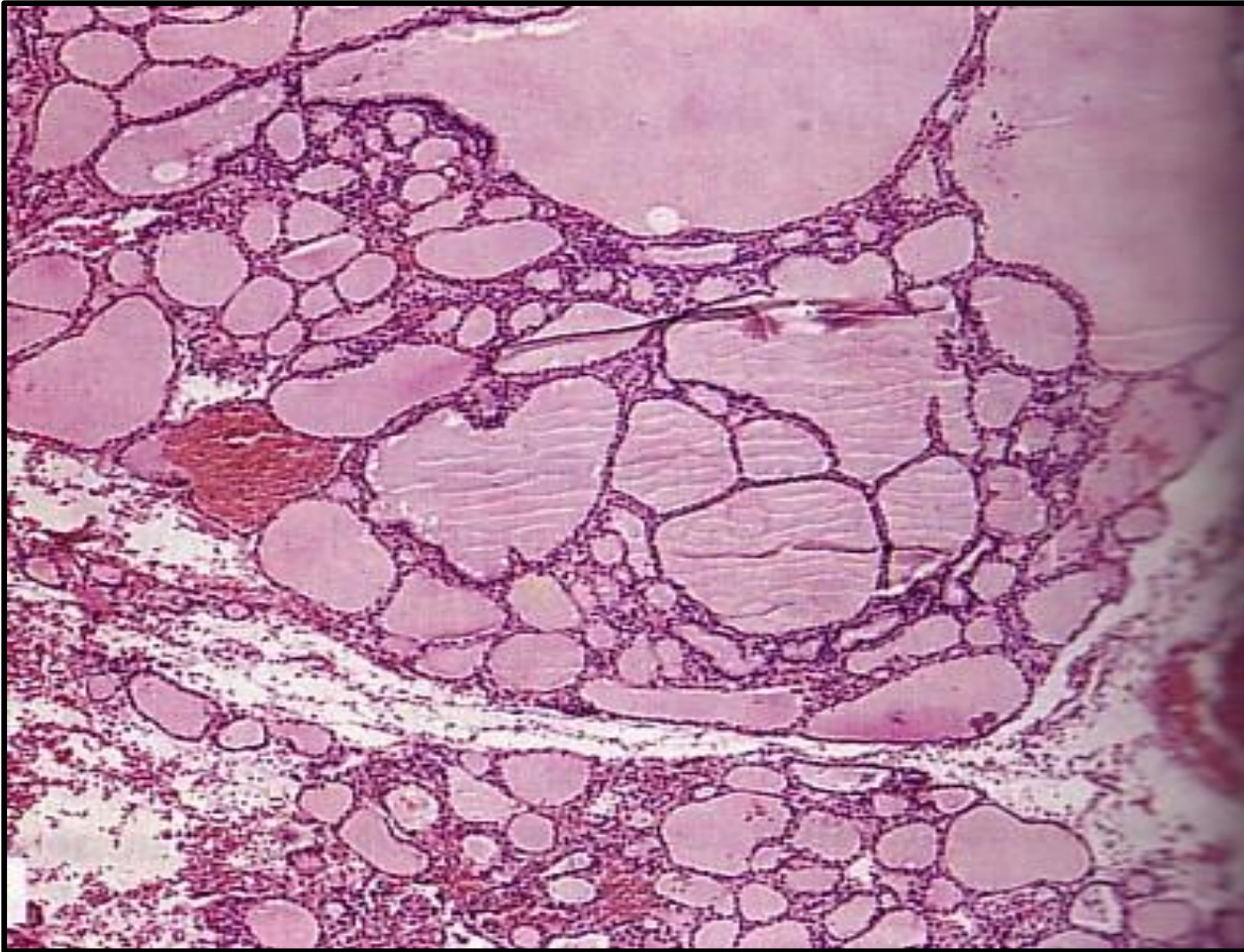

Multinodular Goiter - Gross



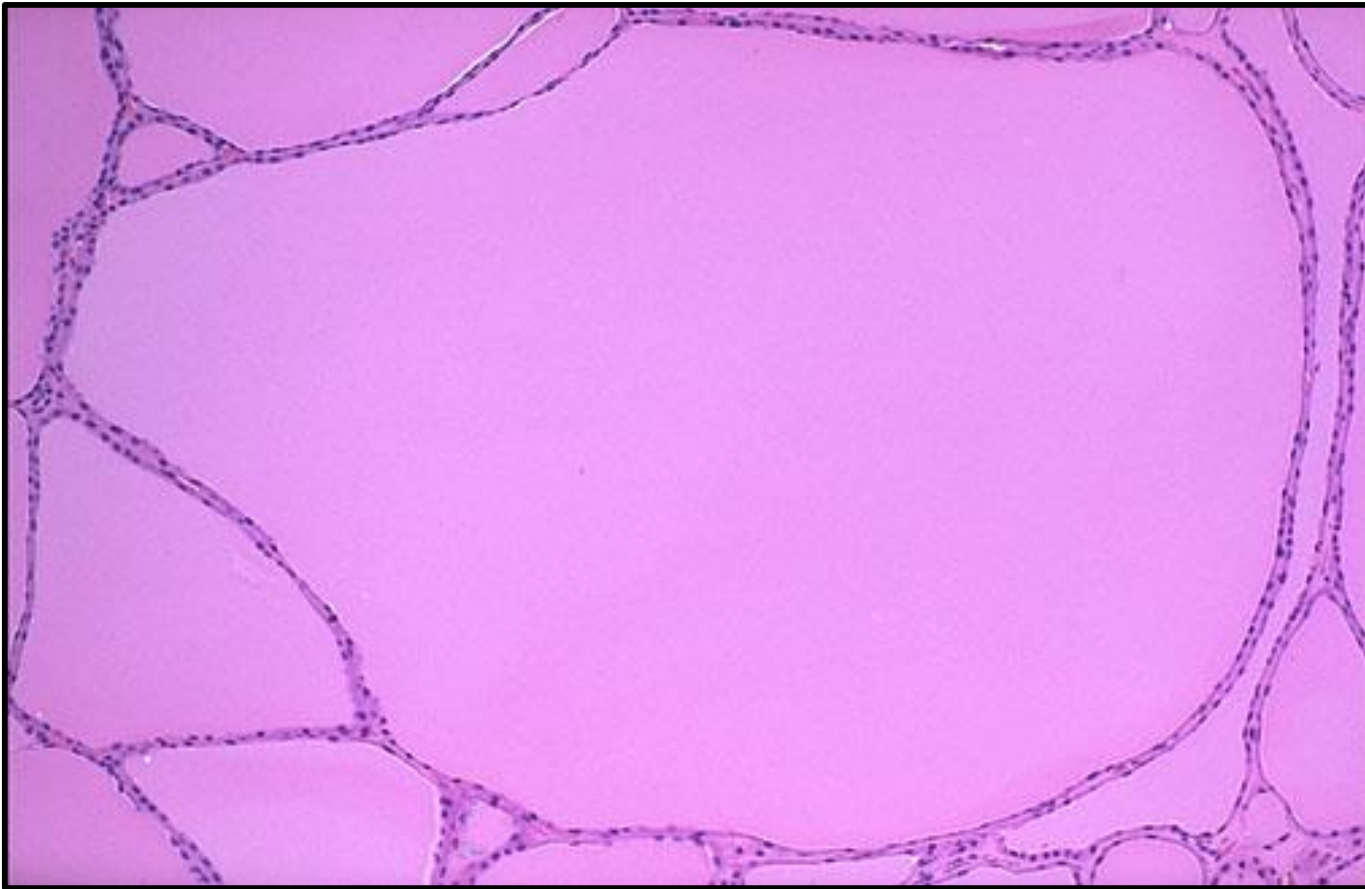
This diffusely asymmetric enlarged thyroid gland is nodular with haemorrhage and cystic degeneration. This patient was euthyroid. This represents the most common cause for an enlarged thyroid gland and the most common disease of the thyroid

Multinodular Goiter - LPF



Numerous follicles varying in size filled with colloid. We can also see : Recent haemorrhage , Haemosiderin , Calcification & Cystic degeneration

Multinodular Goiter - LPF



The follicles are irregularly enlarged, with flattened epithelium, consistent with inactivity, in this microscopic appearance at low power of a multinodular goiter.



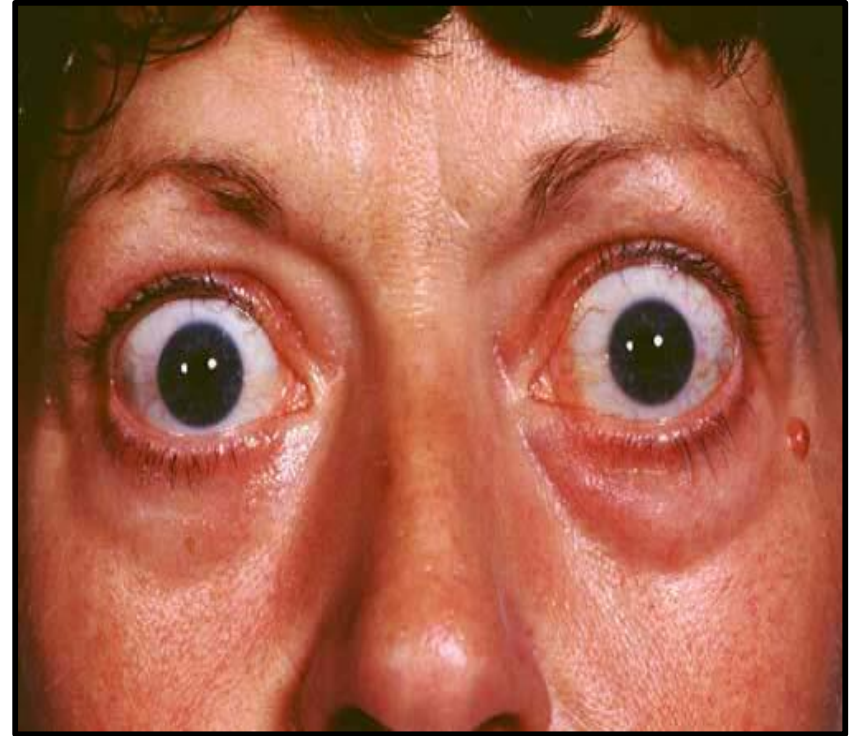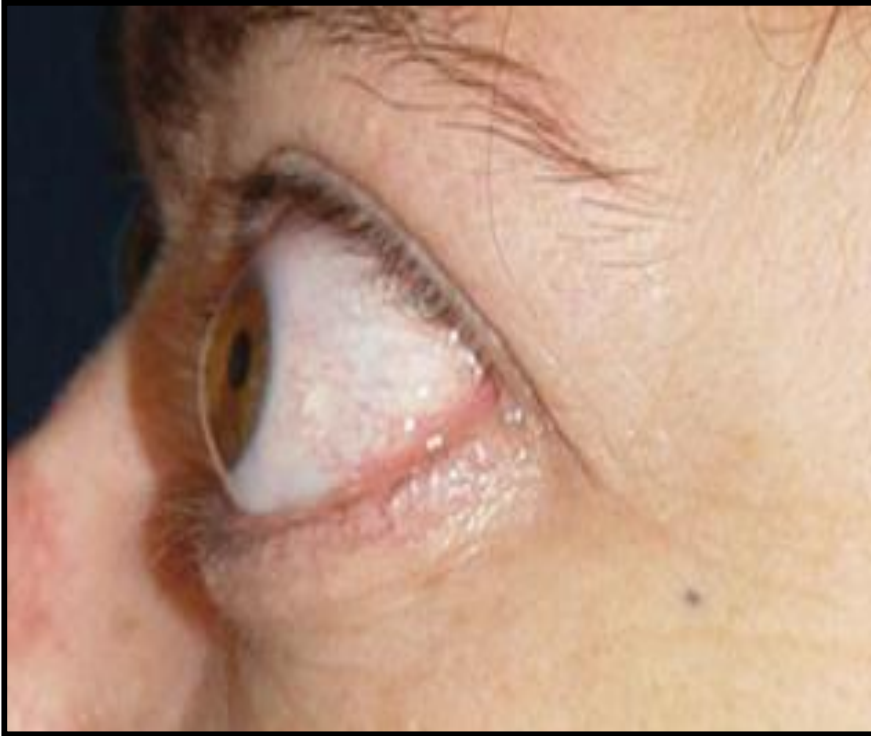
2- Hyperthyroidism & Grave's Disease

HYPERTHYROIDISM

CLINICALLY:

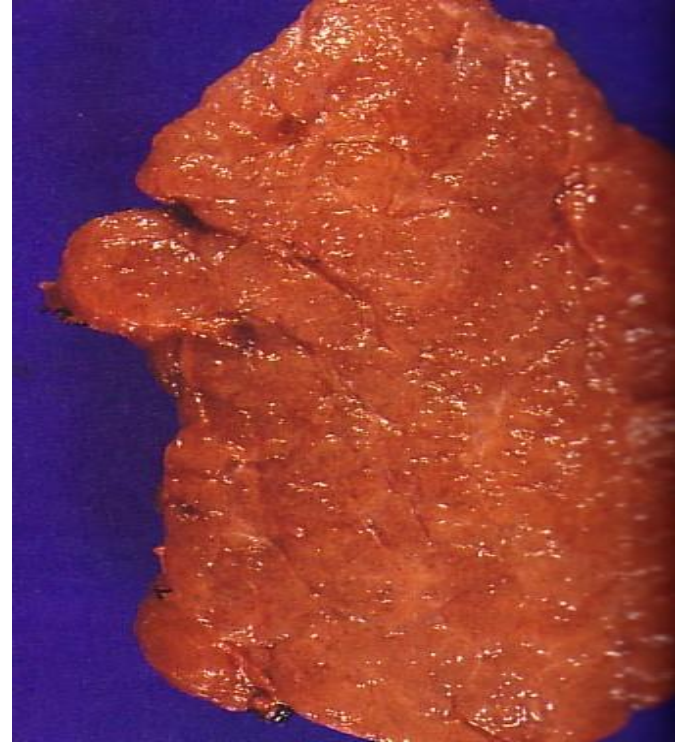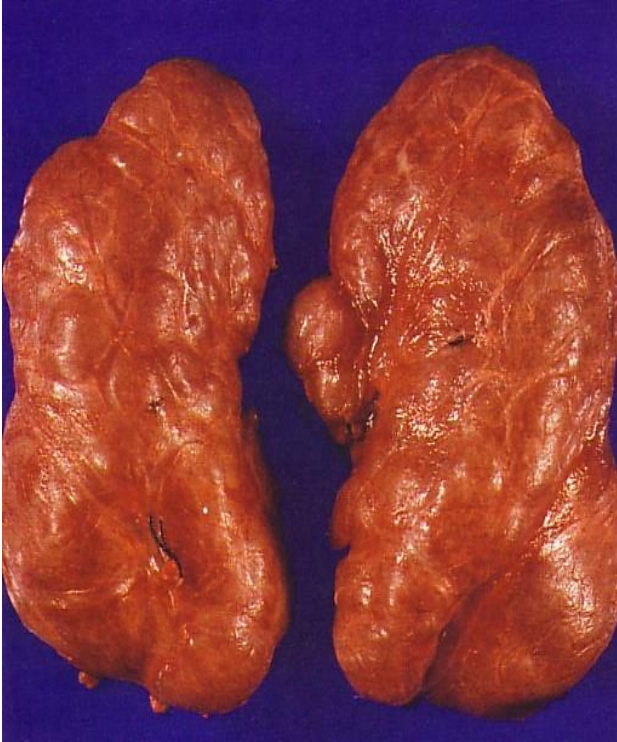- ***Hypermetabolism***
- ***Tachycardia, palpitations***
- ***Increased T₃, T₄***
- ***Goiter***
- ***Exophthalmos***
- ***Tremor***
- ***GIT hypermotility***
- ***Thyroid "storm", life threatening***

Exophthalmos – Sign of Grave's Disease



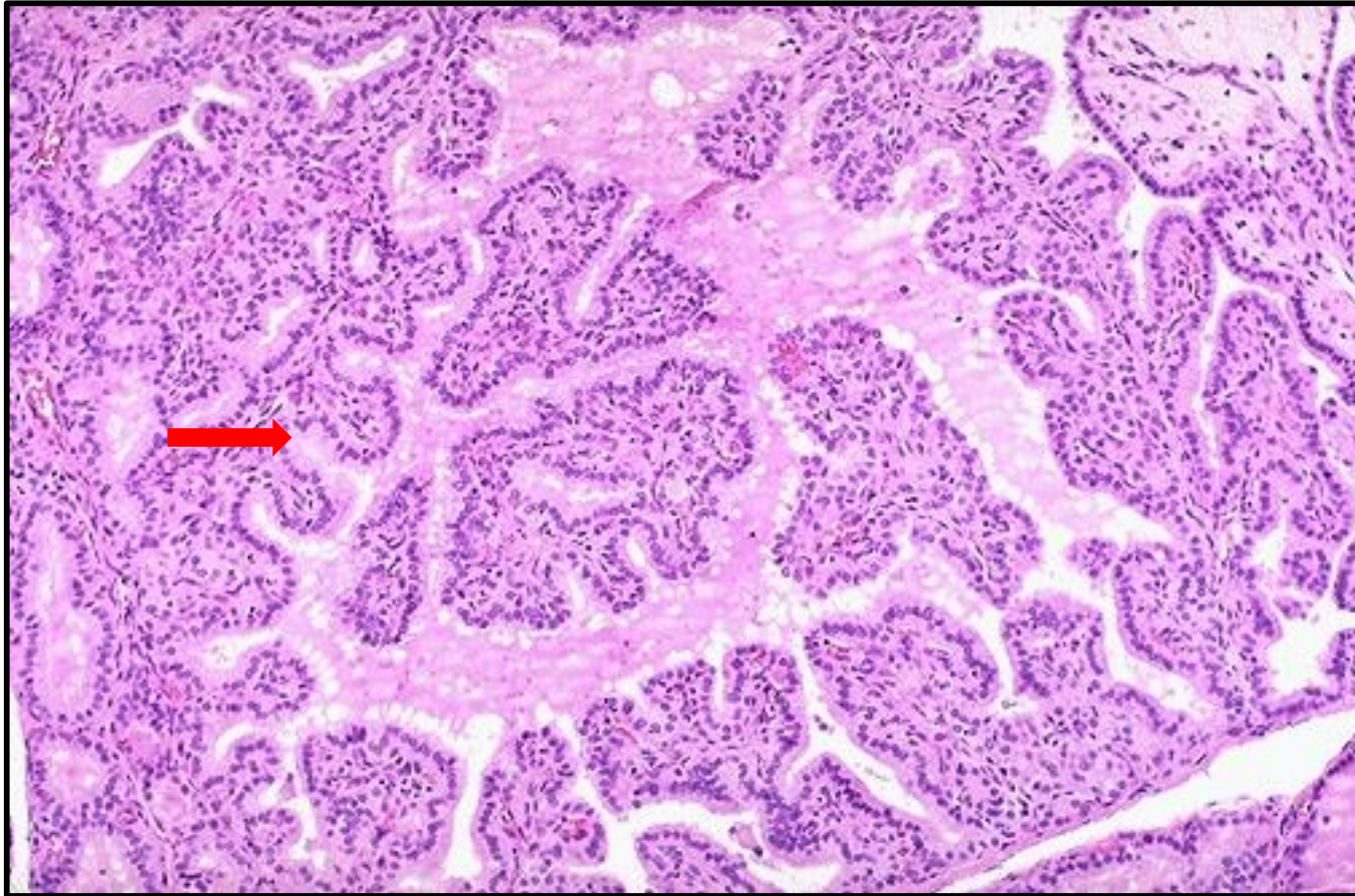
*Proptosis, Lid lag , Lid retraction , Peri-ocular fat deposition
and Scleral rim above the iris*

Grave's Disease - Gross



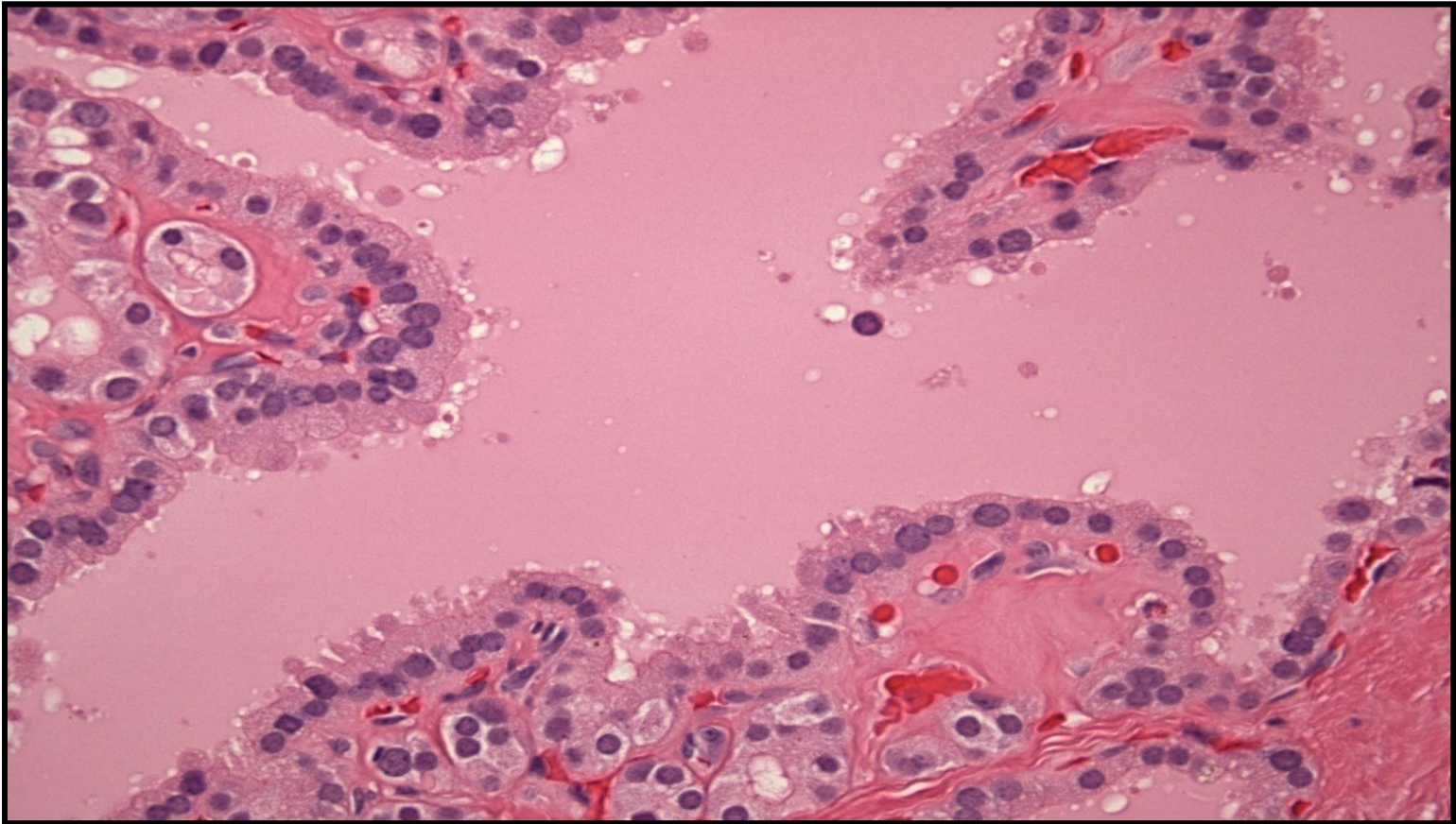
- *Symmetrical enlargement of thyroid gland*
- *Cut-surface is homogenous, soft and appear meaty*
- *Hyperplasia and hypertrophy of follicular cells*

Grave's Disease - LPF



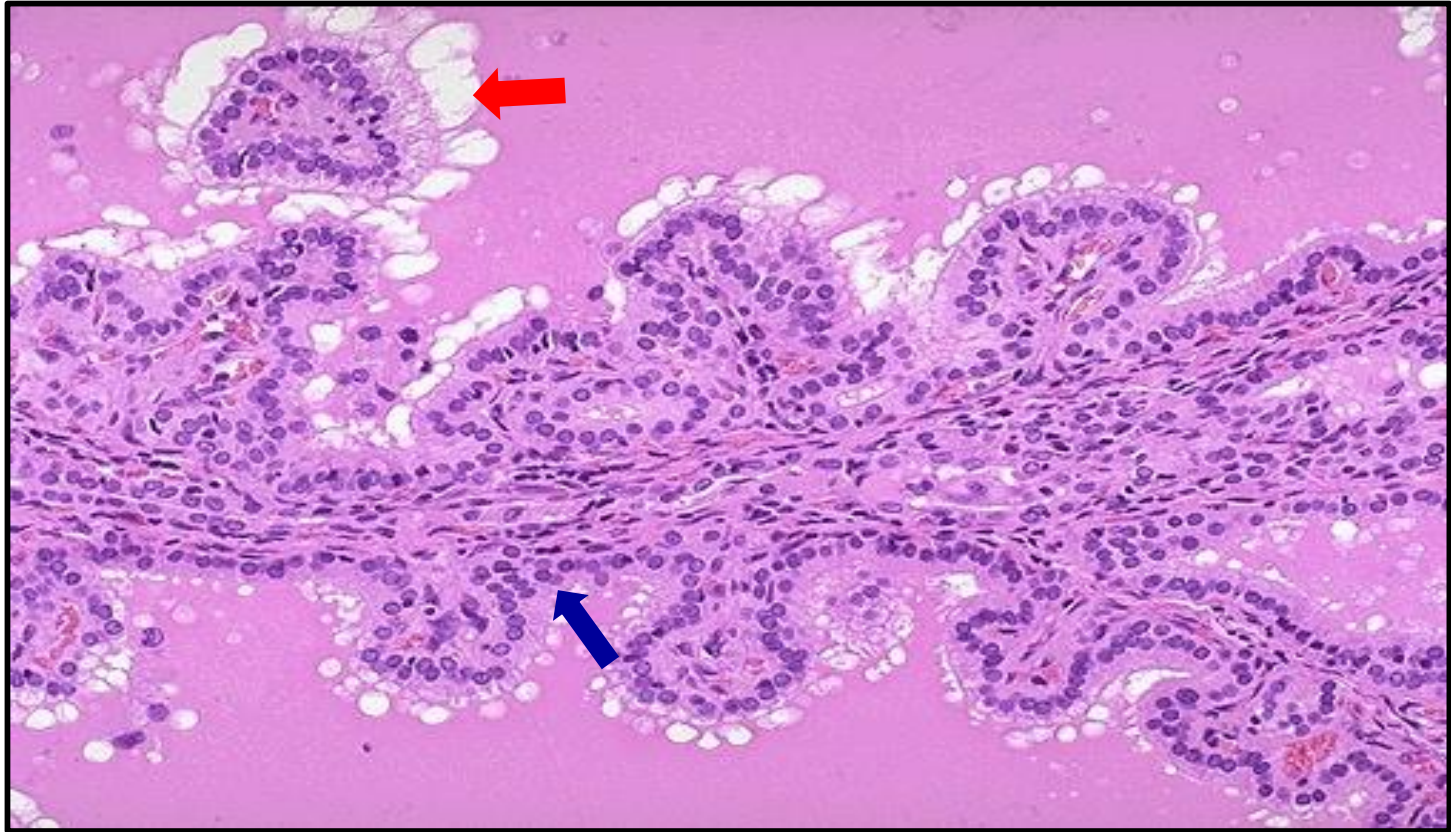
*A diffusely enlarged thyroid gland associated with hyperthyroidism is known as Graves disease. At LPF, note the prominent **infoldings** of the hyperplastic follicular epithelium*

Grave's Disease - HPF



Section shows thyroid follicles lined by columnar and high cuboidal cells with evidence of peripheral vacuoles within the intrafollicular colloid material . Note the presence of peripheral smaller thyroid follicles devoid of colloid but lined by similar cells

Grave's Disease - HPF

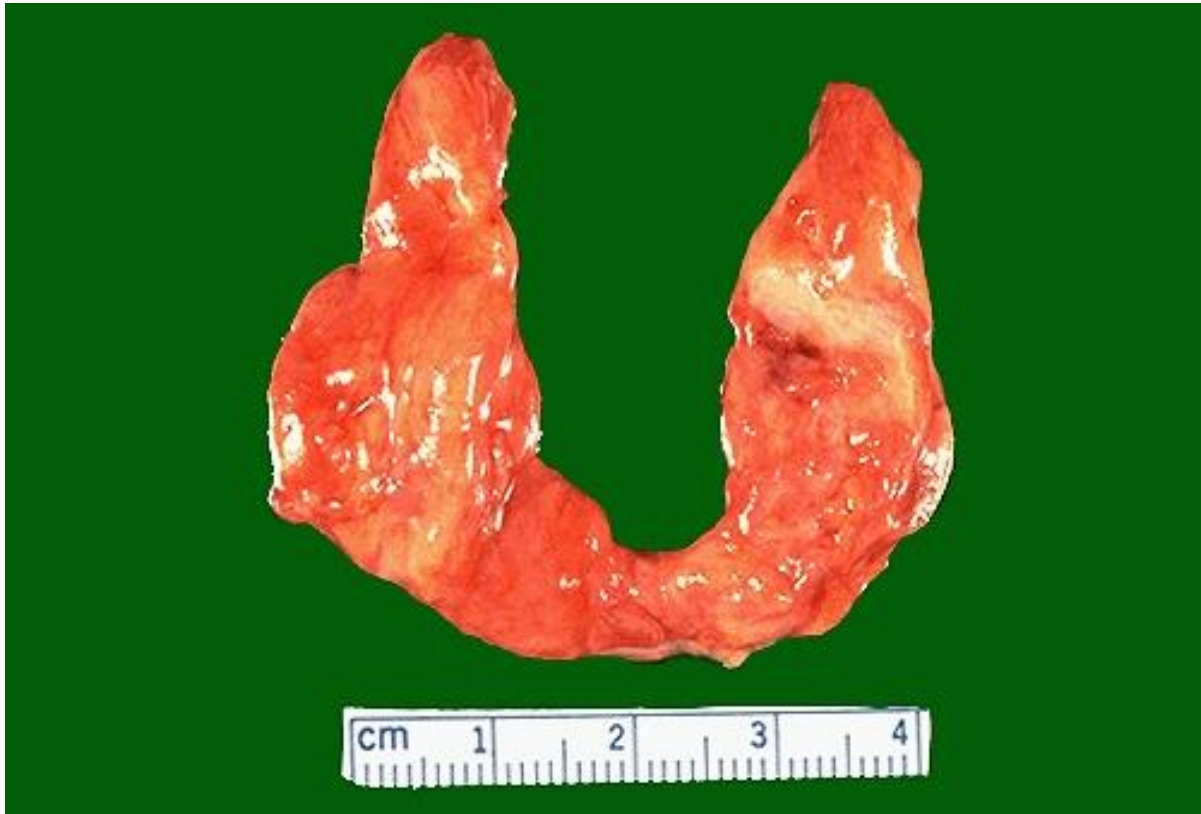

*Hyperplastic thyroid epithelial columnar cells. Note the **vacuolation of colloid** next to the epithelium where the increased activity of the epithelium to produce increased thyroid hormone has led to scalloping out of the colloid in the follicle.*



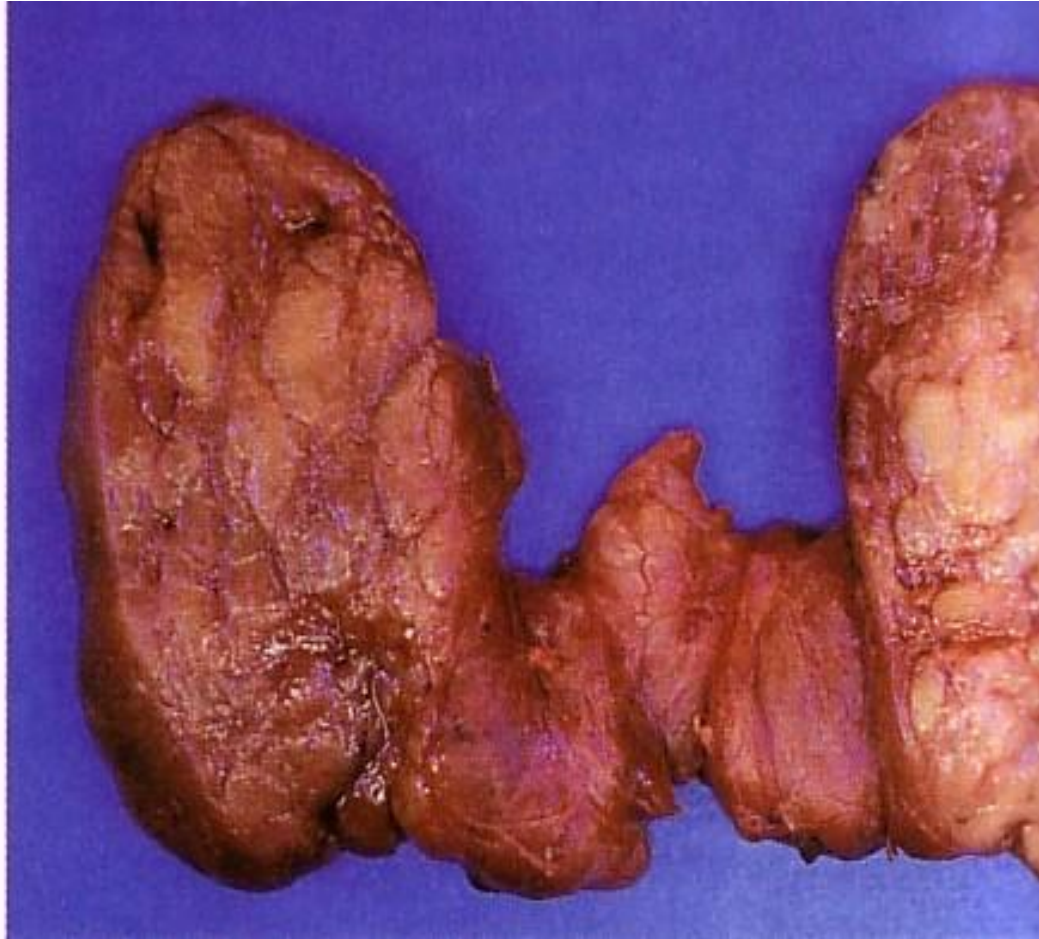
3- Hashimoto's Thyroiditis

Hashimoto's Thyroiditis, Gross



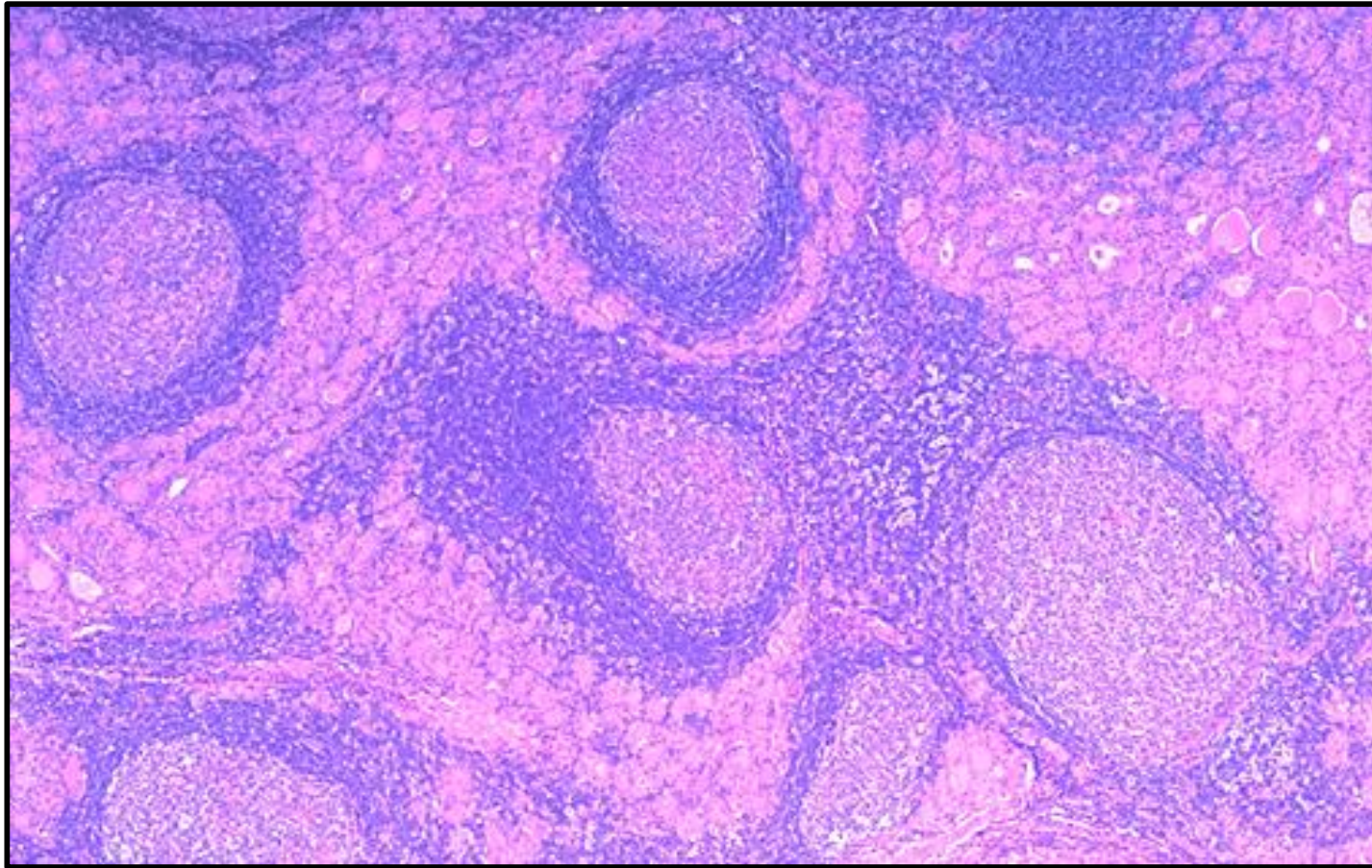
This symmetrically small thyroid gland demonstrates atrophy. This patient was hypothyroid. This is the end result of Hashimoto's thyroiditis. Initially, the thyroid is enlarged and there may be transient hyperthyroidism, followed by a euthyroid state and then hypothyroidism with eventual atrophy years later. Complications like B cell lymphoma and Papillary carcinoma (PTC) might occur.

Hashimoto's Thyroiditis - Gross



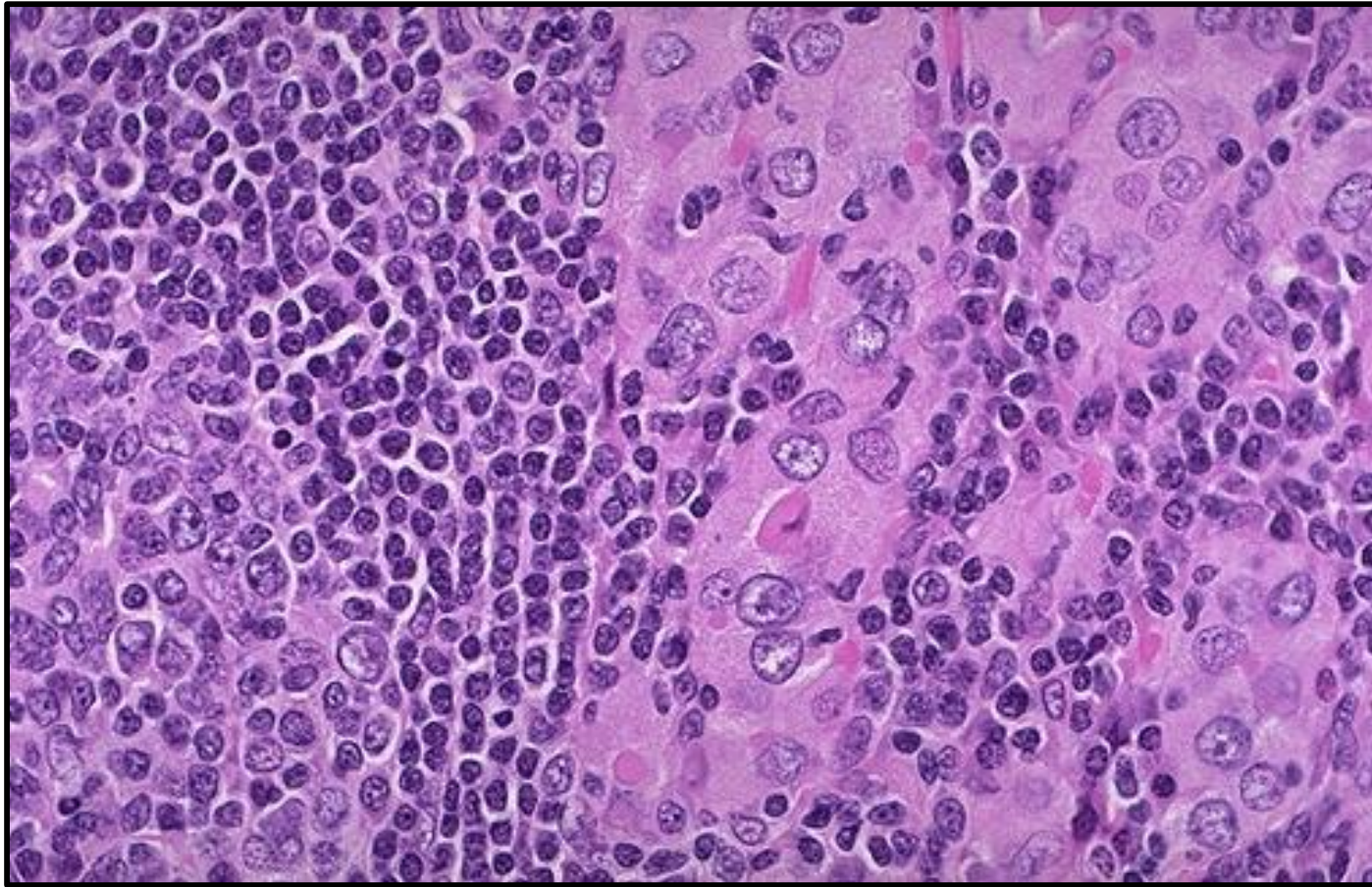
Pale, yellow-tan, firm & slightly nodular cut surface.

Hashimoto's Thyroiditis - LPF



This view shows an early stage of Hashimoto thyroiditis with prominent lymphoid follicles containing large, active germinal centers. In this autoimmune disease, antithyroglobulin and antimicrosomal (thyroid peroxidase) autoantibodies can often be detected in serum (Autoimmune T cell mediated).

Hashimoto's Thyroiditis - HPF

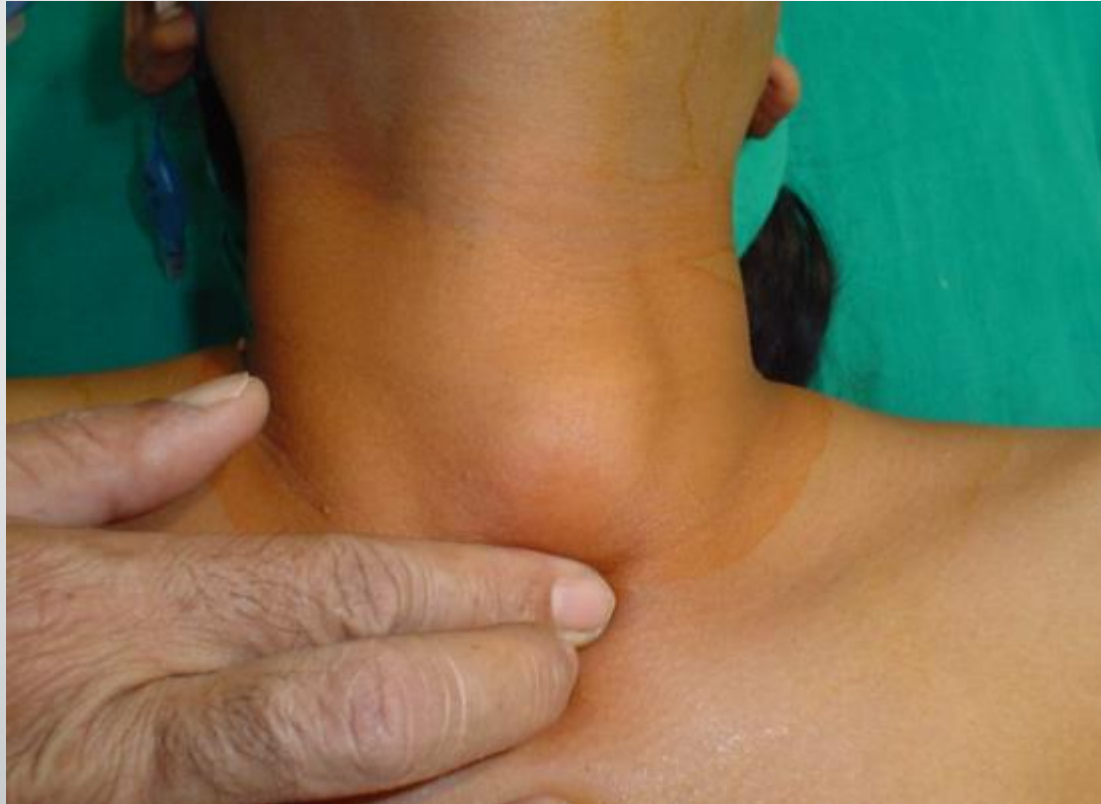

- *Hurthle cell or oxyphil cell change.*
- *Lymphocytic infiltration with lymphoid follicles formation.*



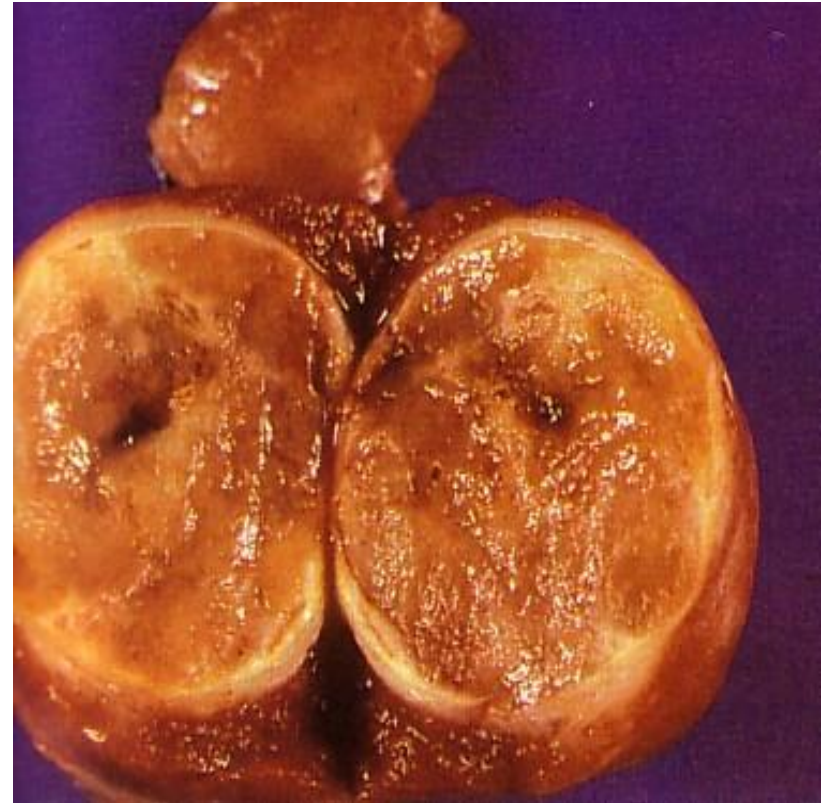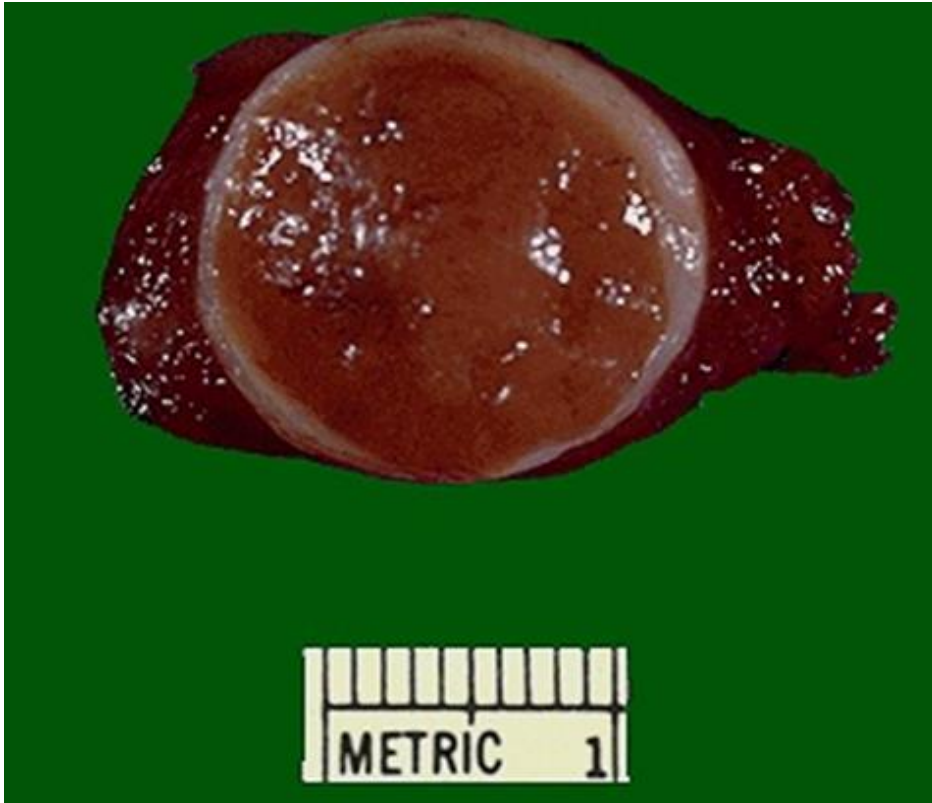
4- Follicular Adenoma

Solitary Thyroid nodule



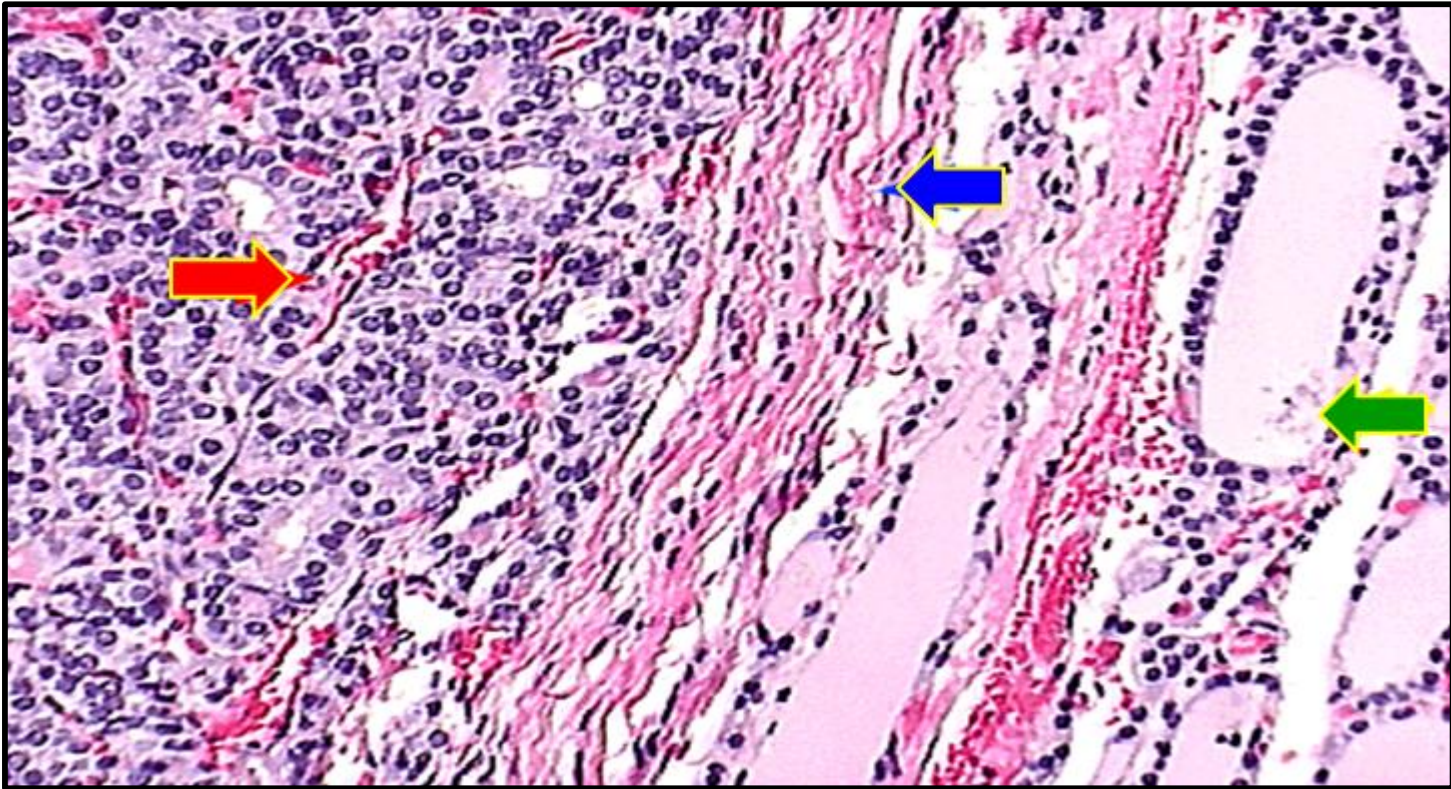
Central and slightly left sided thyroid nodule.

Follicular Adenoma – Gross cut section



- *Well circumscribed and encapsulated tumor nodule.*
- *Pale and yellowish cut-surface.*

Follicular Adenoma – LPF

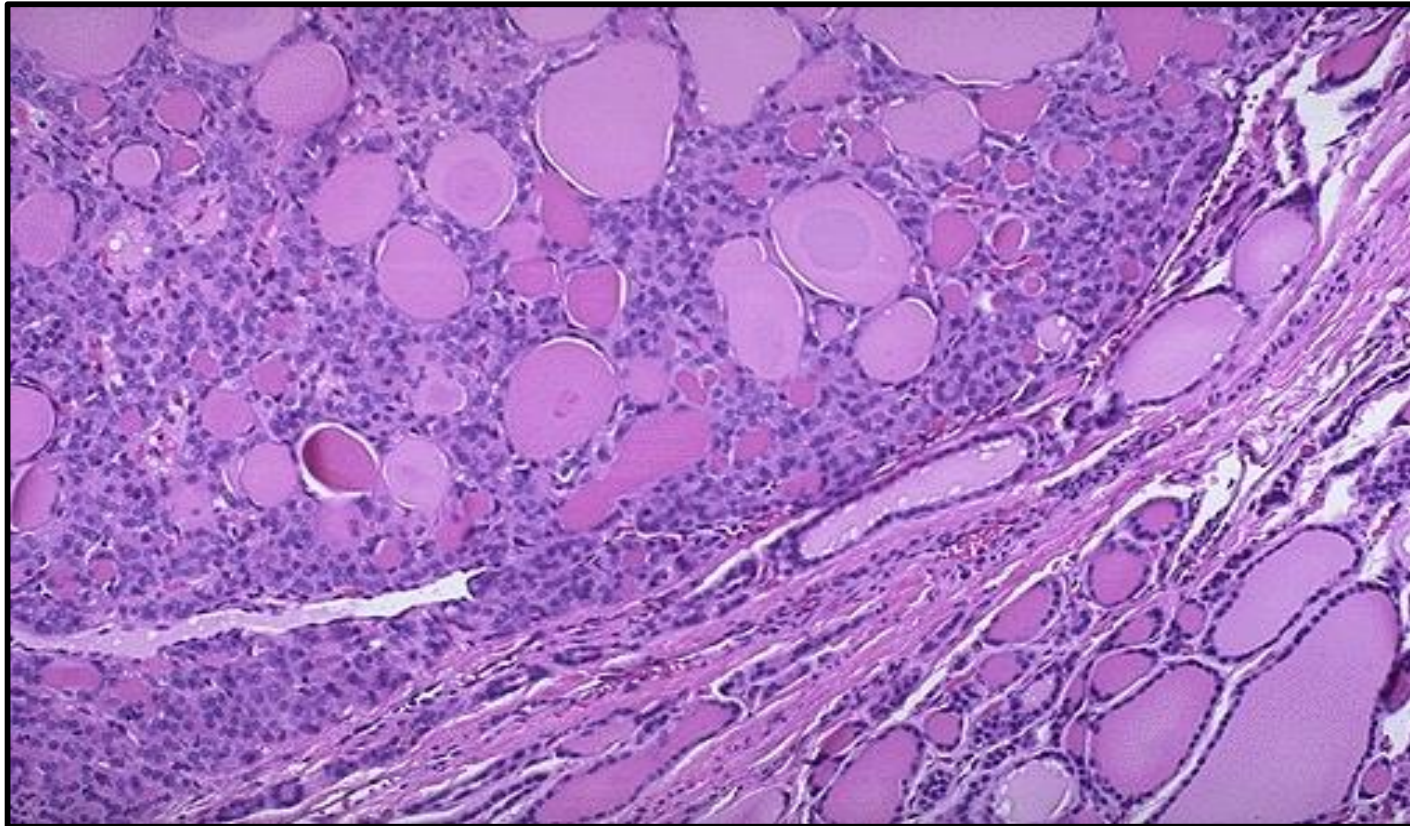


The **Red arrow** is located within the adenoma showing Small neoplastic follicles with little colloid material.


The **Blue arrow** points to the capsule of the adenoma.

The **Green arrow** points to Normal thyroid follicles outside the tumor.

Follicular Adenoma – HPF

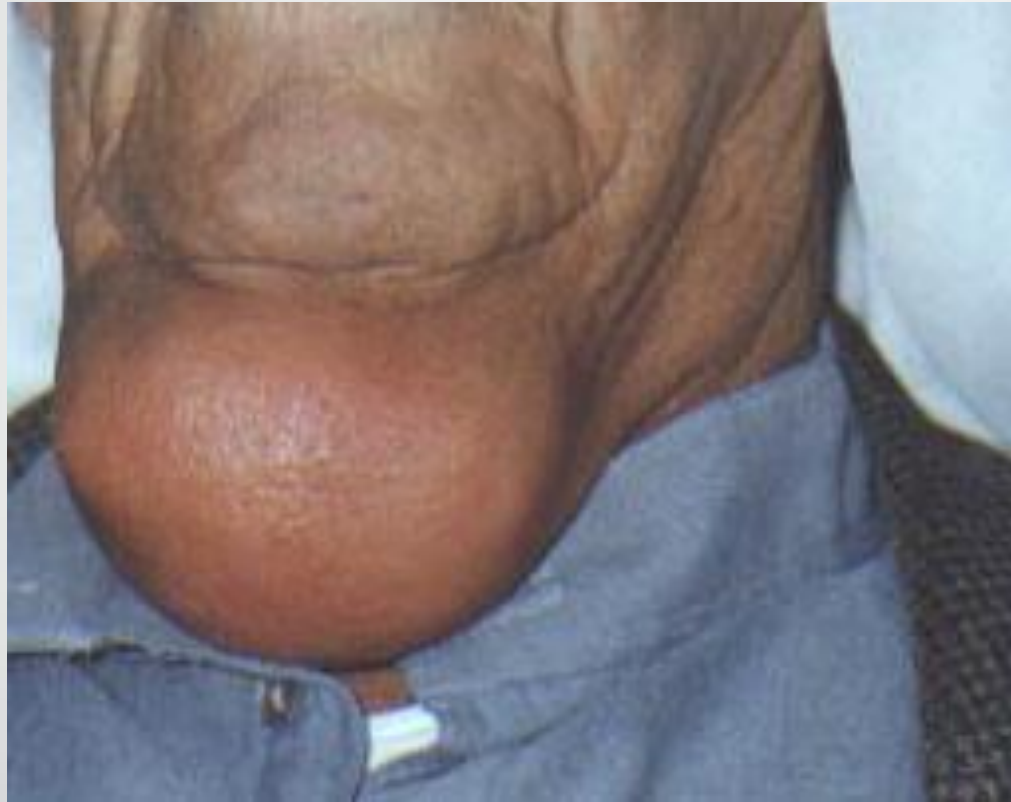

Normal thyroid follicles appear at the lower right. The follicular adenoma is at the center to upper left. This adenoma is a well- differentiated neoplasm because it closely resemble normal tissue. Pathologic features that if present they will indicate malignant transformation are Capsular invasion and Vascular invasion.



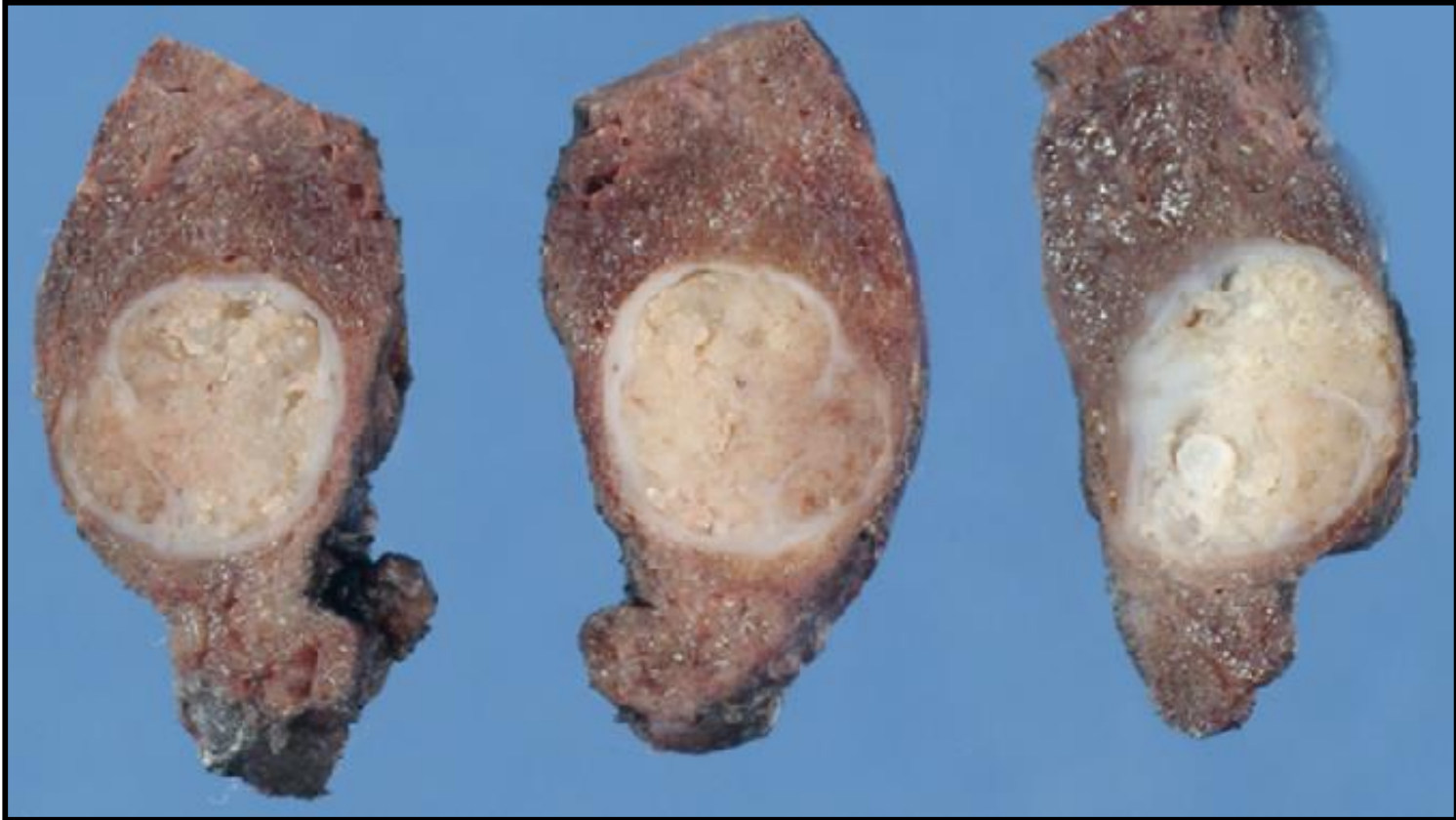5- Papillary Thyroid Carcinoma

Papillary Thyroid Carcinoma



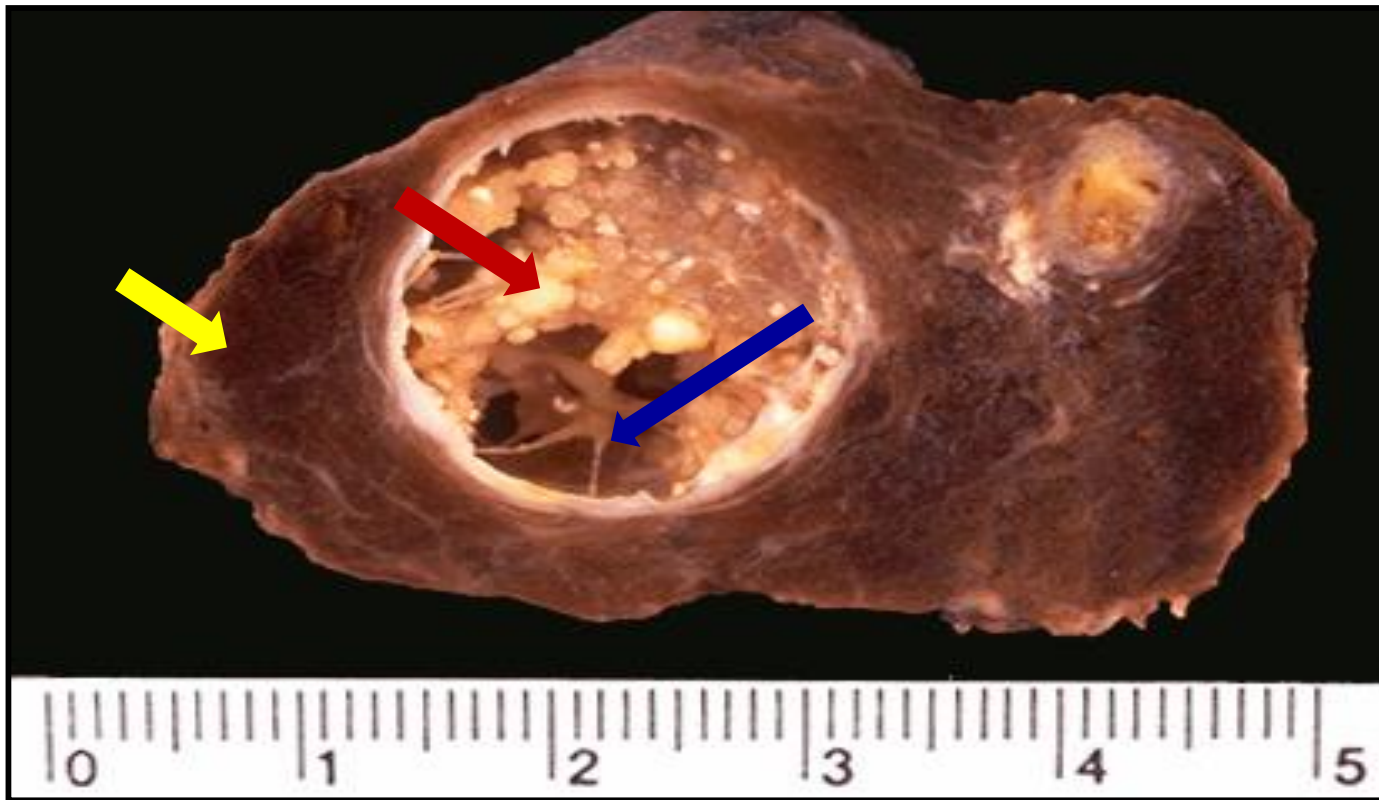
Huge thyroid swelling due to papillary thyroid carcinoma

Papillary Thyroid Carcinoma– Gross



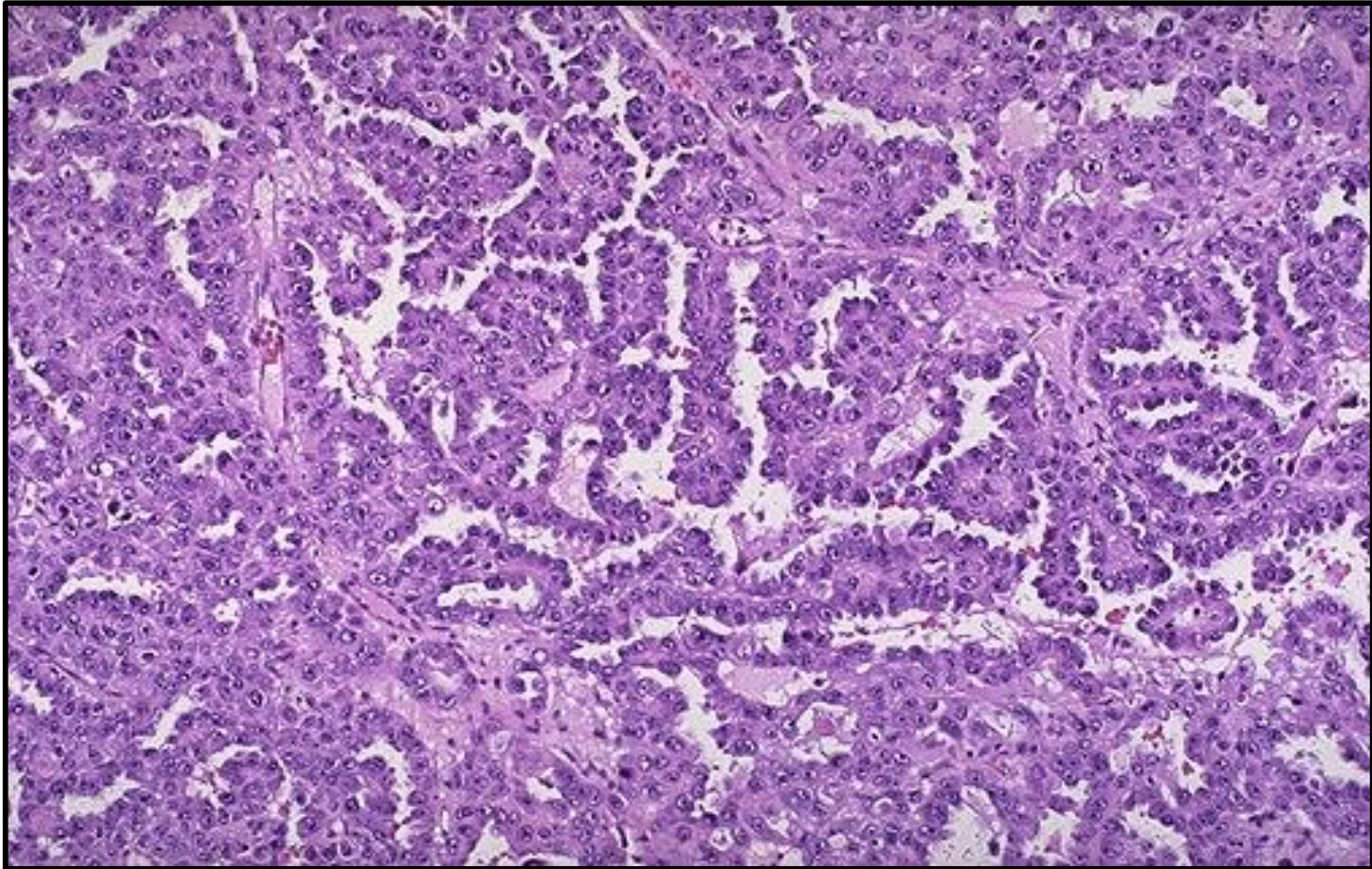
A relatively well circumscribed pale and firm nodule showing a whitish cut surface with vague scattered papillary areas .

Multifocal Papillary Thyroid Carcinoma – Gross cut section



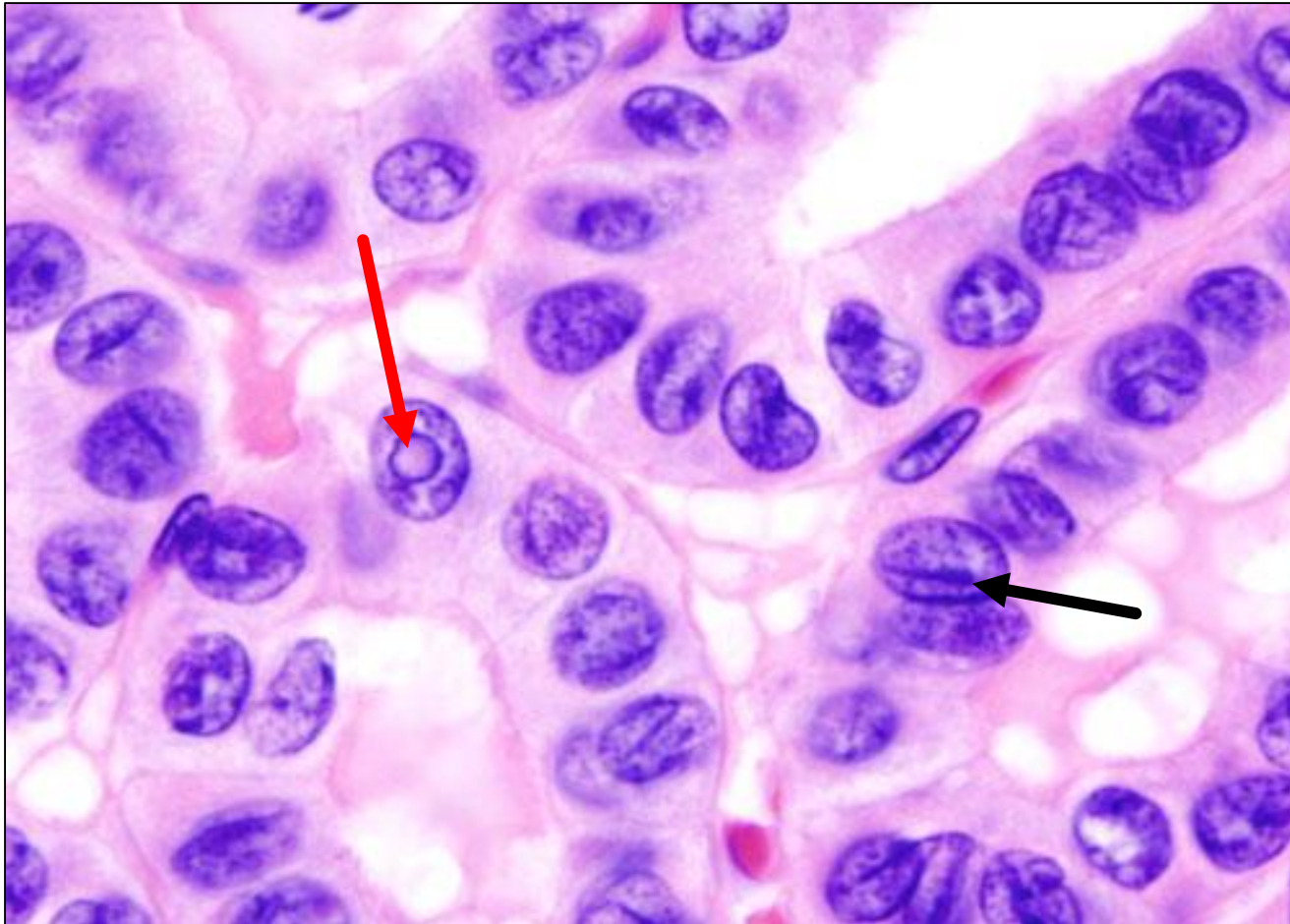
This neoplasm can be multifocal, as seen here, because of the propensity of this neoplasm to invade lymphatics within thyroid, and lymph node metastases are also common. The thyroid lobe is cystic and contains solid area with papillary structure.

Papillary Thyroid Carcinoma– LPF




*Sections show a papillary neoplasm consisting of papillary fronds lined by overlapping clear nuclei (Orphan Annie nuclei).
Calcified Psammoma bodies are also seen*

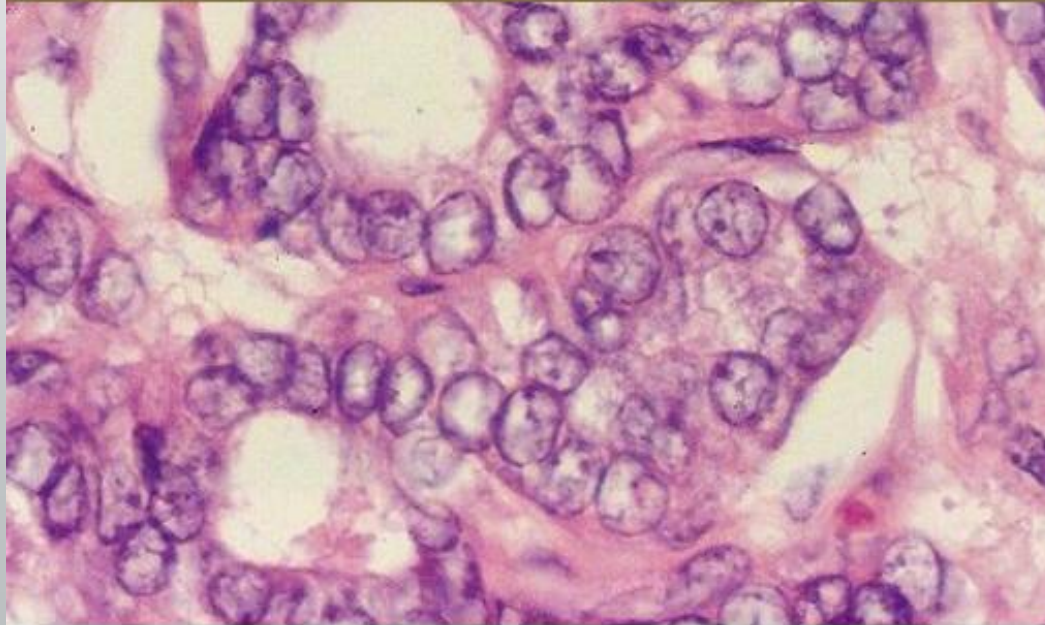
Papillary Thyroid Carcinoma– HPF



*High power microscopic field showing a classical papillary carcinoma of the thyroid gland. Note the presence of **intranuclear inclusion** and coffee bean nucleus with prominent nuclear groove.*



MORE THAN 1,000 COMICS featuring America's Spunkiest Kid!



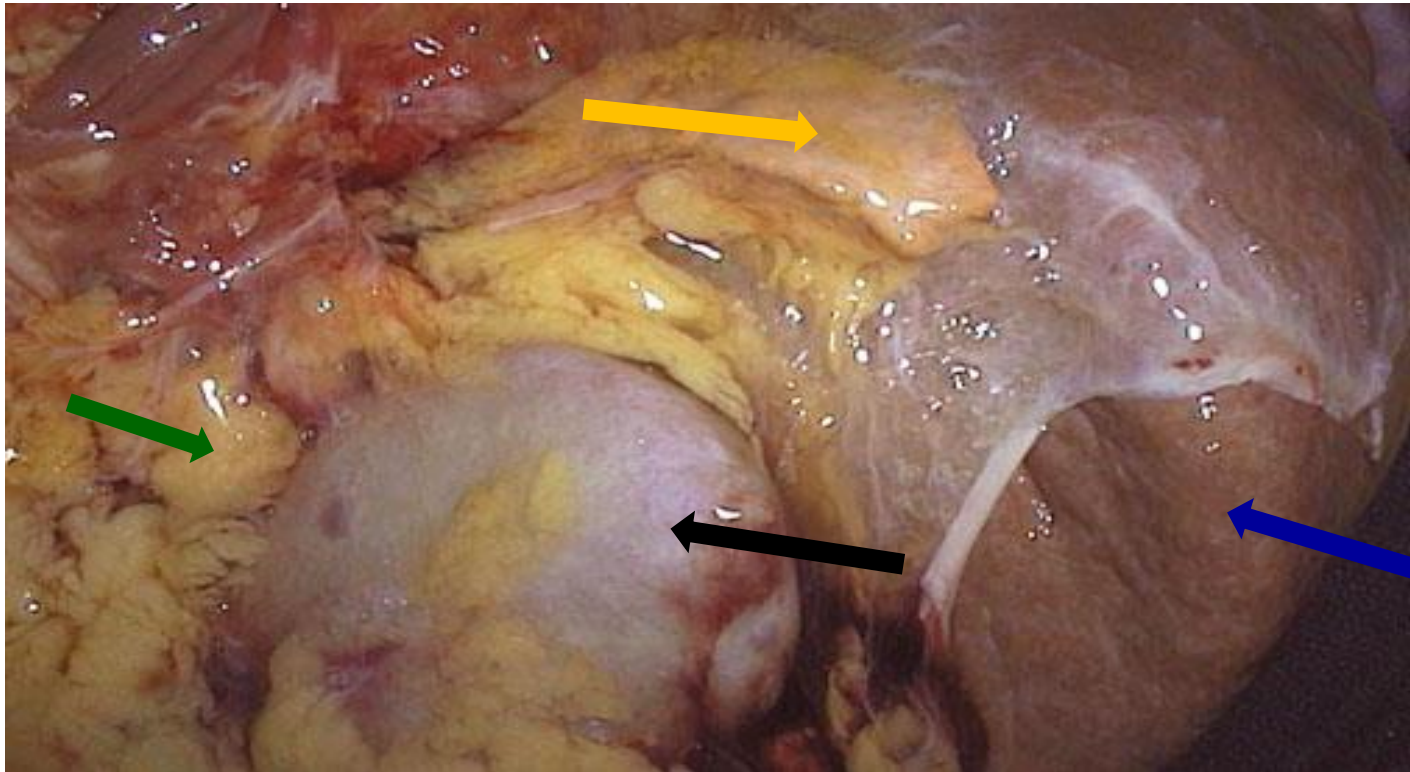


ADRENAL GLAND



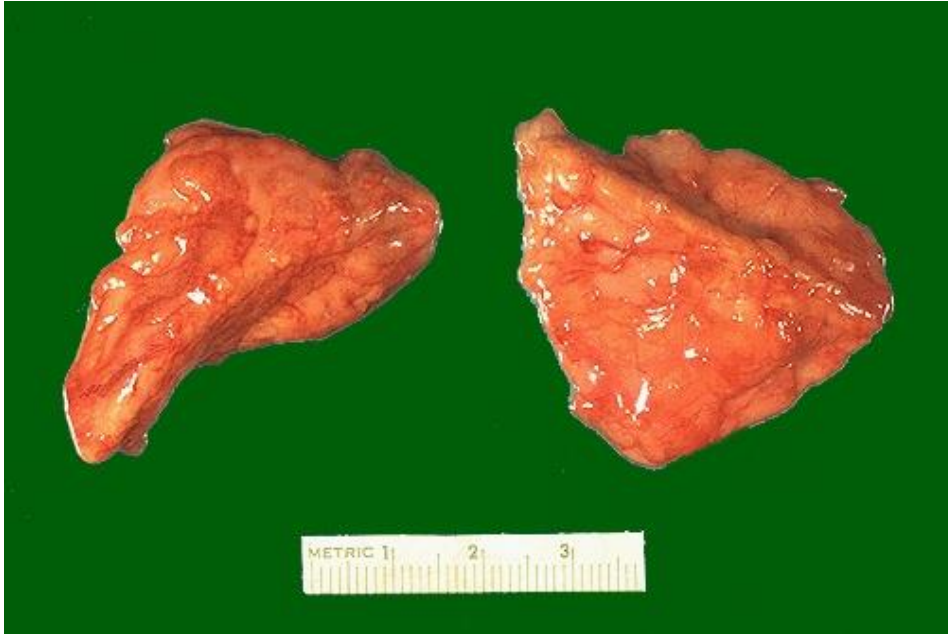Pheochromocytoma

Adrenal Gland – In situ

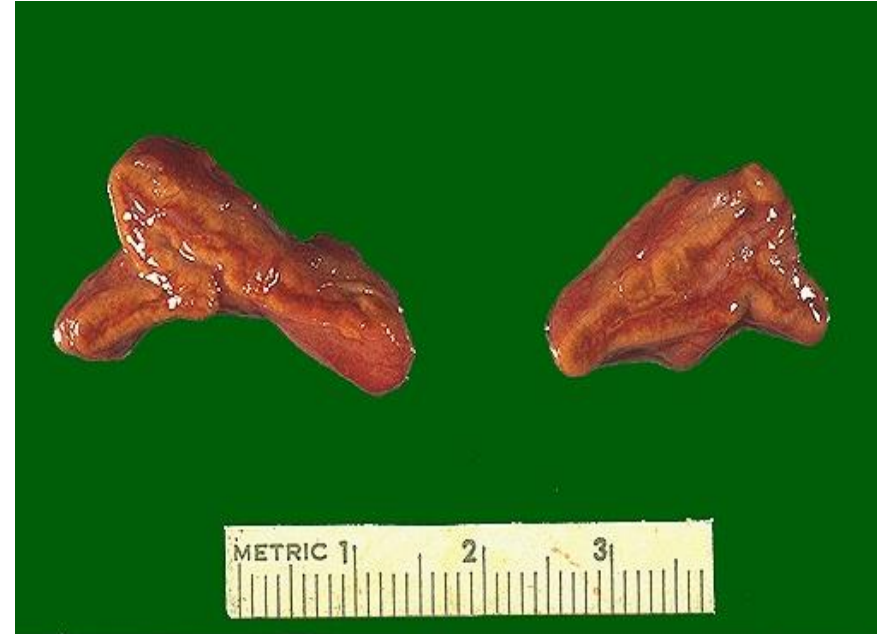

Right adrenal gland is shown here positioned between the **liver** and the **kidney** in the retroperitoneum. Note the amount of **adipose tissue**, some of which has been reflected to reveal the upper pole of the kidney and the adrenal.

Adrenal Gland – Normal Gross & Cross section

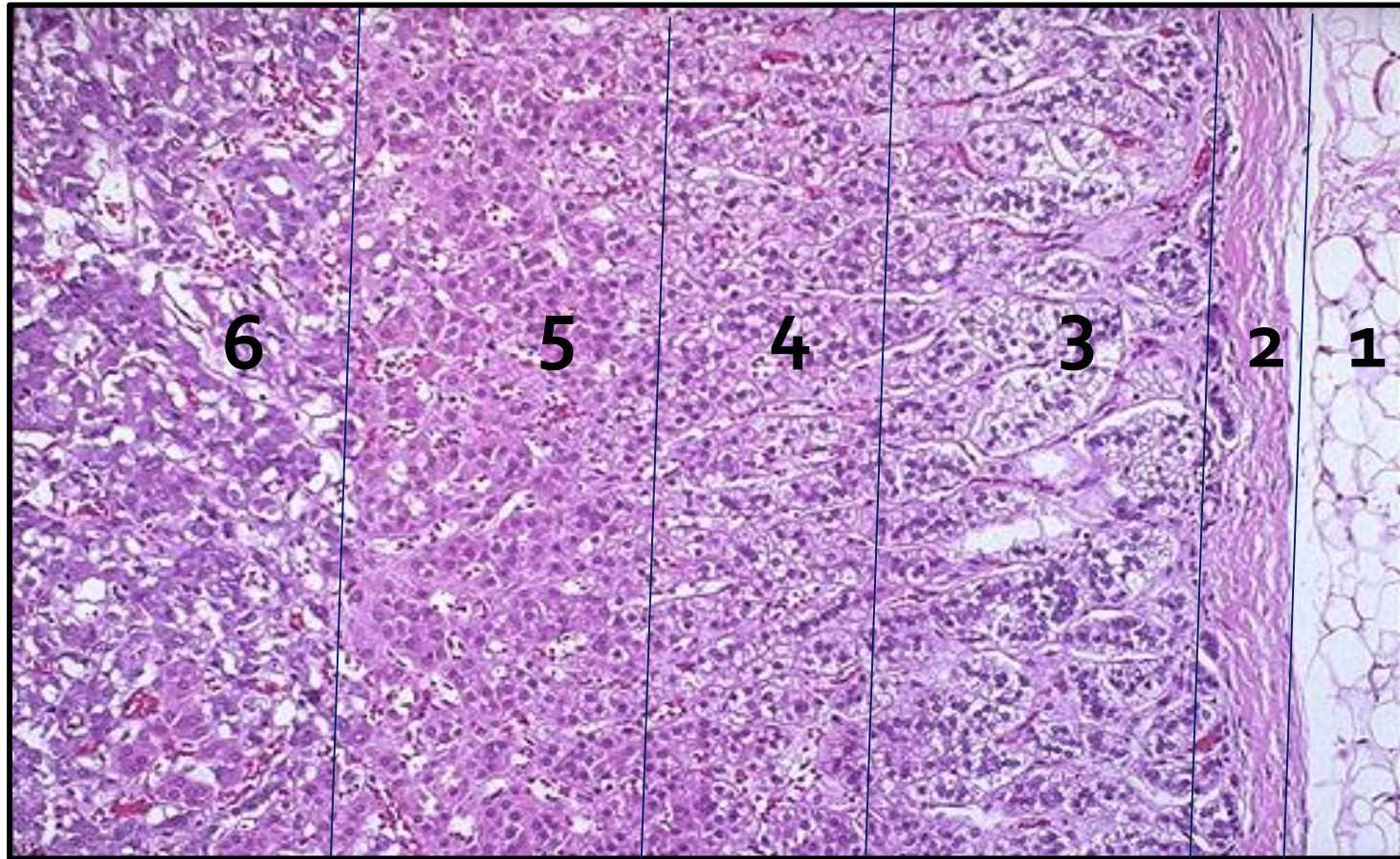


***Here are normal adrenal glands.
Each adult adrenal gland
weighs from 4 to 6 grams.***



***Sectioning across the adrenals
reveals a golden yellow outer
cortex and an inner red to grey
medulla.***

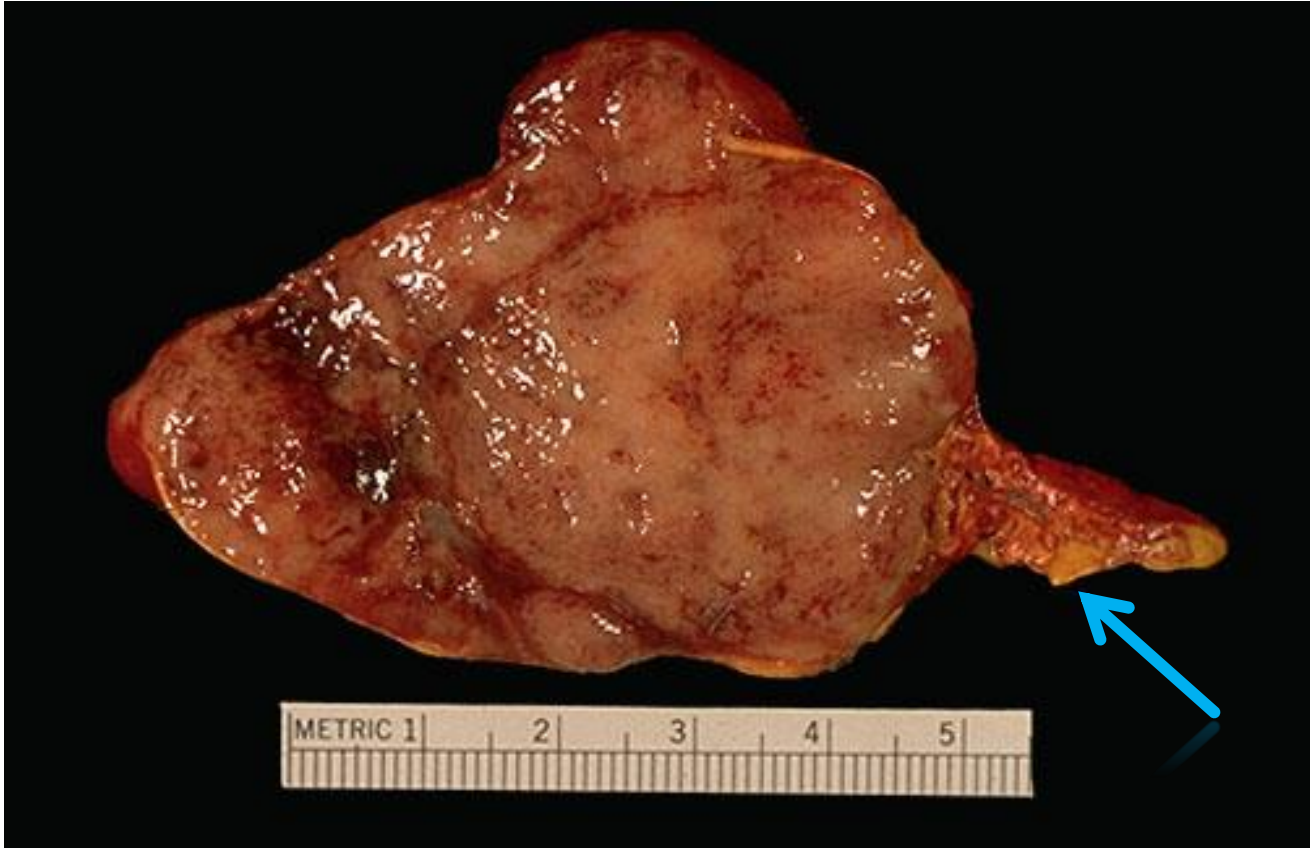Normal Adrenal Gland Histology



1 – Periadrenal fat
3- Zona Glomerulosa
5- Zona Reticularis

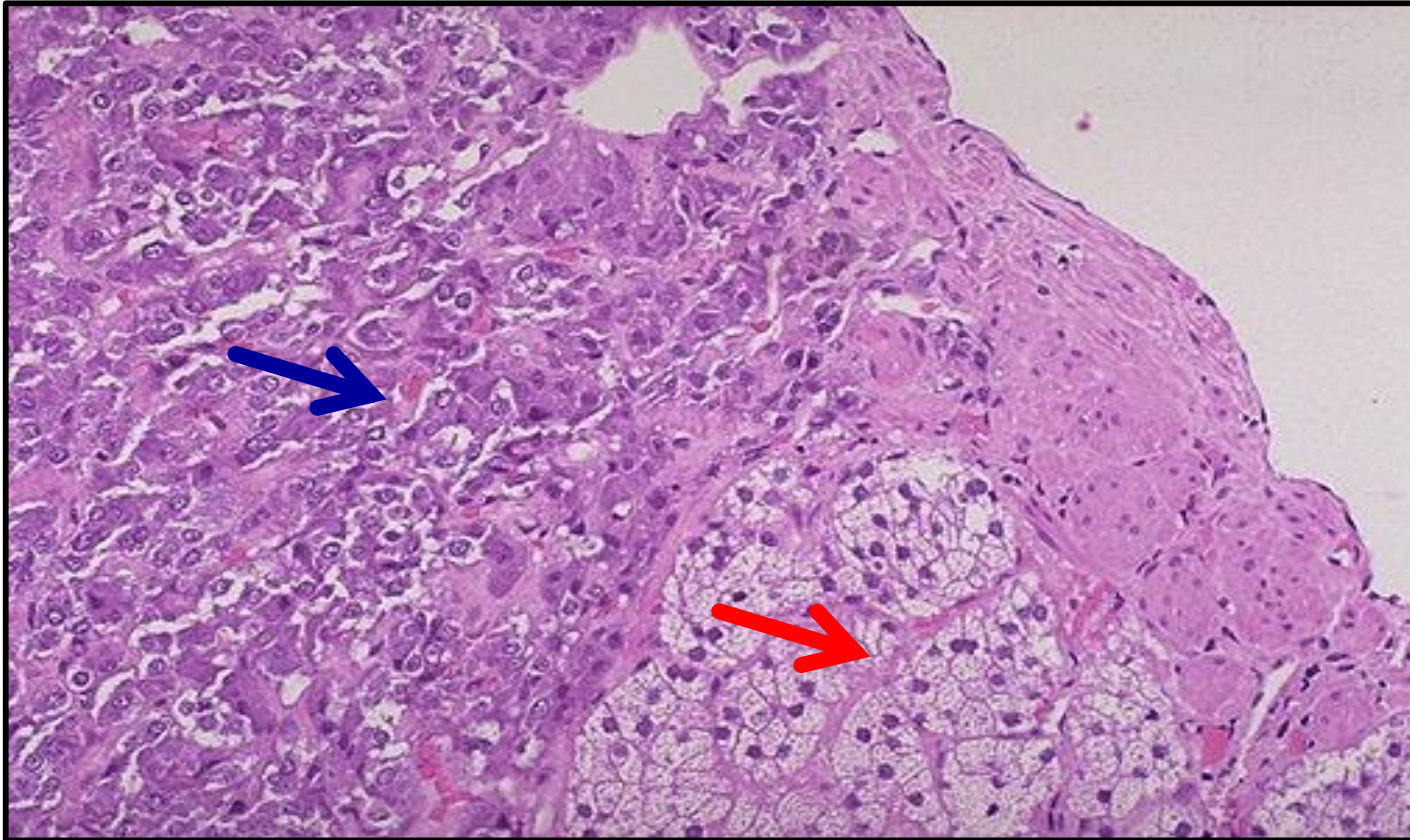
2- Adrenal Capsule
4- Zona Fasciculata
6- adrenal Medulla

Pheochromocytoma – Gross cut section



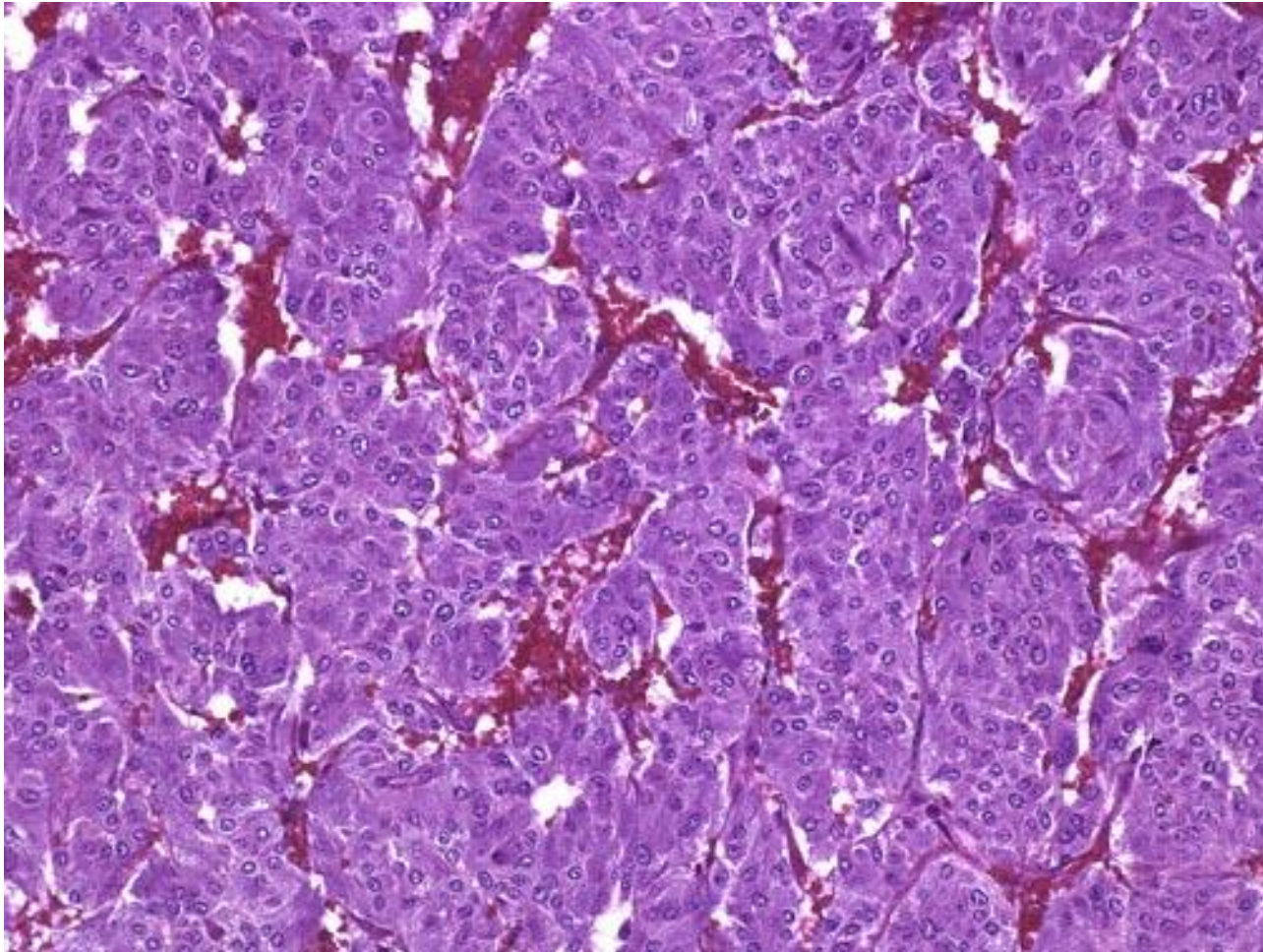
A single partly pale and partly hemorrhagic adrenal medullary mass . Note the grey-tan color of the tumor compared to the yellow cortex stretched around it and a small remnant of remaining adrenal at the lower right ([arrow](#))

Pheochromocytoma – LPF



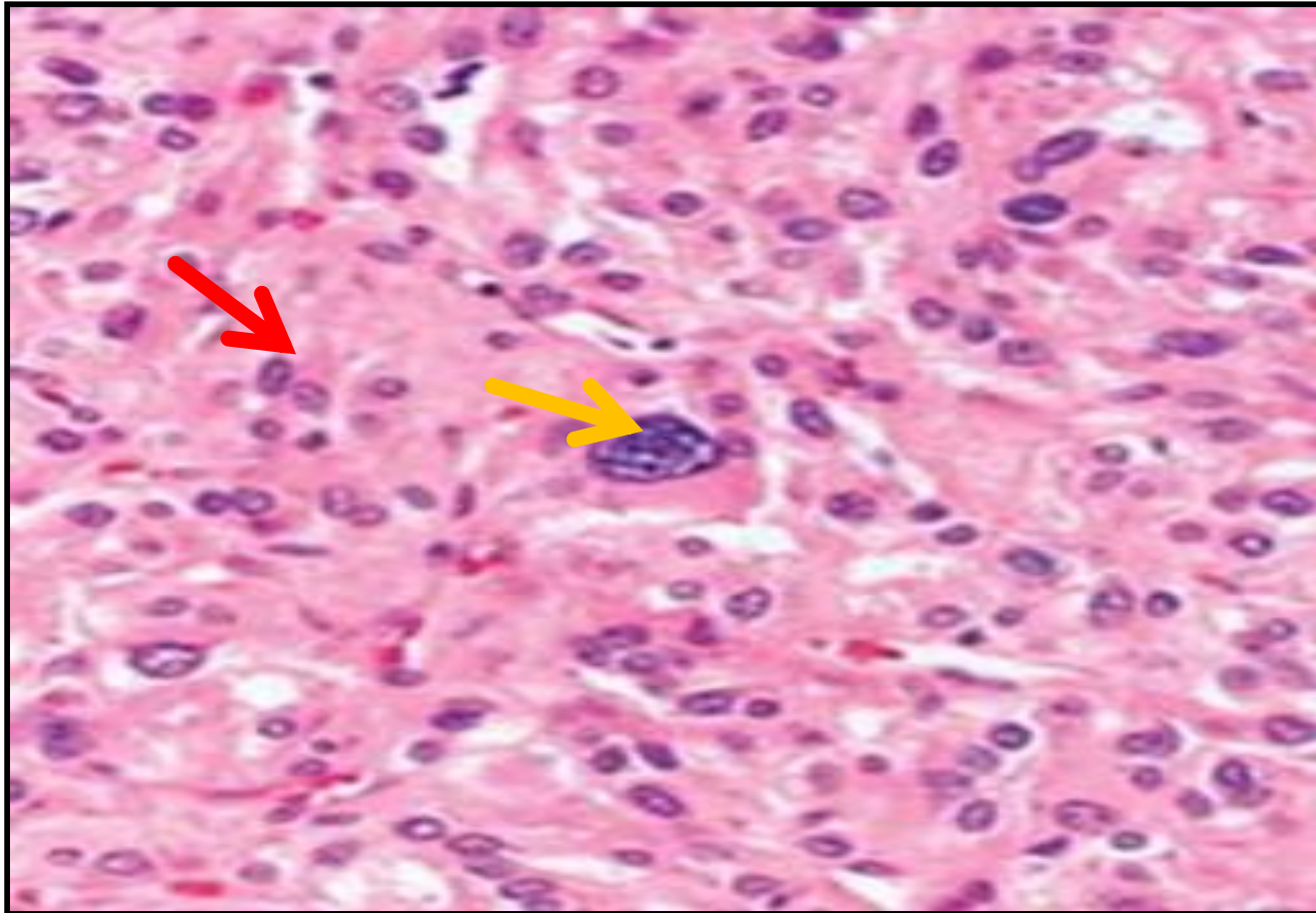
There is some residual adrenal cortical tissue at the lower center right, with the darker cells of the pheochromocytoma seen above and to the left.

Pheochromocytoma – LPF



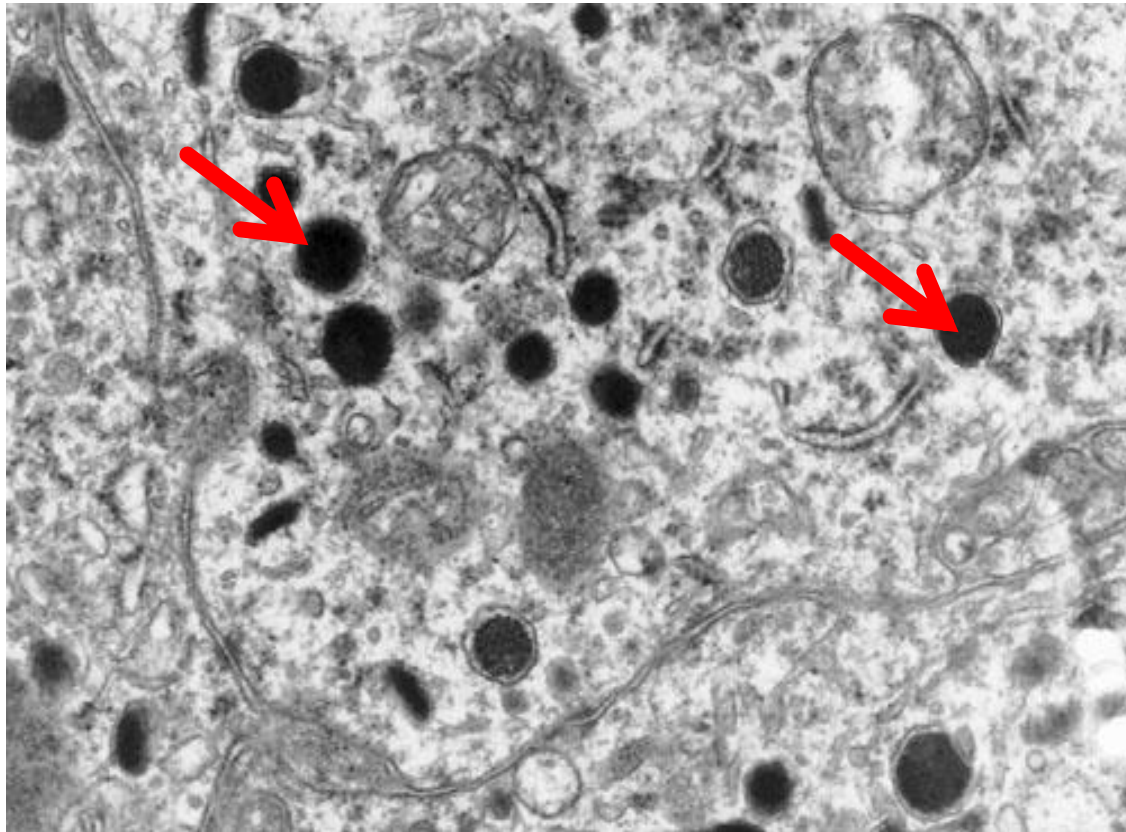
Microscopic view of pheochromocytoma consisting of circular balls of cells with trabecular areas. Note the presence of numerous blood vessels between the tumor cells

Pheochromocytoma – HPF



*High power view of pheochromocytoma consisting of **Atypical cells showing granular and eosinophilic cytoplasm** . Note the presence of **Pleomorphic tumour cells** near the center of the picture .*

Pheochromocytoma – Electron Microscopy view



By electron microscopy, the neoplastic cells of the pheochromocytoma contain variable numbers of membrane-bound, electron-dense neurosecretory granules . It is these granules that contain the catecholamines. The granules seen here appear as small black round objects in the cytoplasm of the cell.

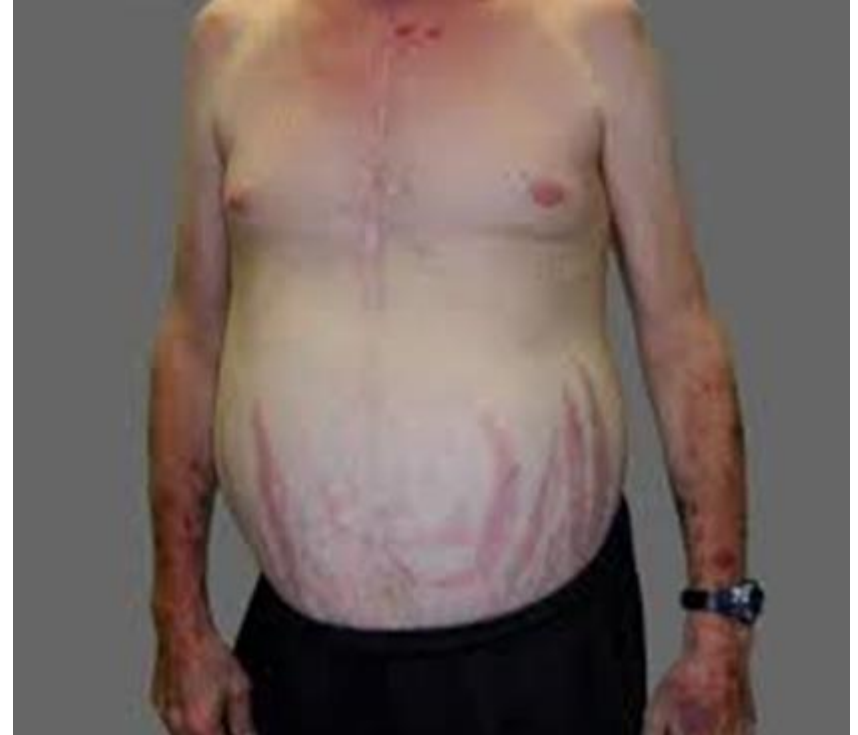

Cushing Syndrome

Cushing Syndrome – Clinical Case

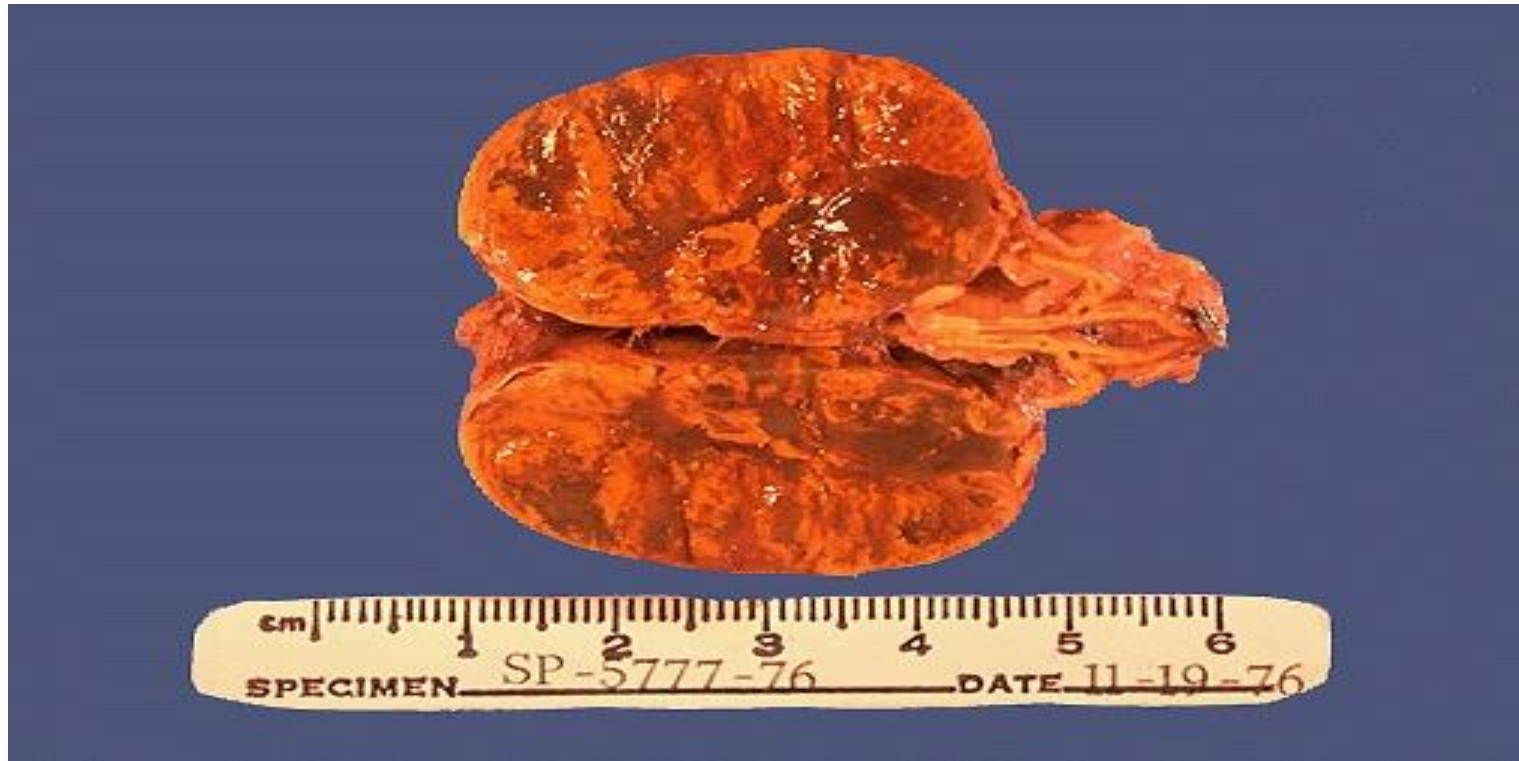

A child with Cushing syndrome as a result of Long-term corticosteroids treatment. Note the classical Moon face appearance



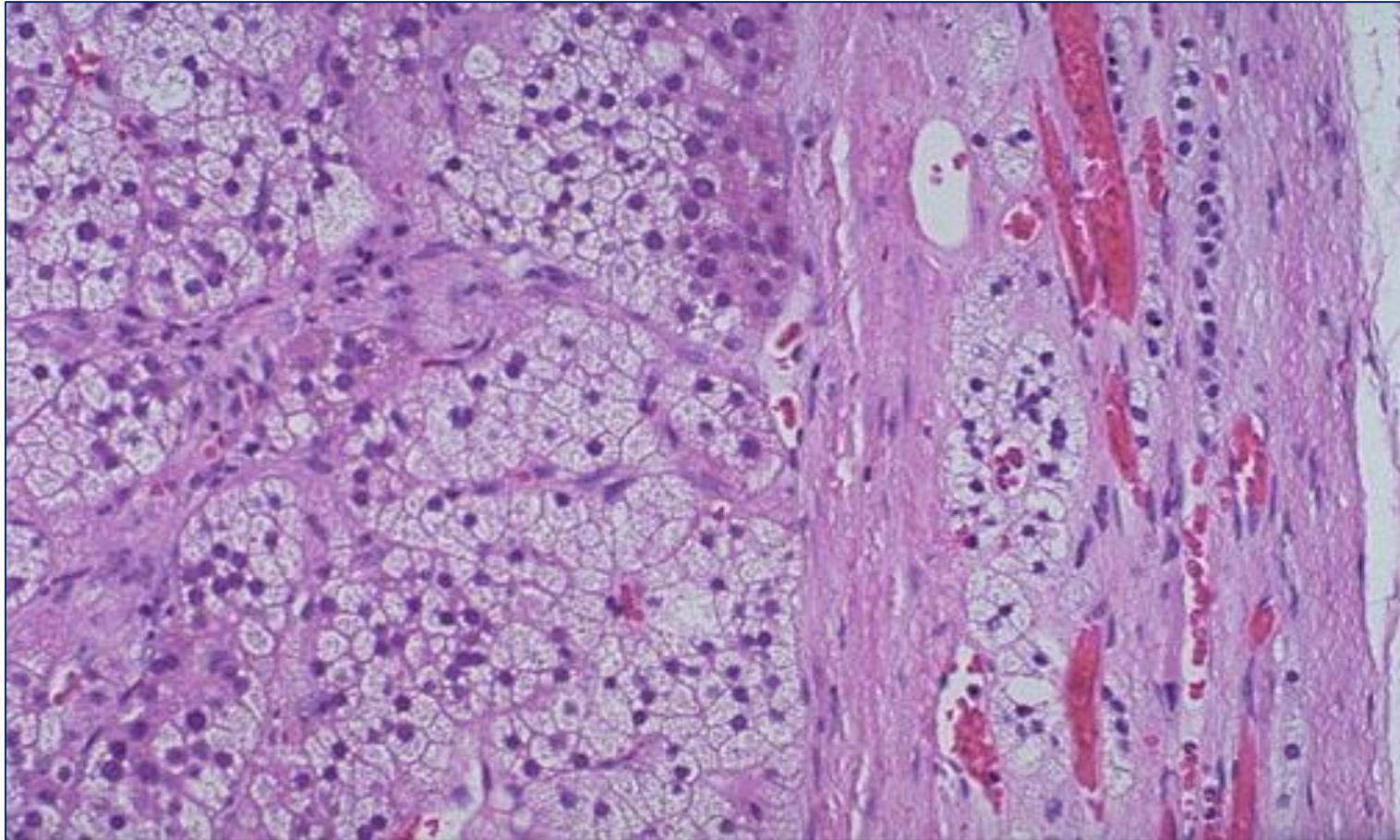
- ***Truncal obesity.***
- ***Abdominal purple striae.***

Cushing syndrome with Cortical Adenoma - Gross



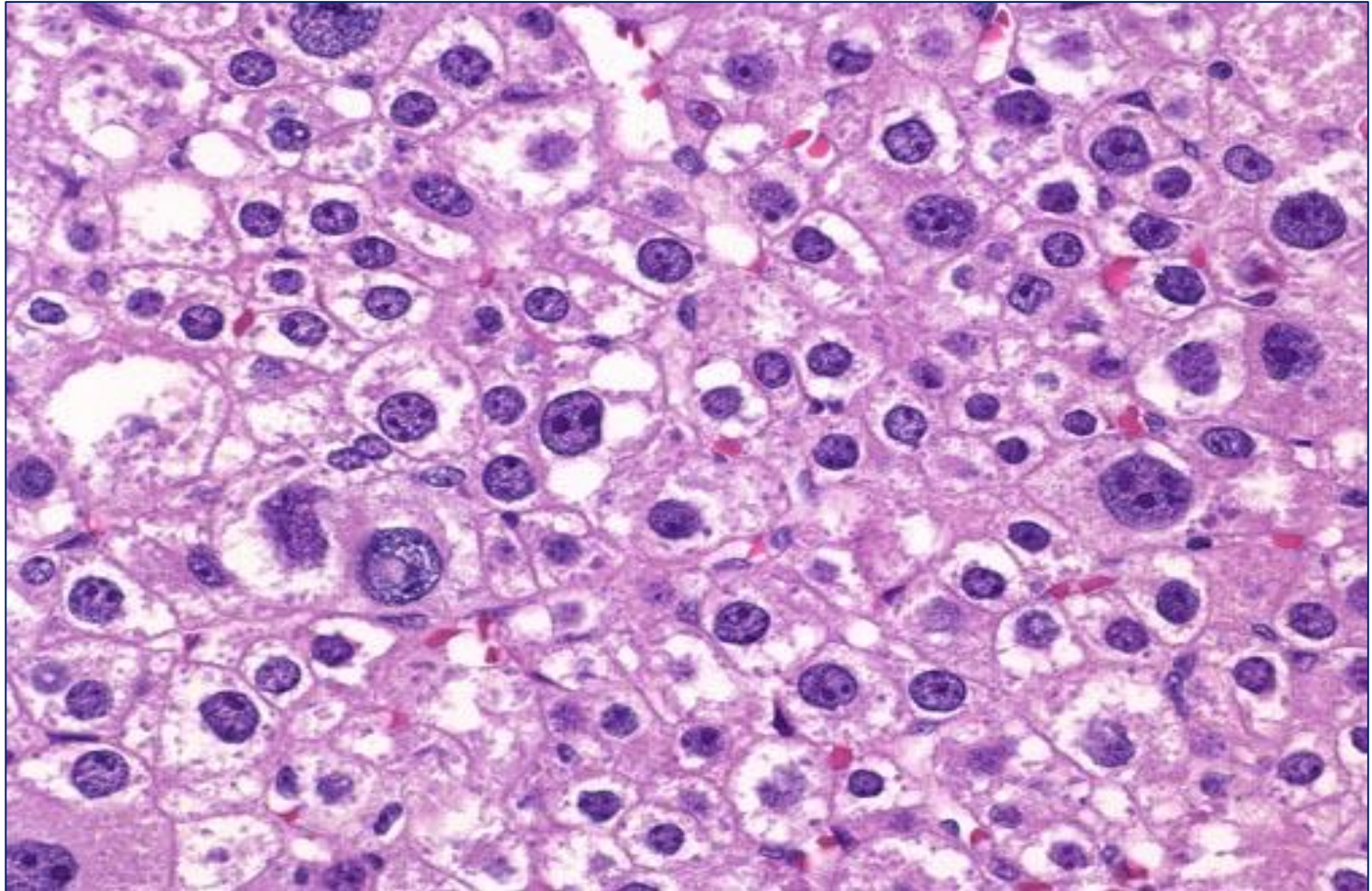
This adrenal gland, removed surgically from a patient with Cushing syndrome. Cortical well encapsulated lesion surrounded by atrophic adrenal gland.

Cortical Adenoma - MPF



*Adrenal cortical adenoma at the left resembles normal adrenal zona fasciculata. The **capsule** of this benign neoplasm is at the right. There may be **minimal** cellular pleomorphism within adenomas. Malignant transformation: Large weight of the lesion (more than 300 g), Cellular anaplasia and No Capsule or invasion of the capsule.*

Adrenal Gland – Cortical Adenoma - HPF



- ***Hyperchromatic and enlarged nuclei.***
- ***Prominent nucleoli.***
- ***Both eosinophilic and clear cytoplasm of neoplastic cells.***

GOOD LUCK

