

Radiological Anatomy of the Adrenal Gland

DR. MOHAMMED AYESH

Radiology

Radiological Anatomy of the Adrenal Gland

- **Main Objective:**

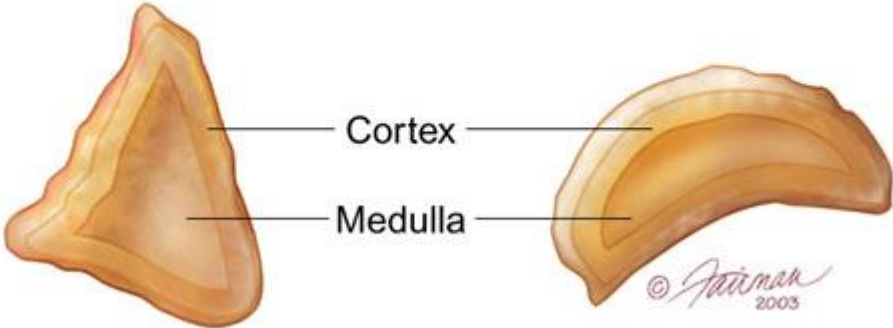
Know the anatomy of adrenal gland in real person through medical imaging (Radiology), and correlated with gross sectional anatomy.

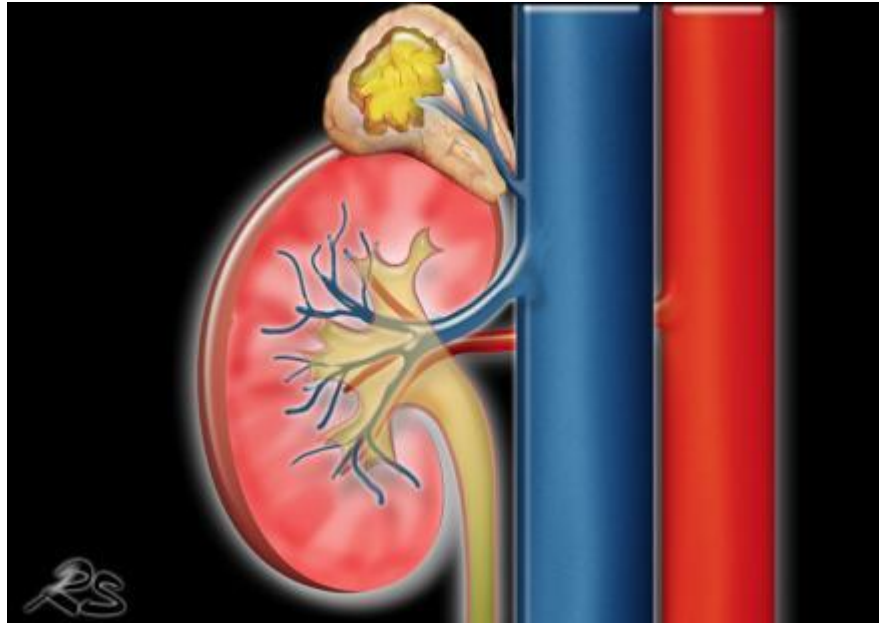
Radiological Anatomy of the Adrenal Gland

- US.
- CT.
- MR.

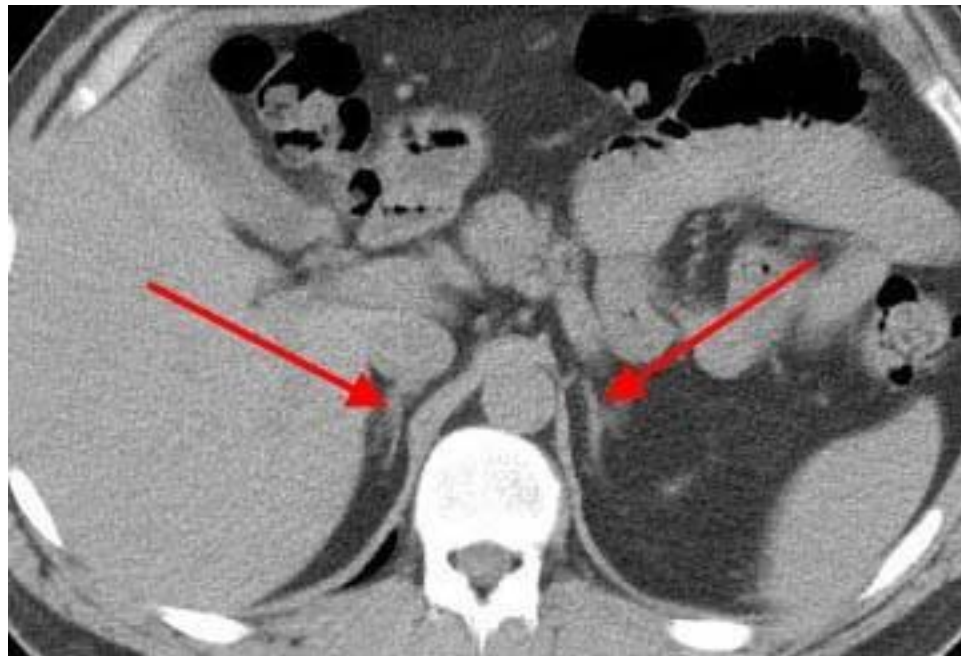Right adrenal gland

Left adrenal gland



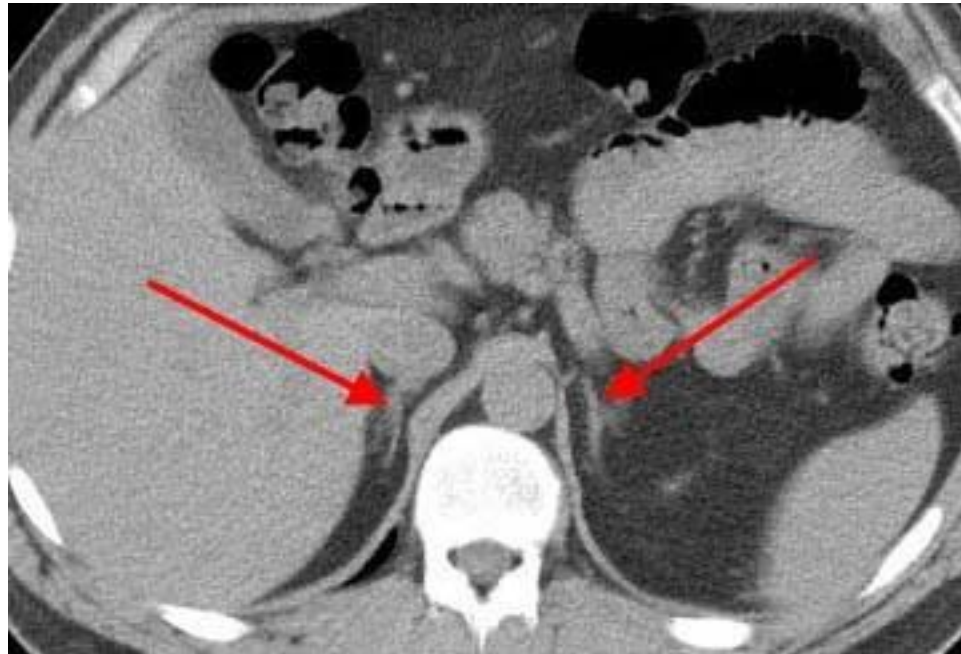

Axial CT Scan



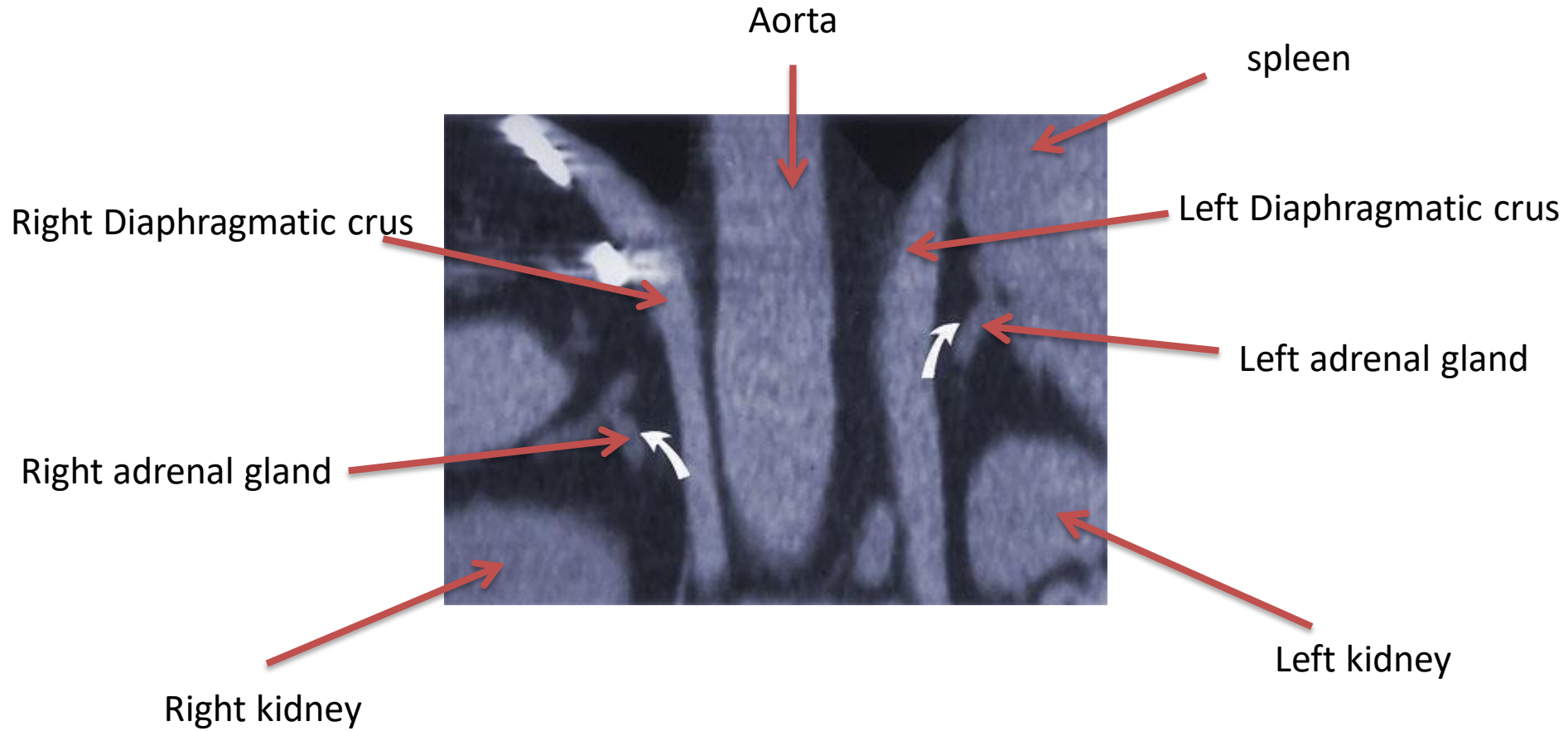
Axial CT Scan

Right adrenal

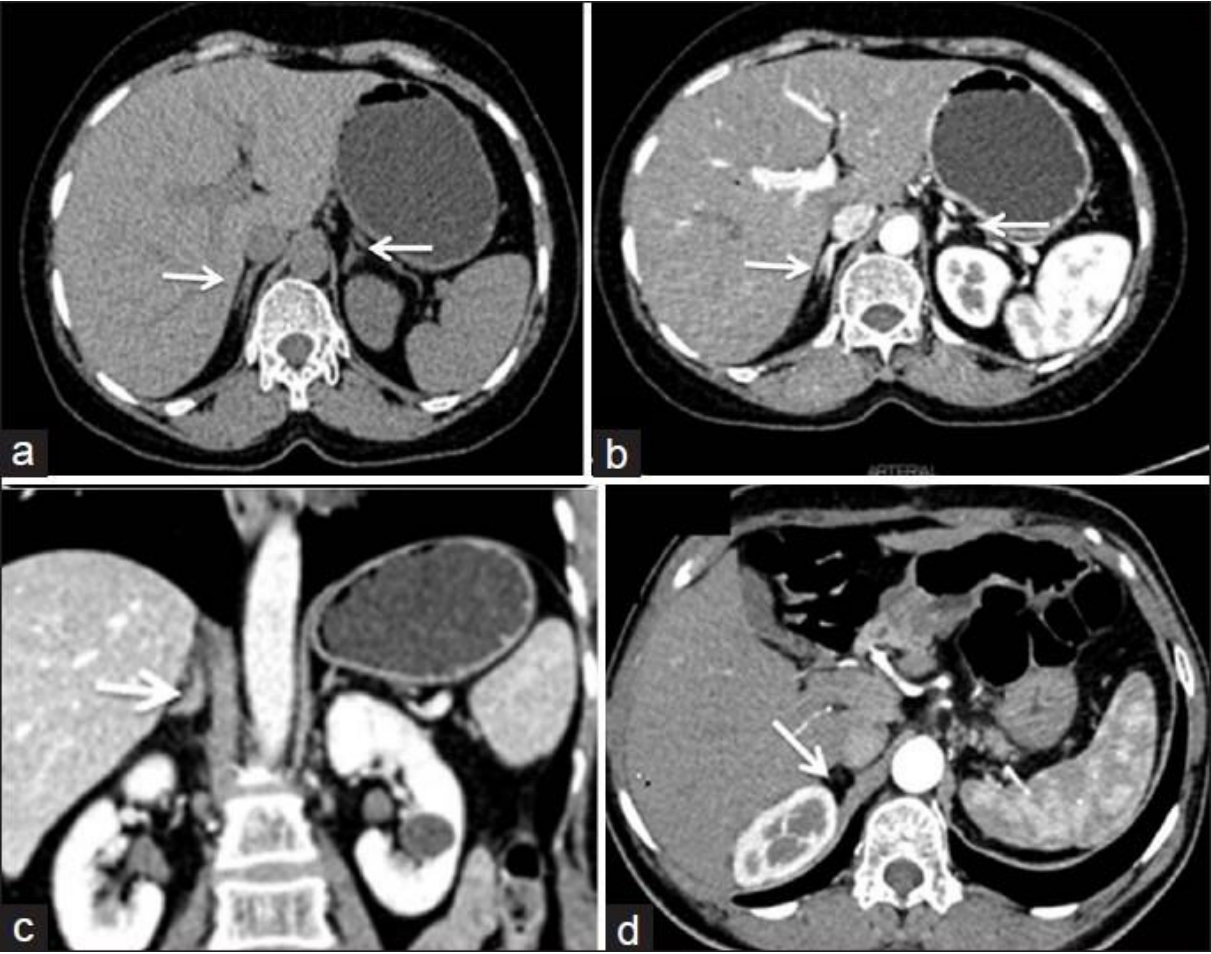


Left adrenal

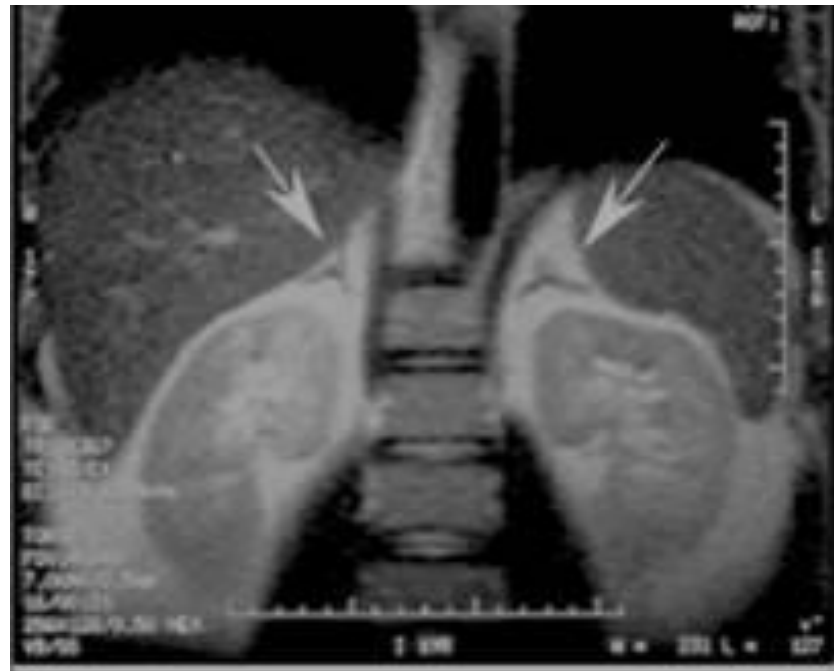Coronal CT Scan



Axial CT Scan WITH IV CONTRAST

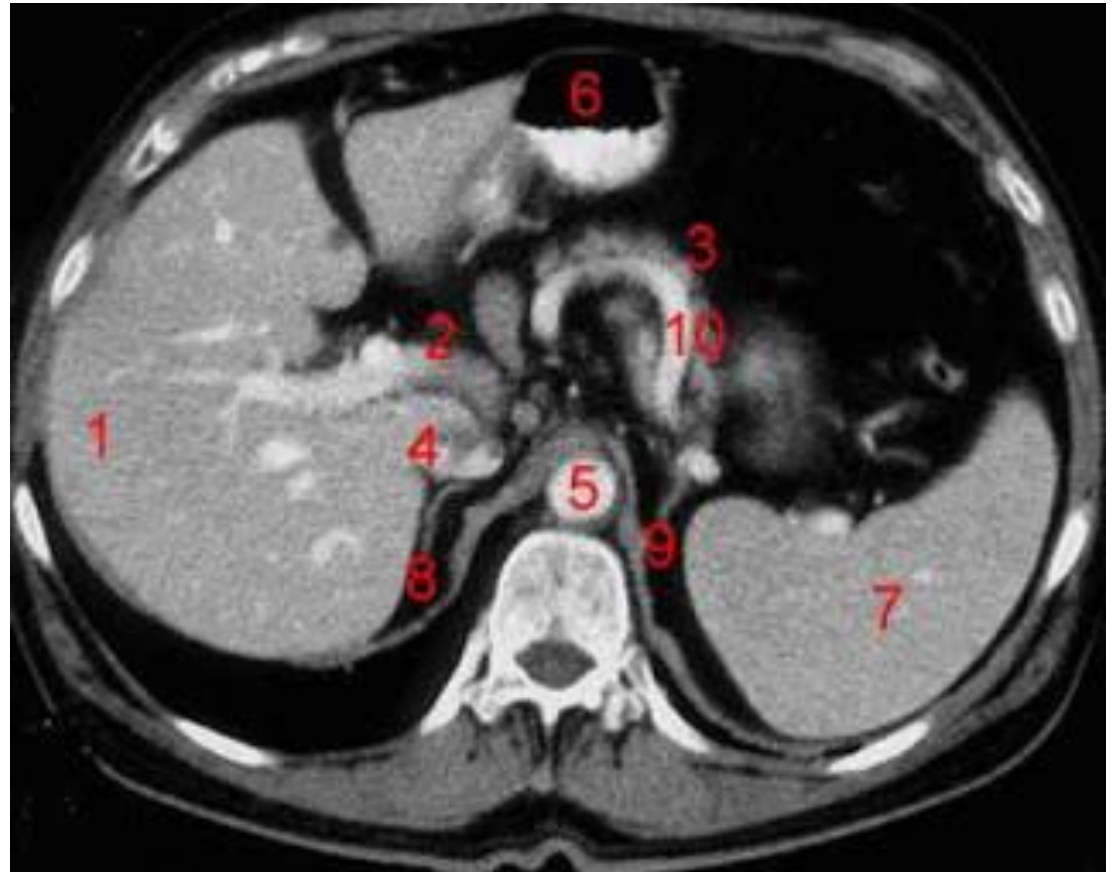


Axial MRI of abdomen



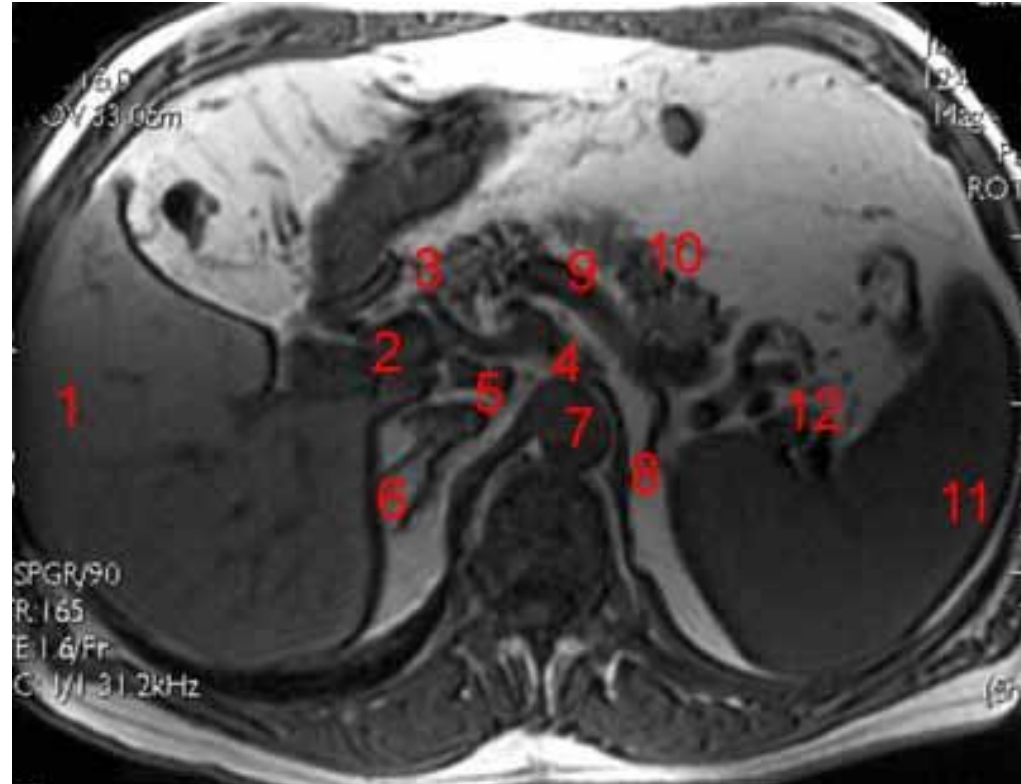
Axial CT of abdomen

- 1. Liver**
- 2. Portal Vein**
- 3. Pancreas**
- 4. Inferior Vena Cava**
- 5. Abdominal Aorta**
- 6. Stomach**
- 7. Spleen**
- 8. Right Adrenal**
- 9. Left Adrenal**
- 10. Splenic artery**

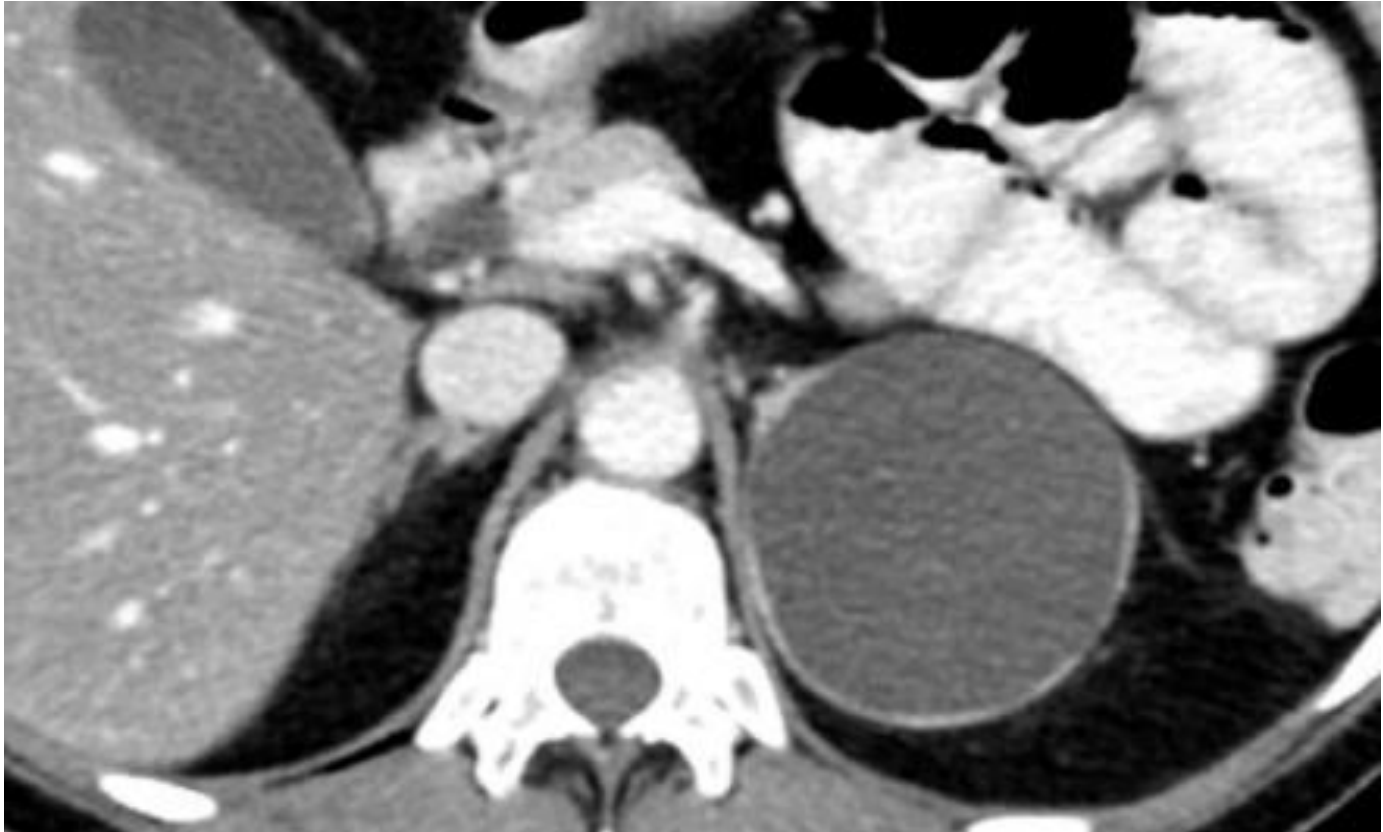


Axial MRI of abdomen

- 1- Liver**
- 2- portal vein.**
- 3- head of pancreas**
- 4- celiac artery**
- 5- Inferior Vena Cava**
- 6- Right Adrenal**
- 7- Abdominal Aorta**
- 8- Left Adrenal**
- 9- splenic artery**
- 10- body of pancreas**
- 11- Spleen**

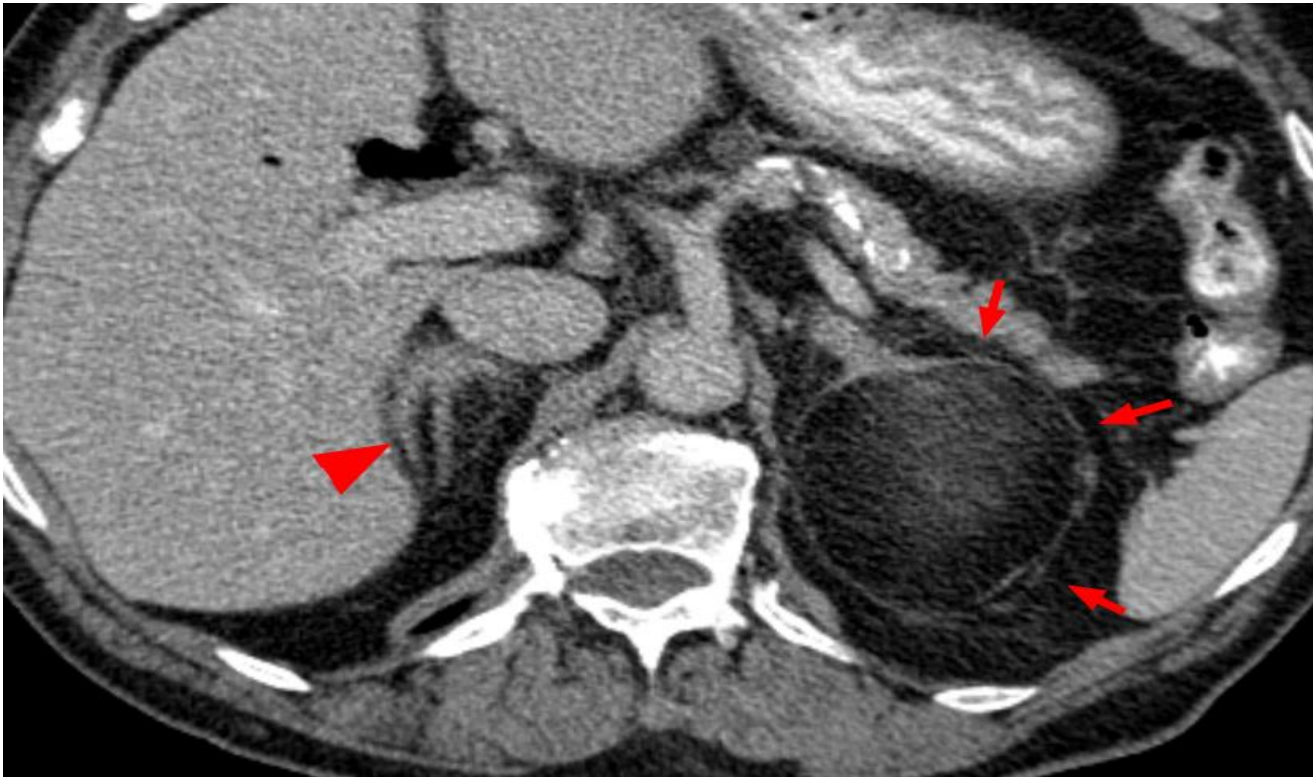

Pathology of the adrenal gland



CYST of the left adrenal gland

Pathology of the adrenal gland



Lipoma of the left adrenal gland

THANK YOU