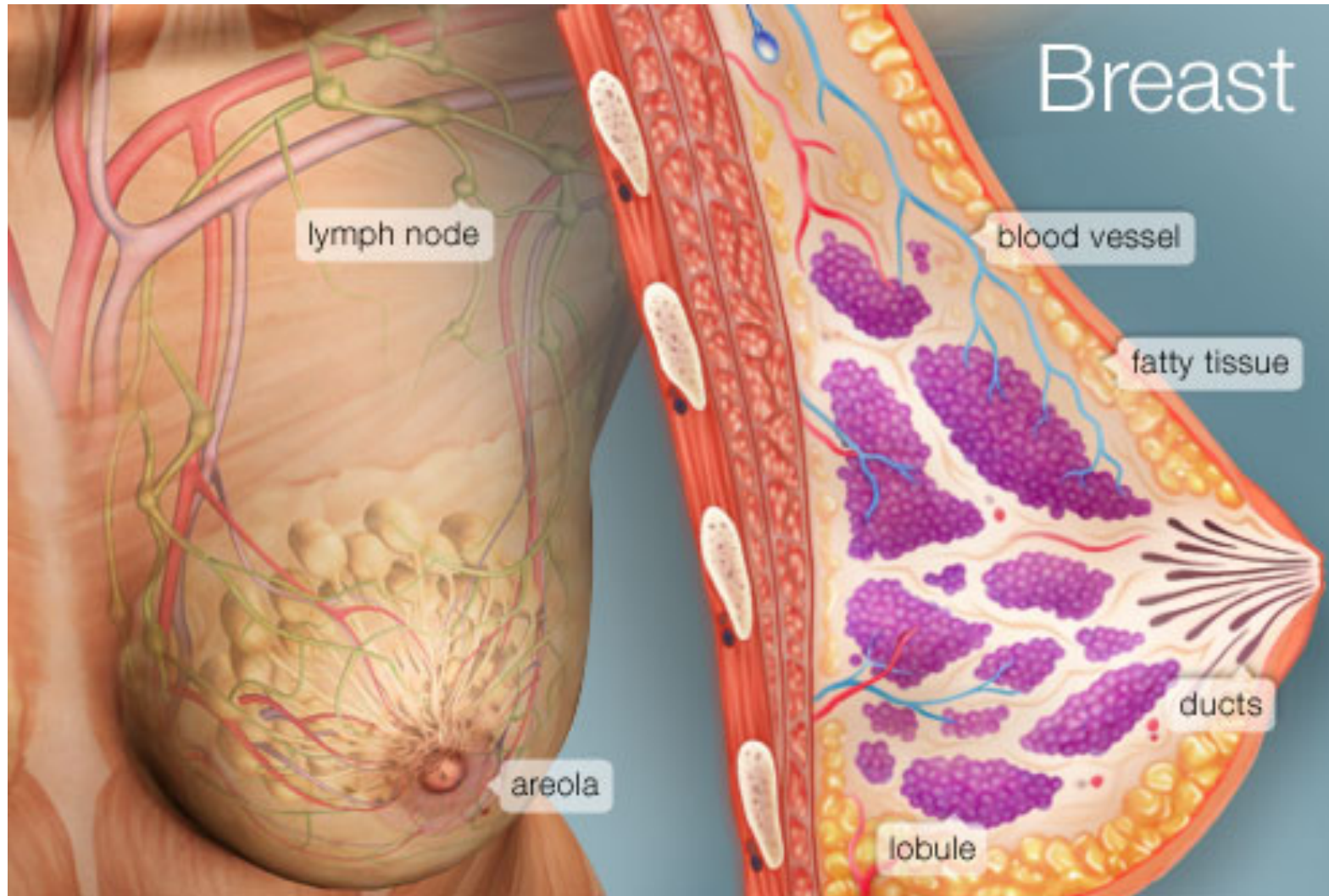


FEMALE BREAST



PROF. Saeed Abuel Makarem

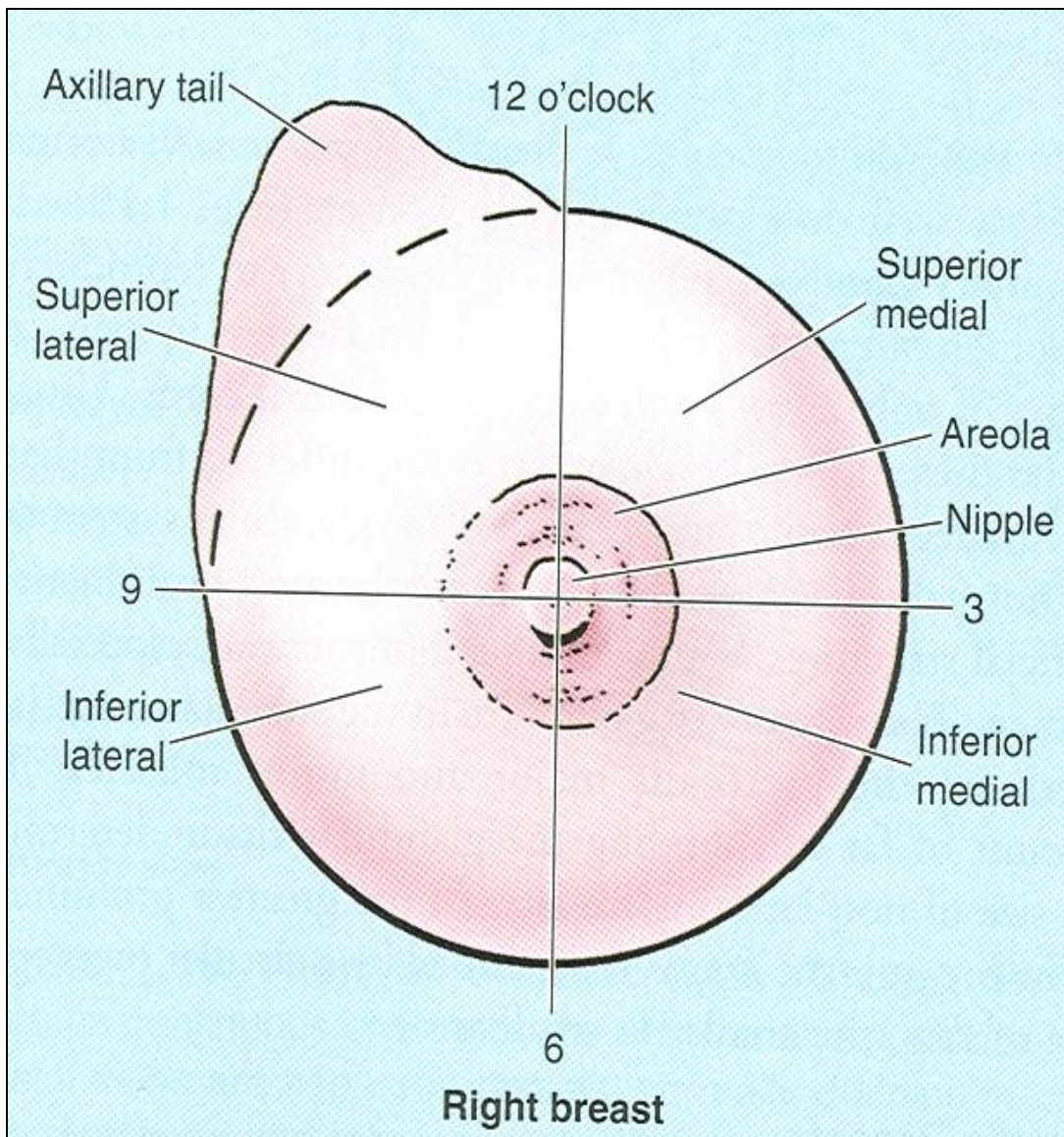


OBJECTIVES

- By the end of the lecture, you should be able to:
- Describe the shape and position of the female breast.
- Describe the structure of the mammary gland.
- List the blood supply of the female breast.
- Describe the lymphatic drainage of the female breast.
- Describe some applied anatomy of the female breast.



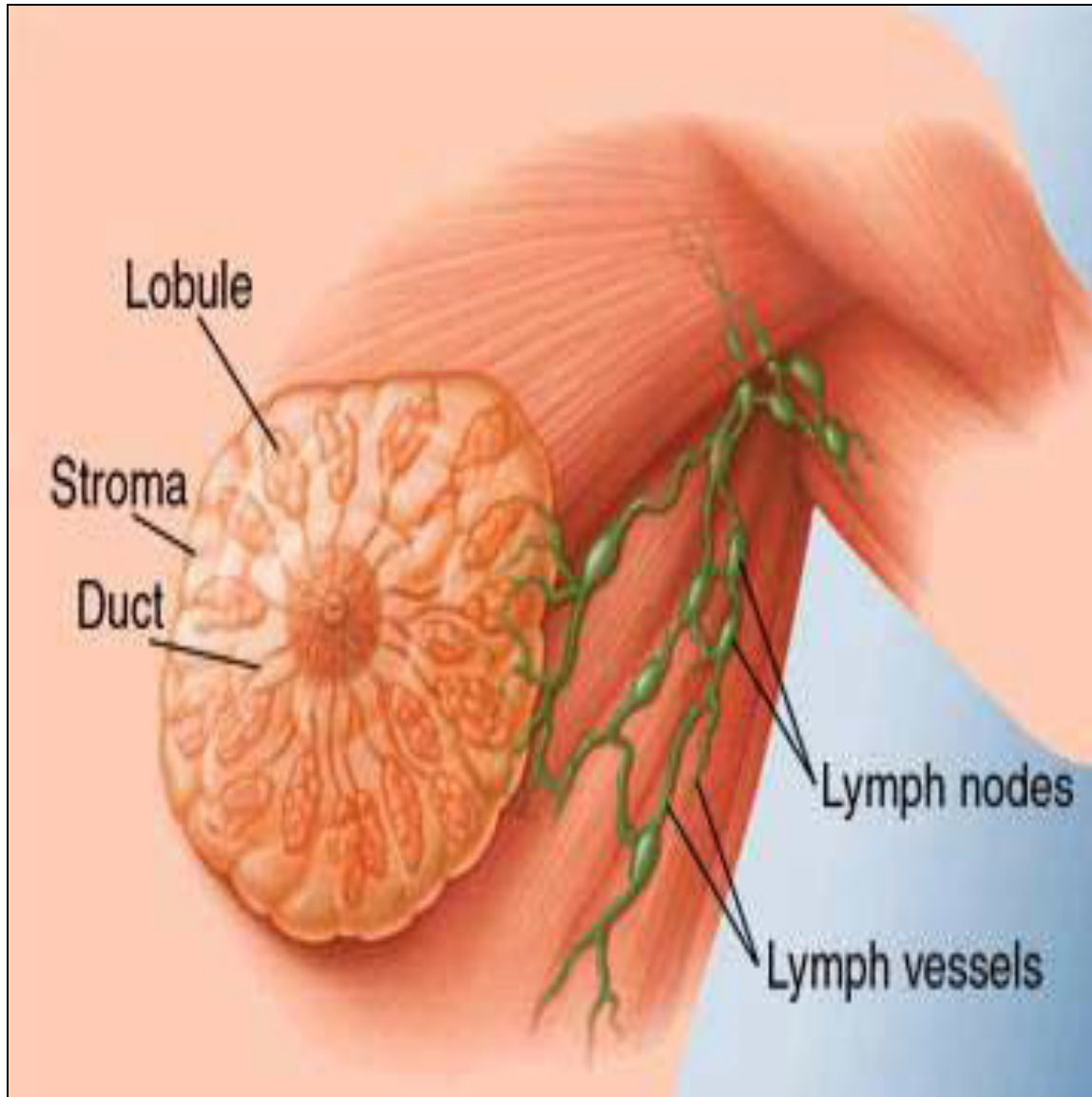
Parts, Shape & position of the Gland



- It is conical in shape.
- It lies in **superficial fascia** of the front of chest.
- It has a base, apex and tail (axillary tail).
- Its base extends from **2nd to 6th ribs**.
- It extends from the lateral margin of the **sternum** to the **midaxillary line**.
- It has no capsule.



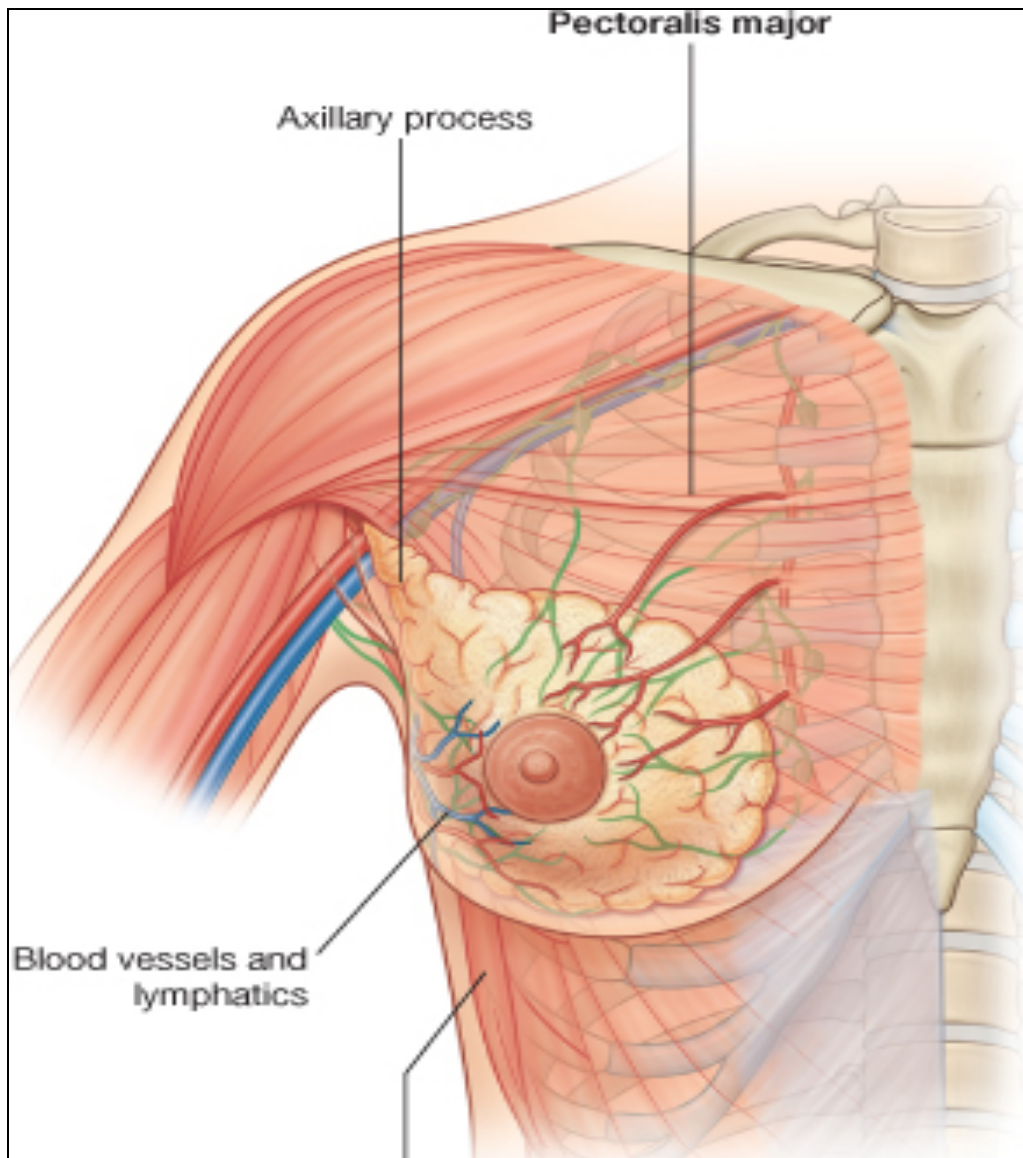
SHAPE AND POSITION OF FEMALE BREAST



- $2/3^{\text{rd}}$ of its base lies on the **pectoralis major**, while its inferolateral $1/3$ lies on:
- **Serratus anterior &**
- **External oblique muscles.**
- Its superolateral part sends a process into the axilla called the **axillary tail or axillary process.**



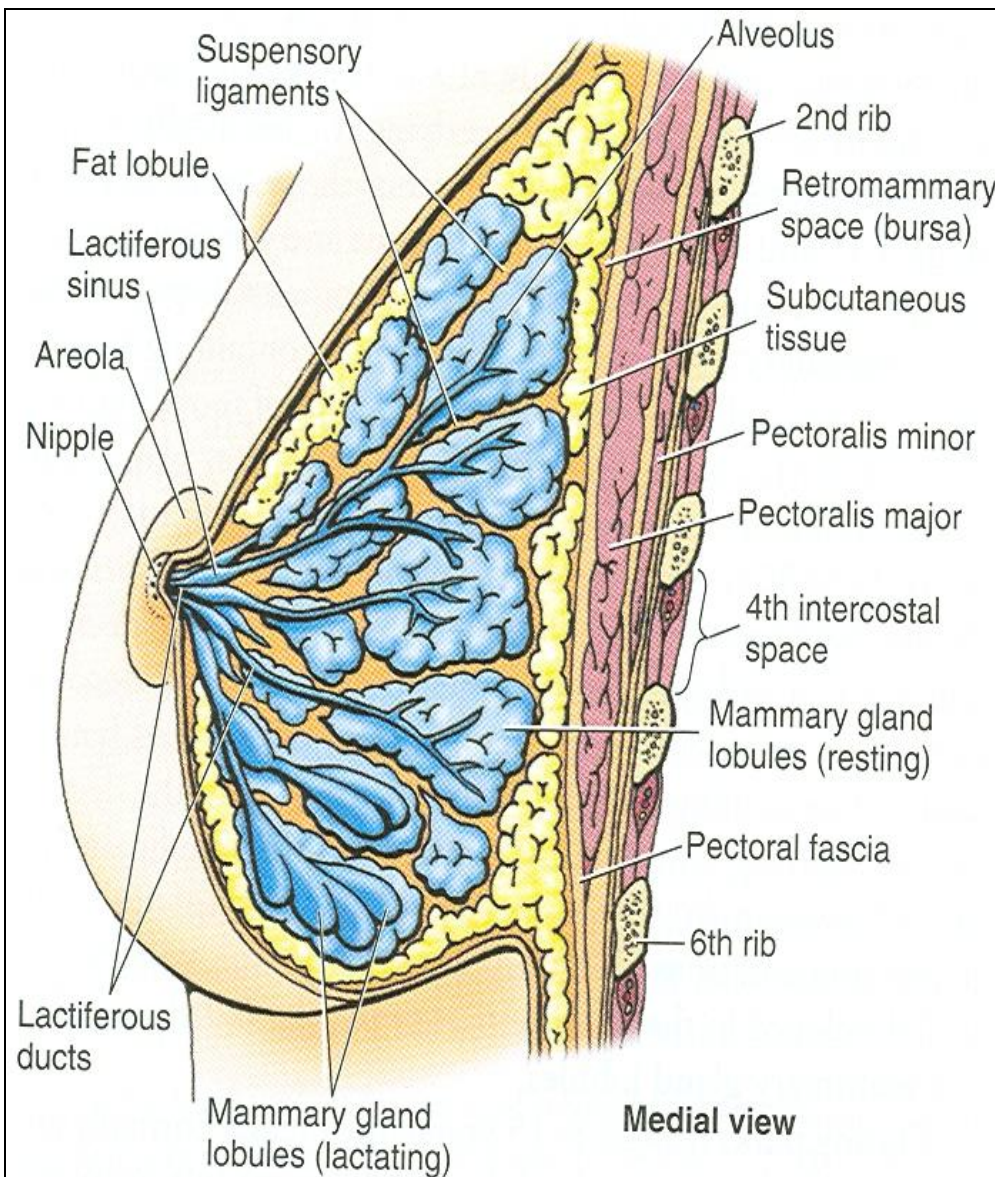
SHAPE AND POSITION OF FEMALE BREAST



- **Nipple:**
- It is a conical eminence that projects forwards from the anterior surface of the breast.
- The nipple lies opposite **4th intercostal space.**
- It carries **15-20** narrow pores **of the lactiferous ducts.**
- **Areola :**
- It is a **dark pink brownish** circular area of skin that surrounds the nipple.
- The subcutaneous tissues of nipple & areola are **devoid of fat.**



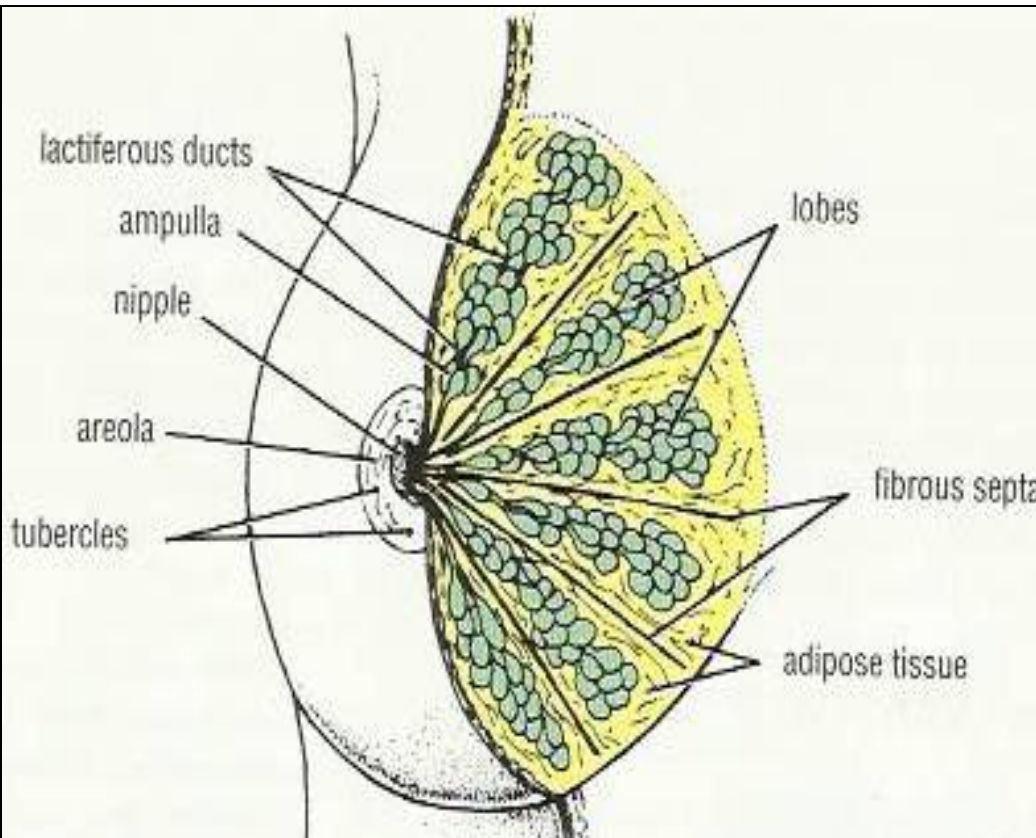
STRUCTURE OF MAMMARY GLAND



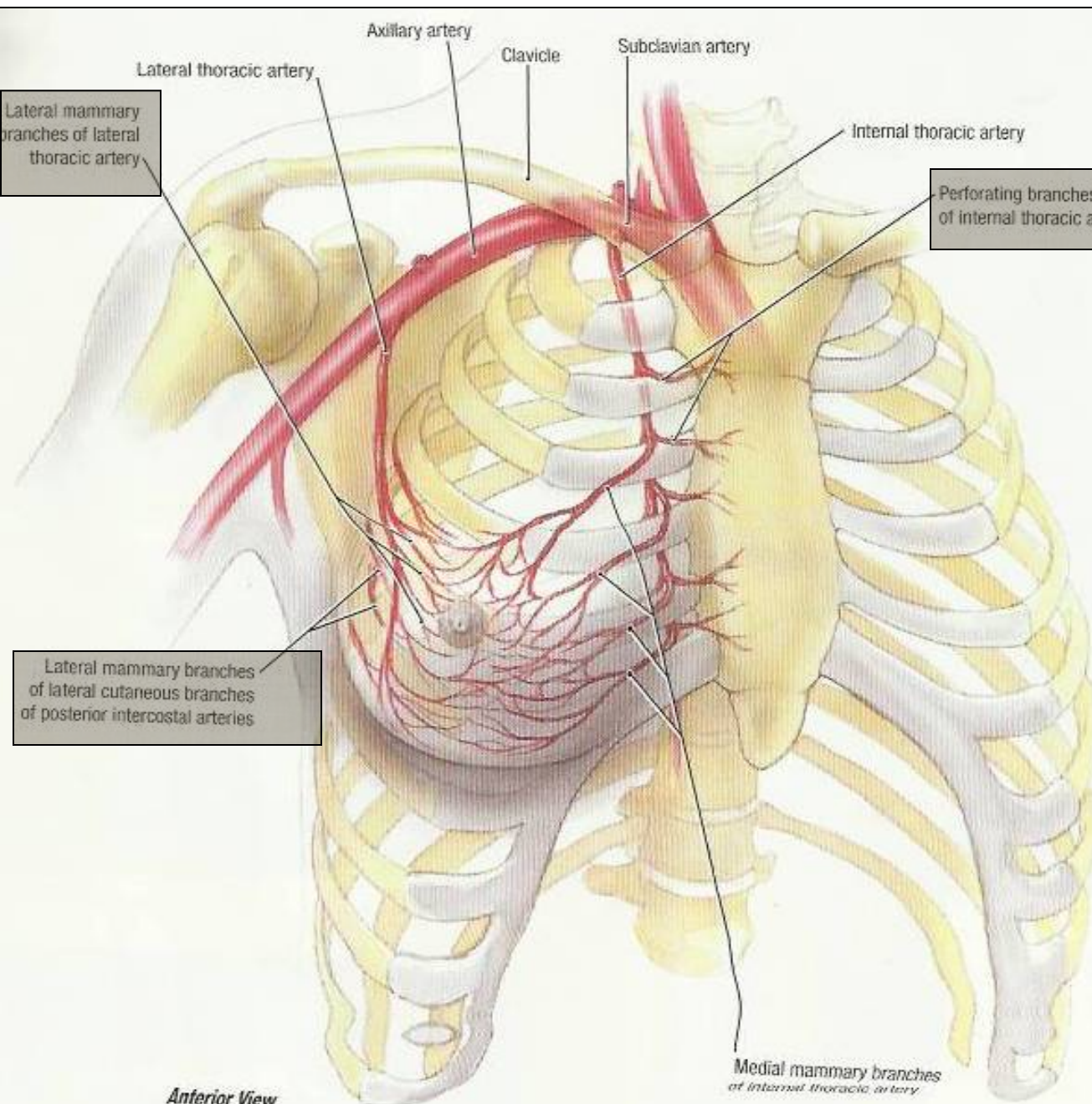
- It is non capsulated gland.
- It consists of lobes and lobules which are embedded in the subcutaneous fatty tissue of superficial fascia.
- It has fibrous strands which run radially and connect the skin with deep fascia of pectoralis major.
- It is separated from the deep fascia covering the underlying muscles by a layer of loose areolar tissue which forms the retromammary space? **What is its Importance?**



STRUCTURE OF MAMMARY GLAND



- It is formed of 15-20 lobes.
- Each lobe is formed of a number of lobules.
- The lobes and lobules are separated by interlobar and interlobular **fibrous** & fatty tissue, called ligaments of **Cooper.** **(Importance?)**
- It has from 15-20 lactiferous ducts which open by the same number of openings on the summit of the nipple.



Anterior View

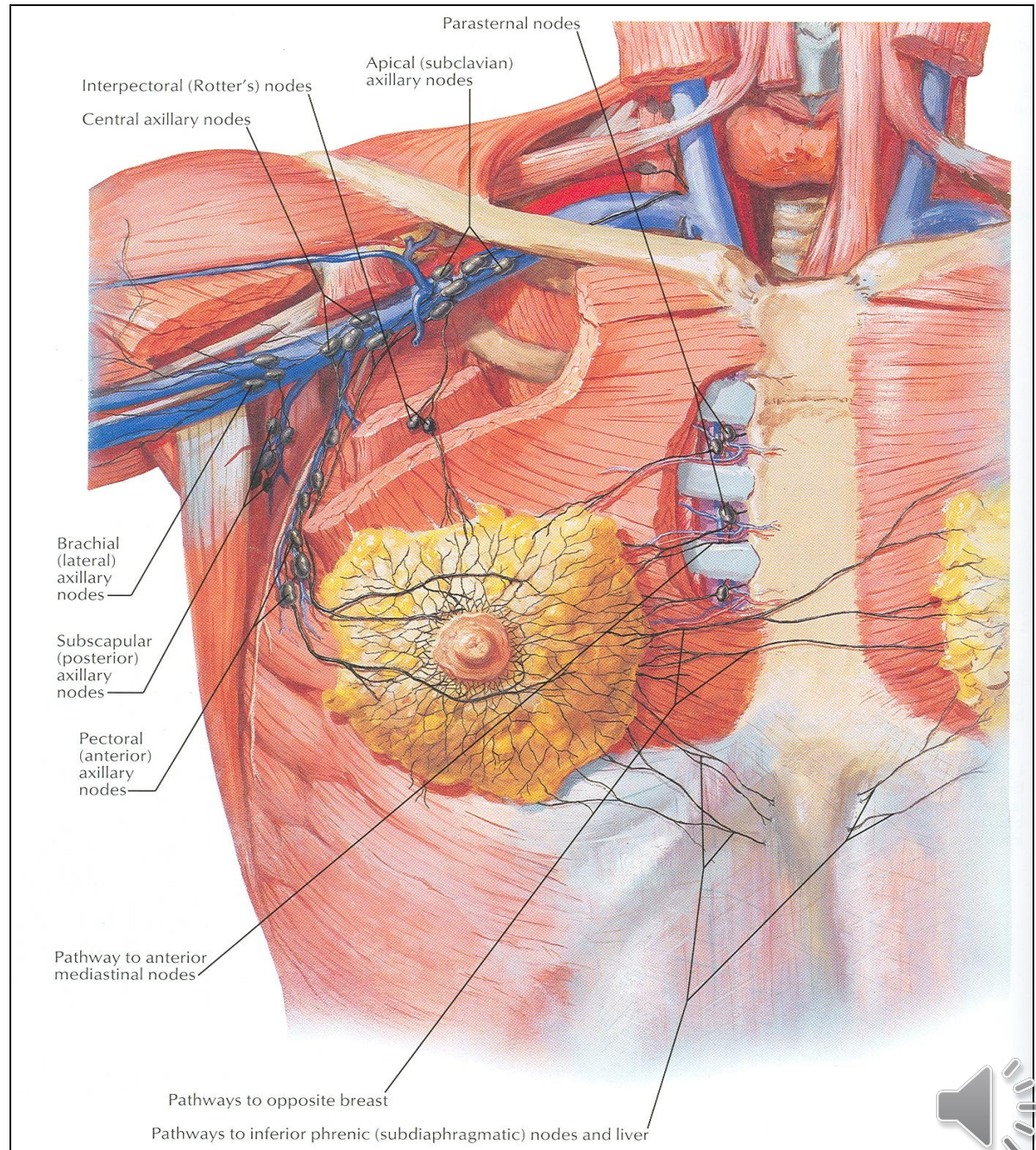
ARTERIAL SUPPLY

- 1. Perforating branches of **internal thoracic (internal mammary) artery.**
- 2. Mammary branches of **lateral thoracic artery.**
- 3. Mammary branches of **Intercostal arteries.**

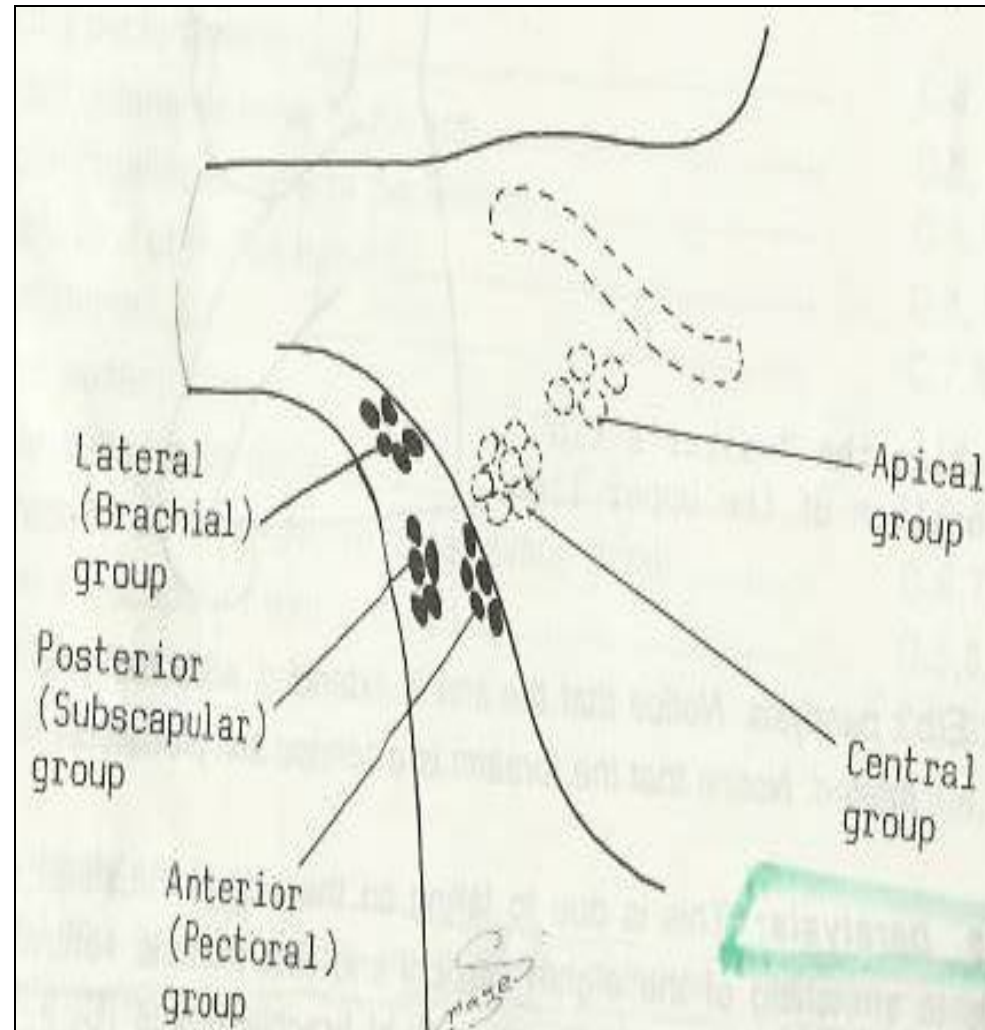


VENOUS SUPPLY

- Veins are corresponding to the arteries.
- **Circular venous plexus** are found at the base of nipple.
- Finally, veins of this plexus drain into **axillary & internal thoracic veins.**



AXILLARY LYMPH NODES



- The axillary nodes are arranged into 5 groups which lie in the axillary fat:
 - 1- Pectoral (Anterior) group:**

Which lies on pectoralis minor along lateral thoracic vessels.
 - 2- Subscapular (Posterior) group:**

Which lies on posterior wall of axilla on lower border of subscapularis along subscapular vessels.
 - 3- Brachial (Lateral) group:**

Lies on lateral wall of axilla along **the axillary vessels**.
 - 4- Central group:**

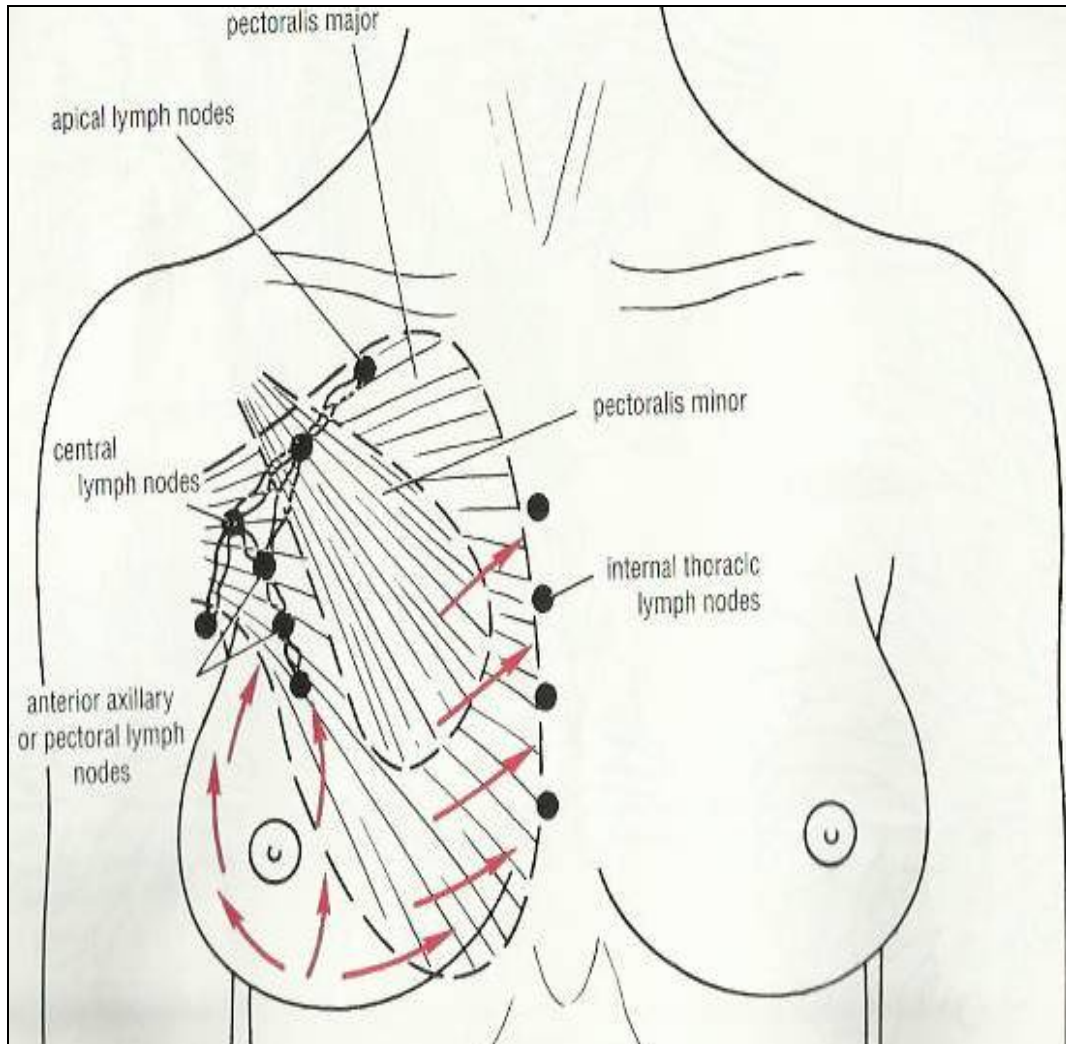
Lies in at the base of axilla.
 - 5. Apical group:**

Lies at apex of axilla.

 - **Subclavian lymph trunk:**
 - it is formed by union of efferent lymph vessels of apical group.
 - It usually opens in subclavian vein. **On the left side** it usually opens into thoracic duct.



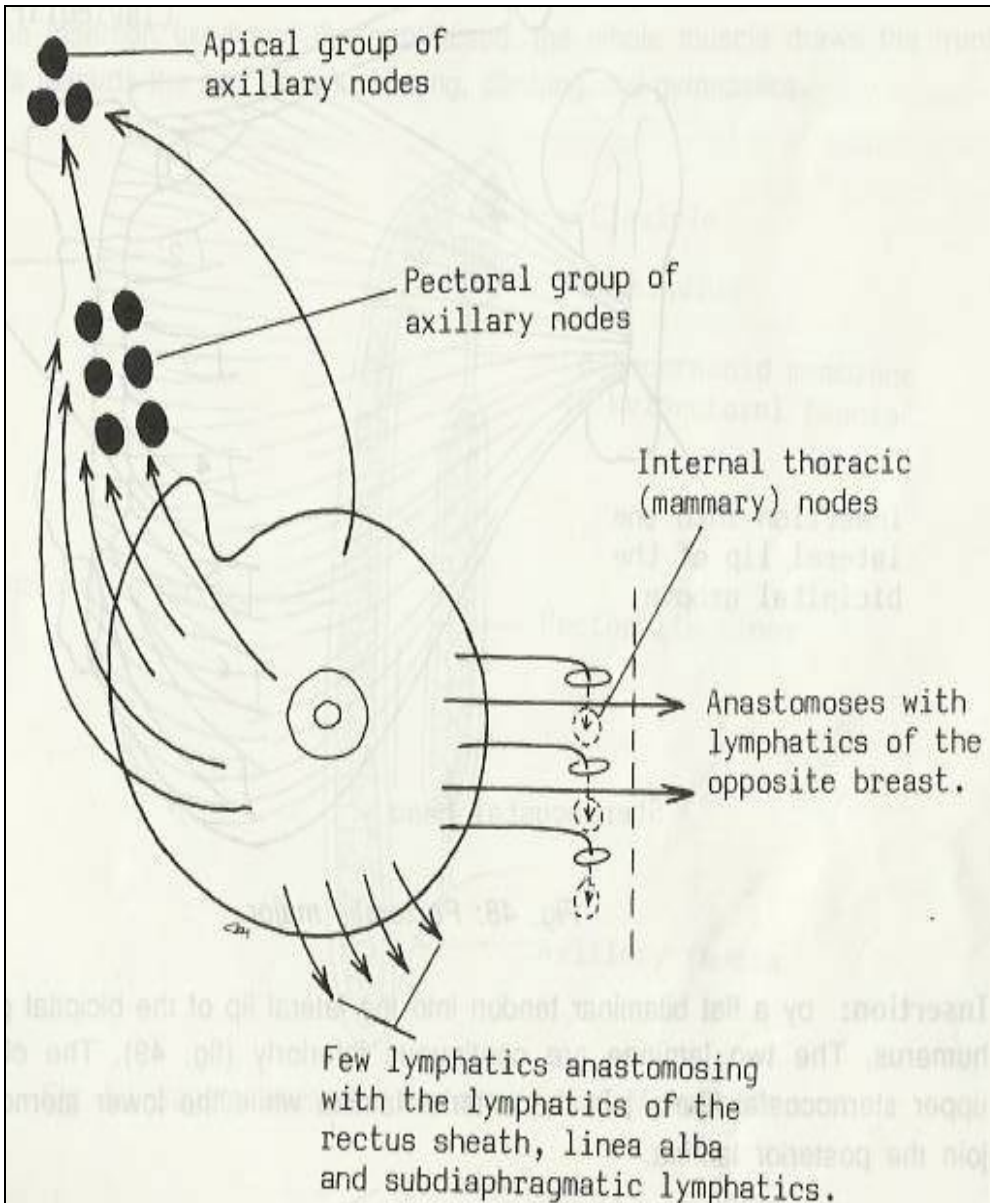
LYMPHATIC DRAINAGE



- **Subareolar lymphatic plexus:**
- Lies beneath the areola.
- **Deep lymphatic plexus:**
- Lies on the deep fascia covering pectoralis major.
- **Both plexuses** radiate in many directions and drain into different lymph nodes.



LYMPHATIC DRAINAGE

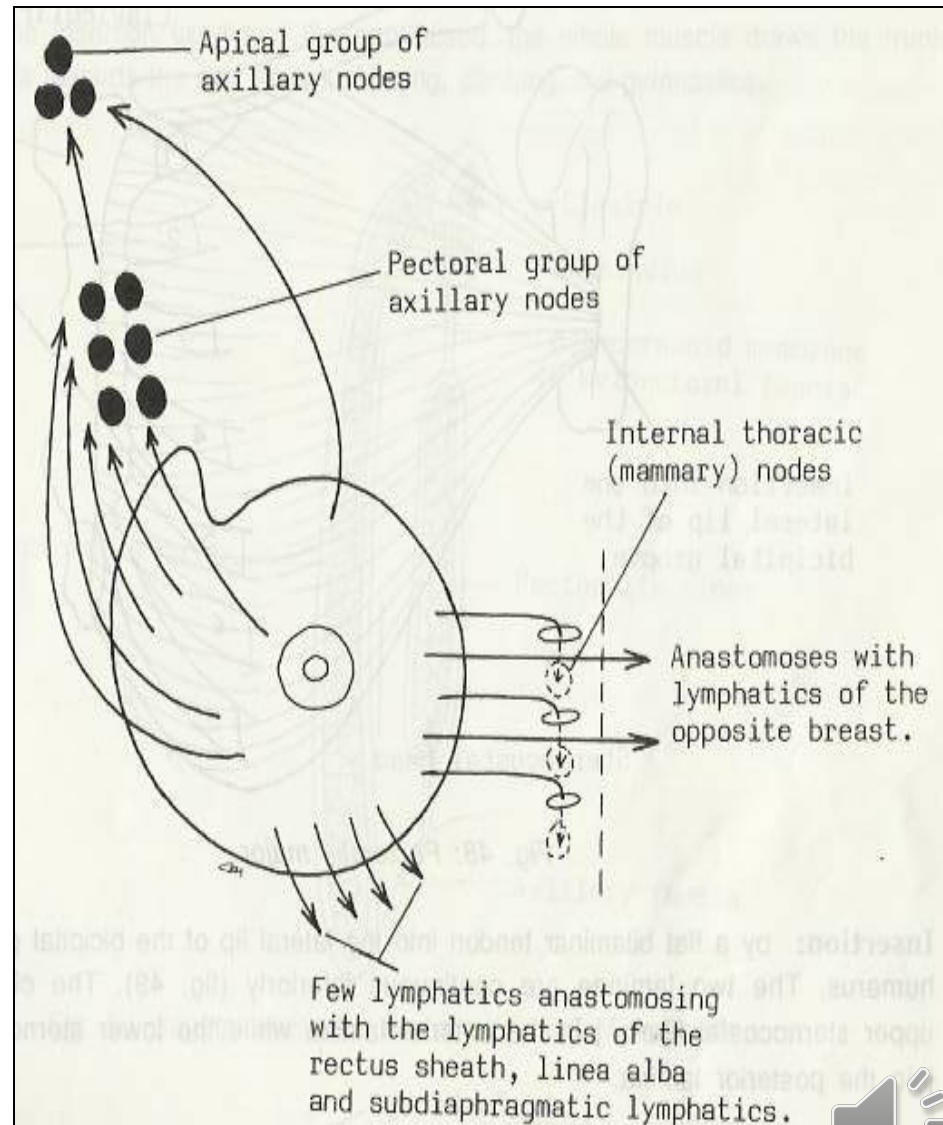


- **Central & lateral parts** of the breast (75%) drain into pectoral group of axillary lymph nodes.
- **Upper part** of the gland drains into apical group of axillary nodes.
- **Medial part** drains into internal thoracic (**Parasternal**) lymph nodes, forming a chain along the internal thoracic vessels.
- **Some lymphatics from the medial part** of the gland pass across the front of sternum to anastomose with that of opposite side.
- Lymphatics from the **inferomedial part** anastomose with lymphatics of rectus sheath & linea alba, and some vessels pass deeply to anastomose with the subdiaphragmatic lymphatic.



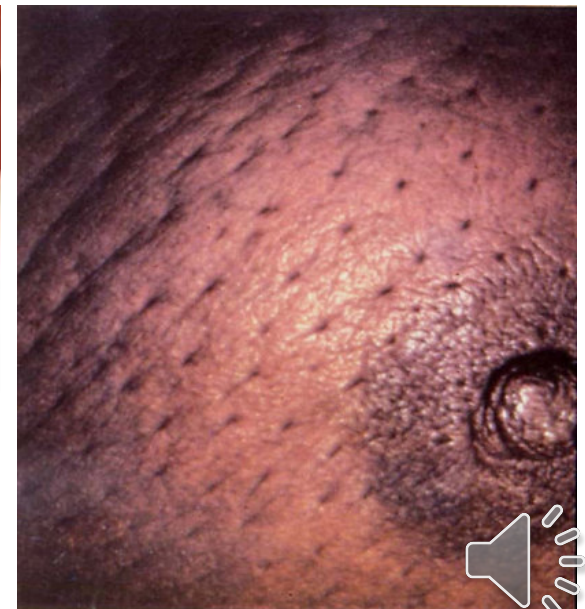
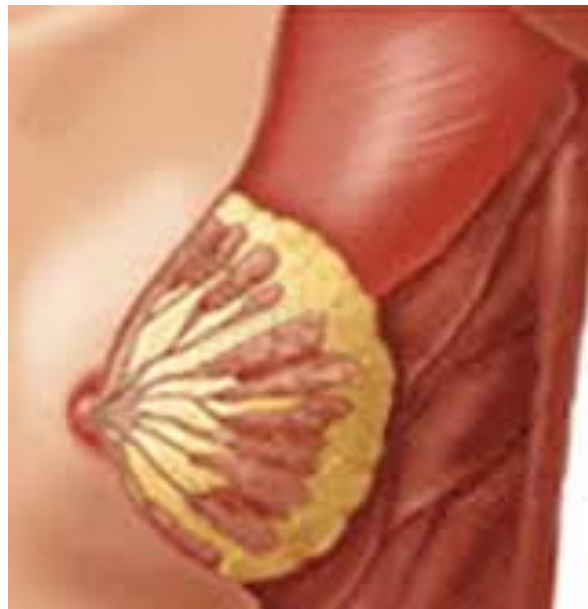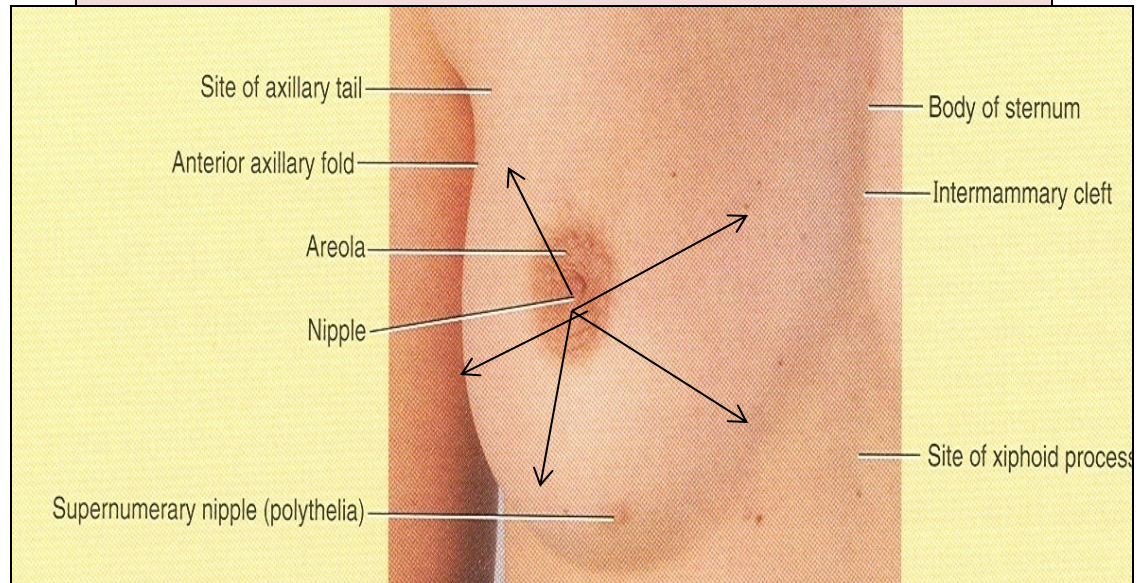
APPLIED ANATOMY- CANCER BREAST

- It is a common surgical condition.
- 60% of carcinomas of breast occur in the upper lateral quadrant.
- 75% of lymph from the breast drains into the **axillary lymph nodes**.
- In case of carcinoma of one breast, the other breast and the opposite axillary lymph nodes are affected because of the anastomosing lymphatics between both breasts.
- In patients with **localized cancer breast**, a simple mastectomy, followed by radiotherapy to the axillary lymph nodes is the treatment of choice.



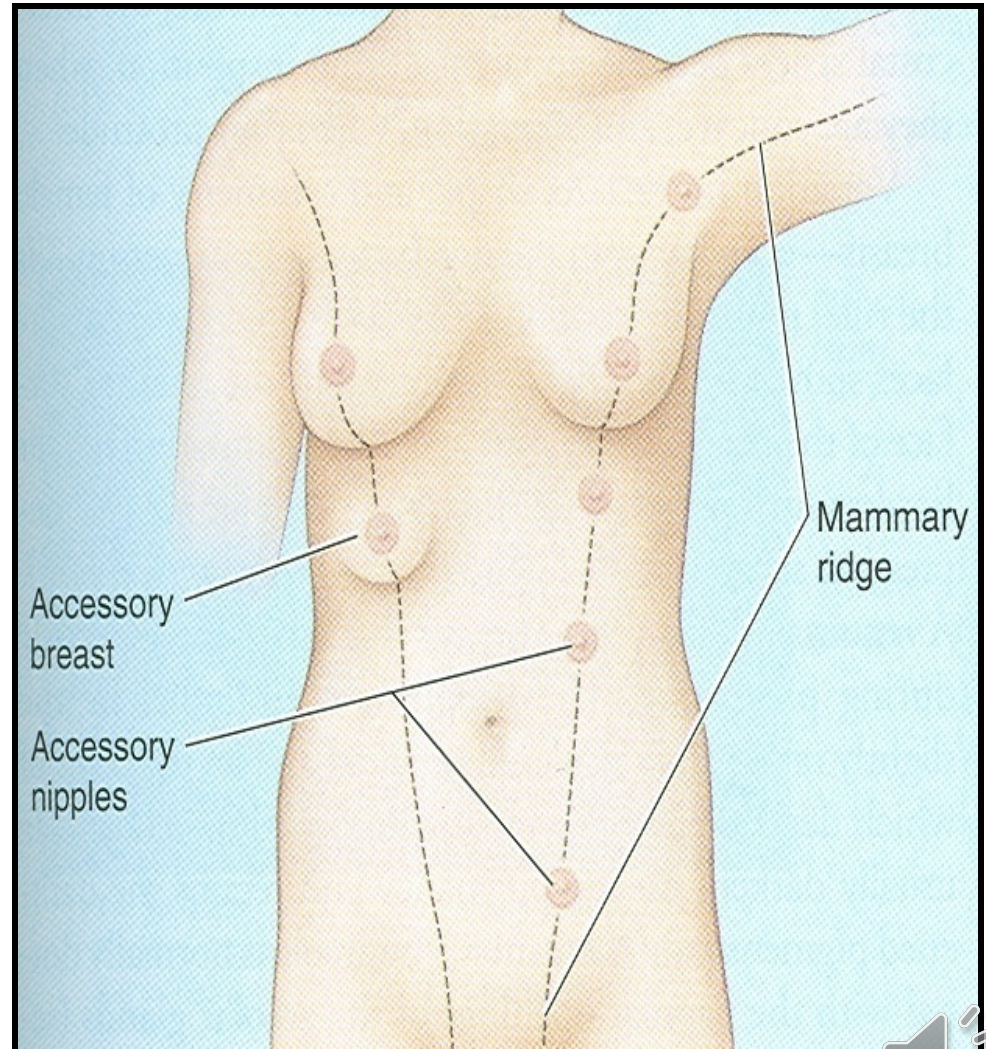
Applied Anatomy

- The lactiferous ducts are radially arranged from the nipple, so incision of the gland should be made in a radial direction to avoid cutting through multiple ducts.
- Infiltration of the ligaments of Cooper by **breast cancer** leads to its shortening giving **peau de 'orange** appearance of the breast.



Mammary ridge

- **Mammary ridge** extends from the axilla to the groin (inguinal region).
- In human, the ridge disappears **EXCEPT** for a small part in the **pectoral region**.
- In animals, several mammary glands are formed along this ridge.



**THANK YOU
AND
GOOD LUCK**

Peau de 'orange

