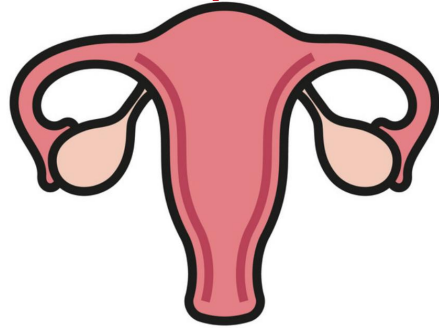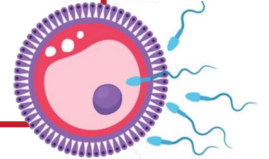


# Male reproductive system

Reproductive block-Anatomy-Lecture 4

Editing file

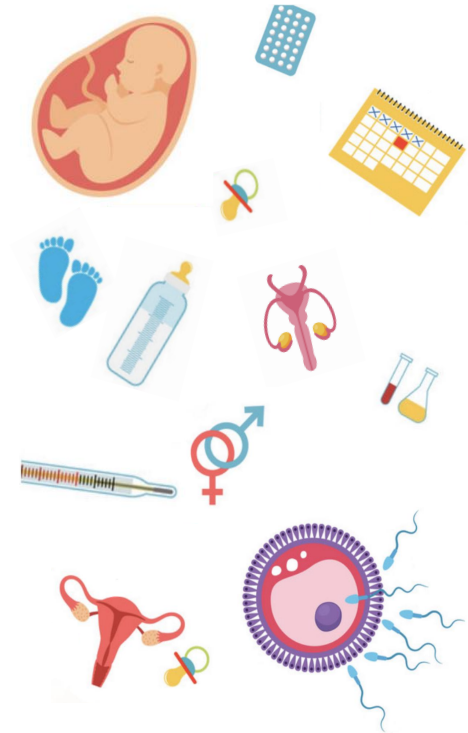

# Objectives

**Color guide :**  
Only in boys slides in **Green**  
Only in girls slides in **Purple**  
important in **Red**  
Notes in **Grey**

 **At the end of the lecture, students should be able to:**

- List the different components of the male reproductive system.
- Describe the anatomy of the primary and the secondary sex organs regarding: (location, function, structure, blood supply & lymphatic drainage).
- Describe the anatomy of the male external genital organs.



# Components of the Male Reproductive System

It Divided into

**Primary sex organ**

First: **Testes**

**Reproductive tract**

Second: **Epididymis**

Third: **Vas Deferens**

Spermatic Cord

**Accessory sex glands**

Fourth: **Seminal Vesicles**

Fifth: **Prostate Gland**

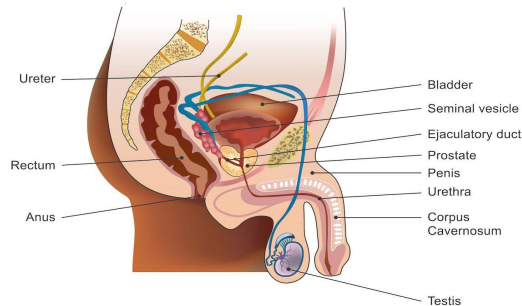
Sixth: **Bulbourethral Glands**

**External genitalia**

Seventh: **Penis**

## Functions

1. Secretion of seminal fluid.
2. Nourishing, activation of sperms.
3. Protection of sperms.



# First: Testes

## Testes: Scrotum

- An outpouching of loose skin and superficial fascia.
- The left scrotum is slightly lower than the right. (because the sigmoid colon compress the left testicular vein so left testes descend down ,and that's why varicose vein appear first in the left side)

## Functions:

1. Houses and protects the testis.
2. Regulates testicular temperature (no testicular -superficial - fat).
3. It has thin skin with sparse hair and sweat glands.
4. **The Dartos muscle** lies within the superficial fascia and replaces Scarpa's fascia of the anterior abdominal wall. (In cold weather the skin of the scrotum shrinks upward , & In hot weather the muscle relaxes and the Scrotum descend downward )

## Testes: Shape

- Paired almond
- suspended in the scrotum by the spermatic cord
- Testis or Testicle (singular), Testes (plural).
- Its volume is about 20-25 ml.
- length 4-5 cm. ·Weight 10.5-14 gm.

## Testes: Coverings

1

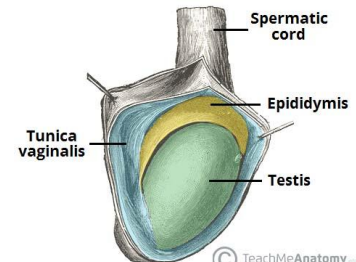
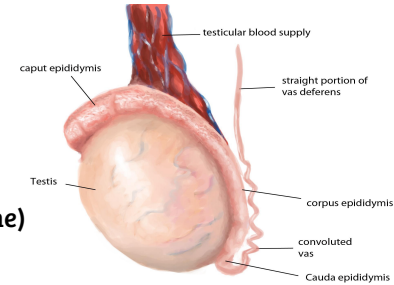
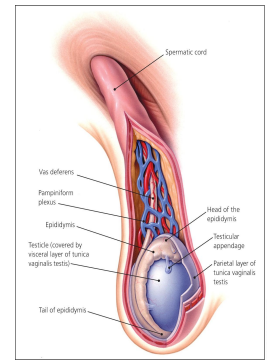
### Tunica Vaginalis:

- Peritoneal covering formed of parietal and visceral layers.
- It surrounds the testis and epididymis.
- It allows free movement of testis within the scrotum.

2

### Tunica Albuginea:

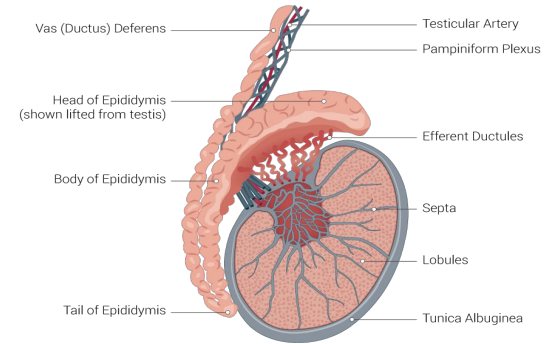
- It is a whitish fibrous capsule.



# First: Testes cont.

## Testes: Internal Structures

- **Fibrous septae:** extend from the capsule, dividing the testis into 200-300 **lobules** (average 250).
- **lobules:** Each lobule contains 1-3 **Seminiferous Tubules** (each is 60cm coiled tubule)
- **Seminiferous Tubules:**
  - They are the site of spermatogenesis.
  - They form the bulk of the testicular tissue.
  - In between the seminiferous tubules lies the **Interstitial cells of Leydig** which secretes **Testosterone hormone**.
- **Rete testis:**
  - A network of tubules.
  - It is the site of merging of the seminiferous tubules.



## Testes: Supply

### Arterial supply

- **Testicular Artery**
- it arises from the abdominal aorta at the level of **L3**

### Venous drainage

- Pampiniform plexus of veins** : About dozen of veins which forms a network within the spermatic cord, they become larger as they approach the inguinal canal to form the **Testicular vein**.
- Right vein drains into **IVC**
  - Left vein drains into **Left renal vein**

### Lymphatics drainage

- **Testicular** Lymphatics follow arteries and veins of the testis and end in the **Lumbar(paraortic) nodes**.
- **Scrotum, Penis and Prepuce** terminate in **Superficial inguinal nodes**.

important In case of testicular carcinoma



# First: Testes cont.

## Cremasteric Reflex

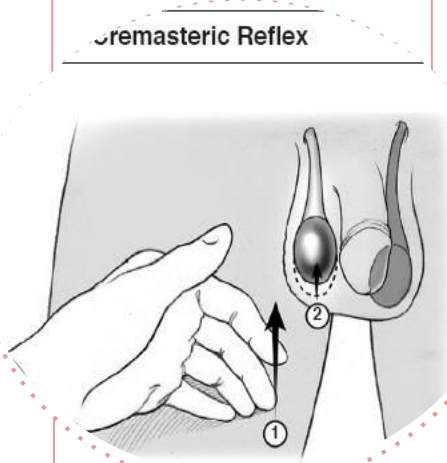
**Indication:** Evaluation of Testicular pain in case of (Testicular Torsion).

**Technique:** Examiner strokes or pinches the skin in the upper medial thigh. It causes cremasteric contraction which is Supplied by the genital branch of genitofemoral nerve.

### Efficacy:

Test sensitivity for Testicular Torsion: 99%.

\*Assumes age over 30 months(2.5 years )



**Observation:** rise of the testicle on the same side (normal).

### Interpretation:

- Normal: it is present with Epididymitis.
- Absent (No testicles rise): suggestive of Testicular Torsion.  
\*Also absent in 50% of boys under the age of 30 months (Do not use this under the age of 30 months).

**Nerve involved:** Genitofemoral (GFN) from (L1, L2).  
it's a reflex thus has an afferent fibers, center and efferent fibers

- Sensory(afferent) :
  - Femoral branch of (GFN)
  - Ilioinguinal.
- Center : L1 ,L2
- Motor (efferent): Genital branch of (GFN)

# Second: Epididymis

## Shape and Location

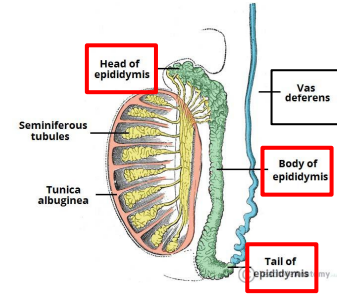
- It is a single **coiled tubule**.
- **6 meters long**.
- Located on the **posterior and superior** margins of the testis.

## Divisions

1. **Head**: receives (rete testis) efferent ductules from the testes. (the most expanded part **above** the Testicle)
2. **Body**: **behind** the Testicle
3. **Tail**: continuous with vas deferens.

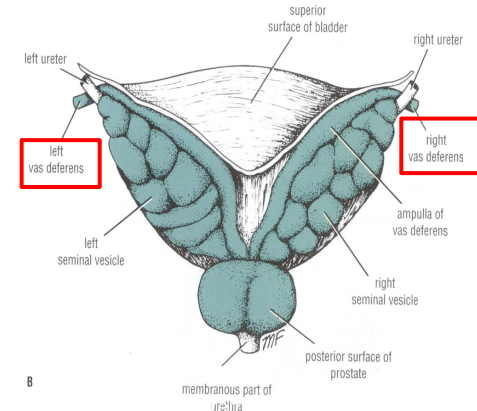
## Functions

- **Secrete and absorb** the nourishing fluid.
- **Recycles** damaged spermatozoa.
- **Stores spermatozoa up to 2 weeks** to allow for **physiological maturation of sperms**



# Third: Vas Deferens

- It is a muscular tube about **45 cm long**.
- Carries sperms from the **epididymis** to pelvic cavity.
- Passes through the inguinal canal as one of the contents of the **spermatic cord**.
- It crosses the lower end of the ureter.
- Its terminal part is dilated to form the **Ampulla of the vas**.
- It joins the duct of the seminal vesicle to form the ejaculatory duct which opens into the prostatic urethra.



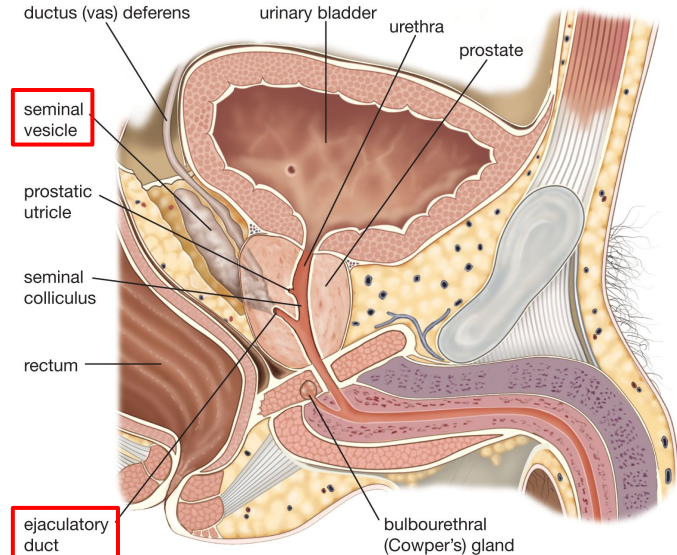
# Fourth: Seminal Vesicle & Ejaculatory ducts

## Seminal Vesicle

- Paired elongated glands (SV).
- Located posterior & inferior to the urinary bladder.
- Lies lateral to the vas deferens.
- Secrete (60% of the Seminal fluid).

## Ejaculatory ducts

- Formed by the union of the lower end of the vas deferens and the duct of the seminal vesicle.
- Its length is about 2.5cm (1 inch)
- The 2 ejaculatory ducts open into the prostatic urethra on both sides of the seminal colliculus.
- They drain the seminal fluid into the prostatic urethra.



© 2012 Encyclopædia Britannica, Inc.



# Fifth: Prostate gland

## Prostate gland: Structure

- The Largest male accessory gland.
- It is a fibromuscular glandular tissue.
- It is a walnut size.

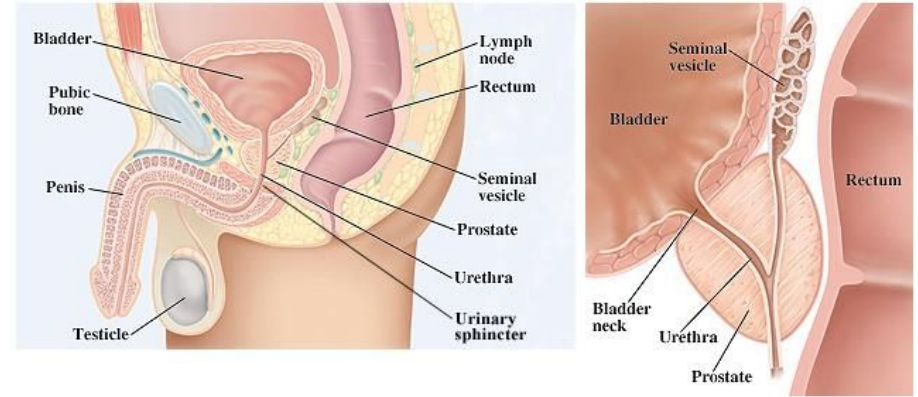
## Prostate gland: Location

- It is located at the neck of bladder.
- It is traversed by the prostatic urethra.

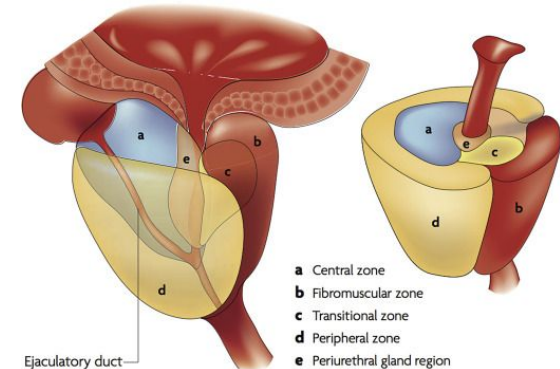
## Prostate gland: Shape

**Shape:** Conical, It has:

- **Base (Superior):** Attached to neck of urinary bladder.
- **Apex (Inferior):** rests on the Urogenital diaphragm.
- **Four Surfaces:**
  - Anterior
  - Posterior
  - 2 lateral (Right & Left) surfaces.



Prostate zones



# Fifth: Prostate gland

## Prostate gland: Functions

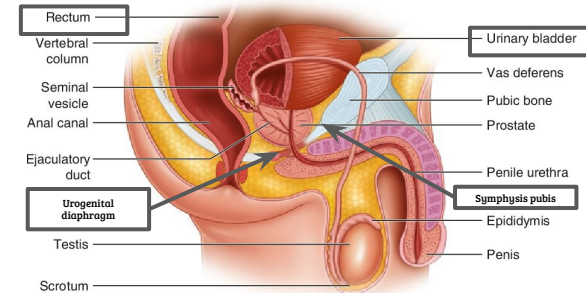
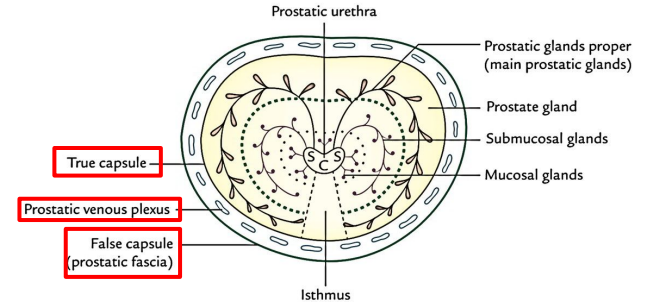
- It secretes enzymes which has the following functions:
  1. Aid in activating sperm motility.
  2. Mucus degradation.
  3. Neutralize the acidity of female reproductive tract (Alkaline fluid).
  4. **Antibiotic**
- It secretes (20-30% of seminal fluid.)
- **Houses prostatic urethra**

## Prostate gland: Capsule

- **Internally:** it has a dense fibrous capsule (**prostatic\true capsule**)
- **Externally:** surrounded from outside by a **fibrous prostatic sheath**(**false capsule**)which is continuous with the puboprostatic part of the levator ani muscle, (levator prostate).
- In between the prostatic capsule and the prostatic fibrous sheath lies the **prostatic venous plexus**.

## Prostate gland: Relations

- **Anterior:** Symphysis pubis (SP).
- **Superior:** Neck of the bladder.
- **Posterior:** Rectum (important for PR examination)
- **Inferior:** Urogenital diaphragm (UGD)
- **Lateral:** Medial margins of levator ani muscles (levator prostate)



# Fifth: Prostate gland

## Prostate gland: Lobes

- Anatomically divided into 5 lobes according to their relation to the urethra
- Urologists & Sonographers, divide the prostate into Peripheral and Central (Internal) zones instead of lobes
- Within each lobe are four lobules, which are defined by the ducts and connective tissue

01

- **Anterior lobe (isthmus):**

- Lies anterior to the urethra.
- Fibromuscular.
- has **no** glandular tissue

02

- **Posterior lobe (correspond to peripheral zone):**

- Posterior to the urethra and inferior to the ejaculatory ducts.

03

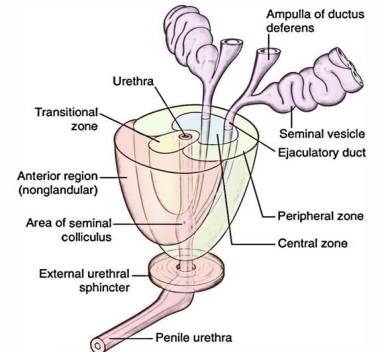
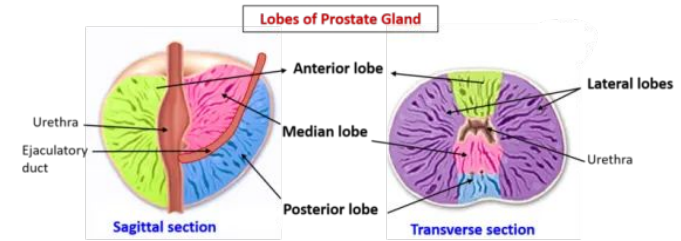
- **Two lateral lobes:**

- On each side of urethra.
- Rich in glandular tissue.

04

- **Middle (median):**

- Represented by The Central zone
- Between the urethra and ejaculatory ducts & closely related to neck of urinary bladder.
- Usually it projects into lumen of the urinary bladder distorting the internal urethral sphincter, after the age of 40 years, (**Benign Prostatic Hyperplasia**).
- Rich in glandular tissue.



# Fifth: Prostate gland cont.

## Prostate gland: supply

### Arterial supply

- **Inferior vesical artery** from **internal iliac artery**.

### Venous drainage

#### Prostatic venous plexus.

- Lies between **prostatic fibrous capsule** and **prostatic sheath**.
- **Drains** into the internal iliac veins.
- Continuous **superiorly** with the vesical venous plexus of the urinary bladder. continuous **posteriorly** to the internal vertebral venous plexus  
Within the vertebral canal (in case of prostate cancer it could metastasis to vertebral column and the brain)

### Lymphatics drainage

- **Internal iliac lymph nodes**.

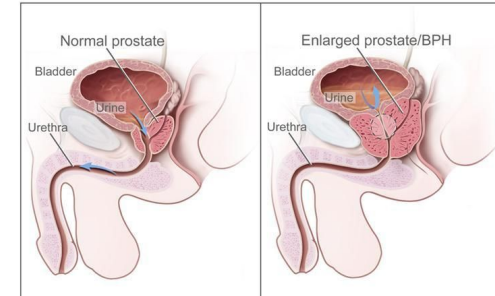
## Prostate gland: Clinical relation

### Benign: Hypertrophy of the Prostate

- Common after **middle** age.
- An enlarged prostate projects into the urinary bladder and distorts the prostatic urethra.
- The middle lobe often enlarges and obstructs the internal urethral orifice, this leads to **Nocturia, Dysuria, Frequency and Urgency**.

### Malignant: Prostatic carcinoma

- Common after the age of 55.
- prostate is felt hard & irregular in per-rectal examination, malignant cells metastasize first to internal iliac & sacral lymph nodes (lymphatic spread).
- Later to distant nodes, bone & brain through internal vertebral venous plexuses. (venous spread)
- **Can cause obstruction to urine flow because of its close relationship to the prostatic urethra.**



# Fifth: Prostate gland cont.

## Prostate gland: Prostatic Urethra

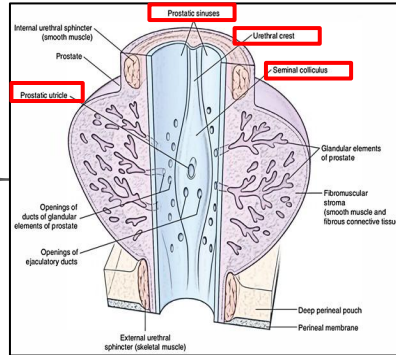
The following structures are seen on the **posterior** wall of the prostatic urethra:

### Urethral crest:

- A longitudinal elevated ridge.

### Prostatic sinus:

- A groove on each side of the crest.
- The prostatic gland opens into the prostatic sinus.



### Seminal colliculus:

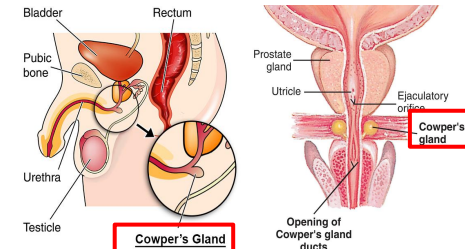
- A rounded eminence that opens into the prostatic utricle.

### Prostatic utricle:

- A depression on the summit of the urethral crest.
- The ejaculatory ducts open on the sides of the utricle

# Sixth: Bulbourethral Cowper's Gland

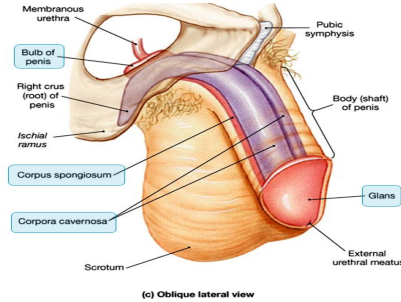
- Small paired glands.
- Located at the base of the penis.
- Secrete alkaline mucus for:
  - Neutralization of urinary acids
  - Lubrication.



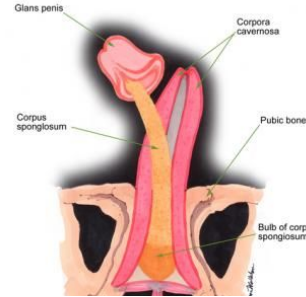
# Seventh: Penis

## A Copulatory and Excretory organ.

**Excretory part:**  
Penile urethra transmits urine & seminal fluid.

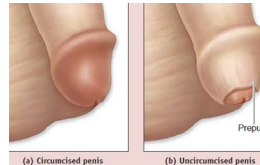
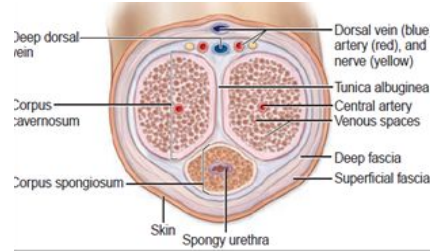


**Copulatory part:**  
Has (3) cylindrical masses of erectile tissue



### Two Corpora Cavernosa

- Two superior (right & left) masses of (Primary erectile tissue).
- Provide the majority of rigidity & length of penis.
- **Their posterior expansions**, forms the 2 Crurae Right crus and left crus which anchor penis to the pelvic bone (anchor tissue) against pelvic bone.



### One Corpus Spongiosum

- The single inferior mass (Secondary erectile tissue).
- It is traversed by the penile urethra.
- **Anterior expansion:** forms the Glans penis.
- **Posterior expansion:** forms the bulb of the penis.
- **Prepuce or foreskin:** fold of skin covering glans penis (before circumcision)

# QUIZ

Q1	Q2	Q3	Q4	Q5	Q6	Q7	Q8
A	A	B	C	B	D	C	B

**Q1:** Where is the body of the epididymis located related to the testes?

- A. Posterior
- B. Anterior
- C. Superior
- D. Inferior

**Q2:** Which group of the following lymph nodes receive from the testis?

- A. paraortic
- B. Pararectal
- C. Superficial inguinal
- D. Deep Inguinal

**Q3:** The union of the vas deferens and seminal vesicle form the .....

- A. epididymis
- B. Ejaculatory duct.
- C. Urethra
- D. Penis

**Q4:** Which of the following structures allows free movement of the testes

- A. Cremasteric muscle
- B. Tunica albugenia
- C. Tunica vaginalis
- D. Dartos muscle

**Q5:** which lobe of prostate gland has no glandular tissue

- A. lateral
- B. Anterior
- C. middle
- D. posterior

**Q6:** which structure will be affected in case of obstruction of internal iliac artery?

- A. penis
- B. testes
- C. Cowper's Gland
- D. prostate gland

**Q7:** in case of carcinoma of the penis. Cancer cells are likely to metastasize to which one of the following nodes?

- A. paraortic
- B. Pararectal
- C. Superficial inguinal
- D. Deep Inguinal

**Q8:** when you are testing the Cremasteric Reflex in a patient, the normal observation should be

- A. rise of the both testicles
- B. rise of the testicle on the same side
- C. rise of the testicle on the opposite side



# Members board



## Team leaders



**Abdulrahman Shadid**

• **Ateen Almutairi**

### Boys team:

- **Mohammed Al-huqbani**
- **Salman Alagla**
- **Ziyad Al-jofan**
- **Ali Aldawood**
-  **Khalid Nagshabandi**
- **Sameh nuser**
-  **Abdullah Basamh**
-  **Alwaleed Alsaleh**
- **Mohaned Makkawi**
- **Abdullah Alghamdi**

### Girls team :

- **Ajeed Al Rashoud**
- **Taif Alotaibi**
- **Noura Al Turki**
- **Amirah Al-Zahrani**
- **Alhanouf Al-haluli**
- **Sara Al-Abdulkarem**
- **Renad Al Haqbani**
- **Nouf Al Humaidhi**
- **Jude Al Khalifah**
- **Nouf Al Hussaini**
- **Danah Al Halees**
- **Rema Al Mutawa**
- **Maha Al Nahdi**
- **Razan Al zohaifi**
- **Ghalia Alnufaei**

Contact us:

