

CEREBRUM

Dr. Jamila EL Medany

Dr Essam Salama

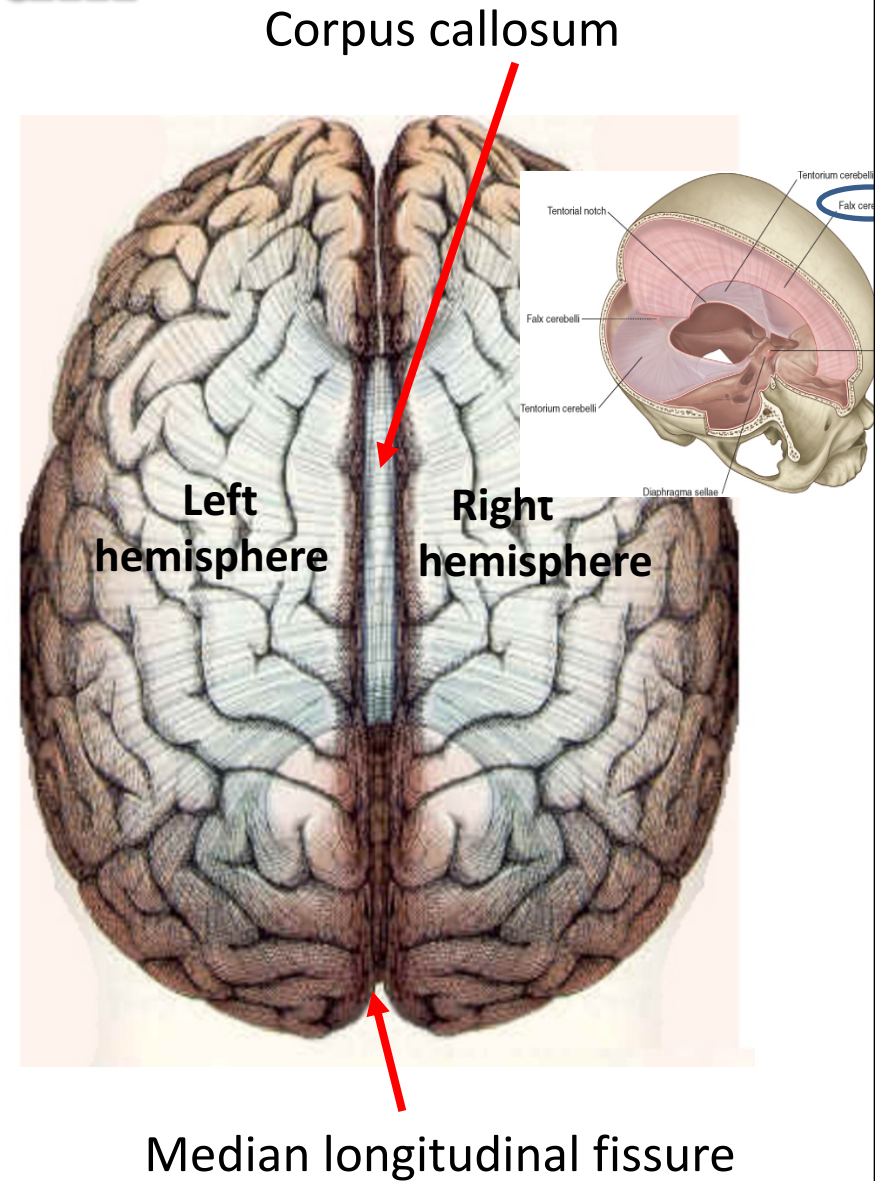
Objectives

At the end of the lecture, the student should be able to:

- List the parts of the cerebral hemisphere (cortex, medulla, basal nuclei, lateral ventricle).
- Describe the subdivision of a cerebral hemisphere into lobes.
- List the important sulci and gyri of each lobe.
- Describe different types of fibers in cerebral medulla (association, projection and commissural) and give example of each type.

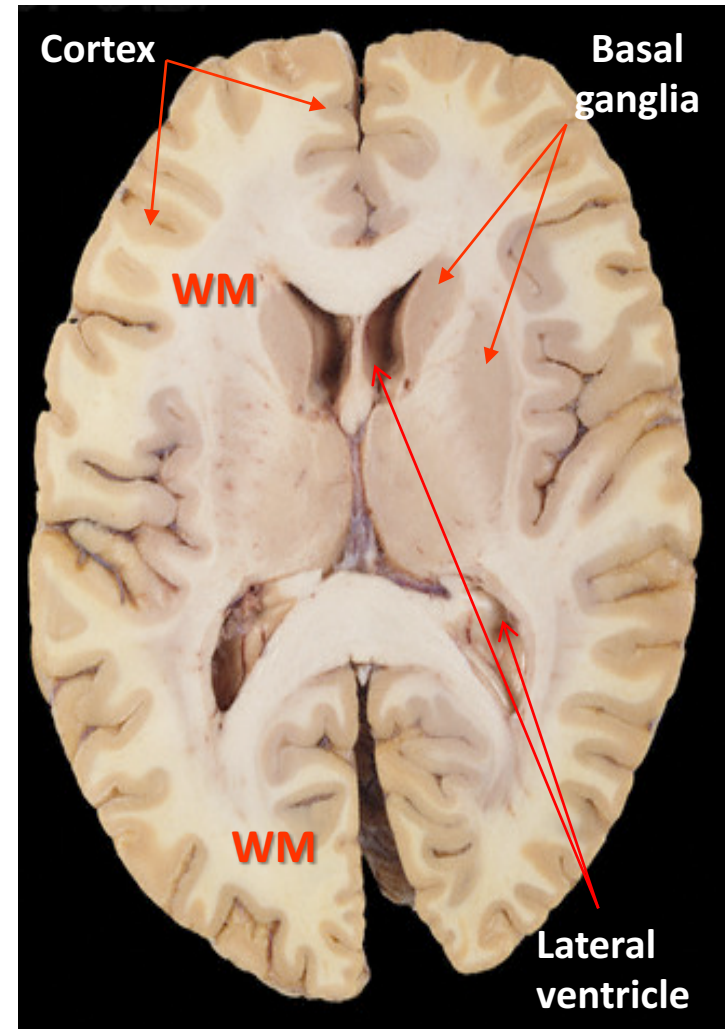
Cerebrum

- Largest part of the forebrain.
- Divided into two halves, the (**cerebral hemispheres**), which are separated by a deep median longitudinal fissure which lodges the **falx cerebri**.
- In the depth of the fissure, the hemispheres are connected by a bundle of fibers called the **corpus callosum**.



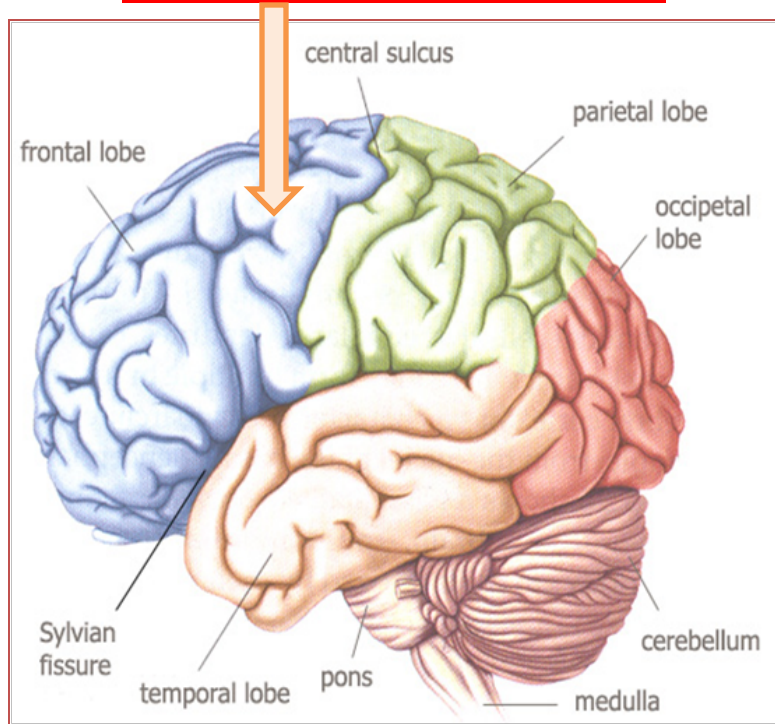
Structure of Cerebrum

- ❑ **Cerebral cortex:** Superficial layer of grey matter
- ❑ **Medulla (White matter) :** Deeper to the cortex, contains axons to and from the cells of the cortex
- ❑ **Basal ganglia:** Number of nuclear masses buried within the white matter
- ❑ **Lateral ventricle:** The cavity of hemisphere

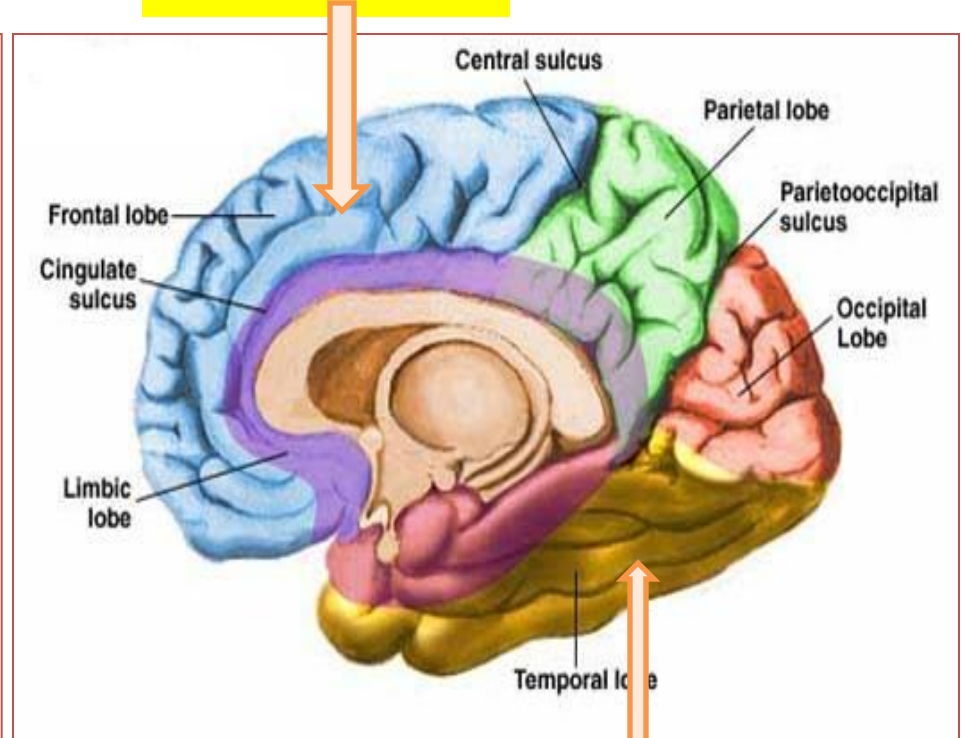


Surfaces(3)

Superolateral



Medial

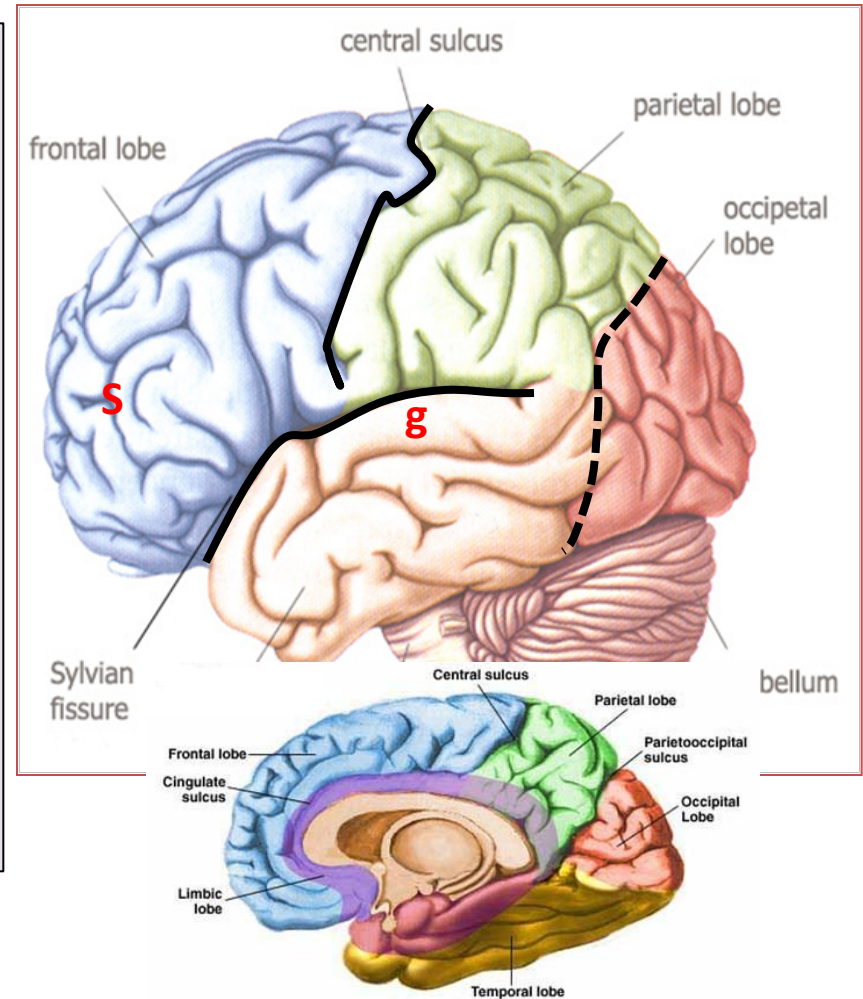


Inferior (tentorial)

Lobes of Cerebrum

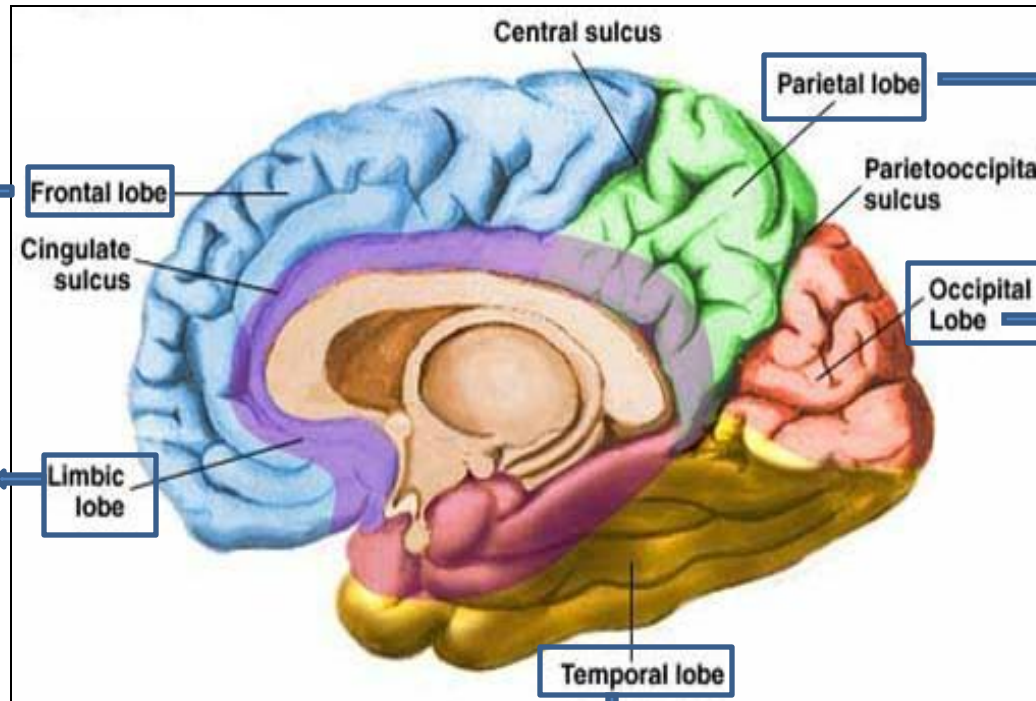
The superficial layer of grey matter is highly convoluted to form a complex pattern of ridges (**gyri**) and grooves (**sulci**). This arrangement maximizes the surface area of the cerebral cortex (about 70% is hidden within the depths of sulci).

- **Three sulci**, consistent in position, named **central**, **lateral (sylvian)** & **parieto-occipital**, divide each hemisphere into **FOUR** lobes: **Frontal**, **Parietal**, **Temporal** & **Occipital** (named after overlying bones) Functionally each hemisphere contains a '**limbic lobe**' on the medial surface.



Function of Lobes

**motor function,
motivation,
aggression,
smell and
mood**



**reception
and
evaluation
of sensory
information**

visual processing

**emotions,
memory
storage &
Linking
conscious
intellectual
functions with
the unconscious
autonomic
functions,**

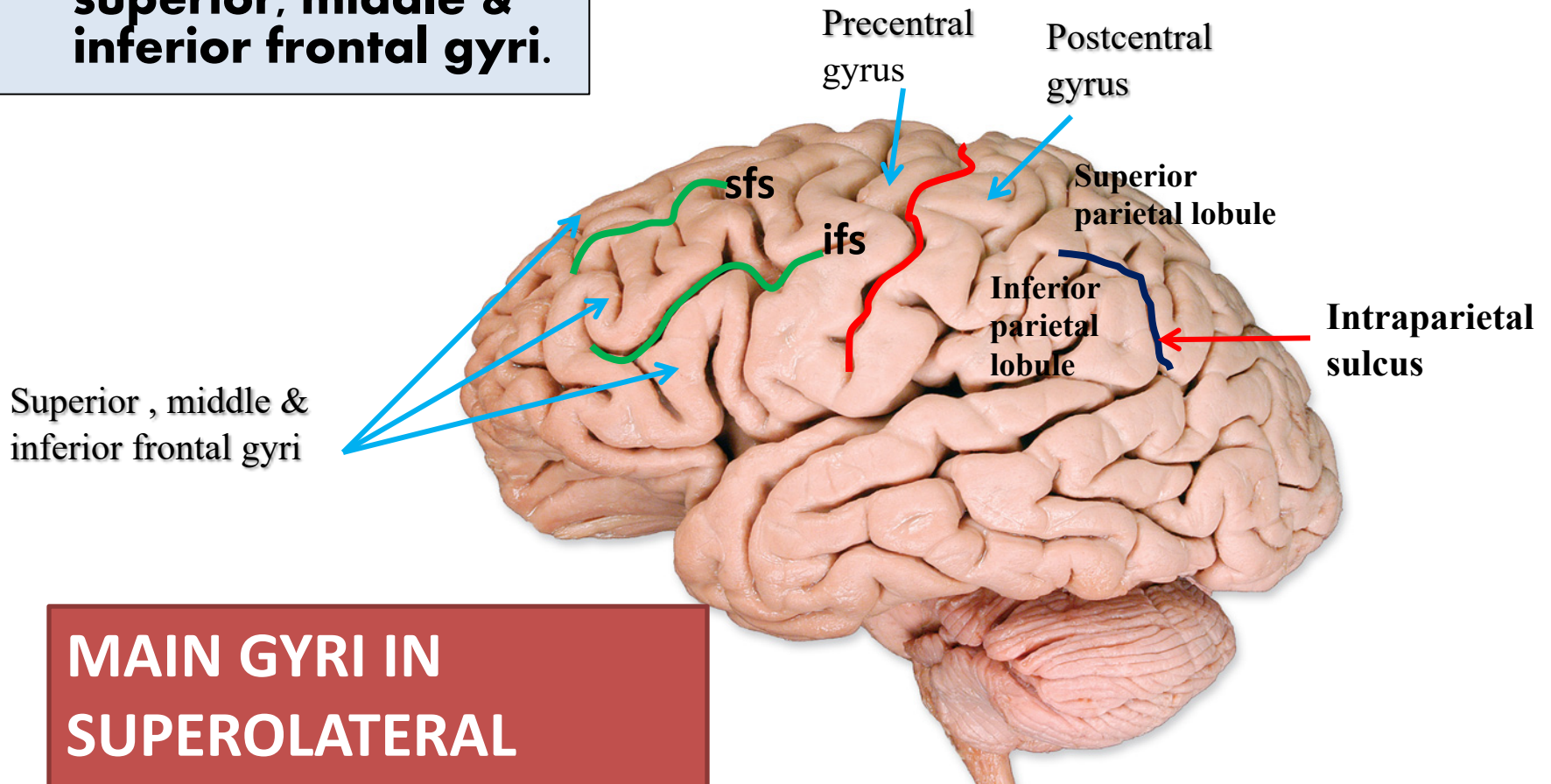
**smell, hearing,
memory and
abstract
thought**

❑ **Frontal lobe:**

- **Precentral gyrus.**
- **Superior & inferior frontal sulci divide the lobe into superior, middle & inferior frontal gyri.**

❑ **Parietal lobe:**

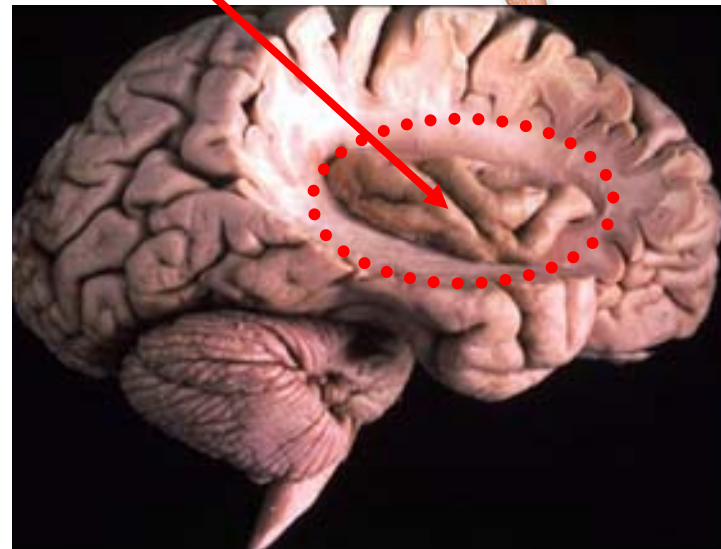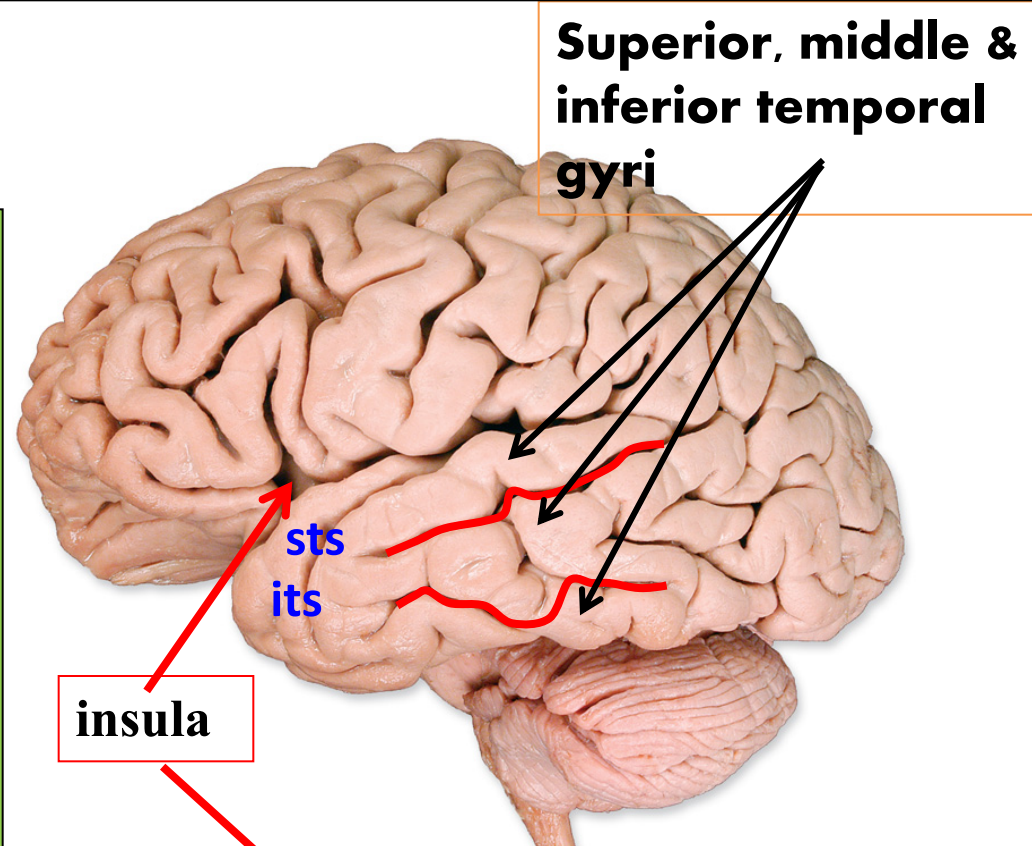
- **Postcentral gyrus.**
- **Intraparietal sulcus divide the lobe into superior & inferior parietal lobules.**



MAIN GYRI IN SUPEROLATERAL SURFACE

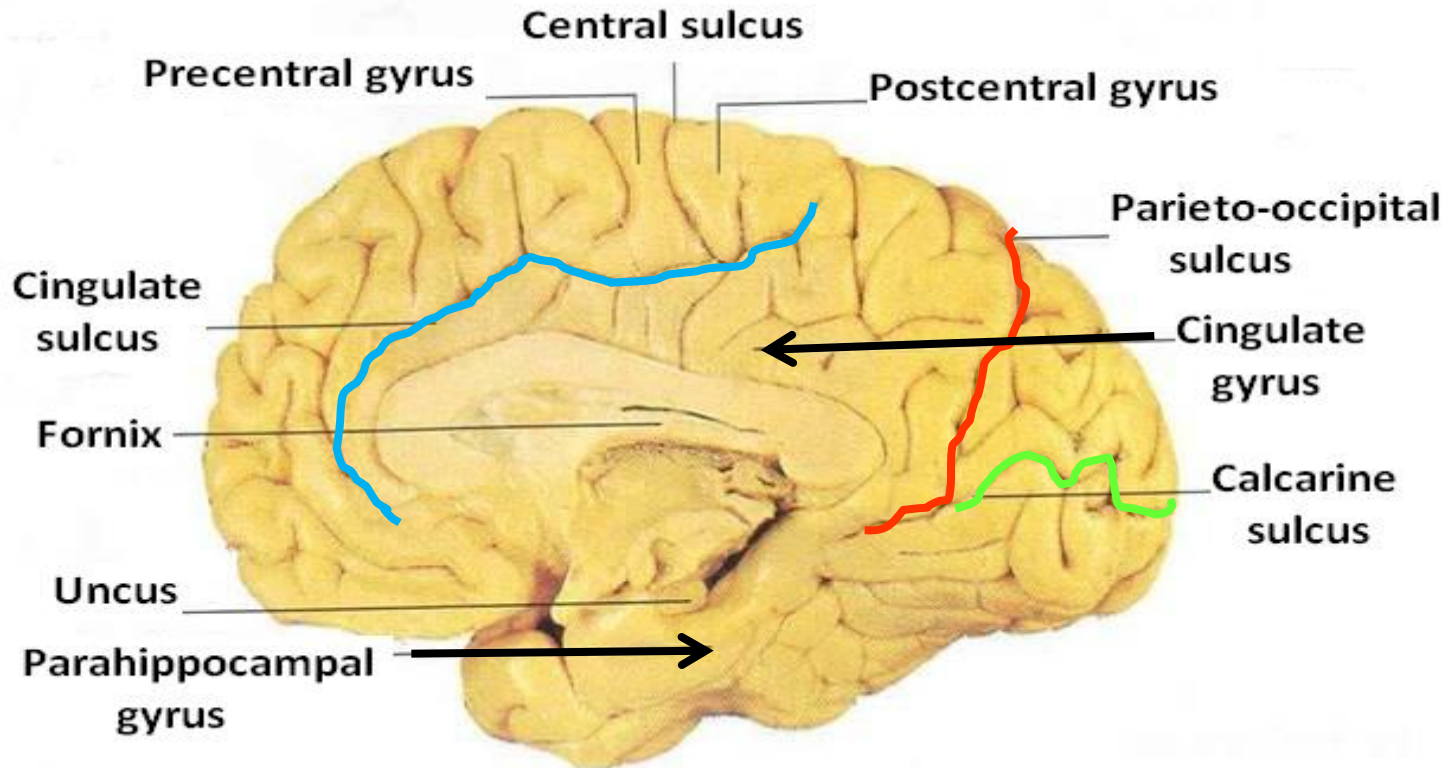
❑ Temporal lobe:

- **Superior & inferior temporal sulci** giving rise to superior, middle & inferior temporal gyri.
- **Insula**: the gyrus in the depth of lateral sulcus, covered by parts of frontal, parietal & temporal lobes called the **opercula** (removed in lower picture.).



Medial Surface

- **Sulci: Parietooccipital, Calcarine, Cingulate**
- **Gyri: Cingulate, Parahippocampal**



Functional Areas of the Cerebral Cortex

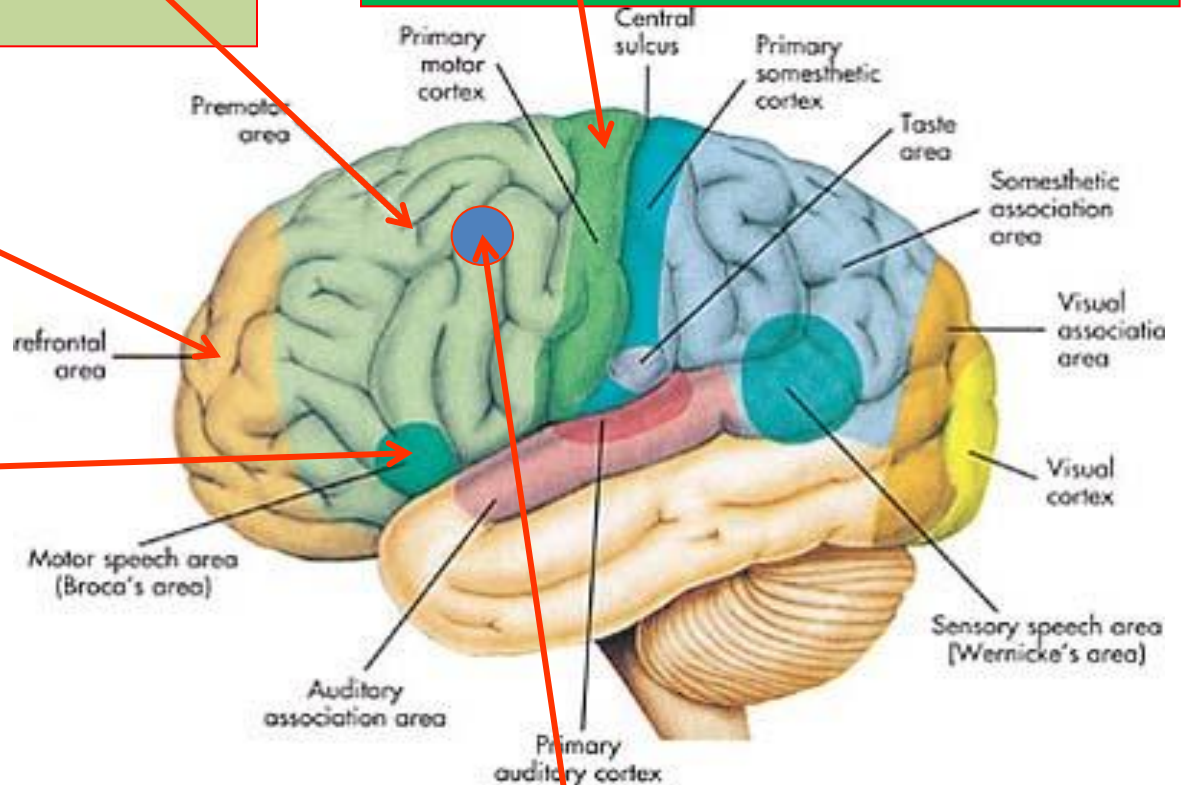
Frontal Lobe

Premotor cortex: Located in the region immediately anterior to the precentral gyrus (**Brodmann's area 6**).

Prefrontal cortex: Extensive region of the frontal lobe anterior to premotor area.

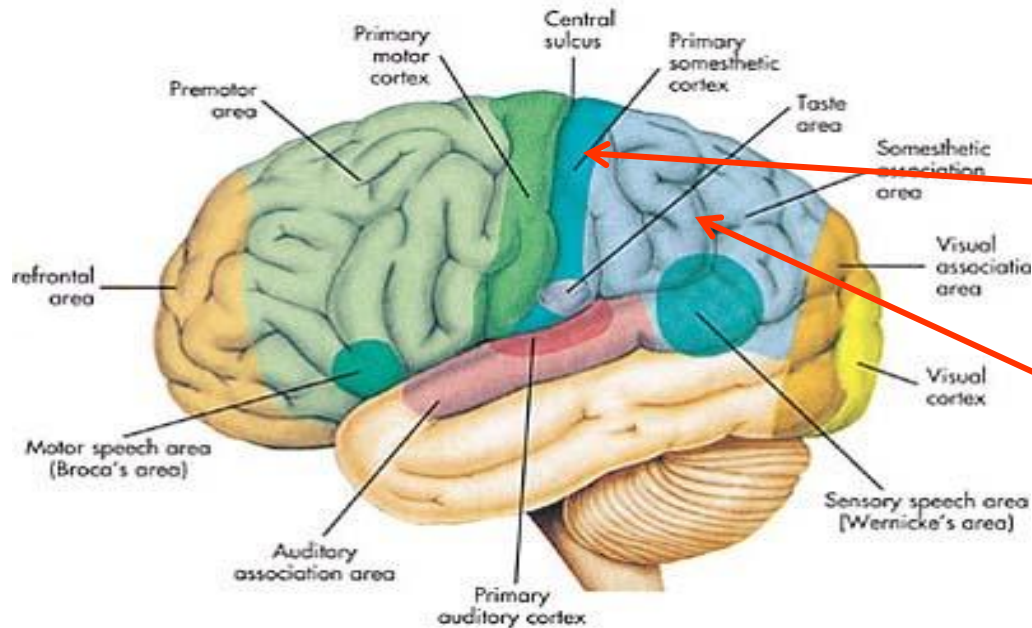
Broca's (motor speech) area: Located in the inferior frontal gyrus of the dominant hemisphere, usually left (**Brodmann's area 44 & 45**).

Primary motor cortex: Located in precentral gyrus (**Brodmann area 4**).



Frontal eye field: Located in the middle frontal gyrus immediately in front of motor cortex (**Brodmann's area 8**).

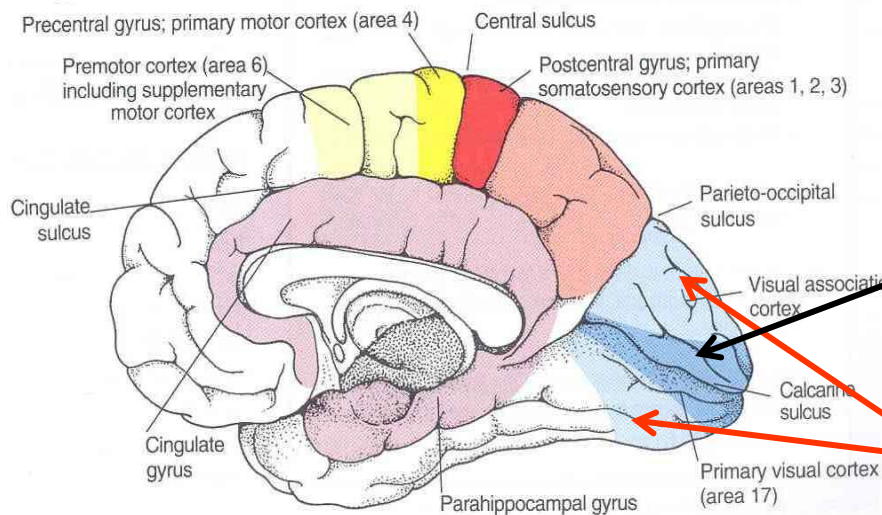
Parietal lobe



Primary somatosensory cortex: located in postcentral gyrus (Brodmann's area 1, 2, 3).

Parietal association cortex: located posterior to primary somatosensory cortex.

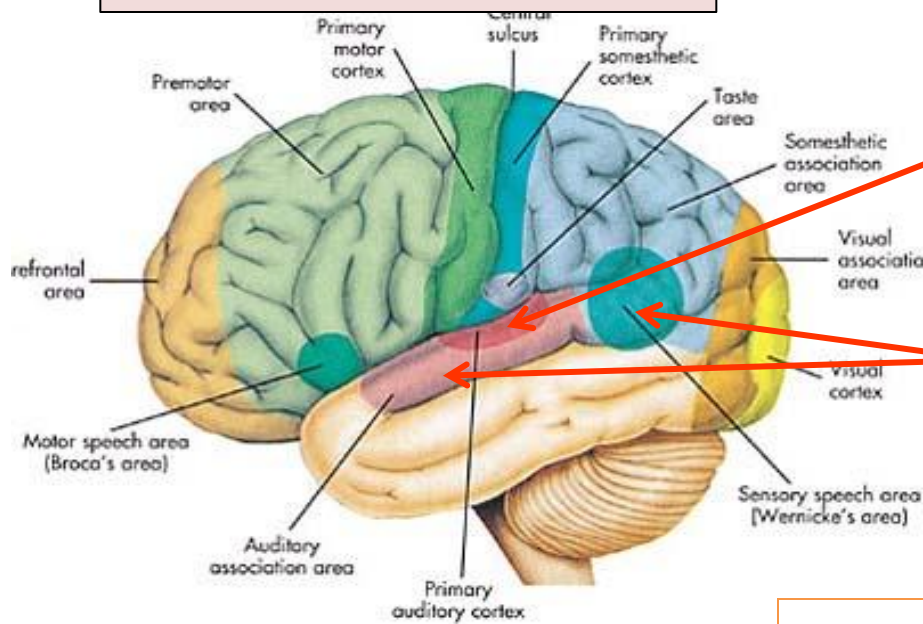
Occipital lobe



Primary visual cortex: located on the medial surface of the hemisphere, in the gyri surrounding the calcarine sulcus (**Brodmann's area 17**).

Visual association cortex: located around the primary visual cortex. Area 19

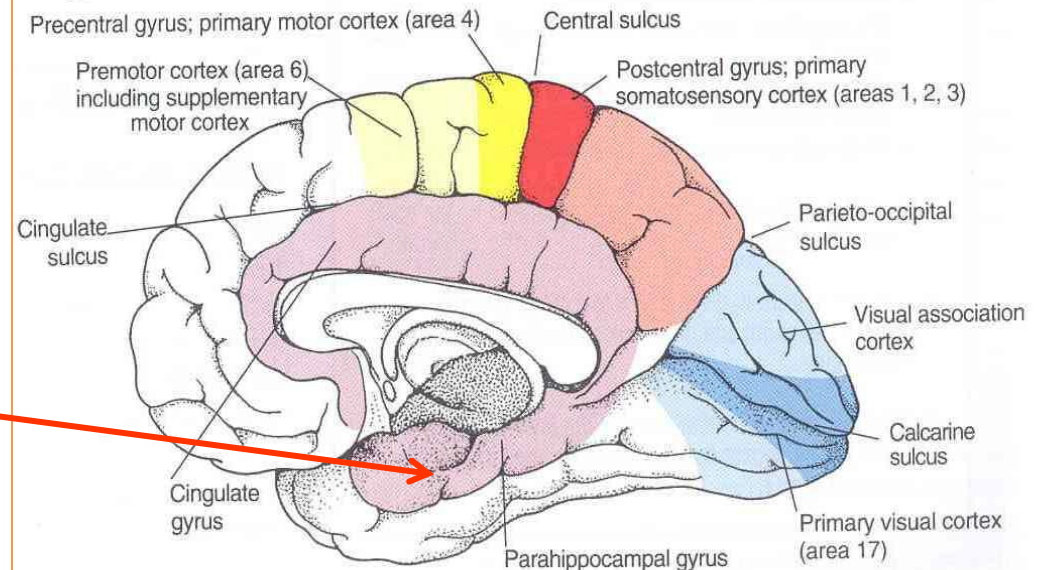
Temporal Lobe

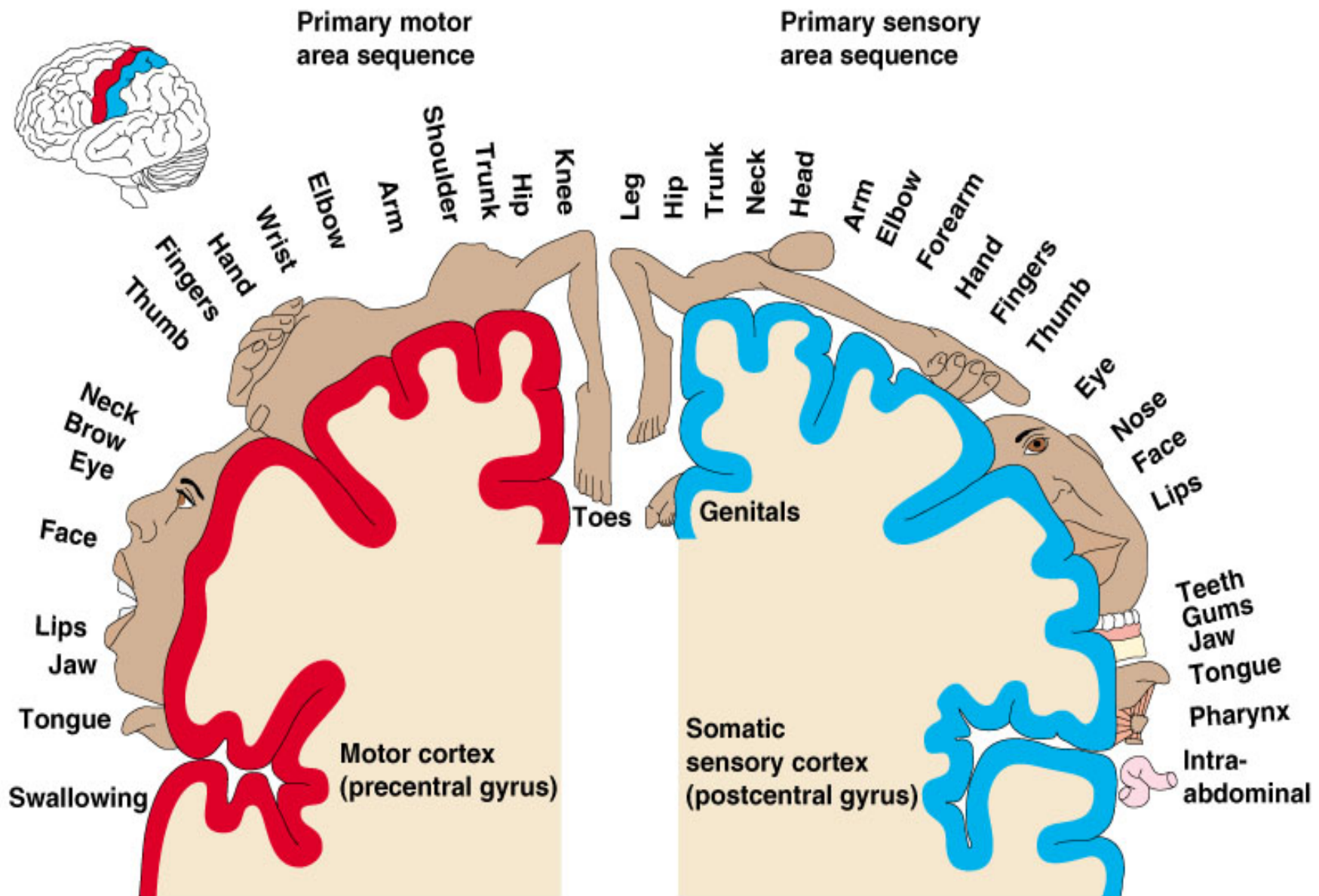


Primary auditory cortex: located in the superior surface of the superior temporal gyrus (**Brodmann's area 41, 42**)

Auditory association cortex: located immediately around the primary auditory cortex (also includes **Wernick's area**)

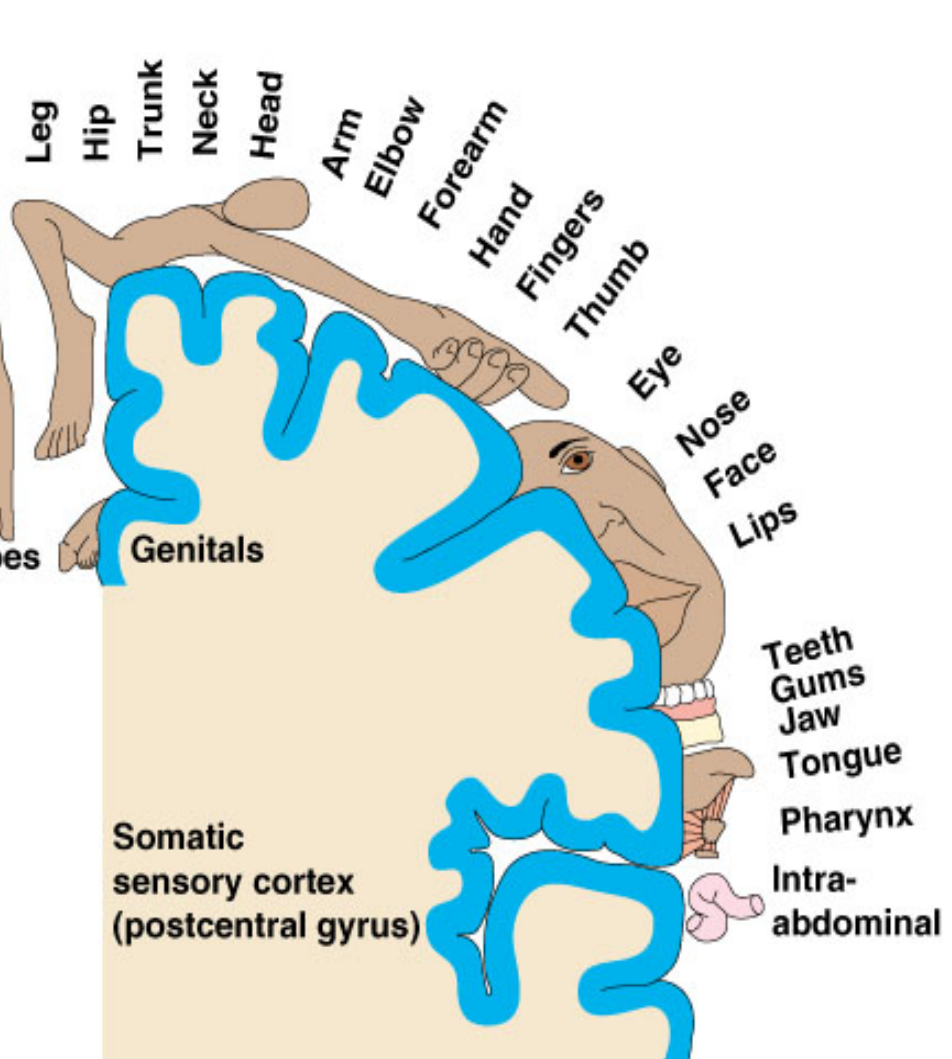
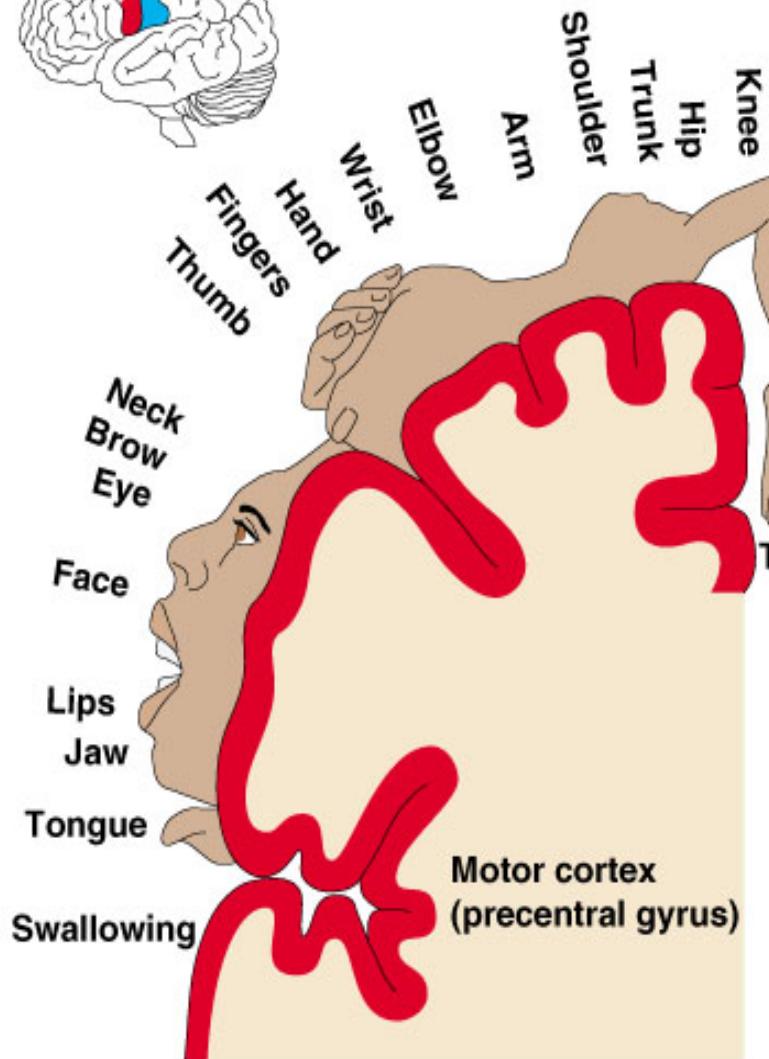
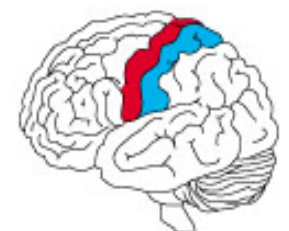Parahippocampal gyrus: located in the inferomedial part of temporal lobe. Deep to this gyrus lies the **hippocampus** and the **amygdala**, which are parts of limbic system





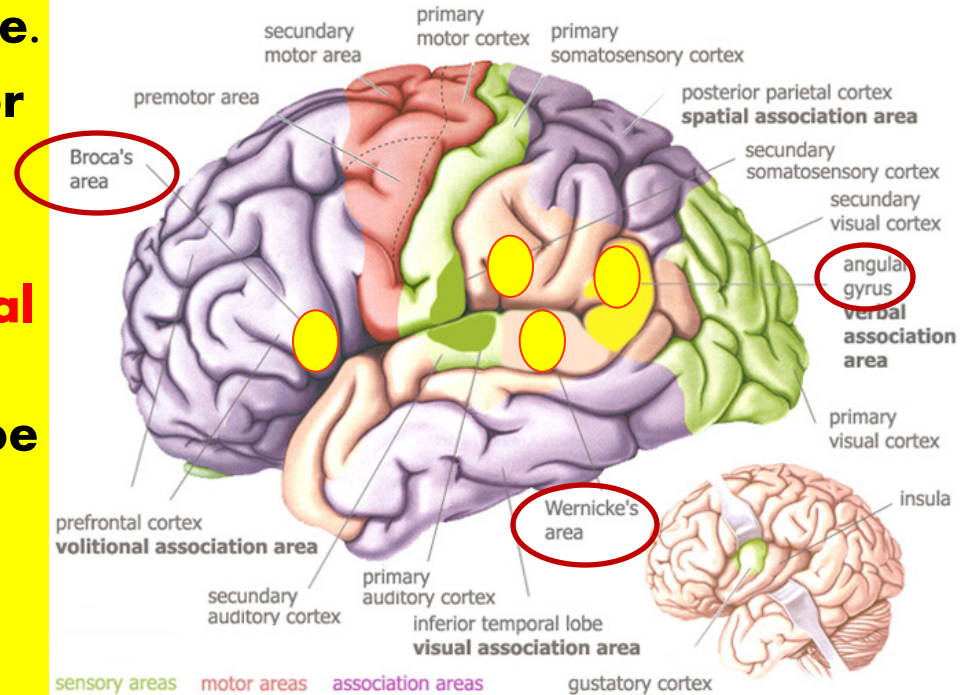
Primary motor area sequence

Primary sensory area sequence



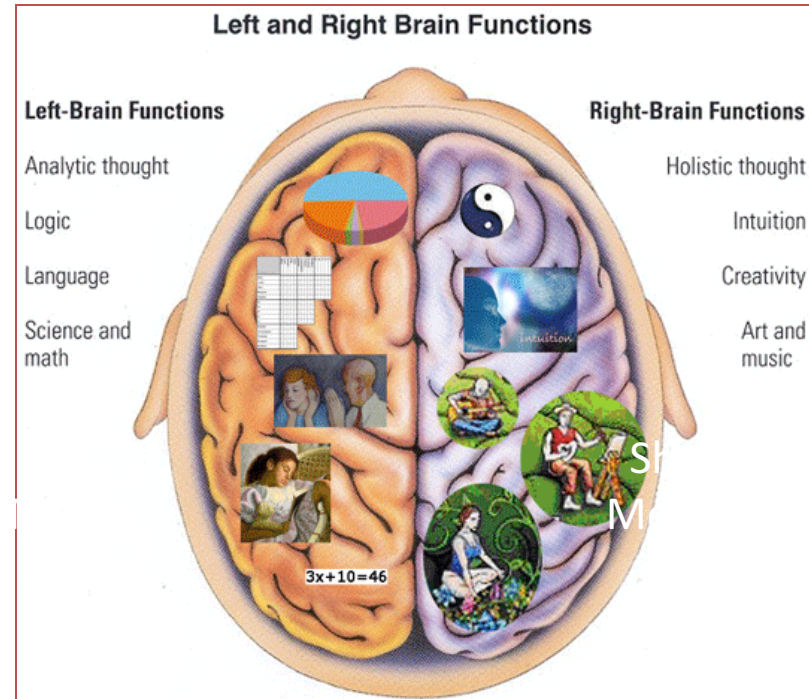
Language Areas

- Organized around the lateral Sulcus.
- **Broca's area:** concerned with expressive aspects of language.
- **Wernick's area:** responsible for comprehension of the spoken words.
- **Angular gyrus & Supramarginal gyrus:** nearby regions of temporal lobe and parietal lobe (of the inferior parietal lobule) are important in naming, reading, writing, and calculation.



Hemispheric Dominance

- The localization of **Speech centers & Mathematical ability** is the criterion for defining the dominant cerebral hemisphere.
- In **96% of normal right-handed individuals and 70% of normal left-handed individuals**, the **Left hemisphere contains the language centers**. These are **Left Hemisphere Dominant**.
- Cerebral dominance becomes established during the first few years after birth.



Hemispheres communicate
via the corpus callosum

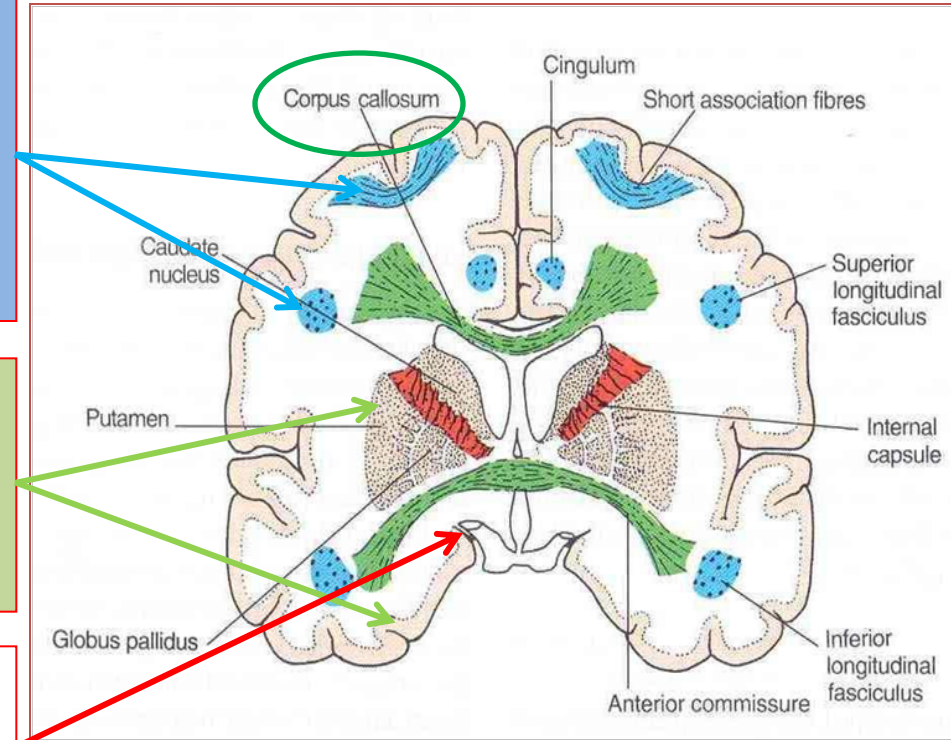
White Matter

- Underlies the cortex, contains nerve fibers, neuroglia cells and blood vessels.
- The nerve fibers originate, terminate or sometimes both, within the cortex.
- Depending on their origin & termination, these nerve fibers are classified into three types: **Association, Projection & Commissural**

Association fibers: Unite different parts of the same hemisphere, are of two types: long & short

Commissural fibers: Connect the corresponding regions of the two hemispheres

Projection fibers: Consist of afferent and efferent fibers of the cerebral cortex



Thank U & Good Luck