

ANATOMY OF SPINAL CORD

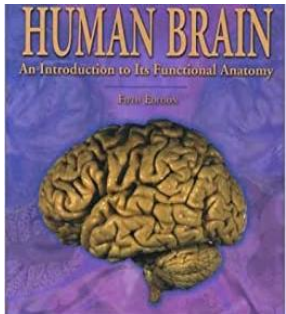
By Khaleel Alyahya, PhD, MEd

[@khaleelya](#)

Department of Anatomy
College of Medicine
King Saud University




RESOURCES




Human Brain

By John Nolte



Essential of Human Anatomy & Physiology

By Elaine Marieb and Suzanne Keller



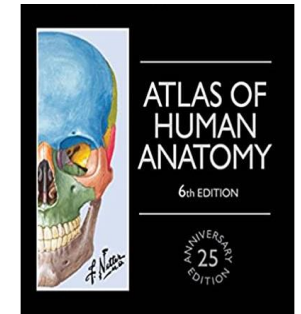
Gray's Anatomy

By Richard Drake, Wayne Vogl & Adam Mitchell



KENHUB

www.kenhub.com



Atlas of Human Anatomy

By Frank Netter

Objectives

- Describe the external anatomy of the spinal cord.
- Describe the internal anatomy of the spinal cord.
- Describe the spinal nerves: formation, branches and distribution via plexuses.
- Define Dermatome and describe its significance.
- Describe the meninges of the spinal cord.
- Define a reflex and reflex arc and describe the components of the reflex arc.



Review

REVIEW

Functions

❑ COLLECTION OF SENSORY INPUT

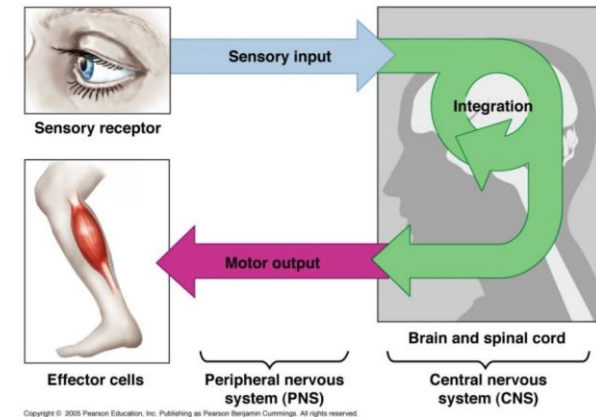
- Identifies changes occurring inside and outside the body by using sensory receptors.
- These changes are called stimuli.

❑ INTEGRATION

- Processes, analyses & interprets these changes and makes decisions.

❑ MOTOR OUTPUT

- It then effects a response by activating muscles or glands (effectors) via motor output.



Organization

Structural

❑ Central Nervous System (CNS)

- Brain & Spinal Cord

❑ Peripheral Nervous System (PNS)

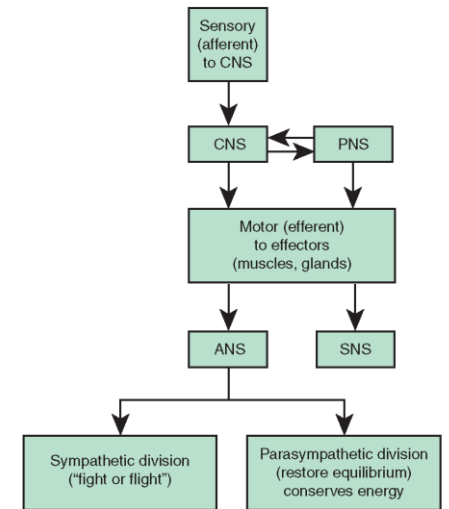
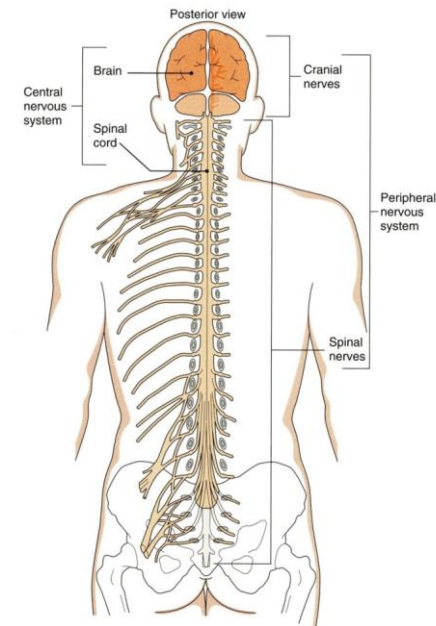
- Nerves & Ganglia
 - Cranial nerves
 - Spinal nerves

Functional

❑ Sensory Division (Afferent)

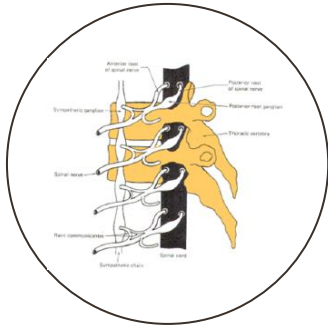
❑ Motor Division (Efferent)

- Autonomic
- Somatic

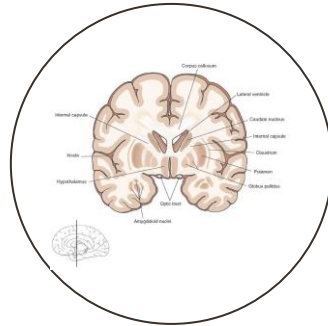


CNS = Central nervous system
PNS = Peripheral nervous system
ANS = Autonomic nervous system
SNS = Somatic nervous system

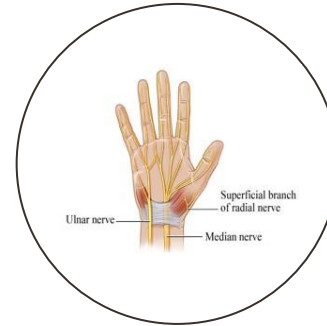
Terms



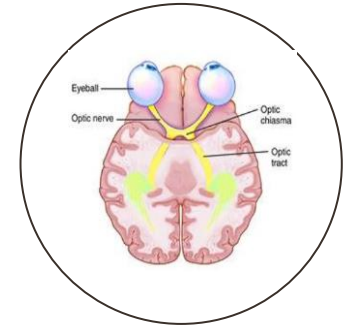
GANGLION
A GROUP OF NEURONS
OUTSIDE THE CNS



NUCLEUS
A GROUP OF NEURONS
WITHIN THE CNS

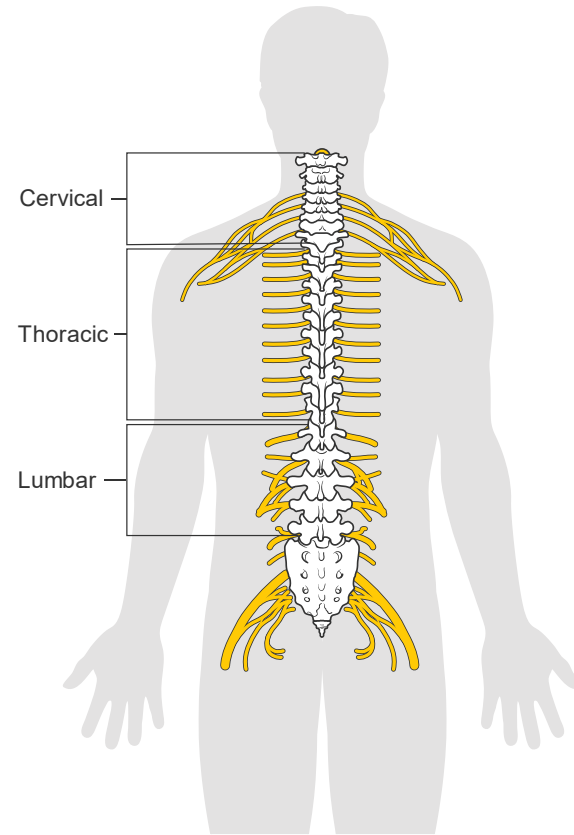


NERVE
A GROUP OF NERVE FIBERS
(AXONS) OUTSIDE THE CNS



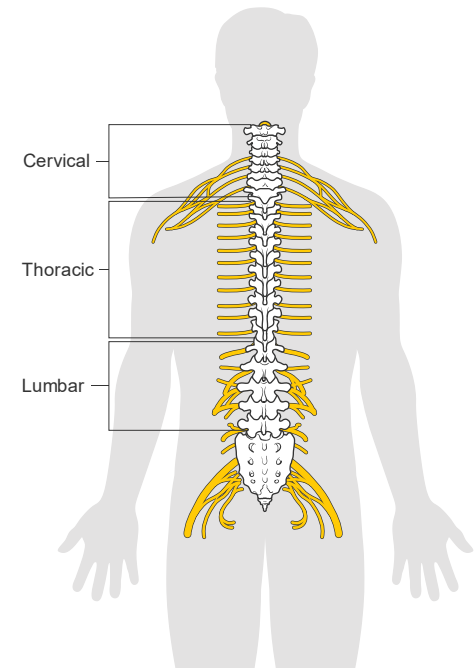
TRACT
A GROUP OF NERVE FIBERS
(AXONS) WITHIN THE CNS

Spinal Cord



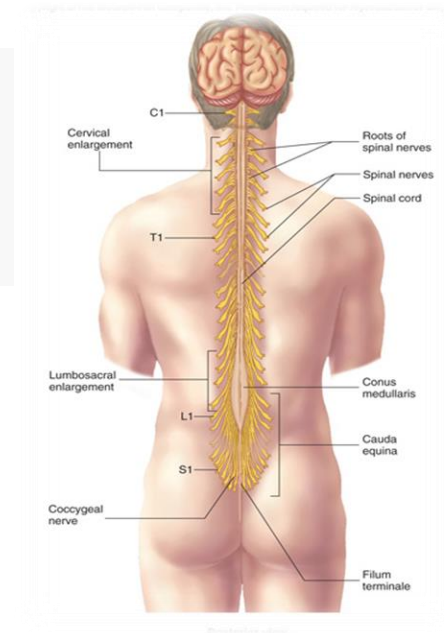
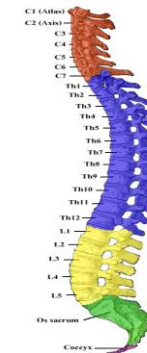
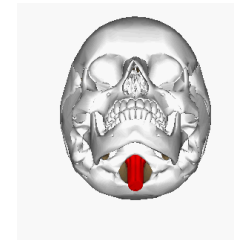
Introduction

- The main pathway for information connecting the brain and peripheral nervous system.
- It is elongated, cylindrical, suspended in the vertebral canal and protected by vertebrae
- Surrounded by the meninges and cerebrospinal fluid (CSF).
- The primary function of spinal cord is a transmission of neural signals between the brain and the rest of the body.
 - Sensory
 - Motor
 - Local reflexes



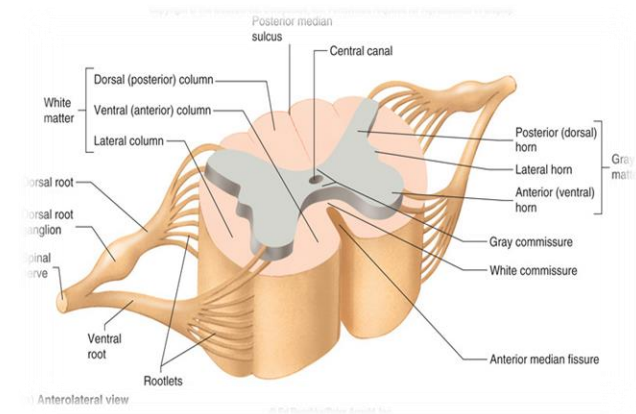
Structures

- Extends from **foramen magnum** to **2nd** lumbar vertebra.
- Continuous above with the **medulla oblongata**.
- The tapered inferior end forms **conus medullaris**.
- It is connected to the coccyx by a non-neuronal cord called **Filum Terminale**.
- Gives rise to **31** pairs of spinal nerves
- The bundle of spinal nerves extending inferiorly from lumbosacral enlargement and conus medullaris surround the filum terminale and form **cauda equina**
- Segmented
 - 8 Cervical
 - 12 Thoracic
 - 5 Lumbar
 - 5 Sacral
 - 1 Coccygeal
- Two enlargements:
 - **Cervical Enlargement:** supplies upper limbs.
 - **Lumbosacral Enlargement:** supplies lower limbs.



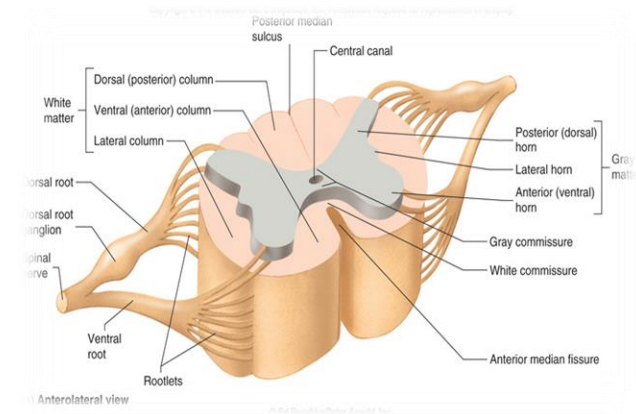
Cross Section

- The spinal cord is incompletely divided into two equal parts, anteriorly by a short, shallow **median fissure** and posteriorly by a deep narrow septum, the **posterior median sulcus**.
- Composed of **grey matter** in the center surrounded by **white matter** supported by neuroglia.
- **Commissures:** connections between left and right halves
 - Gray with central canal in the center
 - White
- **Roots:** spinal nerves arise as rootlets then combine to form roots
 - Dorsal (posterior) root has a ganglion
 - Ventral (anterior)
 - Two roots merge latera



Grey Matter

- The arrangement of grey matter in the spinal cord resembles the shape of the letter H.
- Having:
 - two posterior horns
 - two anterior horns
 - two lateral horns/columns.
- Consists of:
 - nerve cell bodies and their processes
 - neuroglia
 - blood vessels



Grey Matter

- The nerve cells are multipolar, and are of THREE main categories:

Sensory neurons (Tract cells)

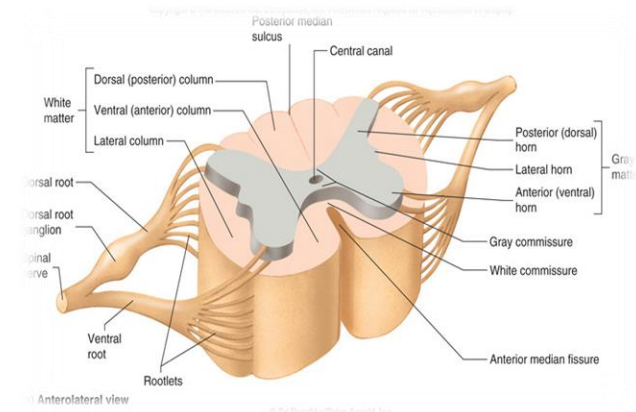
- receive impulses from the periphery of the body and whose axons constitute the ascending fasciculi of the white matter.
- located in the dorsal horns.

Lower motor neurons

- transmit impulses to the skeletal muscles.
- located in the ventral horns
 - similar neurons in the lateral horn are the preganglionic neurons of the autonomic system.

Interneurons (connector neurons)

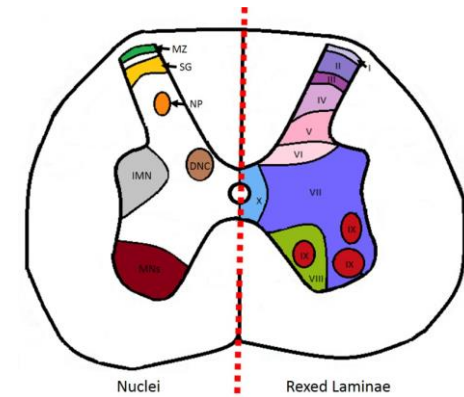
- linking sensory and motor neurons, at the same or different levels, which form spinal reflex arcs.



Spinal Cord Nuclei

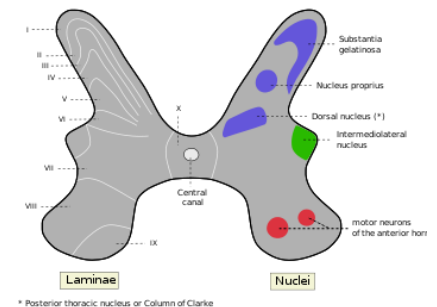
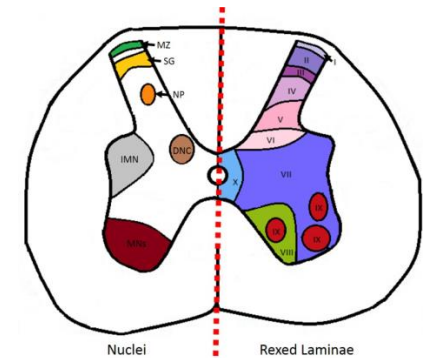
The prominent **nuclei** (groups of neuron cell bodies) in the spinal cord are:

- **Marginal zone:** located at the tip of the dorsal horn and is important for relaying pain and temperature sensation to the brain. (Laminae I)
- **Substantia gelatinosa:** located at the top of the dorsal horn, it is important for relaying pain, temperature and light touch sensation to the brain. It is composed of large neurons and found throughout the length of spinal cord. (Laminae II)
- **Nucleus proprius:** located in the neck of the dorsal horn anterior to substantia gelatinosa, and it is concerned with senses of position & movement. Also composed of large neurons and found throughout the length of spinal cord. (Laminae IV)
- **Dorsal nucleus of Clarke:** the most dorso-medial nuclei, and it relays unconscious proprioceptive information to the brain. Only found in spinal segments C8 to L3. (Laminae VII)
- **Intermediolateral nucleus:** located in the intermediate column and lateral horn, and it relays sensory information from viscera to the brain, and autonomic signals from the brain to the visceral organs. (Laminae VII)
- **Lateral motor neurons and medial motor neurons:** located in the ventral horn. Composed of motor neurons that innervate visceral and skeletal muscles. (Laminae VIII & IX)



Rexed Laminae

- It is an alternative to spinal cord **nuclei** where cells were grouped according to their structure and function, rather than solely on location.
- Identified in the early **1950s** by Swedish neuroscientist.
- Cells of the same type are clustered into groups, which occur in **long columns**
- In transverse section, these columns appear as layers, especially within the dorsal horn
- These layers are called the **laminae of Rexed** that are numbered by Roman numerals, starting from the tip of the dorsal horn and moving ventrally into the ventral horn.



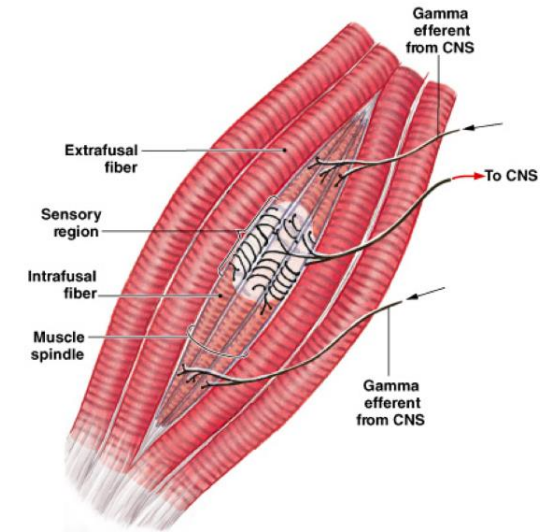
Motor Neurons in Ventral Horn

Large multipolar cells

- whose axons pass out in the ventral roots of spinal nerves as alpha efferent which innervate **extrafusal muscle** fibers of skeletal muscles.

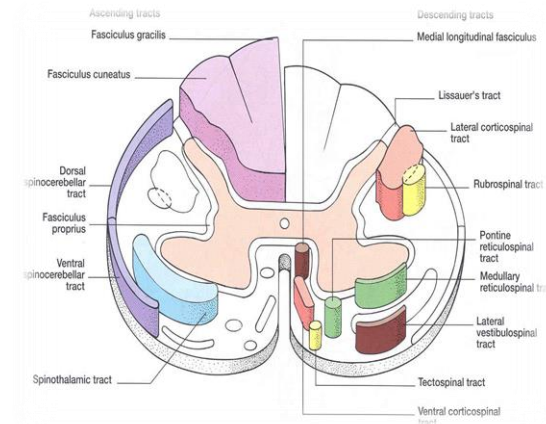
Small multipolar cells

- whose axons pass out in the ventral roots of spinal nerves as gamma efferent which innervate **intrafusal muscle** fibers of neuromuscular spindles

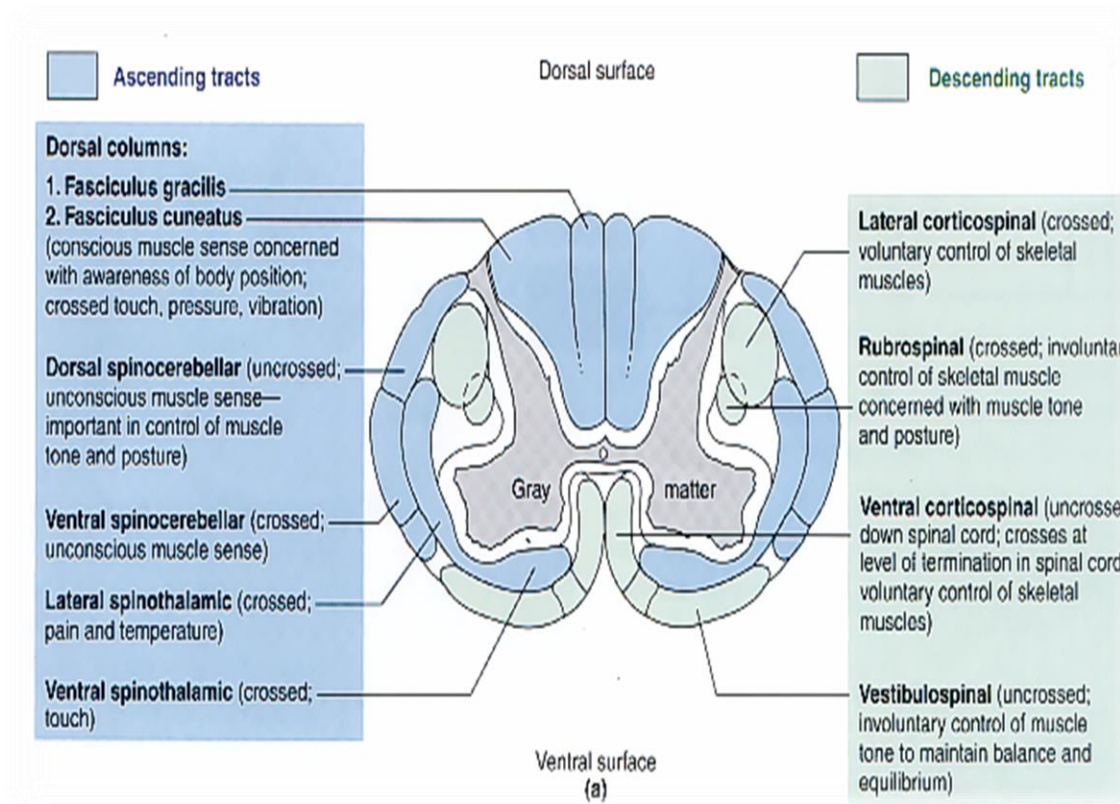


White Matter

- Consists of mixture of **nerve fibers**, **neuroglia** and **blood vessels**.
- White color is due to high proportion of **myelinated** nerve fibers
- The white matter of the spinal cord is arranged in **columns/funiculi**; anterior, posterior and lateral.
- The nerve fibers are arranged as **bundles**, running vertically through the cord.
- A group of nerve fibers (**axons**) that share a common origin, termination and function form a tract or fasciculus
- These **tracts** are formed by sensory nerve fibers ascending to the brain, motor nerve fibers descending from the brain and fibers of connector neurons.
- Tracts are often named according to their points of origin and destination, e.g. **spinothalamic**, **corticospinal**.



White Matter



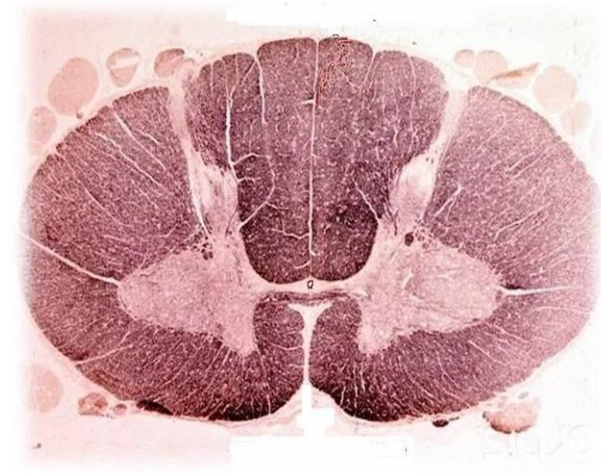Commissures

Grey Commissure

- Transverse bridge of grey matter connecting the anterior and posterior gray horns on each side
- It is pierced by the central canal that divides it into anterior and posterior parts

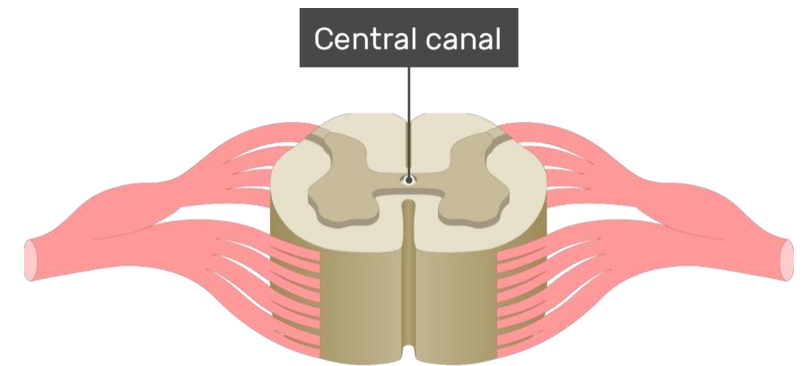
White Commissure

- Lies ventral to the gray commissure
- Mainly contains decussating nerve fibers



Central Canal

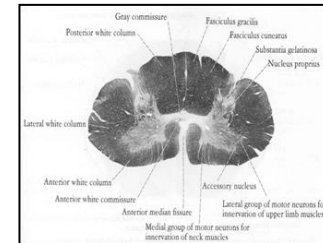
- The **cerebrospinal-filled** space that runs longitudinally through the entire length of the spinal cord.
- Lined by **ependyma** (ciliated columnar epithelium)
- Continuous with the ventricular system of the brain
- Superiorly opens into the **4th** ventricle
- Inferiorly in the **conus medullaris**, it expands into the fusiform terminal ventricle and terminates below at the root of **filum terminale**



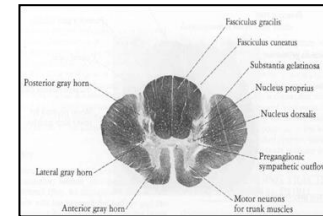
Regional Differences

- Although the general pattern of gray matter is the same throughout spinal cord, regional differences are apparent in transverse sections
- The amount of **white matter increases** in a **caudal-to-cranial** direction because fibers are added to ascending tracts and fibers leave descending tracts
- The **gray matter** is in **increased** volume in **cervical & lumbosacral** enlargements for innervation of upper & lower limbs
- The lateral horn is characteristic of thoracic and upper lumbar segments

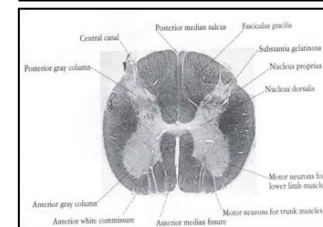
Cervical



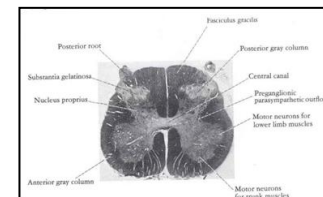
Thoracic



Lumbar

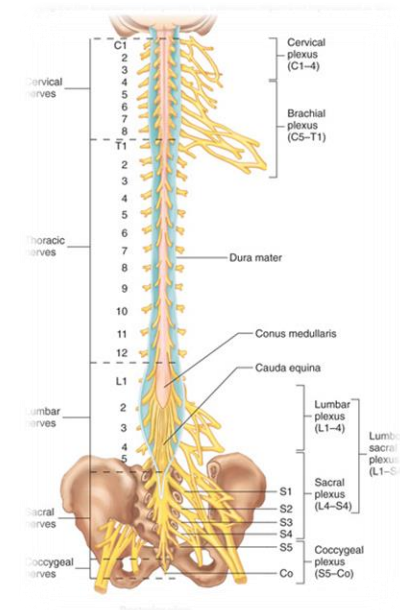


Sacral



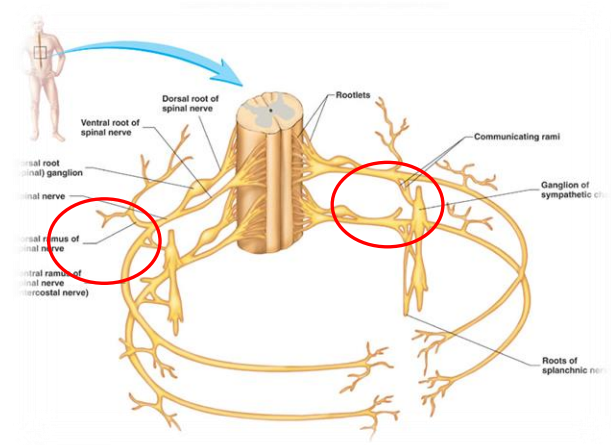
Spinal Nerves

- **Thirty-one** pairs of spinal nerves
- **First pair** exit vertebral column between skull and atlas, last four pairs exit via the sacral foramina and others exit through intervertebral foramina
- **Eight** pair cervical, **twelve** pair thoracic, **five** pair lumbar, **five** pair sacral, **one** pair coccygeal
- Each spinal nerve arises as rootlets which then combine to form **dorsal** (posterior) & **ventral** (anterior) roots.
- Two roots merge laterally and form the spinal nerve.
- Dorsal (posterior) root has a ganglion (dorsal root/sensory ganglion) that contains the cell bodies of the sensory neurons
- Each spinal nerve then divides into a smaller dorsal and a larger ventral ramus



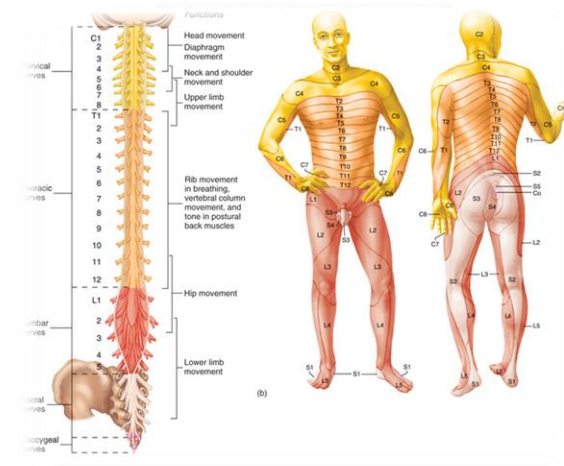
Branches of Spinal Nerves

- **Dorsal Ramus:** innervate deep muscles of the trunk responsible for movements of the vertebral column and skin near the midline of the back.
- **Ventral Ramus:** what they innervate depends upon which part of the spinal cord is considered.
 - Thoracic region: form intercostal nerves that innervate the intercostal muscles and the skin over the thorax
 - Remaining spinal nerve ventral rami (roots of the plexus): form five plexuses (intermingling of nerves).
 - Ventral rami of **C1-C4** = **cervical plexus**
 - Ventral rami of **C5-T1** = **brachial plexus**
 - Ventral rami of **L1-L5** = **lumbar plexus**
 - Ventral rami of **L4-S4** = **sacral plexus**
 - Ventral rami of **S4 & S5** = **coccygeal plexus**
- **Communicating Rami:** communicate with sympathetic chain of ganglia.



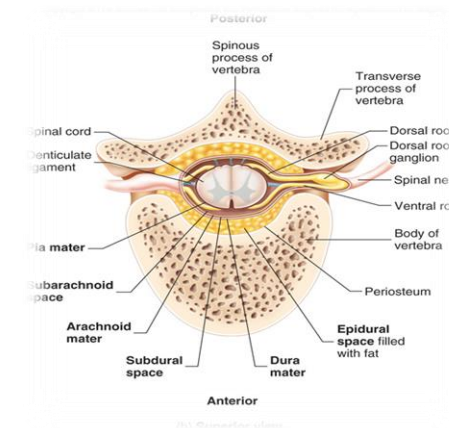
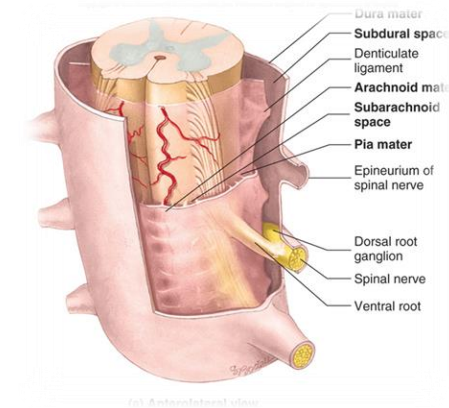
Dermatomes

- Dermatome is a segment of skin supplied by one spinal nerve.
- Each of these spinal nerves relay sensation from a particular region of skin to the brain.
- The nerves from the upper cervical spine supply the skin of the neck.
- **C5 to T1** nerves supply the arms.
- **T2 to L2** nerves supply the chest and abdomen.
- **L3 to S1** nerves supply the skin of the legs.
- **S1-C1** nerves go to the groin.
- Testing of dermatomes is part of the neurological examination looking for sensation changes within a specific dermatome that may help in determining the pathological disc level.



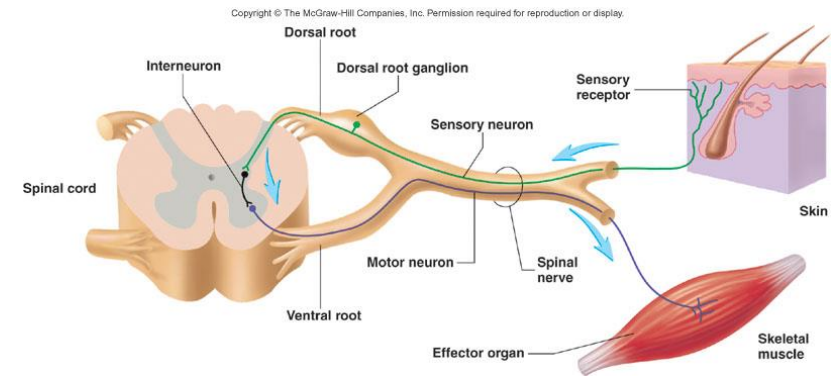
Spinal Meninges

- **Connective tissue membranes surrounding spinal cord and brain**
 - **Dura mater:** continuous with epineurium of the spinal nerves
 - **Arachnoid mater:** thin and wispy
 - **Pia mater:** bound tightly to surface of brain and spinal cord.
 - Forms the filum terminale, which anchors spinal cord to coccyx and the denticulate ligaments that attach the spinal cord to the dura mater
- **Spaces**
 - **Epidural:** Contains blood vessels, connective tissue and fat.
 - **Subdural:** Contains serous fluid
 - **Subarachnoid:** Contains CSF and blood vessels within web-like strands of arachnoid tissue



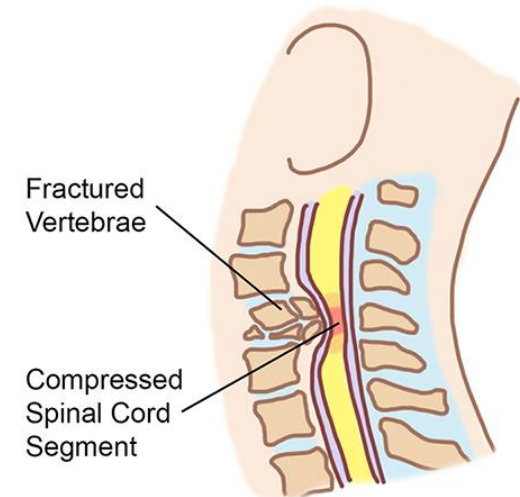
Reflex & Reflex Arc

- A reflex is a rapid, involuntary, stereotyped pattern of response brought by a **sensory stimulus**.
- A neural pathway mediating the reflex actions is called **reflex arc**.



Spinal Nerve Injury

- The spinal cord injury is the damage to the spinal cord that causes temporary or permanent changes in the functions.
- **Symptoms** may include loss of muscle function, sensation, or autonomic function.
- Injury can occur at any level of the spinal cord and can be complete injury with a total loss of sensation and muscle function, or it can be incomplete injury.
- Depending on the location and the severity of damage, the symptoms could include **numbness, paralysis or incontinence**.
- Long term outcomes ranges widely from full recovery to permanent quadriplegia or paraplegia.
- Complications can include **muscle atrophy, pressure sores, infections, and breathing problems**.





QUESTIONS?

alkhaleel@ksu.edu.sa