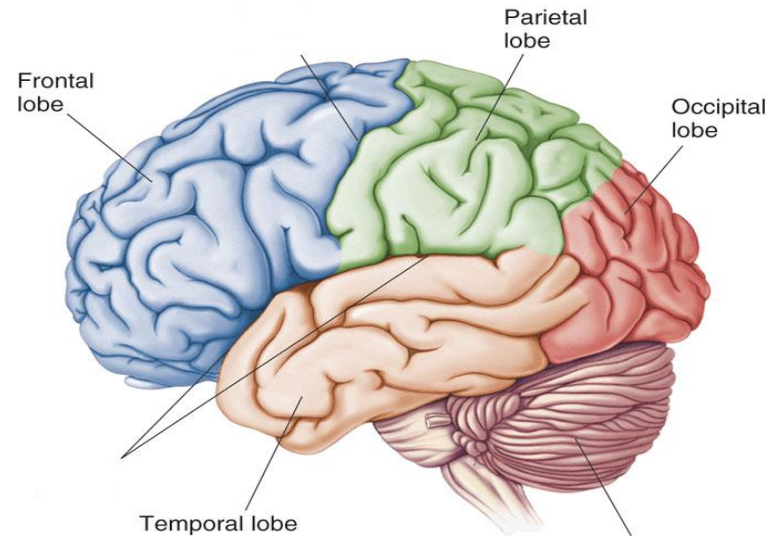


# **FUNCTIONS OF CEREBRAL HEMISPHERE**

*Dr. Salah Elmalik*



# Objectives

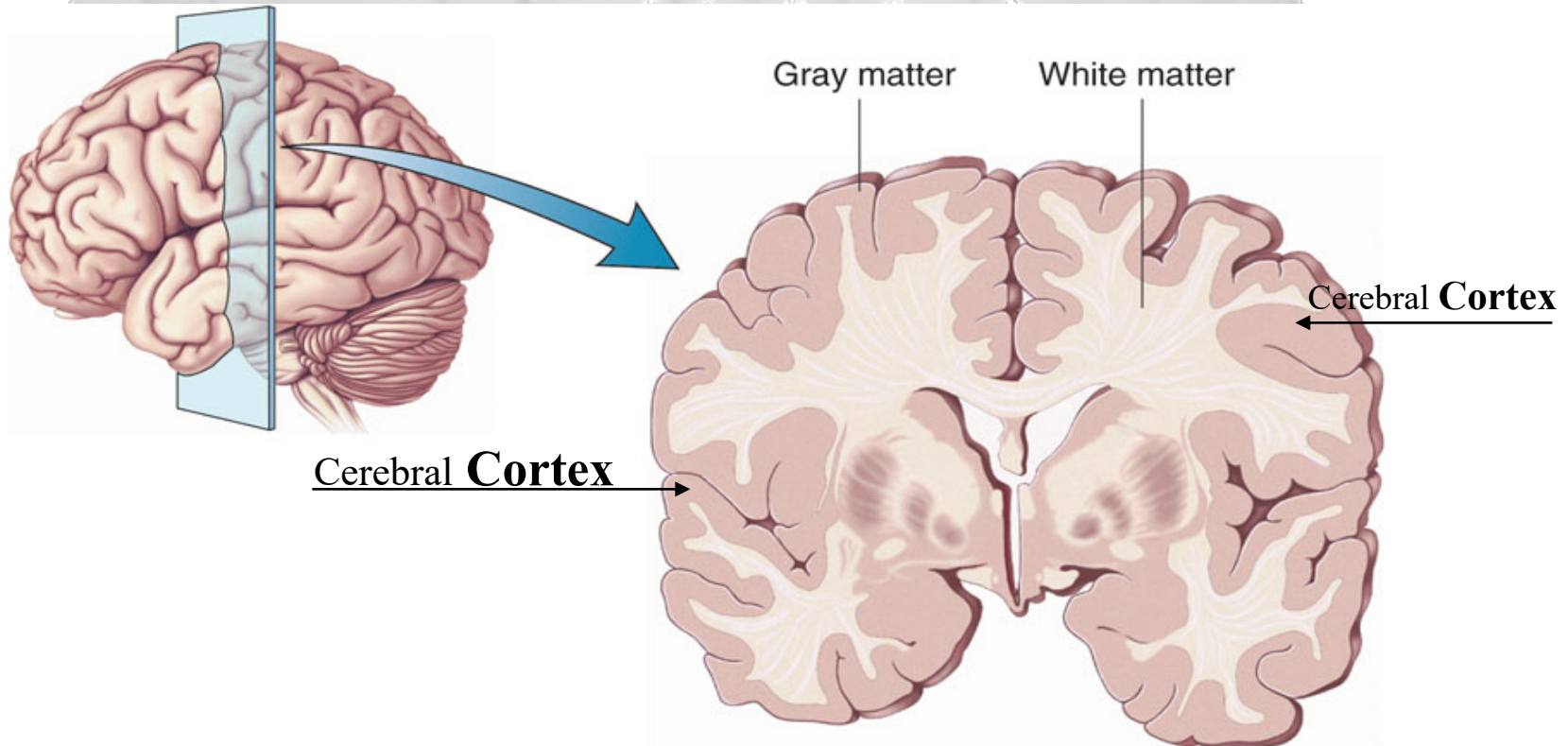
At the end of this lecture the student should be able to:

- List the cerebral cortex layers
- •Explain the three main types of functional areas in the cerebral cortex
- •Know the most important association areas of the brain and their functions
- •know the terms categorical hemisphere and representational hemisphere and summarize the difference between them.

# Introduction

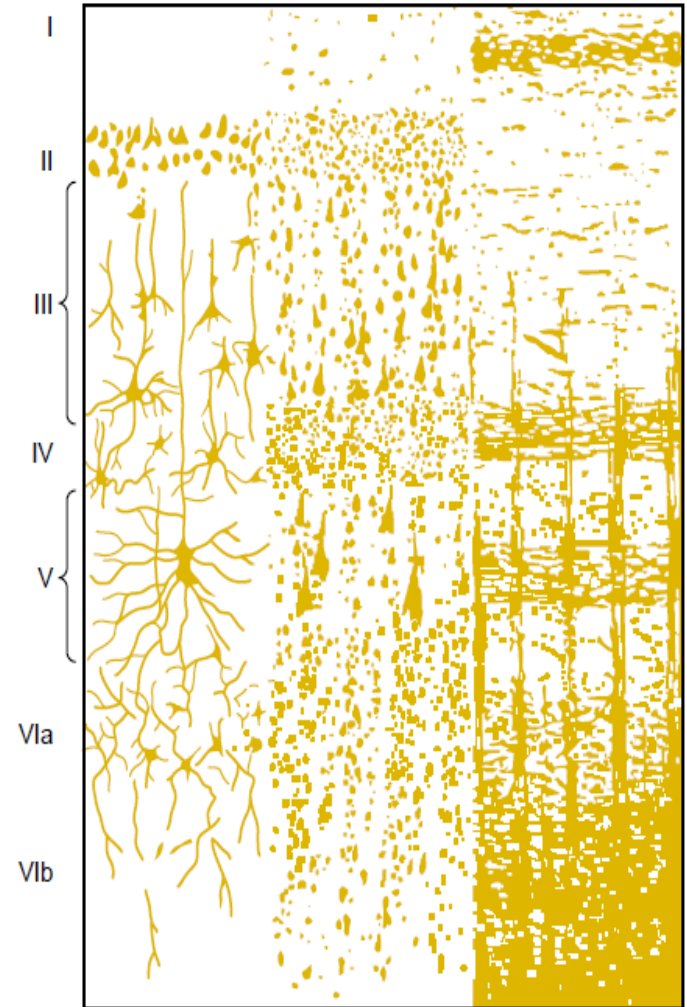
- ❑ The cerebrum is the largest part of the brain with two hemispheres, linked by commissural fibres of corpus callosum.
- ❑ Each cerebral hemisphere contains externally highly convoluted cortex of grey matter and internal mass of white matter or medulla.
- ❑ The cerebral hemispheres contain motor and sensory areas and the limbic system.

**Cerebral Cortex** - The outermost layer of gray matter making up the superficial aspect of the cerebrum.



# Cerebral Cortex

- Microscopically the cortex consists of six layers or laminae lying parallel to the surface
- From outside to inside the layers are:
  - I. Molecular layer
  - II. The external granular layer
  - III. Layer of pyramidal cell
  - IV. Internal granular layer
  - V. large pyramidal cell layer
  - VI. Layer of fusiform or polymorphic cells.



# Cerebral Cortex Layers

- The incoming sensory signal excites neuronal layer IV first; then the signal spreads toward the surface of the cortex and also toward deeper layers.
- 2. Layers I and II & III perform most of intracortical association function.
- 3. The neurons in layers II and III making short horizontal connections with adjacent cortical areas.
- 4. The neurons in layers V and VI send output signals to brain stem ,spinal cord (V) & thalamus (VI)

# There are three main types of functional areas in the cerebral cortex:

## □ Primary Areas:

- The primary motor areas have direct connections with specific muscles for causing discrete muscle movements.
- The primary sensory areas detect specific sensations—visual, auditory, or somatic—transmitted directly to the brain from peripheral sensory organs.

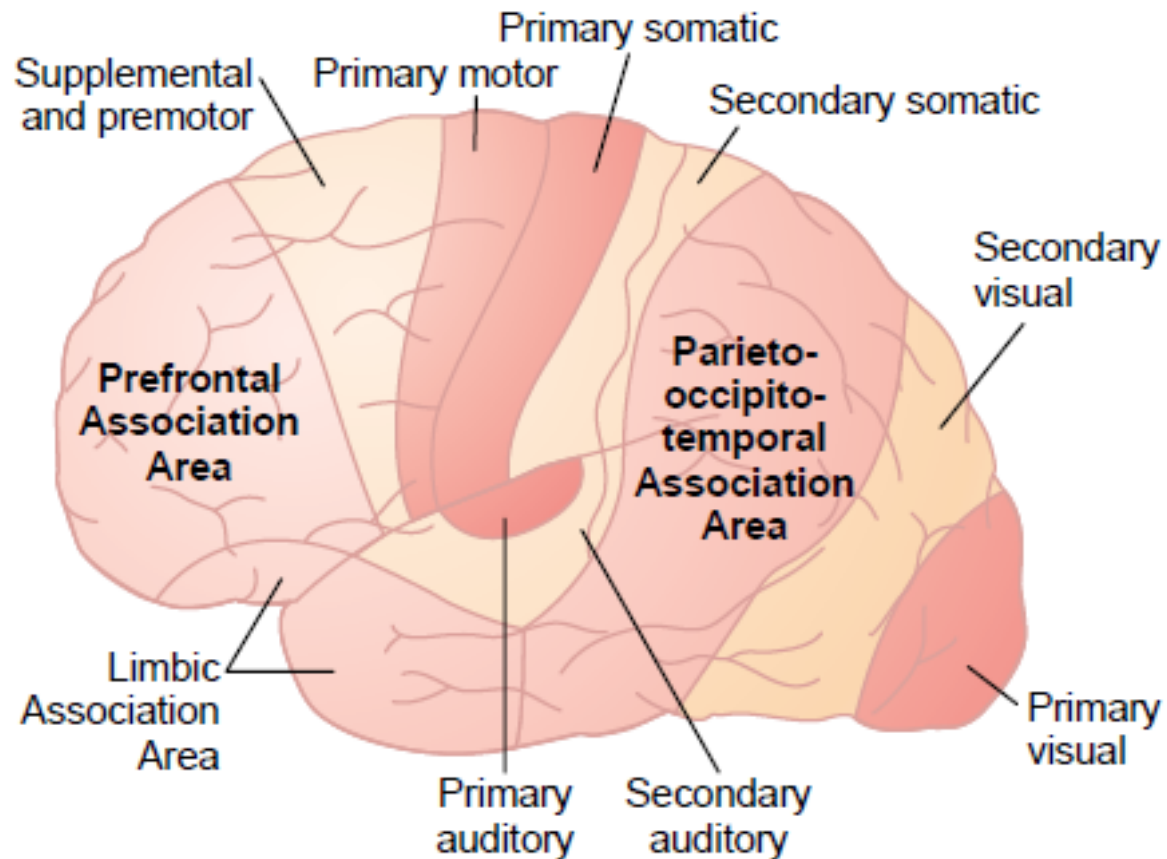
## □ The secondary areas:

make sense out of the signals in the primary areas.

## □ Association Areas

receive and analyze signals simultaneously from multiple regions of both the motor and sensory cortices as well as from subcortical structures.

# Association Areas





# Association Areas

- These areas receive and analyze signals simultaneously from multiple regions of both the motor and sensory cortices as well as from subcortical structures.

The most important association areas are

- (1) Parieto-occipitotemporal association area
- (2) prefrontal association area
- (3) limbic association area.

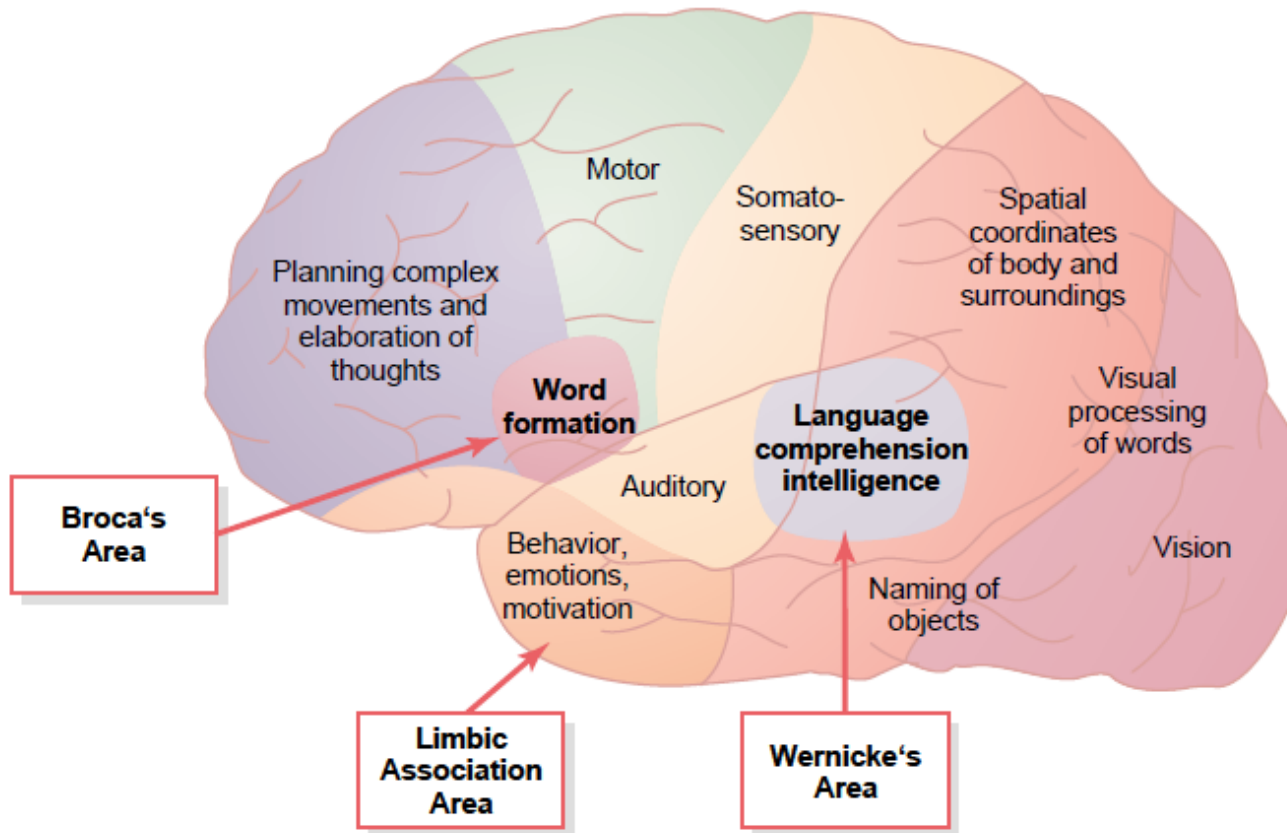
# **Parieto- Occipitotemporal Association Areas**

- 1. Analysis of the Spatial Coordinates of the Body.
- 2. Language Comprehension.
- 3. Initial Processing of Visual Language (Reading).
- 4. Area for Naming Objects.

# PARIETO-OCCIPITOTEMPORAL ASSOCIATION AREAS

AREA	SITE	FUNCTION
Analysis of the Spatial Coordinates of the Body.	beginning in the posterior parietal cortex and extending into the superior occipital cortex	computes the coordinates of the visual , auditory, and body surroundings.
Area for Language Comprehension	Wernicke's area, lies behind the primary auditory cortex in the posterior part of the superior gyrus of the temporal lobe	higher intellectual function
Area for Initial Processing of Visual Language (Reading).	angular gyrus area	make meaning out of the visually perceived words (lesion causes Dyslexia or Word Blindness)
Area for Naming Objects.	Lateral portion of anterior occipital lobe & posterior temporal	naming objects.

s in  
pe-  
ca's  
ion  
195  
ted



# Prefrontal Association Area

- Is the anterior pole of frontal lobe.
- It contributes in the following functions:
  1. Planning of complex pattern of movements.
  2. Personality characteristics and social relationship
  3. Production of deep, more abstract and logically sequenced thoughts which enable attainment of goals
  4. Working memory (ability to tie thoughts together in a logical sequence by comparing many bits of information with appropriate stored knowledge and be able to instantly recall this information for future planning)

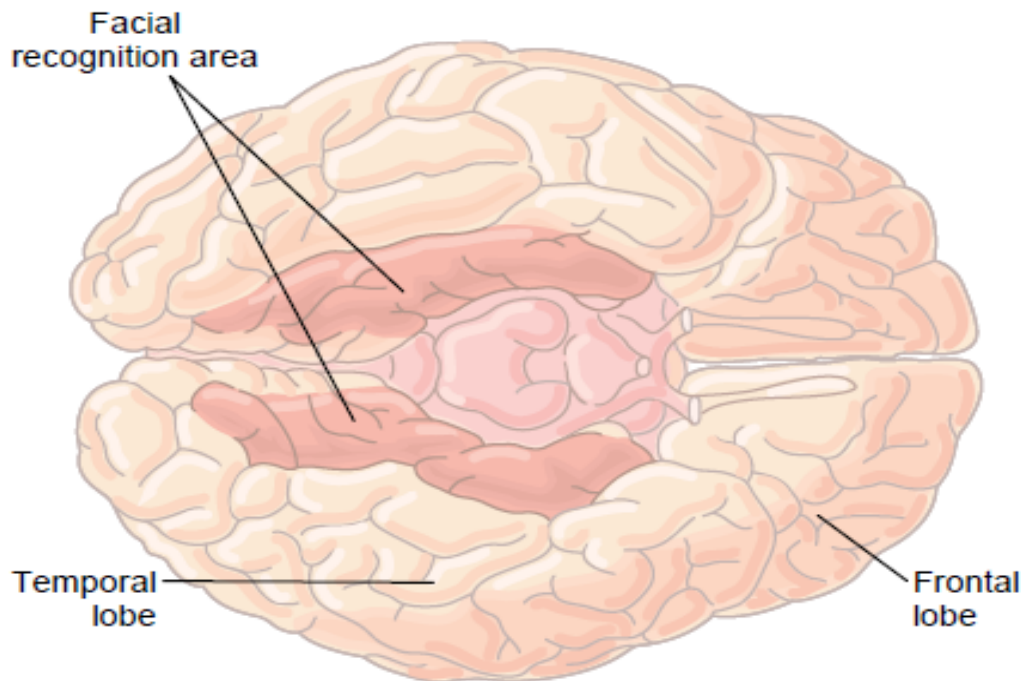
*Lesions in this area lead to change in personality and behavior*

# Limbic Association Area

- Consists of anterior and inner portion of temporal lobe , ventral portion of the frontal lobe, and cingulate gyrus on mid surface of each cerebral hemisphere
- Is primarily concerned with emotion , behavior and motivational drive for different tasks most importantly learning.
- *Lesion of this area may lead to decreased aggression , lack of emotion , hyper sexuality & hyperphagia*

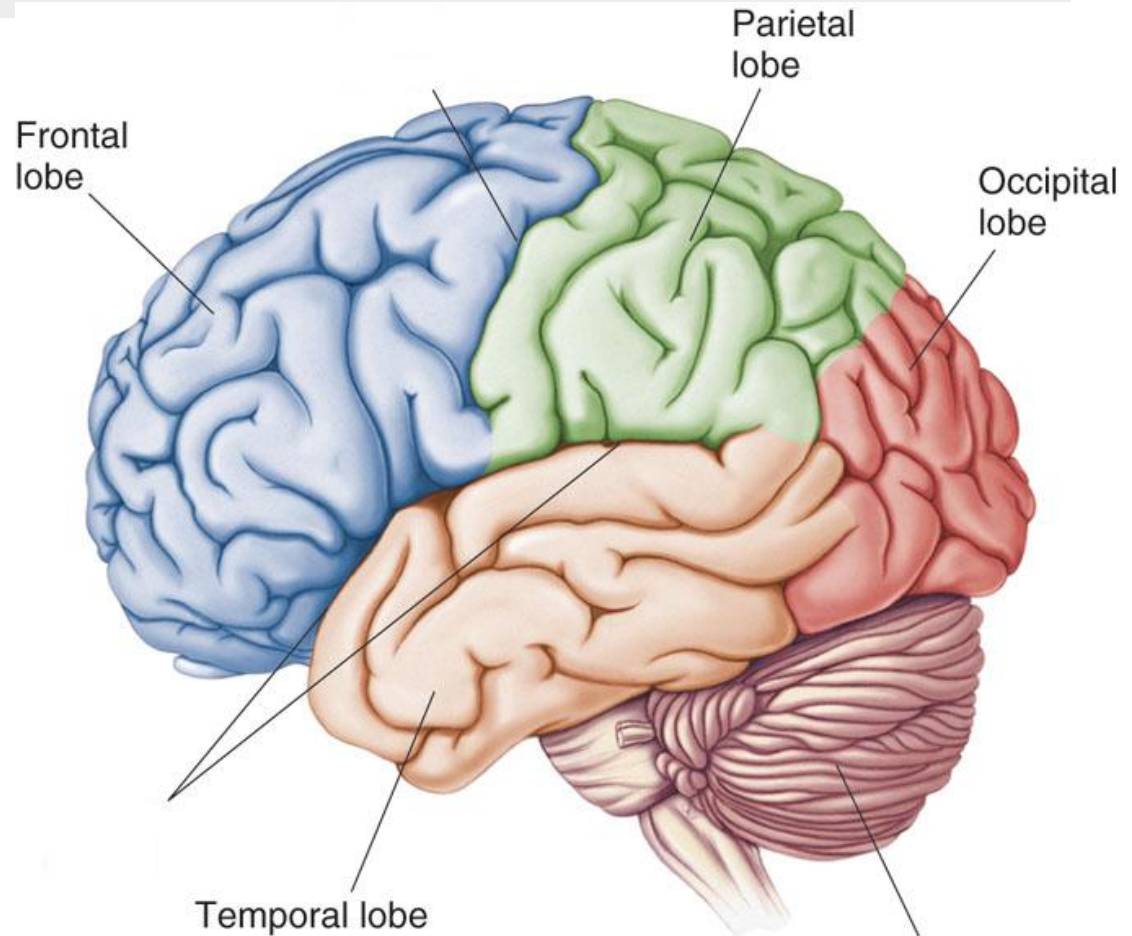
# Area of Recognition of Faces

- Located on the underside of the brain on the medial occipital and temporal lobes
- The occipital portion is contiguous with visual cortex , while the temporal one is closely associated with limbic system
- *Inability to recognize faces is called prosopagnosia*



# Lobes of the Brain

- Frontal
- Parietal
- Occipital
- Temporal

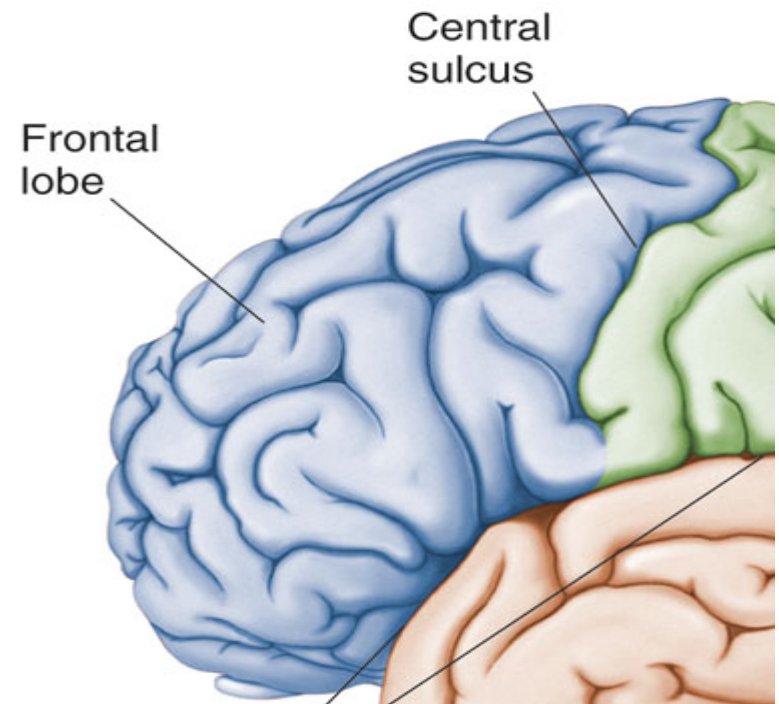




# Lobes of the Brain - Frontal

- The Frontal Lobe of the brain is located deep to the Frontal Bone of the skull
- It plays an integral role in the following functions:

- Memory Formation
- Emotions
- Decision Making
- Reasoning
- Personality



# Frontal Lobe - Cortical Regions

- **Primary Motor Cortex (Precentral Gyrus)** - Cortical site involved with controlling movements of the body.
- **Broca's Area** - plan of motor pattern for expressing of individual words. Located on Left Frontal Lobe.
  - **Broca's Aphasia** - Results in the ability to comprehend speech, but the decreased motor ability (or inability) to speak and form words.
- **Orbitofrontal Cortex** - Site of Frontal Lobotomies

<p>* <u>Desired Effects:</u></p>	<p>* <u>Possible Side Effects:</u></p>
<ul style="list-style-type: none"><li>- Diminished Rage</li><li>- Decreased Aggression</li><li>- Poor Emotional Responses</li></ul>	<ul style="list-style-type: none"><li>- Epilepsy</li><li>- Poor Emotional Responses</li><li>- Perseveration (Uncontrolled, repetitive actions, gestures, or words)</li></ul>





- **Olfactory Bulb** - Cranial Nerve I, Responsible for sensation of Smell

Central sulcus

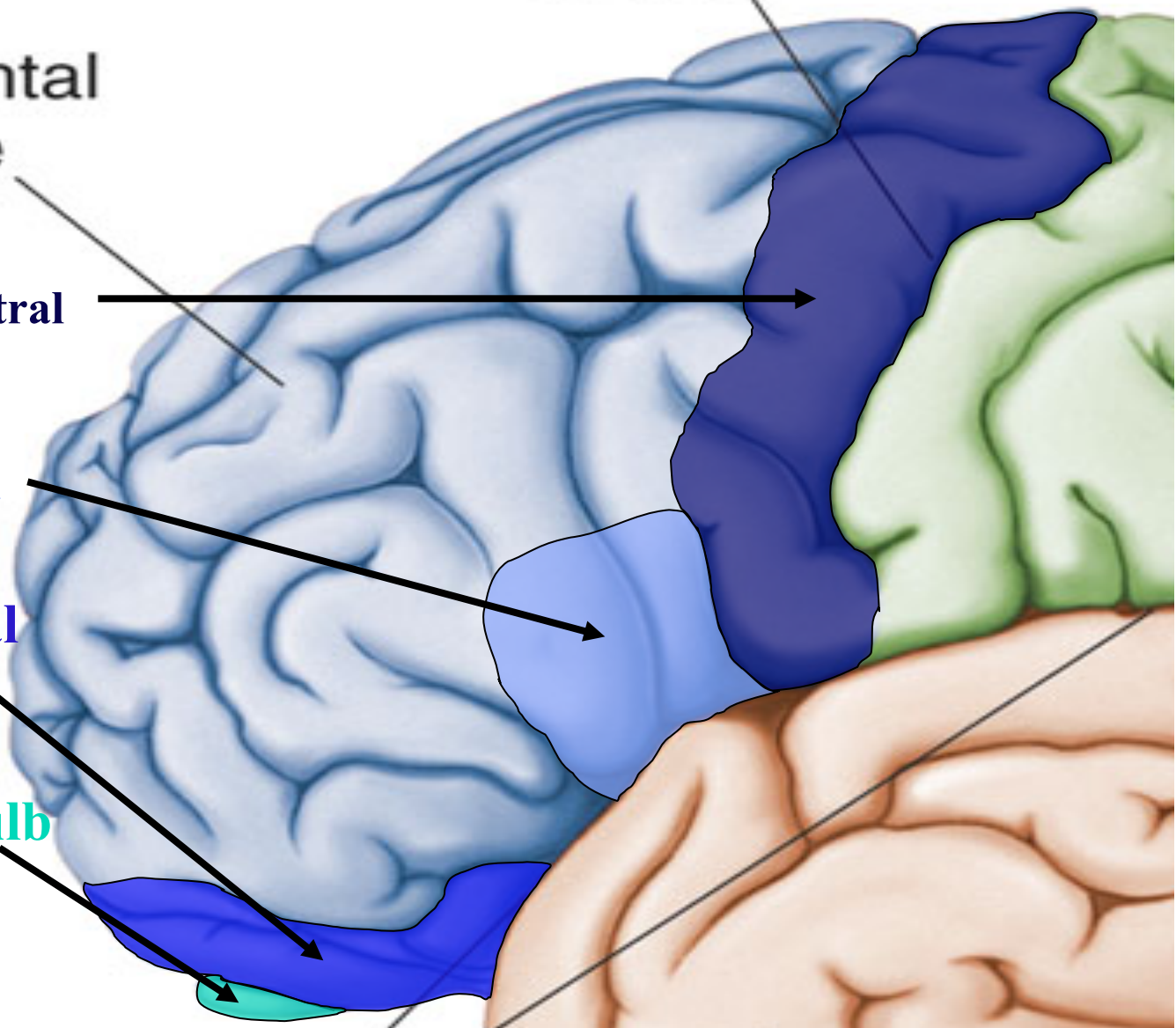
Frontal lobe

Primary Motor Cortex/ Precentral Gyrus

Broca's Area

Orbitofrontal Cortex

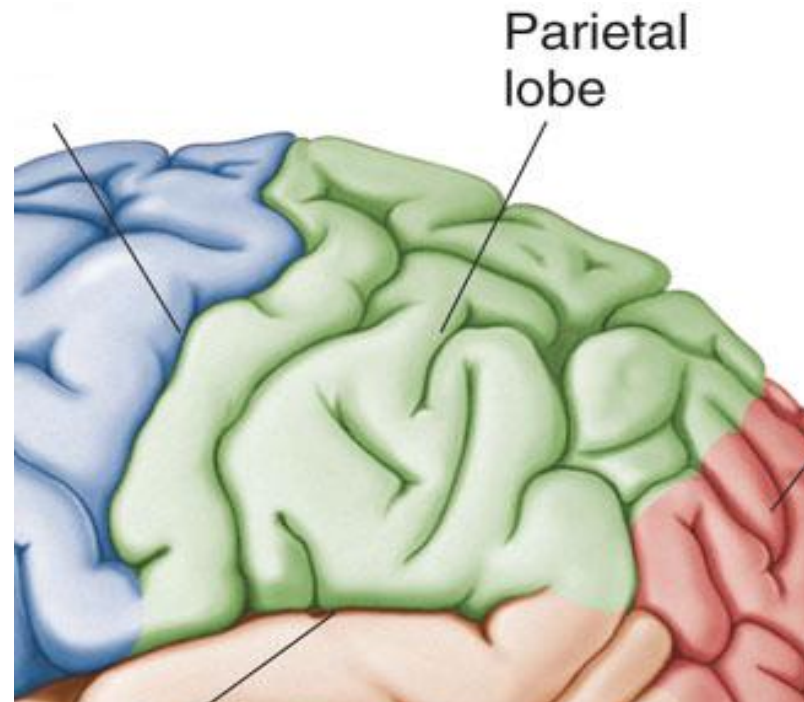
Olfactory Bulb



Regions

# Lobes of the Brain - Parietal Lobe

- The Parietal Lobe of the brain is located deep to the Parietal Bone of the skull.
- It plays a major role in the following functions/actions:
  - Senses and integrates sensation(s)
  - Spatial awareness and perception (Proprioception - Awareness of body/ body parts in space and in relation to each other)



# Parietal Lobe - Cortical Regions

- **Primary Somatosensory Cortex (Postcentral Gyrus)** - Site involved with processing of tactile and proprioceptive information.
- **Somatosensory Association Cortex** - Assists with the integration and interpretation of sensations relative to body position and orientation in space.
- **Primary Gustatory Cortex** -
  - Located in parietal operculum of Insula
  - Primary site involved with the interpretation of the sensation of Taste.

# Parietal Lobe

- ❑ Parietal lobe is essential for our feeling of touch, warmth/heat , cold, pain , body position and appreciation of shapes of palpated objects .
- ❑ *When damaged , the person loses the ability to recognize shapes of complex objects by palpation (palpation = examination of objects by touch )*
- ❑ *& also develops Sensory Inattention on opposite side*  
*(if both sides of the patient are tested simultaneously, e.g. for touch, then the stimulus is appreciated only on the side contralateral to a normal parietal hemisphere.)*



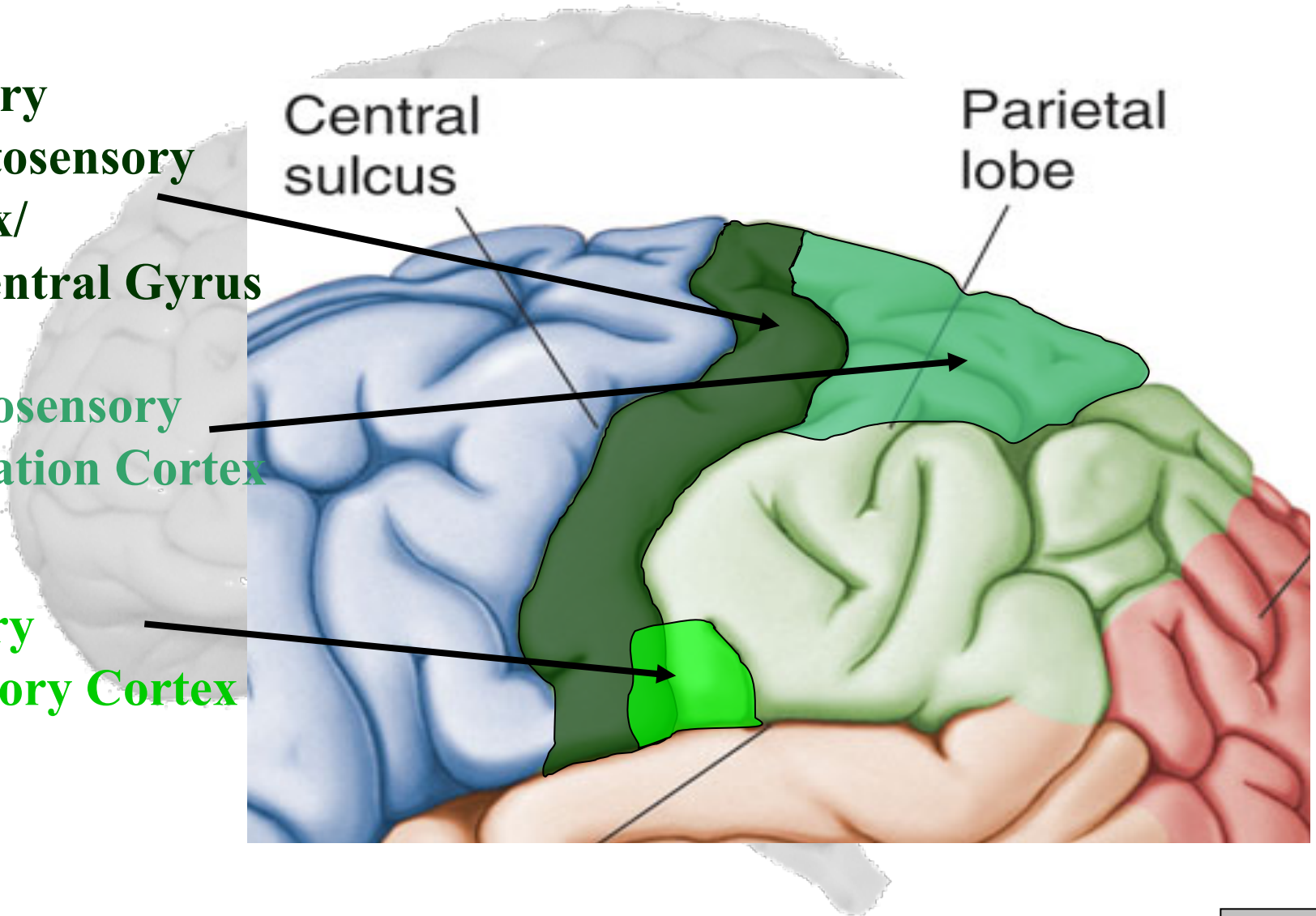
**Primary  
Somatosensory  
Cortex/  
Postcentral Gyrus**

**Somatosensory  
Association Cortex**

**Primary  
Gustatory Cortex**

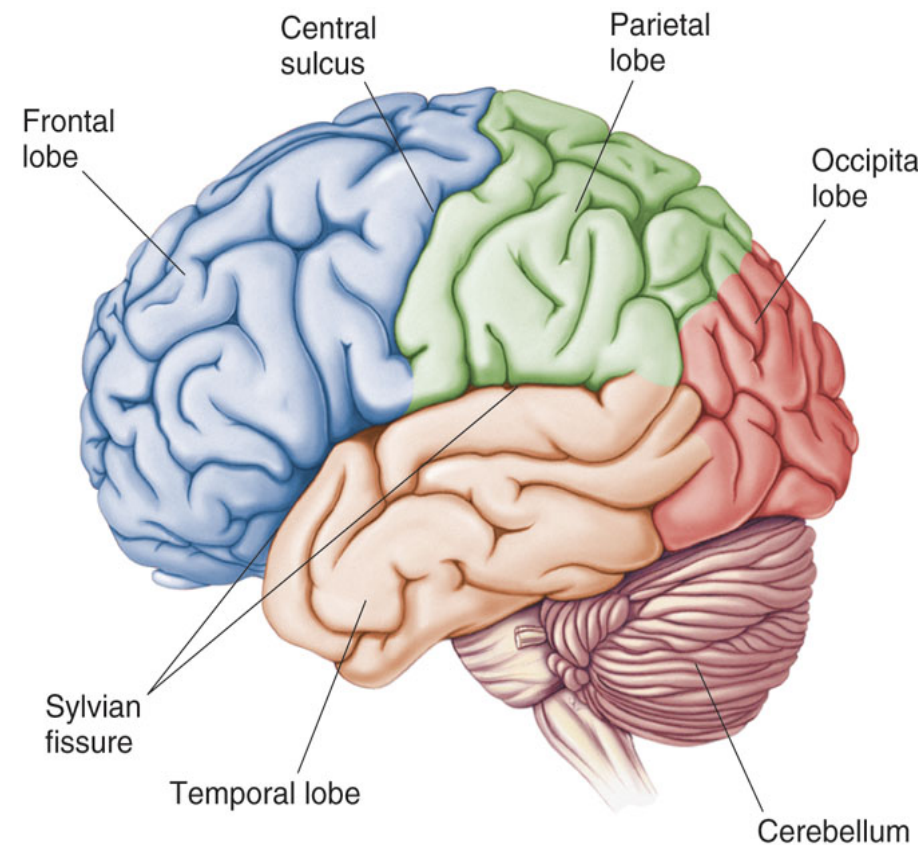
Central  
sulcus

Parietal  
lobe



# Lobes of the Brain – Occipital Lobe

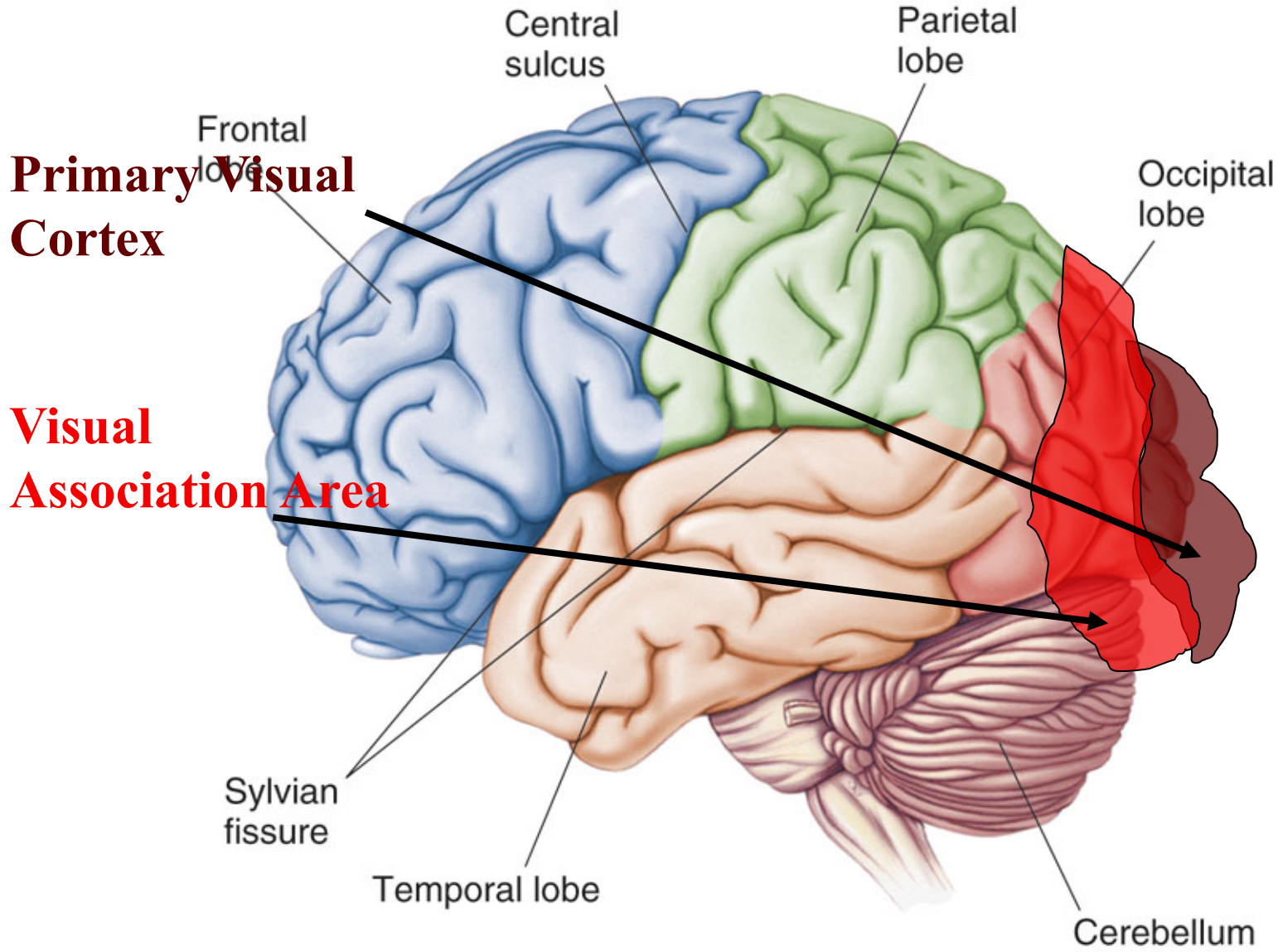
- The Occipital Lobe of the Brain is located deep to the Occipital Bone of the Skull.
- Its primary function is the processing, integration, interpretation, etc. of **VISION** and visual stimuli.





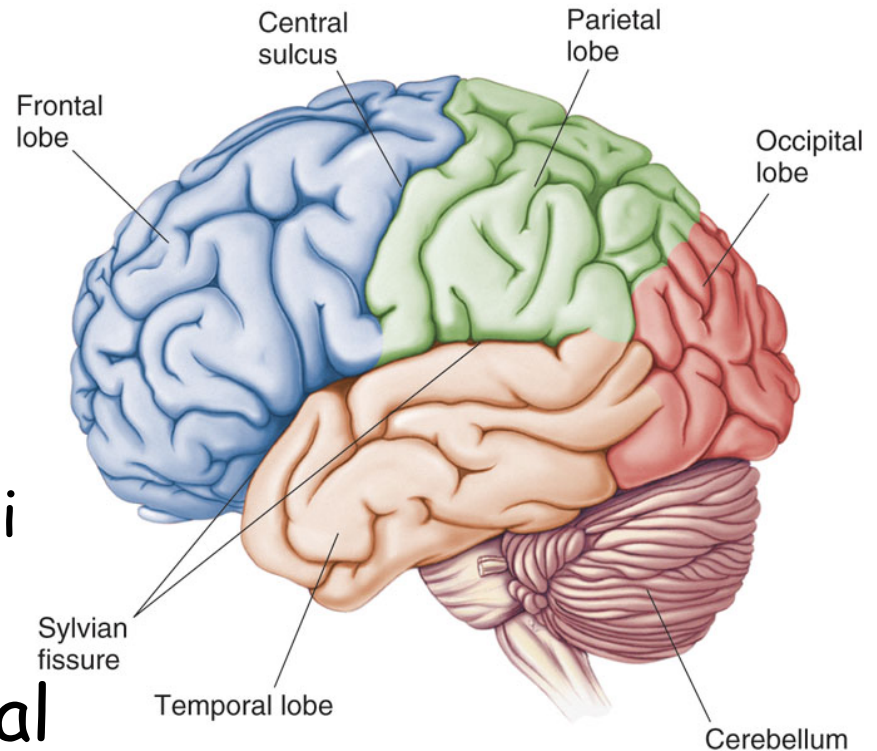
# Occipital Lobe – Cortical Regions

- **Primary Visual Cortex** - This is the primary area of the brain responsible for detection of visual stimuli
- **Visual Association Area** - Interprets information acquired through the primary visual cortex.



# Lobes of the Brain – Temporal Lobe

- The Temporal Lobes are located on the sides of the brain, deep to the Temporal Bones of the skull.
- They play an integral role in the following functions:
  - Hearing
  - Organization/Comprehension of language
  - Information Retrieval (Memory and Memory Formation)



# Temporal Lobe – Cortical Regions

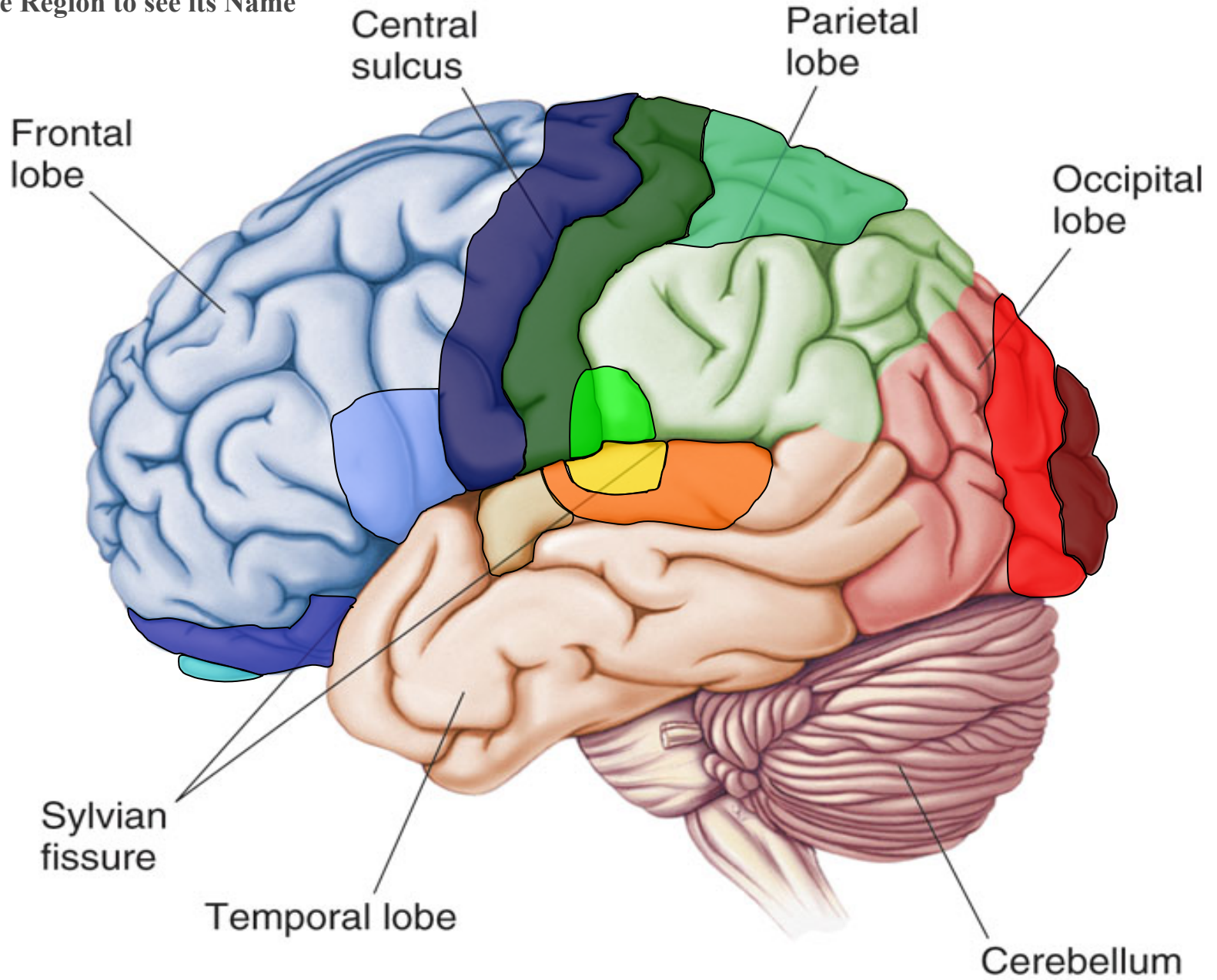
- **Primary Auditory Cortex** - Responsible for hearing
- **Primary Olfactory Cortex** - Interprets the sense of smell once it reaches the cortex via the olfactory bulbs. (Not visible on the superficial cortex)
- **Wernicke's Area** - Language comprehension.
- Located on the Left Temporal Lobe (dominant hemisphere).
- Understand auditory and visual information and send them to Brocas area

# Temporal Lobe

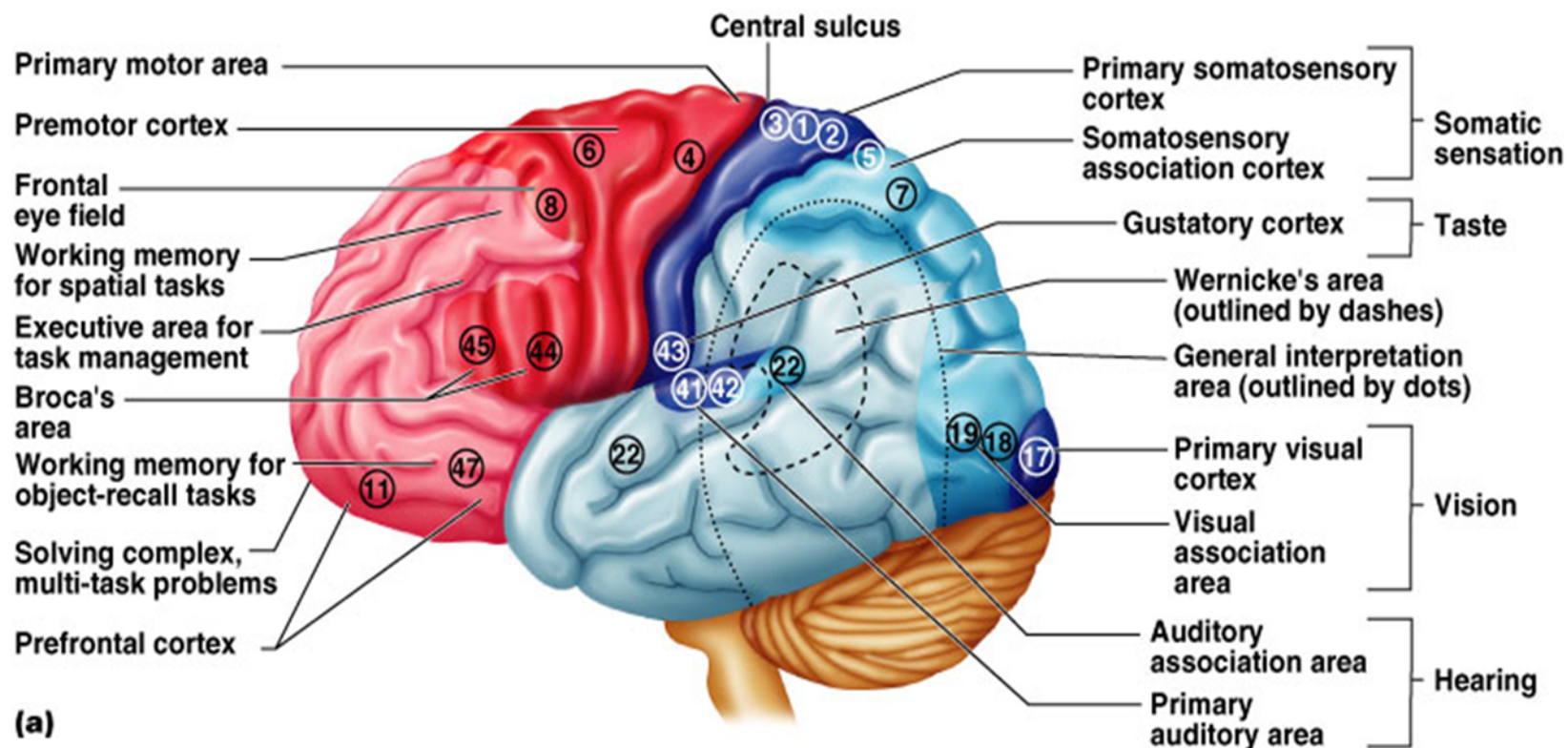
☐ Lesion → may lead to:

- ✓ - **Wernicke's Aphasia** - Language comprehension is inhibited. The individuals have difficulty understanding written and spoken language
- ✓ Memory impairment
- ✓ & can be associated with temporal lobe epilepsy

Click the Region to see its Name





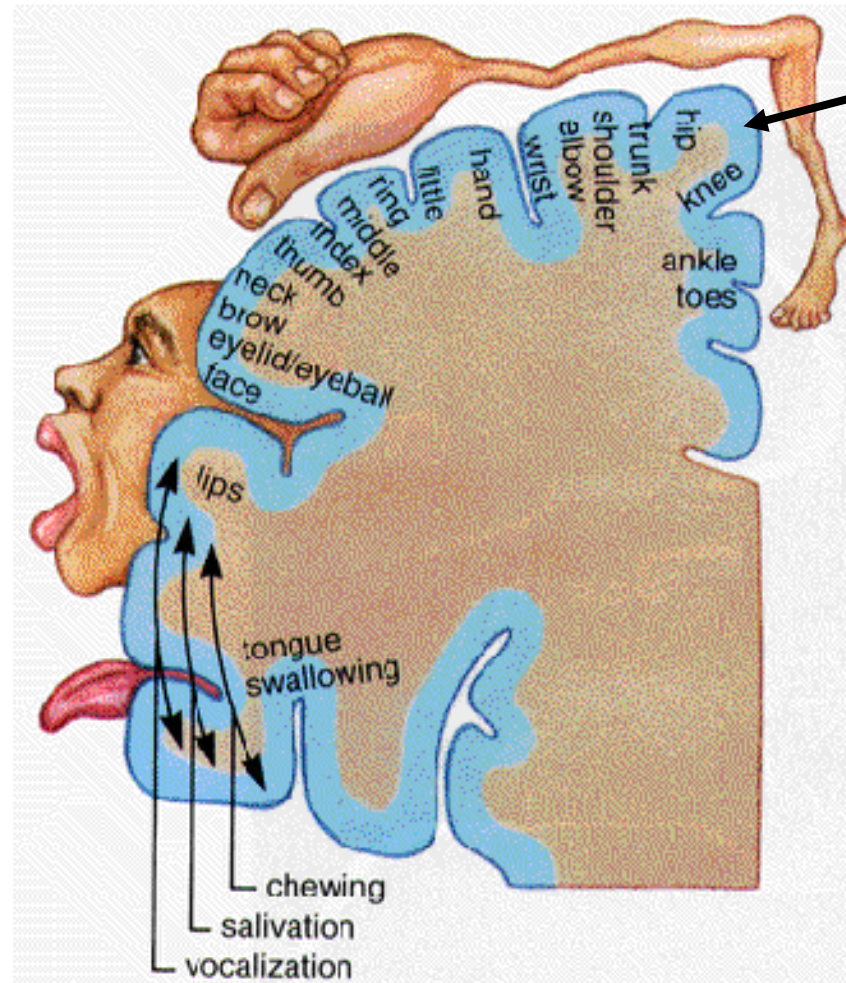


# Dominant (categorical hemisphere) & Non-dominant (representational) Hemisphere

- ❖ Functional differences between left and right hemispheres
- In most people, left hemisphere (**dominant hemisphere**) controls:
  - reading, writing, and math, decision-making, logic, speech and language (usually)
- Right cerebral hemisphere relates to:
  - ✓ understanding & interpreting music,
  - ✓ Non verbal visual Experience (facial expression , gesture)
  - ✓ Spatial relation between the person & their surroundings
  - ✓ Body language and intonation of peoples voices

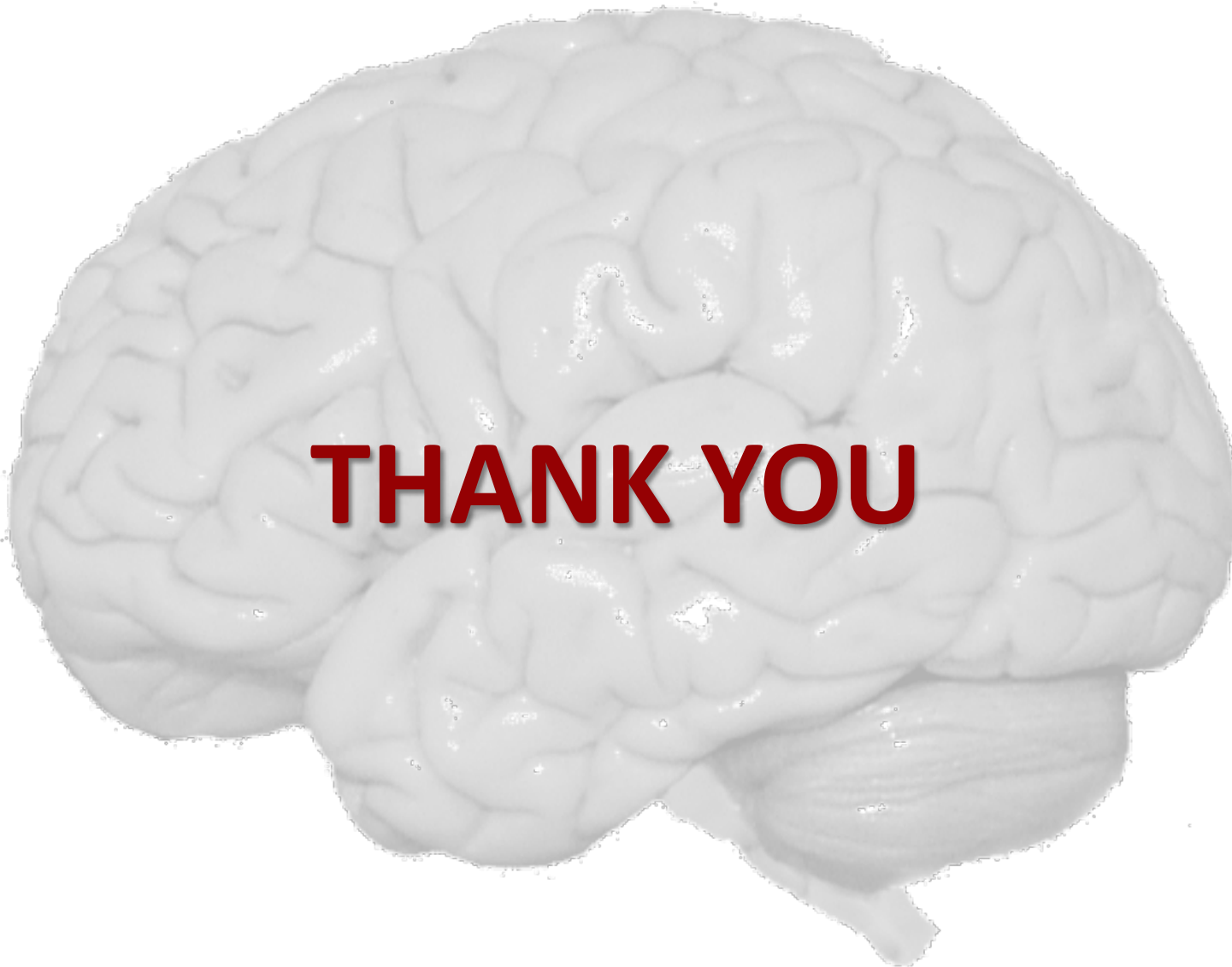

## A: Primary Motor Cortex



\* This graphic representation of the regions of the Primary Motor Cortex and Primary Sensory Cortex is one example of a HOMUNCULUS:

Homunculus



**THANK YOU**