

# Brachial Plexus

Anatomy Practical

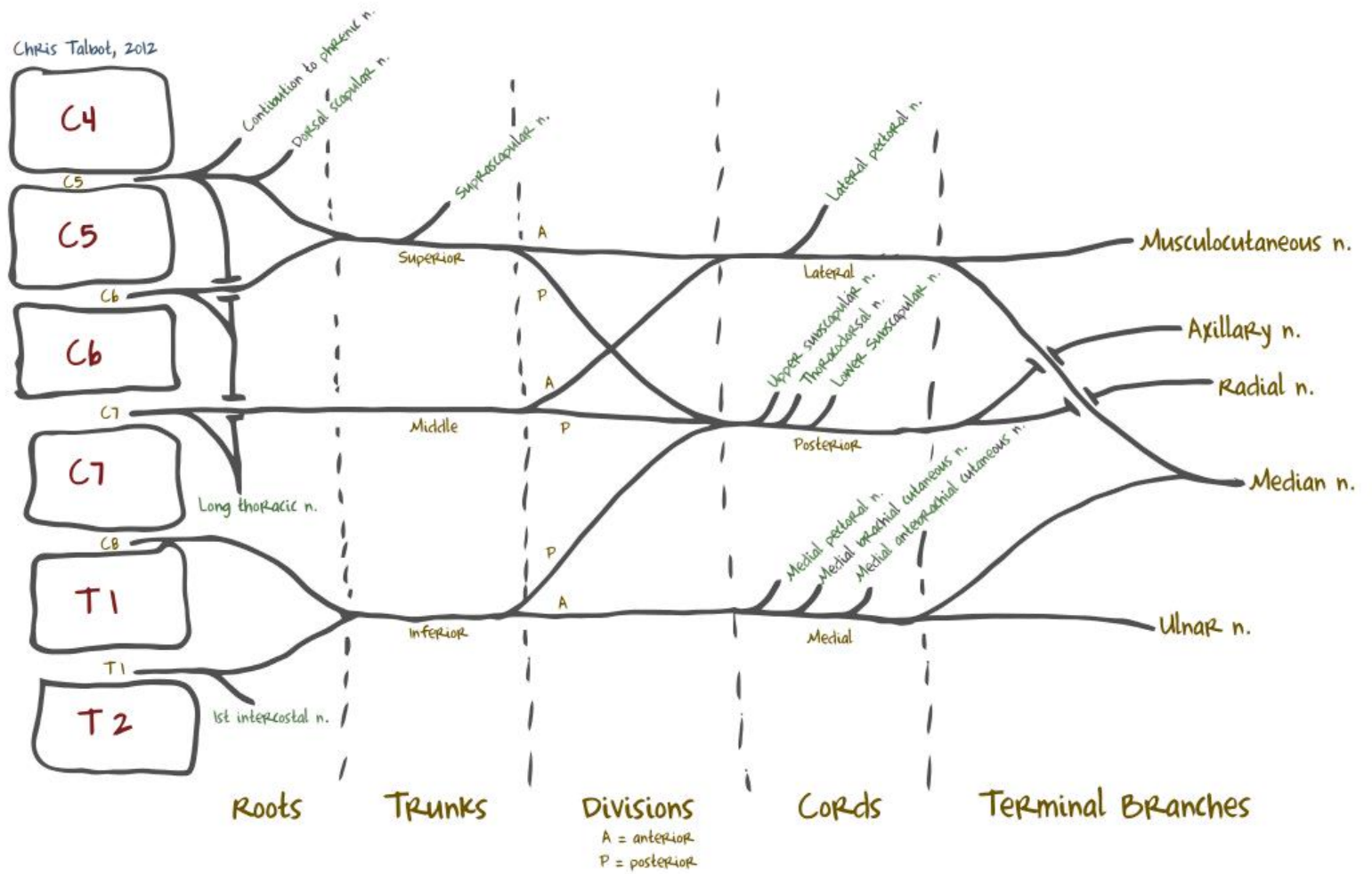
**By Dr. Mohsen Ali**

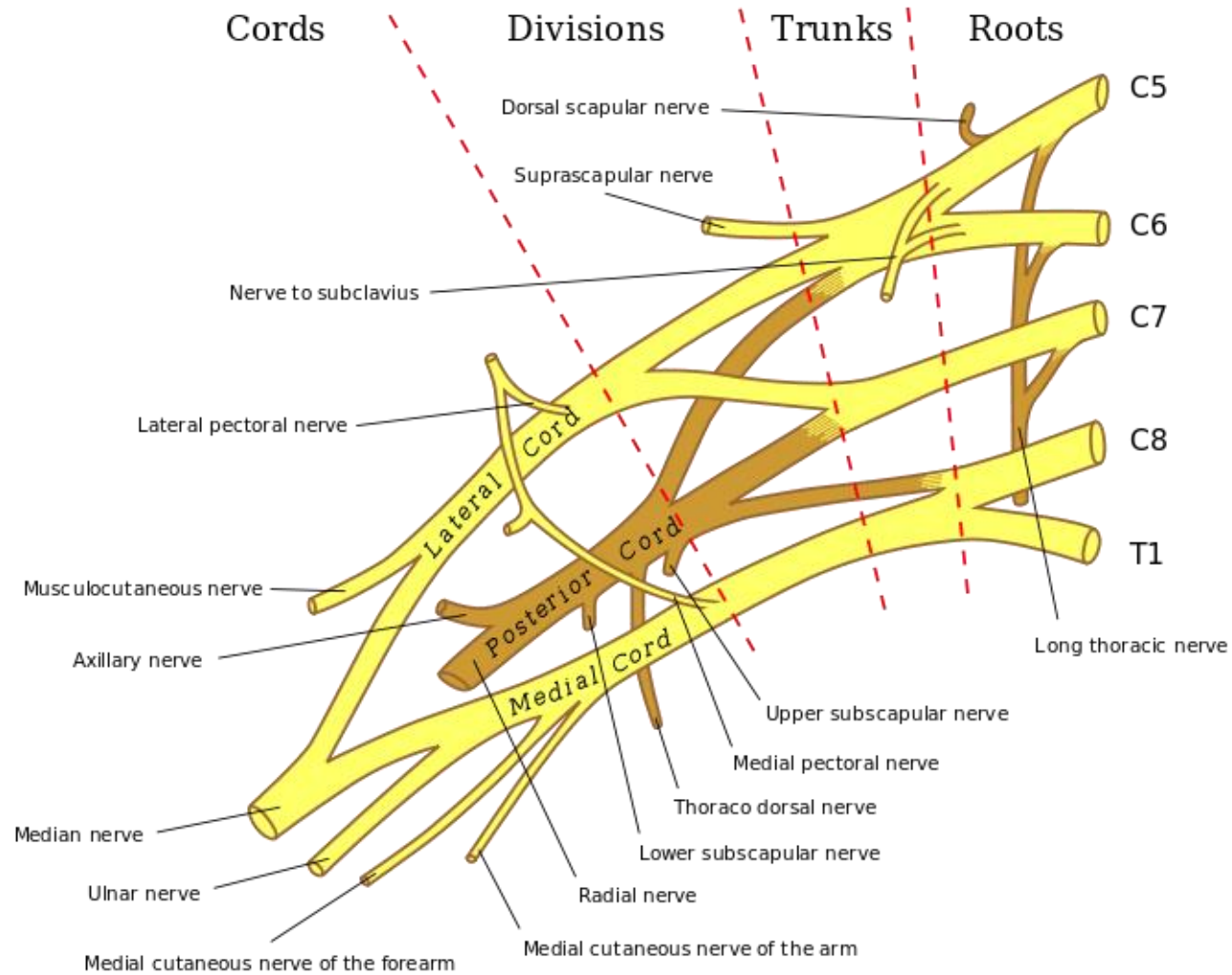
**Anatomy Department**

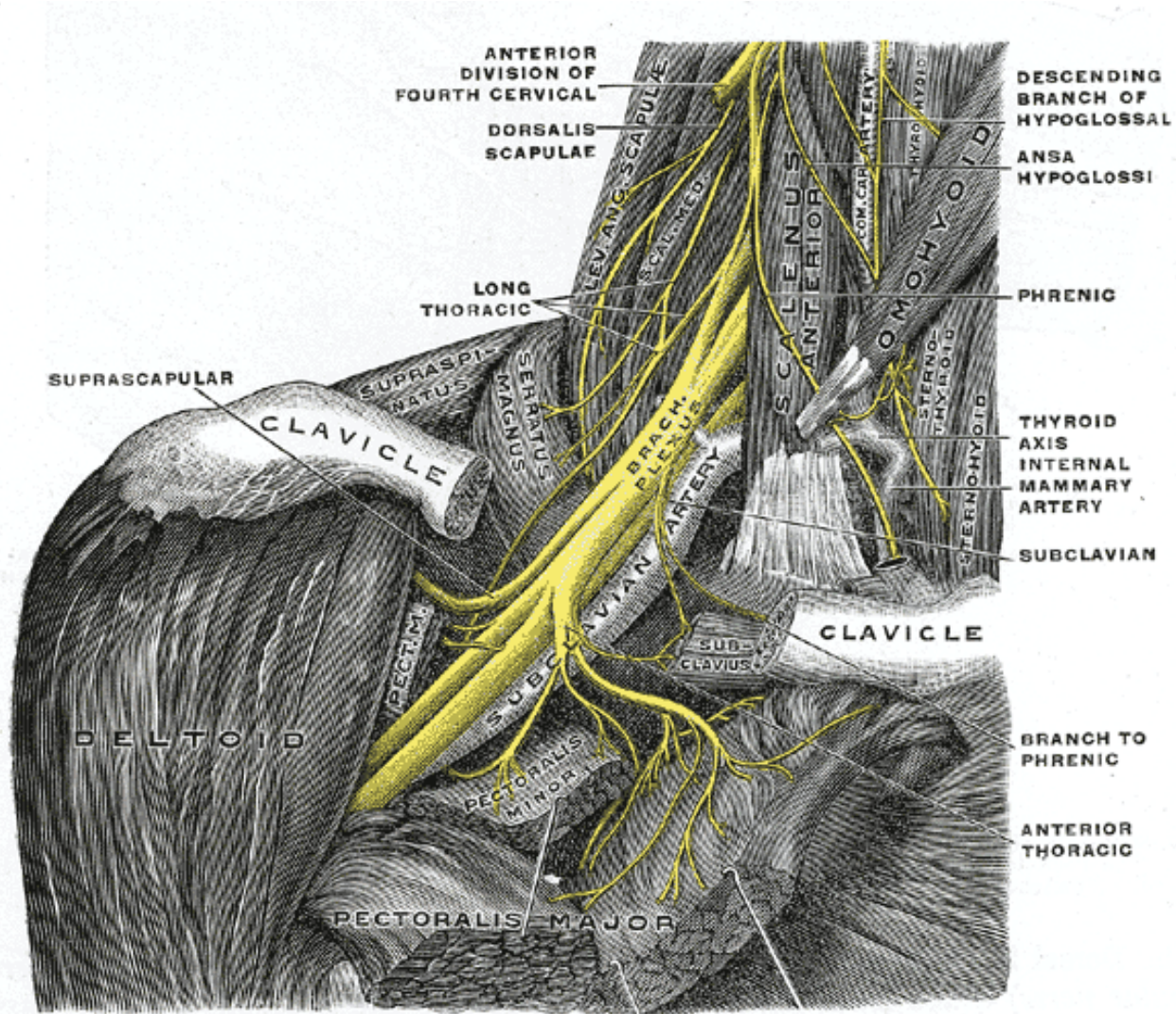
**College of Medicine**

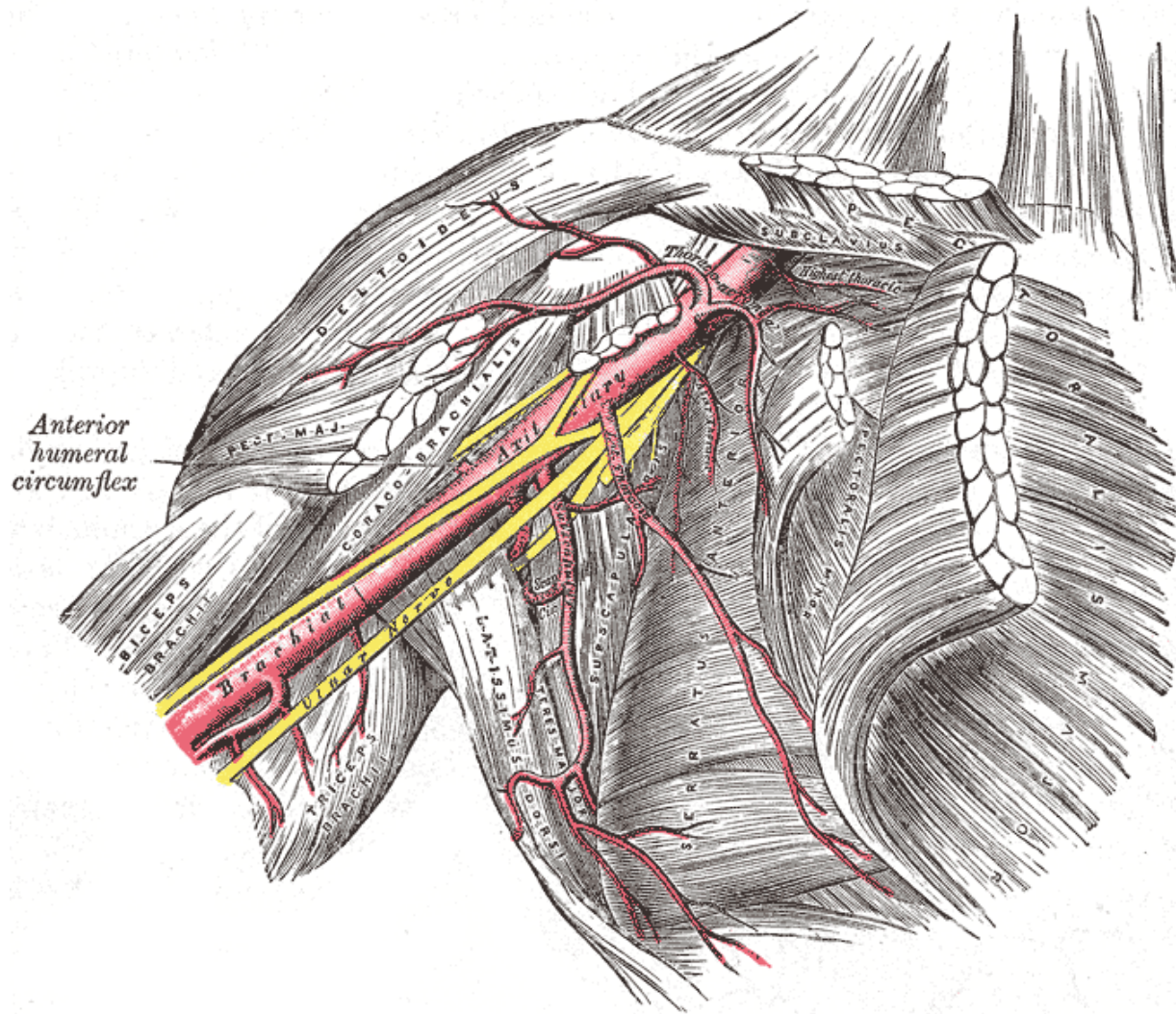
**King Saud University**

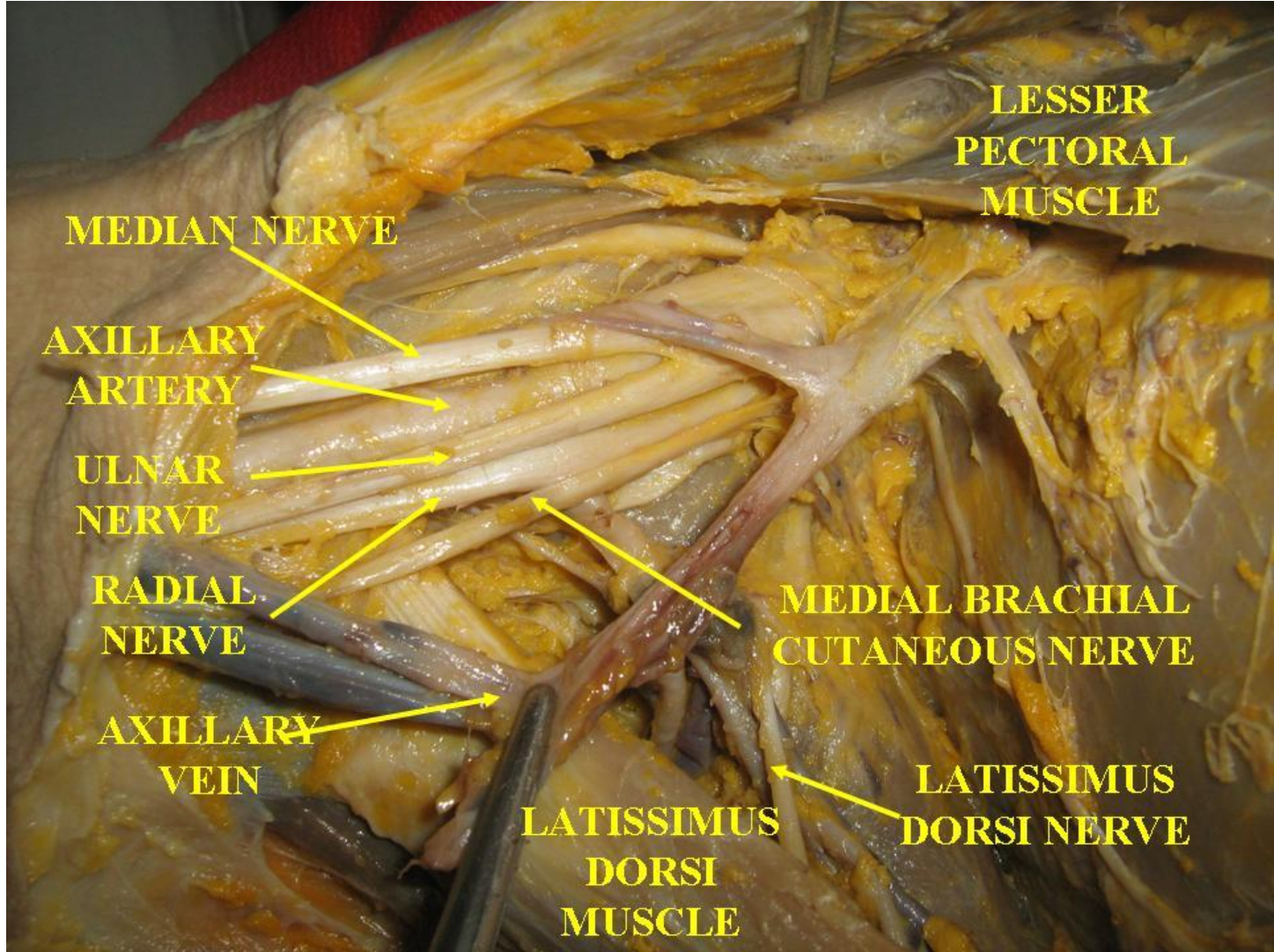
Chris Talbot, 2012

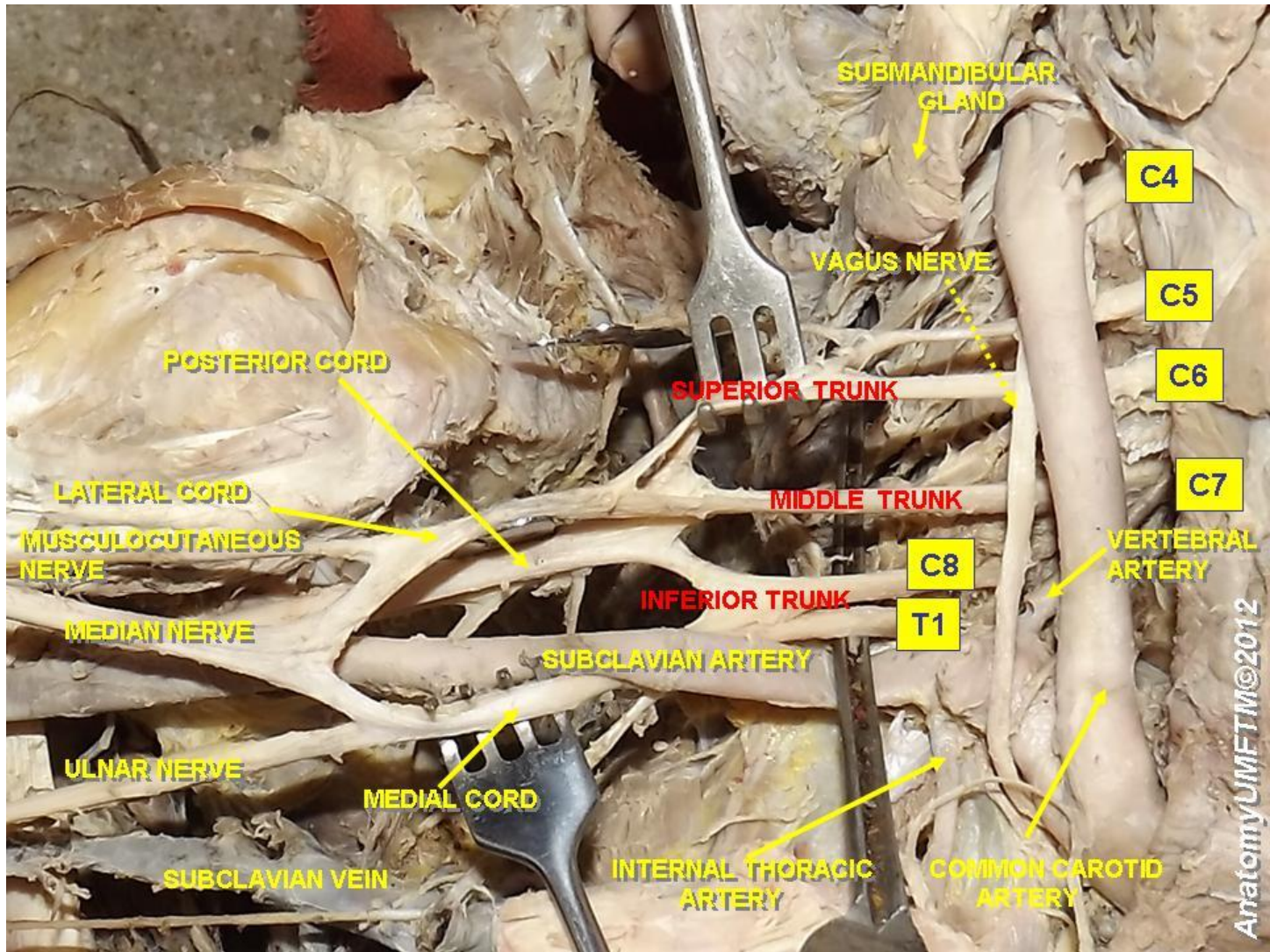


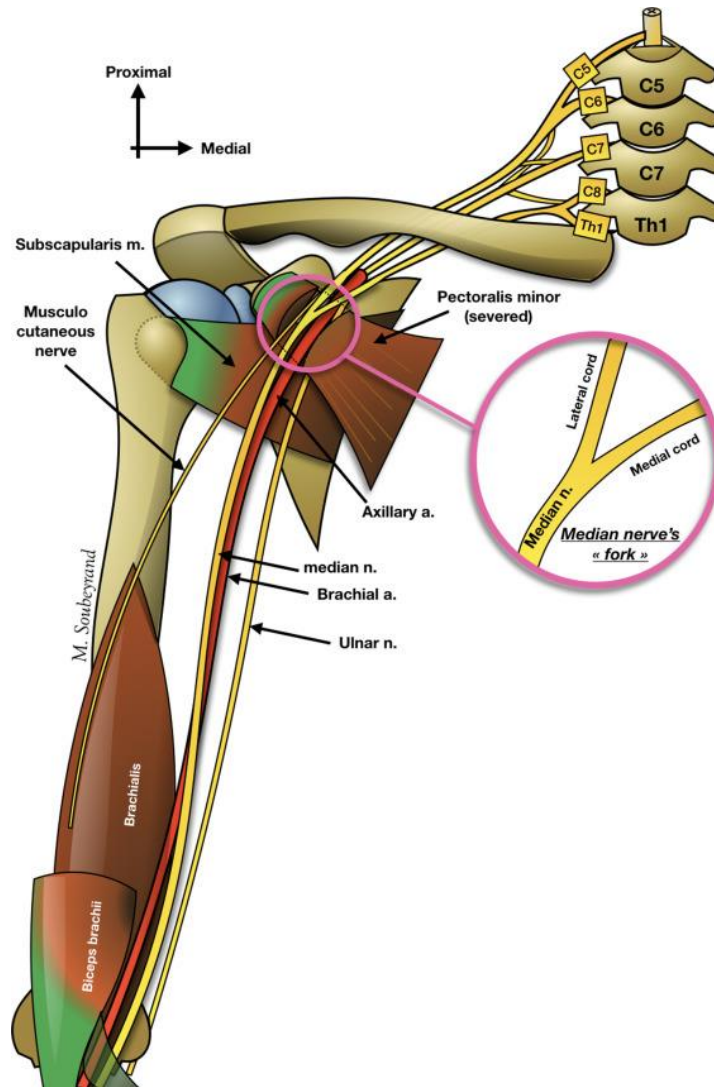




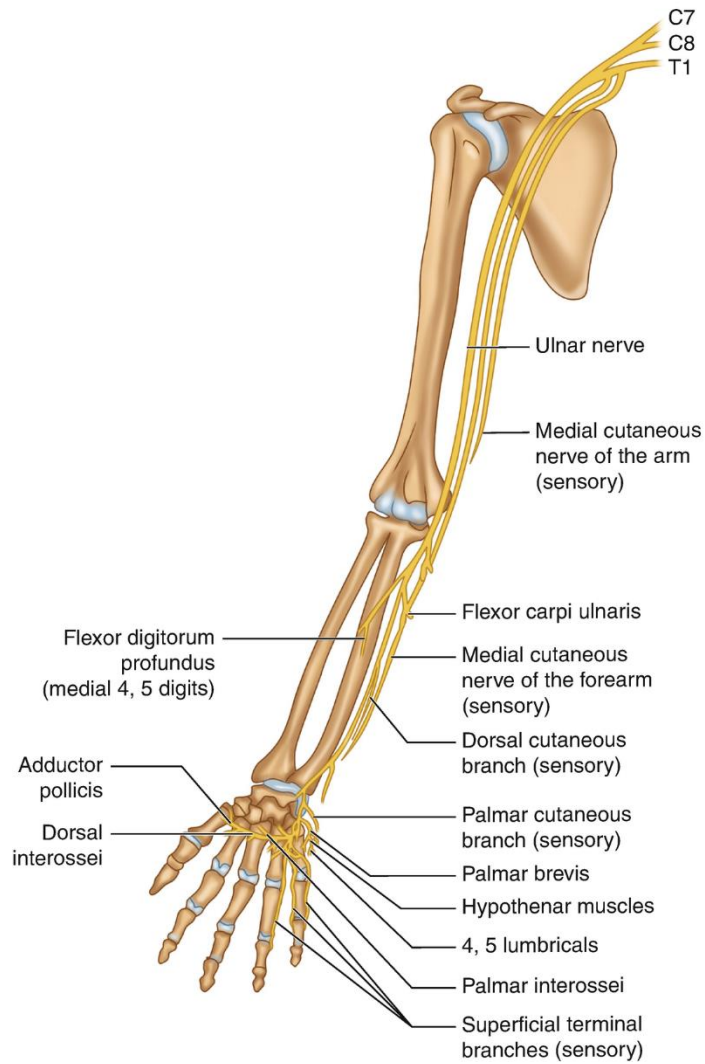


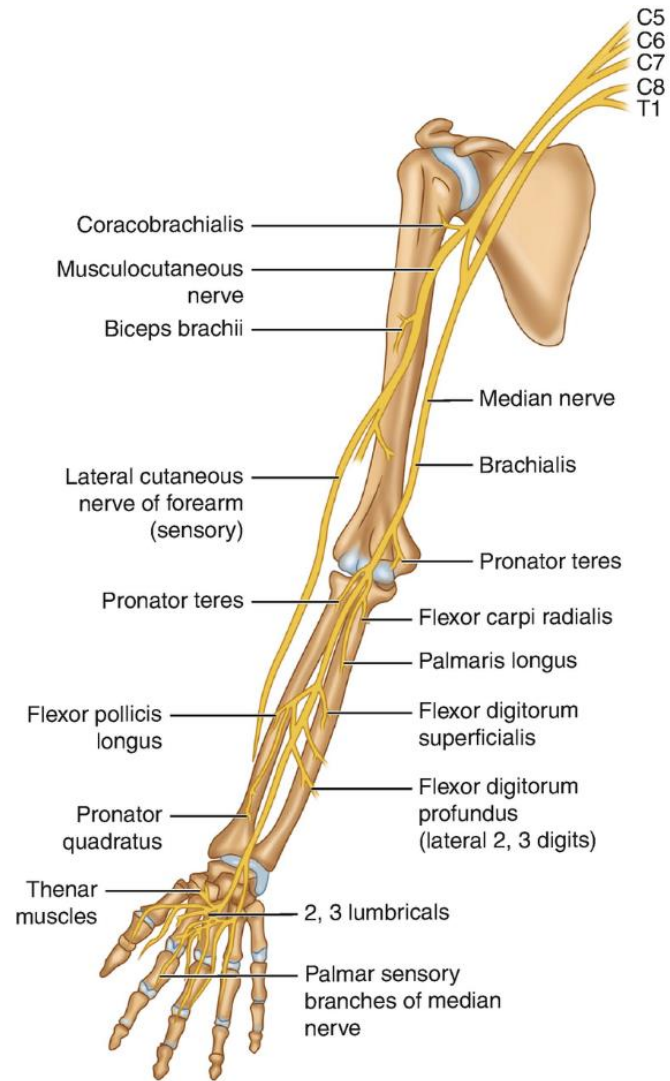


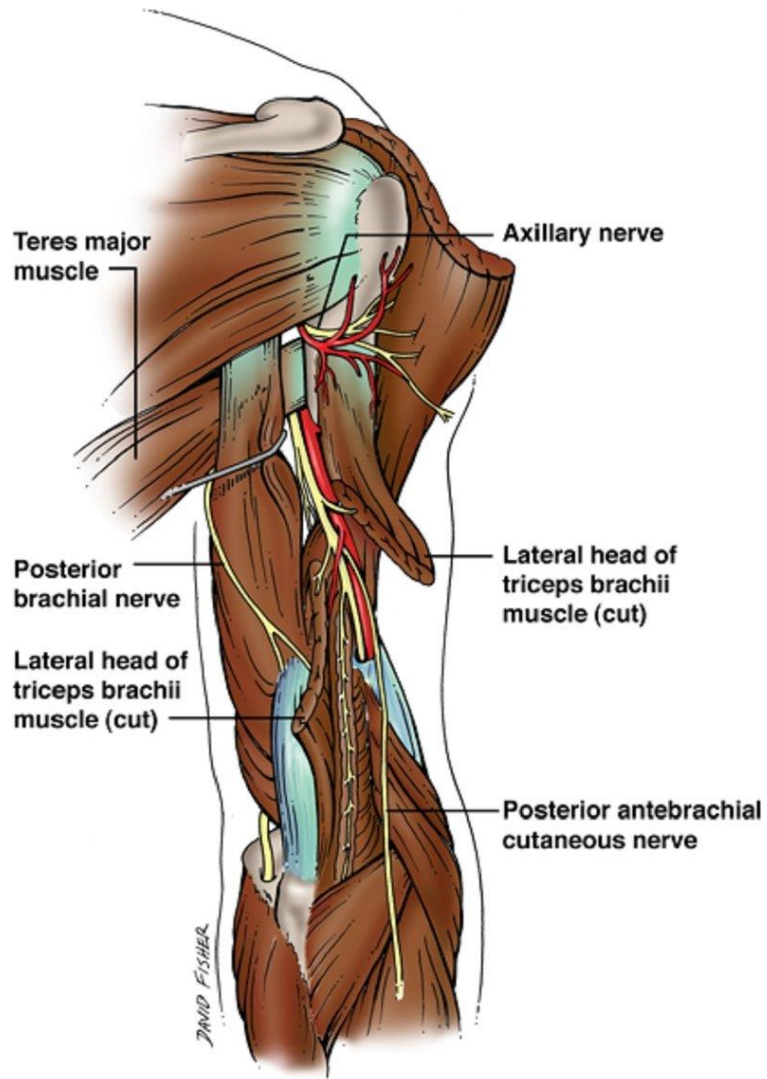












## **Disclosure**

Please be advised that this work is intended for non-profit purely educational purposes. We used some images from the internet and other sources. We did our best to link all images to their original sources to preserve copyrights. If you are the owner of one of those images, and you are not satisfied with our copyright level, please contact us and let us know how to make things right. We deeply appreciate your cooperation and consideration.

Contact: **[anatomy@ksu.edu.sa](mailto:anatomy@ksu.edu.sa)**