

Sacral Plexus

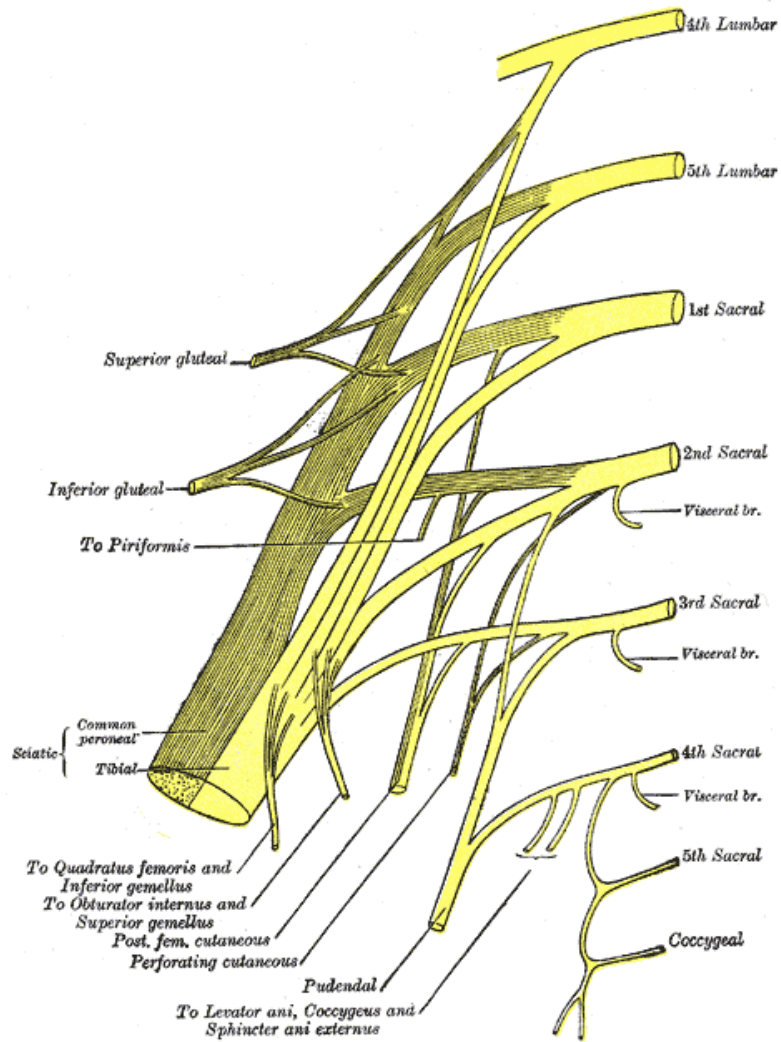
Anatomy Practical

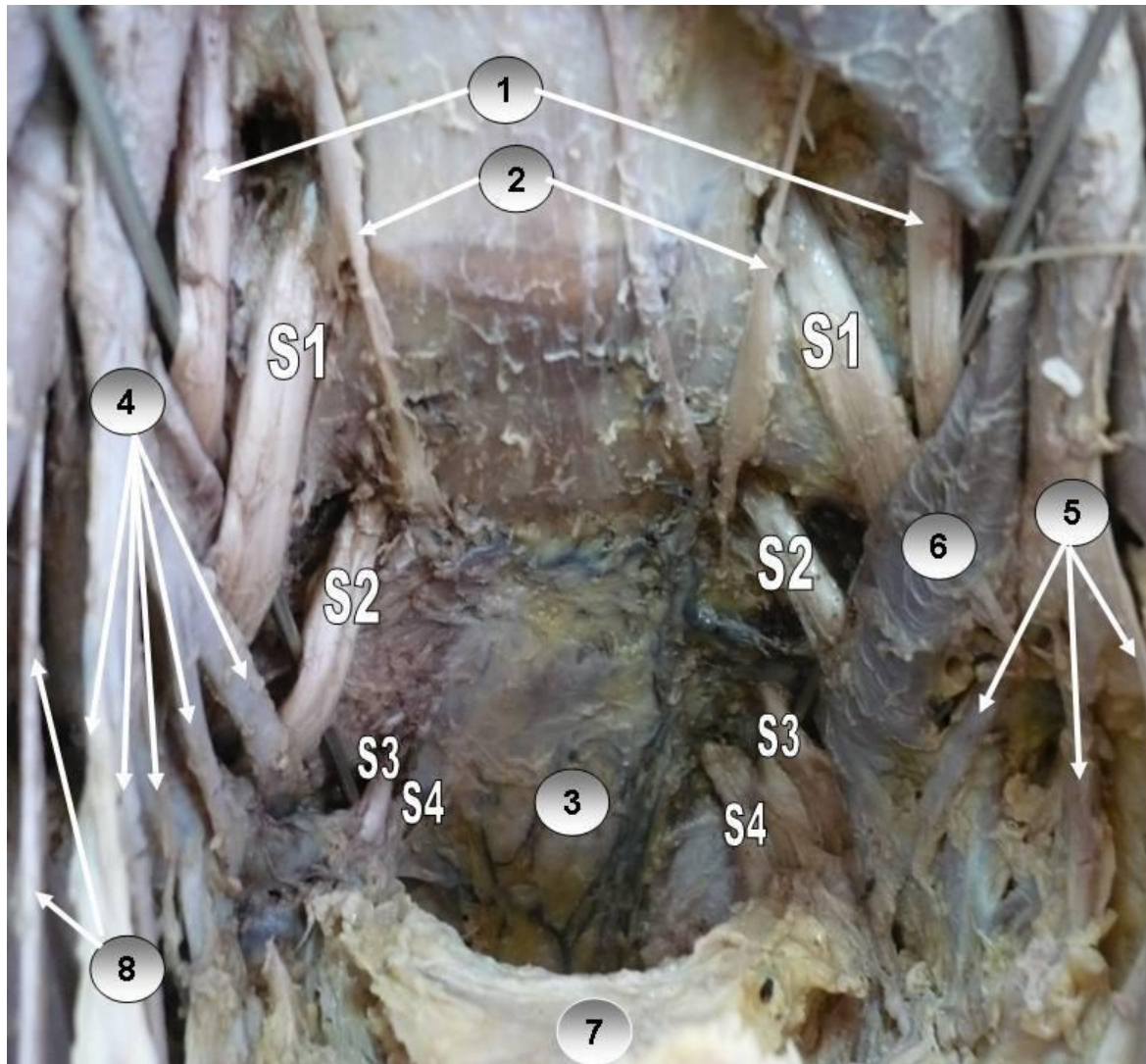
By Dr. Mohsen Ali

Anatomy Department

College of Medicine

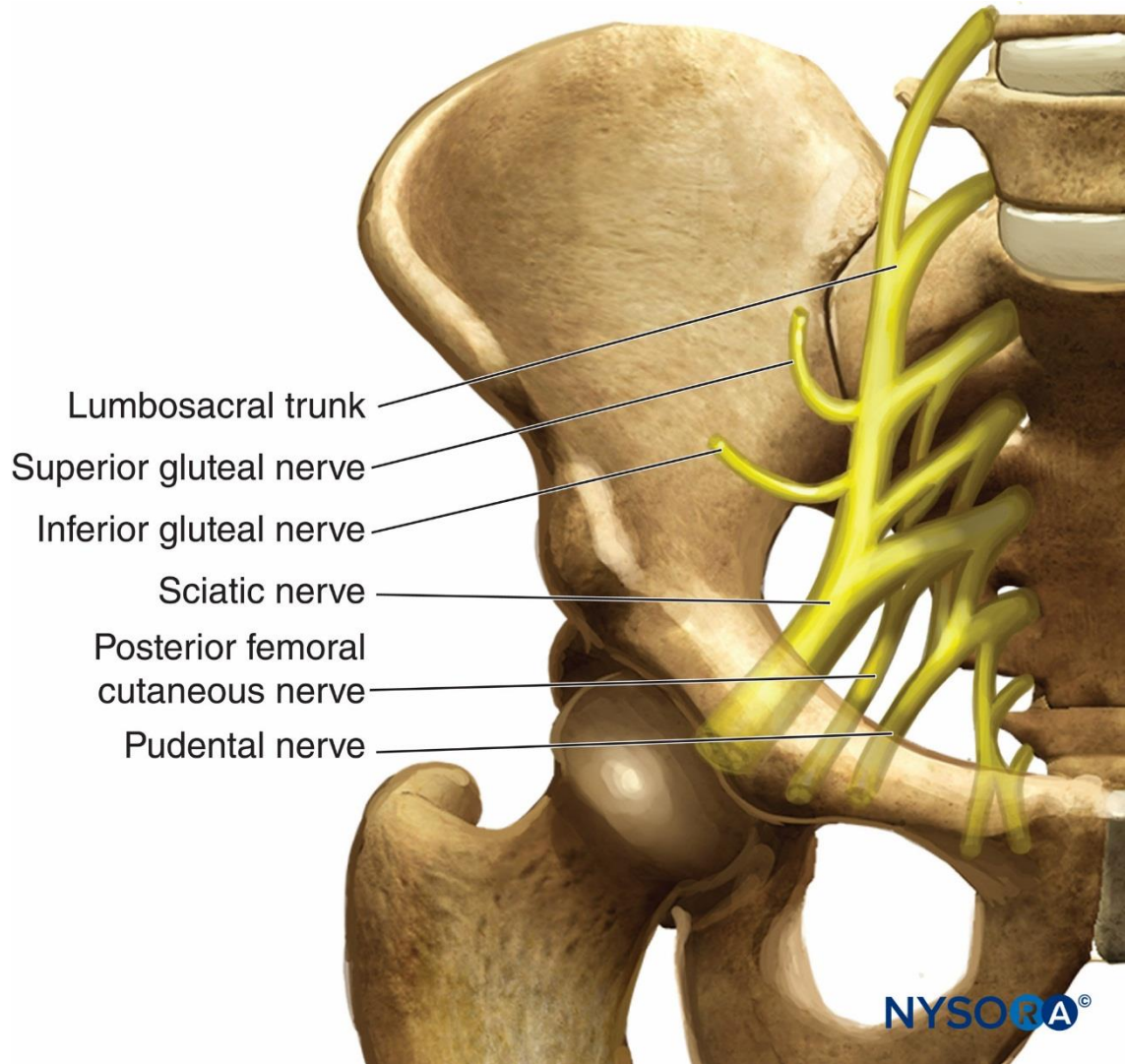
King Saud University





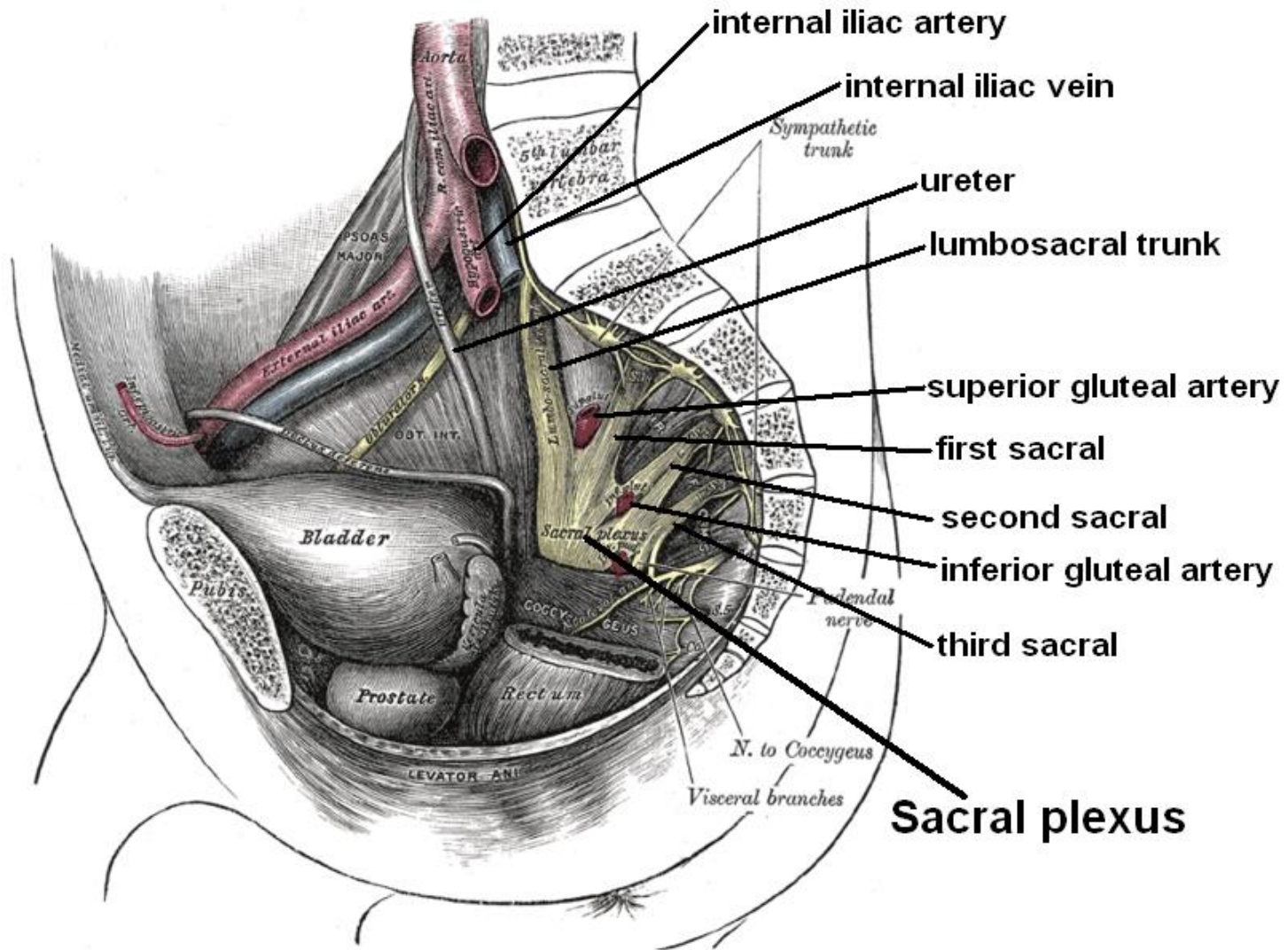
- 1. LOMBO-SACRAL TRUNK
- 2. SACRAL SYMPHATIC
- 3. RETRORECTAL SPACE
- 4. RIGHT INTERNAL I IAC. ARTRY
- 5. LEFT INTERNAL I IAC. ARTRY
- 6. LEFT INTERNAL ILIAC VEIN
- 7. RECTUM
- 8. OBTURATOR NERVE

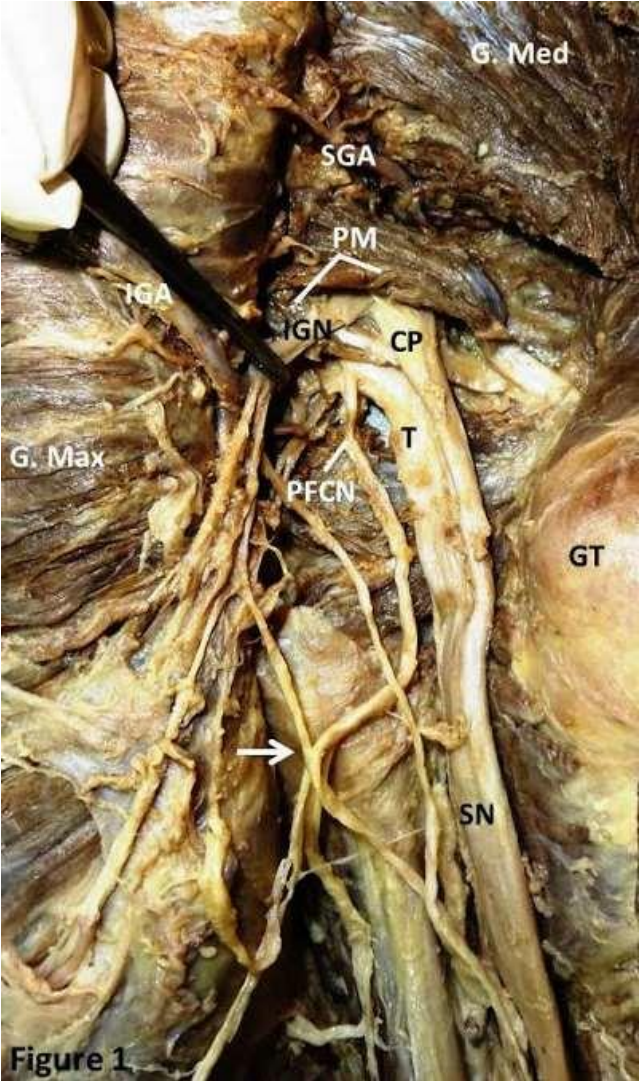




- Lumbosacral trunk
- Superior gluteal nerve
- Inferior gluteal nerve
- Sciatic nerve
- Posterior femoral cutaneous nerve
- Pudental nerve

NYSORA®





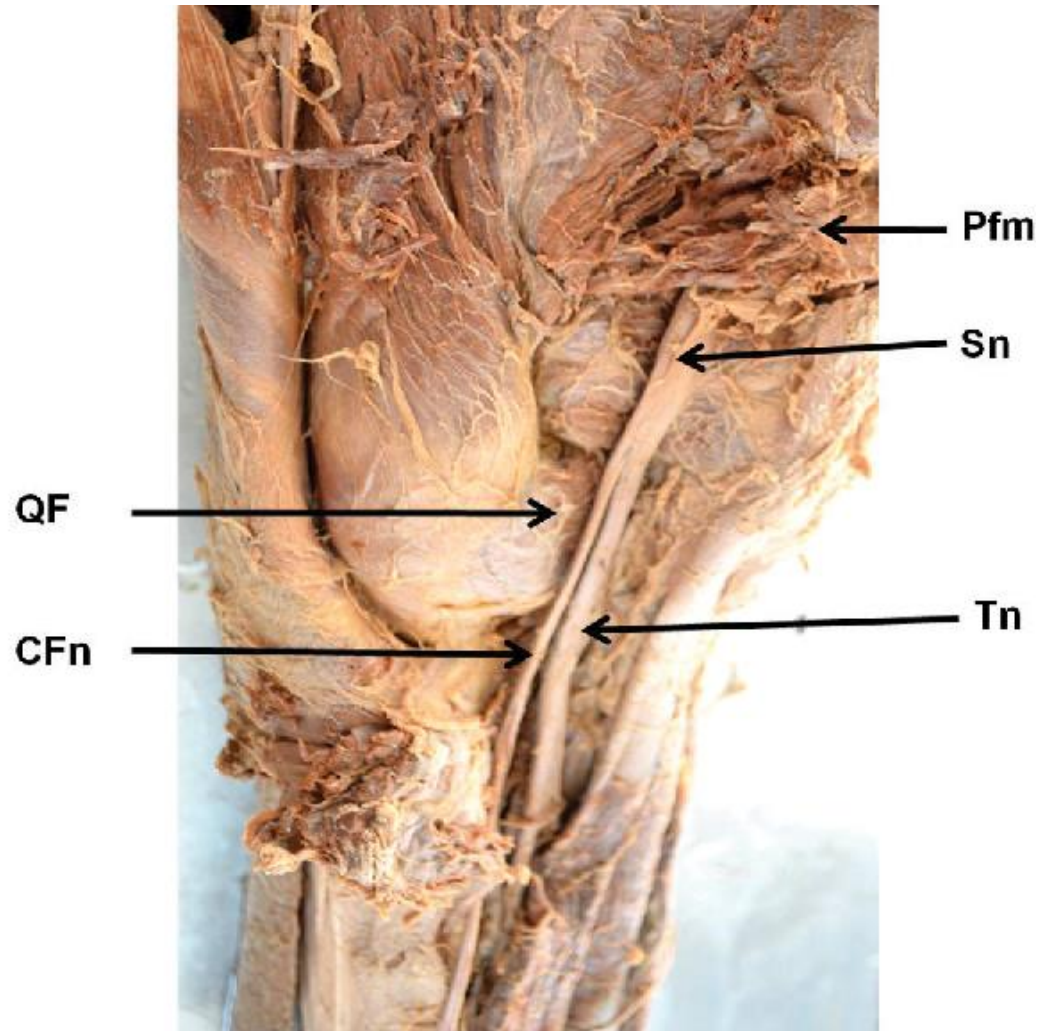
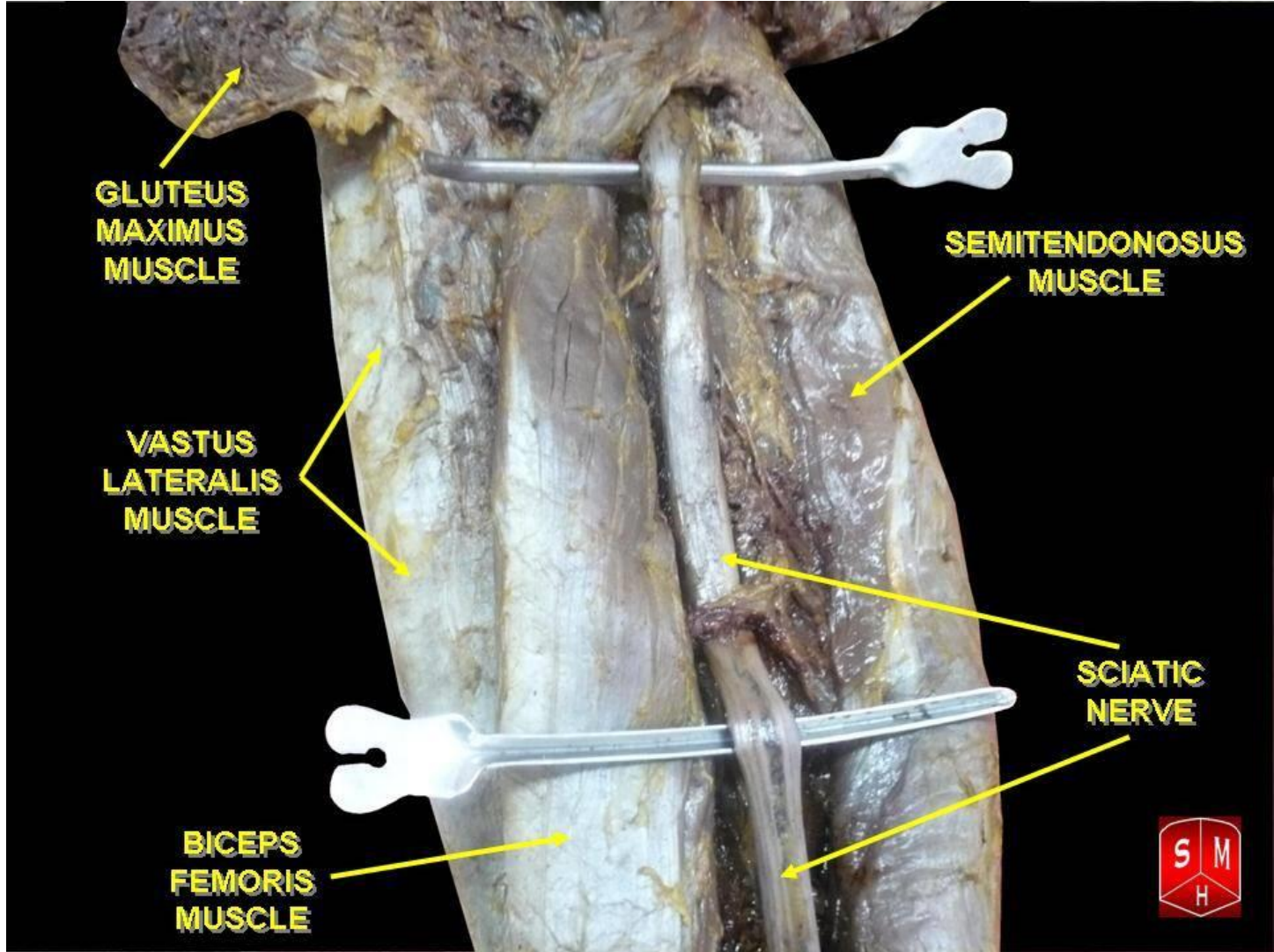
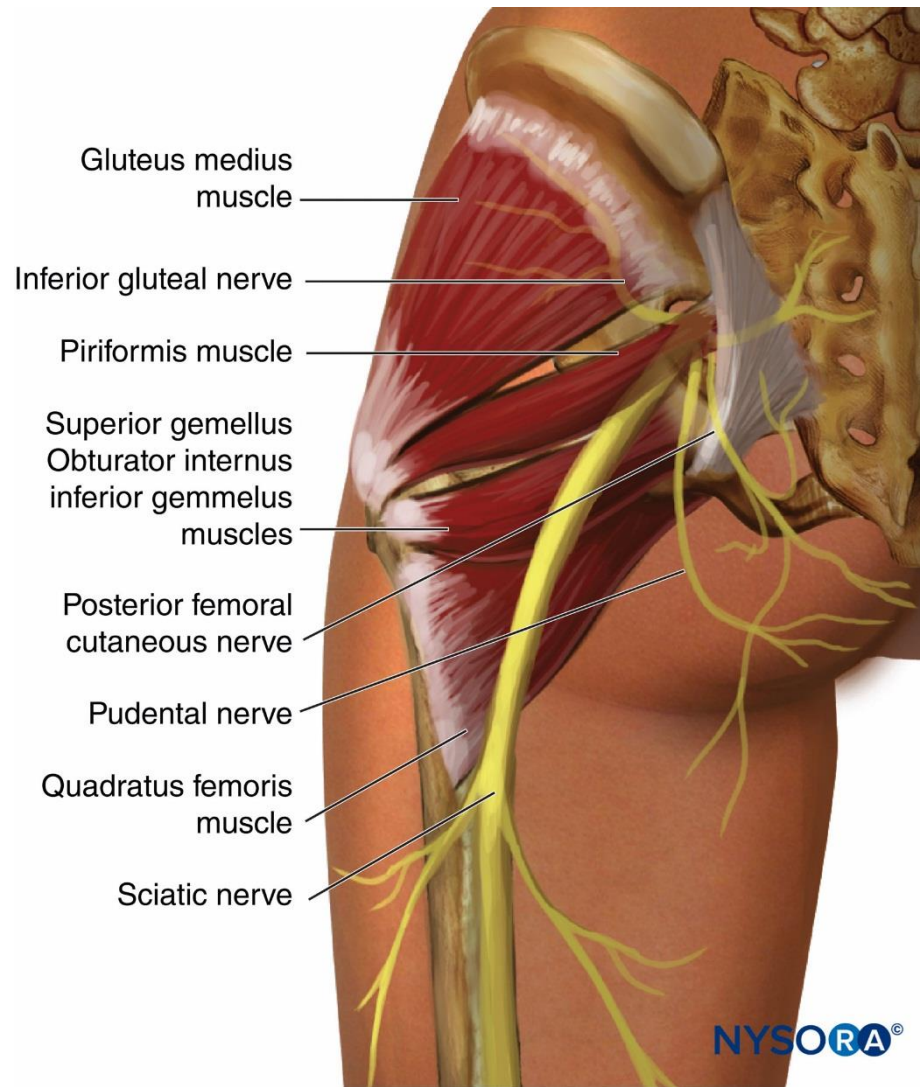
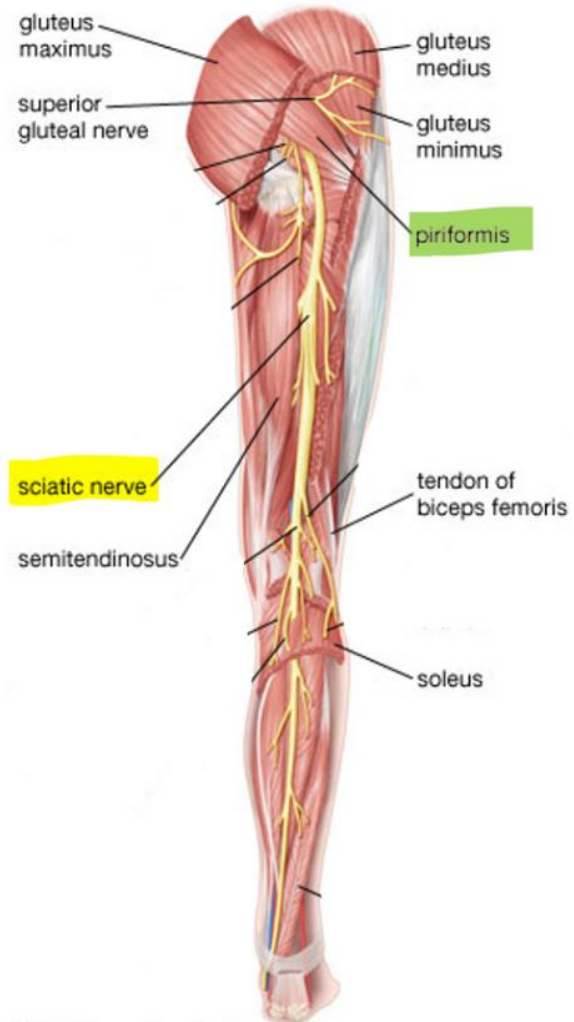


Figure 5. The left gluteal region after reflecting gluteus maximus







© 2007 Encyclopædia Britannica, Inc.

Disclosure

Please be advised that this work is intended for non-profit purely educational purposes. We used some images from the internet and other sources. We did our best to link all images to their original sources to preserve copyrights. If you are the owner of one of those images, and you are not satisfied with our copyright level, please contact us and let us know how to make things right. We deeply appreciate your cooperation and consideration.

Contact: **anatomy@ksu.edu.sa**