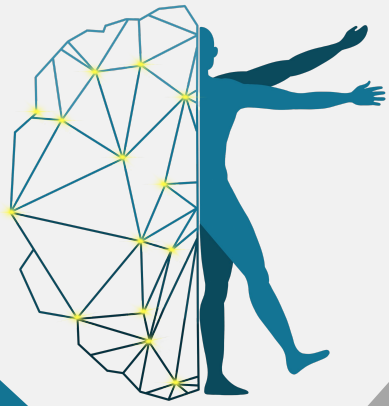

UMN & LMN Lesions

Objectives:

- ❖ Describe the functional anatomy of upper and lower motor neurons
- ❖ Describe and differentiate the features of upper and lower motor neuron lesions
- ❖ Explain features of Brown Sequard Syndrome
- ❖ Correlate the site of lesion with pattern of loss of sensations
- ❖ Describe facial, bulbar and pseudobulbar palsy



[Najeeb](#)



[JJ Medicine](#)



[Upper & Lower Motor neuron lesions \(Ghada Alsadhan\)](#)

Color index:

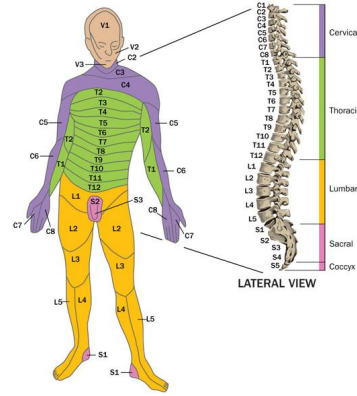
- ❖ **Important.**
- ❖ **Girls slide only.**
- ❖ **Boys slide only.**
- ❖ **Dr's note.**
- ❖ **Extra information.**



Editing File

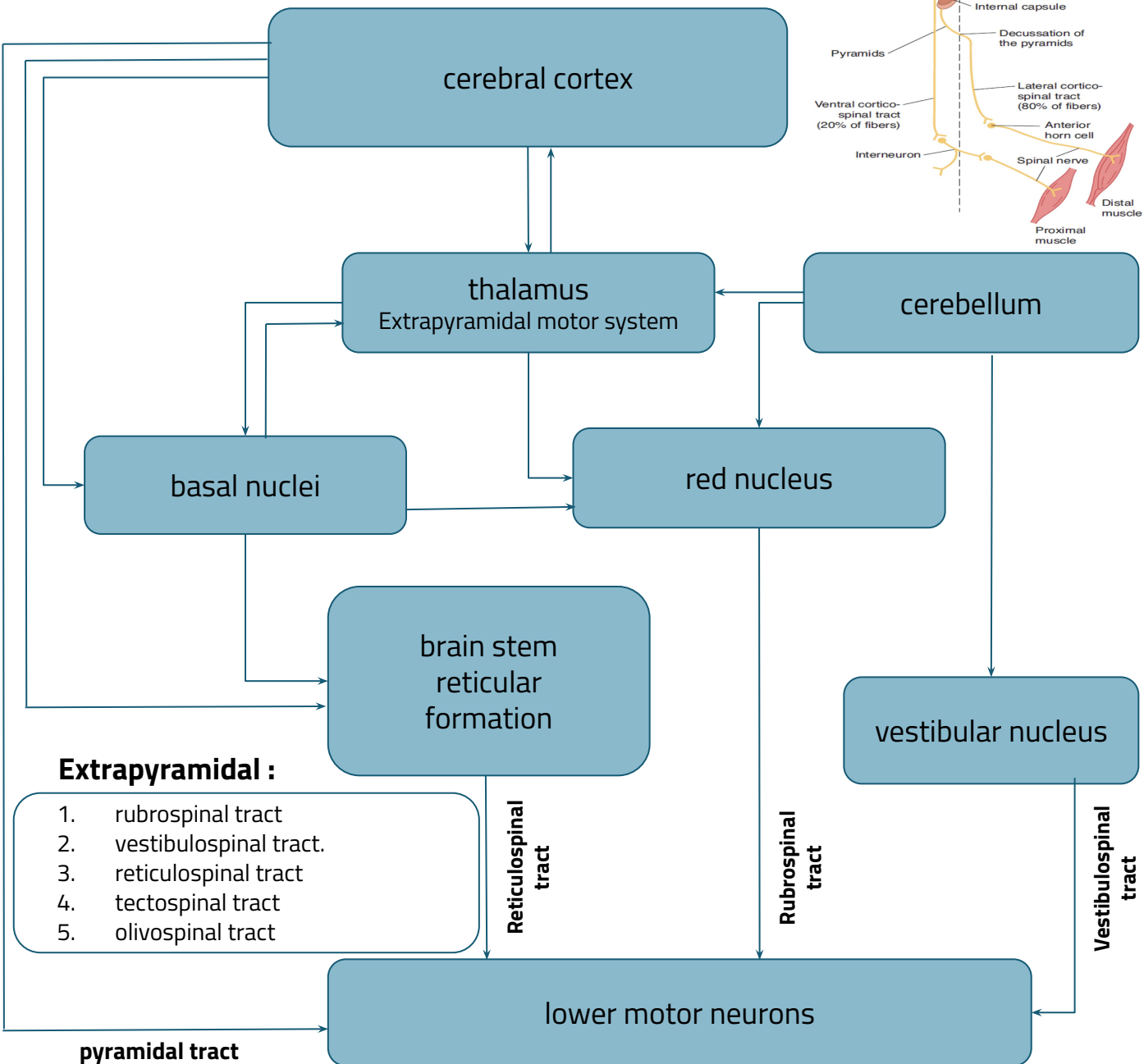
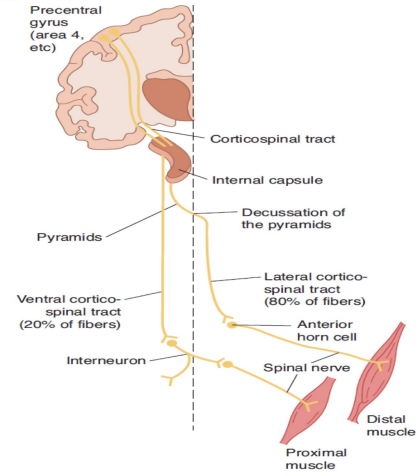
Spinal segments

31 segments, embryological segment growth of cord lags behind > mature spinal cord ends at L1.



Upper & Lower motor neurons

UMNs control LMNs through two different pathways



Extrapyramidal :

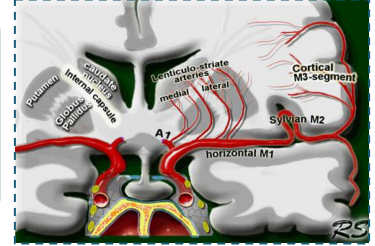
1. rubrospinal tract
2. vestibulospinal tract.
3. reticulospinal tract
4. tectospinal tract
5. olivospinal tract

Lenticulostriate Arteries

The most common site for stroke

*only in female slides

The superior parts of both the anterior and posterior and the genu of the internal capsule are supplied by the lenticulostriate arteries, which are branches of the M1 segment of middle cerebral artery.



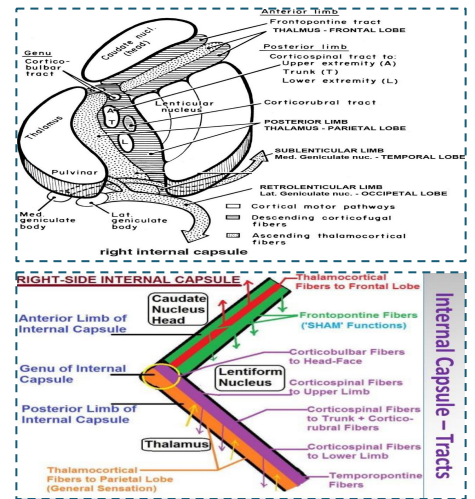
Right Internal Capsule

*only in female slides

❖ Reciprocal connections between thalamus and cortex are found in four limbs of the internal capsule:

- Anterior limb with frontal lobe
- Posterior limb with parietal lobe
- Retrolenticular limb with occipital lobe .
- Sublenticular limb with temporal lobe

- ❖ The genu contains the corticobulbar axons
- ❖ Corticospinal axons are in the posterior limb
- ❖ Corticopontine axons are in both the anterior and posterior limbs



*If the internal capsule is injured, (all fibers in purple color) will be affected

Causes of UMNL & LMNL

Upper Motor Neuron Lesion

Can result from

- Cerebral stroke by **hemorrhage, thrombosis or embolism**
- Spinal cord transection or hemisection (brown sequard syndrome)

Lower Motor Neuron Lesion

Can result from

- **Anterior horn cell lesions** e.g: poliomyelitis, motor neuron disease
- **Spinal root lesions or peripheral nerve lesion** e.g: nerve injury by trauma or compressive lesion .

Note*: Pure corticospinal tract lesion cause hypotonia instead of spasticity The reason is that pure pyramidal tract lesion is very very rare, and spasticity is due to loss of inhibitory control of extrapyramidal tracts rare and we don't see it clinically, only in experiments.



	Upper Motor Neuron Lesion	Lower Motor Neuron Lesion
Pattern	paralysis affect movements affects limbs	individual muscle or group of muscles are affected
Wasting	not pronounced (about 20 -30% wasting)	pronounced (about 70-80% wasting)
Tone	spasticity muscles hypertonic (clasp knife)	tendon reflexes diminished or absent
Tendon reflexes	brisk/increased	diminished or absent
Superficial reflexes	Absent	Absent
NCV	normal	decreased
Denervation potentials (Fibrillations) from fibrils, so can't be seen with eye only on EEG	Absent	Present
Fasciculations can be seen with eyes	Absent	Present
Trophic changes	Less	Pronounced in skin and nails
Clonus	present	Absent
Babinski's sign *Normal physiological Babinski's sign : in neonates	Extensor plantar response (positive)	Flexor or absent plantar responses

clonus is exaggerated tendon reflexes, the reflex arc is intact in UMNL so stretch reflex can still happen but not regulated by higher centers which leads to clonus

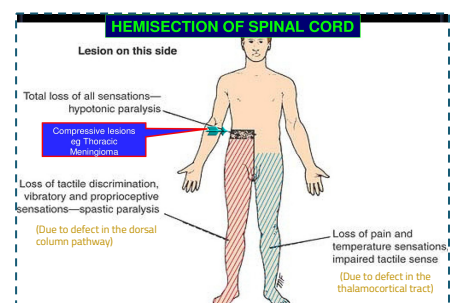
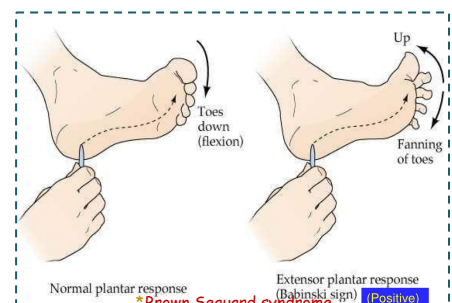
Fasciculation vs Fibrillation

Fasciculation

is a brief spontaneous contraction affecting a small number of muscle fibres, often causing a flicker of movement under the skin. (you can see the muscle contraction by your eyes)

fibrillation

a small.local,involuntary,muscular contraction due to spontaneous activation of single muscle cells or muscle fibers. (we must do EMG+NCV)



Brown Sequard Syndrome 

Hemisection of Spinal Cord

*Girls doctor: you have to know the symptoms of each affected tract

Ipsilateral Loss

- Fine touch, vibration, proprioception (dorsal column)
- leg ataxia (dorsal spinocerebellar)
- spastic paresis below lesion (lateral corticospinal)
- Flaccid paralysis (ventral horn destruction)
- Dermatomal anesthesia (dorsal horn destruction)

Contralateral Loss

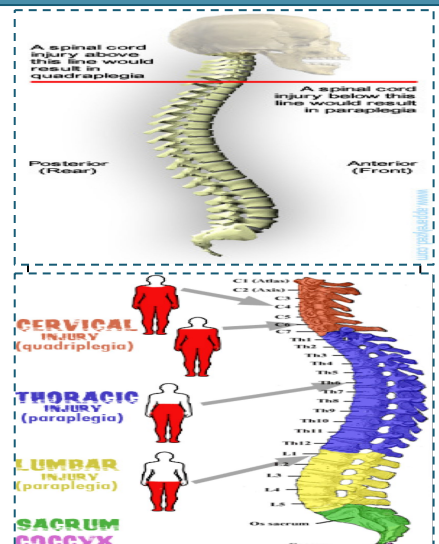
- Loss of pain and temperature (lateral spinothalamic)
- Loss of crude touch and pressure (ventral spinothalamic)
- Minor contralateral muscle weakness (ventral corticospinal)
- Leg ataxia (ventral spinocerebellar)

Upper cervical cord lesions produce quadriplegia and weakness of the diaphragm and lower lesions spare diaphragm with good prognosis if the phrenic nerve is intact respiration is spared with good prognosis

Lesions at **C4-C5** produce **quadriplegia**

- ❖ Hemiparesis means weakness
- ❖ Hemiplegia means total paralysis

limerick c3,c4,and c5 keep the diaphragm alive.



*only in male slides

Ipsilateral lower motor neuron paralysis

1

Ipsilateral lower motor neuron paralysis in the segment of the lesion and muscular atrophy, these signs are caused by damage to the neurons on the anterior gray column and possibly by damage to the nerve roots of the same segment.

Ipsilateral spastic paralysis

2

below the level of the lesion, an ipsilateral babinski sign is present, and depending on the segment of the cord damage < an ipsilateral loss of superficial abdominal reflex occurs, all these signs are due to loss of the corticospinal tracts on the same side of the lesion.

Ipsilateral band of cutaneous anesthesia

3

in the segment of the lesion < this results from the destruction of the posterior root and entrance into the spinal cord at the level of the lesion.

Ipsilateral loss of tactile discrimination and vibratory and proprioceptive sensations

4

.below the level of the lesion, these signs are caused by destruction of the ascending tracts in the posterior white column on the same side of the lesion .

Contralateral loss of pain and temperature sensations

5

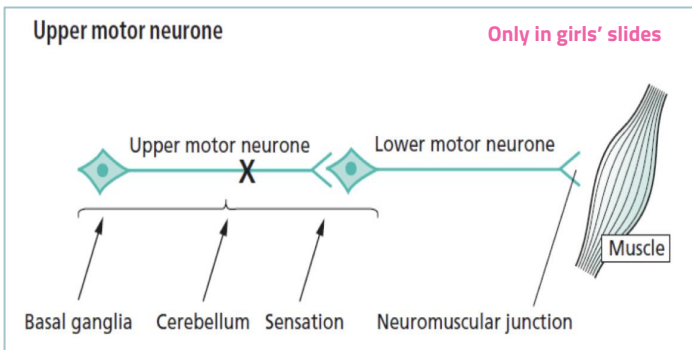
below the level of the lesion, this is due to destruction of the crossed lateral spinothalamic tracts on the same side of the lesion, because the tracts cross obliquely, the sensory loss occurs two three segment below the lesion distally.

Contralateral but not complete loss of tactile sensation

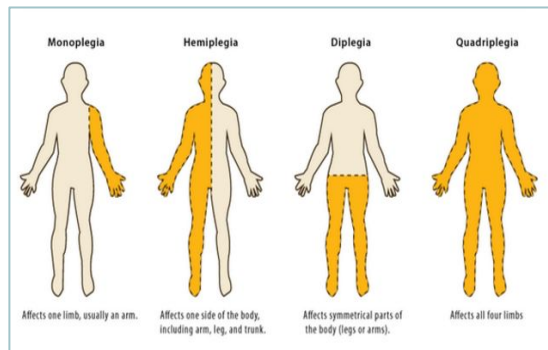
6

below the level of the lesion, this condition is brought about by destruction of the crossed anterior spinothalamic tracts on the side of the lesion, sensory impairment occurs two or three segment blow the level of the lesion distally

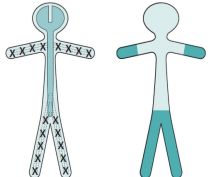
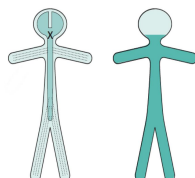
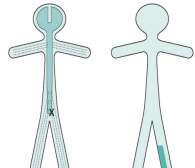
<h2>Contralateral Hemiparesis</h2>	<p>Internal capsule</p> <p>Lesions situated deep in the cerebral hemisphere, in the region of the internal capsule, are much more likely to produce weakness of the whole of the contralateral side of the body, face, arm and leg. Because of the funnelling of fibre pathways in the region of the internal capsule, such lesions commonly produce significant contralateral sensory loss (hemianesthesia) and visual loss (homonymous hemianopia), in addition to hemiparesis</p>	
<h2>Ipsilateral Hemiparesis</h2>	<p>A unilateral high cervical cord lesion will produce hemiparesis similar to that which is caused by a contralateral cerebral hemisphere lesion, except that the face can not be involved in the hemiparesis, vision will be normal, and the same dissociation of sensory loss may be found below the level of the lesion</p>	
<h2>Contralateral Monoparesis</h2> <p>Only in boys' slides</p>	<p>Lesion situated peripherally in the cerebral hemispheres i.e. involving part of the motor homunculus only, produces weakness of part of the contralateral side of the body, e.g.the contralateral leg. If the lesion also involves the adjacent sensory homunculus in the postcentral gyrus, there may be some sensory loss in the same part of the body</p>	
<h2>Ipsilateral Monoparesis</h2>	<p>A unilateral lesion in the spinal cord below the level of the neck produces upper motor neuron weakness in one leg. There may be posterior column (position sense) sensory loss in the same leg, and spinothalamic (pain and temperature) sensory loss in the contralateral leg. This is known as dissociated sensory loss, and the whole picture is sometimes referred to as the Brown-Séquard syndrome</p>	
<h2>Tetraparesis or Quadriparesis</h2>	<p>Tetraparesis or Quadriparesis, If the lesion is in the upper cervical cord or brainstem</p> <p>A spinal cord lesion more usually causes upper motor neuron signs in both legs, often asymmetrically since the pathology rarely affects both sides of the spinal cord equally</p>	
<h2>Paraparesis</h2> <p>Only in boys' slides</p>	<p>Paraparesis, if the lesion is at or below the cervical portion of the spinal cord.</p> <p>A spinal cord lesion more usually causes upper motor neuron signs in both legs, often asymmetrically since the pathology rarely affects both sides of the spinal cord equally.</p>	

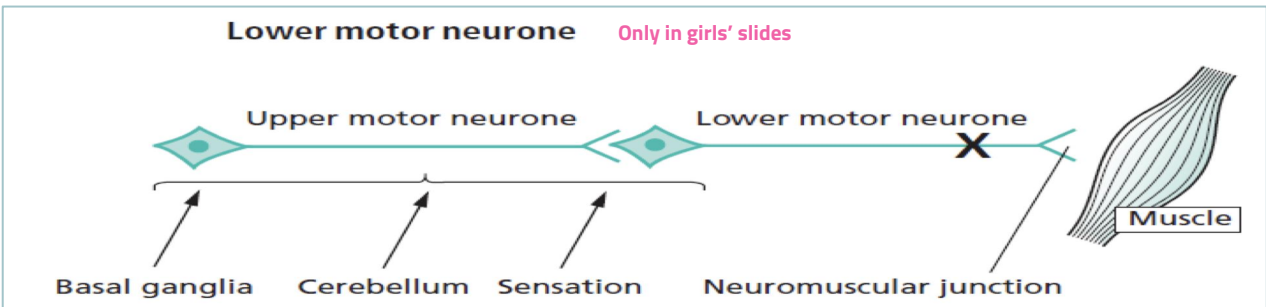


Extra picture for better understanding



LMNL *only in male slides

<p>Generalized LMN Weakness</p>	<p>May result from widespread damage to the axons of LMNs. This is the nature of peripheral neuropathy (polyneuropathy) in diabetes. The axons of the dorsal root sensory neurons are usually simultaneously involved. The LMN weakness and sensory loss tend to be most marked distally in the limbs</p>	
<p>Generalized LMN Weakness</p>	<p>May result from pathology affecting the LMNs throughout the spinal cord and brainstem, as in motor neuron disease or poliomyelitis. Generalized limb weakness (proximal and distal), trunk and bulbar weakness characterize this sort of LMN disorder.</p>	
<p>LMN Weakness of one spinal root</p>	<p>One spinal root or one individual peripheral nerve. The LMN signs are found only in the muscles supplied by the particular nerve root or peripheral. There is sensory impairment in the area supplied by the nerve or nerve root. Examples of such lesions are an S1 nerve root syndrome caused by a prolapsed intervertebral disc, or a common peroneal nerve palsy (neck of the fibula). Median (Carpal tunnel syndrome)) we do scans and NCS</p>	



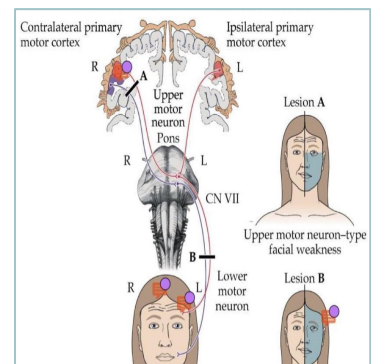
VII Cranial Nerve lesion

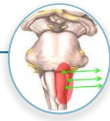
UMN VII Cranial Nerve Lesion

Cause weakness of the lower part of the face on the opposite side. Frontalis is spared: normal furrowing of the brow is preserved; **eye closure and blinking are largely unaffected**. Lower motor neuron (LMN) lesions.

LMN VII Cranial Nerve Lesion

LMN VIIth Cranial Nerve lesion causes weakness (ipsilateral) of all facial expression muscles. The angle of the mouth falls; unilateral dribbling develops. Frowning (frontalis) and eye closure are weak. **Corneal exposure and ulceration** occur if the eye does not close during sleep **called Bell's palsy, most common cause is viral infection**

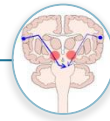




Extra Picture

Bulbar Palsy

- ❖ Bilateral affection of LMN
- ❖ defect of IX-XII cranial nerves or their nuclei in Medulla Oblongata
- ❖ LMN lesion Peripheral Palsy
- ❖ Dysphagia (liquid>solid), nasal regurgitation, slurred speech.
- ❖ Nasal speech, wasted tongue with fasciculation, absent gag reflex.
- ❖ Cause: polyradiculoneuritis (GBS); brainstem lesions, tumors, meningoencephalitis, MND



Extra Picture

Pseudobulbar Palsy (supranuclear)

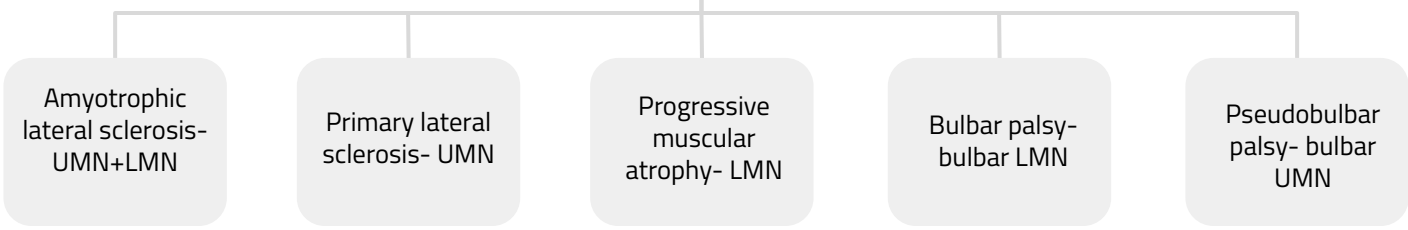
- ❖ Bilateral lesion of corticobulbar tract
- ❖ UMN defect of central palsy IX-XII cranial nerves.
- ❖ Dysphagia, dysarthria, emotional lability (unprovoked crying or laughing).
- ❖ Slow indistinct speech, spastic tongue, brisk jaw jerk (masseter reflex).
- ❖ Frontal release signs.
- ❖ Cause: CVA, arteriosclerosis

Only in girls' slides

Motor Neuron Disease

Selectively affect motor neurons that control voluntary muscle activity.

Types:



Only in girls' slides

Spinal cord

Transverse Myelitis

Upper sensory level for all sensations, LMN signs at the level of lesion, flaccid paralysis (spinal shock)→UMN signs distally, Bladder/Bowel involved

Anterior Spinal Artery Syndrome

Upper sensory level for pain/temperature, sparing of posterior columns, UMN signs distally

Brown-Sequard syndrome

I/L spastic paralysis & loss of joint/position sense, C/L loss of pain/temperature sensation

Bladder Control

Cortical

- ❖ Post-central lesions cause **loss of sense** of bladder fullness.
- ❖ Pre-central lesions cause **difficulty initiating** micturition.
- ❖ Frontal lesions cause **socially inappropriate** micturition

Spinal Cord

- ❖ Bilateral UMN lesions (pyramidal tracts) cause urinary frequency and incontinence. The bladder is small and hypertonic, i.e. sensitive to small changes in intravesical pressure.
- ❖ Frontal lesions can also cause a **hypertonic bladder**.

LMN

Sacral lesions (conus medullaris, sacral root and pelvic nerve- bilateral) cause a **flaccid, atonic bladder** that overflows (cauda equina), often unexpectedly.

Extra & Intramedullary Syndrome

Extramedullary Lesion	Intramedullary Lesion
<p>Extramedullary lesions, radicular pain is often prominent, and there is early sacral sensory loss (lateral spinothalamic tract) and spastic weakness in the legs (corticospinal tract) due to the superficial location of leg fibers in the corticospinal tract.</p> <p>Early UMN signs</p>	<p>Intramedullary lesions tend to produce poorly localized burning pain rather than radicular pain and spare sensation in the perineal and sacral areas ("sacral sparing"), reflecting the laminated configuration of the spinothalamic tract with sacral fibers outermost; corticospinal tract signs appear later.</p> <p>Late UMN signs</p>

Only in girls' slides

SYSTEM	FEATURES	EXTRAMEDULLARY	INTRAMEDULLARY
HISTORY	Onset	Asymmetrical	Symmetrical
	Pain	Local or vertebral (extradural) Radicular (intradural)	Funicular or tract pain
MOTOR	UMN signs	early	late
	LMN signs	segmental	diffuse
SENSORY	Sensory involvement	Ascending (sacral involvement)	Descending (sacral sparing))
	Dissociated sensory loss	absent	present
AUTONOMIC	Sphincter involvement	late	early

Only in the boys' slides

Clinical Feature	Site of Lesion
Ipsilateral LMN paralysis in the segment	Ant Horn cell
Ipsilateral spastic paralysis below the level	UMN Lesion
Ipsilateral band of cutaneous anesthesia	post root damage
Ipsilateral loss of tactile vibratory and proprioceptive sensations below the level	Dorsal Column
Contralateral loss of pain and temperature sensations below the level of the lesion.	Lat Spinothalamic
Contralateral but not complete loss of tactile sensation	Ant Spinothalamic
Ipsilateral Dystaxia	Dorsal Spinocerebellar
Contralateral Dystaxia	Ventral Spinocerebellar
Bilateral Pain & Temp Loss Upper limbs	Ant Commissure
All sensory lost	Dorsal Horn
All motor lost	Ant Horn

Q1: Which of the following cause quadriplegia with good prognosis?

- A. Upper cervical lesion
- B. Lower cervical lesion
- C. Thoracic lesion
- D. Lumbar lesion

Q3: Which one of the following characteristics is for UMN lesion?

- A. Pronounced wasting
- B. NCV is decreased
- C. Flexor or absent plantar response
- D. Tendon reflex is increased

Q5: Tendon reflex in UMN lesion is.....

- A. Brisk/ Increased
- B. Absent
- C. Decreased
- D. Lost

Q2: Which of the following can cause LMN lesion?

- A. Cerebral stroke
- B. Spinal cord transection
- C. Poliomyelitis
- D. Brown sequard syndrome

Q4: Which one of the following is a manifestation of brown sequard syndrome?

- A. Hyperaesthesia at level of lesion
- B. Loss of all reflexes below the level of the lesion
- C. Contralateral loss of pain and temperature below the level of lesion
- D. Loss of dorsal column sensation above the level of lesion

Q6: NCV (Nerve Conduction Velocity) in LMN lesion is.....

- A. Increased
- B. Decreased
- C. Normal
- D. Absent

6: B
5: A
4: C
3: D
2: C
1: B
key:
answer

1- What is the difference between contralateral and ipsilateral hemiparesis?

2- What is the difference between bulbar and pseudobulbar?

3- Compare between UMN lesions and LMN lesions ?

4- Why the contralateral loss of pain and temperature sensation occur two or three segment below the level of lesion ?

A1: - Ipsilateral hemiparesis the face **can not be involved** in the hemiparesis and the vision is normal
- Contralateral hemiparesis weakness of the **whole contralateral side of the face** and visual loss (homonymous hemianopia)

A2: [Slide 10](#)

A3: [Slide 5](#)

A4: Because it crossed obliquely.

Leaders:

- **Abdulaziz Alsuhaim.**
- Ghada Aljedaie.
- Homoud Algadheb.
- Raghad Albarrak.
- Samar Almohammedi.

Organizers:

- **Abeer Awwad**
- Basel Fakeeha.
- Fatimah Saad.
- Hessah Alalyan.
- Majed Alaskar.
- Mayasem Alhazmi.
- Mohamed Alquhidan.
- Sadeem Al Zayed.

Note takers:

- Abeer Awwad.
- **Fahad Alajmi.**
- Hessah Alalyan.
- **Reem Aldosari**
- Shuaa Khdary.

Revisers:

- Abeer Awwad.
- **Saud Alrshed.**
- Teif Almutiri.

MEMBERS:

- Abdulaziz Alrabiah.
- Abdulaziz Alderaywsh.
- Abdulaziz Alamri.
- Abdulaziz Alomar.
- Abdullah Alburikan.
- Abdullah Binjadou.
- Abdullah Alanzan.
- Abdullah Alhumimidi.
- Abdulrahman Almegbel.
- Abdulrahman Barashid.
- Abdulrhman Alsuhaibany.
- Abeer Awwad.
- Ahmad Alkhayatt.
- Aljoharah Albnyan.
- Aljoud Algazlan.
- Almaha Alshathri.
- Arwa Al-Qahtani.
- Bader Alrayes.
- Bassam Alasmari.
- Bushra Alotaibi.

- Faisal Jazzar.
- Feras Alqaidi.
- Ghaida Alassiry.
- Ghaida Alshehri.
- Hamad Almousa.
- Haya Alanazi.
- Hind Almotywea.
- Ibraheem Altamimi.
- **Ibrahim Alnamlah.**
- Joud Alarifi.
- Khalid Altowajjeri.
- Khalid Almutlaq.
- Leen AlMadhyani.
- May Barakah.
- Mohamed Alquhidan.
- Mohammed Alkathiri.
- Murshed Alharby.
- Nada Bin Obied.
- Norah Alsalem.
- Norah Aldakhil.

- Nouf Alsubaie.
- Noura Alshathri.
- Nurah Alqahtani.
- Omar Alhalabi.
- Raed Alnutaifi.
- Rayan Jabaan.
- Reem Alqahtani.
- **Sarah AlQuwayz.**
- Saud Alhasani.
- Shaden Alobaid.
- Shahd Almezel.
- Shatha Aldossary.
- Shayma Alghanoum.
- Tarfah Alkaltham.
- Yara Alasmari.
- Yara Alomar.
- Yara Alzahrani.
- Yazeed Alqahtani.
- ziyad Alhosan.