

بِسْمِ اللَّهِ الرَّحْمَنِ الرَّحِيمِ

# *Liver & Spleen*

*Dr. Sanaa Alshaarawy*

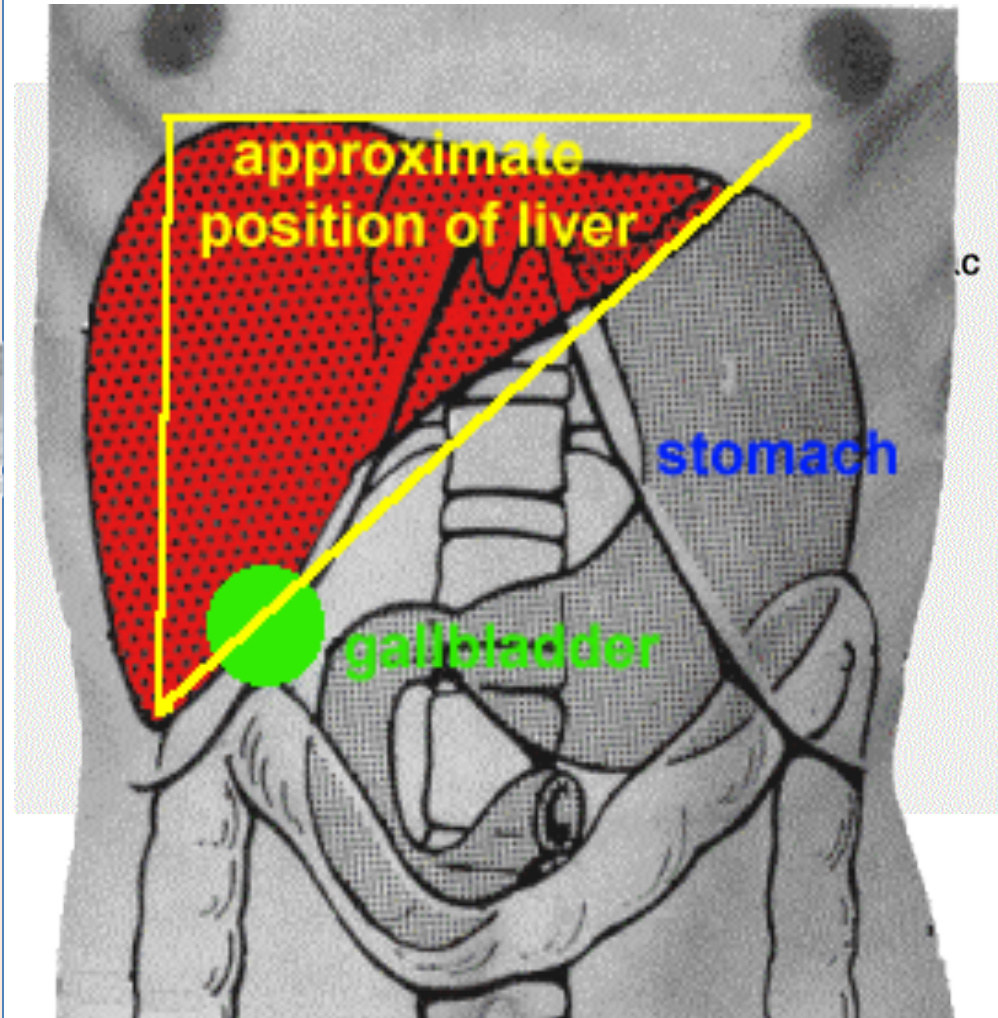
# Objectives

*At the end of the lecture, the student should be able to describe the:*

- Location, subdivisions, relations and peritoneal reflection of liver.
- Blood supply, nerve supply and lymphatic drainage of liver
- Location, subdivisions and relations and peritoneal reflection of spleen.
- Blood supply, nerve supply and lymphatic drainage of spleen.

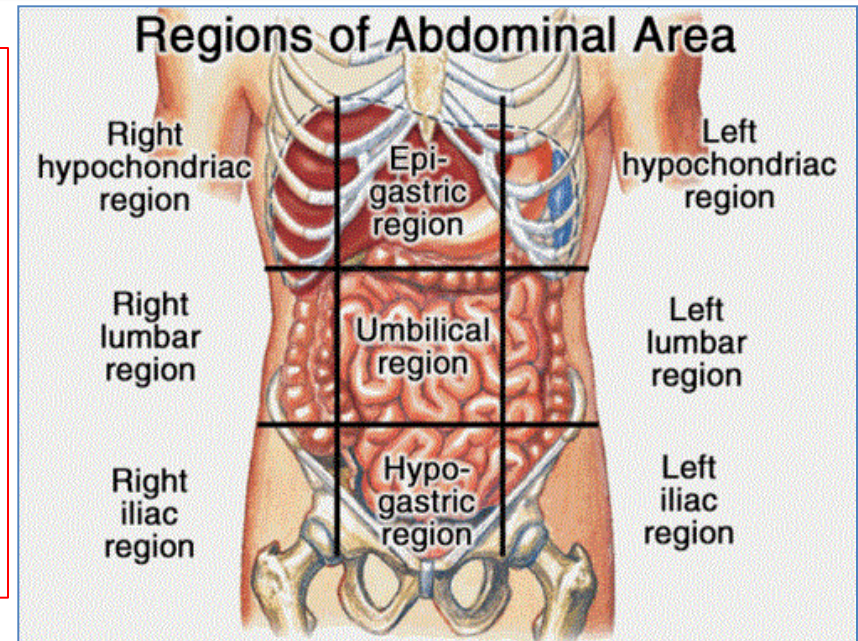
# Liver

- The **largest gland** in the body.
- Weighs approximately 1500 g (approximately 2.5% of adult body weight).
- **Lies mainly** in the **right hypochondrium** and **epigastrium** and extends into the **left hypochondrium**.
- **Protected by** the **thoracic cage** and **diaphragm**, its greater part **lies deep** to ribs 7-11 on the right side and crosses the midline toward the left below the nipple.

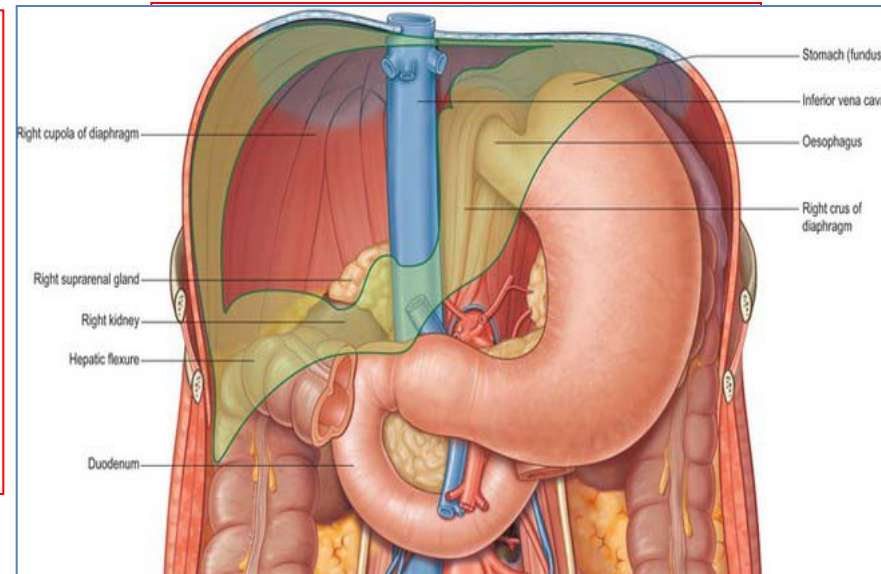


# Relations of Liver

- **Anterior:** Diaphragm, **right & left pleura** and **lower margins of both lungs**, **right and left costal margins**, **xiphoid process**, and **anterior abdominal wall** in the subcostal angle

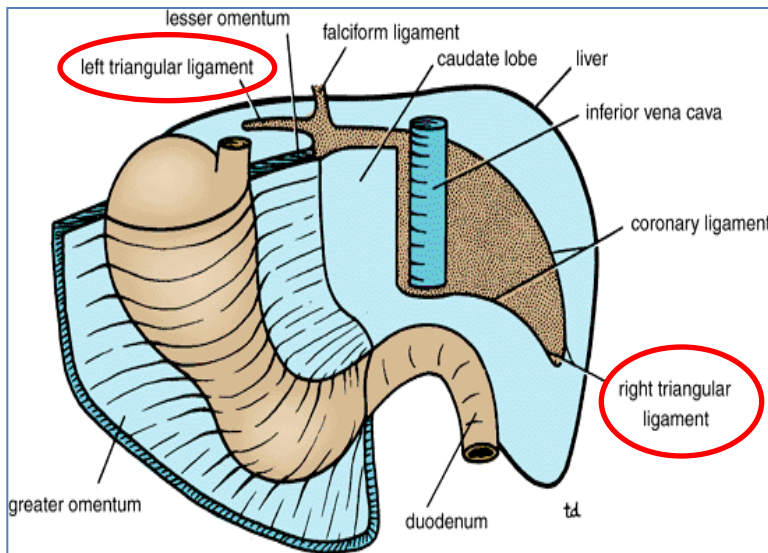
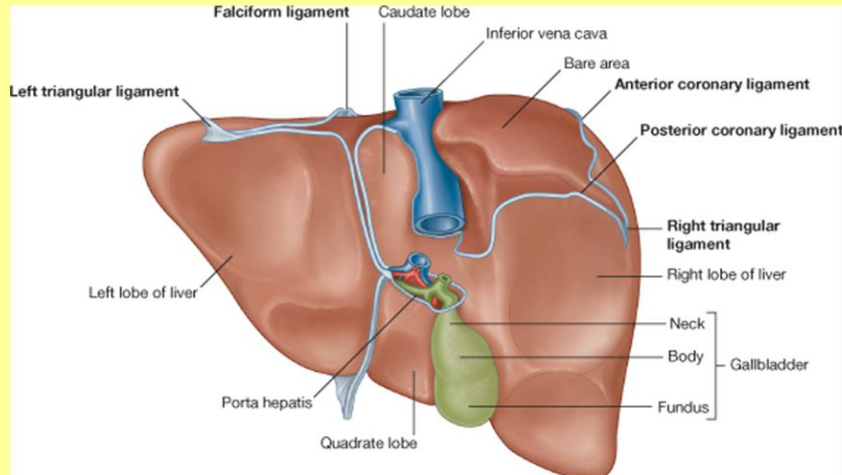


- **Posterior:** Diaphragm, **right kidney**, **hepatic flexure of the colon**, **/duodenum**, **gallbladder**, **inferior vena cava**, **esophagus** and **fundus of the stomach**



# Peritoneal Reflection

## POSTERIOR SURFACE OF LIVER

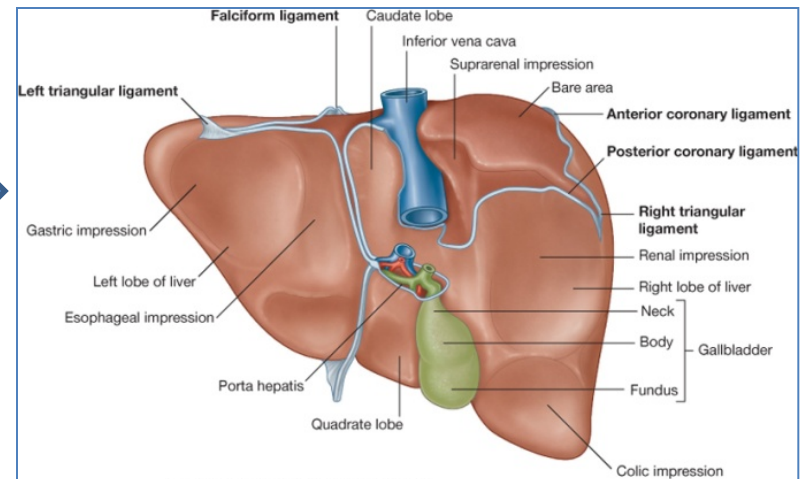
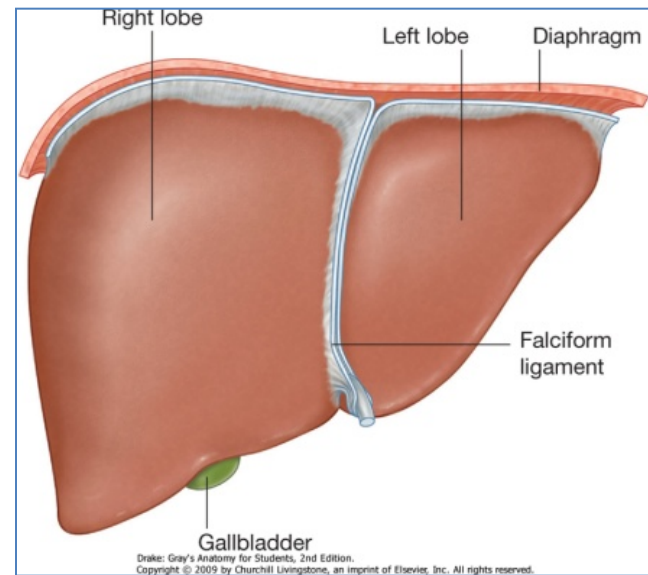


- The liver is surrounded by a fibrous capsule and **completely covered by peritoneum (except the bare areas)**.
- The **bare area** of the liver is **triangular area on the posterior surface of right lobe** where there is **no intervening peritoneum** between the **liver** and the **diaphragm**.
- **Boundaries of Bare area:**
  - **Anterior:** superior layer of coronary ligament.
  - **Posterior:** inferior layer of coronary ligament.
  - **Laterally:** right and left triangular ligaments.

**Other bare areas include : porta hepatis; fossa for gall bladder & grooves for IVC**

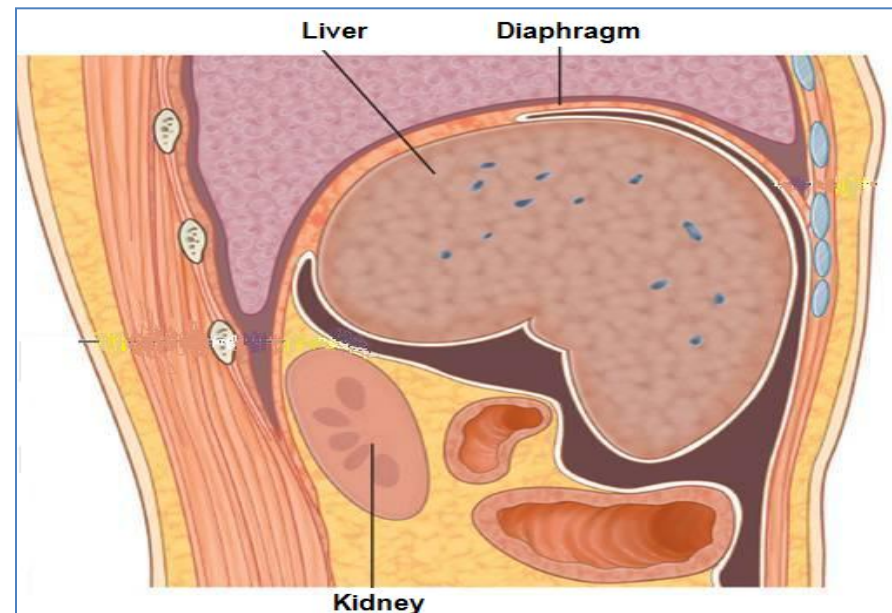
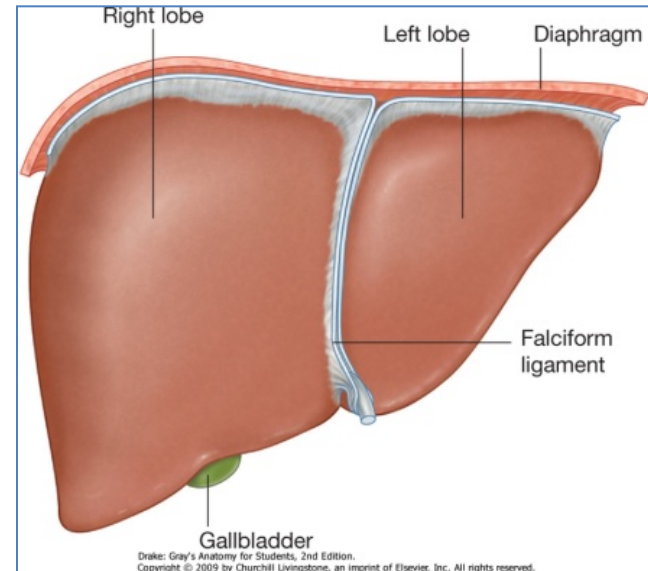
# Surfaces of Liver

- The liver has two surfaces:
  - A **convex** diaphragmatic surface (Antero-superior).
  - A relatively flat or even **concave** visceral surface (postero-inferior)



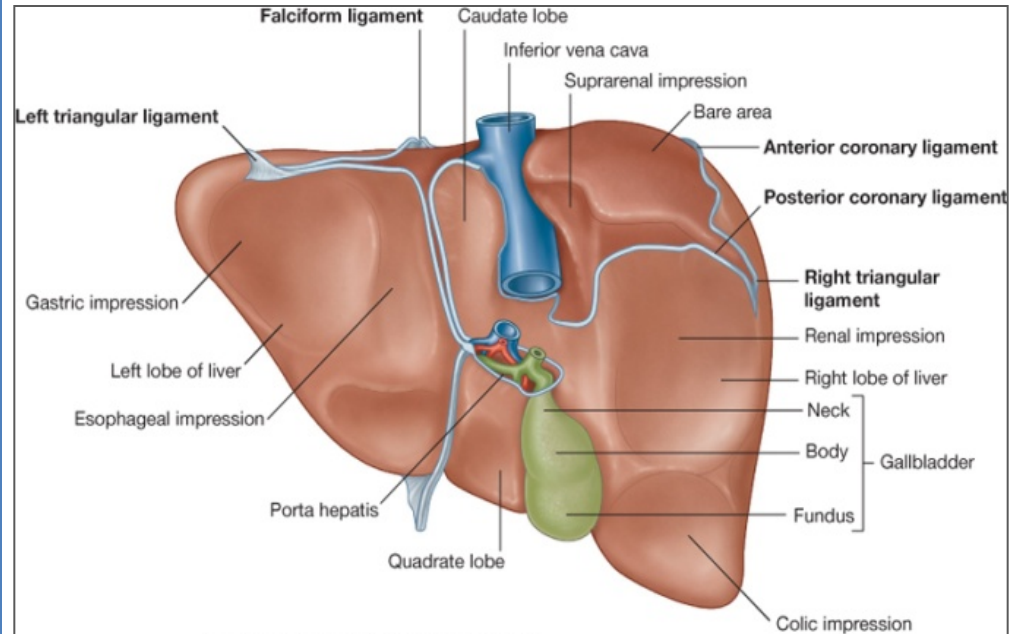
# Diaphragmatic Surface

- **The convex upper surface** is **smooth** and **molded to the undersurface** of the domes of the **diaphragm** which **separates it from the pleurae, lungs, pericardium, and heart** .
- **Covered with visceral peritoneum,**
- **Except posteriorly in the bare area of the liver,** where it lies in direct contact with the diaphragm.



# Visceral Surface

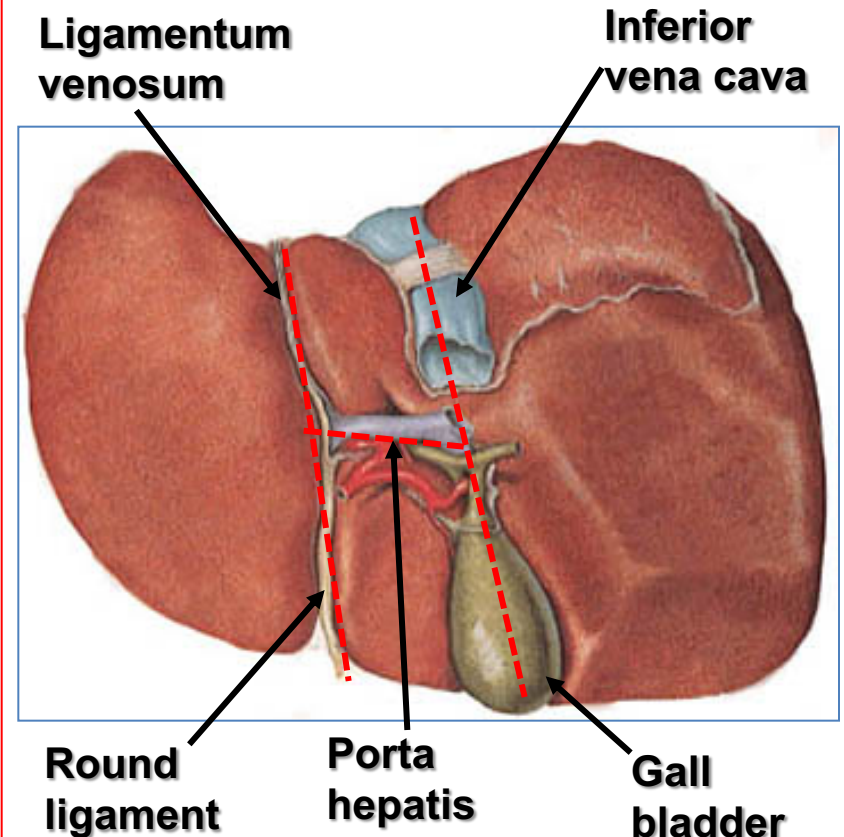
- It is the **posteroinferior surface**, related to **abdominal viscera**.
- It is covered with **peritoneum**, except at **the fossa** for the **gallbladder**, the **porta hepatis** and **IVC groove**.
- It bears multiple **fissures** and **impressions** for contact with other organs.





# Fissures of the Liver

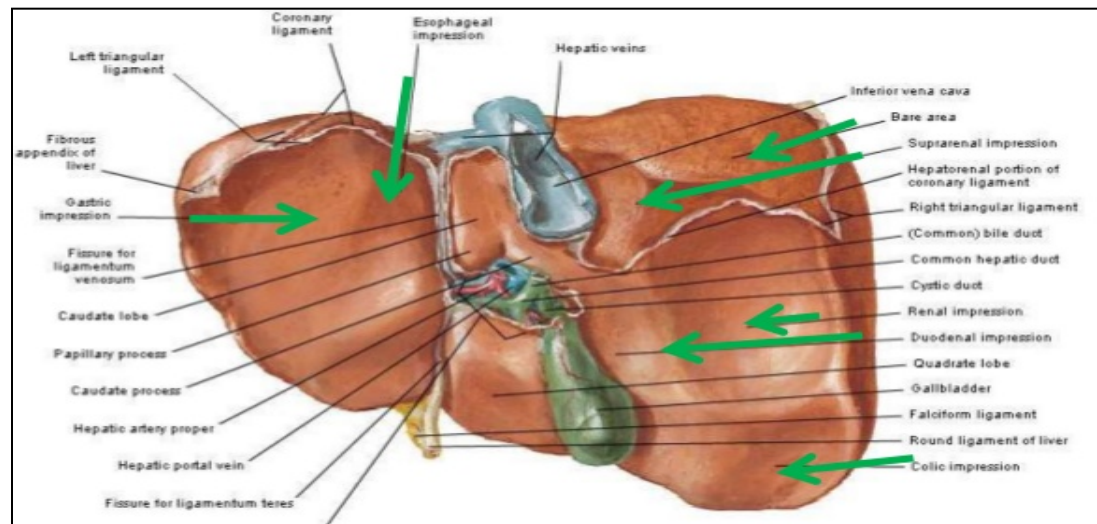
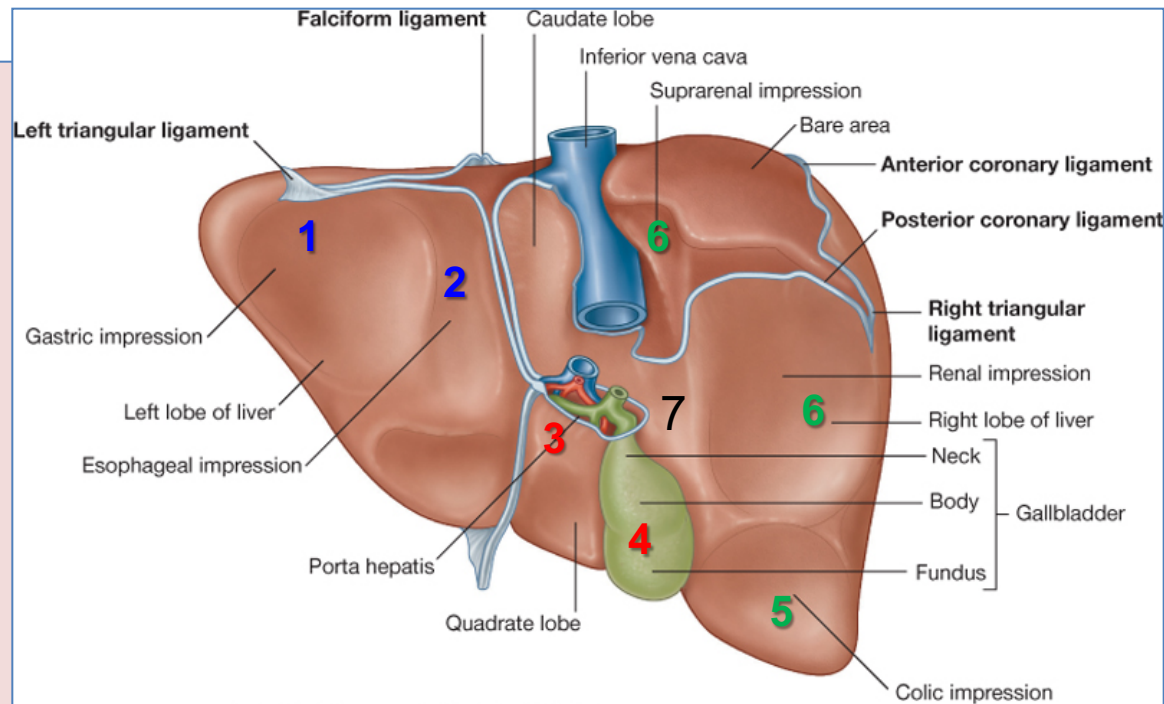
- **Two sagittally oriented fissures, linked centrally by the transverse porta hepatis, form the letter H on the visceral surface.**
- The **left fissure** is the continuous groove formed:
  - **Anteriorly** by the **fissure** for the **round ligament (lig.teres).**
  - **Posteriorly** by the **fissure** for the **ligamentum venosum.**
- The **right fissure** is the continuous groove formed:
  - **Anteriorly** by the **fossa** for the **gallbladder**
  - **Posteriorly** by the **groove** for the **inferior vena cava.**



# Relations of Visceral Surface of the Liver

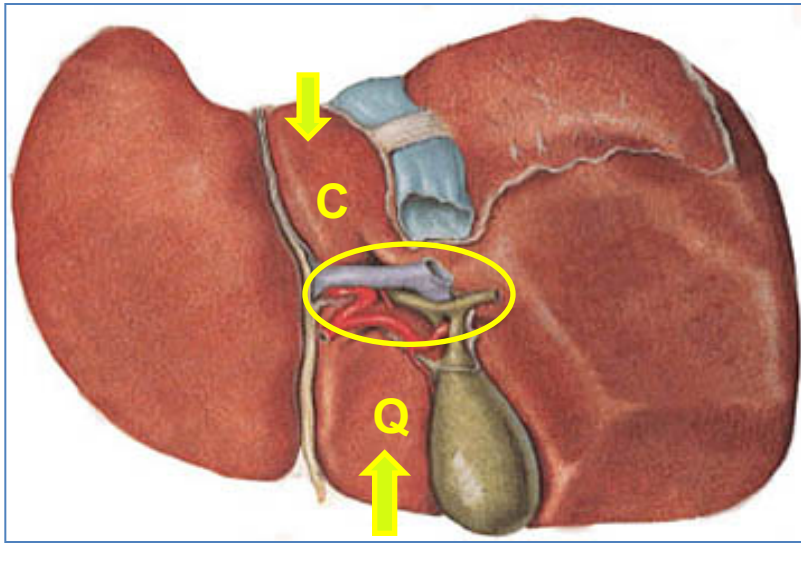
The visceral surface is related to the:

1. Stomach.
2. Esophagus
3. lesser omentum
4. gallbladder
5. right colic flexure
6. right kidney and right suprarenal gland.
7. Duodenum.



# Porta Hepatis (Hilum of the Liver)

- A transverse fissure found on the **posteroinferior surface** and lies between the **caudate** and **quadrate** lobes.
- The upper part of the the **lesser omentum** is attached to its margins.



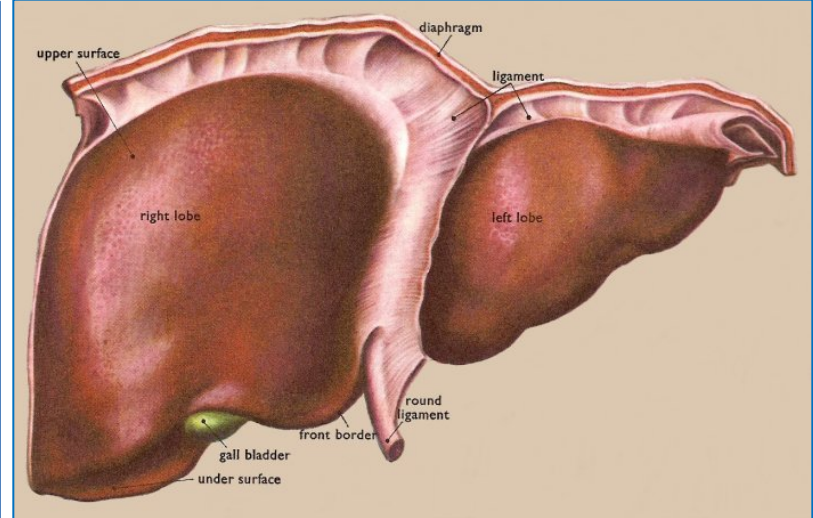
## Structures passing through the porta hepatis include:

- Right and left **hepatic ducts**.
- Right and left branches of the **hepatic artery**
- Right and left branches of the **portal vein**
- Sympathetic and parasympathetic **nerve fibers**
- A few **hepatic lymph nodes** lie here; they drain the liver and gallbladder and send their efferent vessels to the **celiac lymph nodes**.

# Ligaments of the Liver

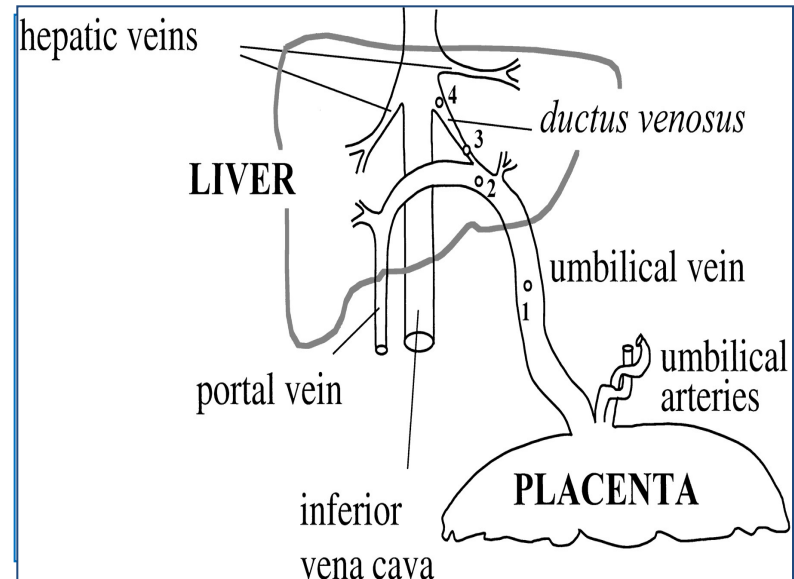
## Falciform ligament

- It is a two-layered fold of the peritoneum.
- **It connects** the liver with the **diaphragm** and **anterior abdominal wall & umbilicus..**
- Its sickle-shaped free margin contains the **ligamentum teres** (**round Ligament**) of liver, the remains of the umbilical vein (obliterated umbilical vein), which carried oxygenated blood from the placenta to the fetus.



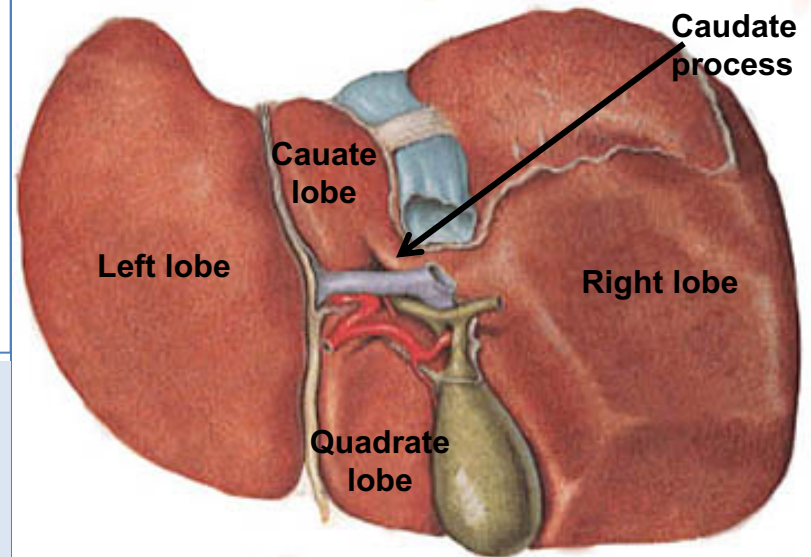
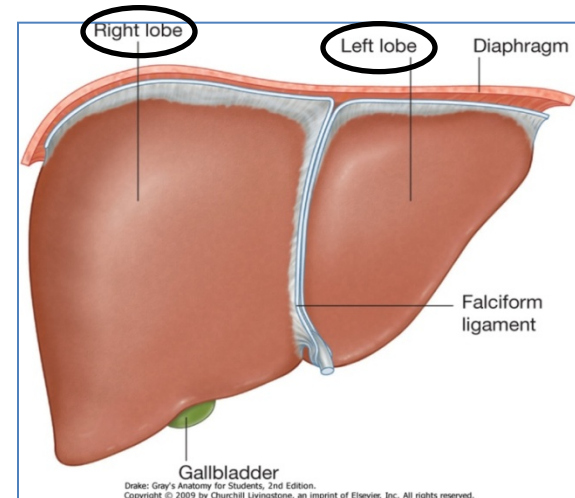
## Ligamentum venosum

It is the fibrous remnant of the fetal ductus venosus (obliterated ductus venosus), which shunted blood from the umbilical vein to the left branch of portal vein to the IVC.



# Lobes of The Liver

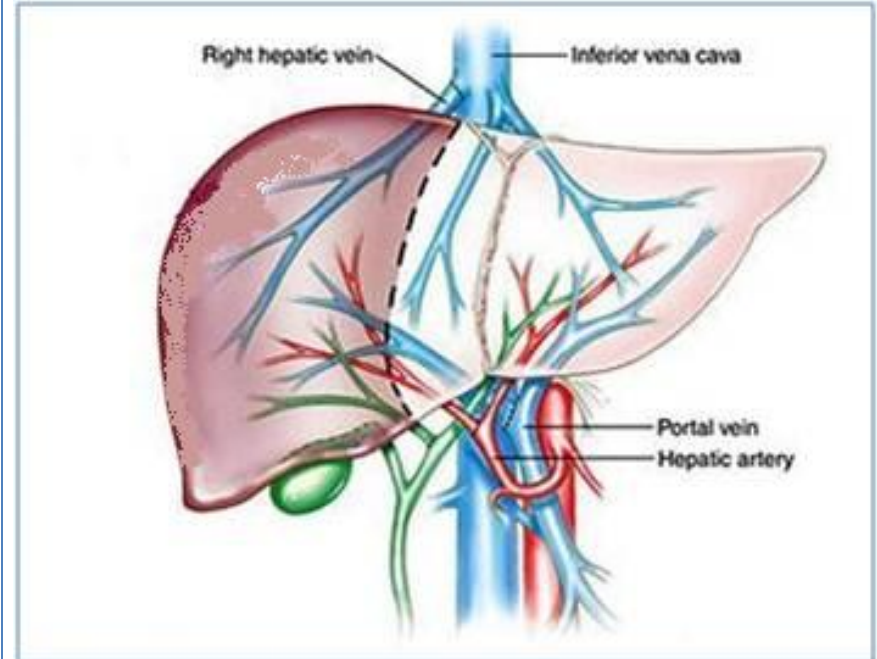
- The liver is divided into a large **right lobe** and a small **left lobe** by the attachment of the **falciform ligament**.
- The **right lobe** is further divided into a **quadrate lobe** and a **caudate lobe** by the presence of the **gallbladder**, the **fissure for the ligamentum teres**, the **inferior vena cava**, and the **fissure for the ligamentum venosum**.
- **The caudate lobe** is connected to the right lobe by the **caudate process**.
- The **Quadrate and caudate lobes** are a functional part of the **left lobe of the liver**.



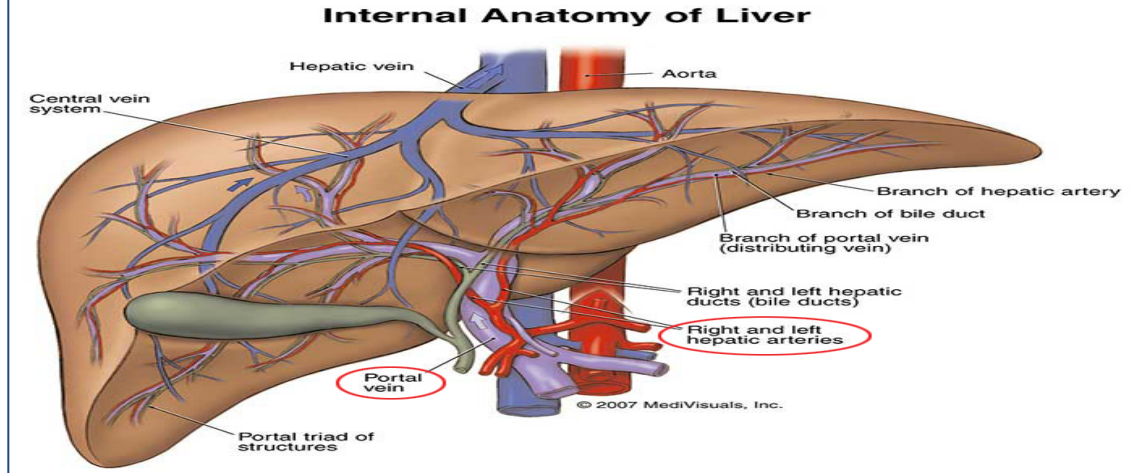
The **functional anatomy** divides the liver into left and right lobes **based on** their relation to the division of common **hepatic duct**, **hepatic portal vein**, and **hepatic artery proper** into right & left branches, so the areas of the liver supplied by these branches constitute the functional left or right lobes.

# Blood Circulation through the Liver

- The blood vessels **conveying** blood to the liver are the **hepatic artery (30%)** a branch of celiac trunk, and **portal vein (70%)**.
- The **hepatic artery** brings **oxygenated blood** to the liver
- The **portal vein** brings venous blood rich in the products of digestion, which have been **absorbed from** the **gastrointestinal tract** to the **liver**.



The **venous blood** is drained **by** right & left **hepatic veins** **into** the **inferior vena cava**



- At or close to the **porta hepatis**, the **hepatic artery** and **portal vein** terminate by dividing into right and left **primary branches** which supply the **right** and **left** parts of liver, respectively.
- **Within the liver**, the primary branches divide to give **secondary** and **tertiary** to supply the **hepatic segments** independently.

- The **hepatic veins**, are **intersegmental** in their **distribution and function**, draining parts of adjacent segments.
- The attachment of these veins to the IVC helps hold the liver in position. (*The **peritoneal ligaments** and the tone of the **abdominal muscles** play a **minor role** in the **support of liver***).<sup>15</sup>

## Lymph Drainage

- The **liver produces** a **large amount** of **lymph**—about one third to one half of all body lymph.
- The **lymph vessels** leave the liver and **enter** several **lymph nodes** in the **porta hepatis**.
- The **efferent vessels** pass to the **celiac nodes**.
- **A few vessels pass** from the **bare area of the liver** through the diaphragm to the **posterior mediastinal lymph nodes**.

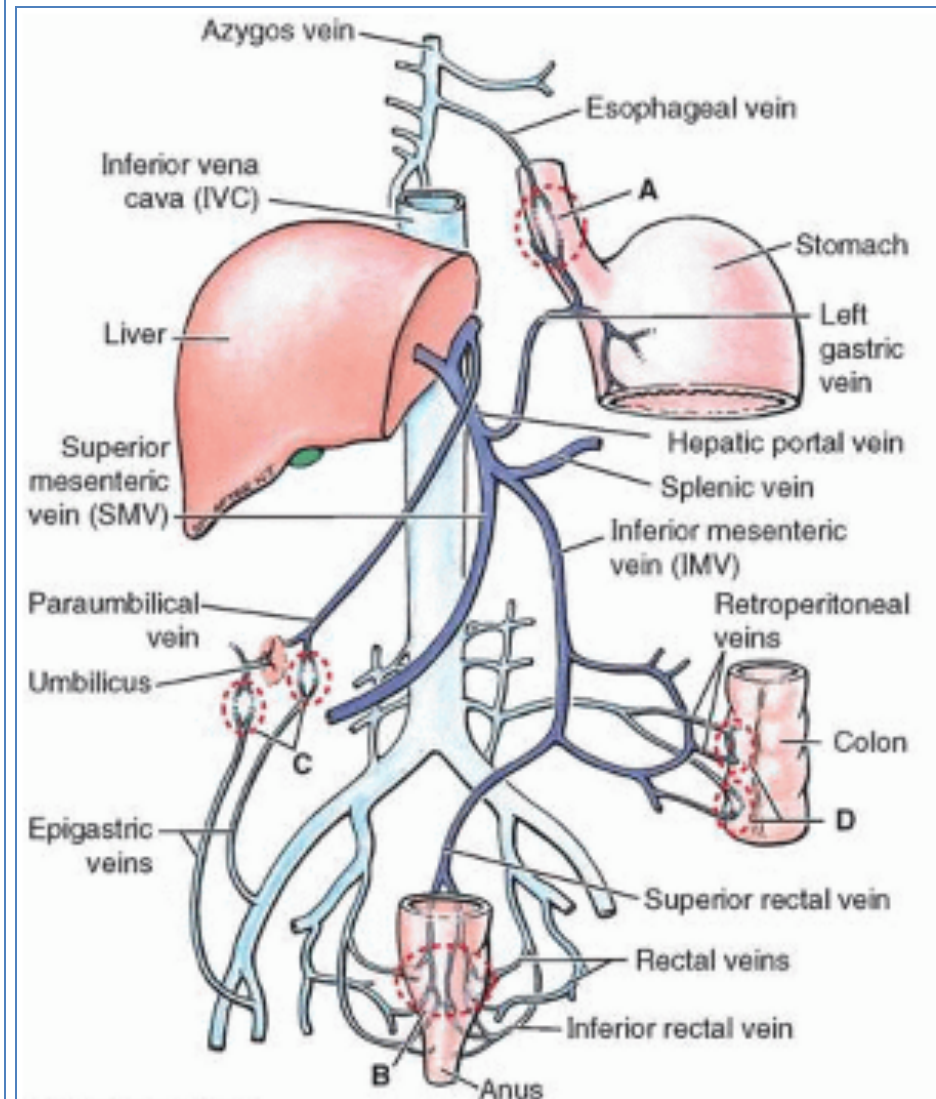
## Nerve Supply

- **Sympathetic** and **parasympathetic nerves**.
- **Sympathetic** from the **celiac plexus**.
- **Parasympathetic nerves** The **anterior vagal trunk** gives rise to a **large hepatic branch**, which passes **directly to the liver**.



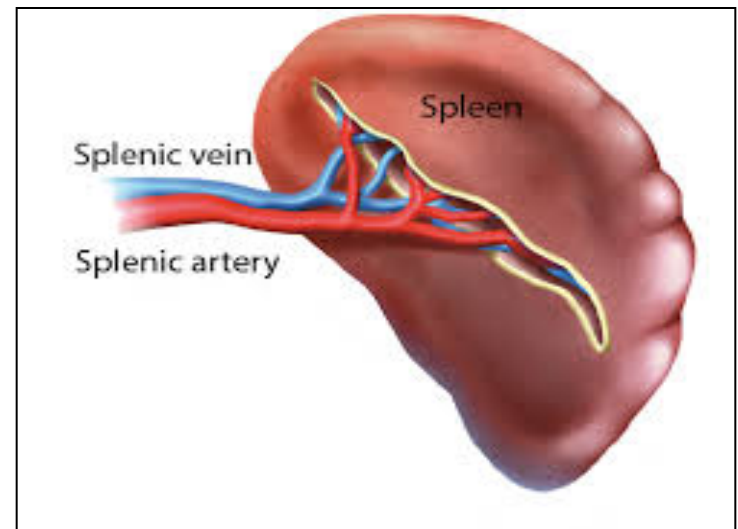
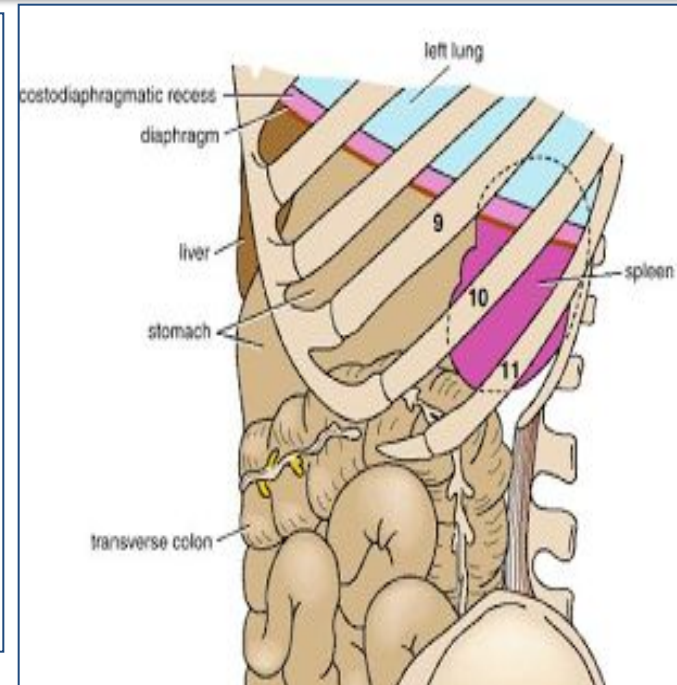
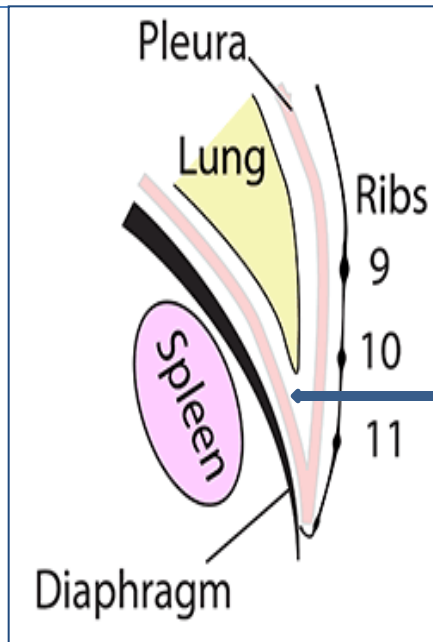
# Portal-Systemic (Portacaval) Anastomoses

- It is a **specific type of anastomosis** that occurs **between the veins** of **portal** circulation and those of **systemic** circulation
- **In portal hypertion**, these anastomosis open and form **venous dilatation** called **varices**.
- **Sites:**
  - A. Lower part of Esophagus (Varices)**
  - B. Upper Anal canal (Hemorrhoids)**
  - C. Paraumbilical region (Caput Medusae)**
  - D. Retroperitoneal (Asymptomatic)**
  - E. Intrahepatic (Patent ductus venosus).**

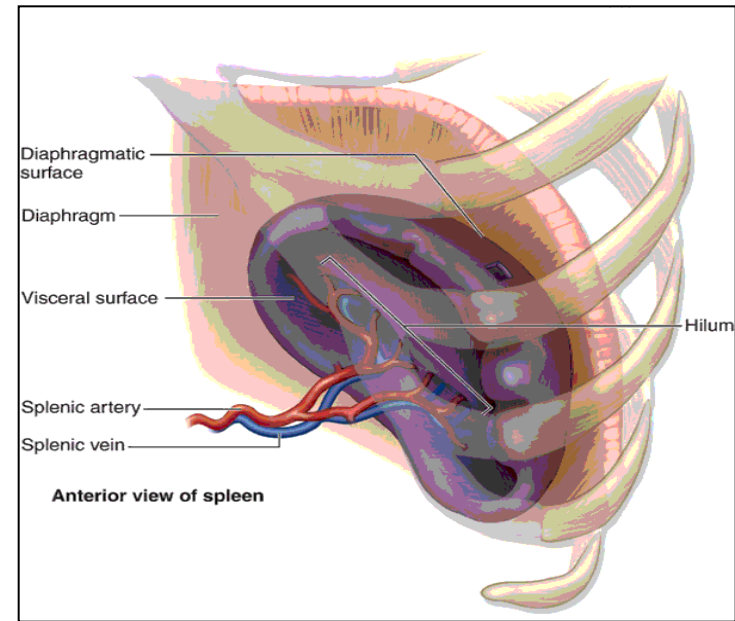


# Spleen

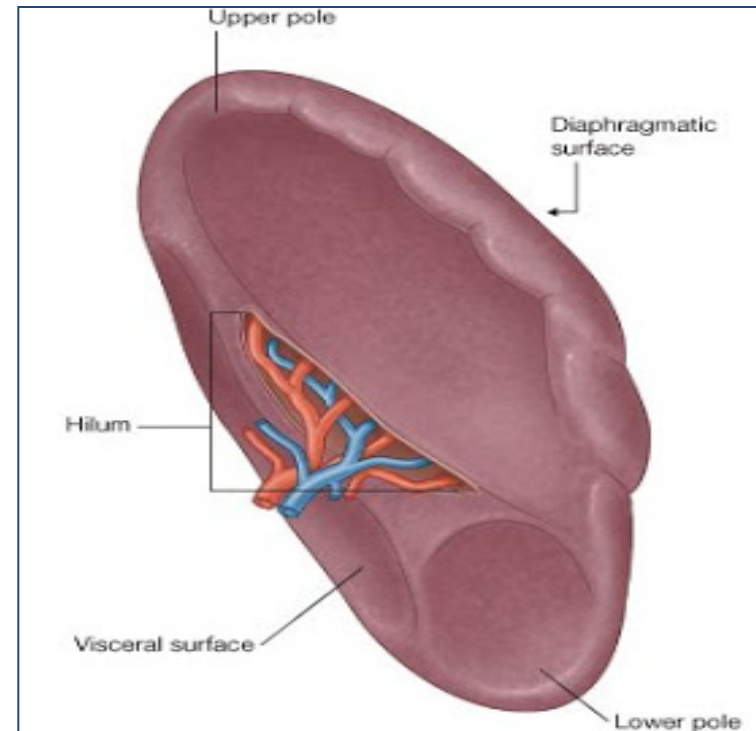
- Largest single mass of **lymphoid tissue**
- **Located in** the **left hypochondrium**, **deep to 9, 10 & 11 ribs**
- **Its Long axis lies** along **10<sup>th</sup> rib**.
- It is **separated from the ribs** by the **diaphragm** and the **costodiaphragmatic recess** (space in pleural cavity).
- Ovoid in shape with **notched anterior border**
- **Lower pole** extends forward as far as the **midaxillary line**.
- **Normal size spleen can not be palpated on clinical examination.** (A healthy spleen is not palpable).



- **Surfaces:**
- **Diaphragmatic surface:** is **convexly curved** to fit the concavity of the **diaphragm** and **curved bodies** of the adjacent **ribs**
- **Visceral surface:** related to viscera.

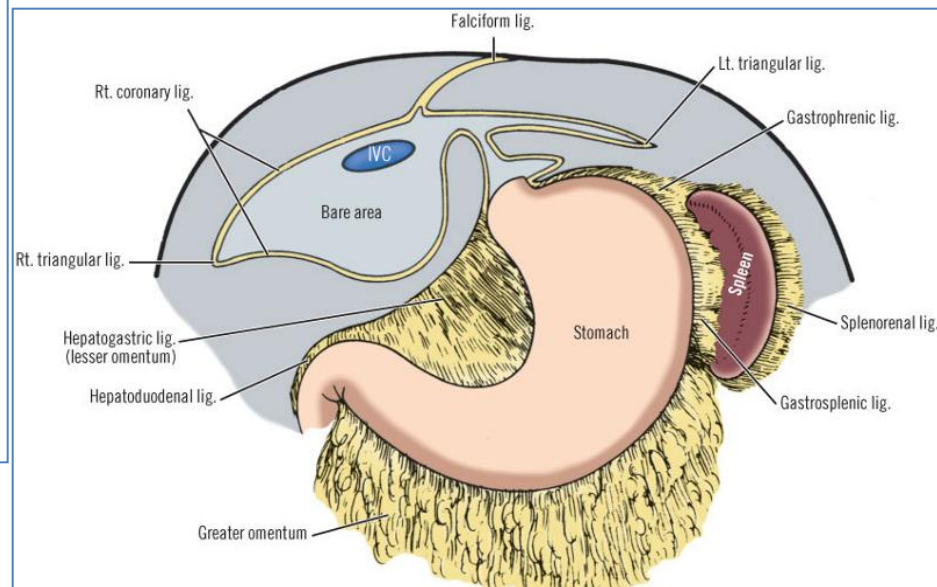
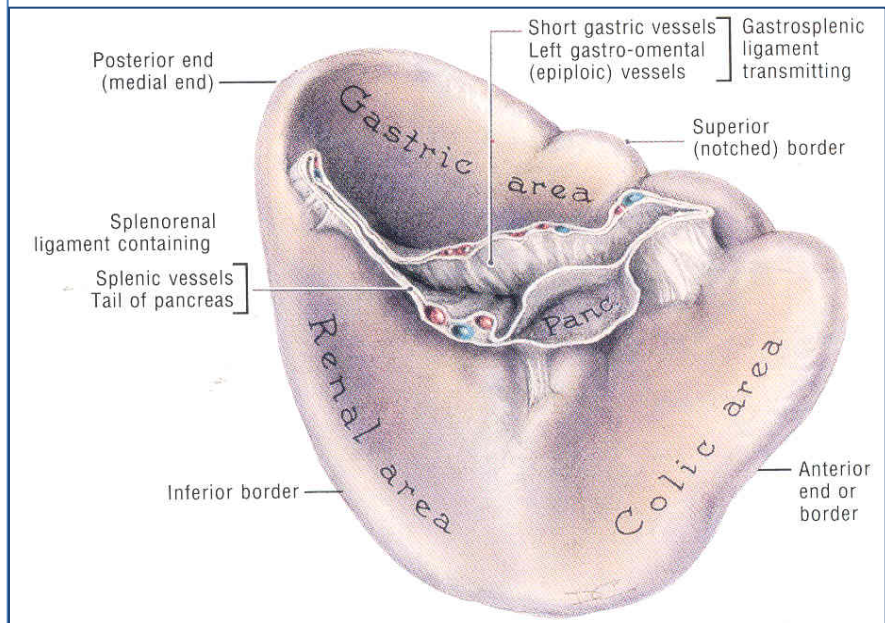


- **Borders:**
- The **superior and anterior** borders are **sharp**. **Anterior border** is **notched**.
- The **posterior** (medial) and **inferior** borders are **rounded**.



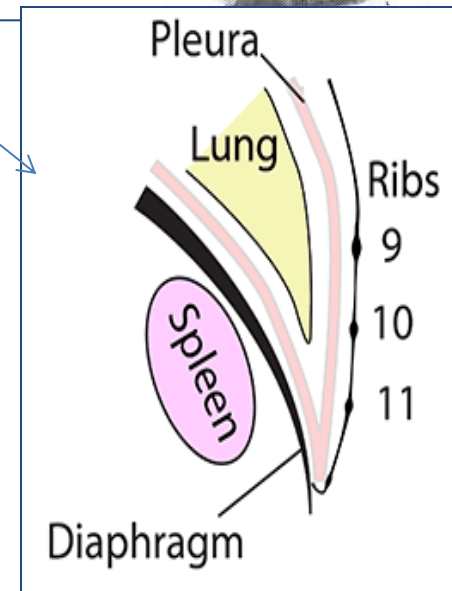
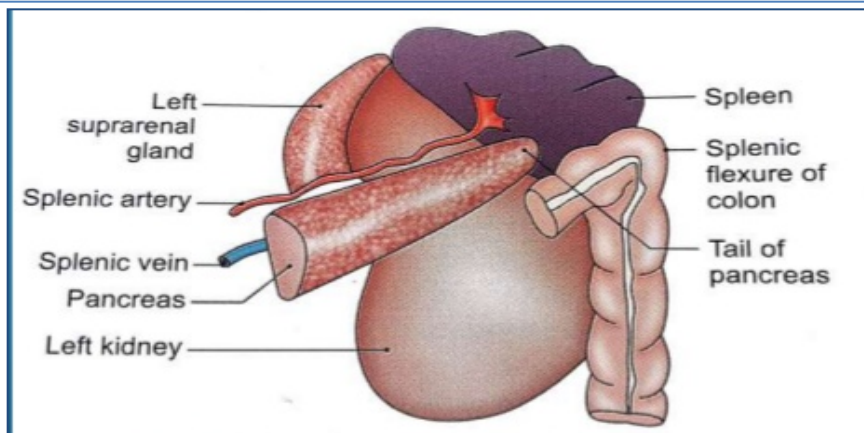
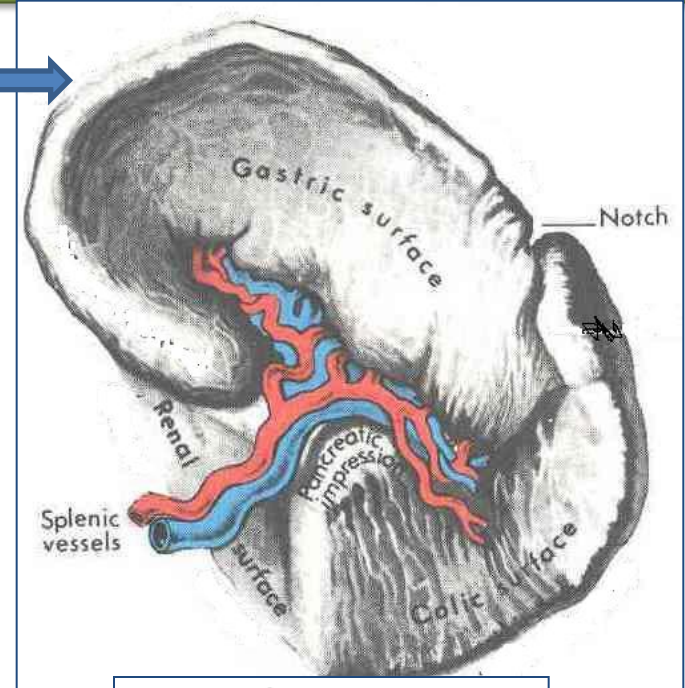
# Peritoneal Reflections/Ligaments

- Spleen is **completely** surrounded by **peritoneum** **EXCEPT** at the **hilum** where **its margins** give attachment to :
  - **Gastrosplenic ligament** to the **greater curvature of stomach** (carrying the **short gastric and left gastroepiploic vessels**)
  - **Lienorenal (splenorenal) ligament** to the **left kidney** (carrying the **splenic vessels and the tail of pancreas**)



# Relations

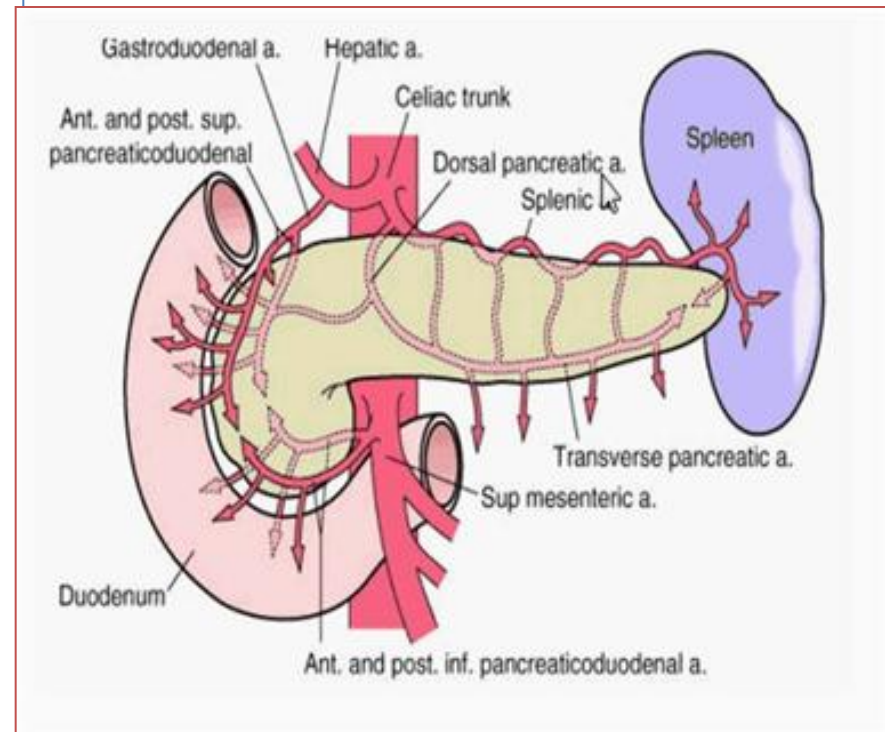
- **Anteriorly:** Stomach, tail of pancreas, left colic flexure & left kidney
- **Posteriorly:** Diaphragm, that separates it from the left pleura (**left costo-diaphragmatic recess**), **left lung** & **9, 10 & 11 ribs.**
- **Inferiorly:** Left colic flexure.
- **Medially:** Left kidney.



# Arterial Supply

## Splenic artery

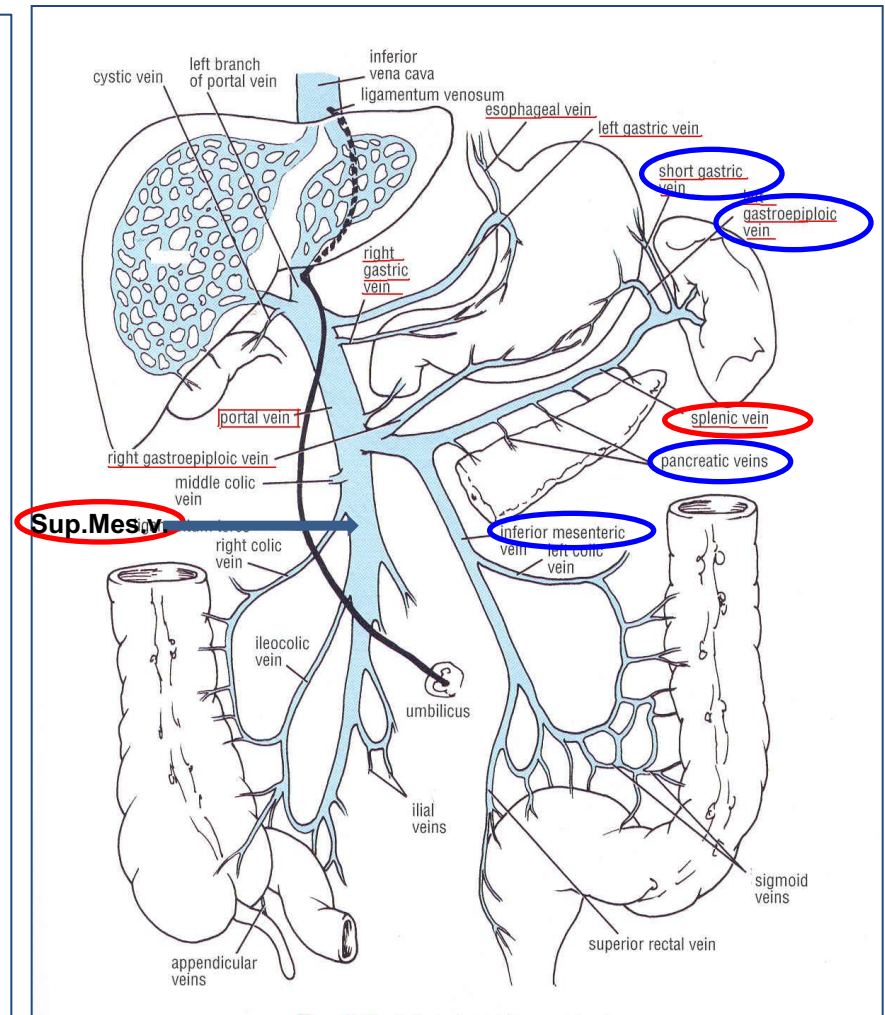
- Largest branch of the **celiac artery**
- Runs a **tortuous course** along the **upper border of the pancreas**
- **Passes within the lienorenal ligament**
- Divides into **4-5 terminal branches**, which enter the spleen **at the hilus**
- **The lack of anastomosis** of these **arterial vessels** within the spleen **results in** the formation of **vascular segments of the spleen** with relatively avascular planes between them, **enabling subtotal splenectomy.**



# Venous Drainage

## Splenic vein

- Leaves the hilus
- Runs behind the tail & body of the pancreas
- Reaches behind the neck of pancreas, where it joins the superior mesenteric vein to form the portal vein
- Tributaries:
  - Short gastric vein
  - left gastroepiploic vein
  - Pancreatic veins
  - Inferior mesenteric vein



## Lymph Drainage

- **Lymphatics** emerge from the hilus and drain into several nodes lying at the **hilum**
- **Efferents** from the hilar nodes **pass along** the course of **splenic artery**, and drain into the **celiac lymph nodes**

## Nerve Supply

- Derived from the **celiac plexus** (Innervation is purely sympathetic).
- Are **distributed mainly along** branches of the **splenic artery**, and are **vasomotor in function**.



**Thank You**