



GIT BLOCK

PATHOLOGY PRACTICAL

Prepared by:

- *Prof. Ammar Al Rikabi*
- *Dr. Sayed Al Esawy*

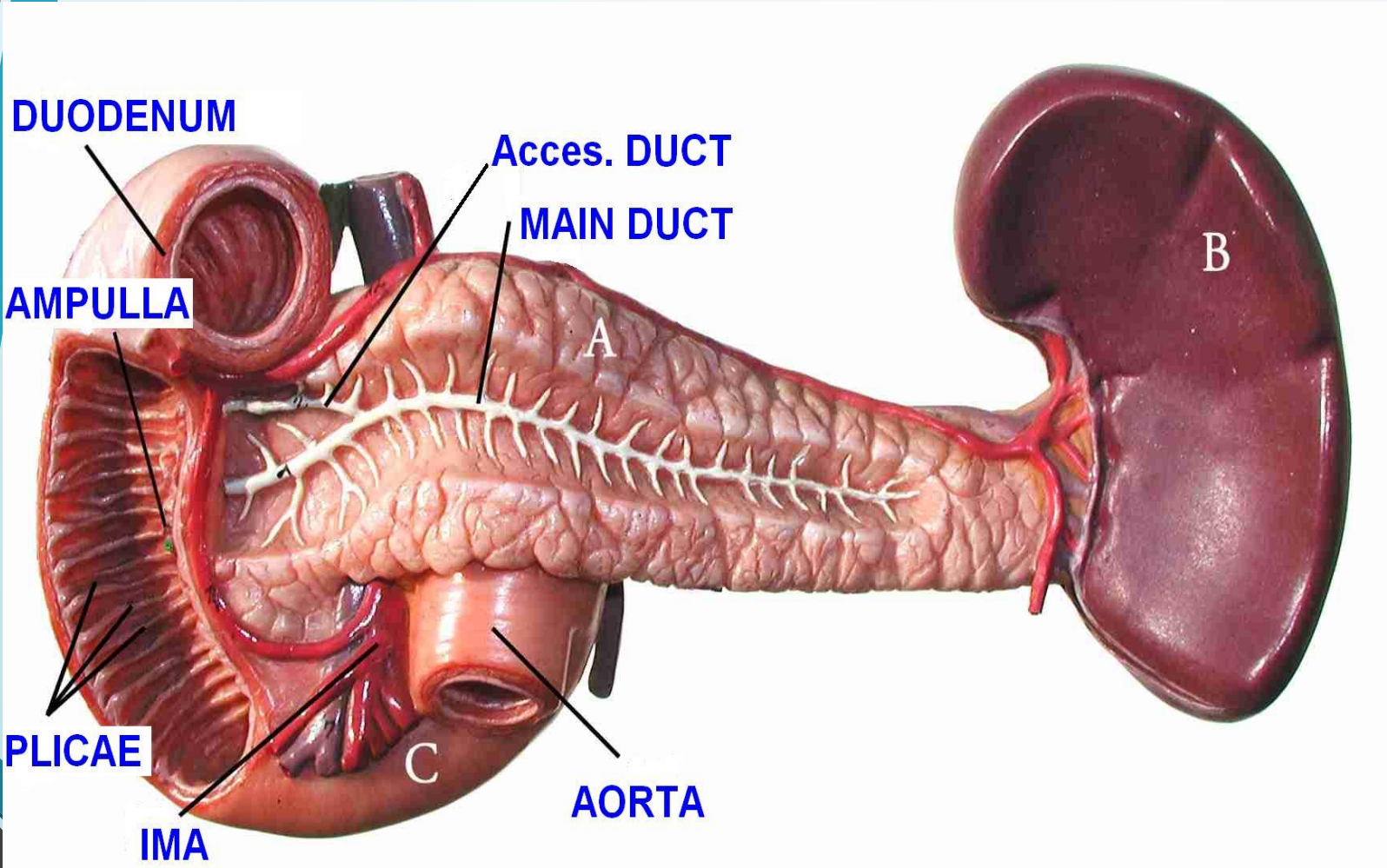
Head of Pathology Department: Dr. Hisham Al Khalidi

PANCREAS

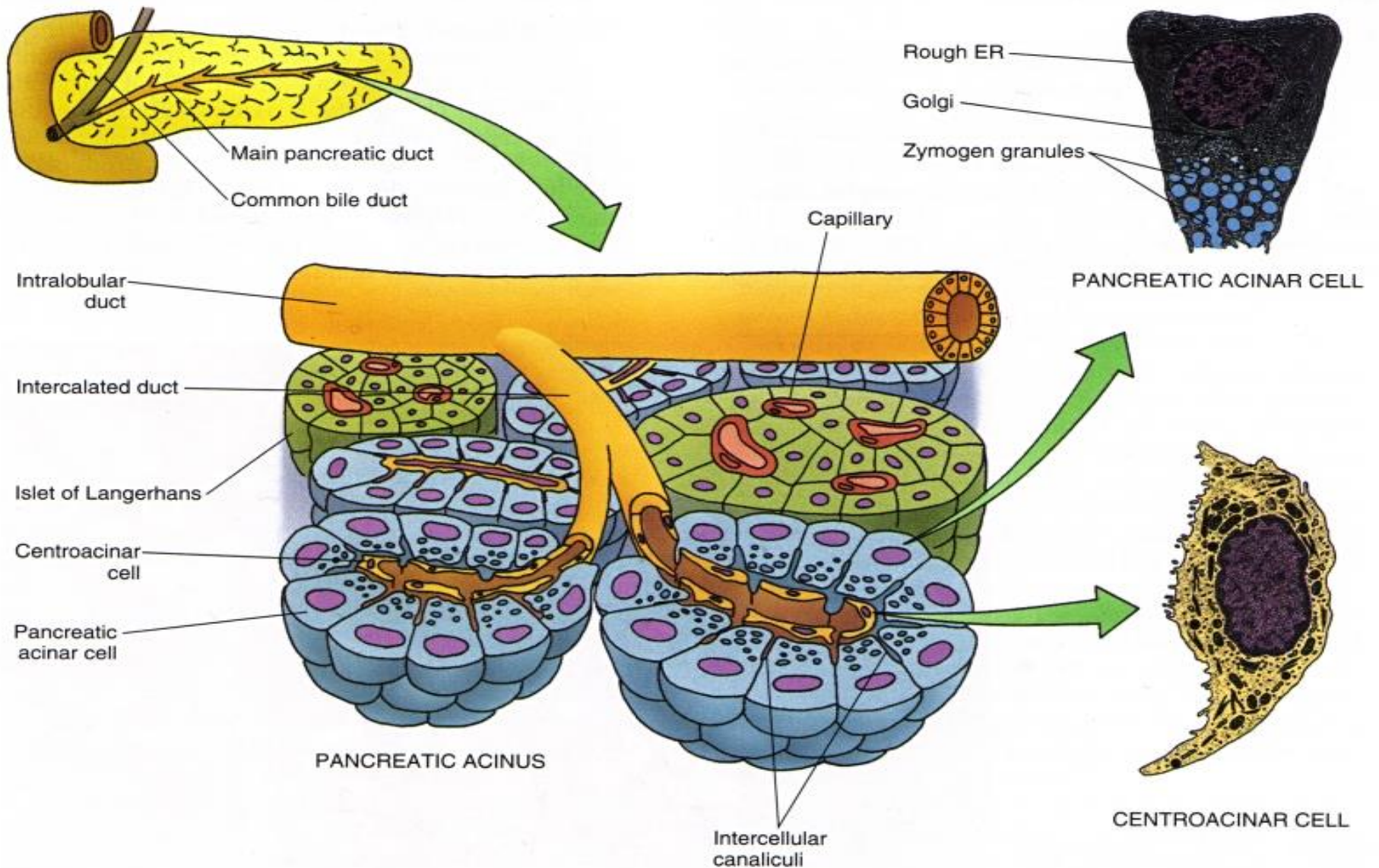


Normal anatomy & histology

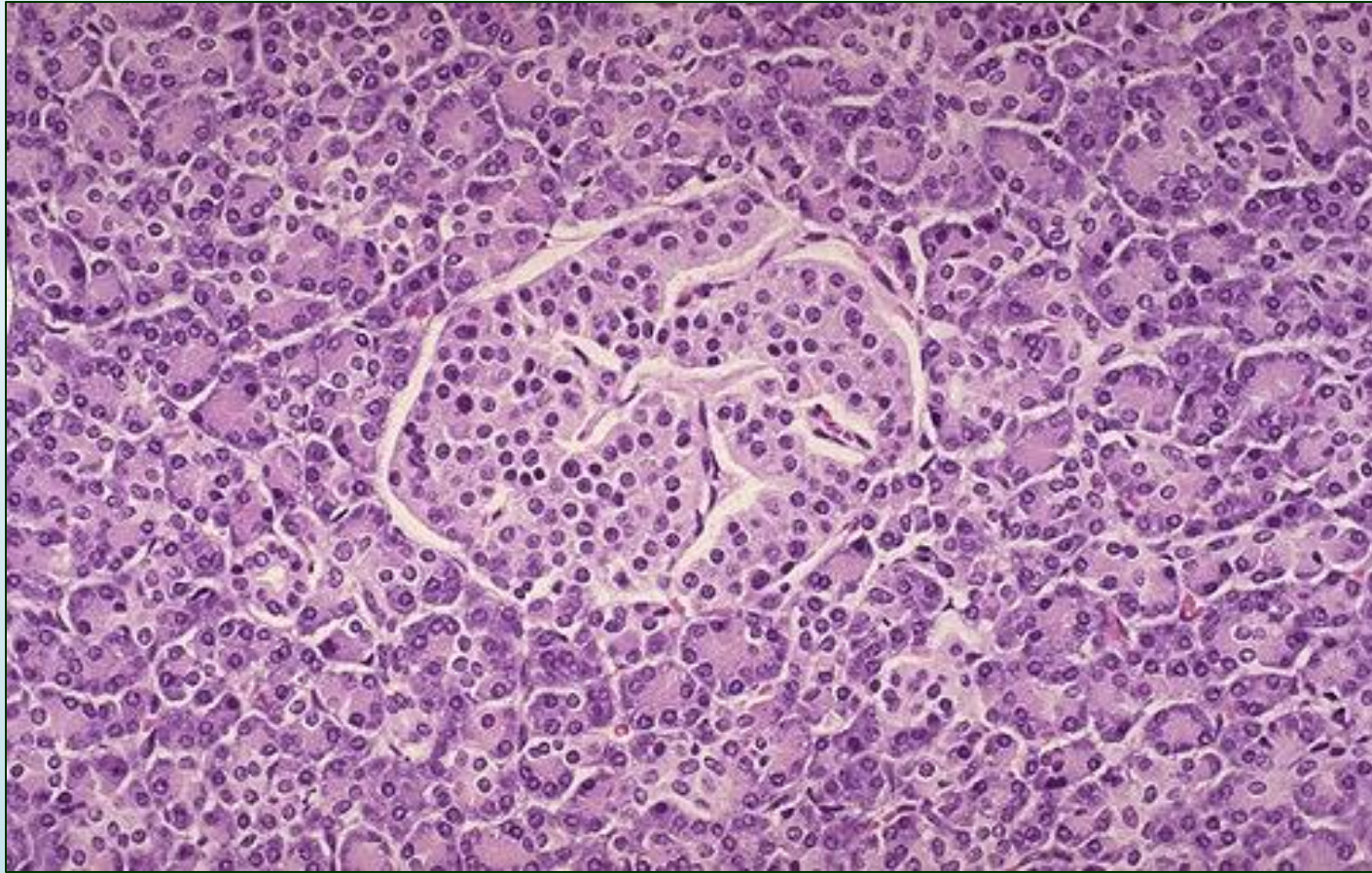
PANCREAS – Normal Anatomy



PANCREAS – Normal Histology (Diagram)

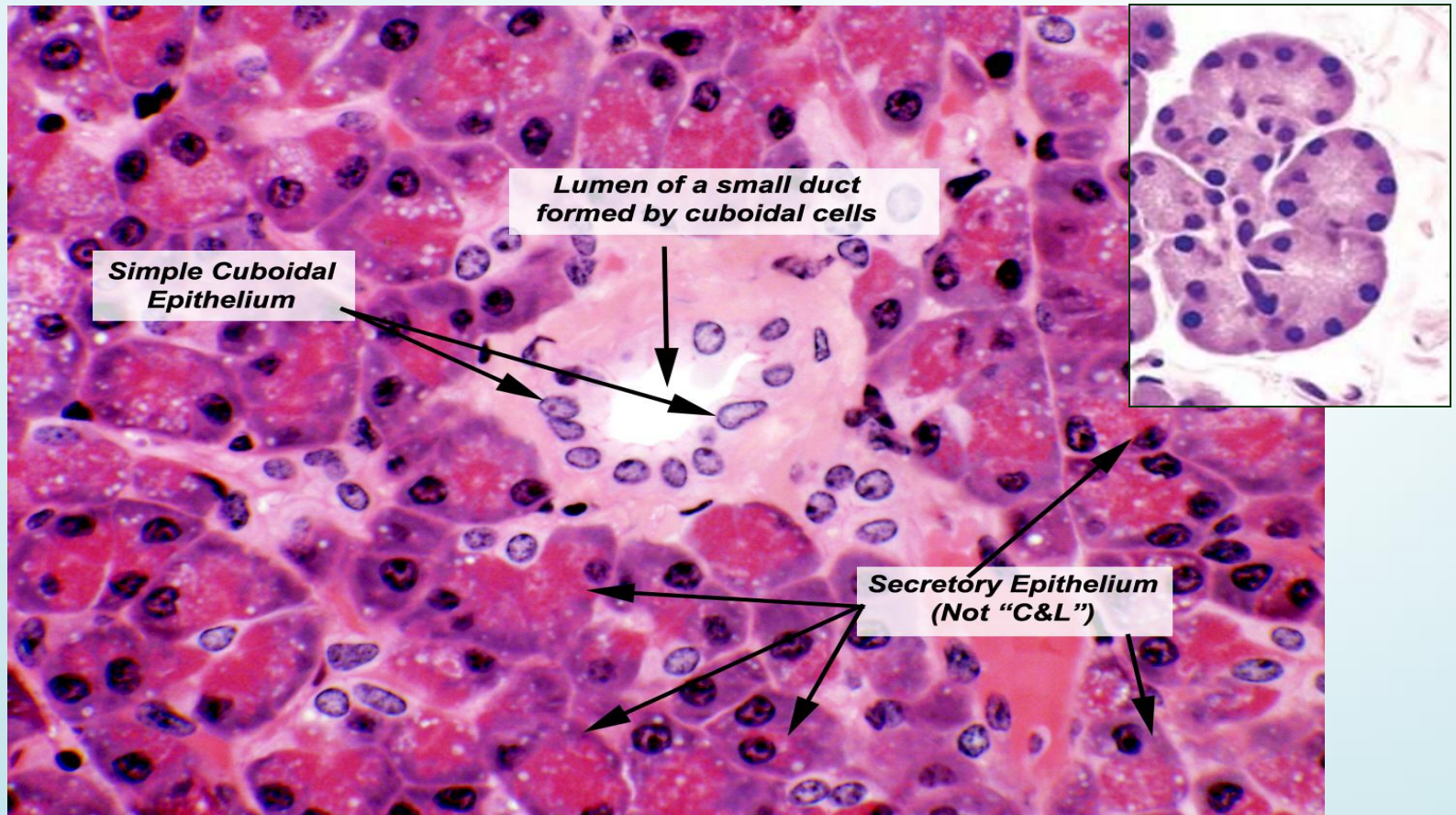


PANCREAS – Normal Histology -LPF



Here is a normal pancreatic islet of Langerhans surrounded by normal exocrine pancreatic acinar tissue. The islets contain alpha cells secreting glucagon, beta cells secreting insulin, and delta cells secreting somatostatin.

PANCREAS – Normal Histology -HPF



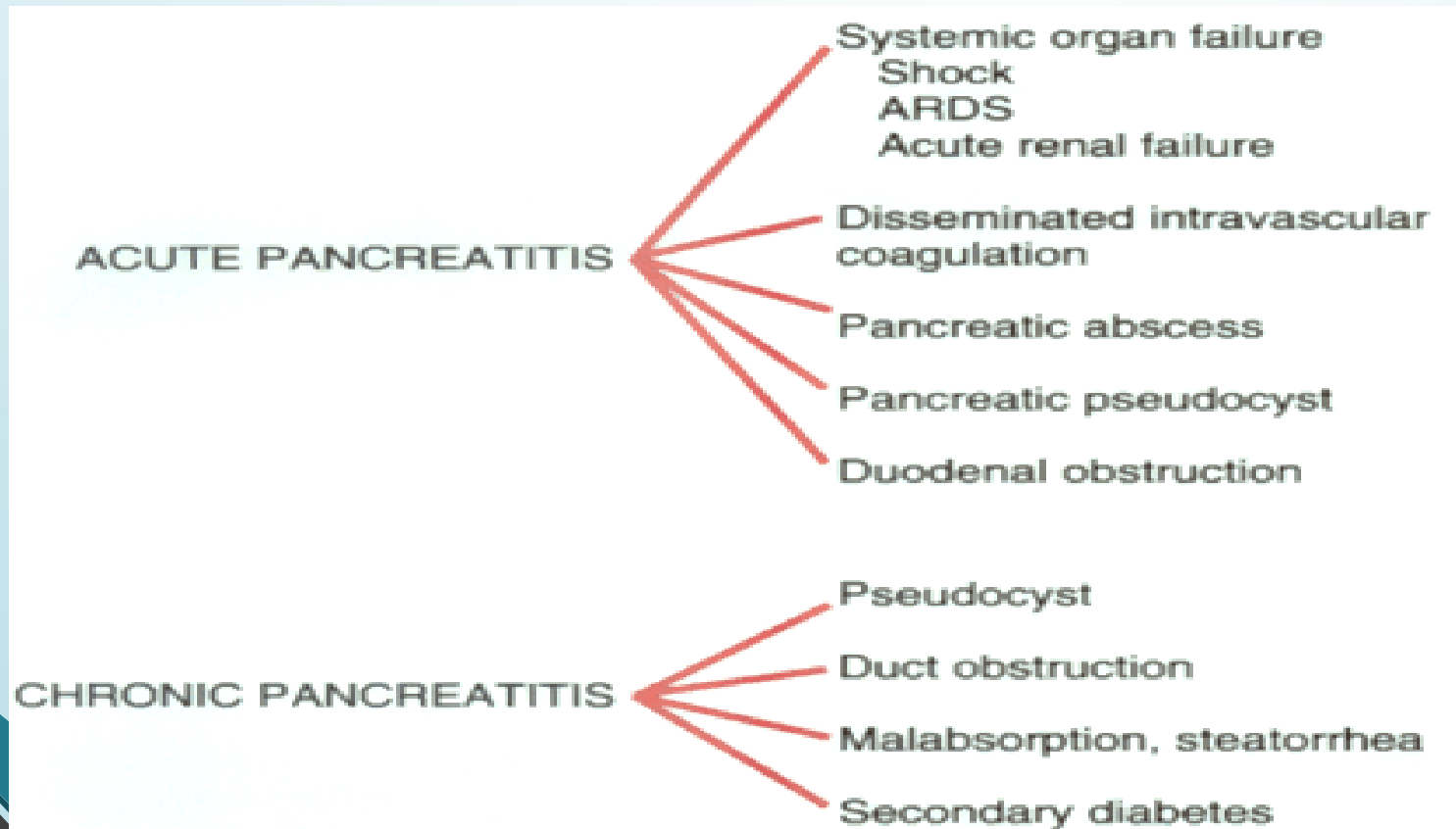
This section of pancreas shows a small duct in the center of the field. The wall of the duct is made of simple cuboidal epithelium. Exocrine gland ducts of this type are made of cuboidal cells arranged like bricks in a wall. As the duct enlarges there may be a transition from cuboidal to a columnar shape



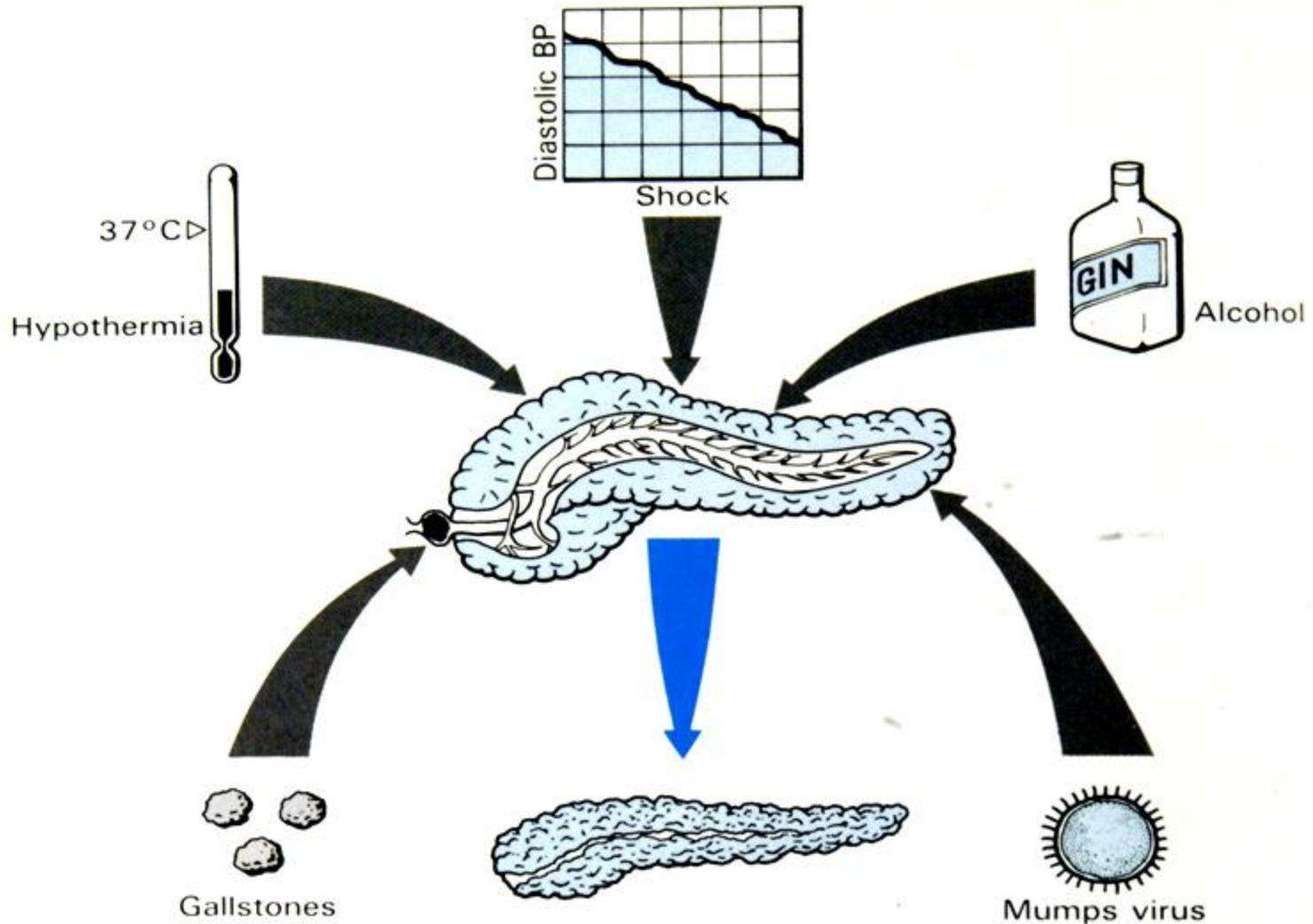
GROSS & HISTOPATHOLOGY

PANCREATITIS - Types

- **ACUTE** (Very serious)
- **CHRONIC** (Calcifications, Pseudocyst)



PANCREATITIS – Common causes





Acute pancreatitis

ACUTE PANCREATITIS - Causes

- ***Alcoholism***
- ***Bile reflux***
- ***Medications (thiazides)***
- ***Hypertriglyceridemia, hypercalcemia***
- ***Acute ischemia***
- ***Trauma, blunt, iatrogenic***
- ***Genes: PRSS₁, SPINK₁***
- ***Idiopathic, 10-20%***

ACUTE PANCREATITIS – Clinical Features

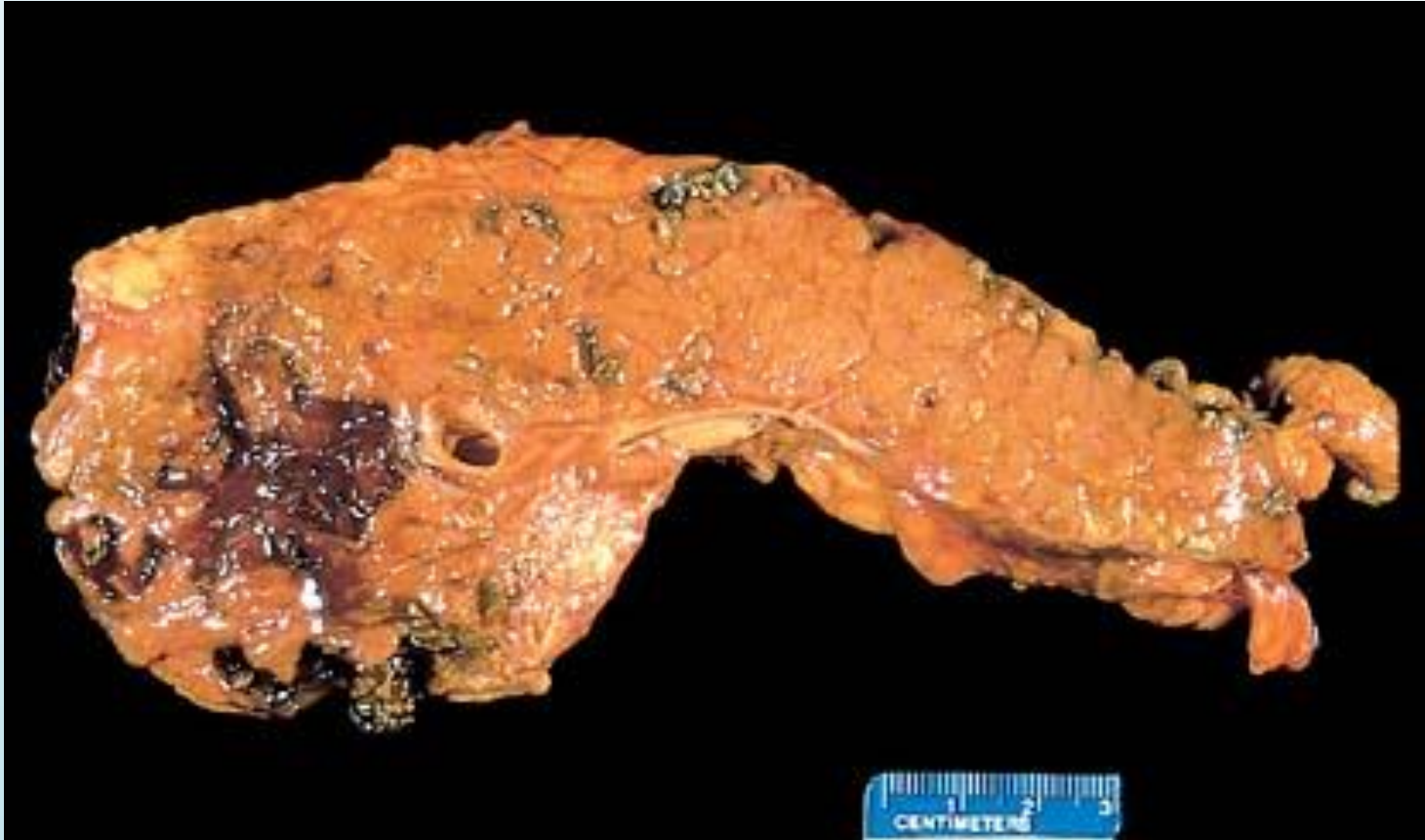- *SEVERE ABDOMINAL PAIN*
- *Extreme Emergency Situation*
- *High Mortality*

- *The MOST important lab test is.....?????*
 - ➔ *α – AMYLASE estimation*

ACUTE PANCREATITIS – Consequences

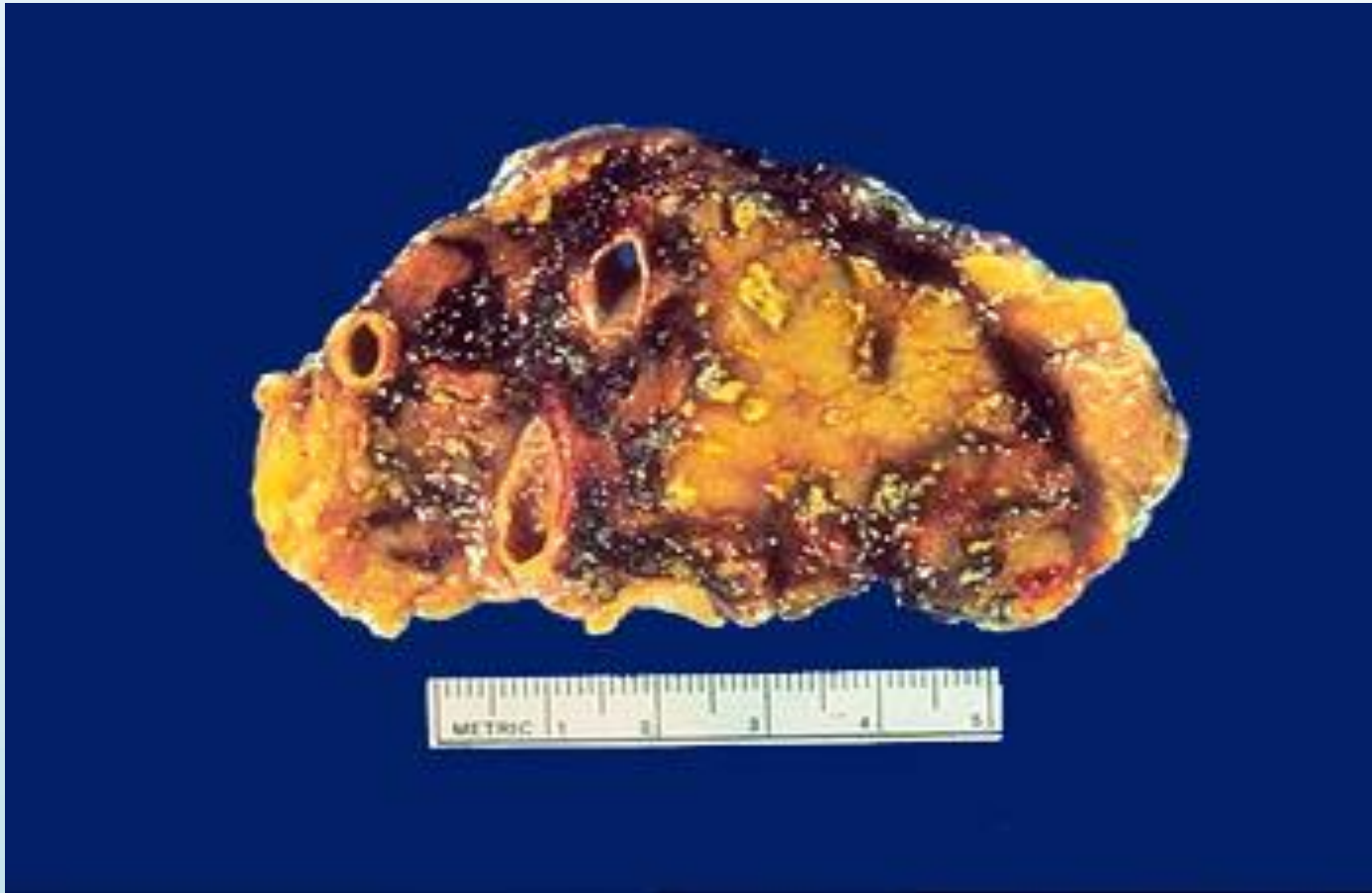- *EDEMA*
- *FAT NECROSIS*
- *ACUTE INFLAMMATORY INFILTRATE*
- *PANCREAS AUTODIGESTION*
- *BLOOD VESSEL DESTRUCTION*
- *"SAPONIFICATION"*

ACUTE PANCREATITIS – Gross



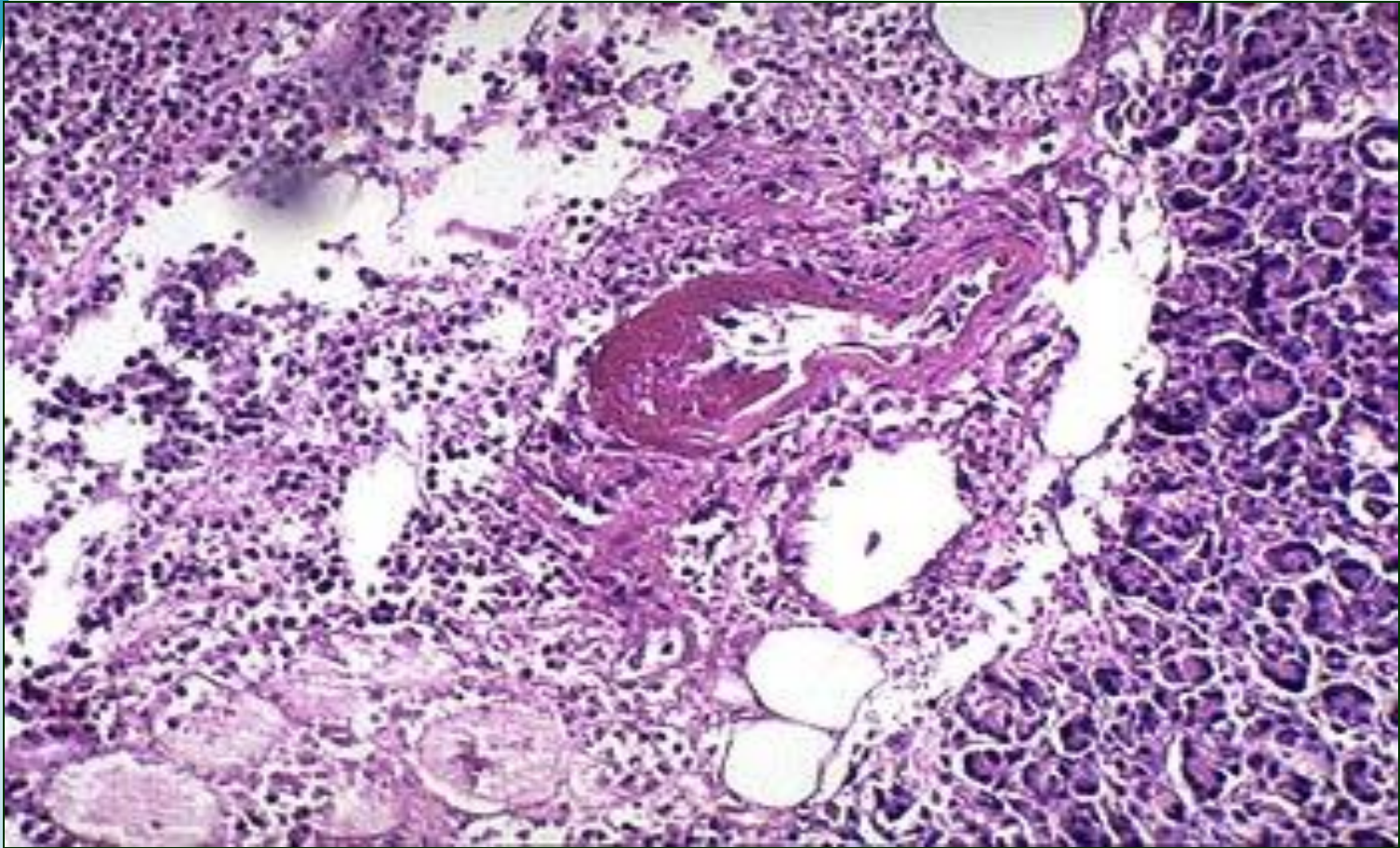
Acute Pancreatitis : Fat necrosis appears as chalky white calcium soaps.

ACUTE PANCREATITIS – Gross



In severe acute pancreatitis, black areas of hemorrhage are present within the pancreas as well as chalky, yellow-white areas of fat necrosis. Pancreatic parenchyma is soft and gray-white due to necrosis

ACUTE PANCREATITIS – LPF

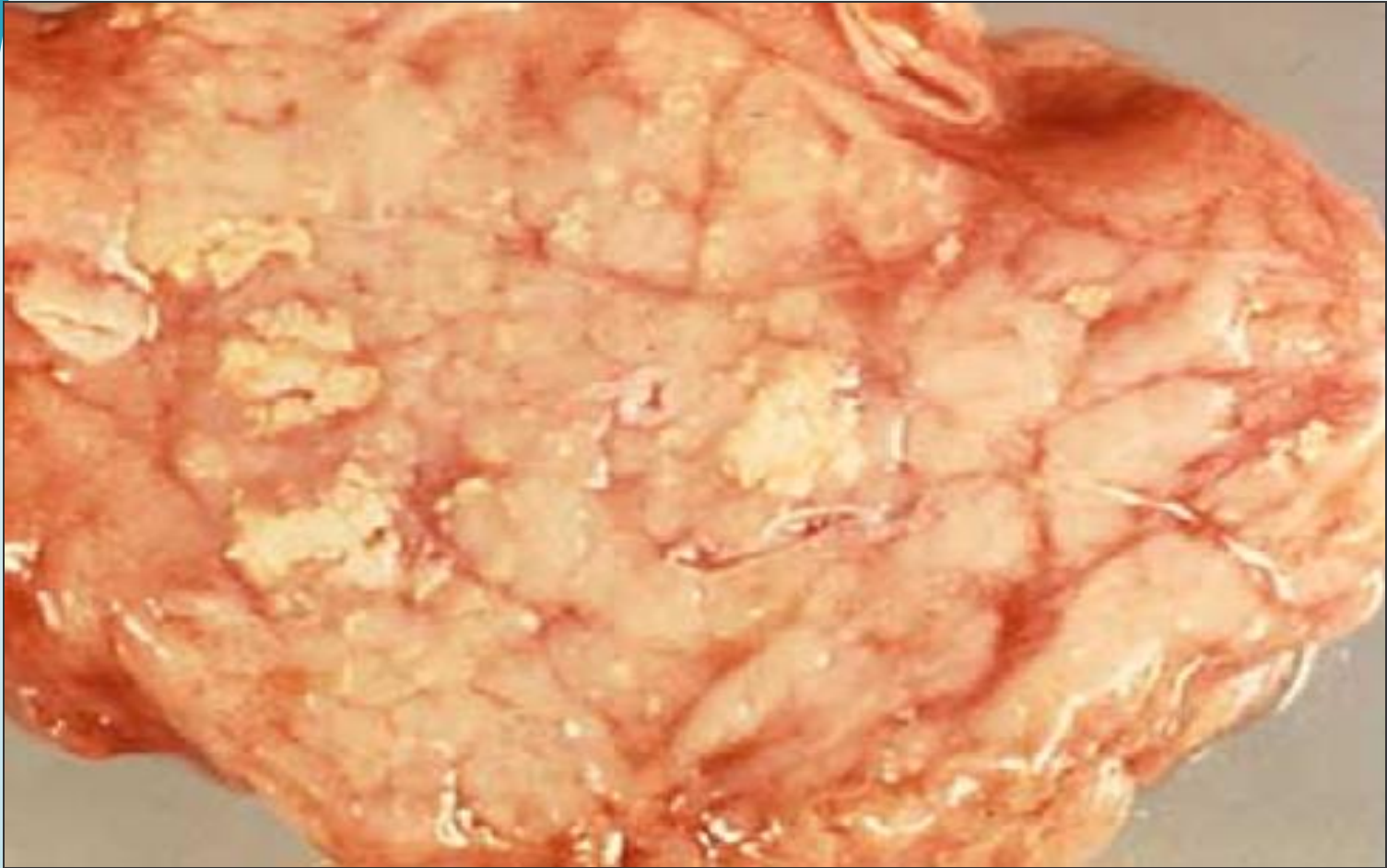


Severe acute pancreatitis shows an area of acute inflammation with necrosis. Within the necrotic area is a blood vessel showing fibrinoid necrosis of the vessel wall leads to severe, hemorrhagic, acute pancreatitis. Common causes of acute pancreatitis are alcoholism , gall stones impaction , traumatic , hereditary and idiopathic .



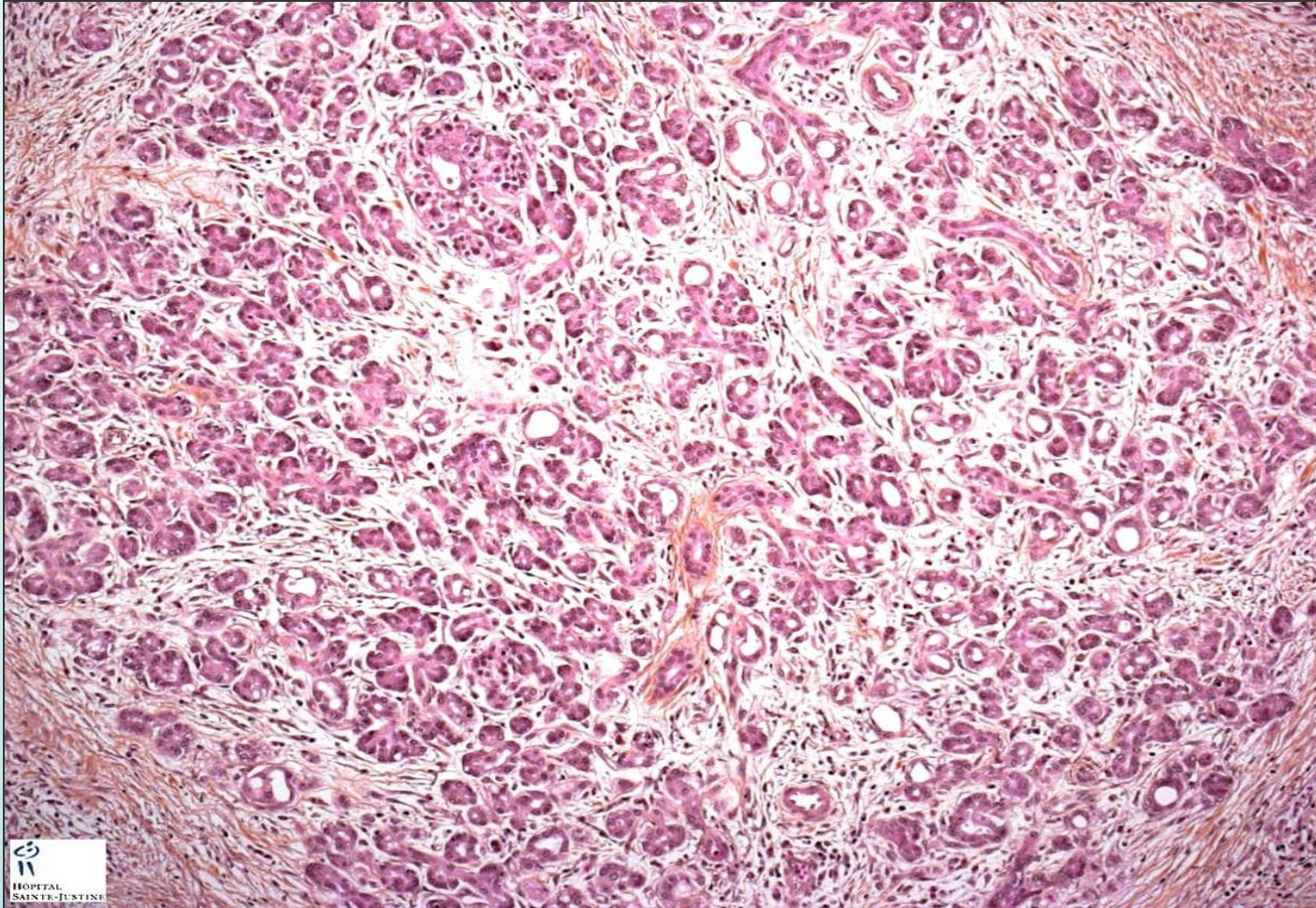
Chronic pancreatitis

CHRONIC PANCREATITIS – GROSS



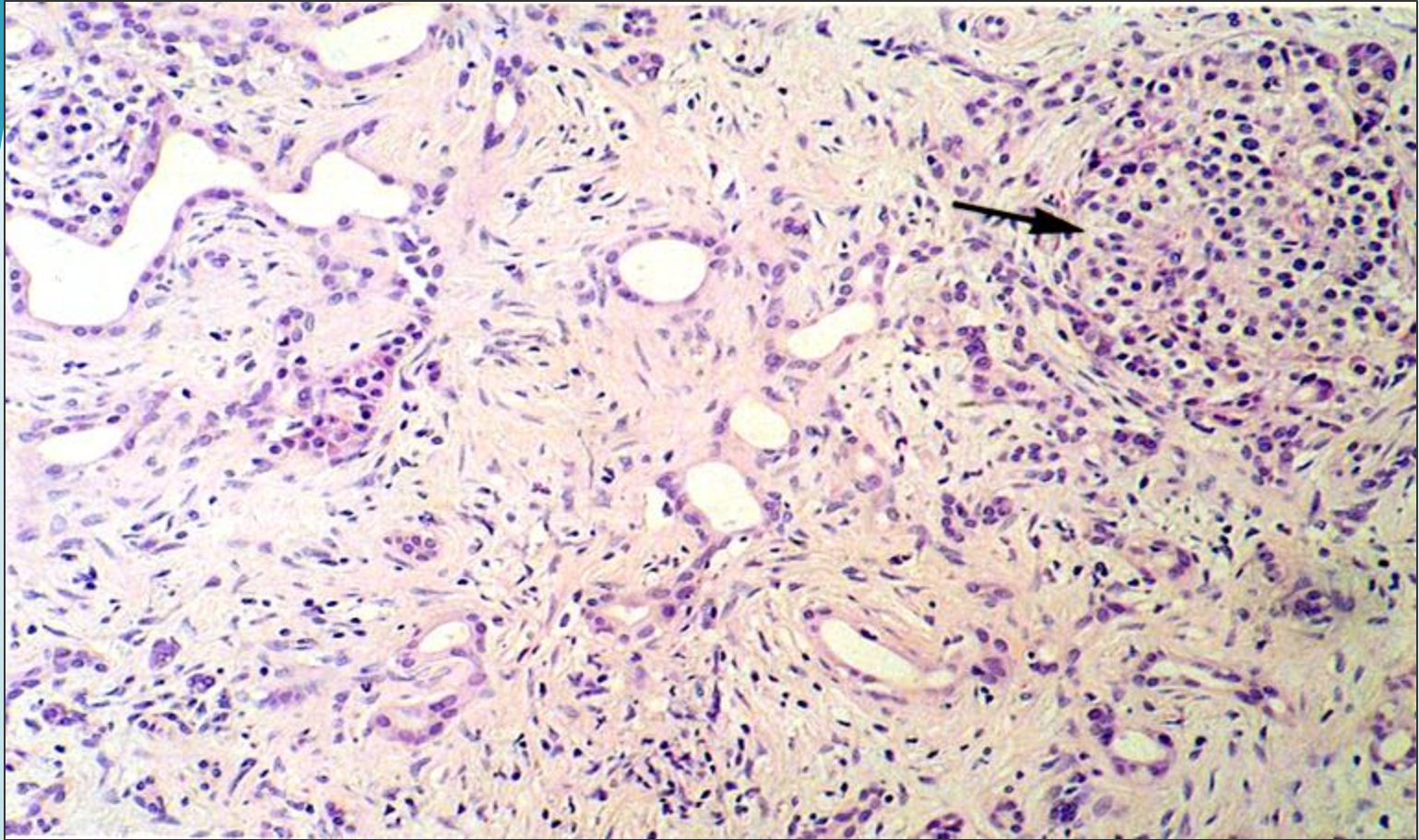
Calcium deposition is secondary to fat necrosis and dystrophic calcification . Possible causes of chronic pancreatitis are gall stones , alcoholism, tropical , hereditary and idiopathic .

CHRONIC PANCREATITIS – LPF



Unfortunately dense fibrosis is a feature BOTH of chronic pancreatitis as well as adenocarcinoma.

CHRONIC PANCREATITIS – LPF



Chronic Pancreatitis: parenchymal fibrosis, chronic inflammatory infiltrate and reduced number and size of acini with variable dilatation of pancreatic ducts and relative sparing of islets of langerhans (arrow)



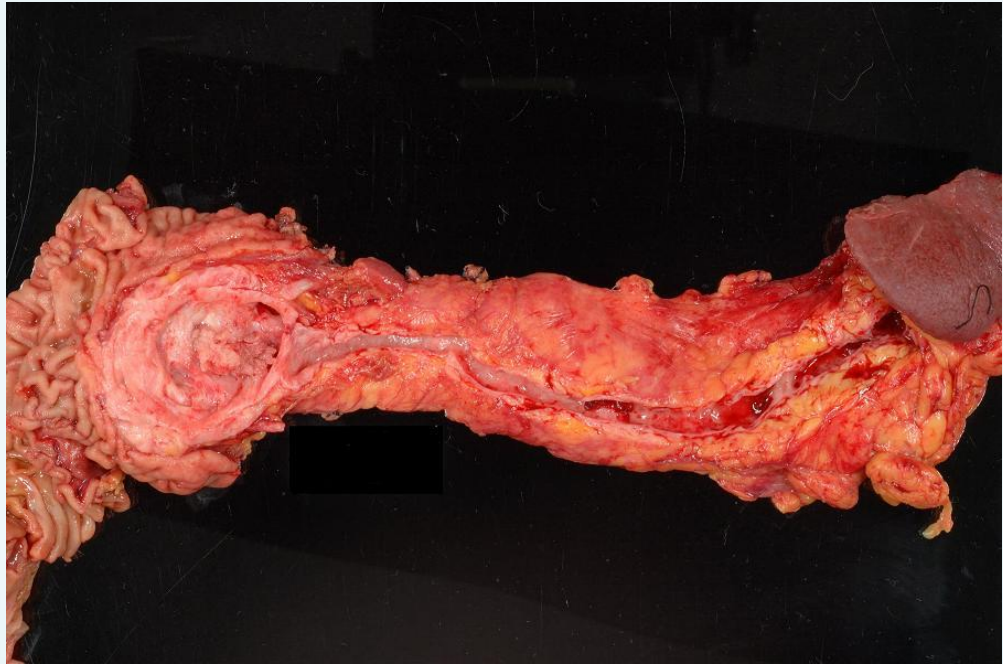
Pancreatic adenocarcinoma

PANCREATIC ADENOCARCINOMA – Gross

predispose to PANCREATIC ADENOCARCINOMA:

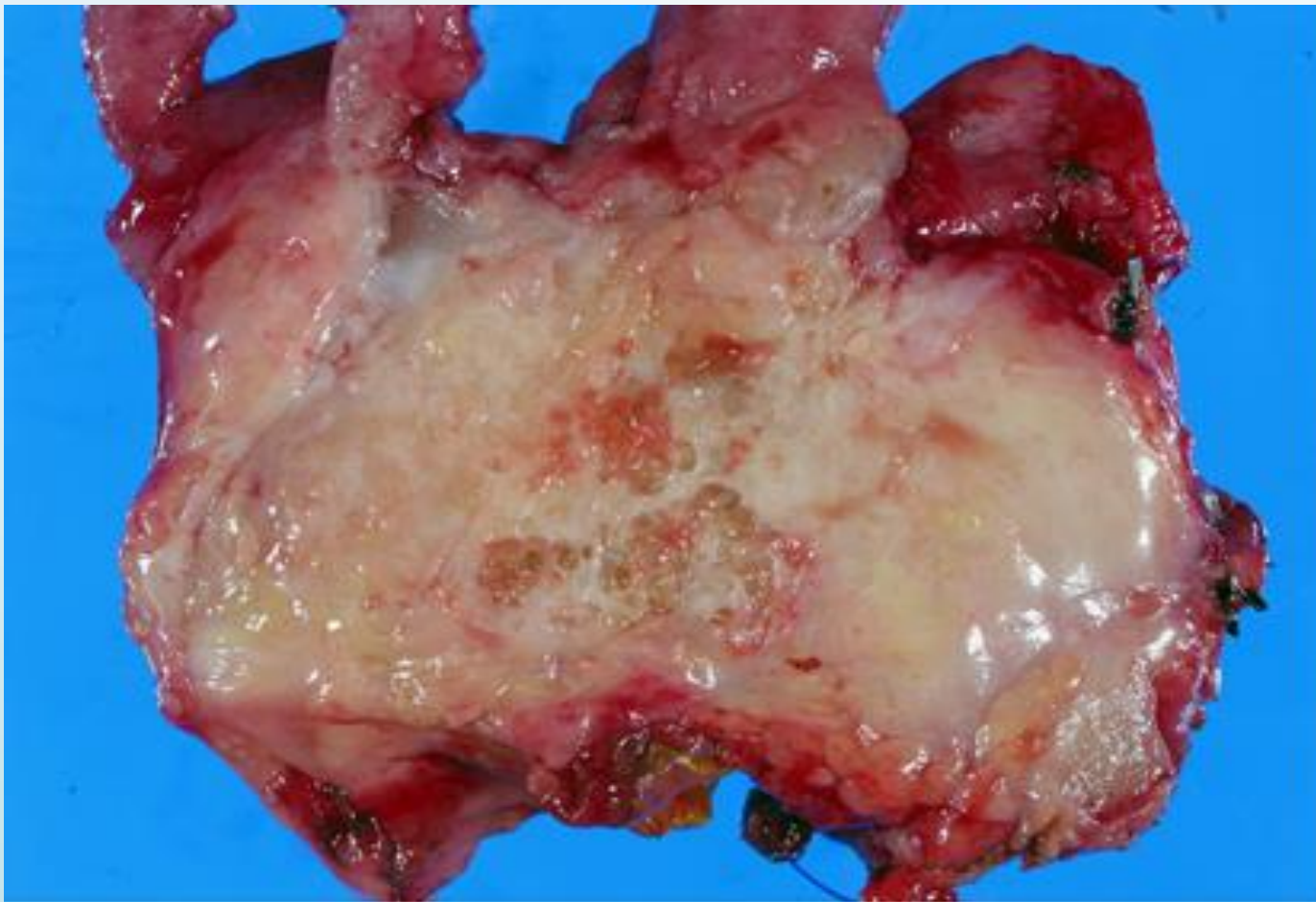
- Chronic pancreatitis
- Diabetic mellitus
- Smoking
- Germline mutation in BRCA2.

The recent sequencing of the pancreatic cancer genome has confirmed that four genes are most commonly affected by somatic mutations in this neoplasm: *KRAS*, *CDKNA2A/p16*, *SMAD4*, and *TP53*:



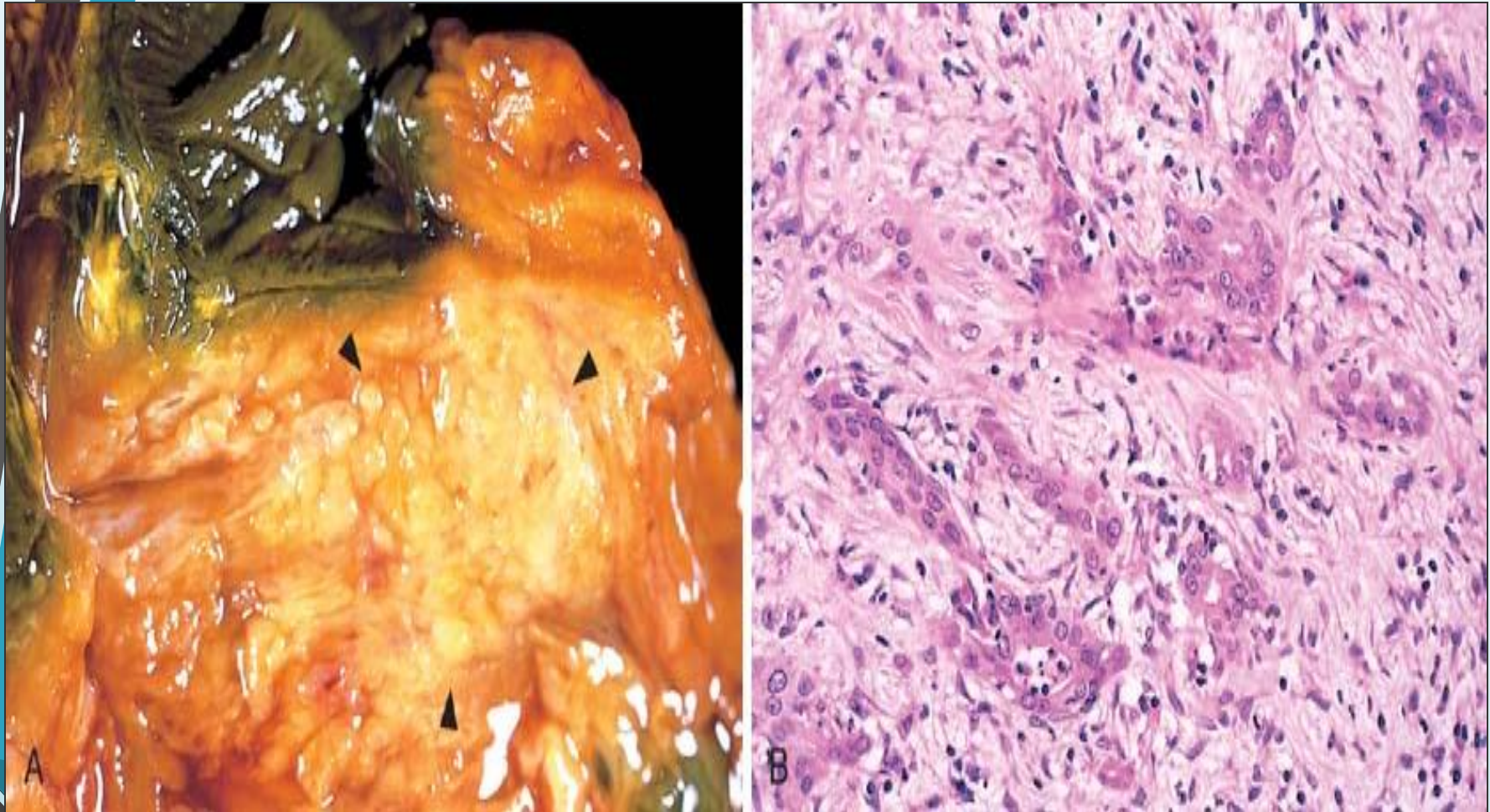
Horizontal section of pancreas showing a well circumscribed tumor nodule at the head of pancreas. Note the presence of a dilated main pancreatic duct. Part of the duodenum is seen on the left and the spleen on the right side.

PANCREATIC ADENOCARCINOMA – Cut surface



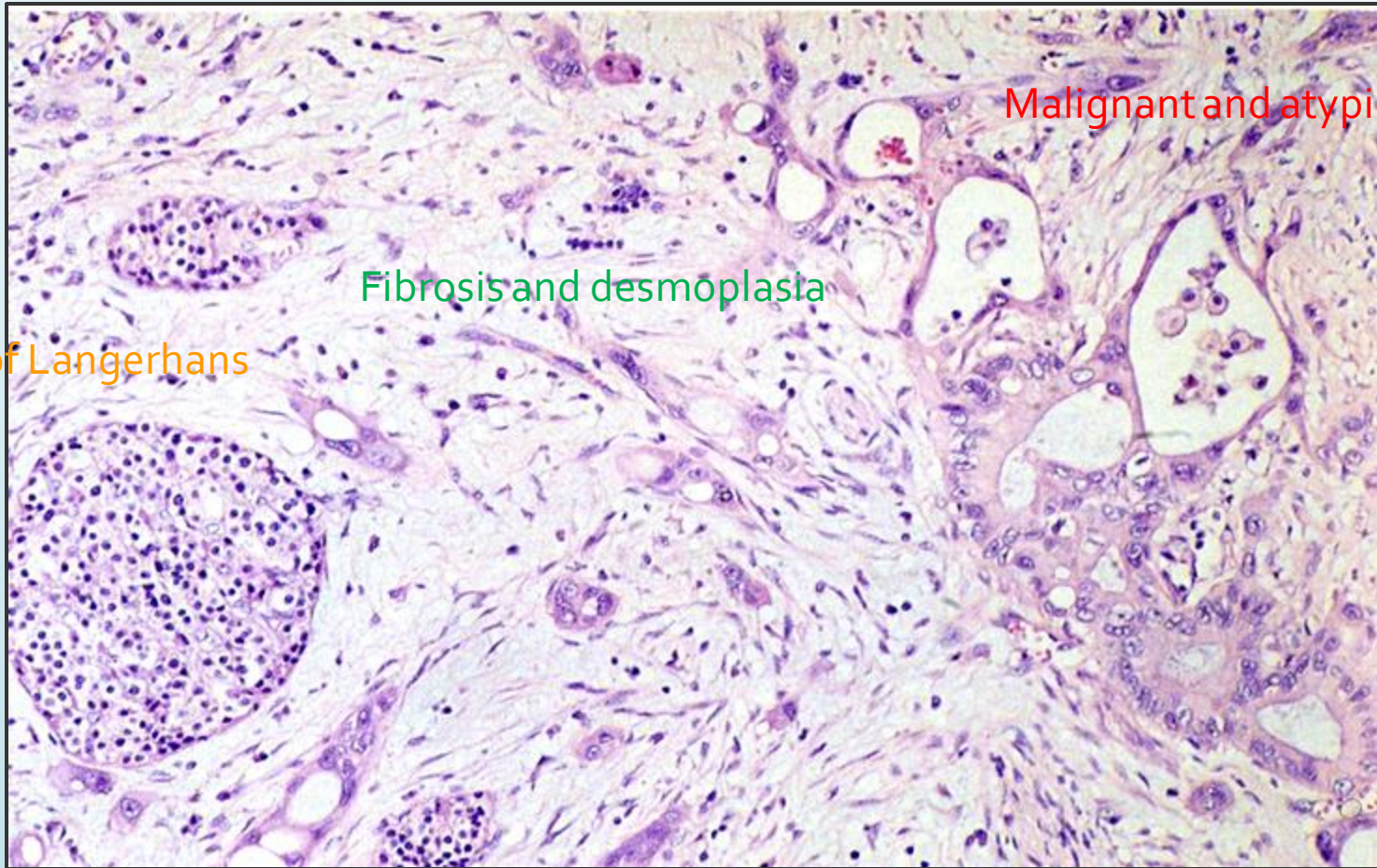
Gross appearance of large duct type ductal adenocarcinoma. A microcystic pattern with cysts measuring from millimeters up to 1 cm.

PANCREATIC ADENOCARCINOMA – Gross & LPF



***Gross picture shows ill defined pale and firm pancreatic mass (left).
Microscopic picture shows malignant glands or acini surrounded by
desmoplastic fibrous stroma (right) .***

PANCREATIC ADENOCARCINOMA – LPF



Malignant and atypical glands

Fibrosis and desmoplasia

Islet of Langerhans

Deeply infiltrative growth pattern with irregular shape and distribution, Desmoplasia, Marked nuclear pleomorphism with nucleoli, Loss of polarity and Mitotic figures

THE END