

Adrenal (Suprarenal) Glands Anatomy & Embryology

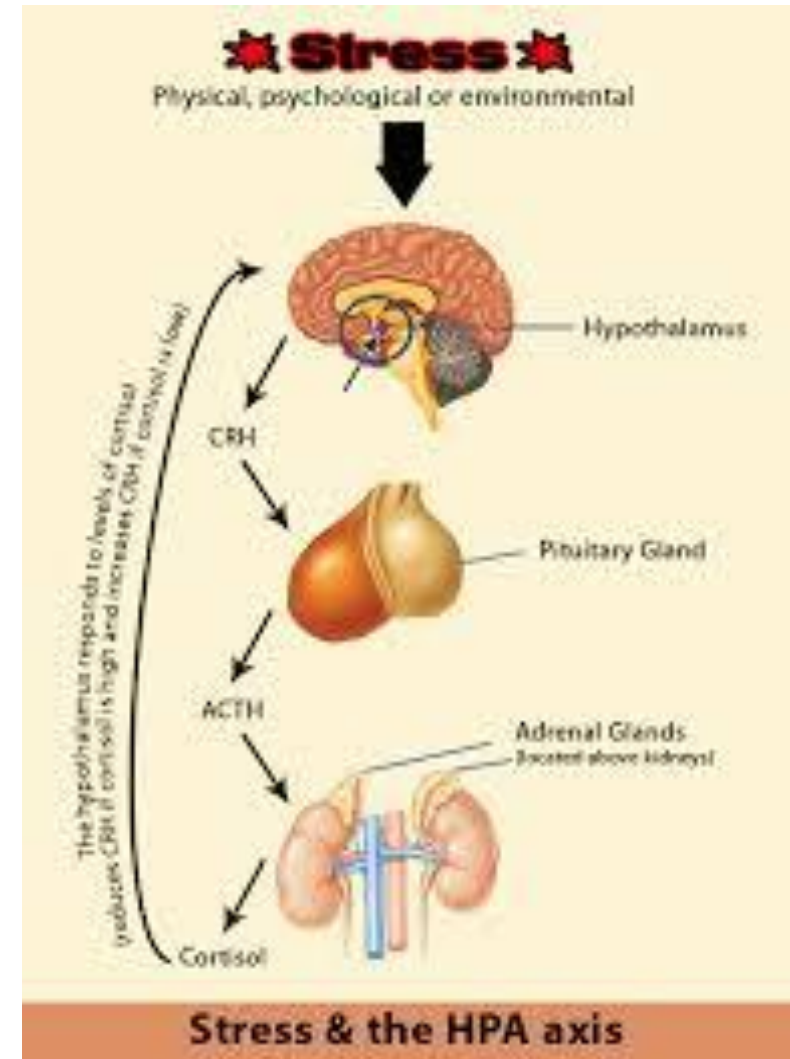
Dr. Jamila EL medany & Dr. Essam Eldin Salama

Objectives

- *At the end of the lecture, the students should be able to describe the:*
- Location, shape and relations of the right and left adrenal glands.
- Blood supply, lymphatic drainage and nerve supply of right and left adrenal glands
- Parts of adrenal glands and function of each part.
- Development of adrenal gland and common anomalies.
- Important clinical notes.

Suprarenal Glands

- The suprarenal (adrenal) gland is a component of the **hypothalamic-pituitary-suprarenal axis** that is responsible for coordinating **stress response** and **metabolism**.



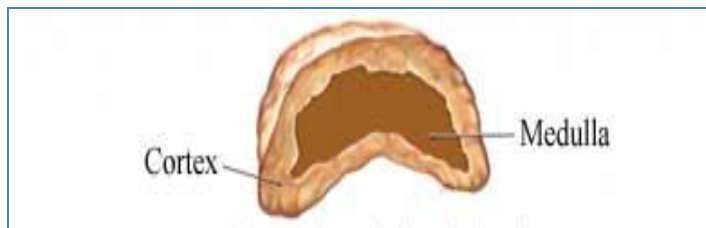
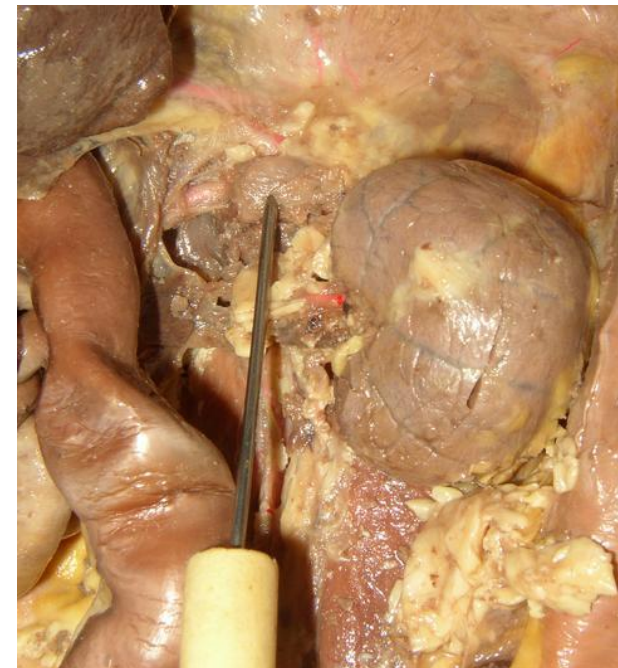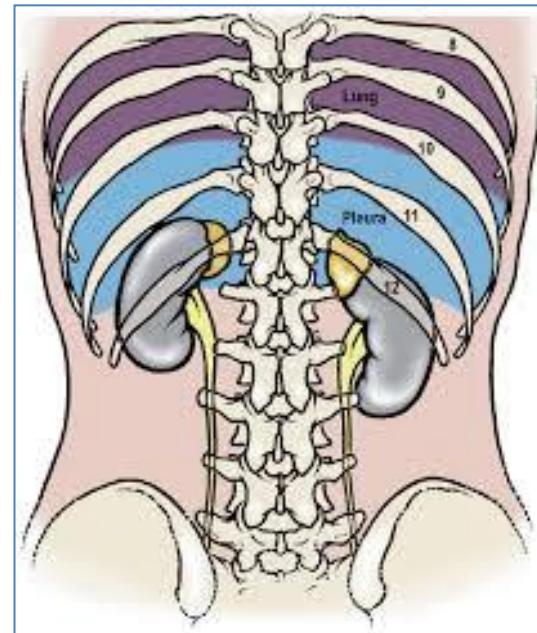
Suprarenal Glands

They are **yellowish retroperitoneal** organs that lie on the upper poles of each kidney.

At the level of the last thoracic vertebra (T12).

They are **surrounded by renal fascia** (but are separated from the kidneys by the **perirenal fat**).

Each gland has an outer yellow **cortex** and an inner dark brown **medulla**.



- Is **pyramidal in** shape.
- Caps the upper pole of the right kidney.
- Relations:

- Anterior:

right lobe of the liver
inferior vena cava.

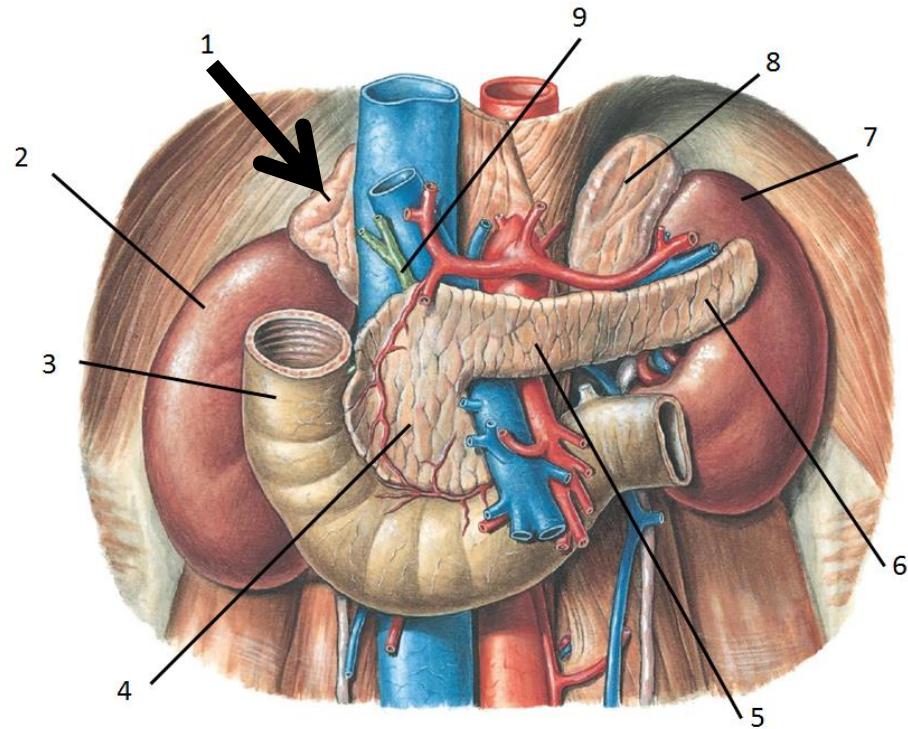
- Posterior:

diaphragm.

- Medial :

Celiac plexus and
ganglia

The right suprarenal gland



- Is **crescentic** in shape
- Extends along the medial border of the left kidney from the upper pole to the hilum.

- Relations:

- **Anterior:**

pancreas, lesser sac, and stomach

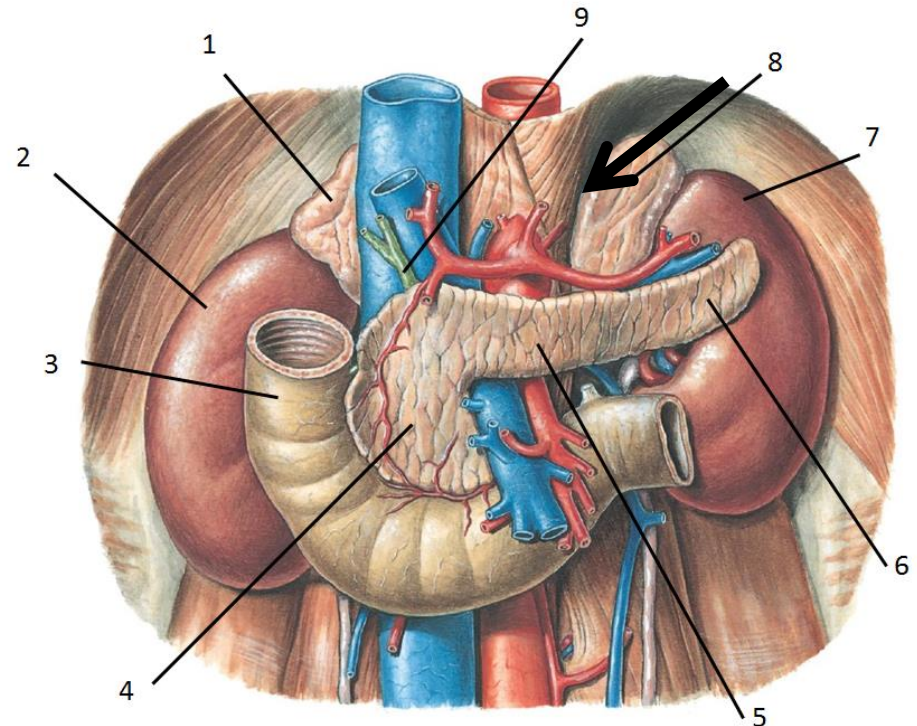
- **Posterior:**

diaphragm.

- **Medial :**

Celiac plexus and ganglia

The left suprarenal gland



Blood supply

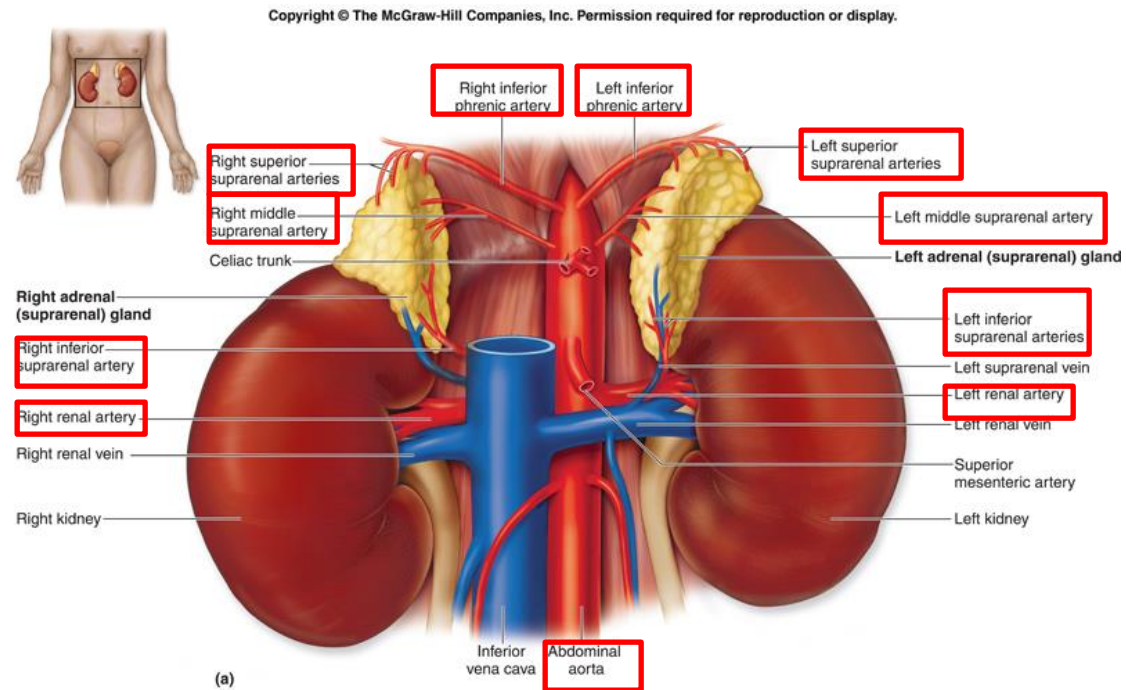
□ Arteries:

■ The arteries supplying each gland are **three** in number:

■ **Superior suprarenal artery,**

■ **Middle suprarenal artery, and**

■ **Inferior suprarenal artery.**



Blood supply

Con.

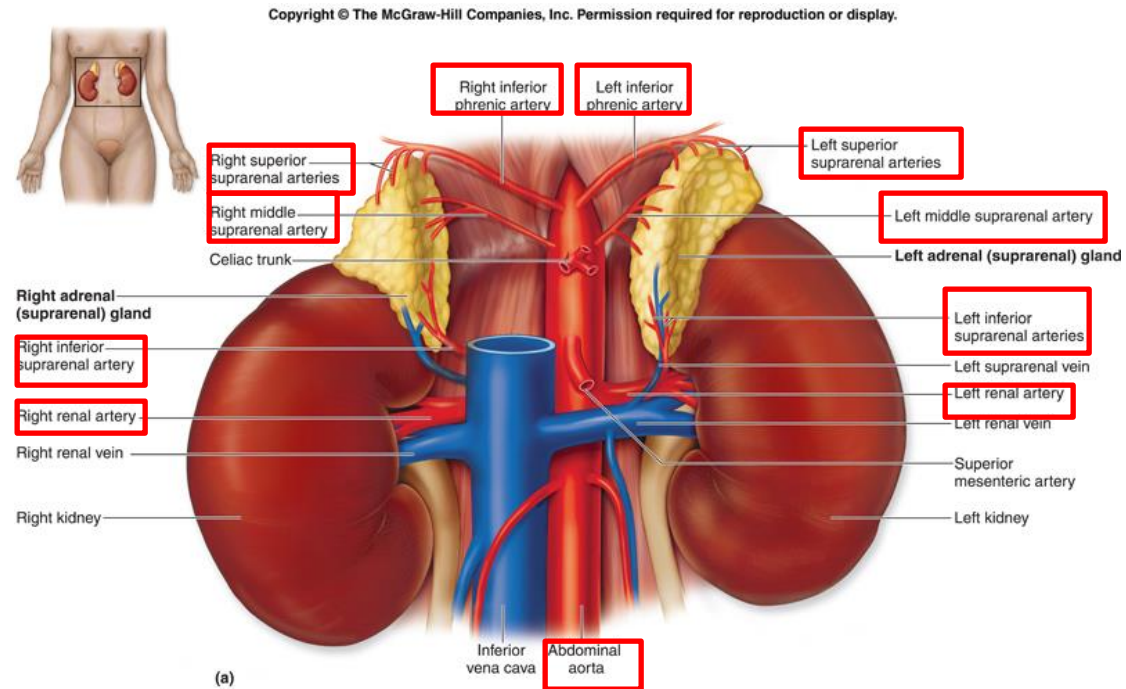
□ Arteries,

Respectively each one arises from;

■ inferior phrenic artery,

■ abdominal aorta, and

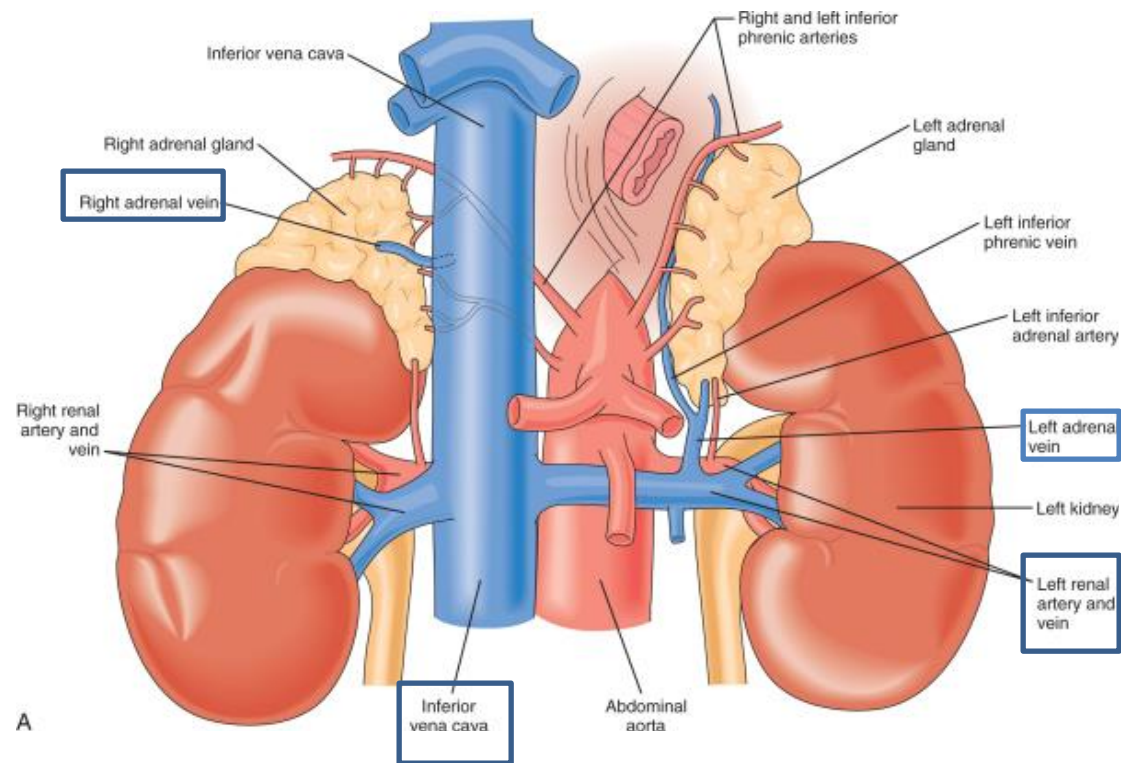
■ renal artery.



Blood supply

□ Veins:

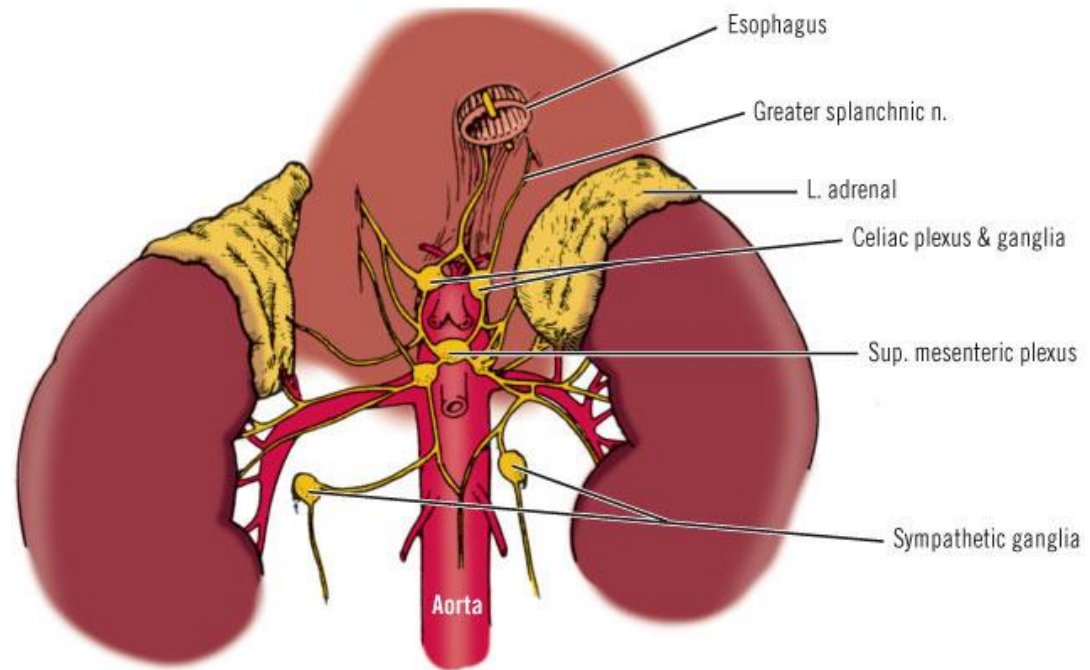
- A single vein emerges from the hilum of each gland and drains into the **inferior vena cava** on the right and the **left renal vein** on the left.



Nerve Supply

□ Nerve Supply:

- **Preganglionic sympathetic fibers**
- derived from the **splanchnic nerves** supply the glands.
- Most of the nerves end in the medulla of the gland.

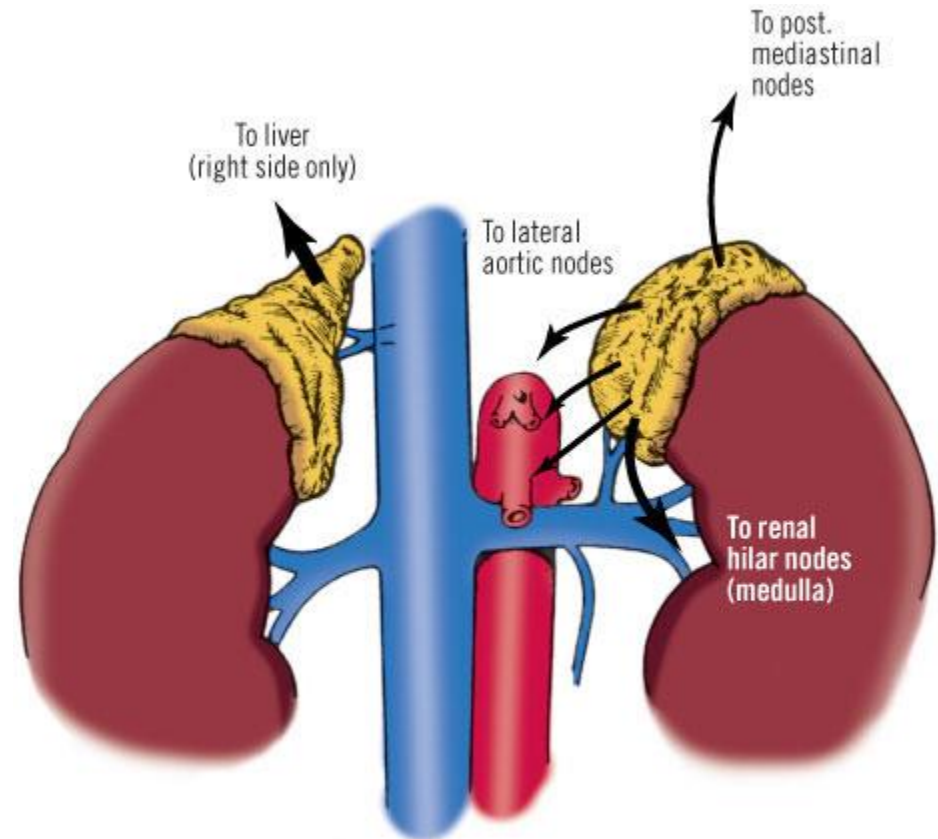


Copyright ©2006 by The McGraw-Hill Companies, Inc.
All rights reserved.

Lymph Drainage

□ Lymph Drainage:

- The lymph drains into the **lateral aortic lymph nodes**.



Copyright ©2006 by The McGraw-Hill Companies, Inc.
All rights reserved.

Functions

- ❑ The **cortex** of the suprarenal glands secretes hormones that include:
 - **Mineral corticoids**, which are concerned with the control of **fluid and electrolyte balance**
 - **Glucocorticoids**, which are concerned with the control of the **metabolism** of carbohydrates, fats, and proteins
 - Small amounts of **sex hormones**, which probably play a role in the **prepubertal development** of the sex organs.
- ❑ The **medulla** of the suprarenal glands secretes the catecholamines: **epinephrine and norepinephrine**

Development of the Adrenal Glands

Development of the Adrenal Glands

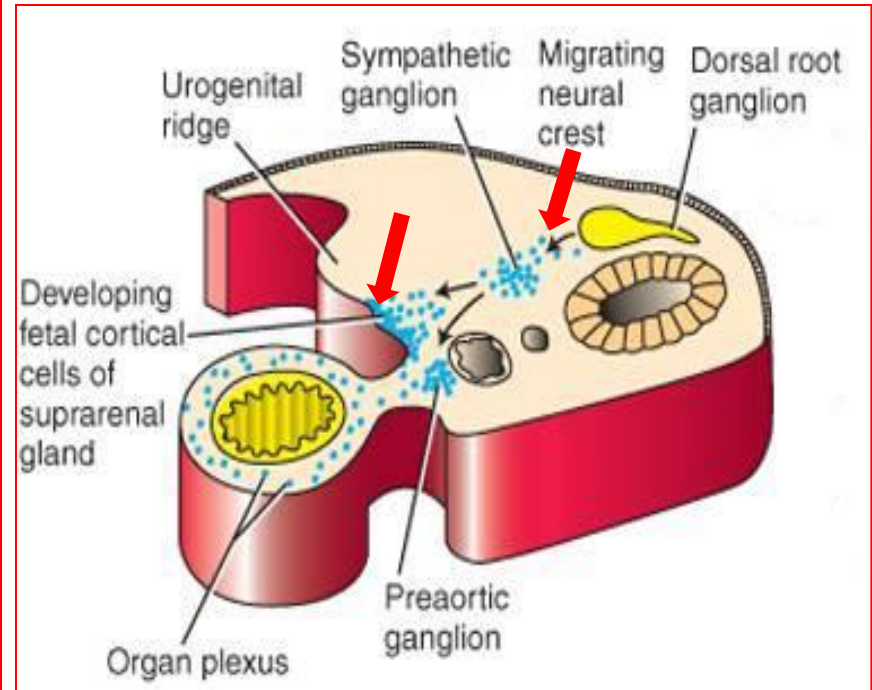
❑ The two parts of the adrenal gland i.e. the cortex and the medulla develop from two different origins.

➤ **Cortex;**

- is **mesodermal** in origin;
- develops from the celomic epithelium of the posterior abdominal wall.

➤ **Medulla;**

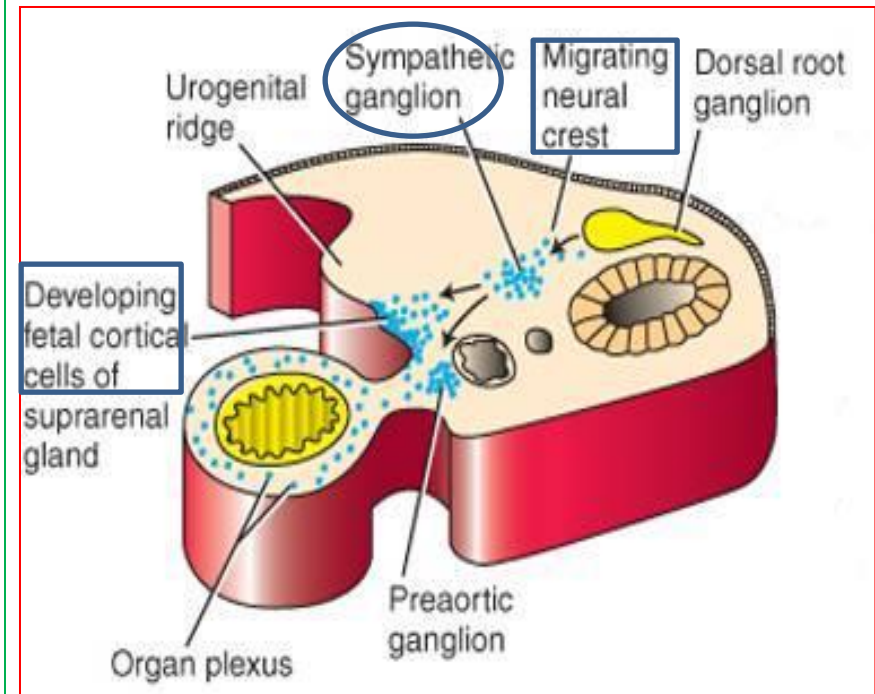
- is **ectodermal** in origin;
- develops from the neural crest cells.



Con.

❑ The cortex

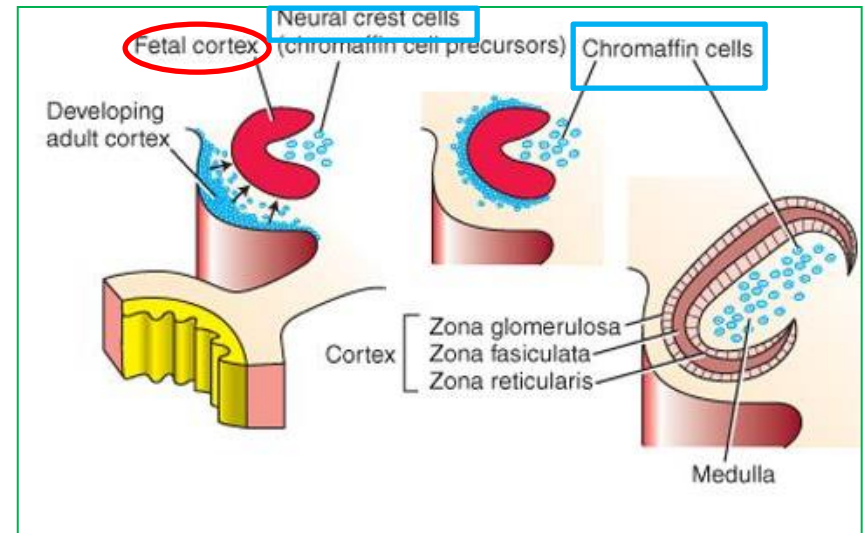
- During the **6th week** of development,
- by **aggregation of the mesenchymal cells.**
- This fetal cortex is derived from the mesothelium lining the posterior abdominal wall.
- between **dorsal mesentery** and **developing gonads.**



Con.

❑ The medulla

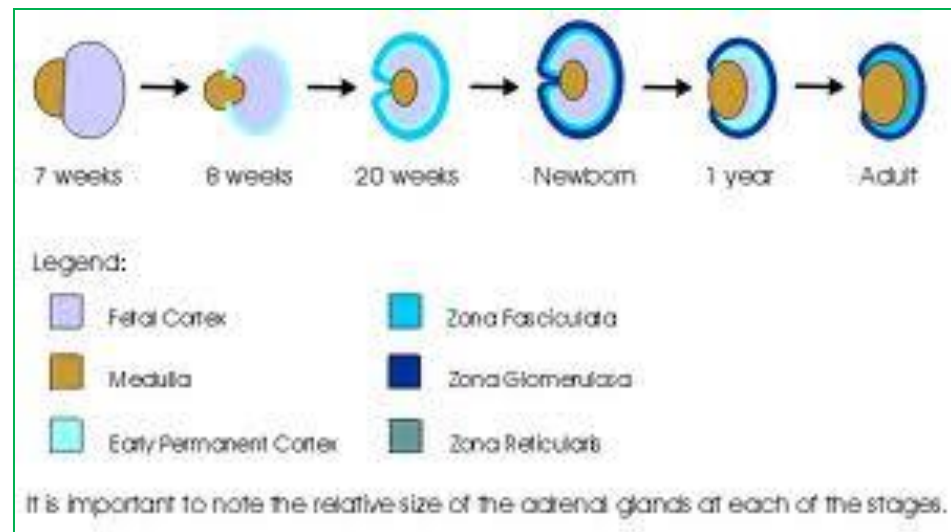
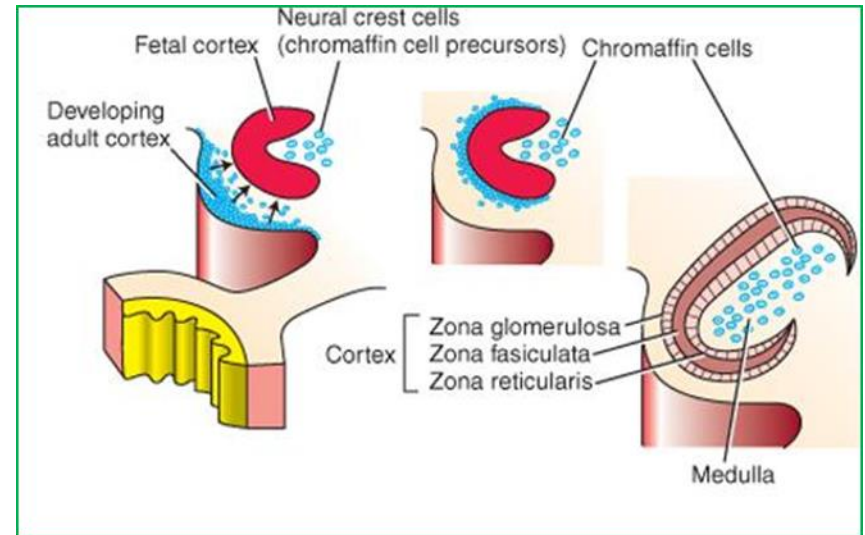
- It forms a **mass medial** to the **fetal cortex**,
- that derived from the adjacent sympathetic ganglion; from neural crest cells.



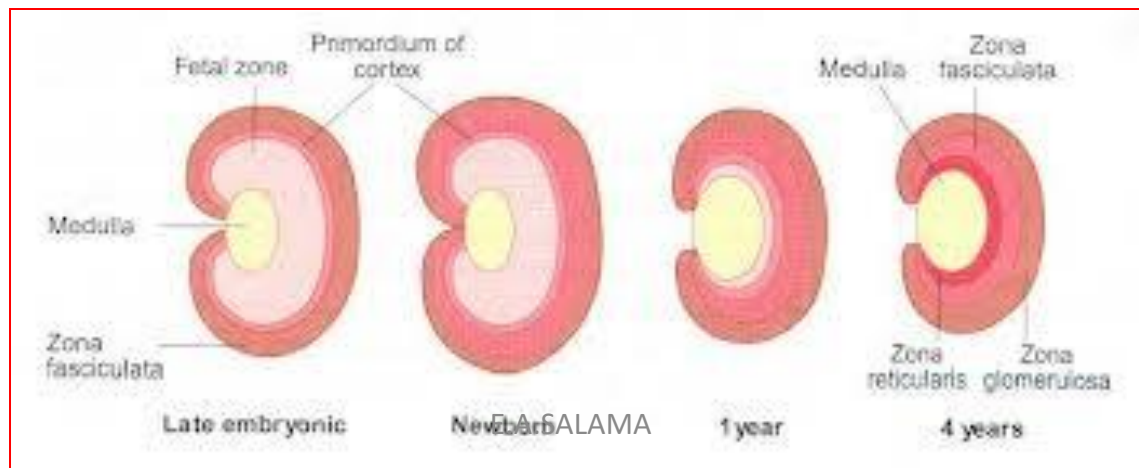
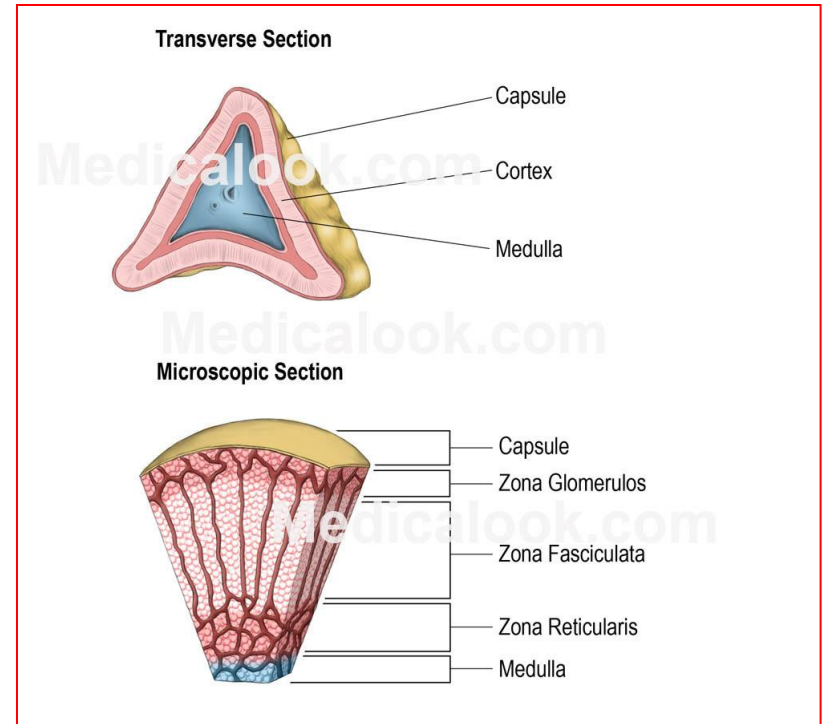
Con.

Permanent cortex

- A **second wave** of mesenchymal cells arise from the mesothelium, **enclose the fetal cortex.**
- forms a thinner definitive **(permanent)** cortex.

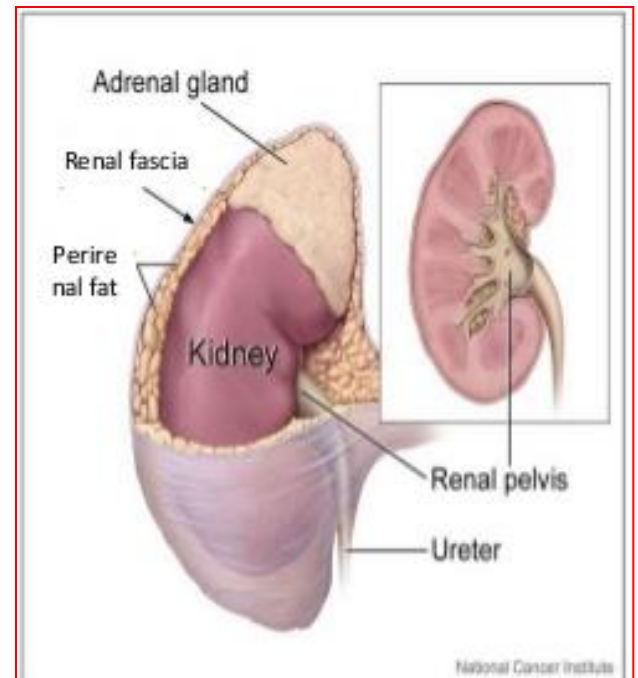


- **Differentiation** of the characteristic suprarenal cortical zones begins during the **late fetal period**.
- **Zona glomerulosa & Zona fasciculata** are present **at birth**, but
- **Zona reticularis** is not recognizable until **the end of third year**.



Clinical notes

- The suprarenal gland is enclosed within the renal fascia with the kidney but in a separate compartment that allow the two organs to be separated easily during surgery.



Con.

- **The suprarenal gland of the fetus is 10-20 times larger than the adult glands** relative to the body weight, and are large compared with the kidneys. This is because of the extensive size of the fetal cortex. The medulla remains relatively small until after birth.
- The suprarenal glands rapidly become smaller during the **first 2-3 weeks** after birth, due to the rapid regression of the fetal cortex.
- Its involution is largely **completed in the first year of life.**
- During the process of involution, the cortex is friable and **susceptible to trauma at birth** leading to severe hemorrhage.

Con.

- **Congenital adrenal hyperplasia (CAH):**
- An abnormal increase in the cortical cells results in **excessive androgen production**; during the **fetal period**.
- **In females**, it may lead to musculization of external genitalia and enlargement of clitoris.
- **In males**, it may remain undetected in early infancy.
- **Later in childhood**, in both sexes, androgen excess may lead to rapid growth and accelerated skeletal maturation.

- esalama@ksu.edu.sa
- essamco58@gmail.com

Thank you