

Ovarian cysts and ovarian tumors

Reference: Robbins & Cotran Pathology and Rubin's Pathology

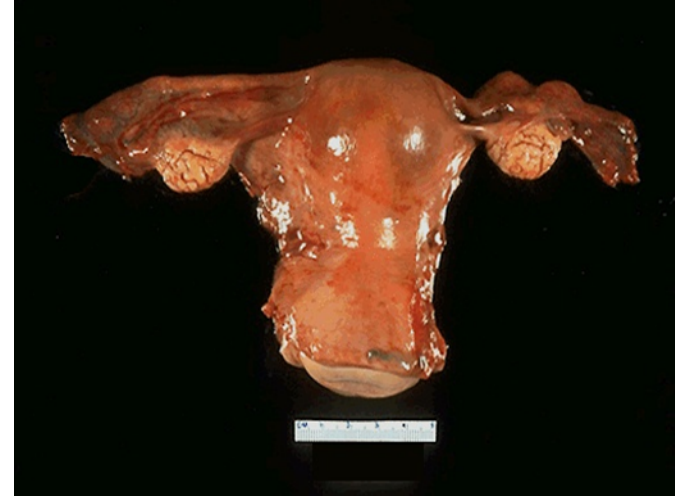Lecture outlines

Lecture: Ovarian cysts and ovarian tumors.

At the end of this lecture, the students should have a working knowledge of:

- The pathology of the major types of ovarian cysts (follicular and luteal).
- The classification and pathology of common ovarian tumors including **surface epithelial**, **germ cell**, **stromal** and metastatic neoplasms.

Ovarian Cysts and Tumors



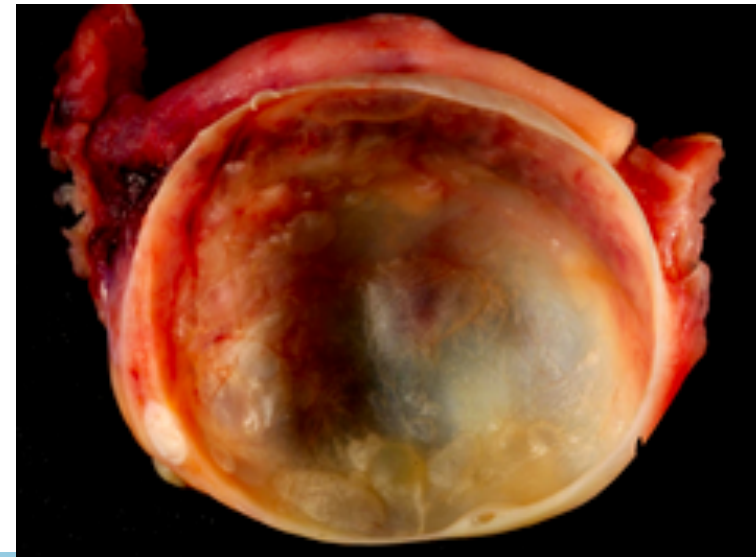
- Non neoplastic cysts are common but they are not serious problems.
- Inflammation of ovaries is rare. It is usually associated with salpingitis of fallopian tubes (salpingo-oophoritis).
- Frequently, the ovaries are affected by **endometriosis**.
- The most important medical problems in ovaries are the neoplasms.
- Death from ovarian cancers is more common than that of cervix and uterus together because ovarian tumors grow silently and are usually diagnosed late, which make them so dangerous.

Non-Neoplastic Cysts of ovary

Non Neoplastic Cyst are more common than the neoplastic ones. They usually cause no problems. Non neoplastic cyst can rupture and cause acute pain and intraabdominal hemorrhage.

non-neoplastic cysts are as follows:

- **Follicular cyst**
- **Corpus luteum cyst**
- **Theca lutein cyst/ hyperreactio luteinalis**
- **Chocolate cyst/Endometriotic cyst**



Non-Neoplastic Cysts of ovary

Follicular cyst

- Arise from the ovarian follicles and are due to distension of un-ruptured Graafian follicle.

Corpus luteum cyst

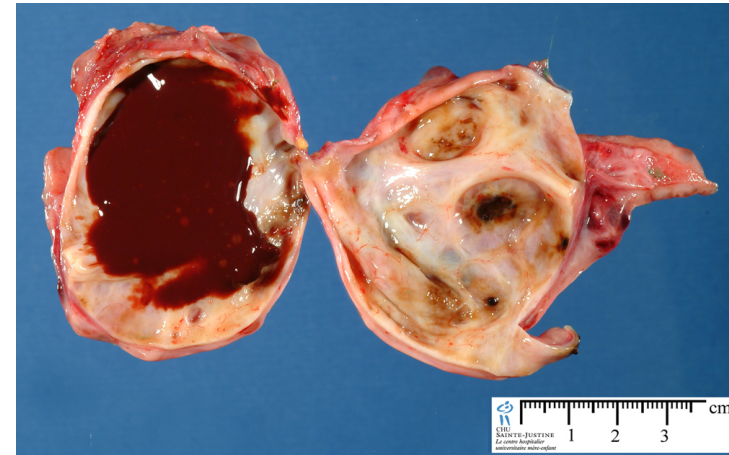- Results from hemorrhage into a persistent mature corpus luteum.

Theca lutein cyst/ hyperreactio luteinalis

- Are thin walled cysts lined by luteinized theca cells. They are associated with high levels of circulating gonadotropins (e.g. pregnancy, hydatidiform mole, etc).

Chocolate cyst /Endometriotic cyst

- The ovary is the most frequent site of endometriosis. And chocolate cyst is a blood filled cyst of the ovary. It is due to endometriosis in the ovary with hemorrhage.



Endometriotic cyst

Ovarian Tumors

- One of the leading cause of cancer death in women.
- Ovarian cancers grow silently and go undetected in the early stage when it is still curable. Most of the patients already have metastasis at the time of diagnosis.
- The WHO Histological Classification for ovarian tumors divides ovarian neoplasms into **primary and metastatic (secondary)**.

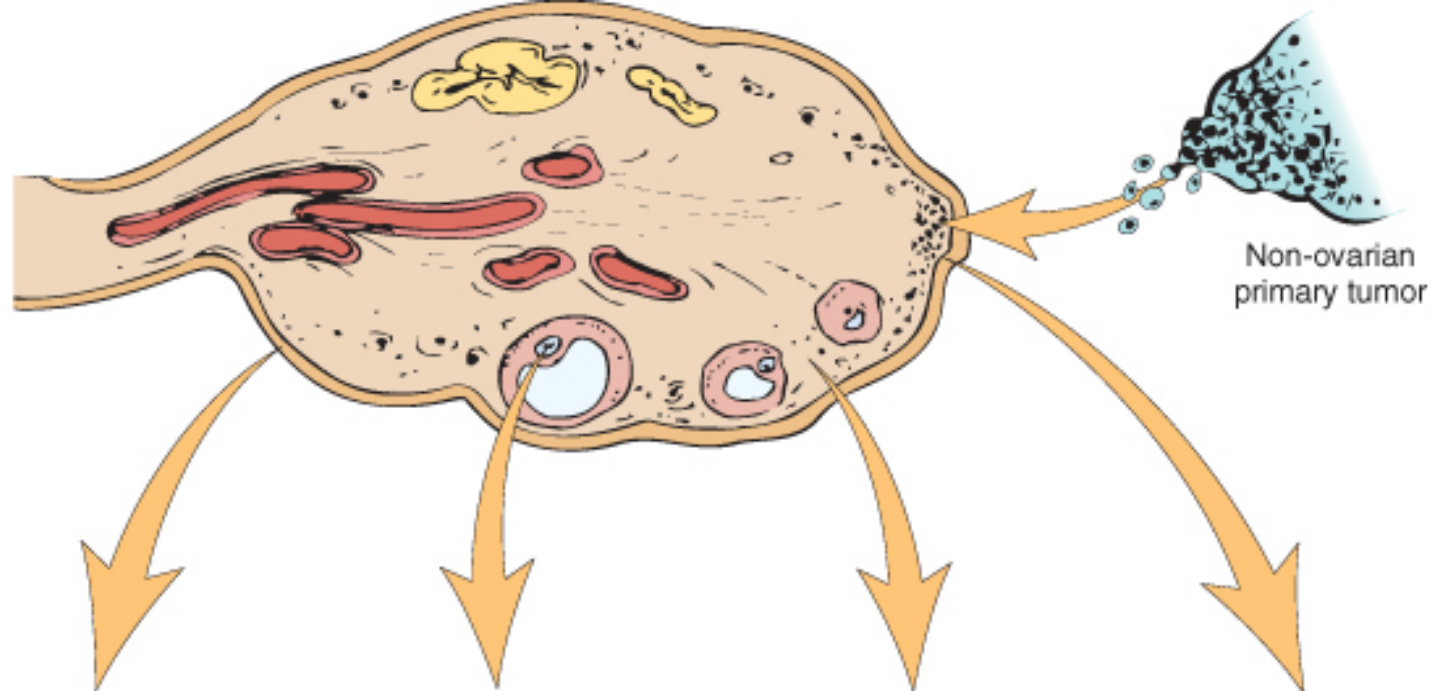
Ovarian Tumors: classification

A. PRIMARY TUMORS: There are **three main primary types** of ovarian tumors based on the origin of the tumor cell. They are:

- 1. Surface epithelial ovarian tumors (65%):** derived from the cells on the surface of the ovary. This is the most common form of primary ovarian cancer and occurs in adults.
- 2. Germ cell tumors (15%):** derived from the egg producing cells of the ovary, i.e. from the ovarian follicles. This occurs mainly in children, teens and young women. They are less common as compared to epithelial ovarian tumors.
- 3. Sex cord stromal tumors (10%):** derived from the ovarian stroma. Uncommon and this class of tumors often produces steroid hormones.

These 3 main types are further divided into many subtypes (see later).

B. METASTATIC/SECONDARY TUMORS (5%): Cancers from other organs can also spread to the ovaries.



ORIGIN	SURFACE EPITHELIAL CELLS (Surface epithelial-stromal cell tumors)	GERM CELL	SEX CORD-STROMA	METASTASIS TO OVARIES
Overall frequency	65%-70%	15%-20%	5%-10%	5%
Proportion of malignant ovarian tumors	90%	3%-5%	2%-3%	5%
Age group affected	20+ years	0-25+ years	All ages	Variable
Types	<ul style="list-style-type: none"> • Serous tumor • Mucinous tumor • Endometrioid tumor • Clear cell tumor • Brenner tumor • Cystadenofibroma 	<ul style="list-style-type: none"> • Teratoma • Dysgerminoma • Endodermal sinus tumor • Choriocarcinoma 	<ul style="list-style-type: none"> • Fibroma • Granulosa-theca cell tumor • Sertoli-Leydig cell tumor 	

Simplified classification of primary ovarian tumors

SURFACE EPITHELIAL TUMORS

Serous tumors:

- Benign (cystadenoma)
- Borderline tumors (serous borderline tumor)
- Malignant (serous adenocarcinoma)

Mucinous tumors:

- Benign (cystadenoma)
- Borderline tumors (mucinous borderline tumor)
- Malignant (mucinous adenocarcinoma)

Endometrioid tumors:

- Benign (cystadenoma)
- Borderline tumors (endometrioid borderline tumor)
- Malignant (endometrioid adenocarcinoma)

Clear cell tumors:

- Benign
- Borderline tumors
- Malignant (clear cell adenocarcinoma)

Transitional cell tumors:

- Brenner tumor
- Brenner tumor of borderline malignancy
- Malignant Brenner tumor
- Transitional cell carcinoma (non-Brenner type)

Others

SEX CORD STROMAL TUMORS

Almost always Benign

- Fibromas/ Fibrothecomas /Thecomas

With Malignant Potential

- Granulosa cell tumors
- Sertoli-Leydig cell tumors

Others

GERM CELL TUMORS

•Teratoma:

- Immature (malignant)
- Mature (benign)
 - Solid
 - Cystic (dermoid cyst)
- Monodermal (e.g., struma ovarii, carcinoid)

•Dysgerminoma

•Yolk sac tumor (endodermal sinus tumor)

•Choriocarcinoma

•Embryonal carcinoma

•Mixed germ cell tumors

NOTE: all ovarian GCTs are considered as malignant except mature teratoma

Surface Epithelial Ovarian Tumors

Surface Epithelial Ovarian Tumors

- Neoplasms of surface epithelium account for majority of all primary ovarian tumors.
- Are 65 – 70 % of overall tumors.
- They account for 90 % of malignant tumors in the ovary.
- Age 20+.

Surface Epithelial Ovarian Tumors

The subtypes of the surface epithelial tumors are:

- **Serous Tumors**
- **Mucinous Tumors**
- **Endometrioid Tumors**
- **Clear cell Tumors**
- **Transitional/Brenner cell Tumors**
- **Others**

All surface epithelial tumors are further divided into:

- i. **Benign:** They do not spread and invade other tissues.
- ii. **Malignant:** are carcinomas and have potential to metastasize beyond the ovary.
- iii. **Borderline/ intermediate/ tumors of low malignant potential:** this is a gray zone. They are 'semi-malignant'. These appear to be low grade cancers with limited invasive potential. They have better prognosis than malignant. These tumors may seed or implant into the peritoneum.

Simplified classification of primary ovarian tumors

SURFACE EPITHELIAL TUMORS

A. Serous tumors:

- Benign (cystadenoma)
- Borderline tumors (serous borderline tumor)
- Malignant (serous adenocarcinoma)

B. Mucinous tumors, endocervical-like and intestinal type:

- Benign (cystadenoma)
- Borderline tumors (mucinous borderline tumor)
- Malignant (mucinous adenocarcinoma)

C. Endometrioid tumors:

- Benign (cystadenoma)
- Borderline tumors (endometrioid borderline tumor)
- Malignant (endometrioid adenocarcinoma)

D. Clear cell tumors:

- Benign
- Borderline tumors
- Malignant (clear cell adenocarcinoma)

E. Transitional cell tumors:

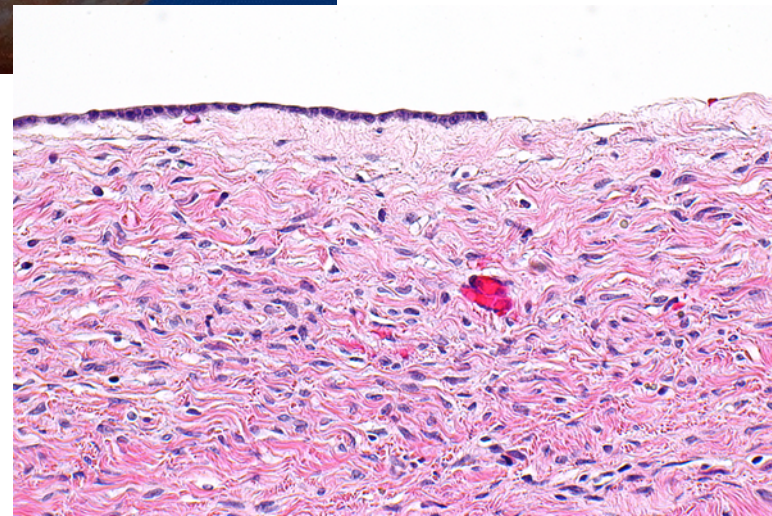
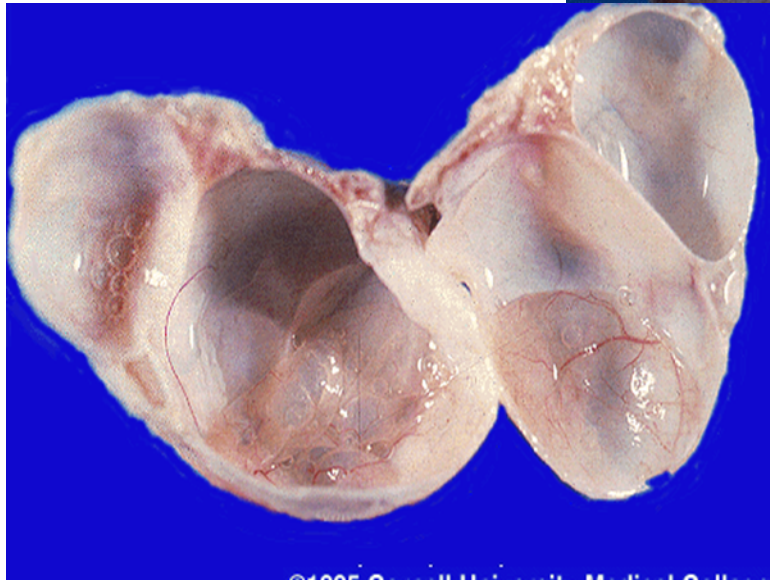
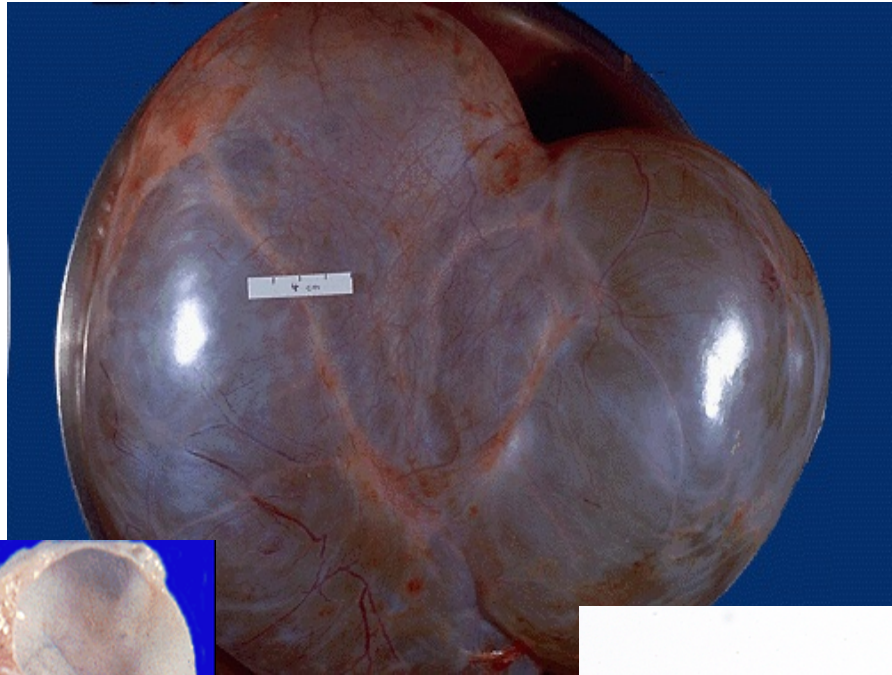
- Brenner tumor
- Brenner tumor of borderline malignancy
- Malignant Brenner tumor
- Transitional cell carcinoma (non-Brenner type)

F. Others

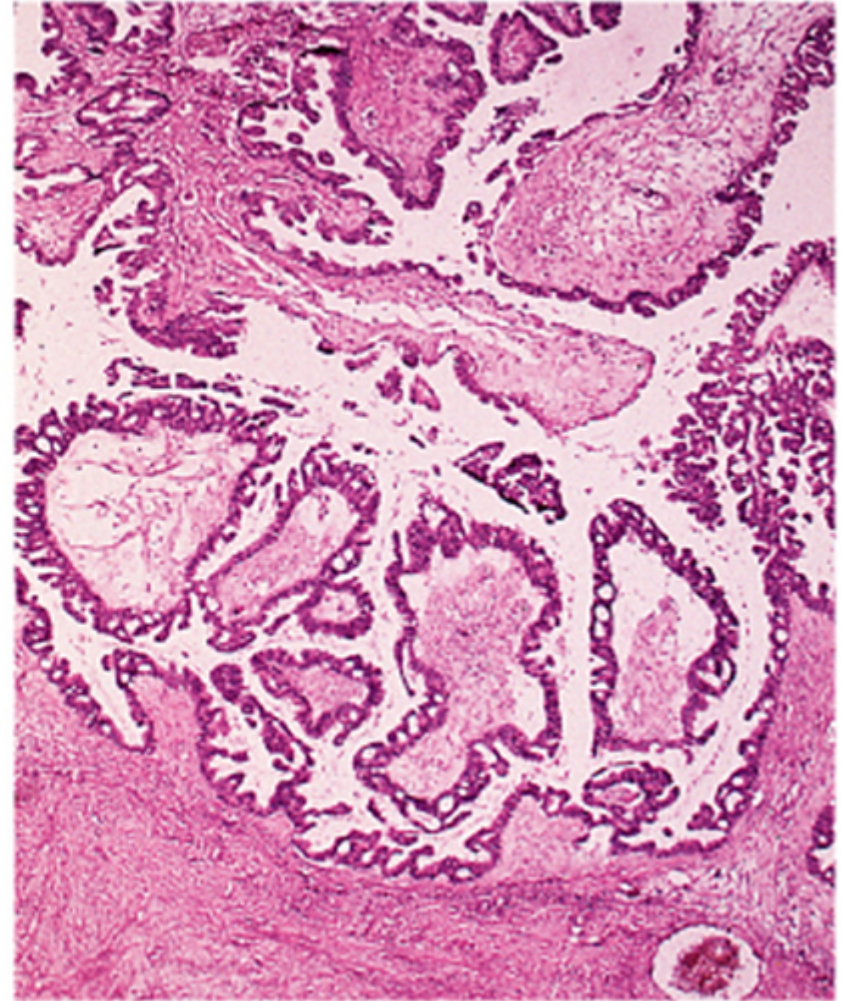
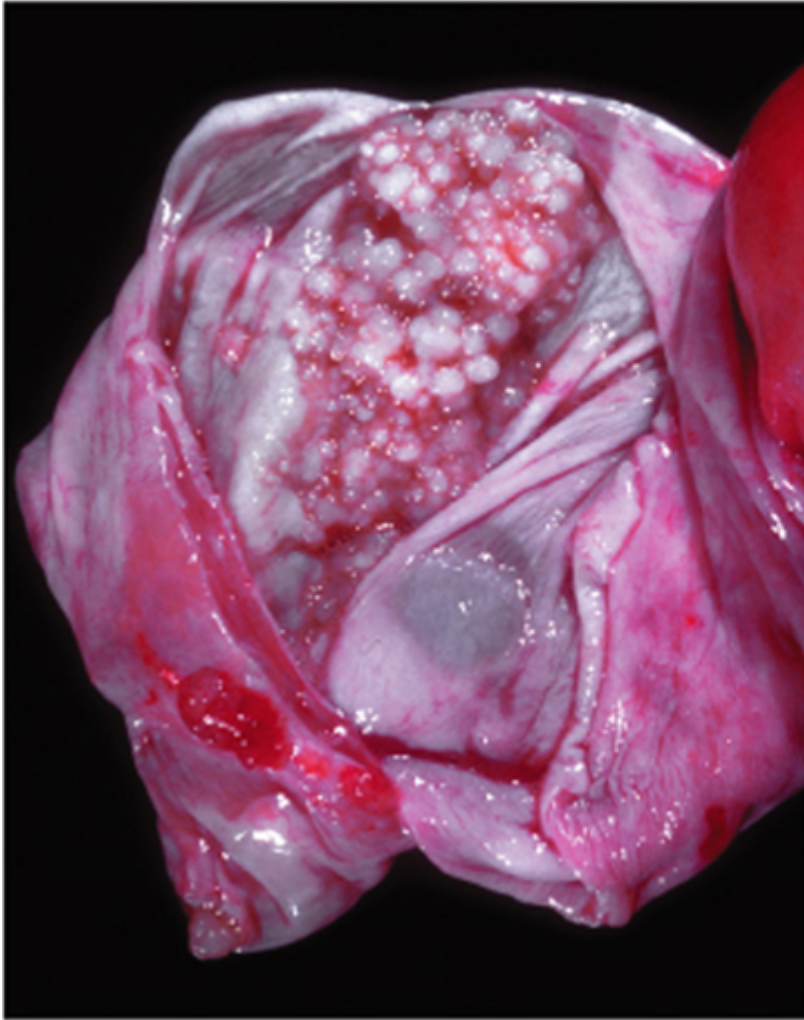
Serous Tumors

- Serous ovarian tumors are the most common type ovarian tumors. They are also the most common group of epithelial tumors. The tumor cells are of serous nature.
- Age is 30 -40.
- Usually cystic filled with clear serous fluid.
- Serous tumors are **often bilateral**.
- Psammoma bodies are commonly seen.
- The tumors are subdivided into **benign (60%), borderline (15%) and malignant (25%)**.
 - **Benign serous tumors (serous cystadenomas)**, are commonly large, cystic and thin-walled, and unilocular. They are lined by serous cells and contain thin, clear yellow fluid.
 - **Borderline serous tumors** cystic with thin wall and smooth surface, but often have multiple papillary excrescences (grape-like clusters), protruding into the lumen in places.
 - **Malignant serous tumors (serous cystadenocarcinoma)** is the commonest malignant ovarian tumor, forming about a third of all cancers of the ovary. The tumors are partly cystic and partly solid with prominent excrescences, often with necrosis and hemorrhage. These tumors usually present with ascites due to abdominal metastases. Treatment: surgery, chemotherapy and radiotherapy. Prognosis; poor.

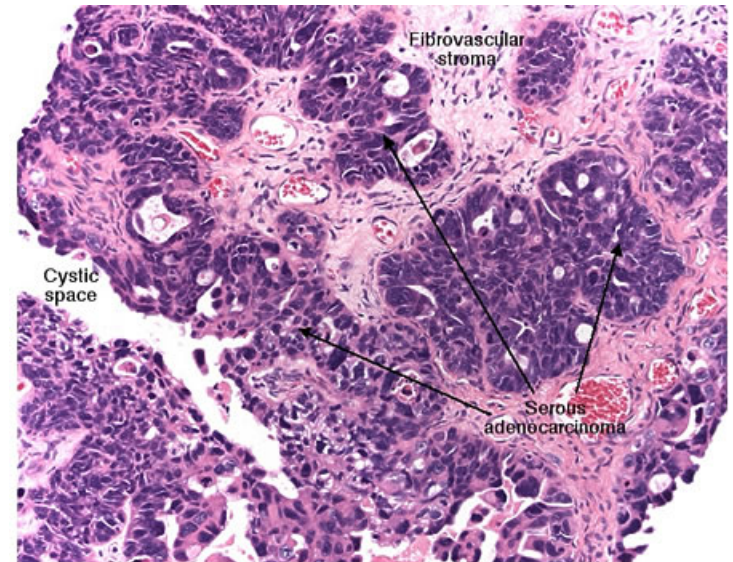
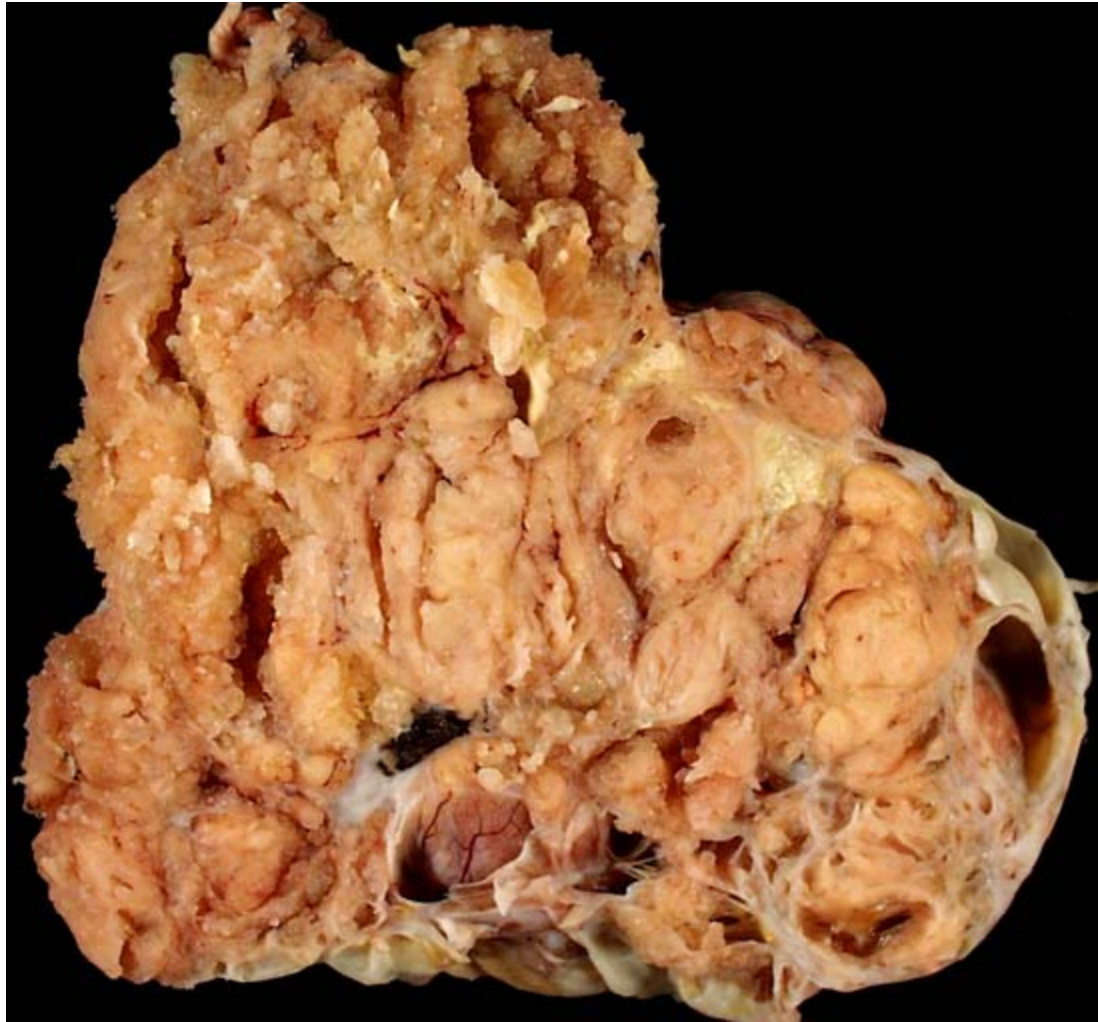Serous cystadenoma



Borderline serous tumor

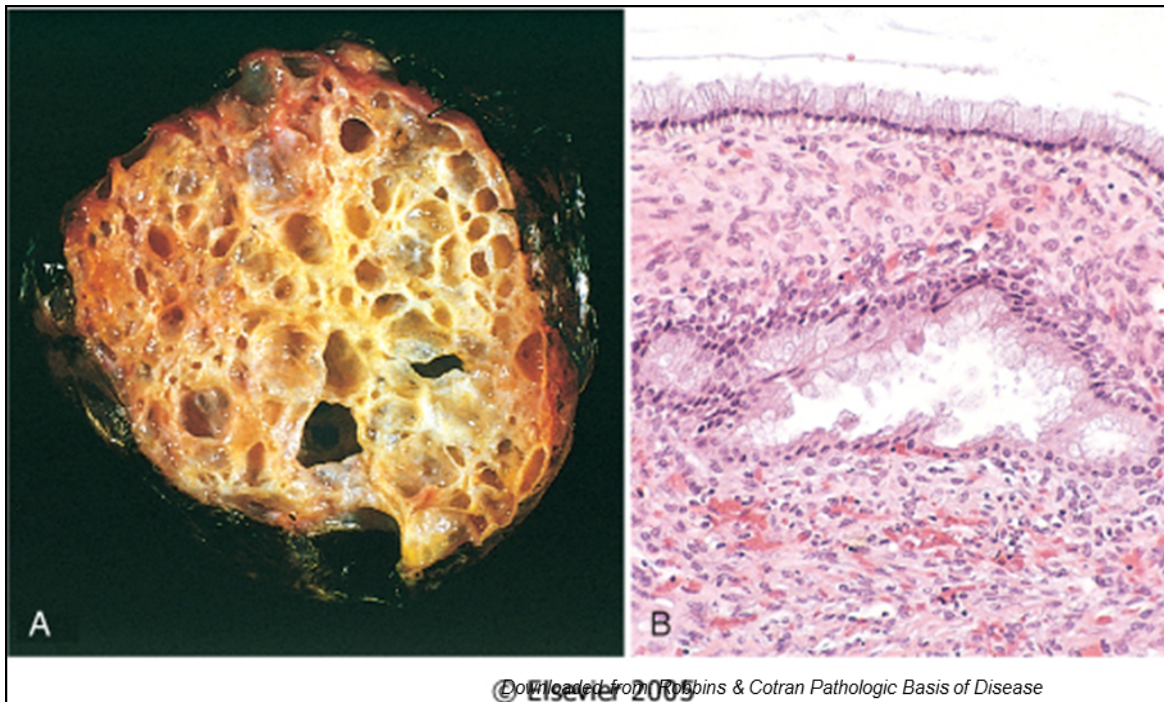


Serous cystadenocarcinoma, ovary



Mucinous Tumors

- Mucinous tumors form about **25%** of all ovarian neoplasms. The tumor cells are mucin-producing cells (which are either endocervical type or intestinal type cells).
- Less likely to be malignant.
- 80% are benign.
- 10% are borderline.
- 10% malignant .
- Bilaterality is uncommon.
- Mucinous tumors can be very large.
- They are typically cystic and multilocular and filled with thick sticky, viscous mucoid fluid.



Mucinous cystadenoma with multicystic cut section and glistening mucoid material; in it. B. the cyst is lined by columnar epithelium (mucin producing)

Other surface epithelial tumors

ENDOMETRIOID TUMORS

- They have tubular gland that resemble the endometrium so the name endometrioid (endometrium-like).
- Endometrioid tumors form **10 to 20%** of all ovarian tumors.
- Most of the endometrioid tumors are malignant (carcinomas).
- Some endometrioid tumors are accompanied by an endometrial carcinoma in the uterus and / or endometriosis in the ovaries.

TRANSITIONAL CELL/ BRENNER TUMOR

- Tumor cell are transitional cell type.
- Most are benign.

Sex Cord-Stromal tumors

Sex Cord-Stromal tumors:

TYPES:

Almost always Benign.

- Thecoma, Fibroma and Fibrothecoma.

With Malignant Potential.

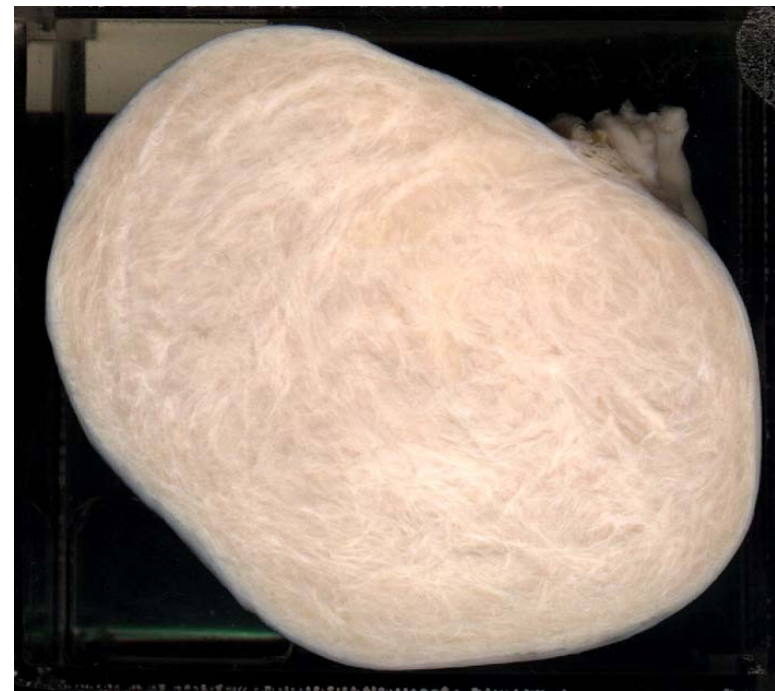- Granulosa Cell tumor.
- Sertoli-Leydig cell tumor.

Others.

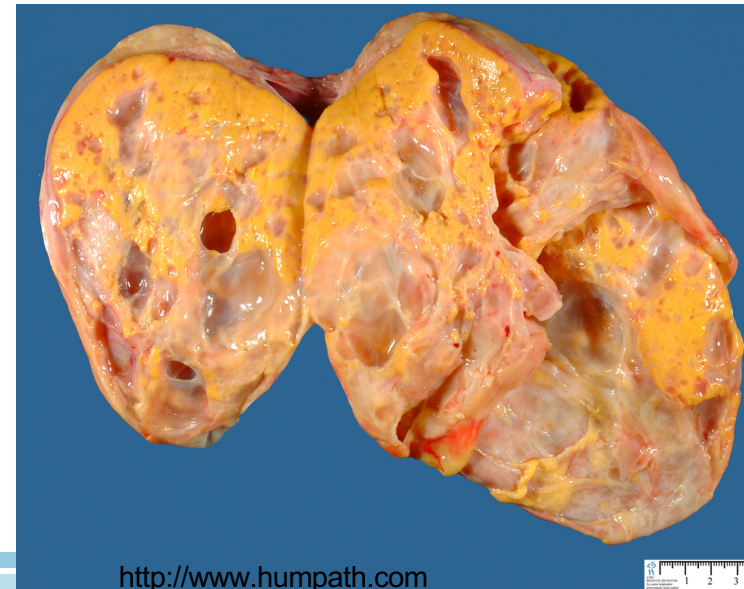Sex Cord Tumors:

Thecoma-Fibroma

- Any age.
- Unilateral.
- Almost always benign. Very rarely malignant.
- They can be either pure thecomas, pure fibromas or fibrothecomomas (mixture of both).
- Pure theca cell tumors produce estrogen.
- Fibromas do not produce estrogen except when mixed with thecomas.
- They are solid tumors, vary in color from white to yellow. Fibromas are whiter, harder with whorled cut surface.
- About 40% cases are associated with ascites and hydrothorax and this combination is called as Meig's Syndrome.



FIBROMA <http://www.med.cmu.ac.th/student/patho>



<http://www.humphath.com>

Sex Cord Tumors:

Granulosa Cell Tumor

- Unilateral, solid and cystic .
- Produce estrogen.
- 2 forms: adult and juvenile.
 - ✓ Adult form is more common in **postmenopausal women**.
 - ✓ The juvenile form is seen the **first three decades**, can present with isosexual precocity.
- can present with abnormal vaginal bleeding.
- can be associated with endometrial hyperplasia and carcinoma .
- About 5 to 25% show malignant behavior.

Sertoli – Leydig cell tumor

- Rare tumors of low malignant potential.
- **All ages.**
- Unilateral yellowish solid tumor.
- **Produces androgens** and present with virilization in 1/3 of cases (oligomenorrhea, amenorrhea, loss of female secondary sex characteristics with hirsutism, clitoromegaly, deepening of voice).

Germ Cell Tumors

Classification of Ovarian Germ Cell Tumors (GCT)

GERM CELL TUMORS

•Teratoma:

- Immature
- Mature (benign)
 - Solid
 - Cystic (dermoid cyst)
 - Monodermal (e.g., struma ovarii, carcinoid)

•Dysgerminoma

•Yolk sac tumor (endodermal sinus tumor)

•Choriocarcinoma

•Embryonal carcinoma

•**Mixed germ cell tumors: mixture** of germ cell tumors occurring together in one tumor mass

NOTE: all ovarian GCTs are considered malignant except mature teratoma.

Germ Cell Tumors:

Teratoma

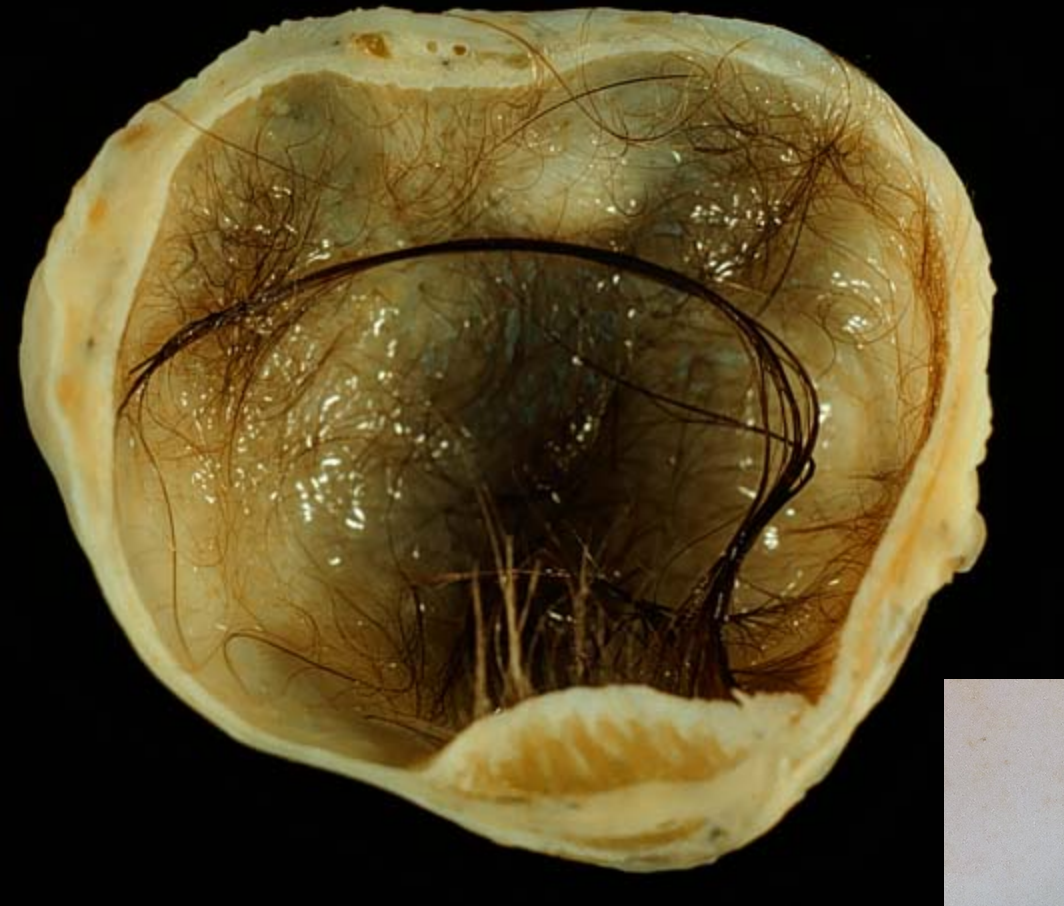- Are 15-20 % of ovarian tumors. Majority occur in the first 2 decades.
- The tumors are subdivided into mature, immature and monodermal.
- **Mature cystic teratoma** are the most common. They are benign.
- **Immature teratomas** are malignant and rare.
- The younger the patient, the greater the likelihood of malignant behavior.

Germ Cell Tumors:

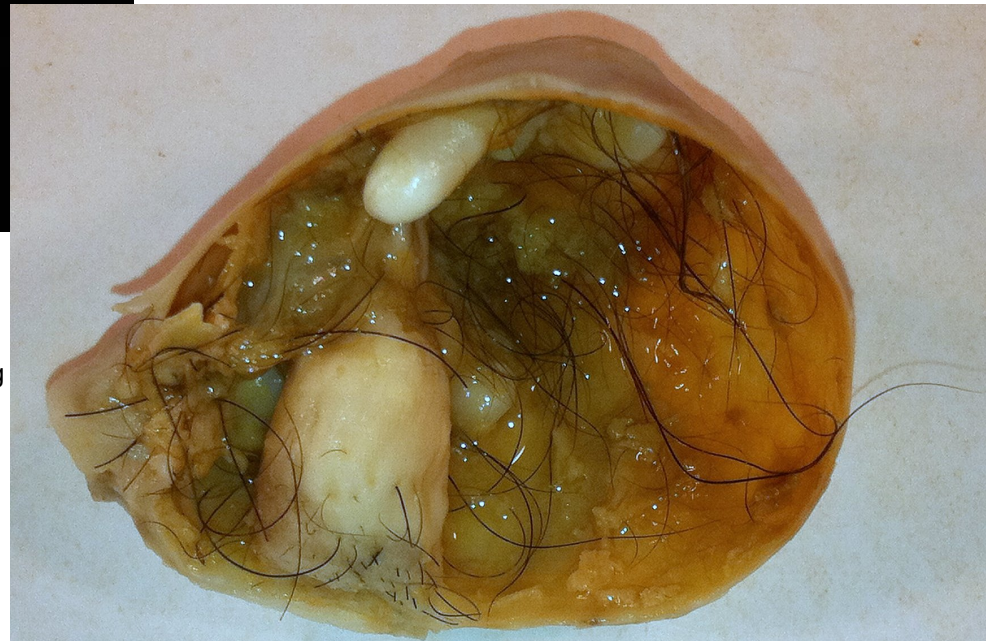Teratoma

Mature cystic teratoma

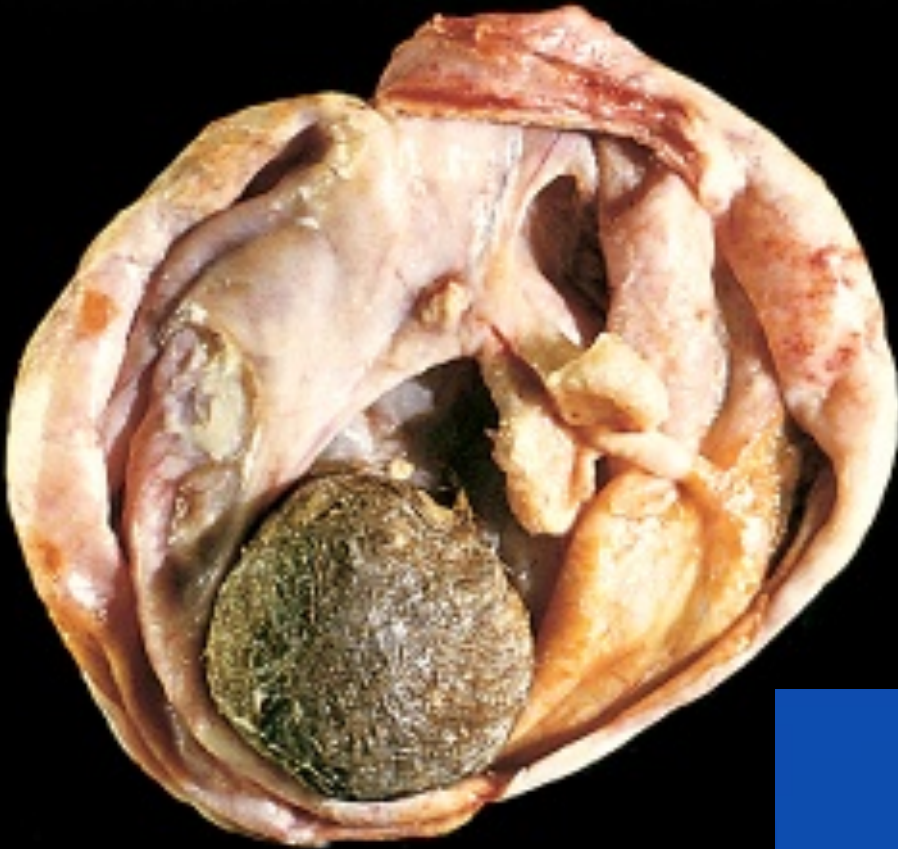- Is the most common ovarian germ cell tumor and the most common type of ovarian teratoma.
- It is a benign neoplasm that typically occurs during reproductive years composed of mature elements of the ectoderm, endoderm and mesoderm.
- It is a cystic tumor, filled with sebaceous material and hair and occasionally teeth.
- Histology: skin, hair, sebaceous glands, and mature neural tissue predominate; cartilage, bone, respiratory and intestinal epithelium are common.
- Complications include torsion, rupture, infection etc.



"Mature cystic teratoma of ovary" by Photograph by Ed Uthman, MD. - <http://web2.airmail.net/uthman/specimens/index.html>. Licensed under Public Domain via Wikimedia Commons - http://commons.wikimedia.org/wiki/File:Mature_cystic_teratoma_of_ovary.jpg [#/media/File:Mature_cystic_teratoma_of_ovary.jpg](#)



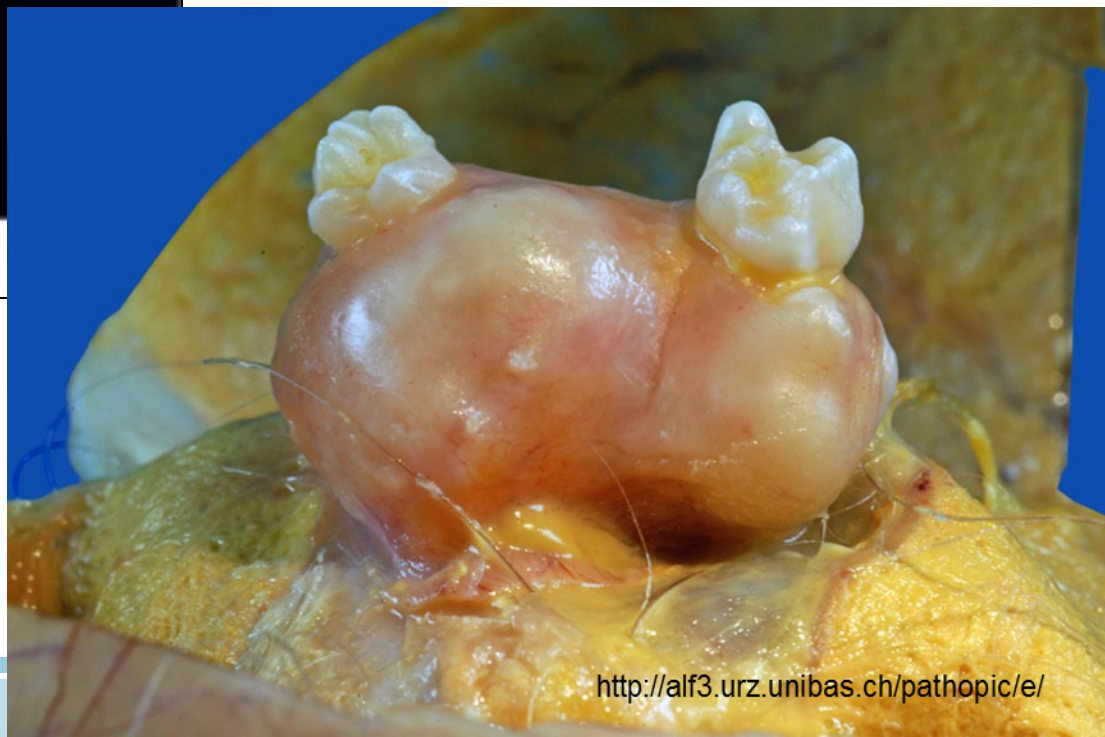http://commons.wikimedia.org/wiki/File:Mature_Cystic_Teratoma_of_the_Ovary_%285560431170%29.jpg



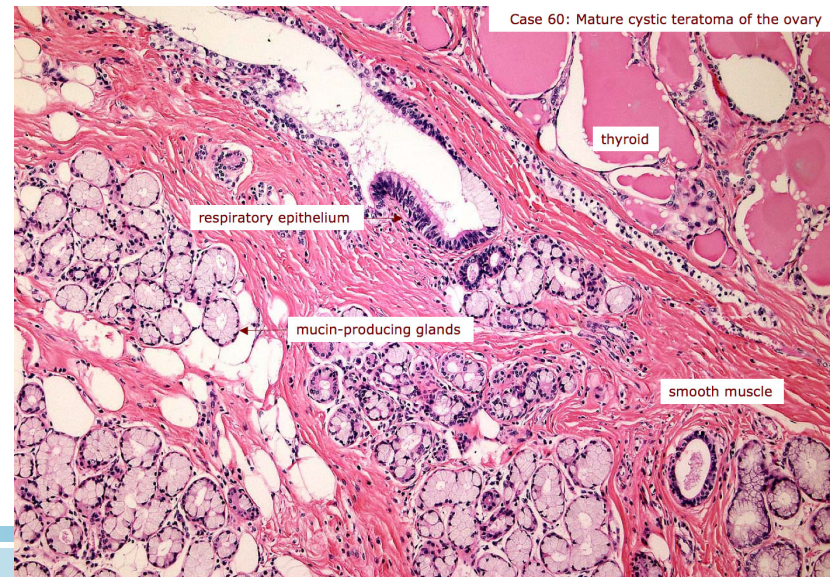
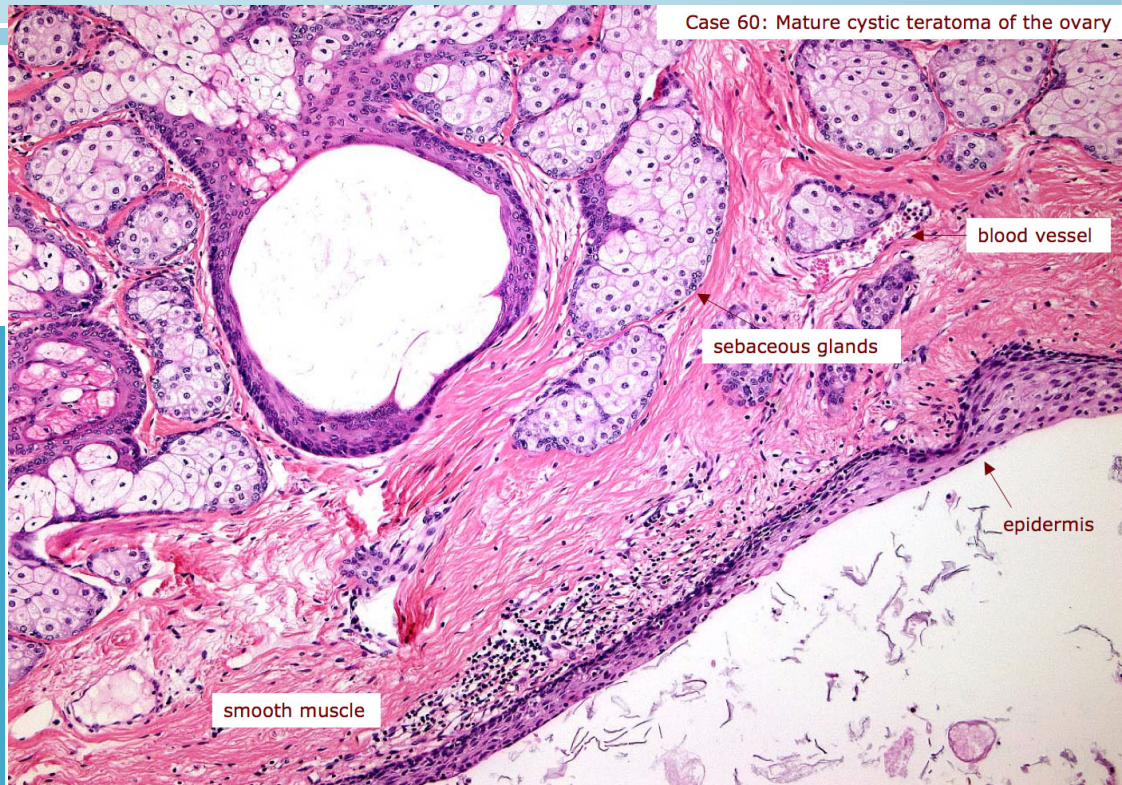
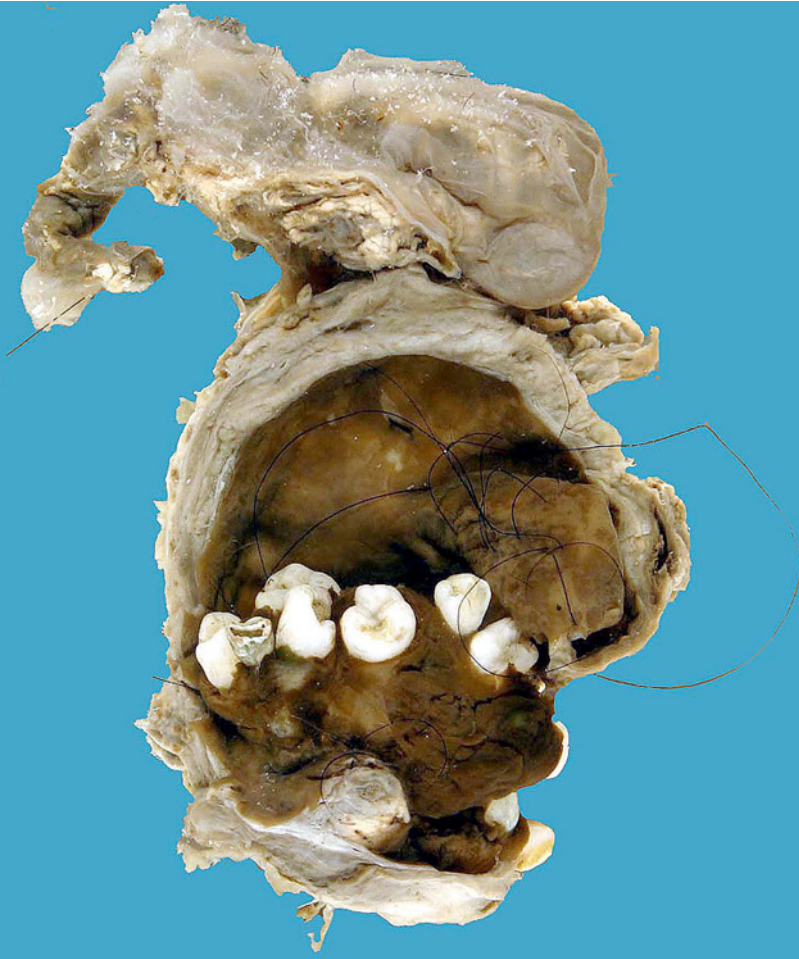
© Elsevier 2005

Opened mature cystic teratoma (dermoid cyst) of the ovary. Hair ball is present.

Robbins & Cotran Pathologic Basis of Disease



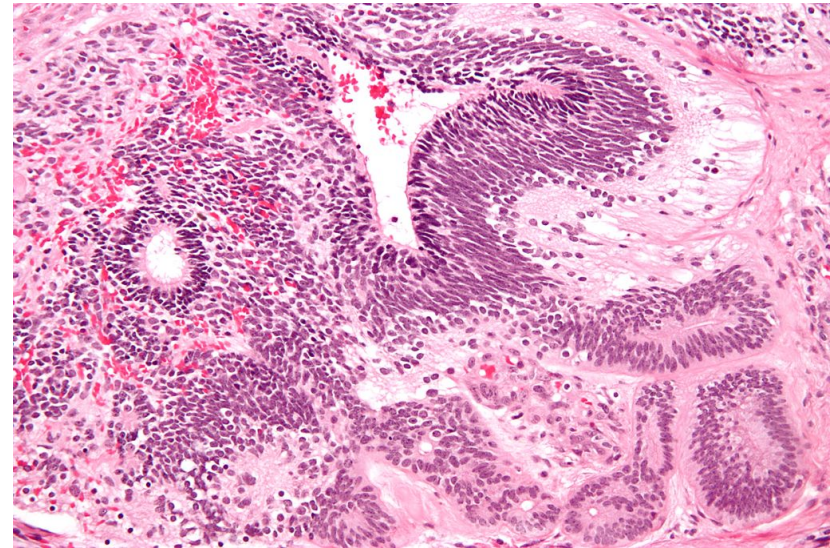
<http://alf3.urz.unibas.ch/pathopic/e/>



Germ Cell Tumors: Teratoma

Immature teratoma

- It is malignant, occurs in children and young adults.
- Usually unilateral and solid.
- Similar to mature teratoma but in addition they contain immature or embryonal tissues especially immature neuroepithelial cells.
- They are graded based on the amount of immature tissue.

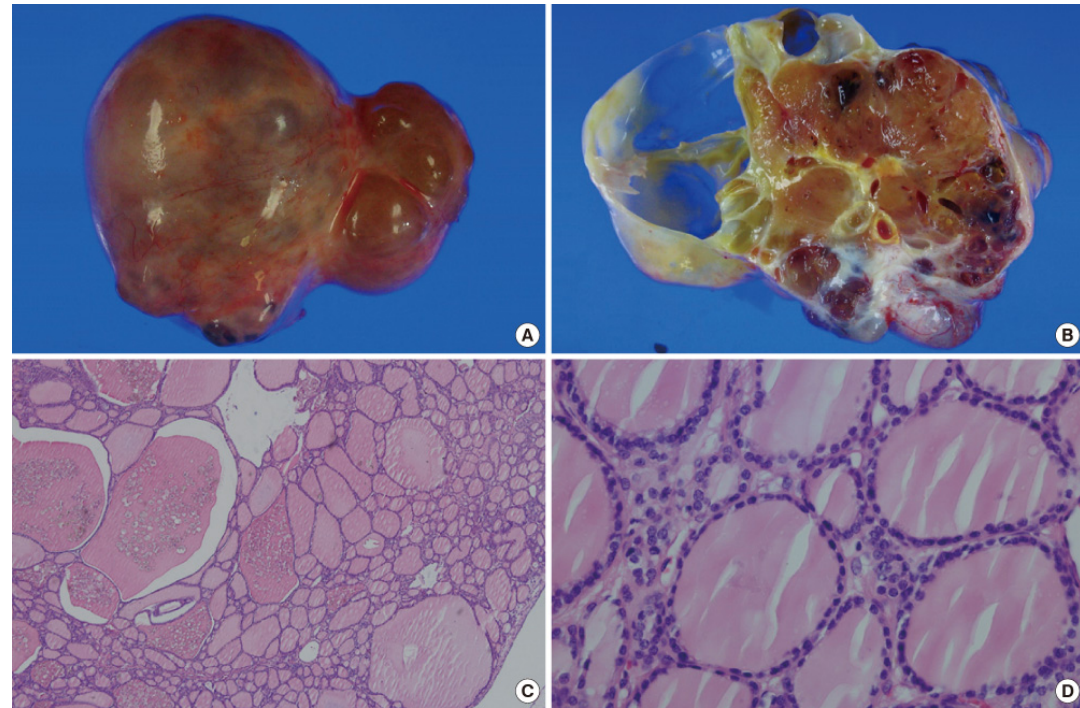


"Immature teratoma high mag" by Nephron - Own work. Licensed under CC BY-SA 3.0 via Wikimedia Commons - http://commons.wikimedia.org/wiki/File:Immature_teratoma_high_mag.jpg#/media/File:Immature_teratoma_high_mag.jpg

Germ Cell Tumors: Teratoma

Monodermal teratoma

- A teratoma composed of one tissue element.
- The most common type of monodermal teratoma is called "struma ovarii", which is made up of mature thyroid tissue.
- The thyroid tissue can sometimes become malignant.
- Sometimes a carcinoid tumor can arise from it.



Other Germ Cell Tumors:

DYSGERMINOMA

- Uncommon.
- Between 10 to 30yrs of age.
- Unilateral and solid mass.
- Microscopically look exactly like its counterpart in testis (Seminoma) and brain (germinoma).
- Malignant.
- PLAP positive.
- Highly sensitive to radiation therapy.

ENDODERMAL SINUS TUMOR

- Also known as yolk sac tumor.
- Under 30 years of age.
- can be pure or a component of a mixed germ cell tumor .
- is radioresistant but responds well to chemotherapy.
- the tumor is associated with elevated serum alpha-fetoprotein and alpha-1-antitrypsin.
- Its characteristic histologic feature : Schiller-Duval bodies.
- Positive for immunostain for alpha-fetoprotein.

Other Germ Cell Tumors:

EMBRYONAL CARCINOMA

- Rare, aggressive, highly malignant, radioresistant but responds to chemotherapy.
- Similar to that seen in testis, usually occurs in combination with other GCTs (mixed GCT).
- 2nd and 3rd decade (children and young adults).
- Unilateral, solid, hemorrhagic and necrotic.
- CD 30 immunostain positive.

CHORIOCARCINOMA

- Rare, aggressive, highly malignant, metastasizes widely through the bloodstream to the lungs, liver, bone etc
- Radioresistant AND chemoresistant.
- Similar to that seen in testis, usually occurs in combination with other GCTs (mixed GCT).
- elevated serum hCG levels.
- unilateral, solid, hemorrhagic tumor, composed of malignant cytotrophoblast and syncytiotrophoblast.
- HCG immunostain positive.

Metastatic carcinoma in ovary

- Accounts for approximately 5% of ovarian tumors.
- Older ages, mostly Bilateral and sometimes very large.
- Primary tumor can be from Gastro-intestinal tract (most common), Breast and lung.
- One of the most classic forms of metastatic carcinoma involving the ovaries is the Krukenberg tumor. This tumor is a metastatic carcinoma composed of signet ring cells in a fibrous background. The most common sites of origin is the GIT (stomach, colon and appendix).