



# Prostate Pathology

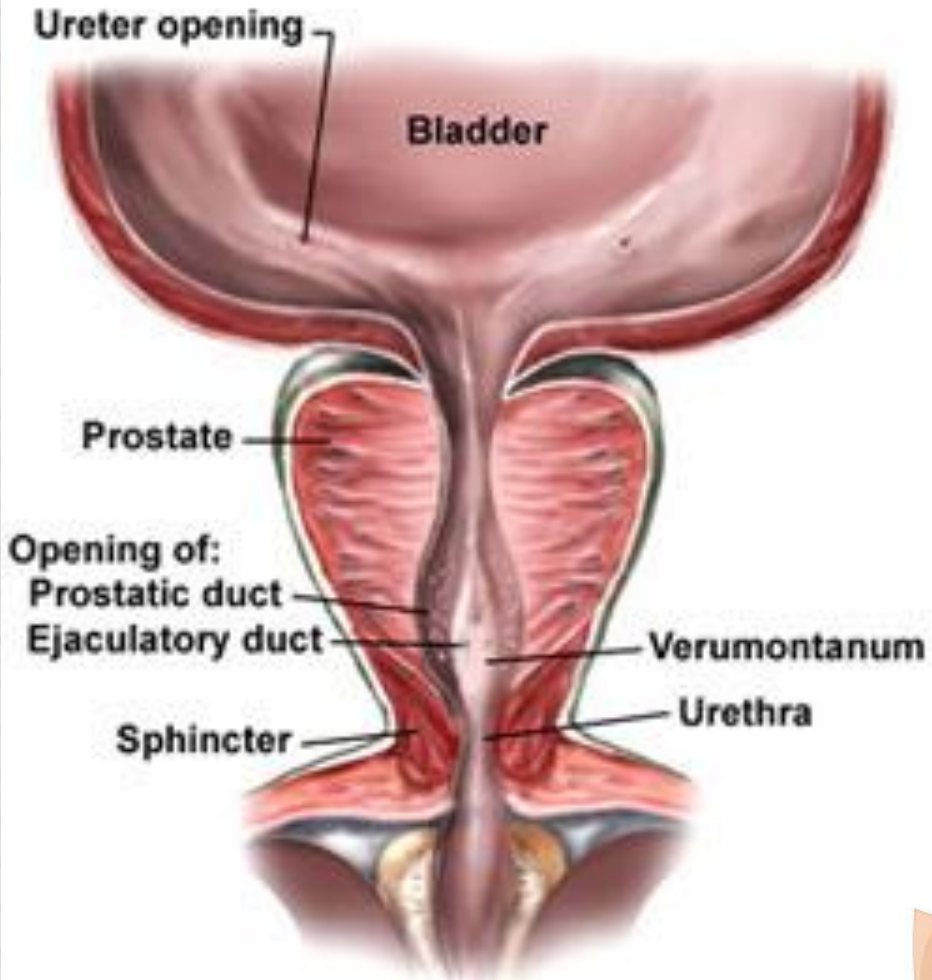
**Reference: Robbins  
& Cotran Pathology  
and Rubin's  
Pathology**

**LECTURE OUTLINE:**

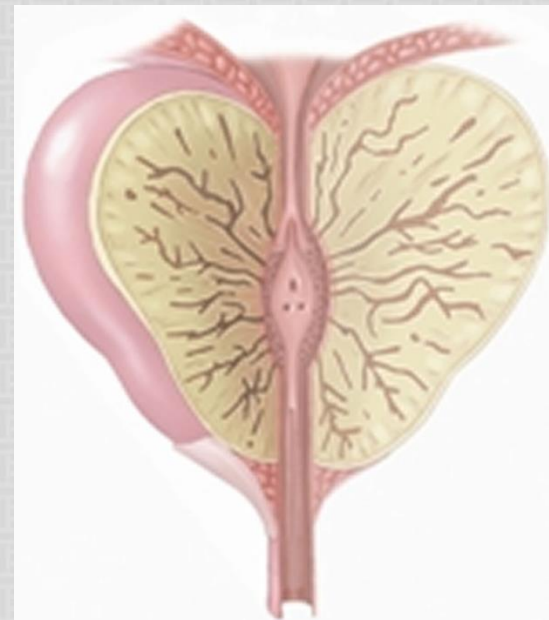
**PROSTATIC HYPERPLASIA AND CANCER OF THE PROSTATE.**

At the end of this lecture, the student should be able to:

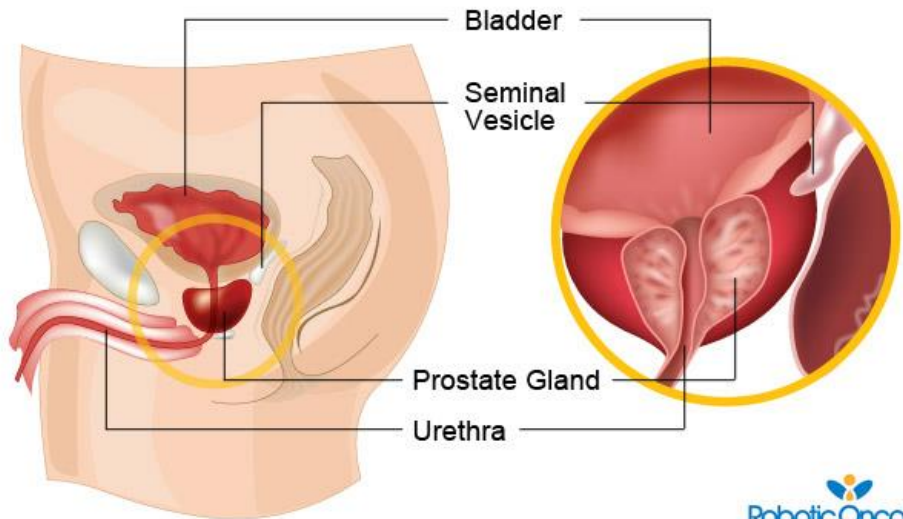
- A. Understand the basic anatomical relations and zones of the prostatic gland.
- B. Know the epidemiology, pathogenesis and histopathologic features of benign prostatic hyperplasia and carcinoma of the prostate.



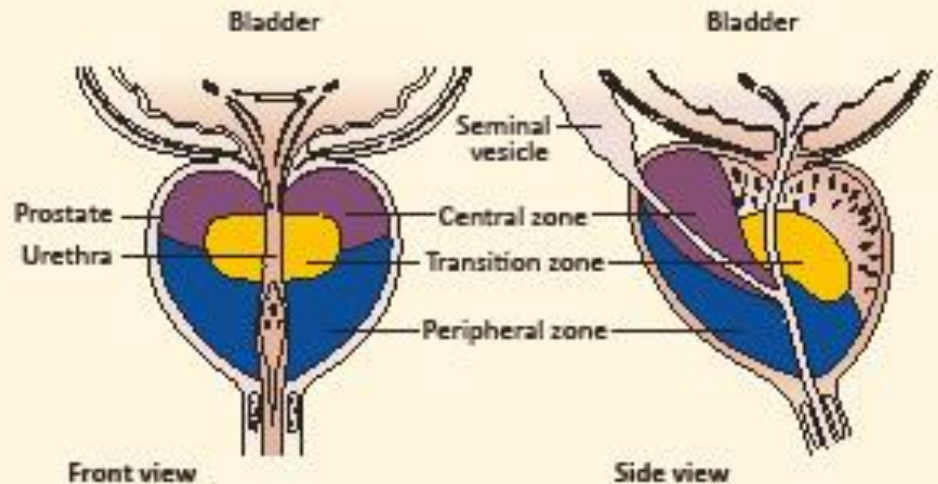
<http://www.yoursurgery.com>



<http://napaurology.com>



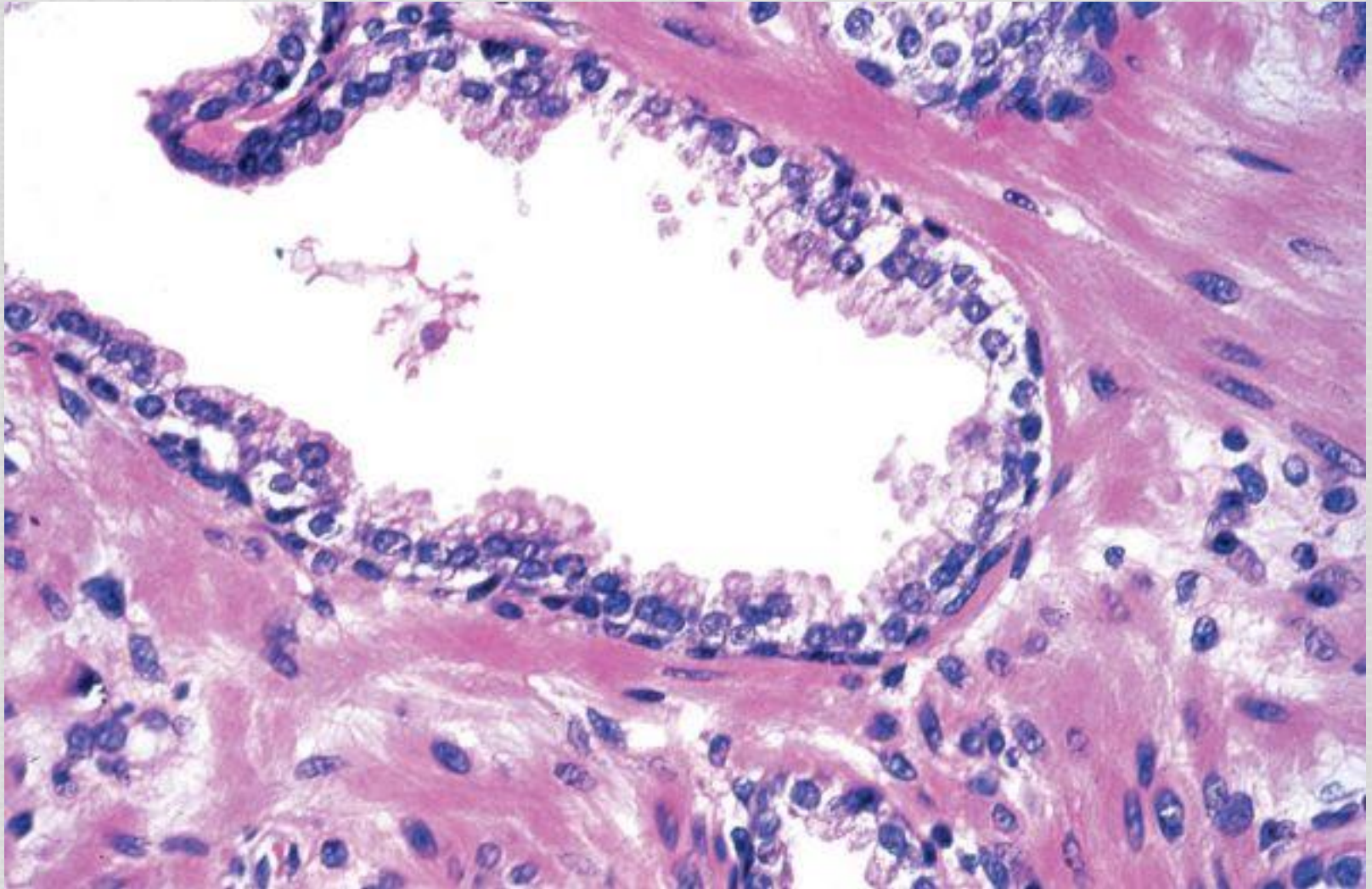
# PROSTATE ANATO



<http://www.theprostatecentre.com>

- Prostate weighs 20 grams in normal adult
- Retroperitoneal organ, encircling the neck of bladder and urethra
- Devoid of a distinct capsule
- The prostate is divided into different zones. They are Central, Peripheral and Transitional zones. The transition zone is the middle area of the prostate, between the peripheral and **central** zones. It surrounds the urethra as it passes through the prostate
- The majority of **prostate cancers are found in the peripheral zone and benign nodular hyperplasia in the transitional zone.**
- Microscopically the prostate is a tubulo-alveolar organ. The prostate glands are lined by two layers of cells, basal cells and columnar secretory cells

# NORMAL PROSTATE



Picture Taken from Robbins and Cotran Pathologic basis of disease. 8<sup>th</sup> edition, Chapter 21, 2010 Sanders

# BENIGN PROSTATIC HYPERPLASIA (BPH)

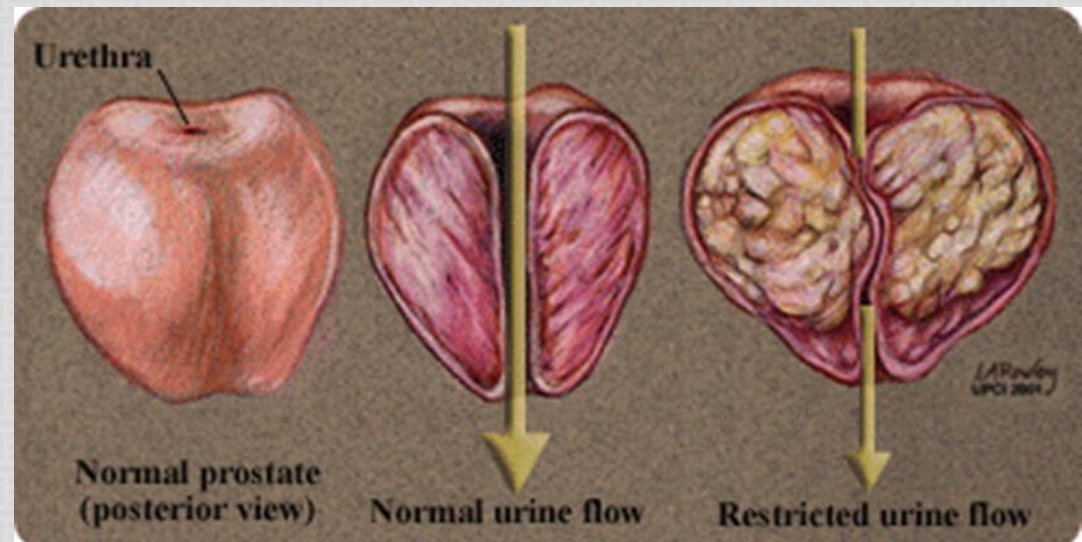
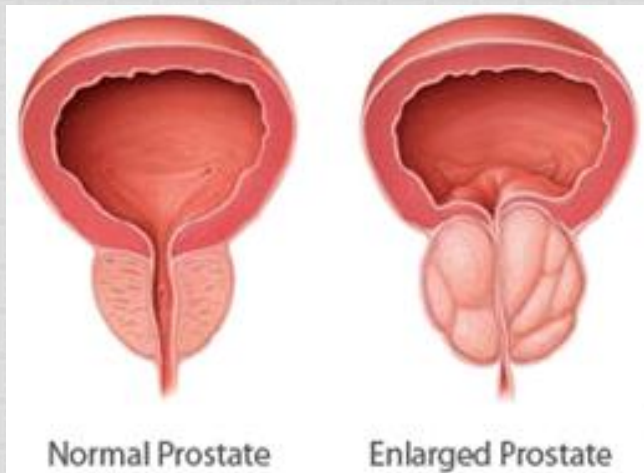
- ▶ Also known as benign nodular hyperplasia
- ▶ Extremely common lesion in men over age 50.
- ▶ About 20% men have BPH by age 40
- ▶ About 70% men have BPH by age 60
- ▶ About 90% men have BPH by age 80.
- ▶ Hyperplasia of glands and stroma results in large nodular enlargement in the periurethral region of the prostate.
- ▶ Once the nodules become large they compress the prostatic urethra causing either partial, or complete obstruction of the urethra.
- ▶ Nodular hyperplasia is not a premalignant lesion

# BPH: PATHOGENESIS

- The essential cause of BPH is unknown
- The pathogenesis is related to the action of androgens.
- Dihydrotestosterone (DHT) is the ultimate mediator for prostatic growth. It increases the proliferation of stromal cells and inhibits epithelial cell death. Therefore DHT is implicated in the pathogenesis of both benign prostatic hyperplasia (BPH) and prostate cancer.
- Testosterone is converted to dihydrotestosterone (DHT) by 5-alpha reductase enzymes.
- Drugs that act as inhibitors of 5-alpha reductase, therefore have an important role in the prevention and treatment of BPH and prostate cancer.
- Prepubertal castration prevents BPH

# BPH: GROSS MORPHOLOGY

- ▶ The prostate weighs between 60 and 100 grams
- ▶ The hallmark of BPH is nodularity due to glandular and fibro-muscular proliferation.
- ▶ Nodular hyperplasia begins in the inner aspect of the prostate gland, the transition zone
- ▶ Cut-section shows nodules which vary in size, color and consistency depending on which element is proliferating more (glandular or fibro-muscular).
- ▶ It compresses the wall of the urethra resulting in a slit-like orifice.





# BPH: MICROSCOPY

- ▶ Microscopically, the main feature of BPH is nodularity
- ▶ The nodules can be:
  - ❖ purely stromal nodules composed mainly of fibromuscular element
  - OR
  - ❖ fibroepithelial with both glandular and fibromuscular component. There is aggregation of small to large to cystically dilated glands, lined by two layers of epithelium surrounded by fibromuscular stroma.
- ▶ Needle biopsy doesn't sample the transitional zone where BPH begins and occurs, therefore the diagnosis of BPH cannot be made on needle biopsy

# BPH: CLINICAL FEATURE & TREATMENT

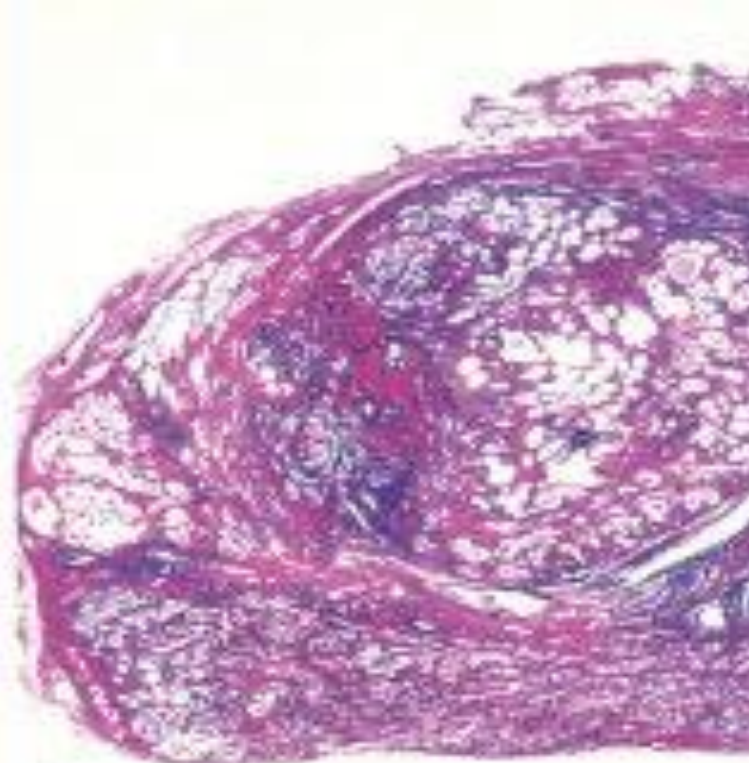
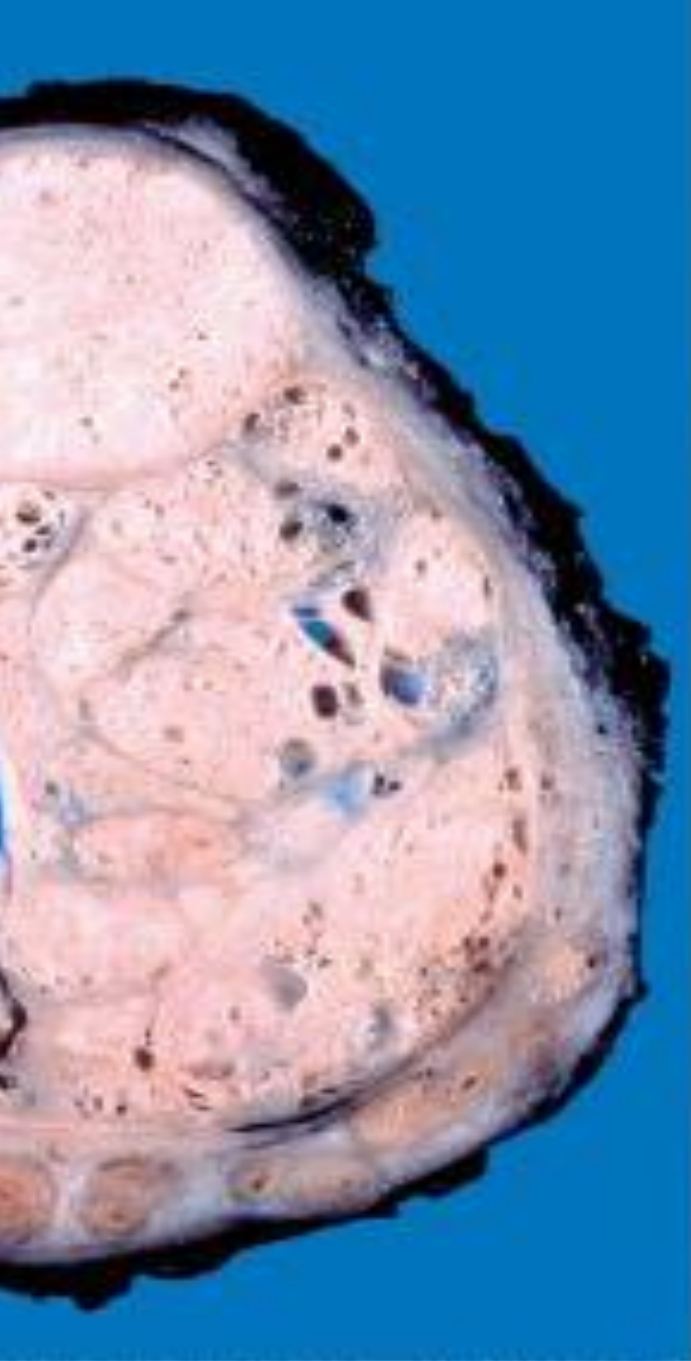
## C/F:

- ❖ The nodule compress the prostatic urethra → urethral obstruction → leads to retention of urine in the bladder → bladder hypertrophy.
- ❖ The inability to empty the bladder completely leads to increase volume of residual urine → therefore infection
- ❖ Increased urinary frequency
- ❖ Nocturia
- ❖ Difficulty in starting and stopping the stream of urine
- ❖ Dysuria
- ❖ Some patients present with acute urinary retention.

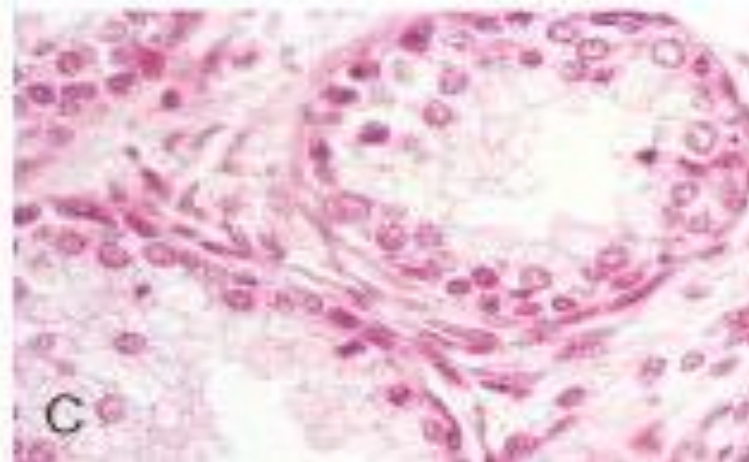
## Treatment:

- ❖ Mild cases of BPH may be treated with  $\alpha$ -blockers and 5- $\alpha$ -reductase inhibitors
- ❖ Moderate to severe cases require transurethral resection of the prostate (TURP)

# BPH

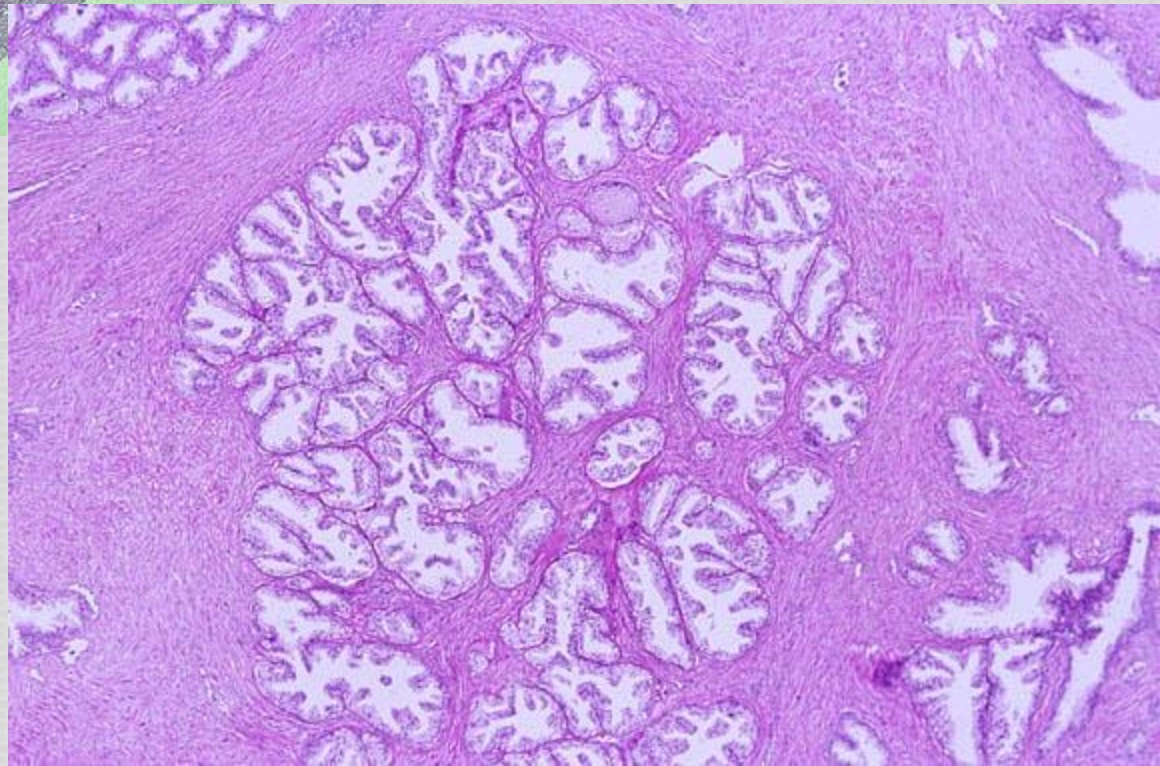
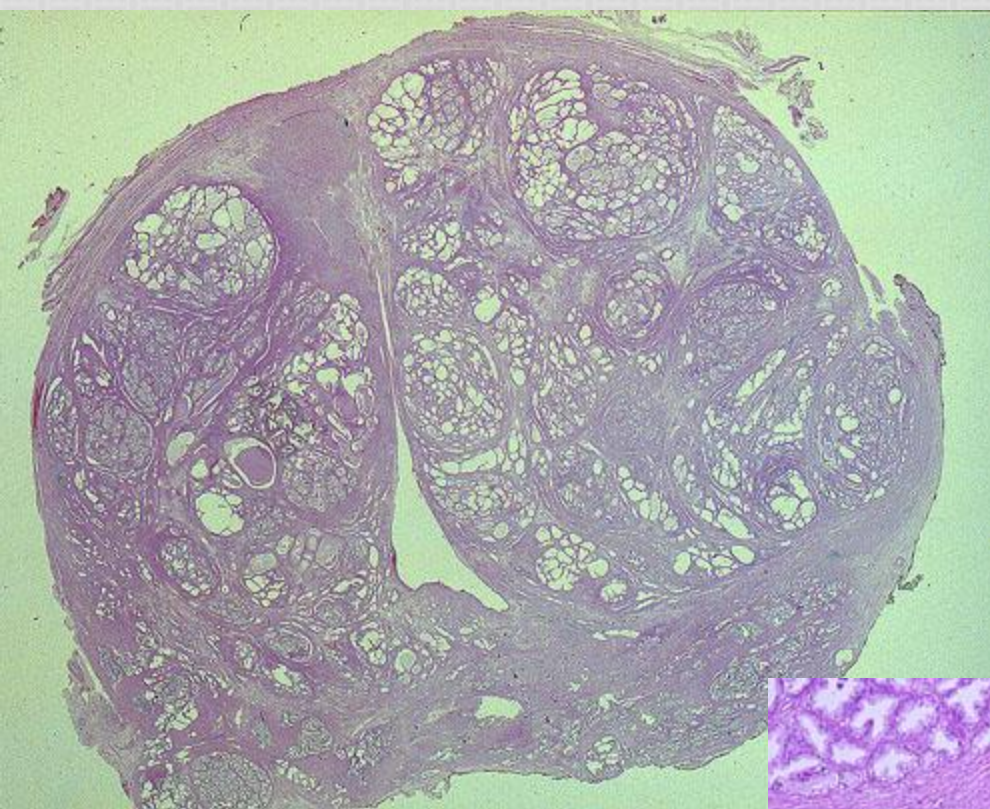


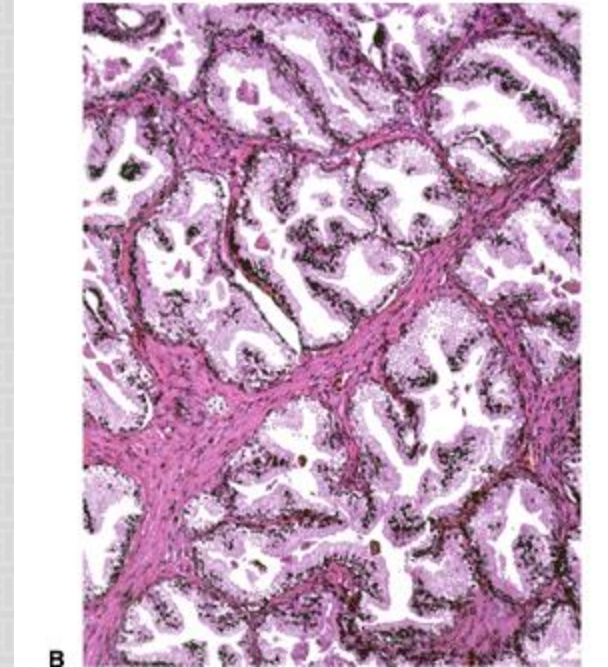
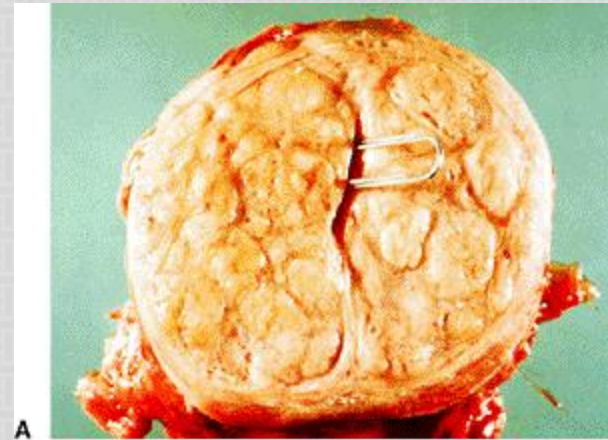
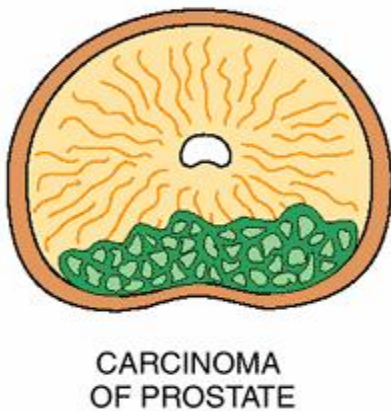
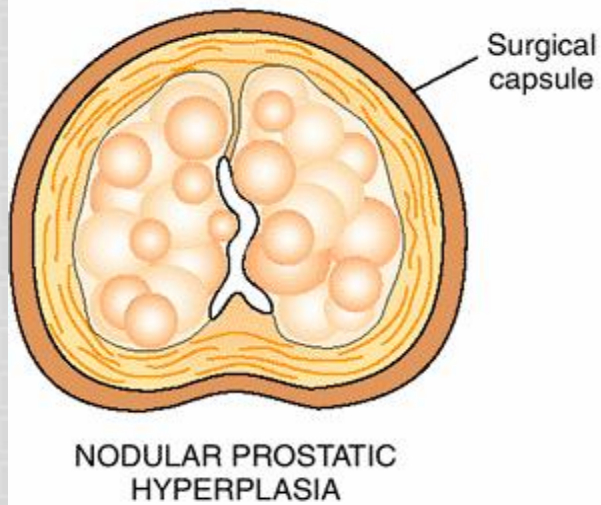
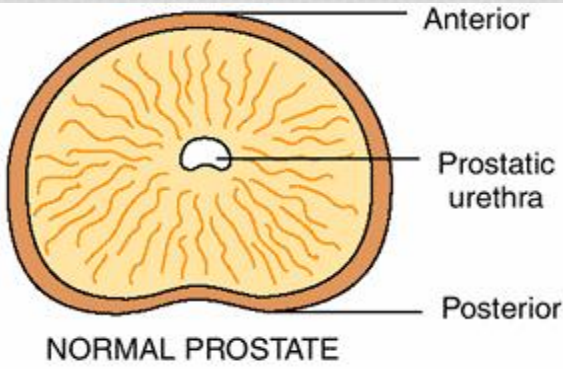
B



C

# Nodular hyperplasia





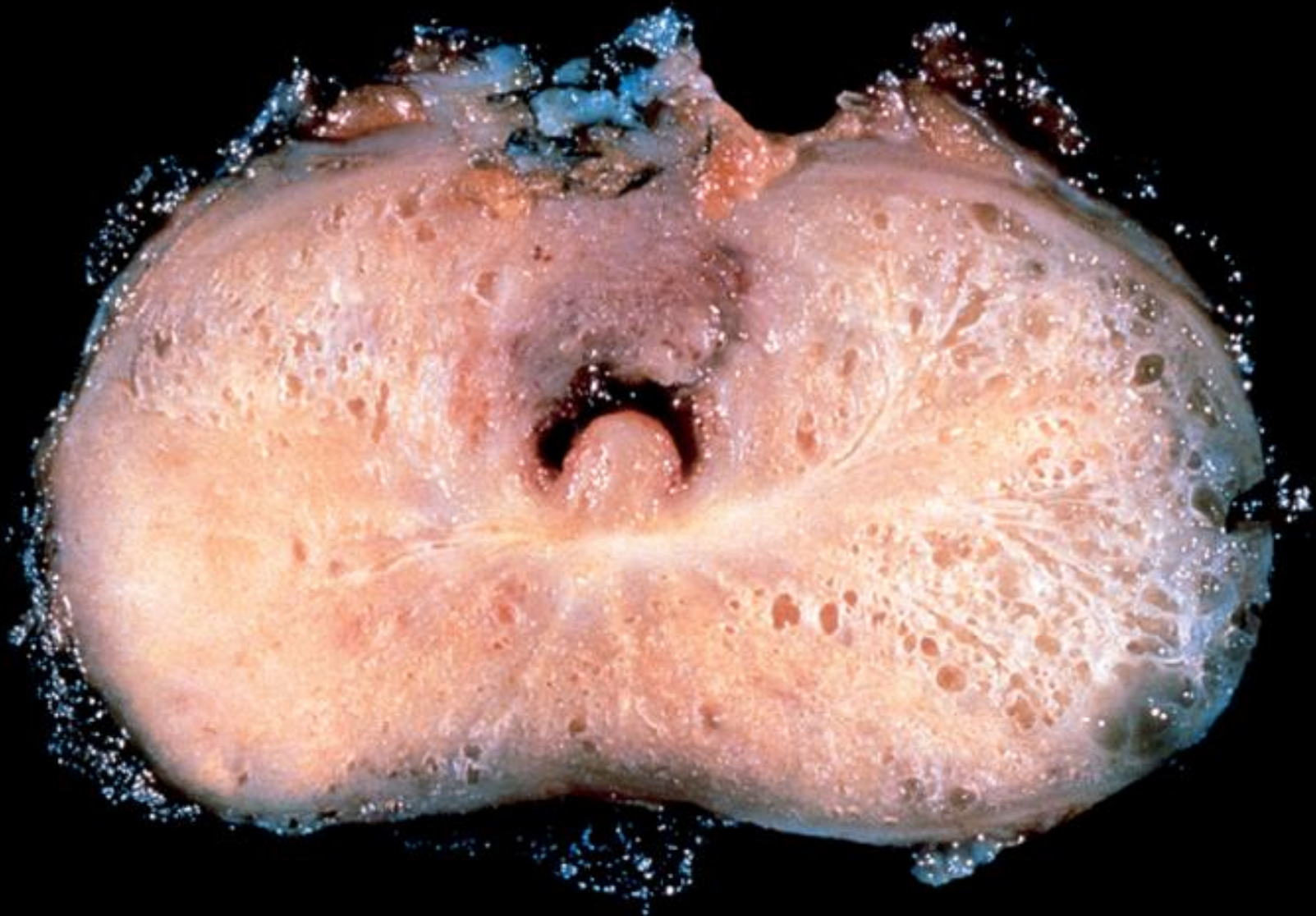
**Figure A & B: BPH**

# PROSTATIC ADENOCARCINOMA

- ▶ The a common form of cancer in men
- ▶ Disease of men over age 50
- ▶ More prevalent among African Americans
- ▶ These tumors show a wide range of clinical behaviors
- ▶ Etiology: Several risk factors : Age, race, family history, hormone level (androgens) and environmental influences.
- ▶ Androgen are believed to play a major role in the pathogenesis

## PROSTATIC ADENOCARCINOMA: MORPHOLOGY

- ▶ 70% arises in the peripheral zone in the posterior part of the gland
- ▶ Tumor is firm and gritty and is palpable on rectal exam
- ▶ Spread by direct local invasion and through blood stream and lymphatics
- ▶ Local extension most commonly involves the periprostatic tissue, seminal vesicles and the base of the urinary bladder (leading to ureteral obstruction)

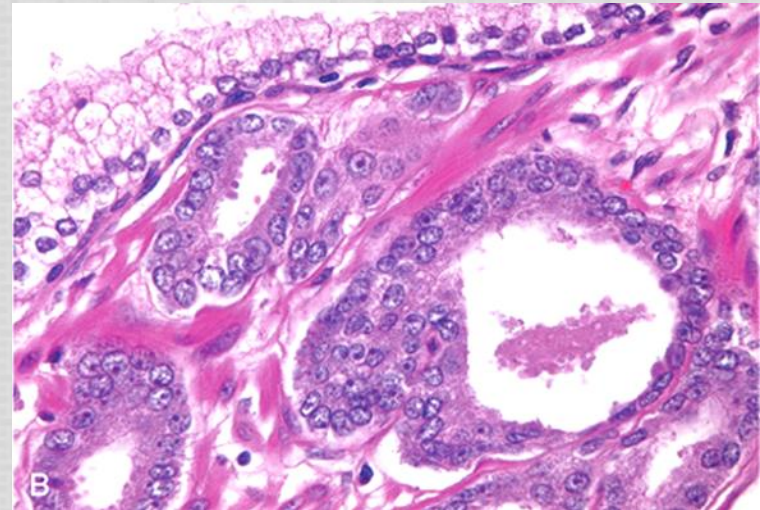
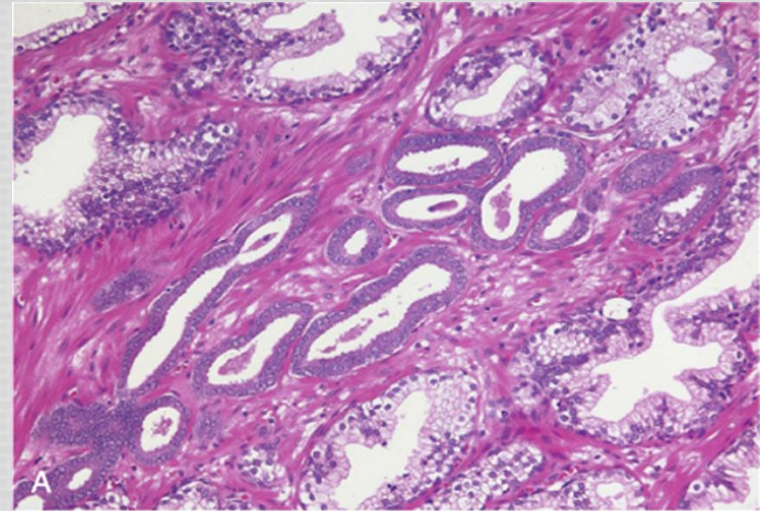


Picture Taken from Robbins and Cotran Pathologic basis of disease. 8<sup>th</sup> edition, Chapter 21, 2010 Sanders



## PROSTATIC ADENOCARCINOMA: MICROSCOPY

- ▶ Histologically, most lesions are adenocarcinomas that produce well-defined gland patterns.
- ▶ The malignant glands are lined by a single layer of cuboidal or low columnar epithelium with large nuclei and one or more large nucleoli. Nuclear pleomorphism is not marked. The outer basal cell layer typical of benign glands is absent
- ▶ Commonly there is perineural invasion.



# PROSTATIC ADENOCARCINOMA

- Metastases first spread via lymphatics: initially to the obturator nodes and eventually to the para-aortic nodes
- Hematogenous extension occurs chiefly to the bones. The bony metastasis are typically osteoblastic .

## GRADING PROSTATIC ADENOCARCINOMA: GLEASON GRADING & SCORING

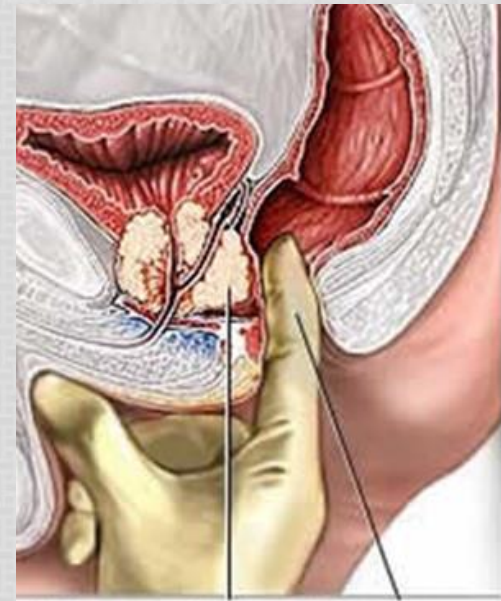- ▶ Gleason system is a histological grading and scoring system for prostatic adenocarcinoma done on the microscopic level.
- ▶ There are five grades (1 to 5) depending on the degree and pattern of differentiation as seen microscopically (in which they range from, grade 1 = well-differentiated to grade 5 = very poorly differentiated).
- ▶ Prostate carcinomas usually have more than one type of grade in the tumor mass. The two most common types of grades seen in the biopsy for each cancer patient are added and the final sum is called the Gleason score.
- ▶ Gleason Grading and Scoring in prostate cancer is very useful in predicting prognosis of a patient.

## **STAGING PROSTATIC ADENOCARCINOMA**

Staging in prostate cancer depends on the TNM system. It is the most important indicator of prognosis.

## PROSTATIC ADENOCARCINOMA: CLINICAL FEATURES

- ▶ Microscopic (or very small size) cancers are asymptomatic and are discovered incidentally.
- ▶ Most arise in the peripheral zone, away from urethra and therefore the urinary symptoms occur late.
- ▶ Occasionally patients present with back pain caused by vertebral metastases
- ▶ Careful digital rectal examination may detect some early cancers.
- ▶ PSA (Prostate Specific Antigen) levels are important in the diagnosis and management of prostate cancer. However, a minority of prostate cancers may have low PSA
- ▶ PSA is organ specific but not cancer specific because it could be increased in BPH and prostatitis.
- ▶ A transrectal needle biopsy is required to confirm the diagnosis



<http://www.medicalhealthguide.com>

## **PROSTATIC ADENOCARCINOMA: TREATMENT**

- ▶ Surgery, radiotherapy and hormonal therapy
- ▶ 90% of treated patients are expected to live for 15 years
- ▶ Currently the most acceptable treatment for clinically localized cancer is radical surgery
- ▶ Locally advanced cancers can be treated by radiotherapy and hormonal therapy. Hormonal therapy (Anti-androgen therapy) can induce remission.
- ▶ Advanced, metastatic carcinoma is treated by androgen removal treatment, either by orchiectomy or by hormonal anti-androgen therapy.
- ▶ The prognosis depends on the Gleason score and stage of tumor.

# PROSTATIC INTRAEPITHELIAL NEOPLASIA (PIN)

- ▶ PIN is the precursor lesion for invasive carcinoma. It can be low grade PIN or high grade PIN. (high grade PIN is like carcinoma in situ)
- ▶ PIN like prostatic carcinoma occurs in the peripheral zone.