

# Female Reproductive System

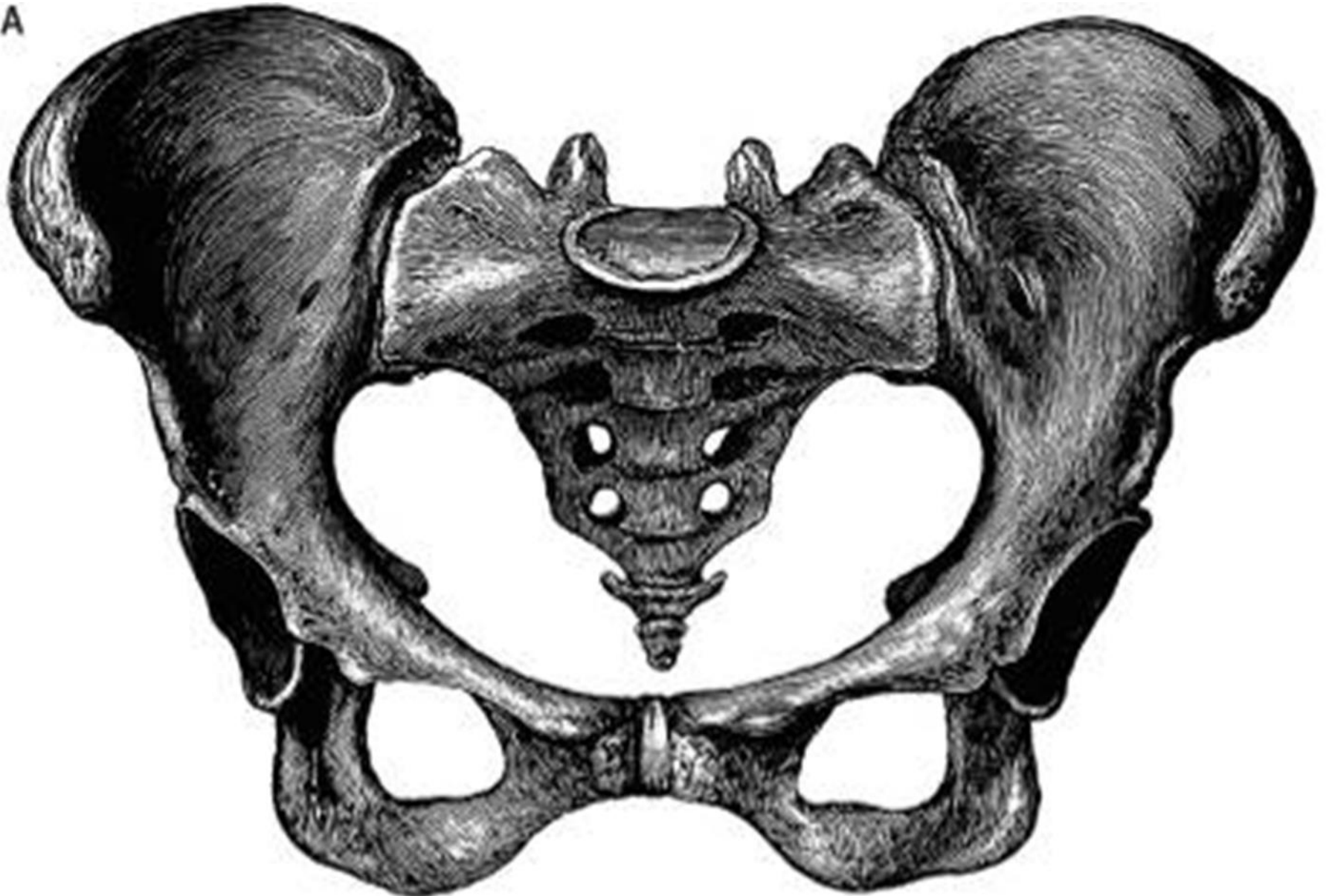## Anatomy Practical

**Anatomy Department**

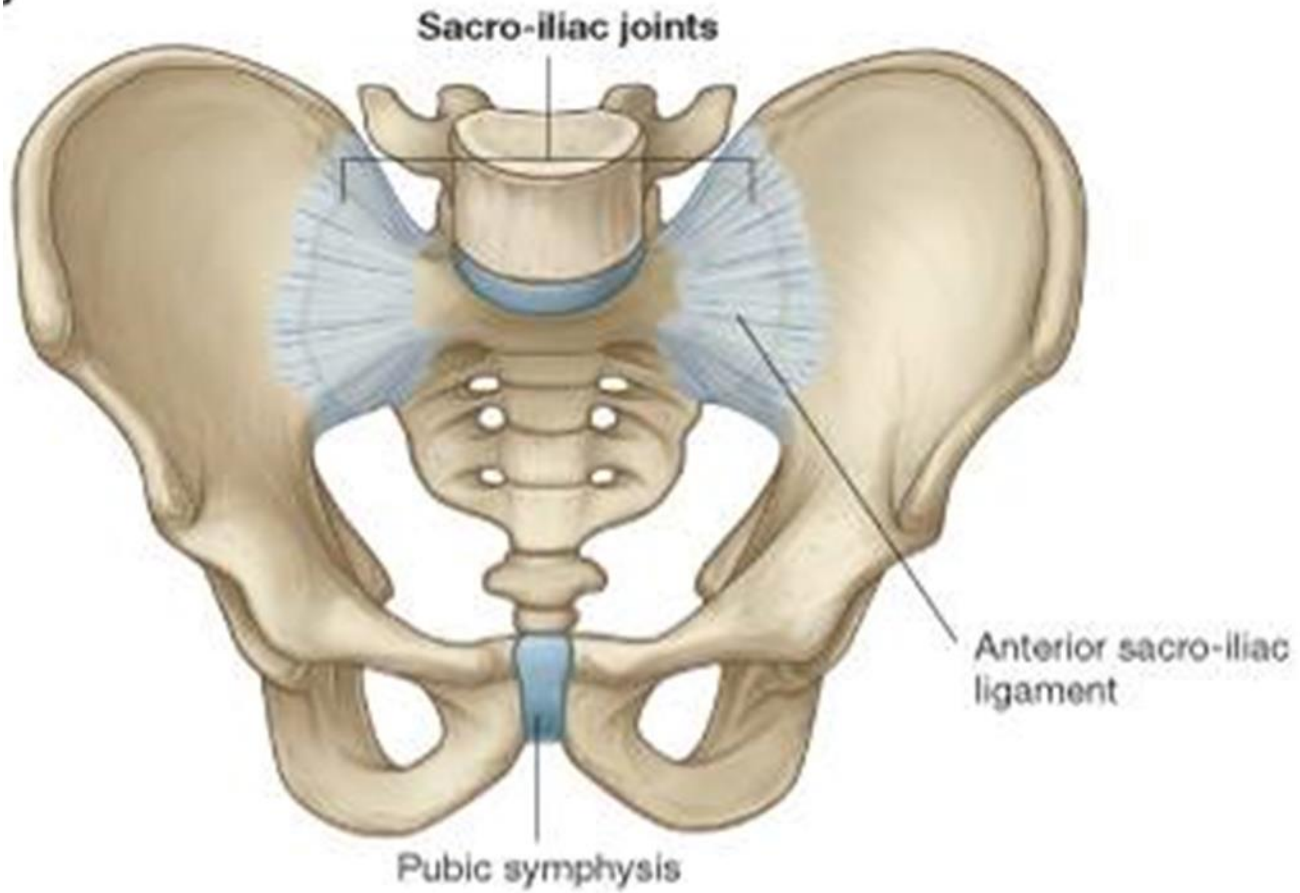
**College of Medicine**

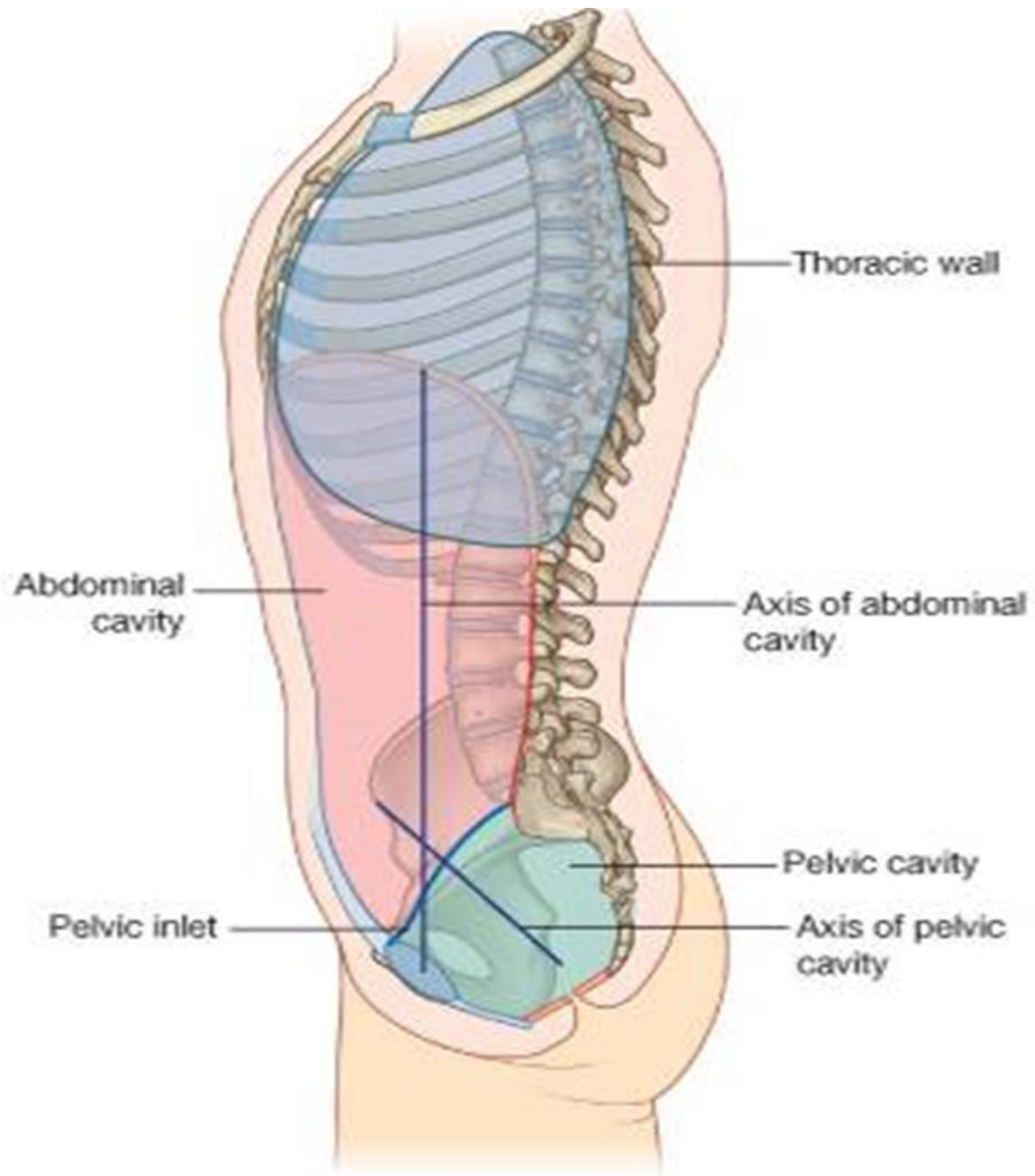
**King Saud University**

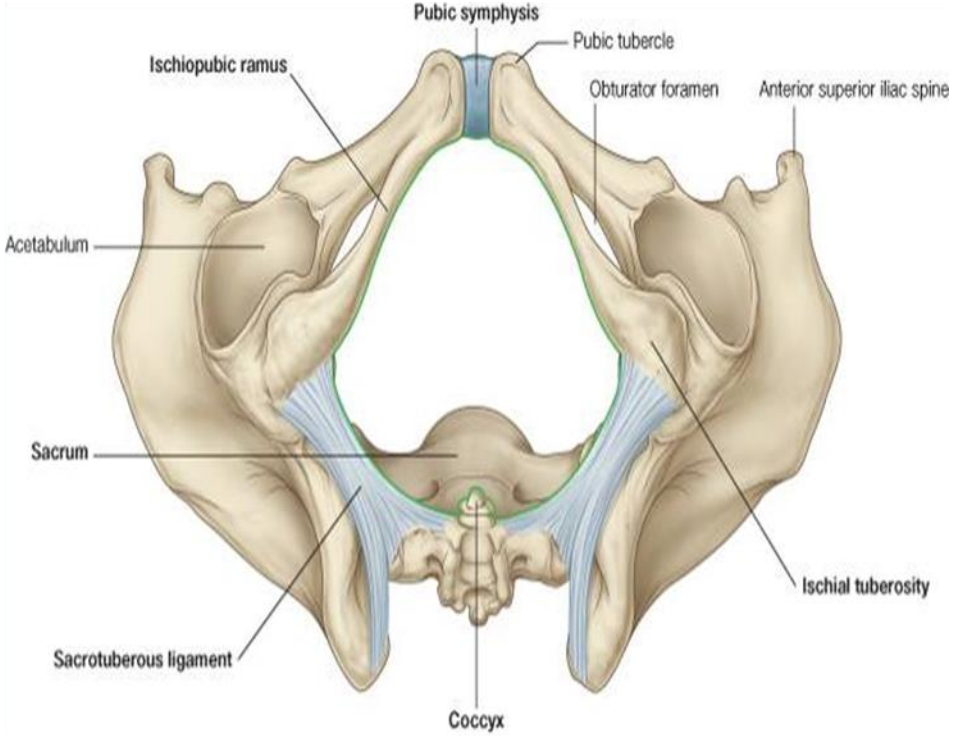
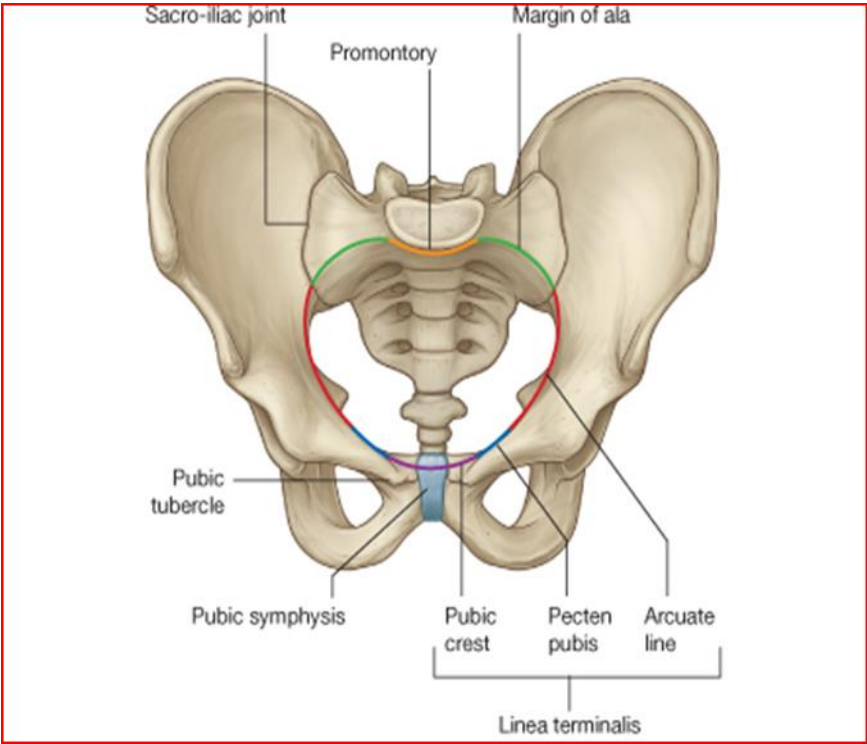
A



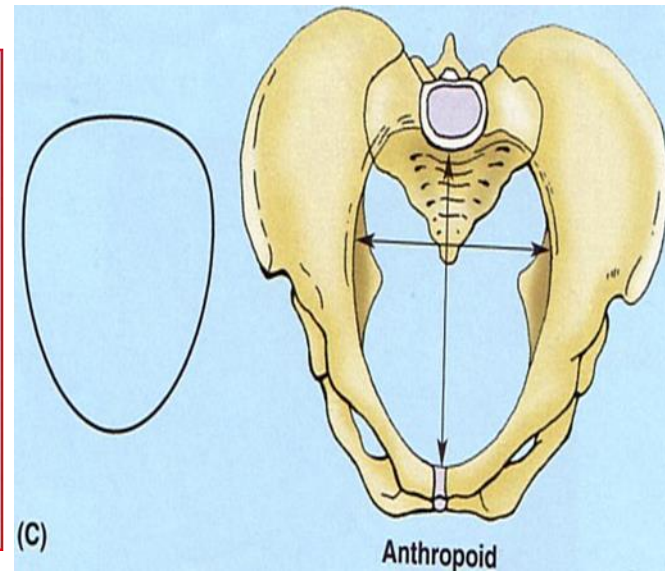
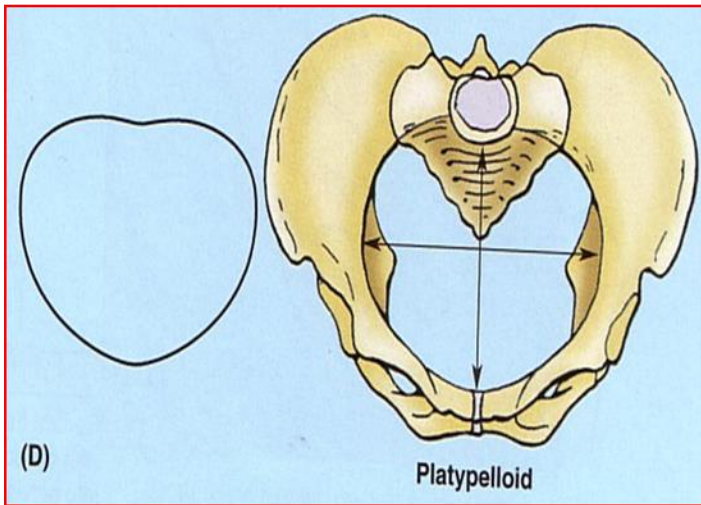
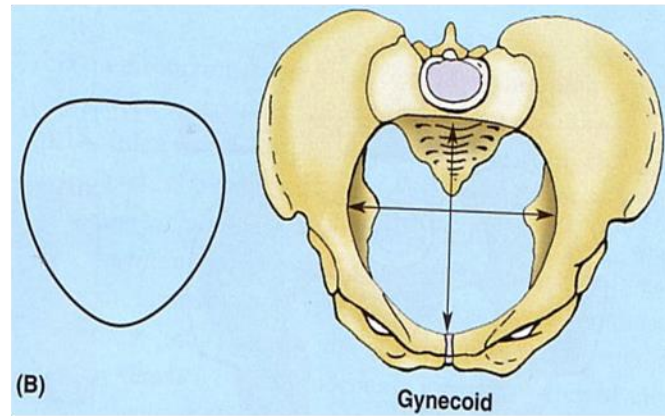
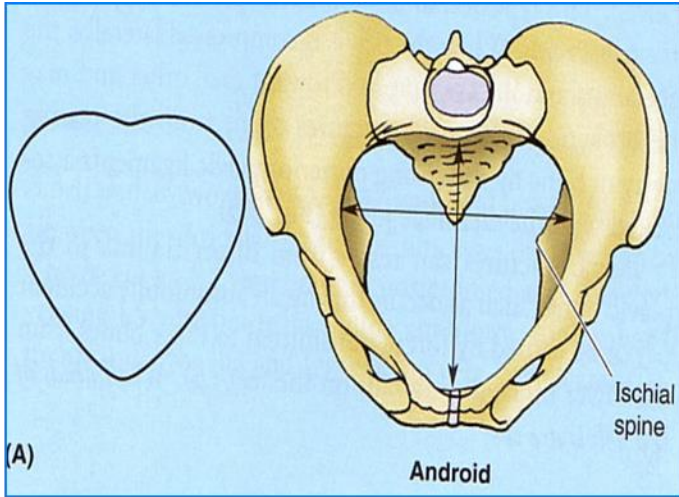
3



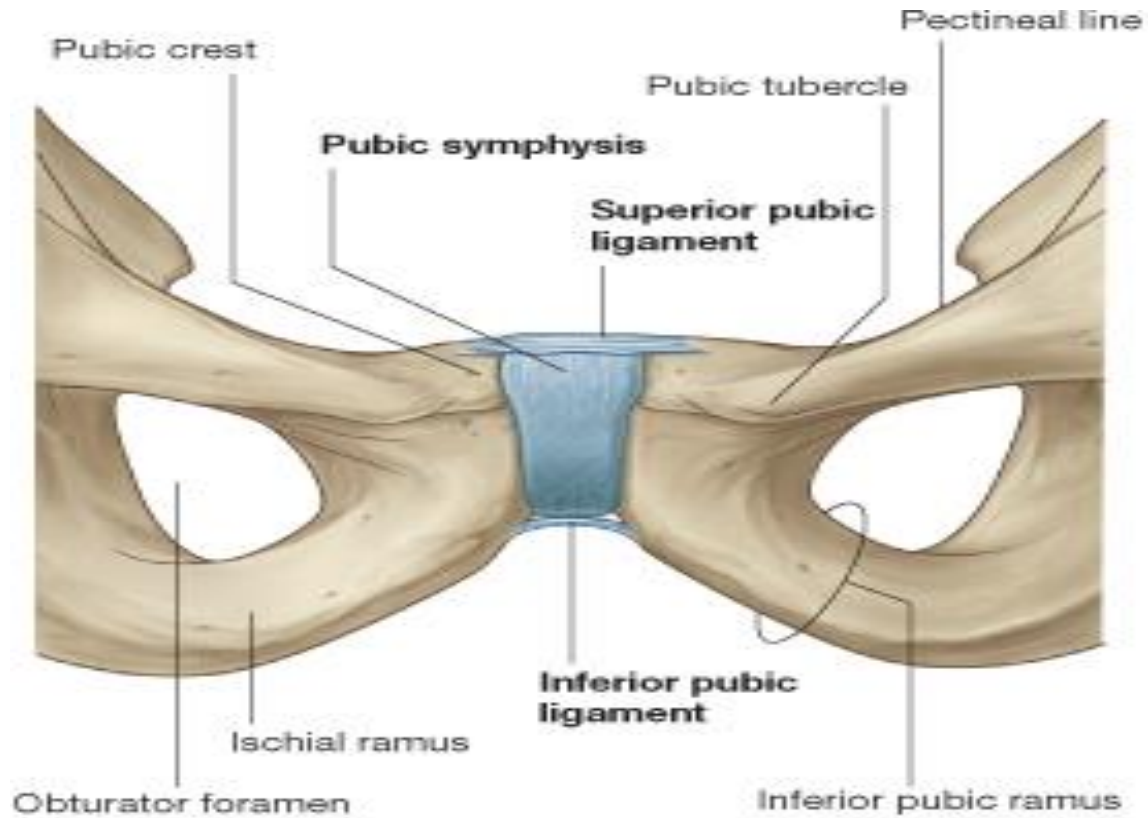




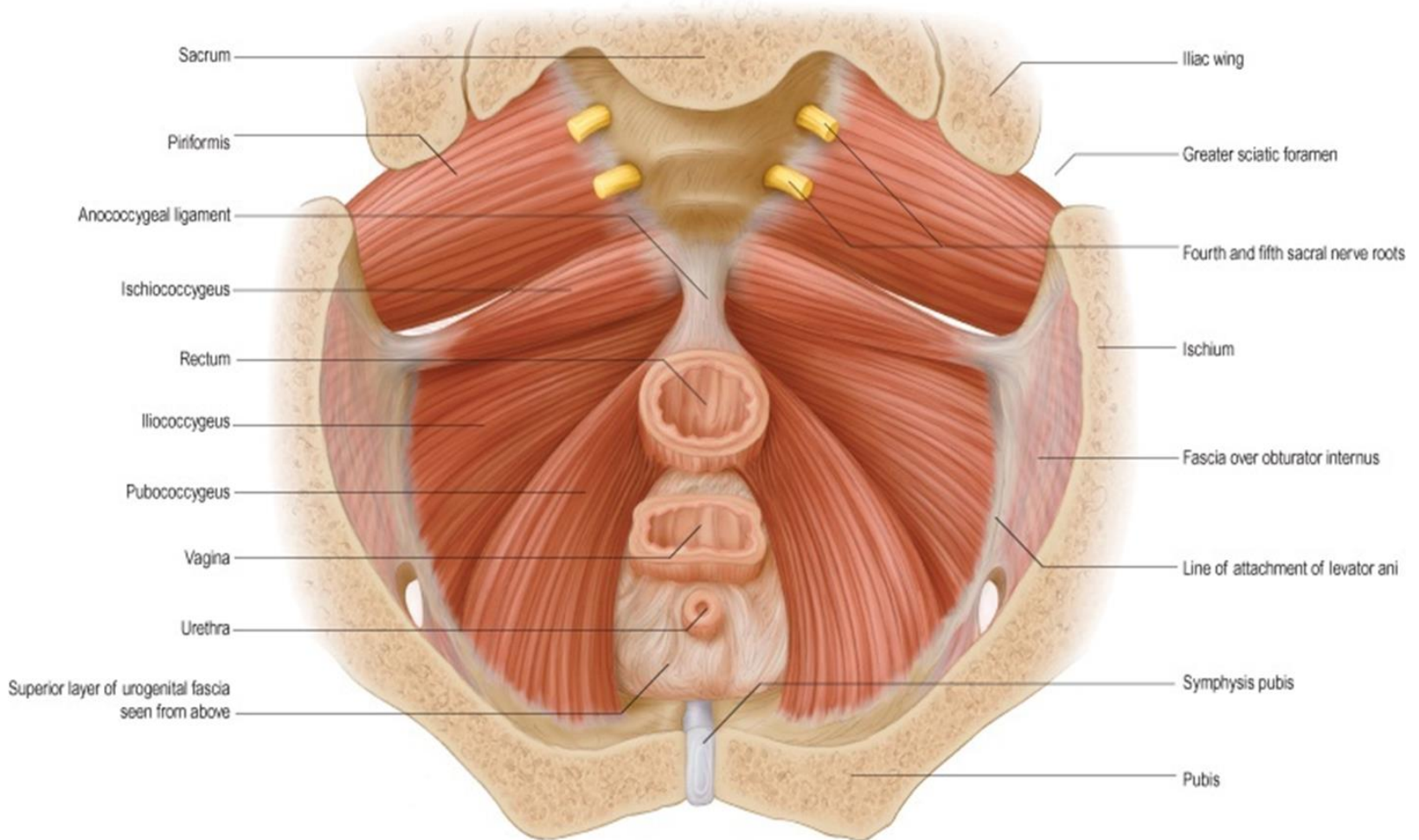




# ANTERIOR PELVIC WALL

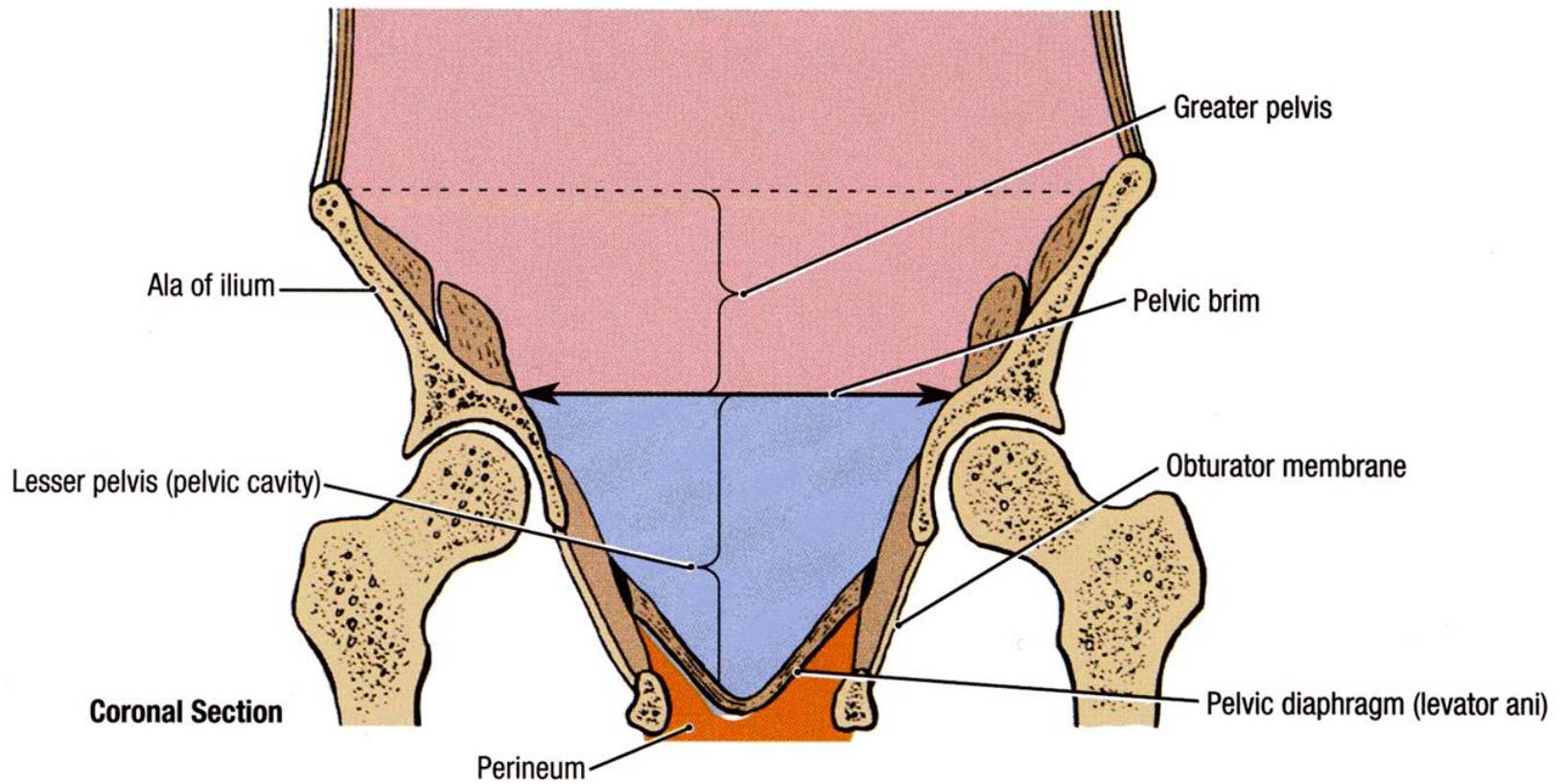


# POSTERIOR PELVIC WALL

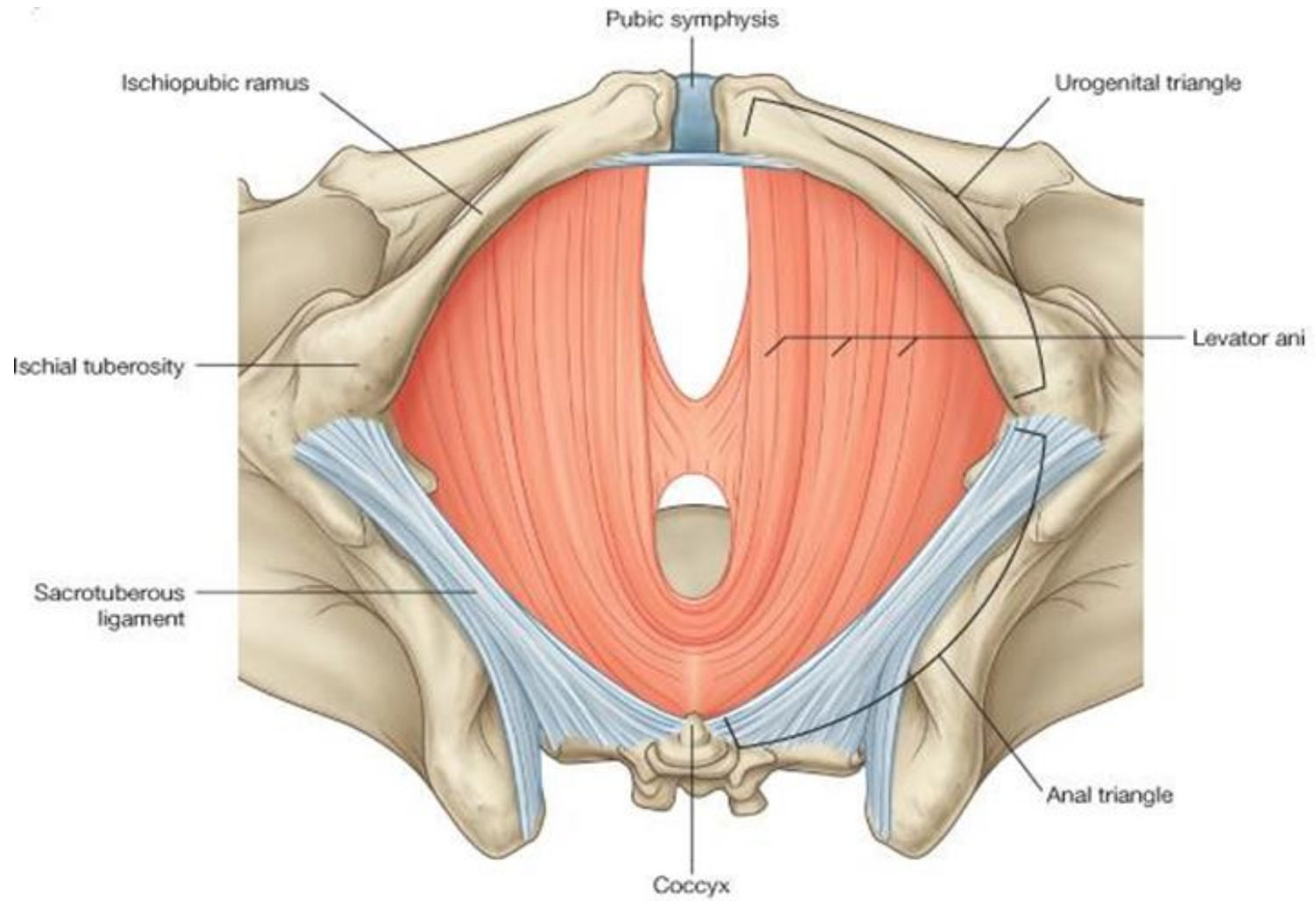




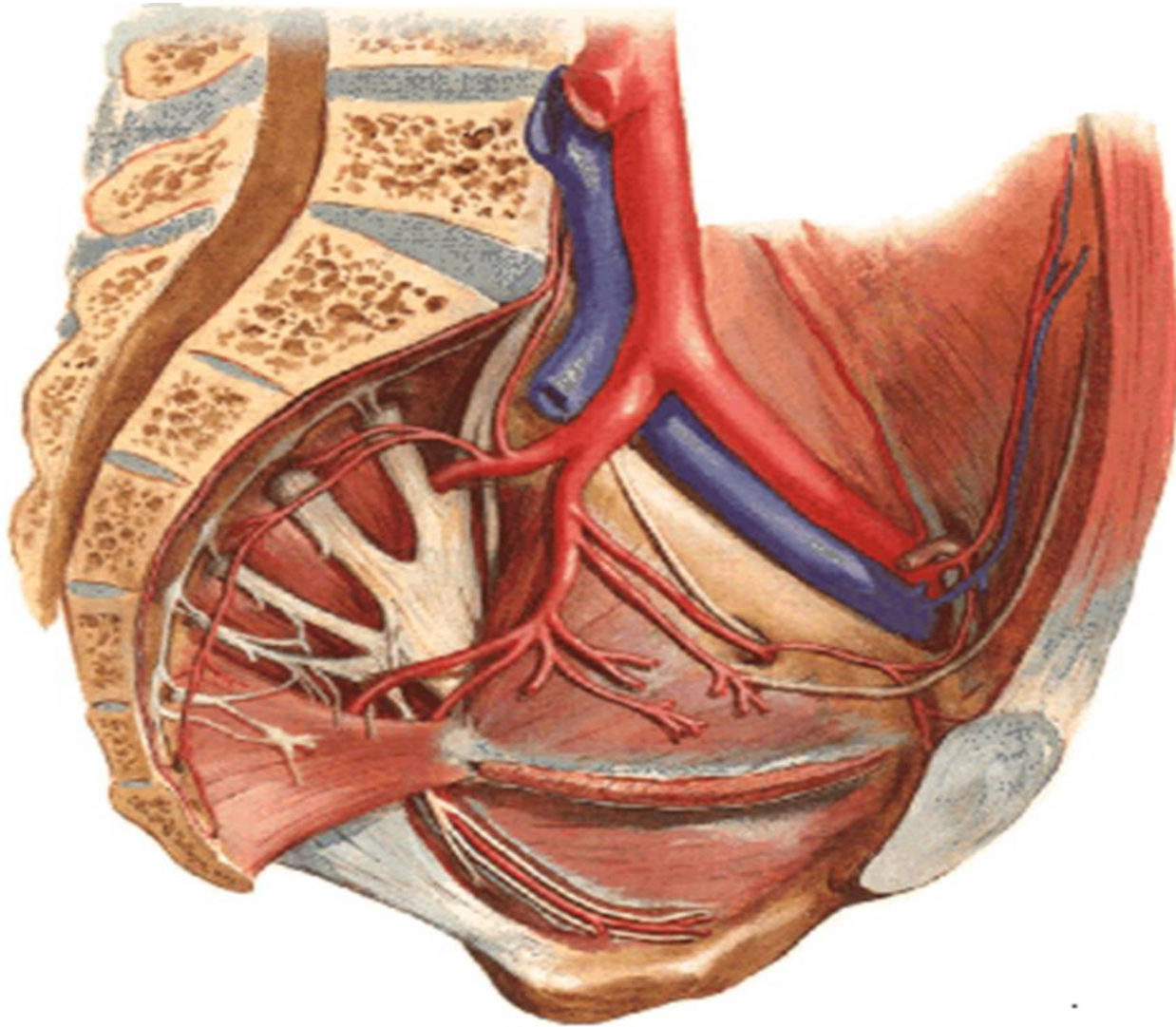
# INFERIOR PELVIC WALL, OR PELVIC FLOOR



# LEVATOR ANI MUSCLES

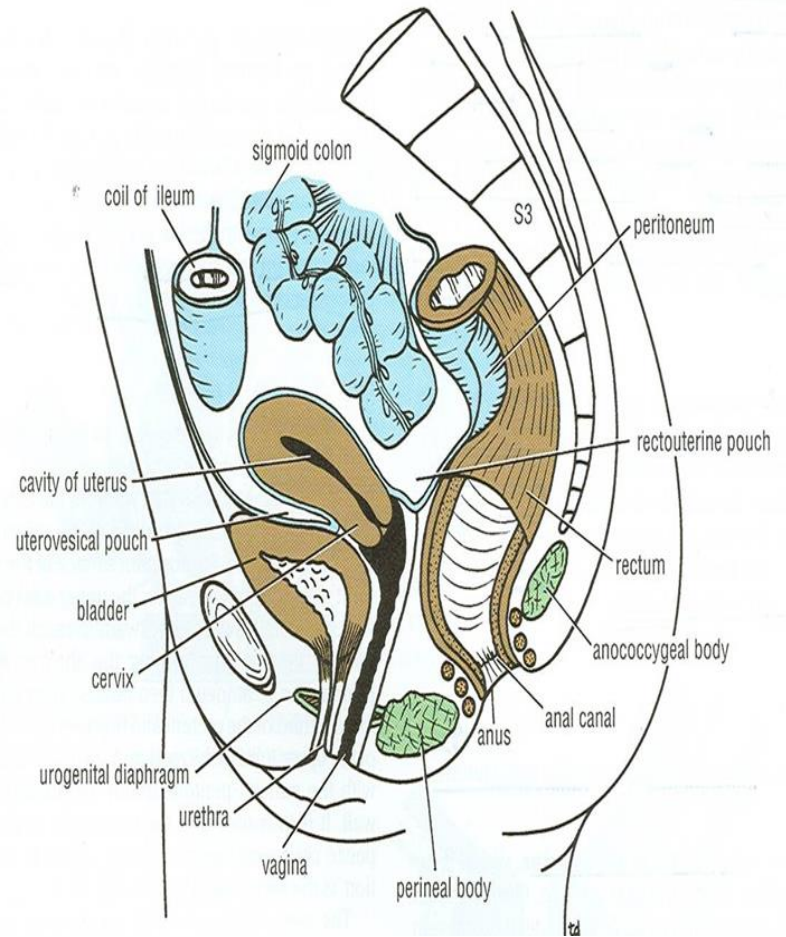
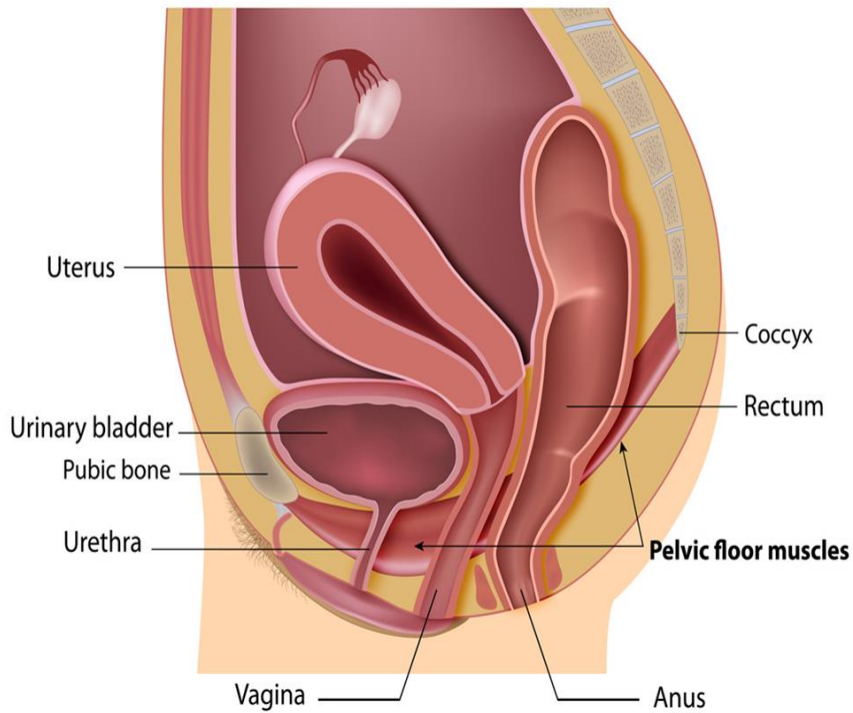


# Arteries of the Pelvis



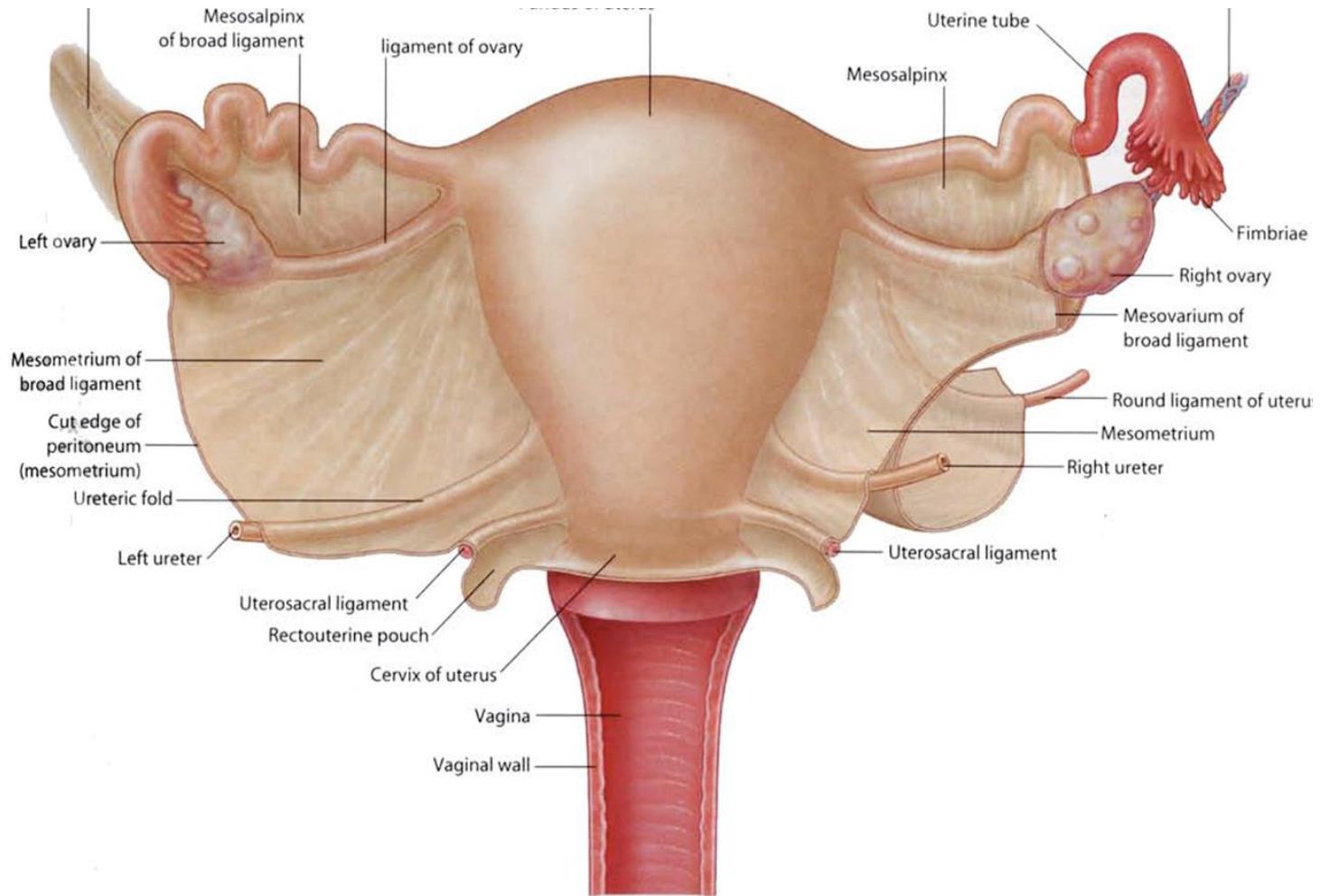


# Arrangements of the pelvic viscera

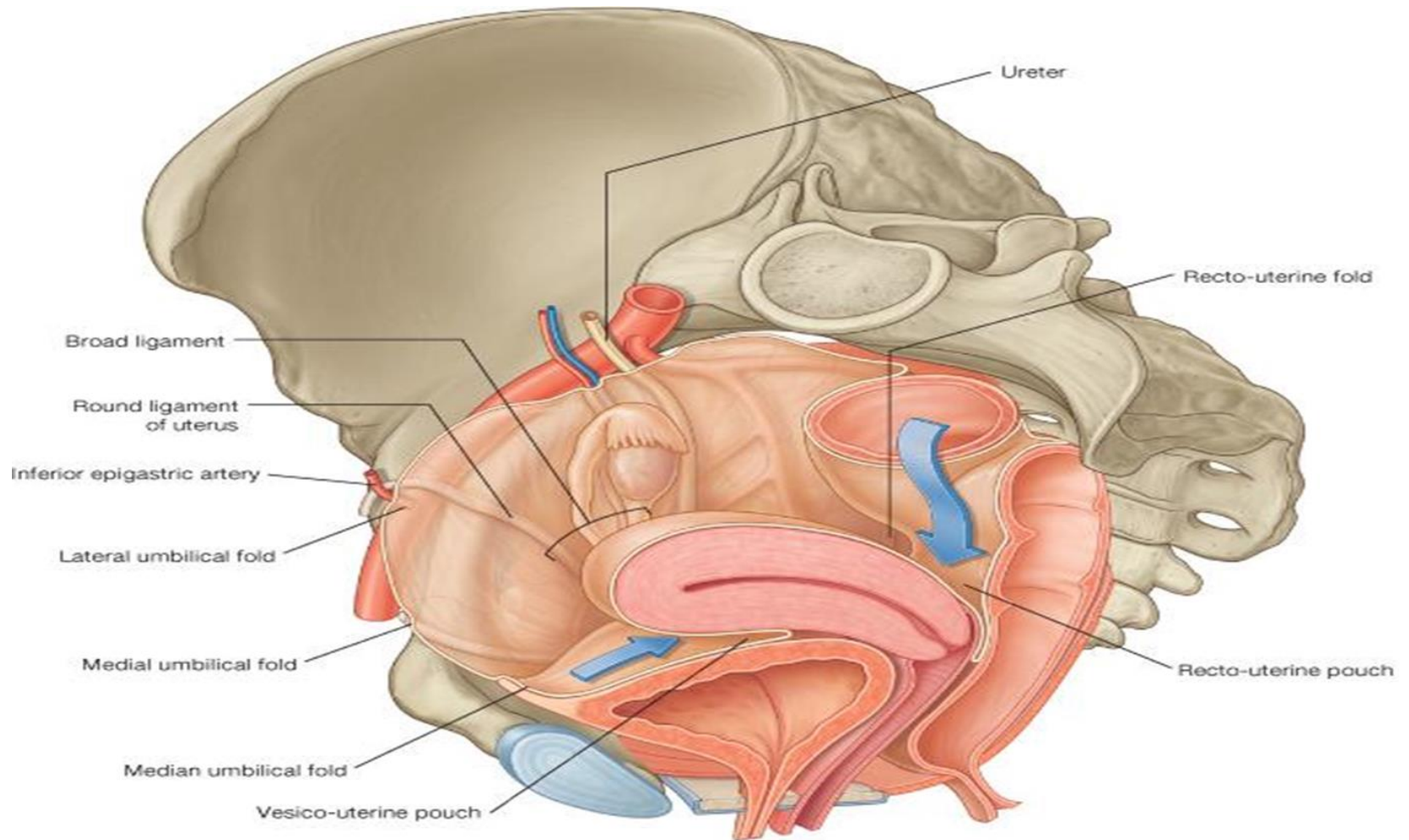


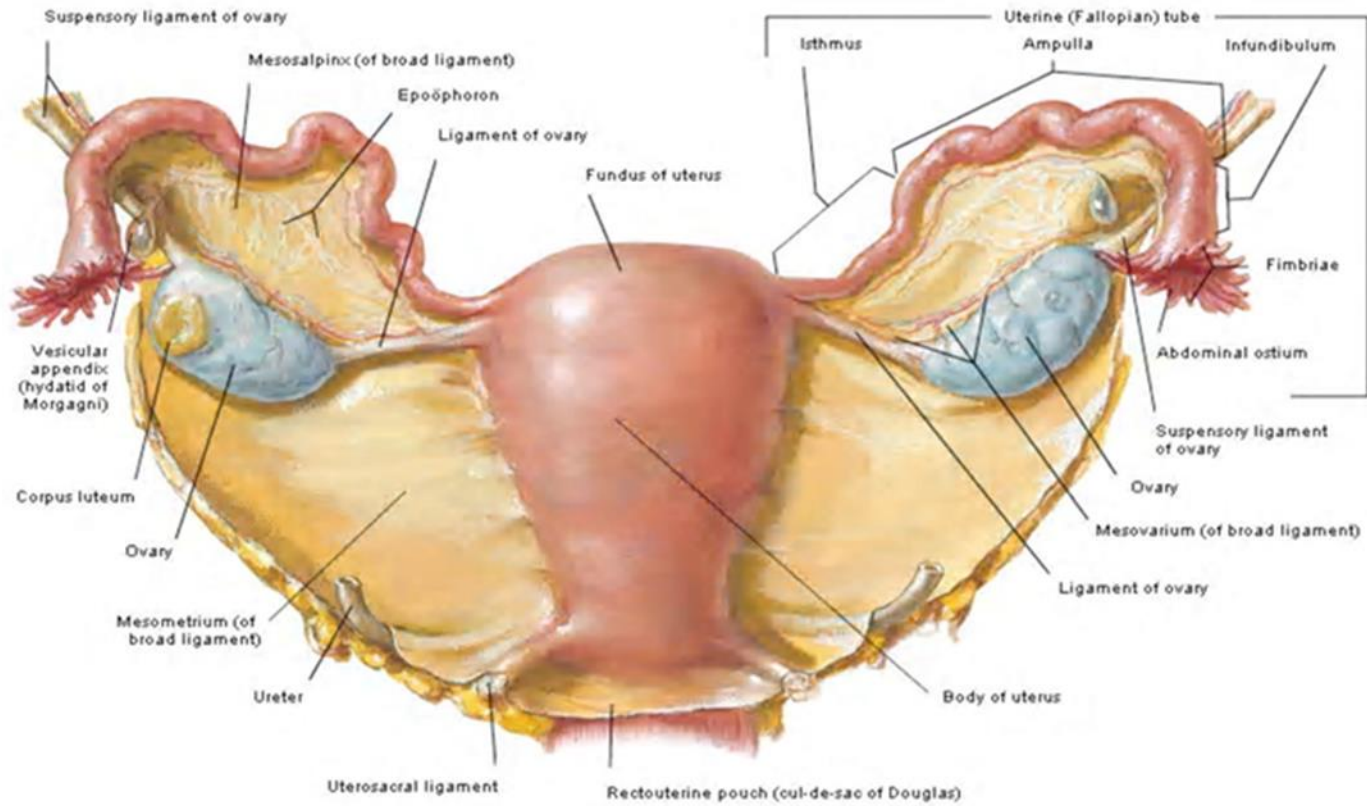


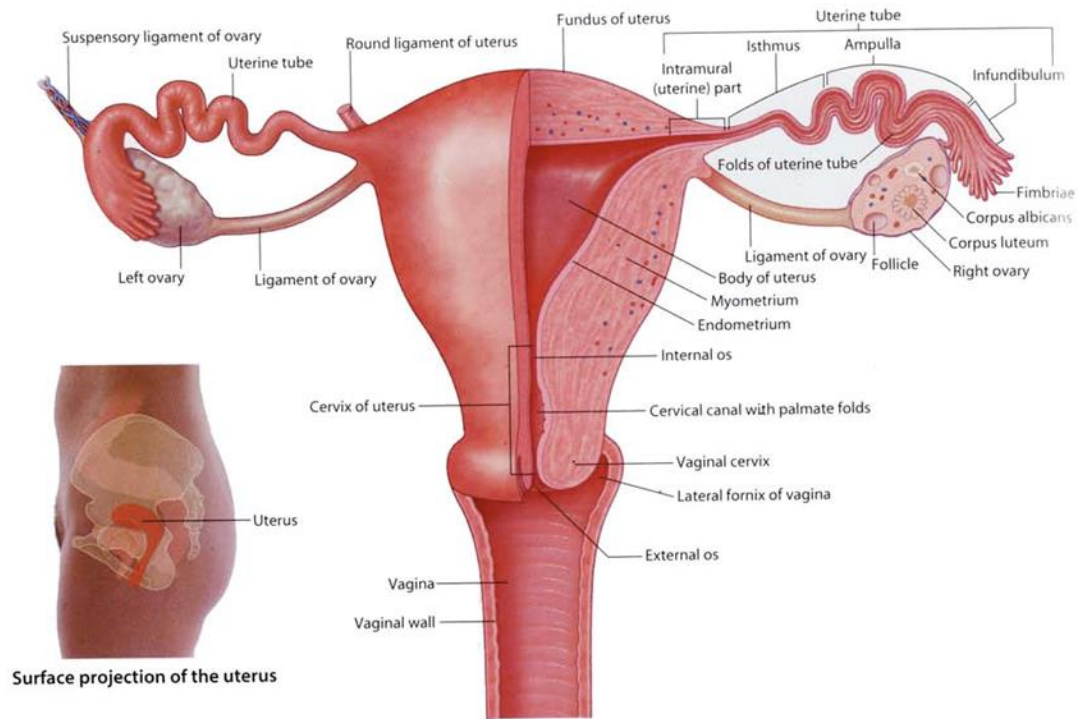
# THE FEMALE REPRODUCTIVE SYSTEM



# PELVIC PERITONEUM IN FEMALE





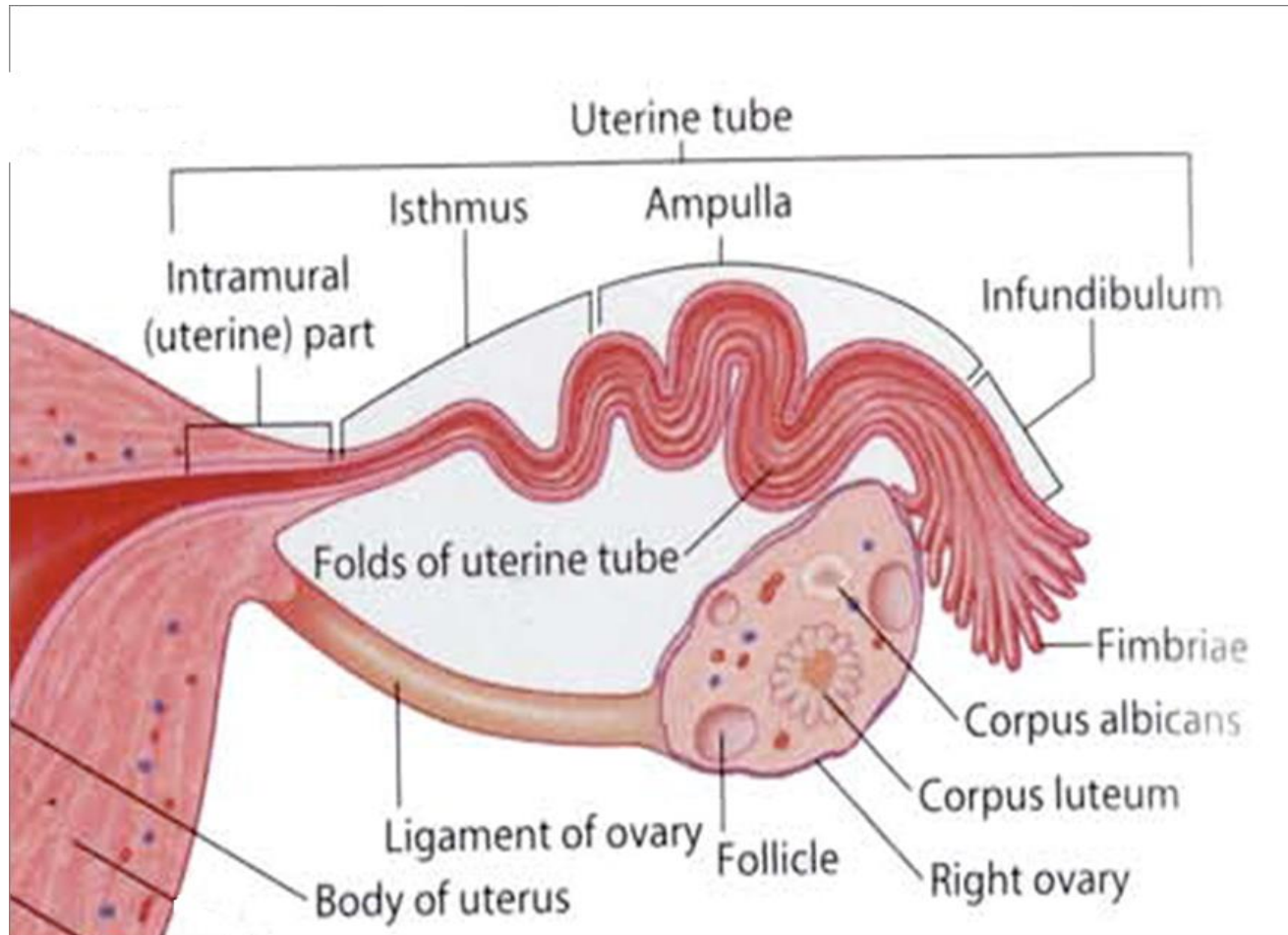


Surface projection of the uterus

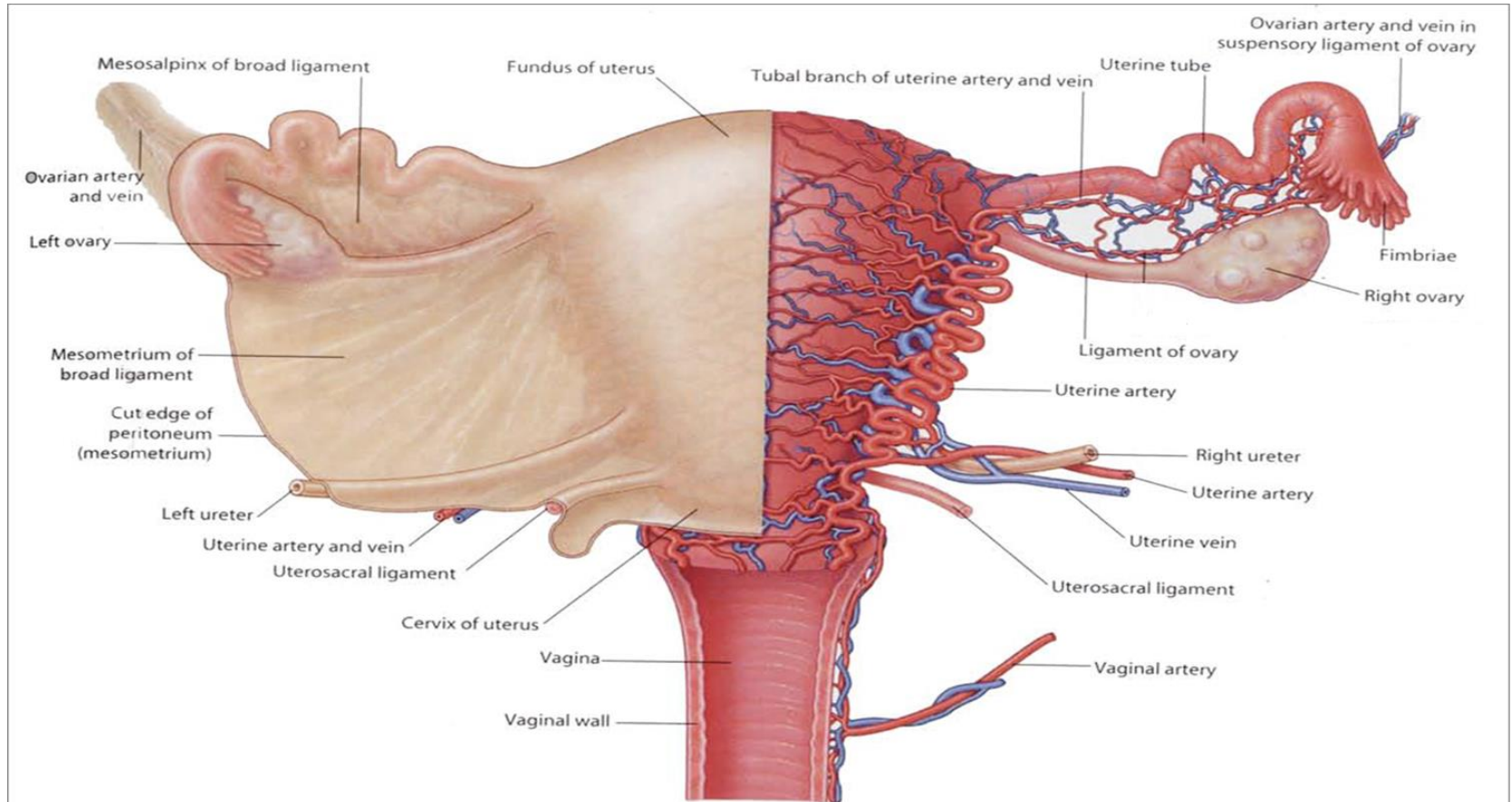
Structure of the uterus and ovaries (posterior view)

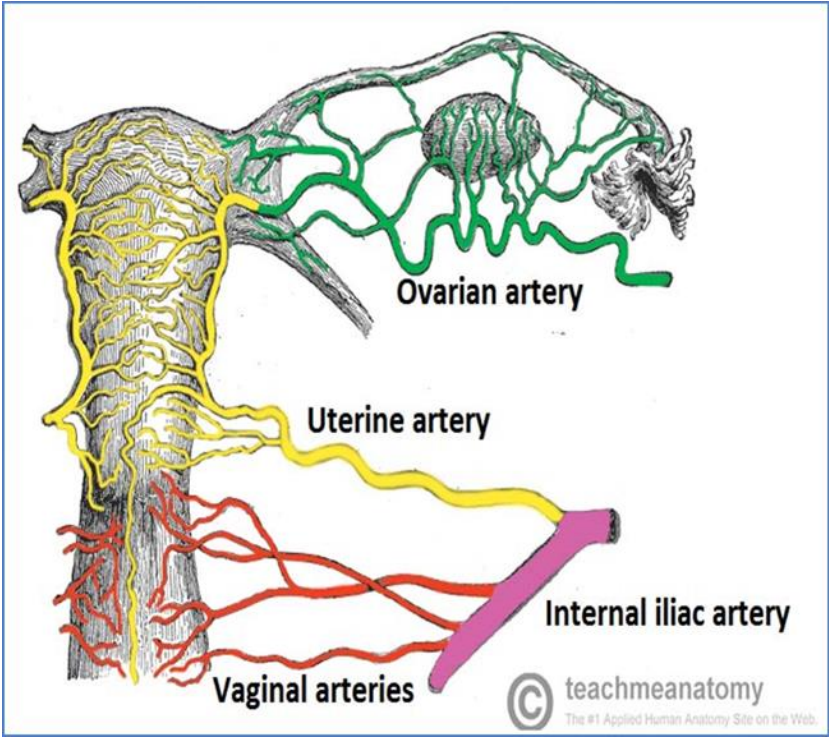


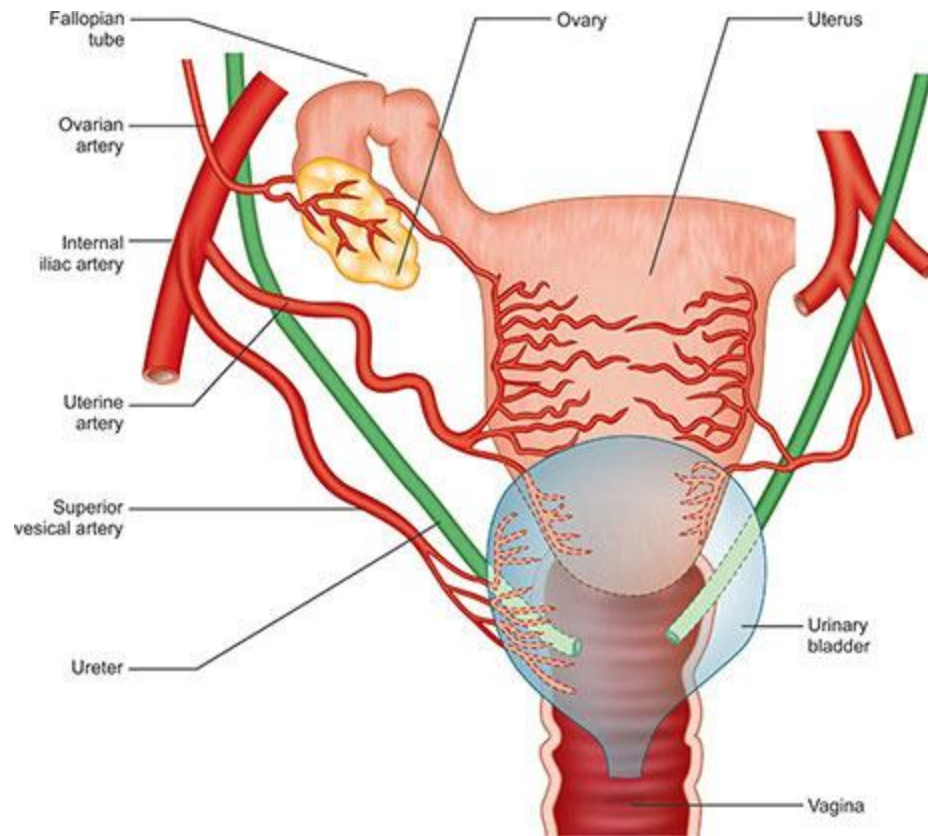
# THE UTERINE (FALLOPIAN) TUBES



# ARTERIAL SUPPLY









**Thank You**

## **Disclosure**

Please be advised that this work is intended for non-profit purely educational purposes. We used some images from the internet and other sources. We did our best to link all images to their original sources to preserve copyrights. If you are the owner of one of those images, and you are not satisfied with our copyright level, please contact us and let us know how to make things right. We deeply appreciate your cooperation and consideration.

Contact: **[anatomy@ksu.edu.sa](mailto:anatomy@ksu.edu.sa)**