

Male Reproductive System

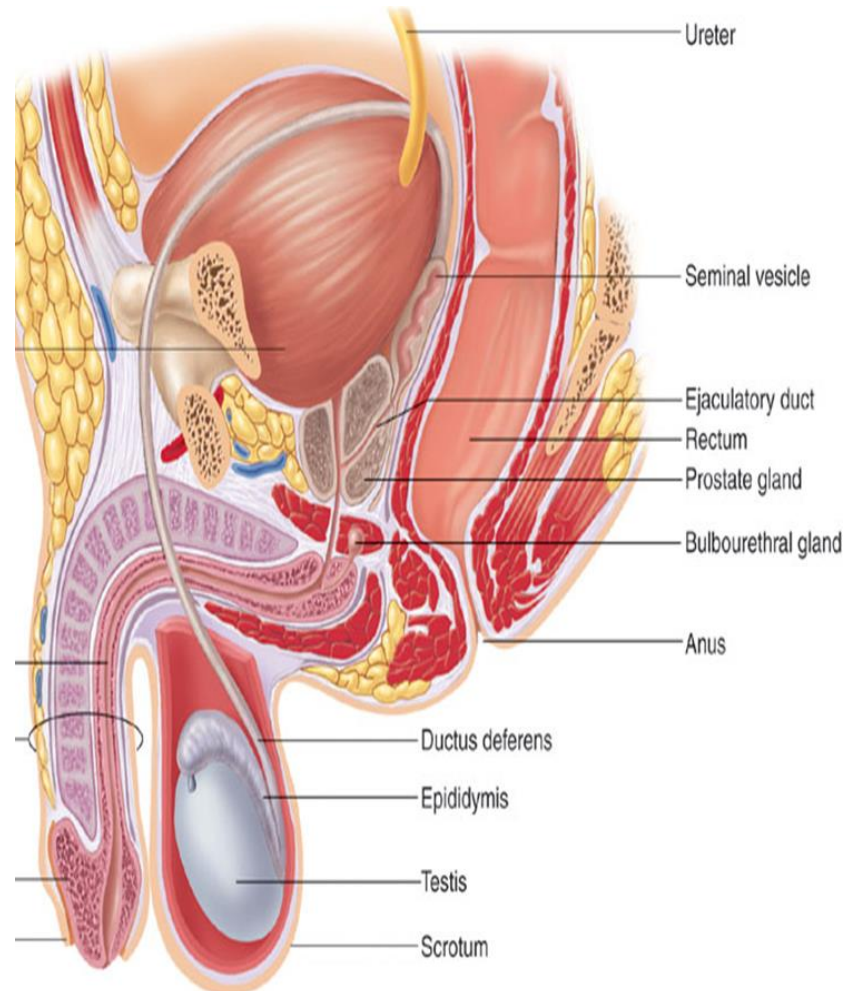
Anatomy Practical

Anatomy Department

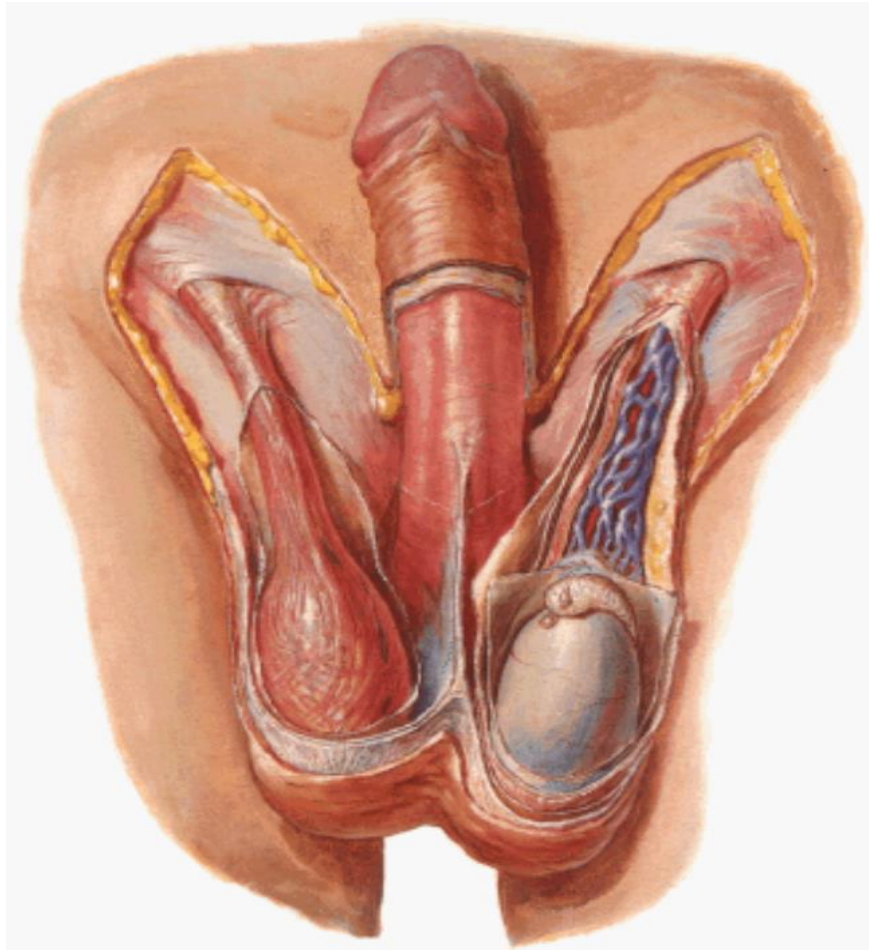
College of Medicine

King Saud University

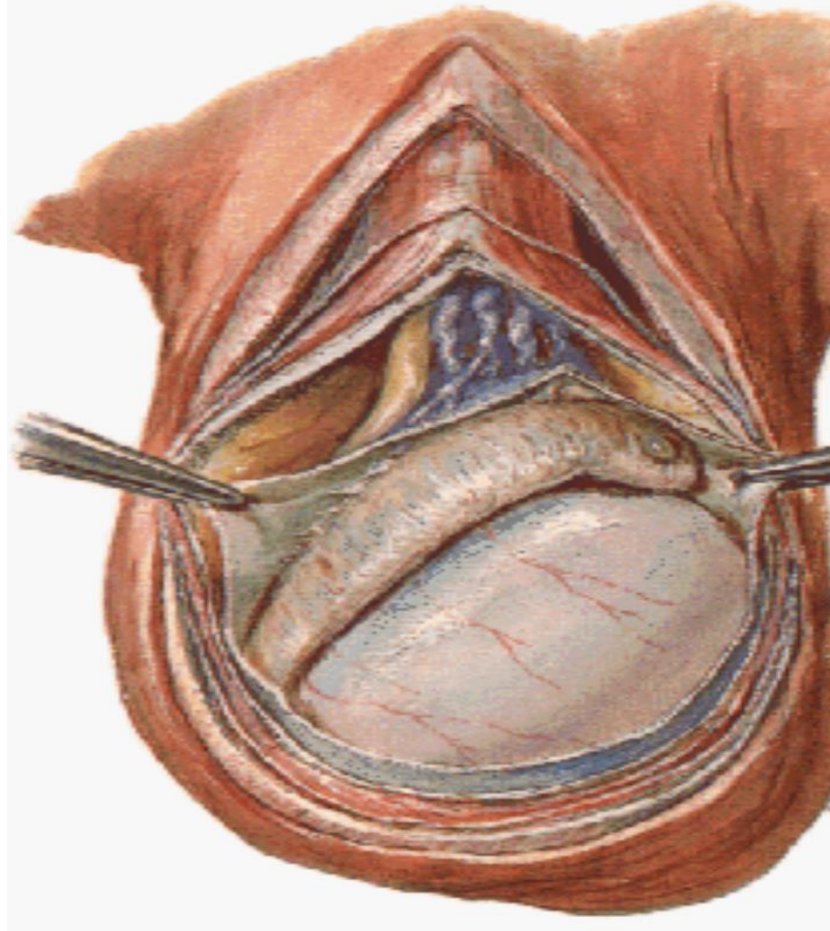
Components of Male Reproductive System

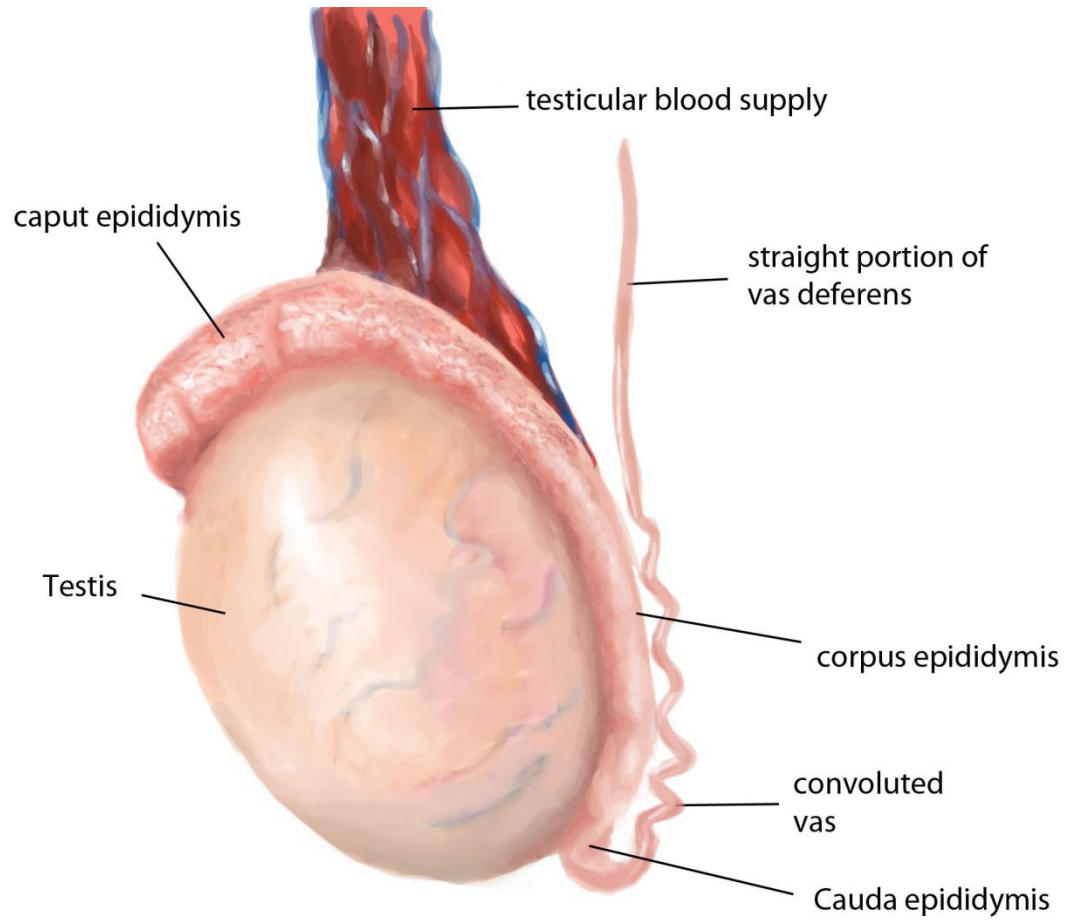


Scrotum



Testis





Coverings of the Testis

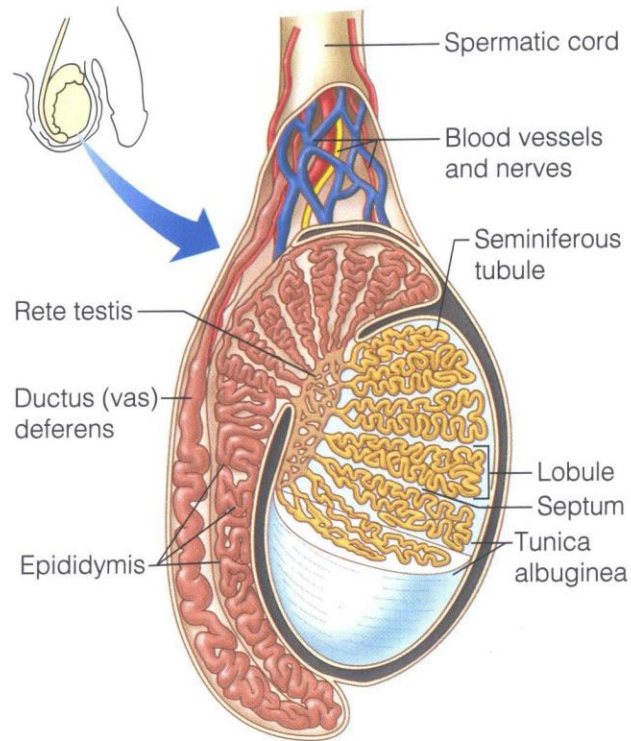


Figure 16.1 Sagittal section of the testis and associated epididymis.

Lyi
the se
(in"ter-
produc
terone
produc
comple

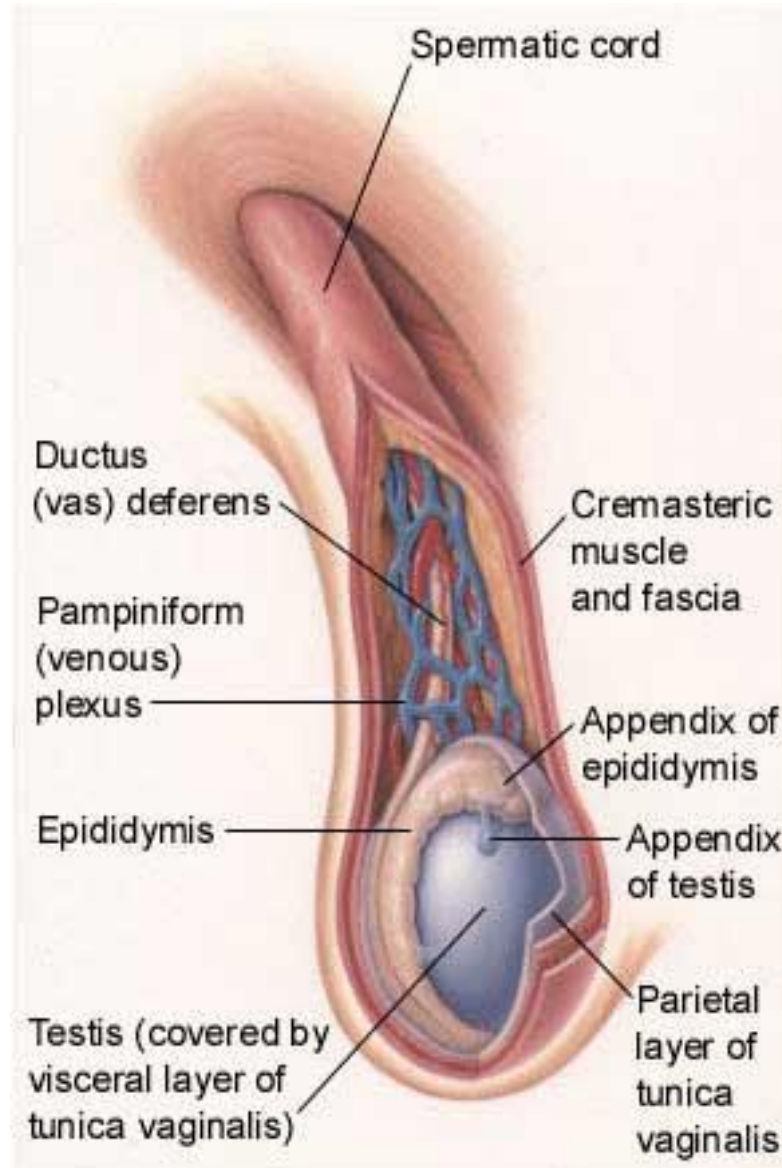
Duct

The ac
tem, v
the ej
(Figure

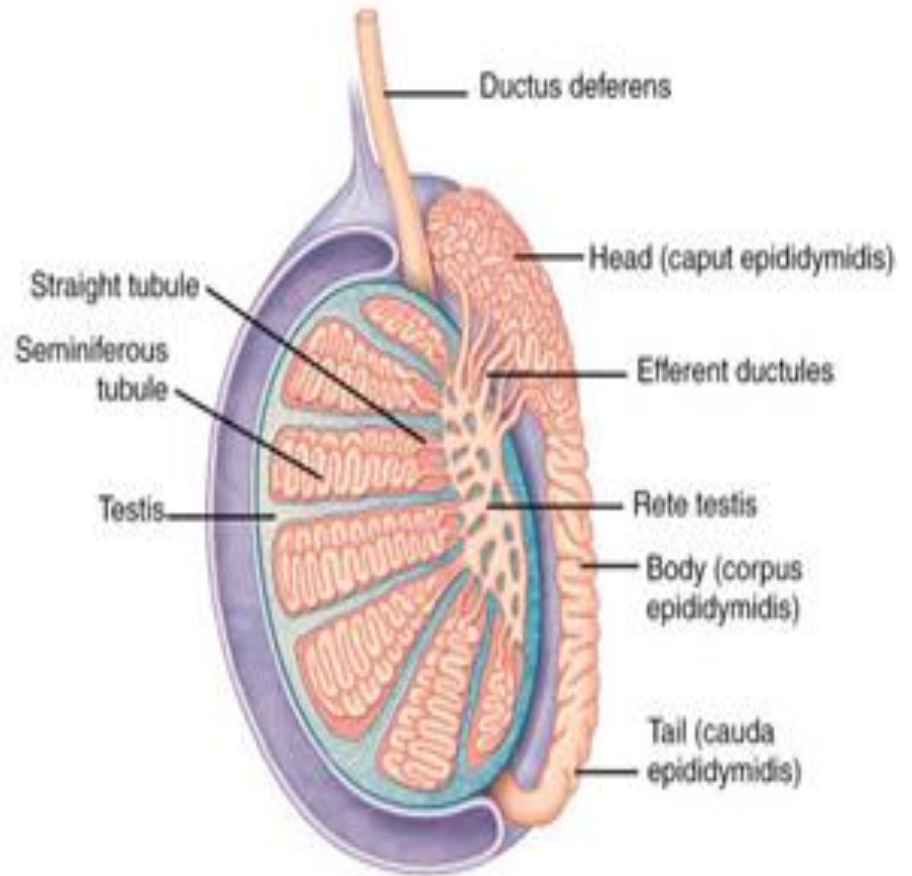
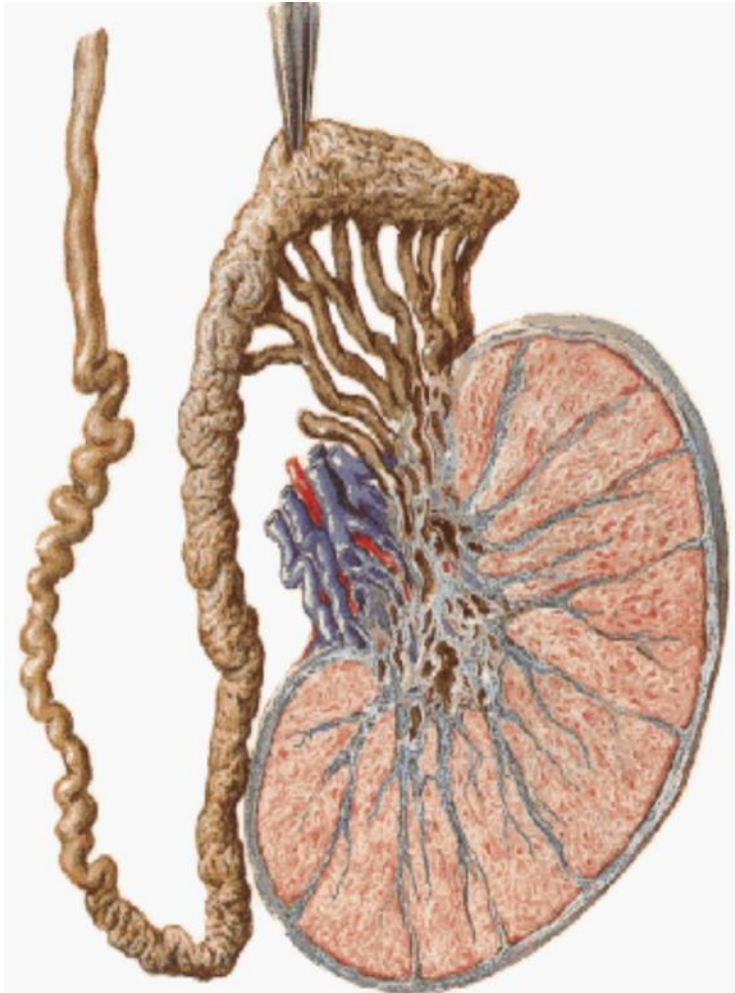
Epidid

The co
tube a
rior pa
terolat
the fir
a temp
that er
their v
didym
ture, g
sexual

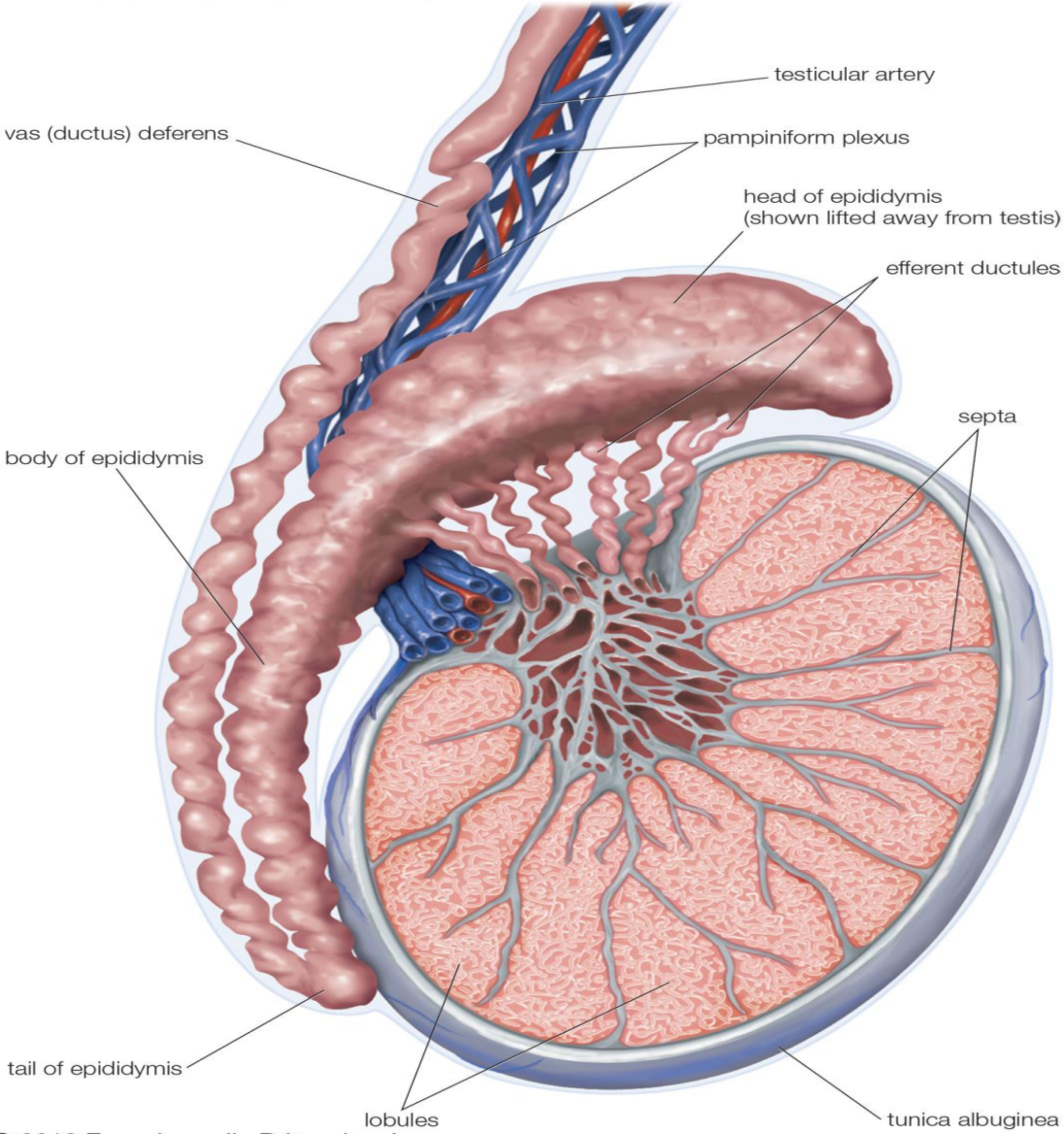
Coverings of the Testis



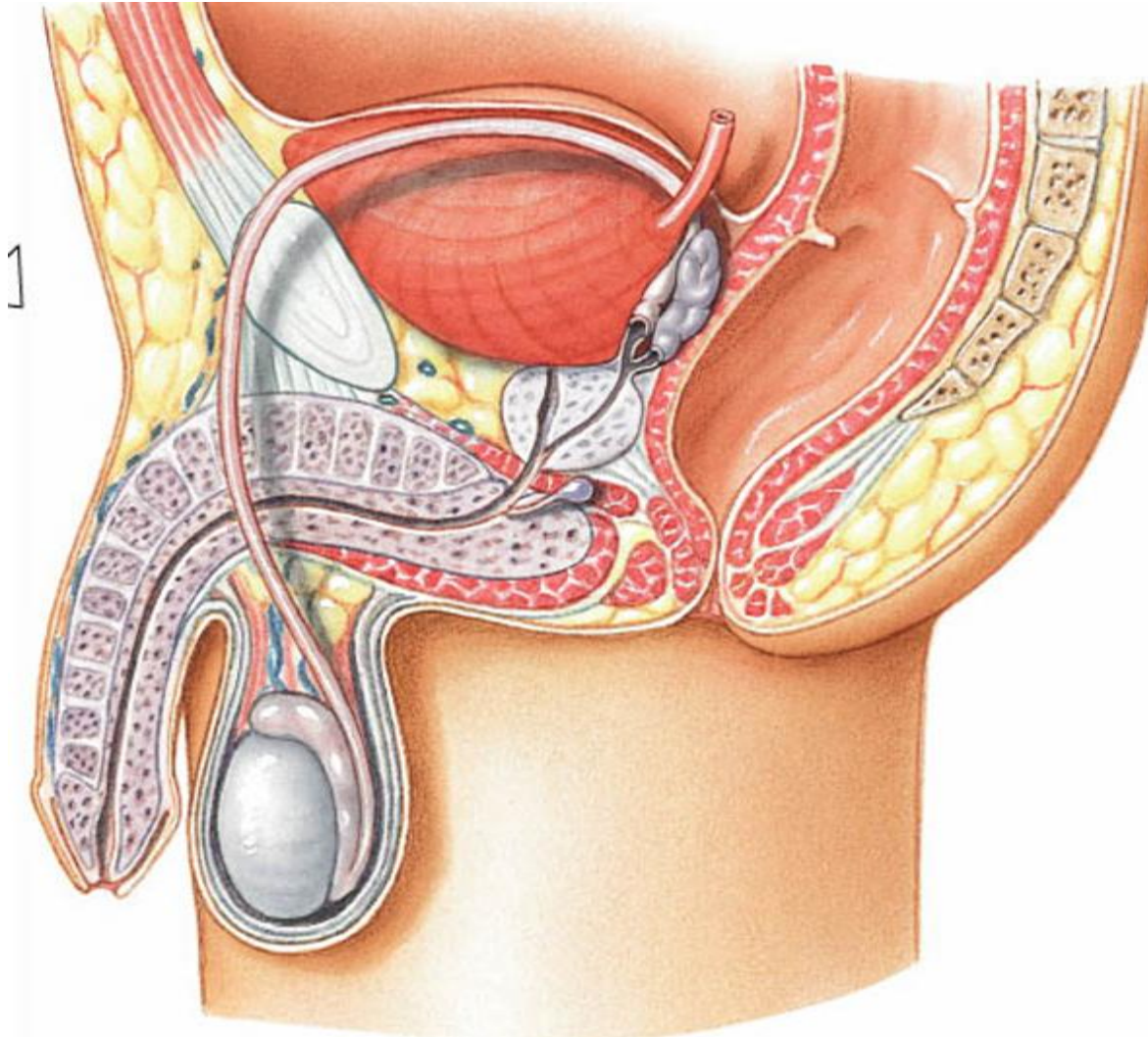
Epididymis



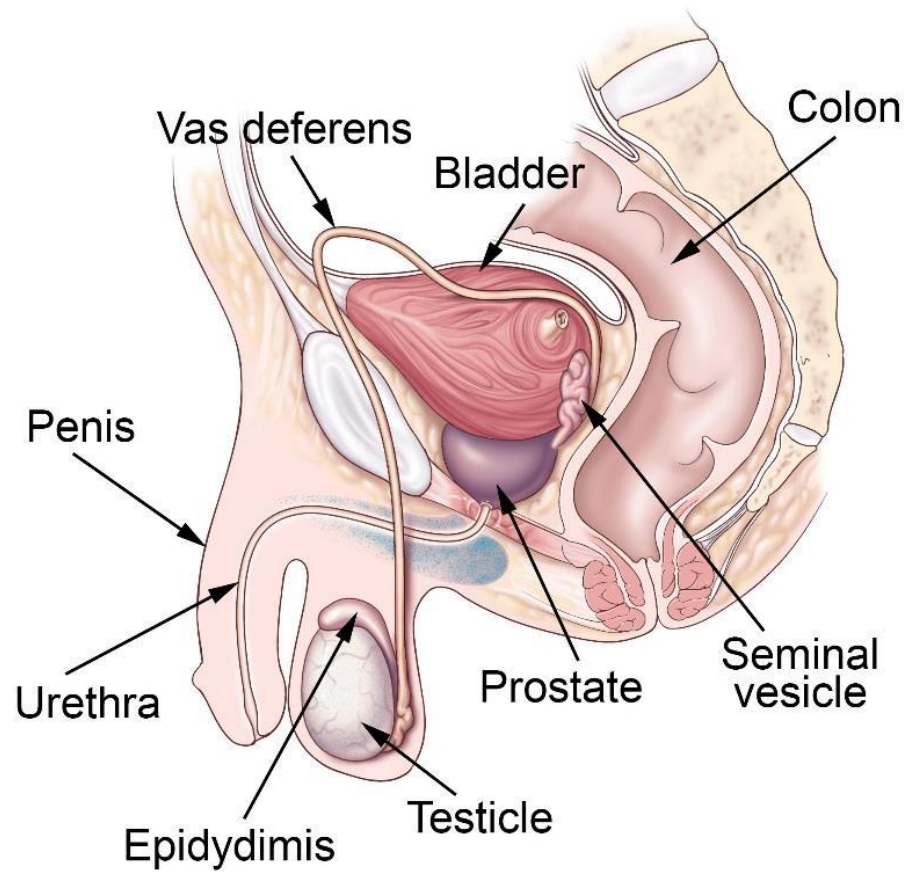
Testis, epididymis, and vas (ductus) deferens



Vas Deferens

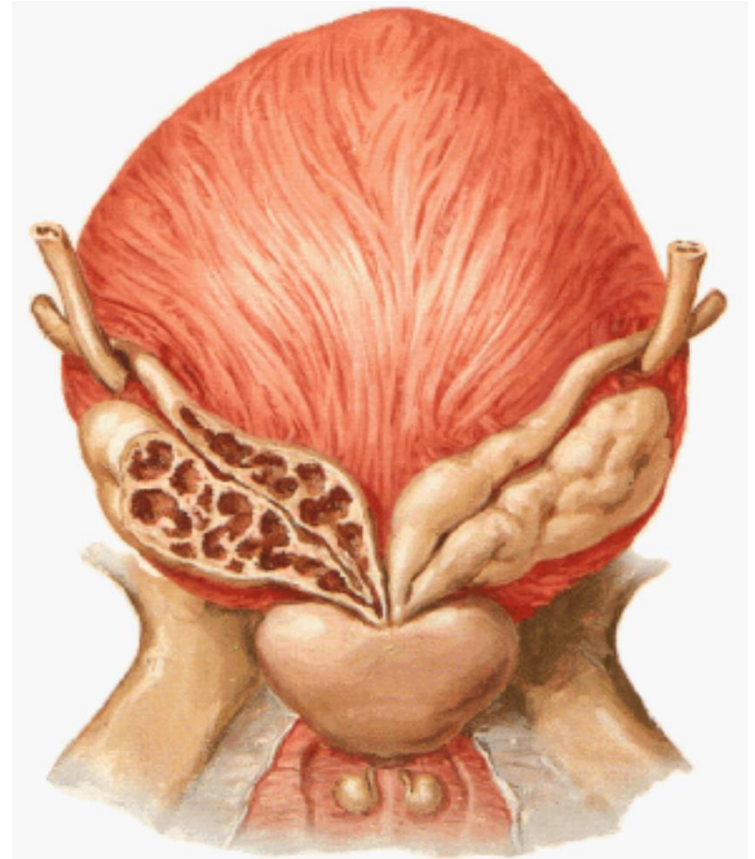
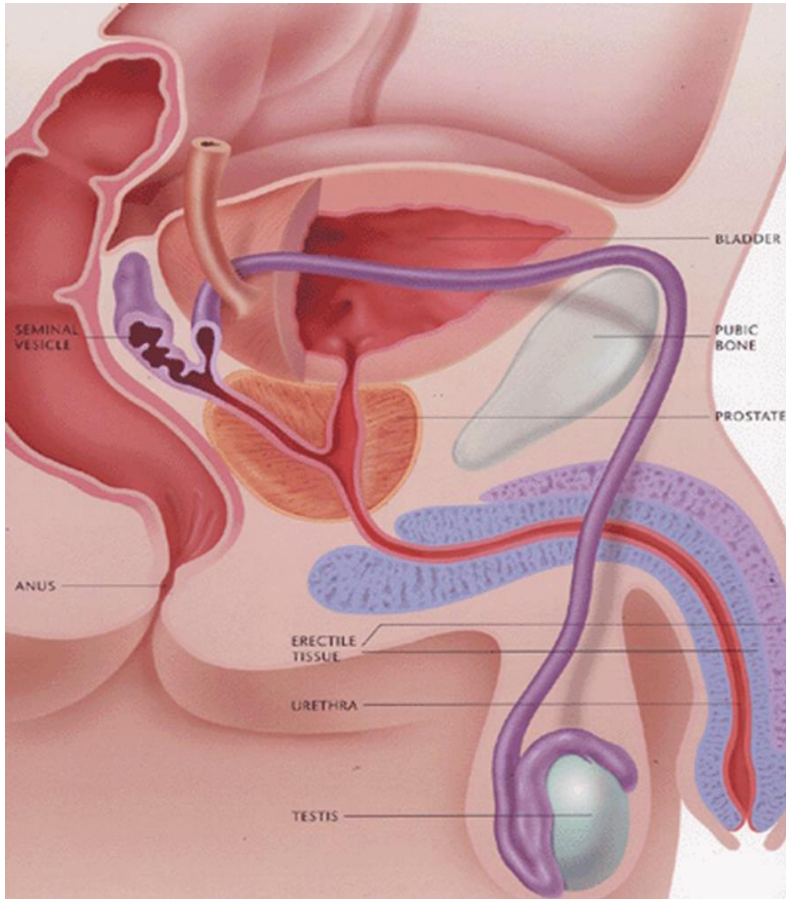


Vas Deferens

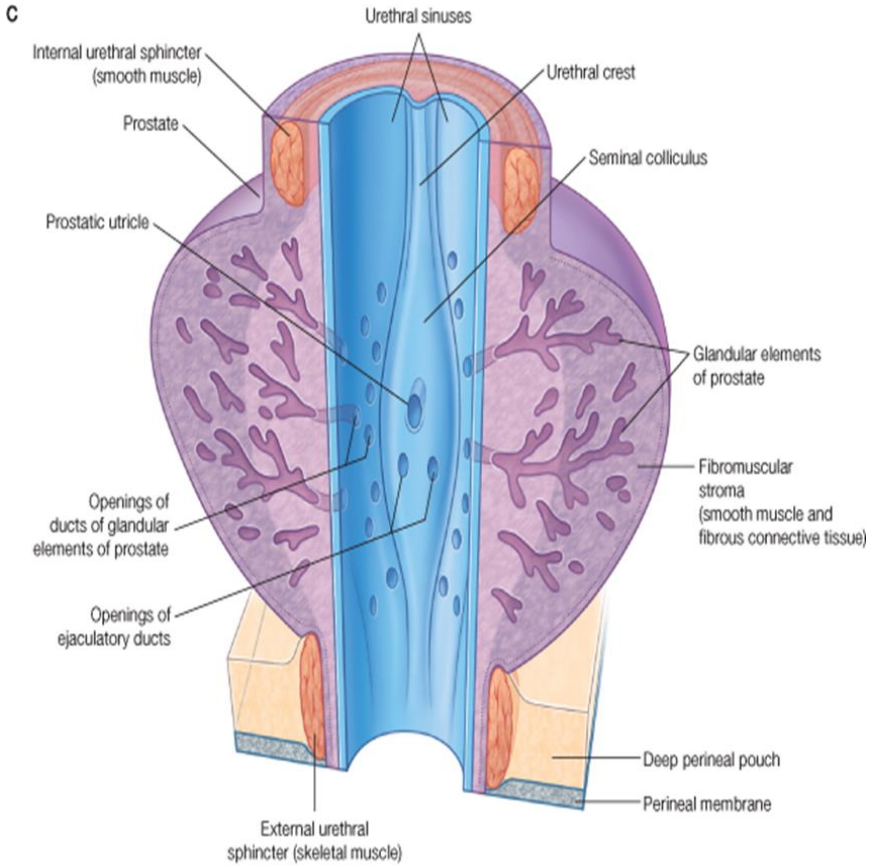
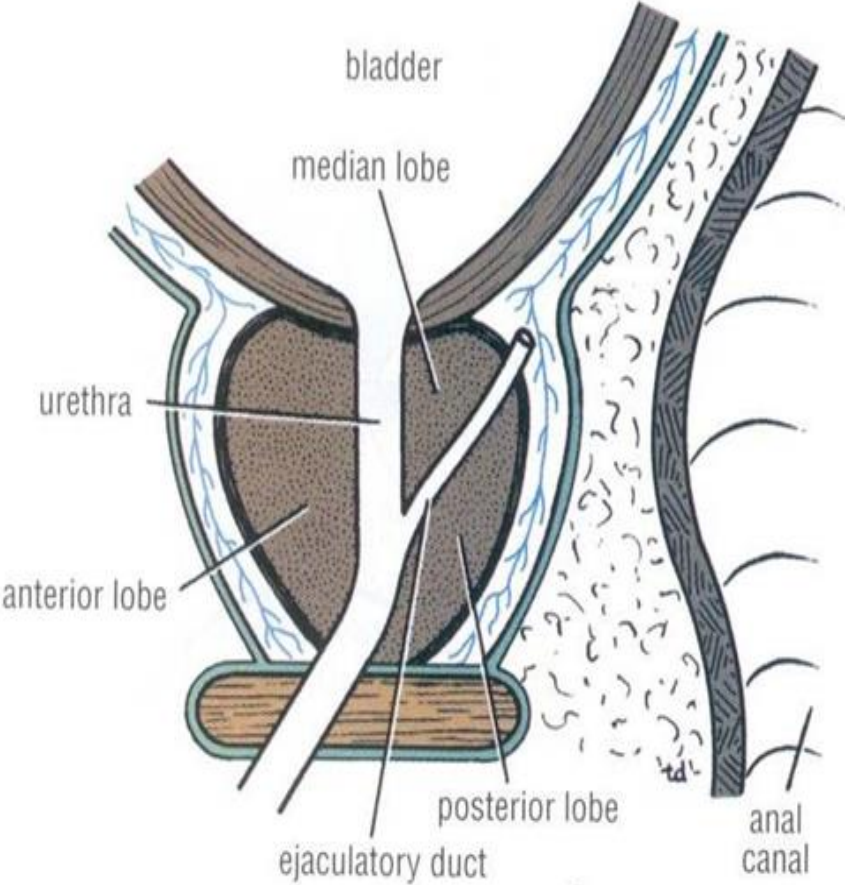


© CCF 2016

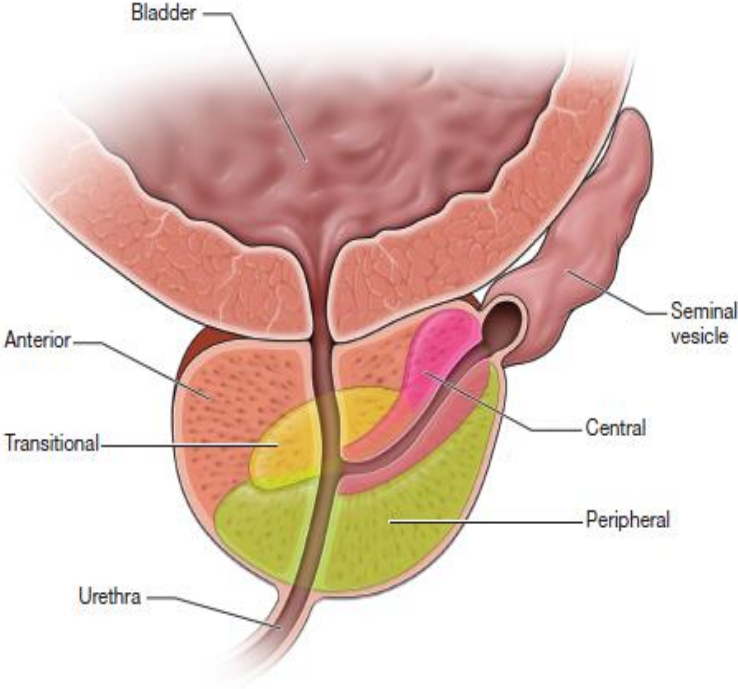
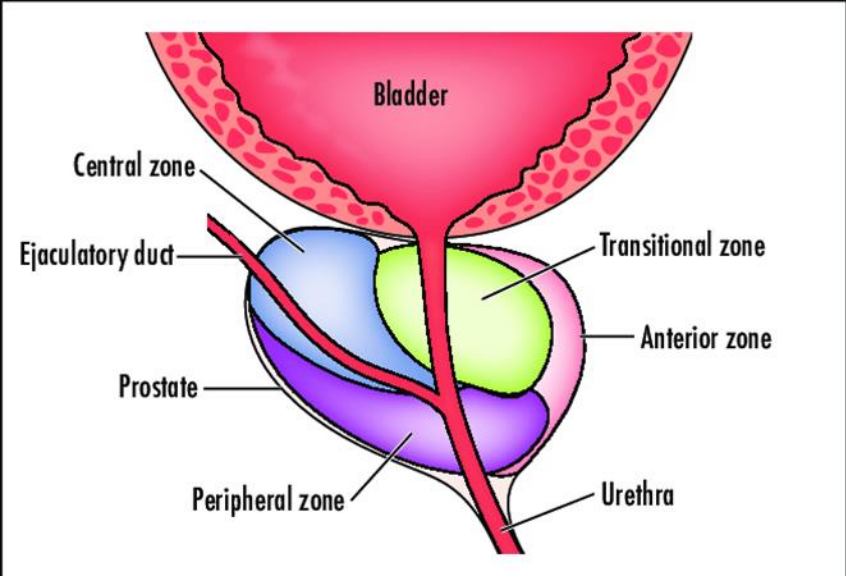
Vas Deferens



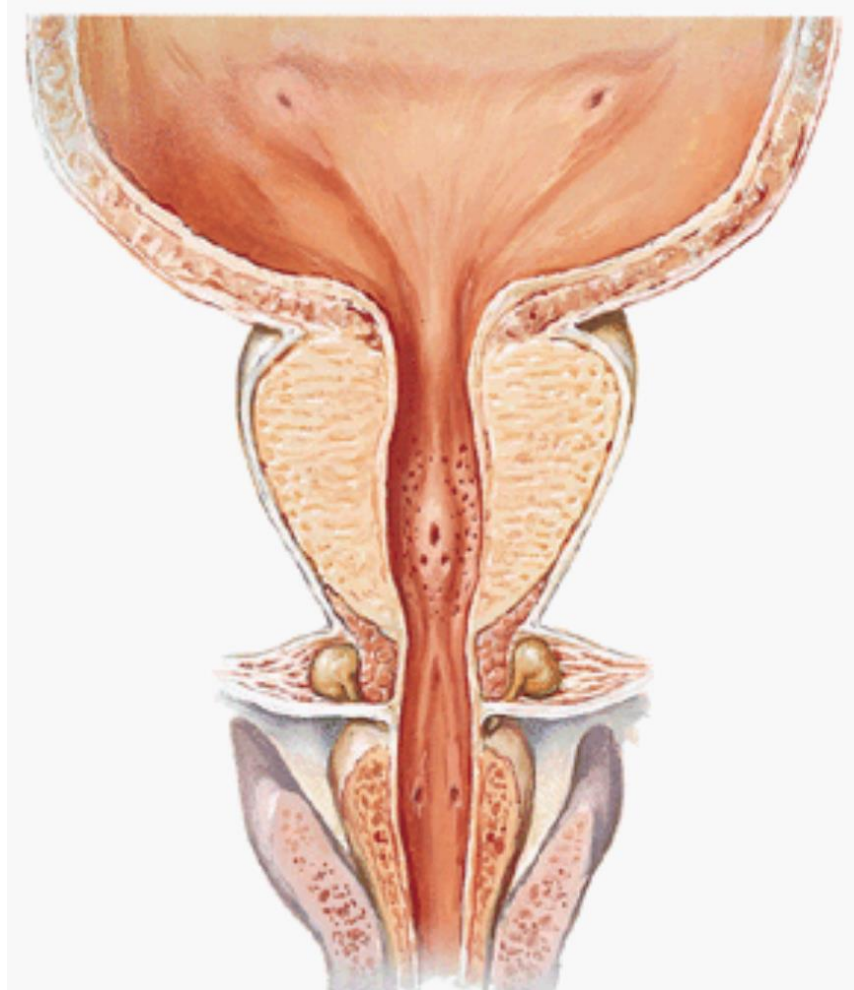
Prostate Gland

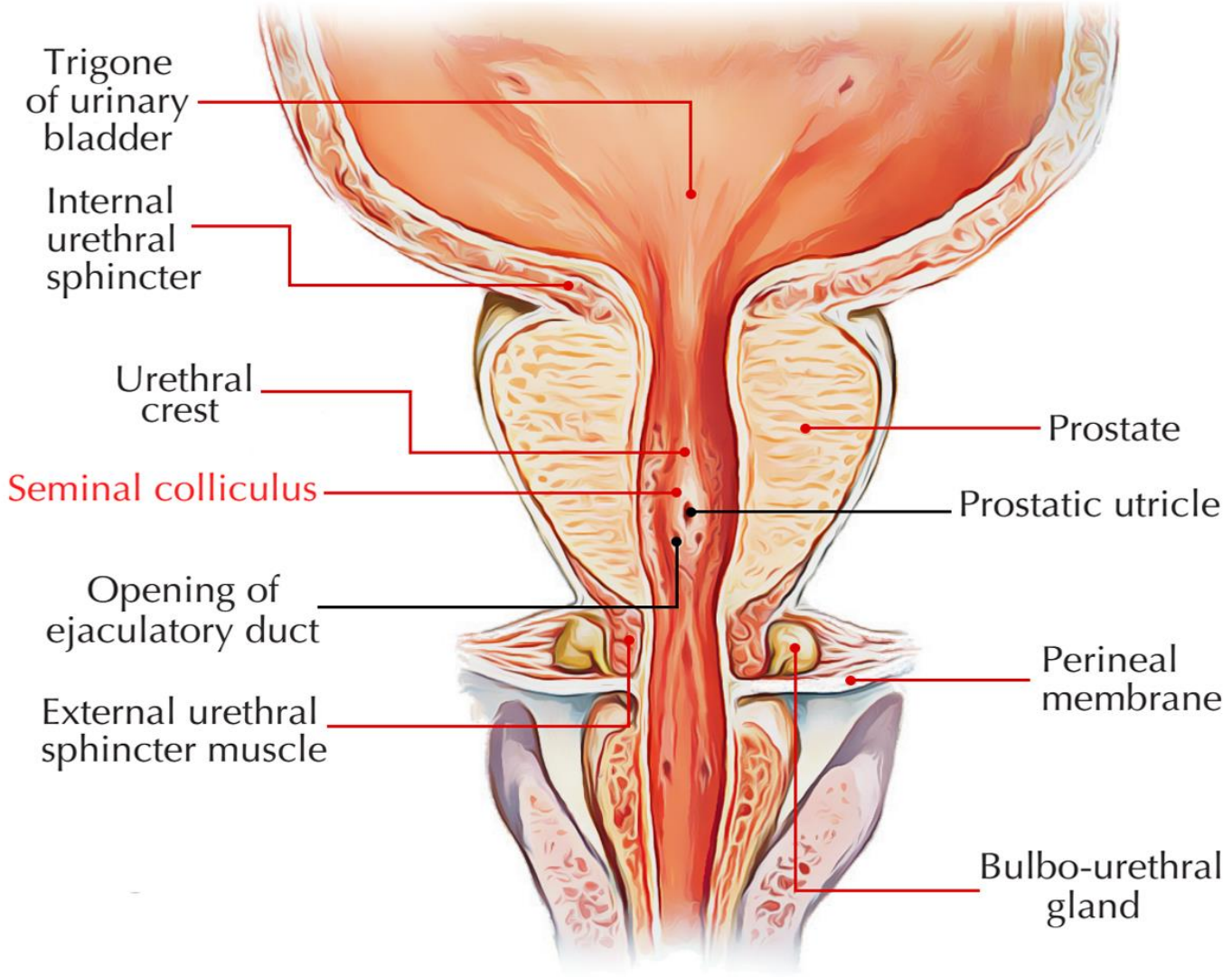


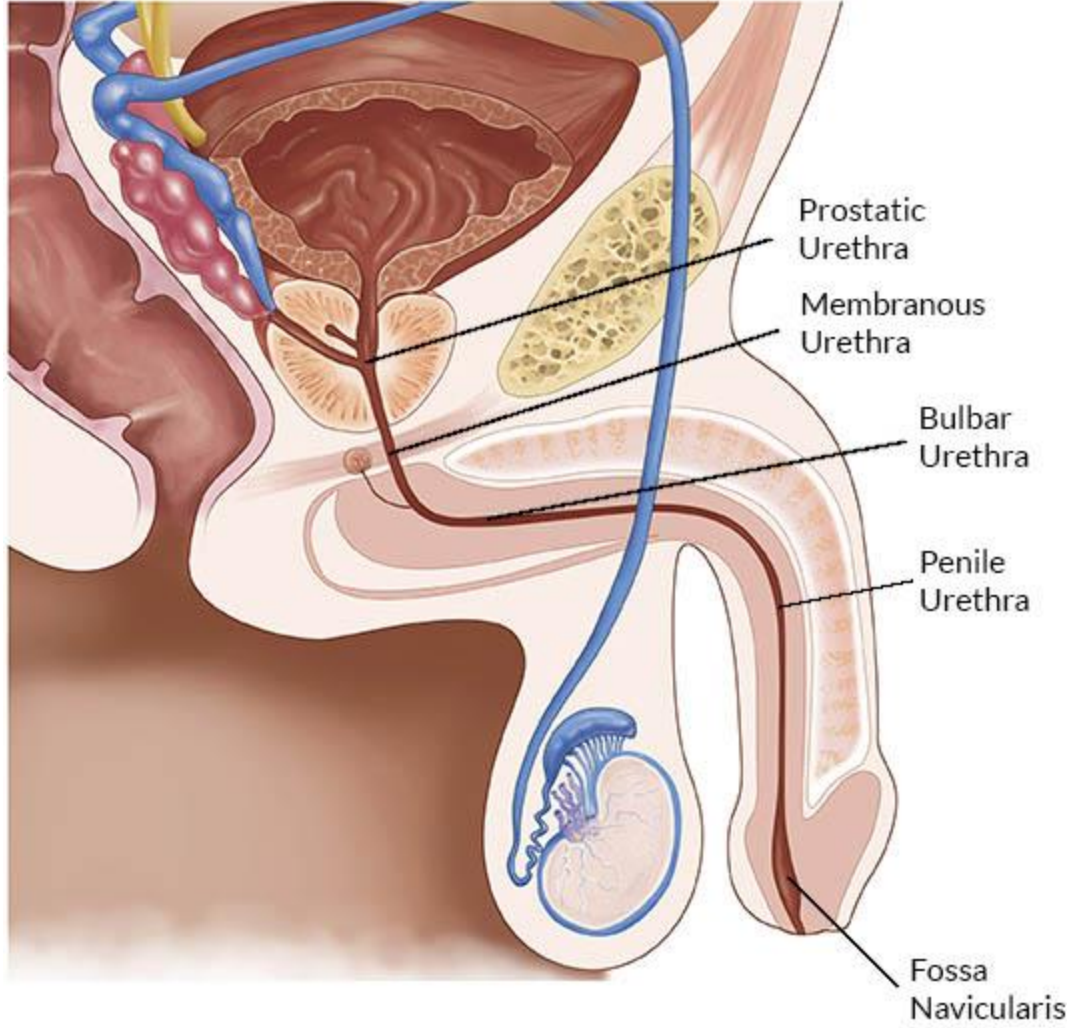
Prostate Gland



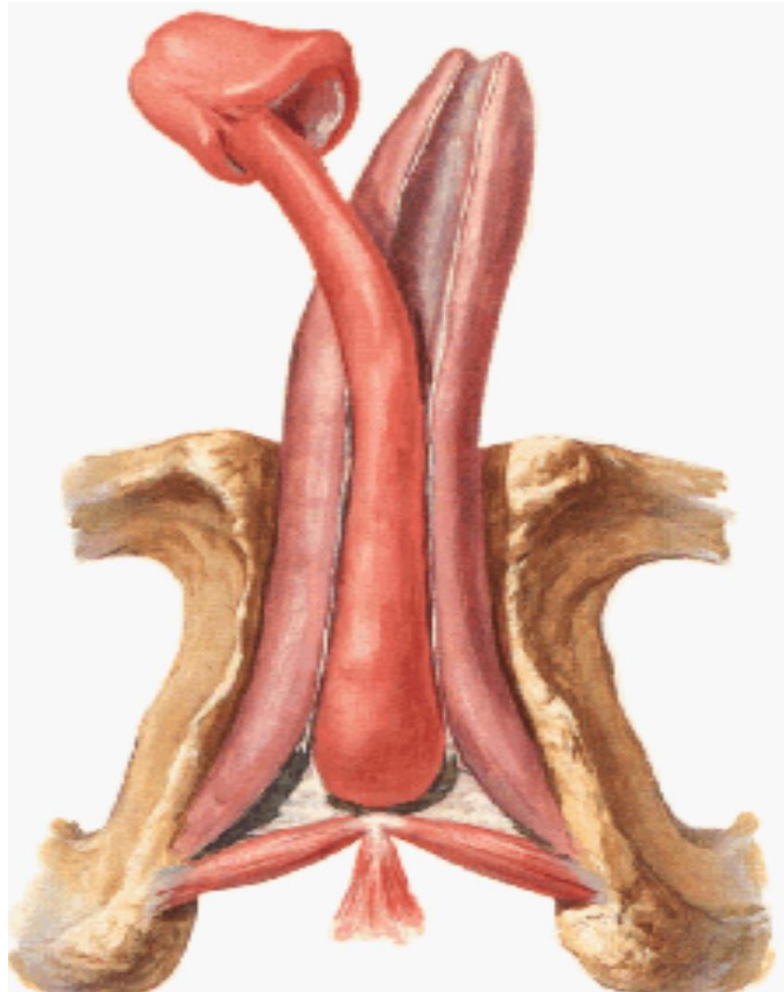
Bulbourethral Glands

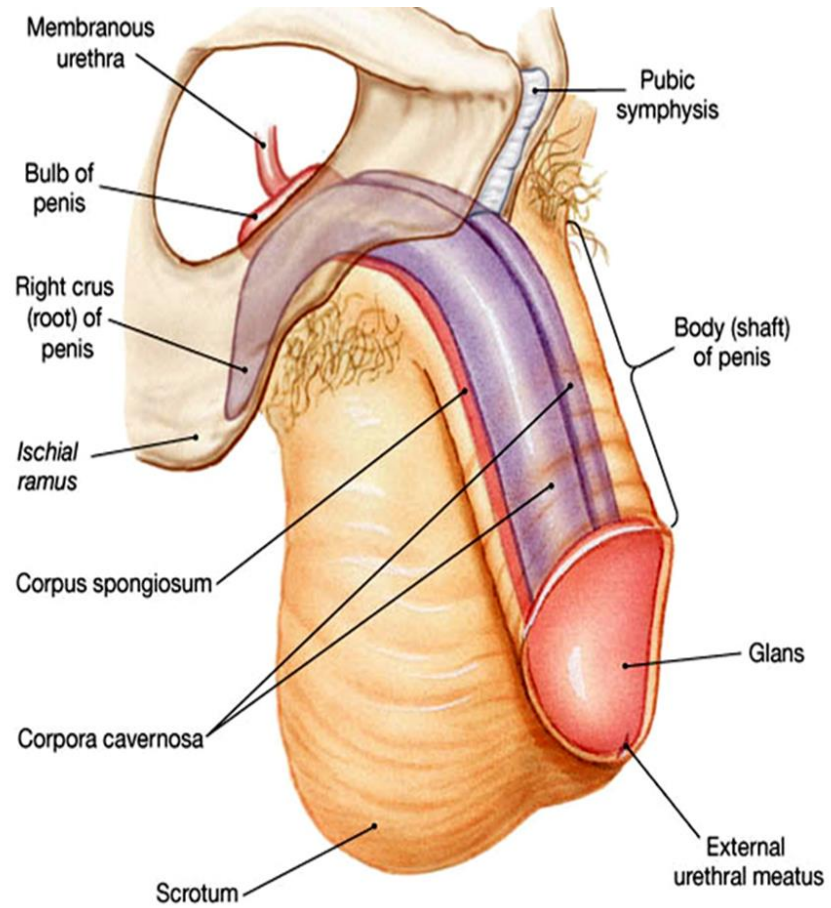






Penis





(c) Oblique lateral view

Thank You

Disclosure

Please be advised that this work is intended for non-profit purely educational purposes. We used some images from the internet and other sources. We did our best to link all images to their original sources to preserve copyrights. If you are the owner of one of those images, and you are not satisfied with our copyright level, please contact us and let us know how to make things right. We deeply appreciate your cooperation and consideration.

Contact: **anatomy@ksu.edu.sa**