

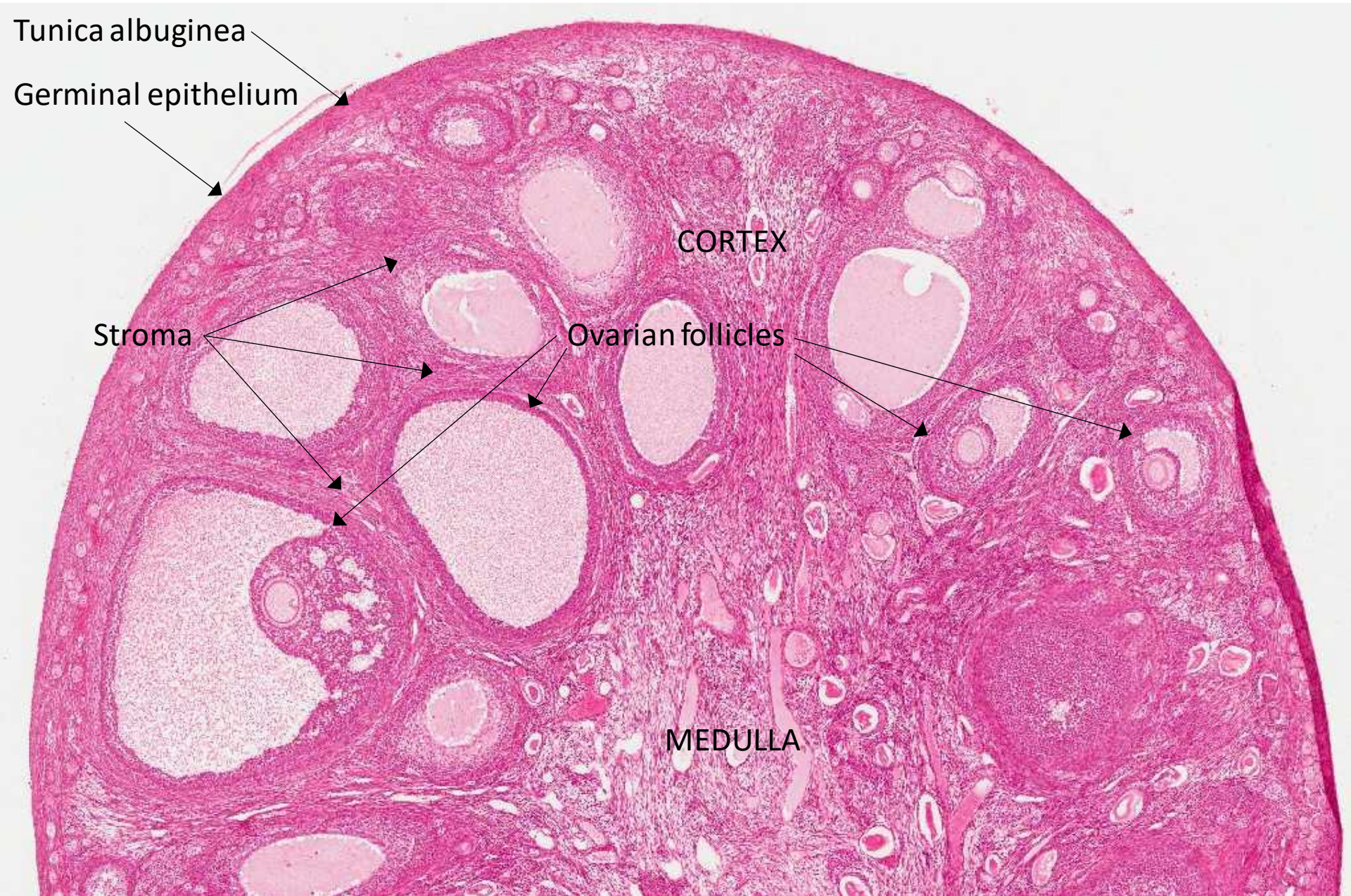
Histology Lab

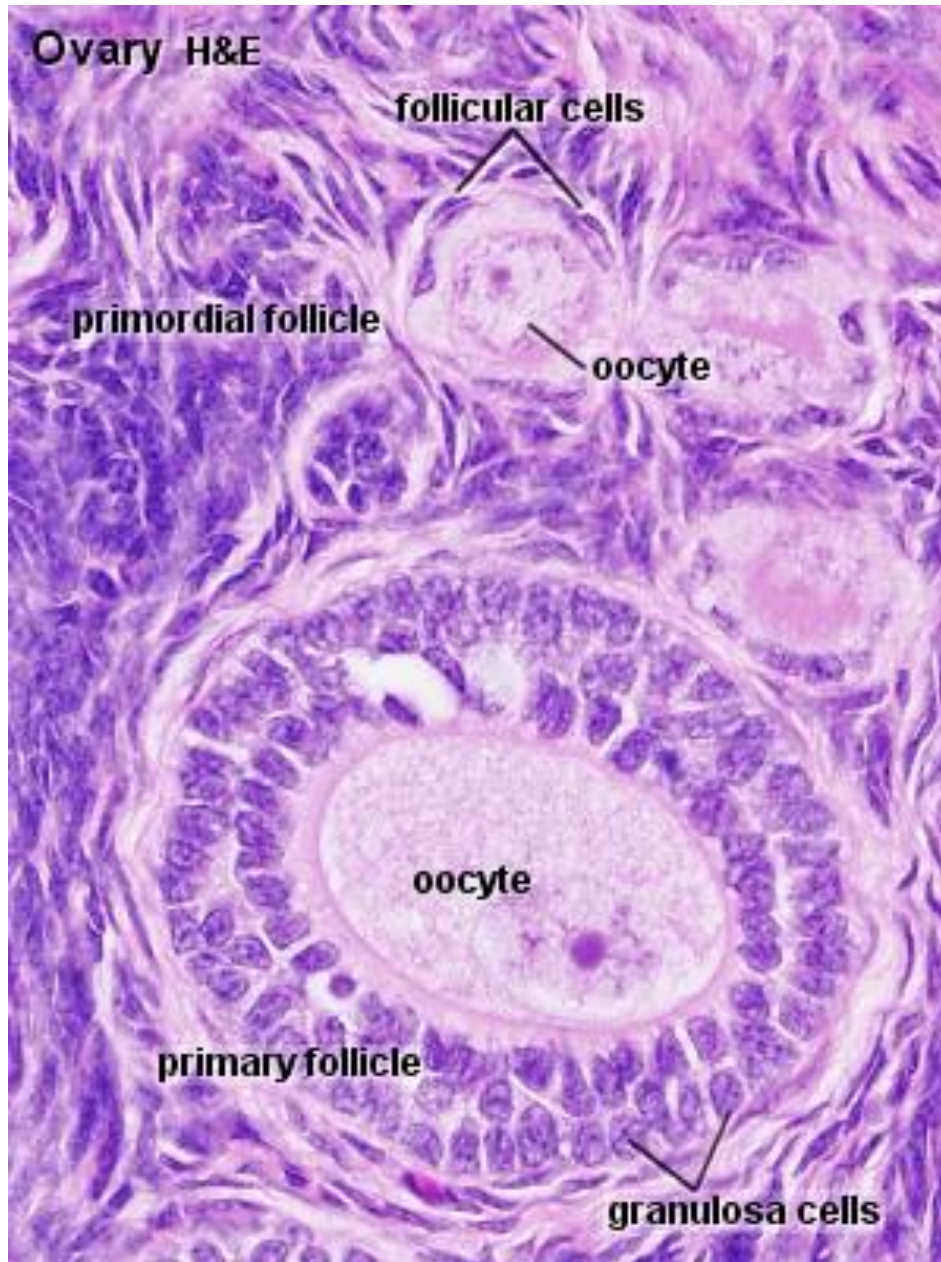Female Reproductive System

Dr. Muhammad Atteya
Anatomy Department
College of Medicine
King Saud University

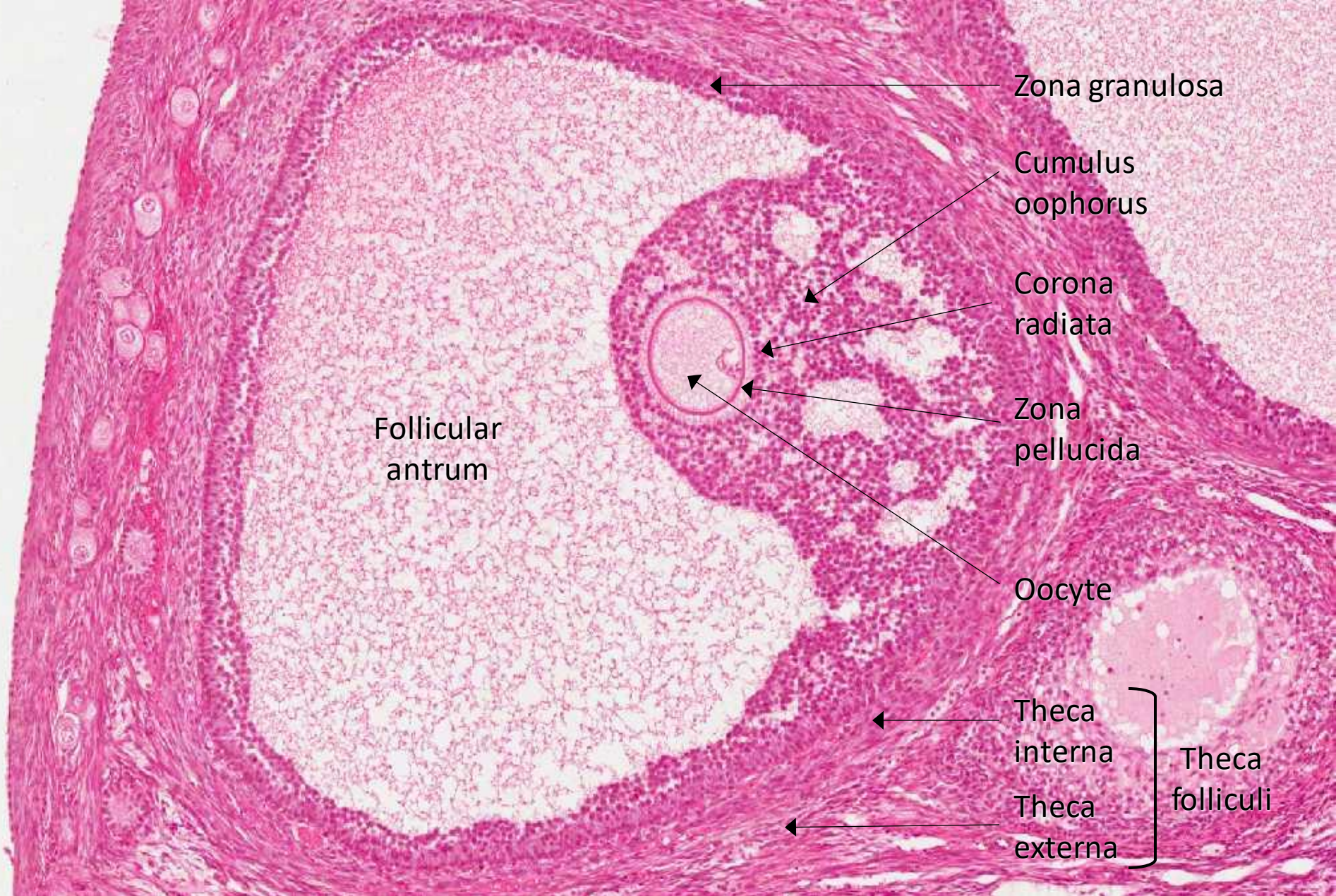


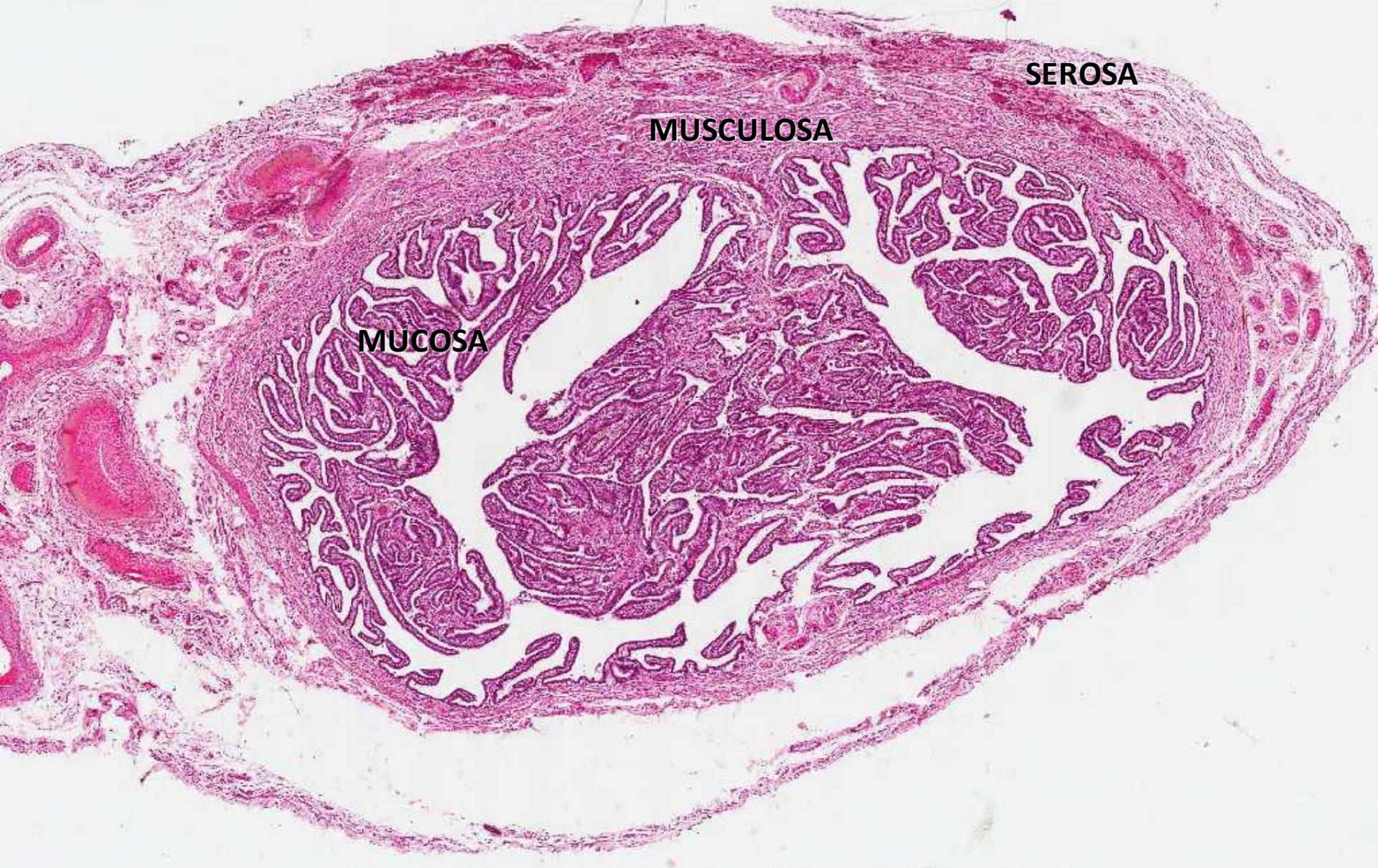
© 2020 KSU ANATOMY





Ovary – Primordial & Primary Follicles



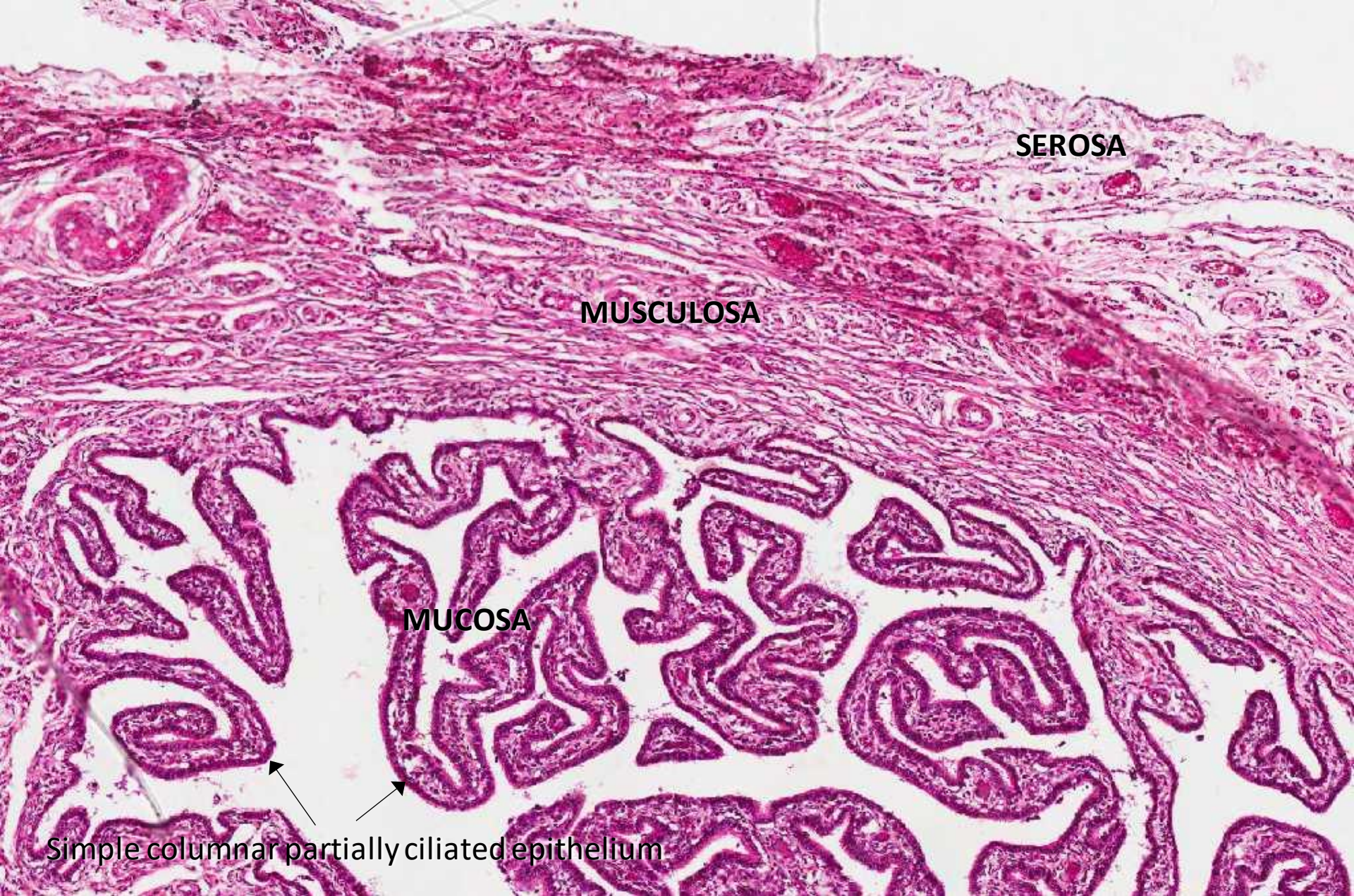

SEROSA

MUSCULOSA

MUCOSA

Fallopian Tube



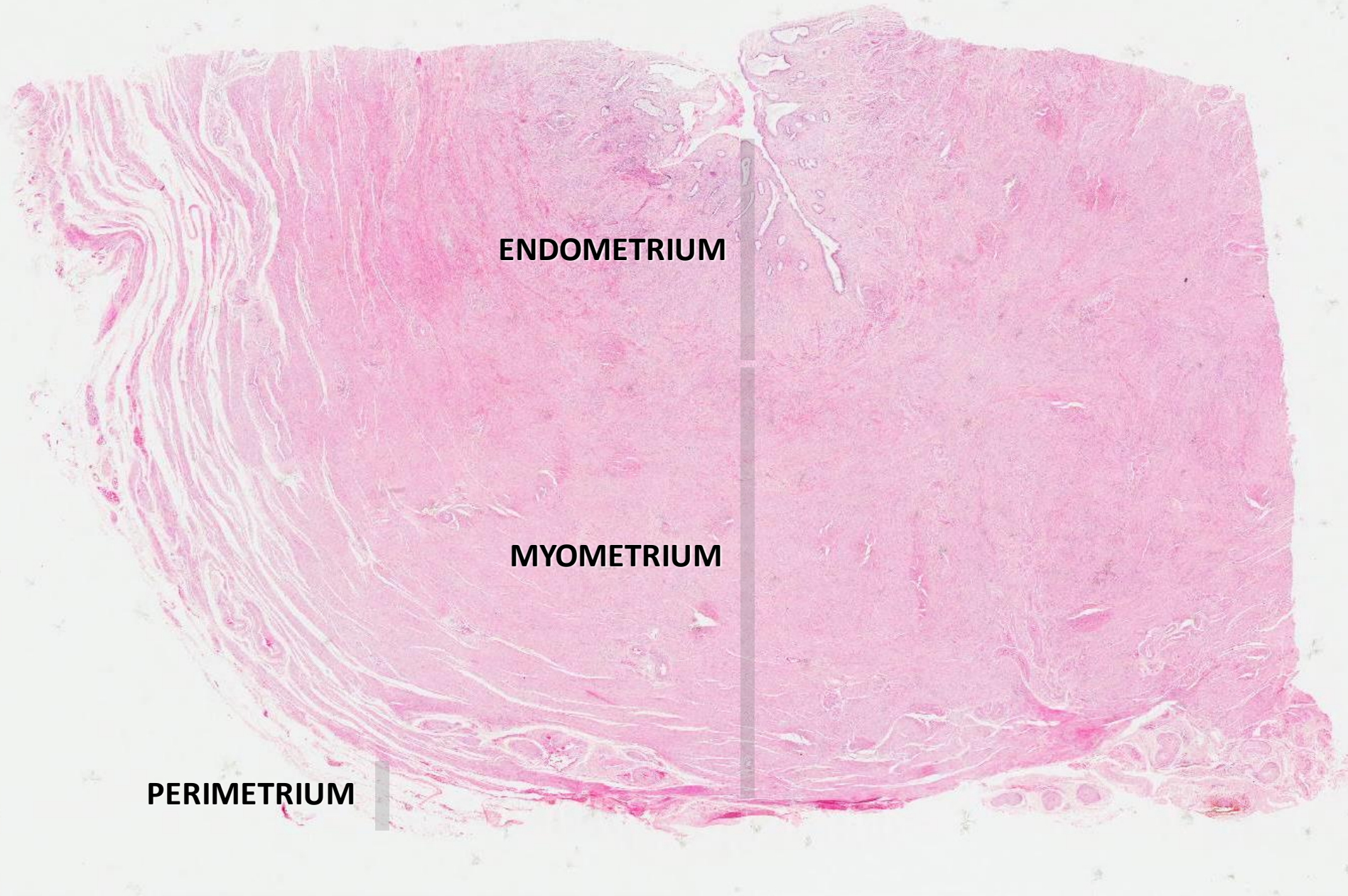
SEROSA

MUSCULOSA

MUCOSA

Simple columnar partially ciliated epithelium

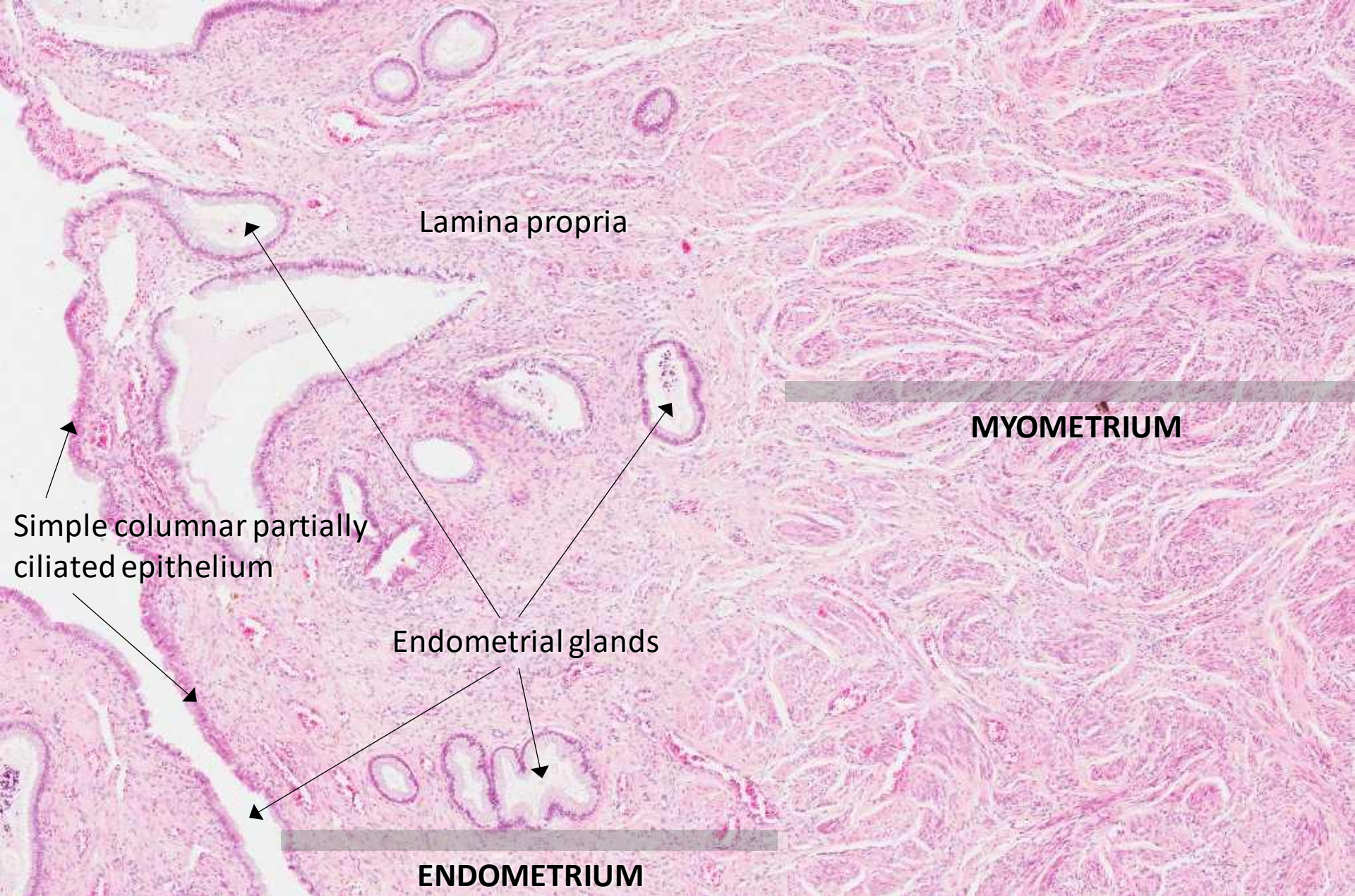
Fallopian Tube



ENDOMETRIUM

MYOMETRIUM

PERIMETRIUM



Lamina propria

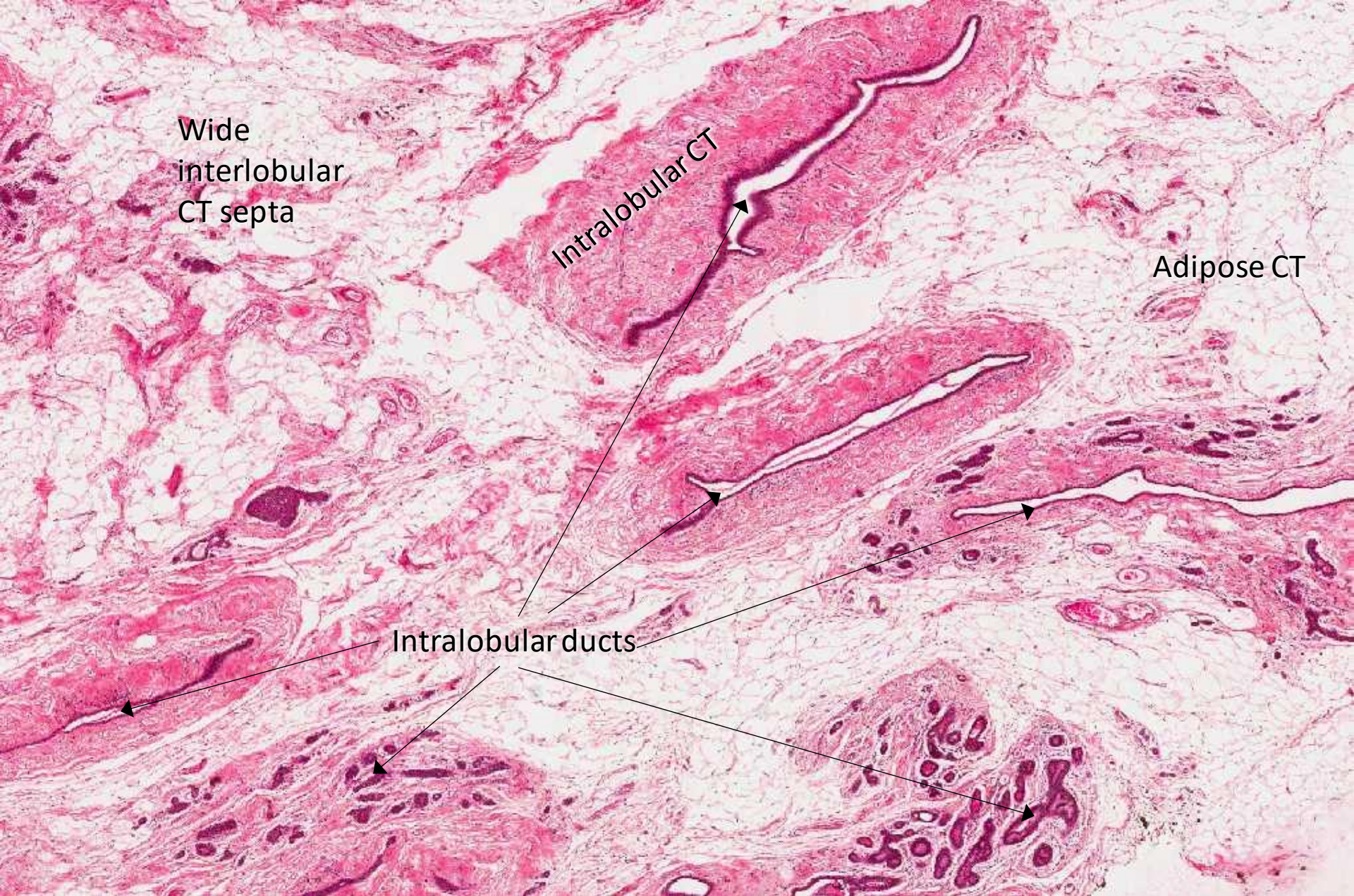
MYOMETRIUM

Simple columnar partially ciliated epithelium

Endometrial glands

ENDOMETRIUM

Uterus



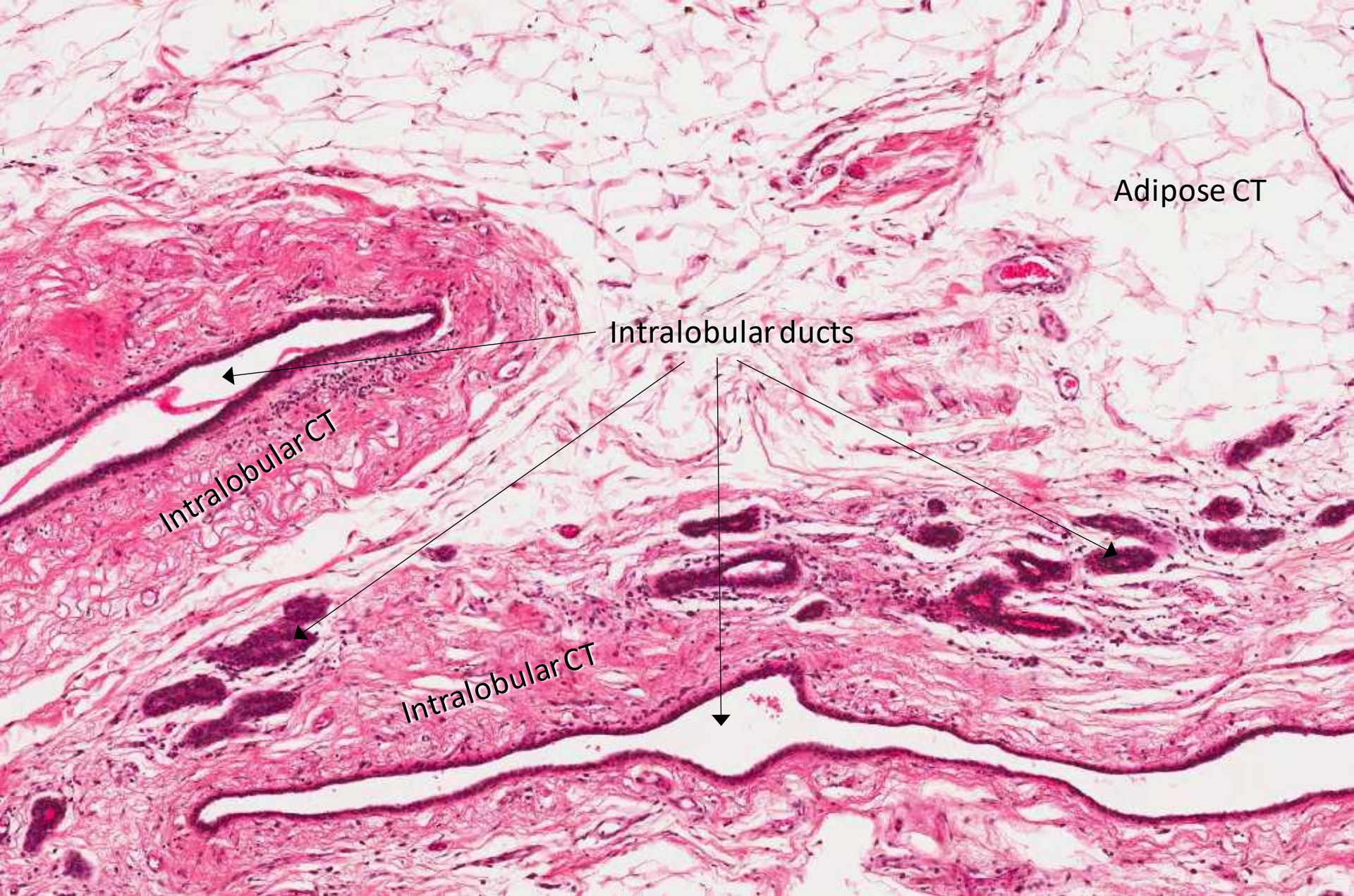Wide
interlobular
CT septa

Intralobular CT

Adipose CT

Intralobular ducts

Resting (Non-lactating) Mammary Gland



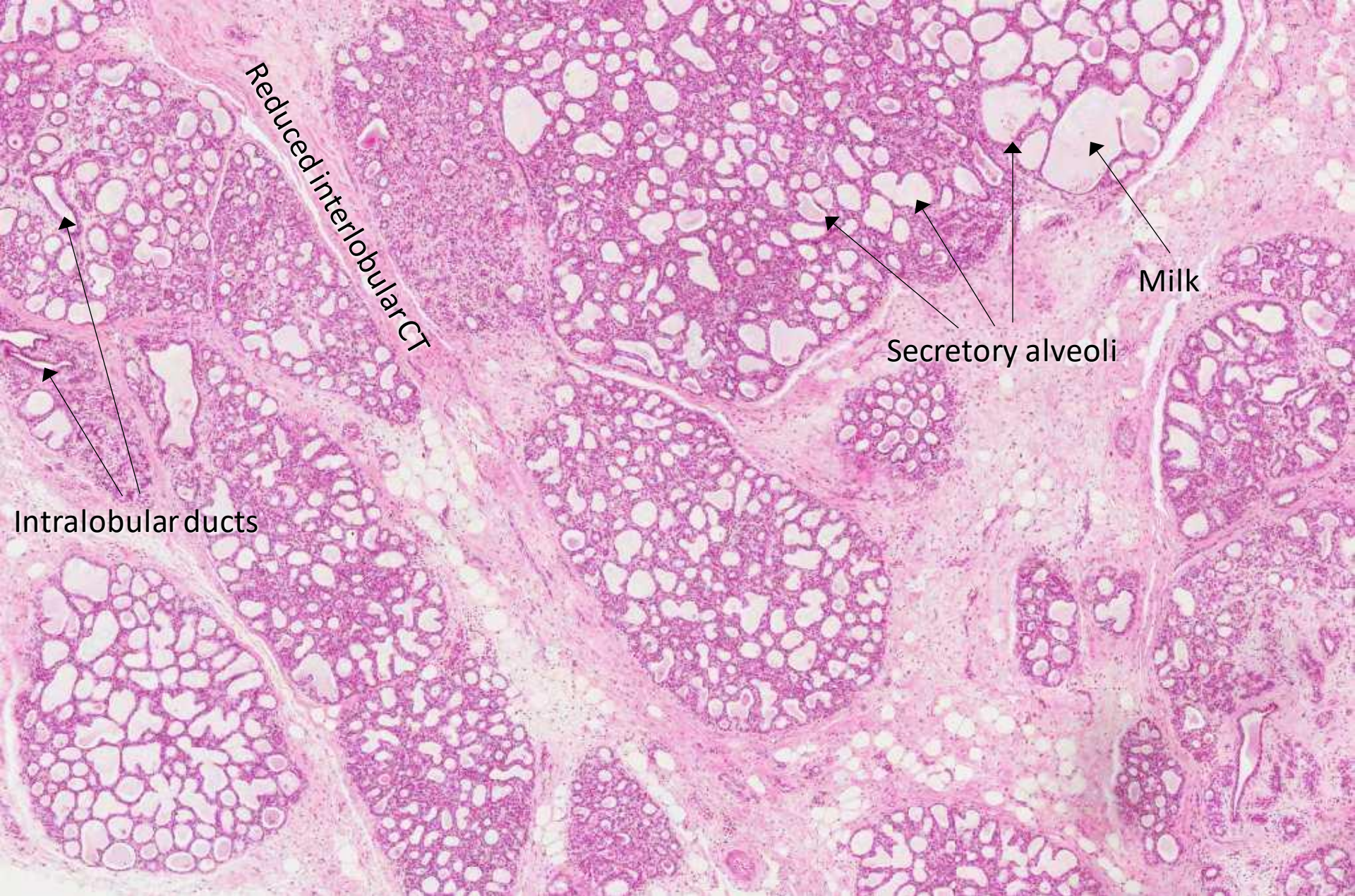
Adipose CT

Intralobular ducts

Intralobular CT

Intralobular CT

Resting (Non-lactating) Mammary Gland



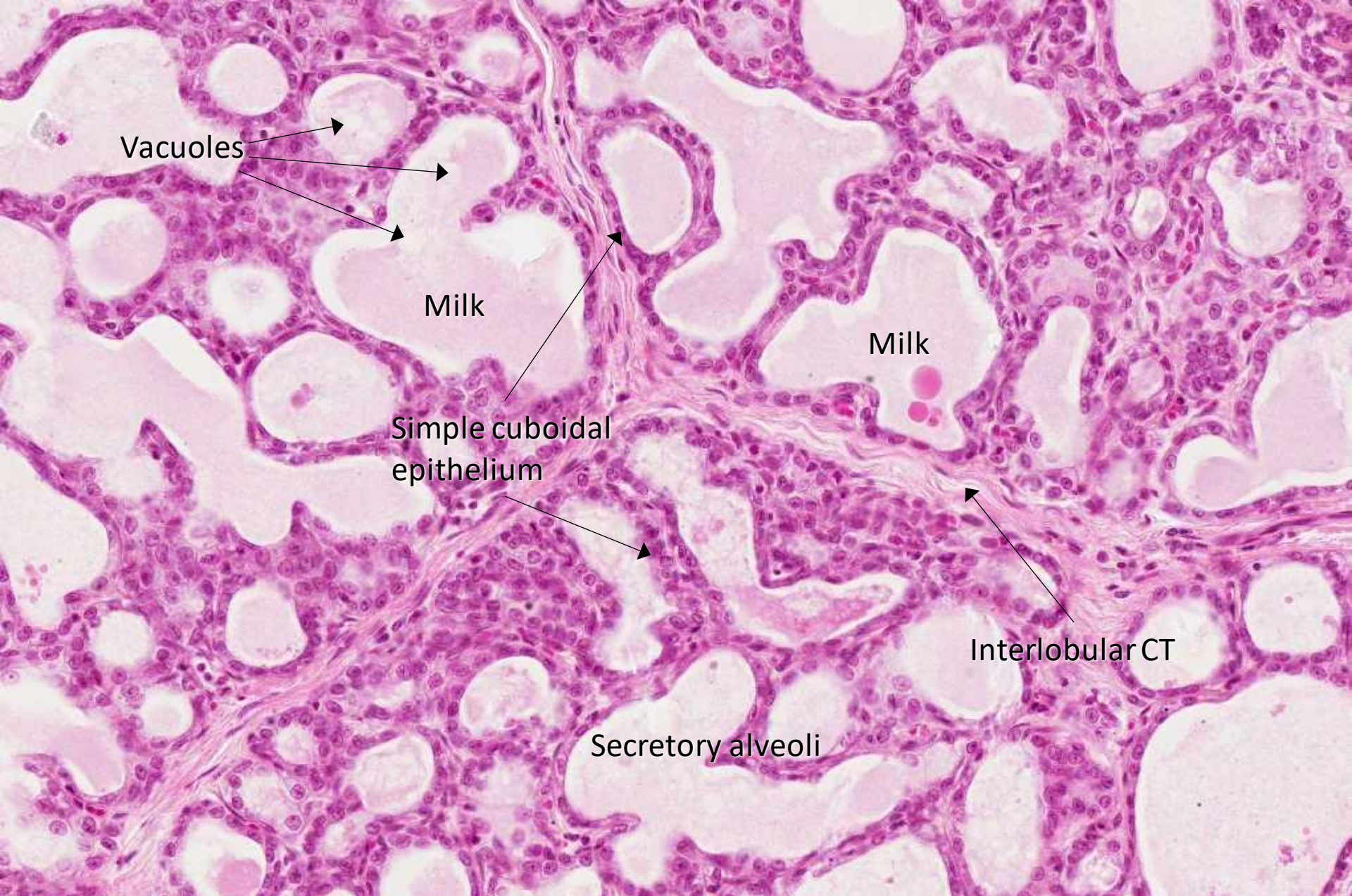
Reduced interlobular CT

Intralobular ducts

Secretory alveoli

Milk

Lactating Mammary Gland



Vacuoles

Milk

Milk

Simple cuboidal
epithelium

Interlobular CT

Secretory alveoli

Thank You



© 2020 KSU ANATOMY

Disclosure

Please be advised that this work is intended for non-profit purely educational purposes. We used some images from the internet and other sources. We did our best to link all images to their original sources to preserve copyrights. If you are the owner of one of those images, and you are not satisfied with our copyright level, please contact us and let us know how to make things right. We deeply appreciate your cooperation and consideration.

Contact: anatomy@ksu.edu.sa



© 2020 KSU ANATOMY