

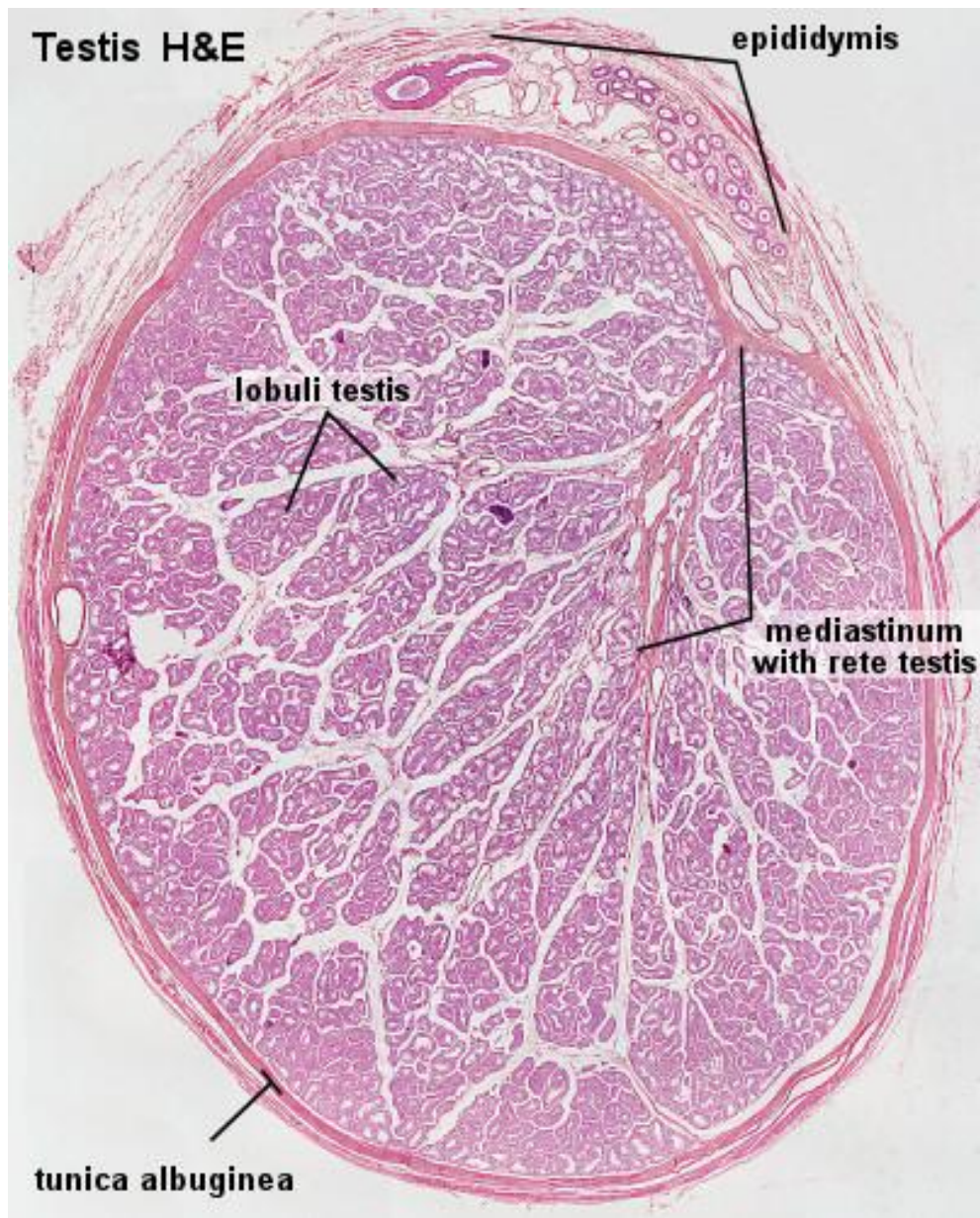
# Histology Lab

## Male Reproductive System

Dr. Muhammad Atteya  
Anatomy Department  
College of Medicine  
King Saud University

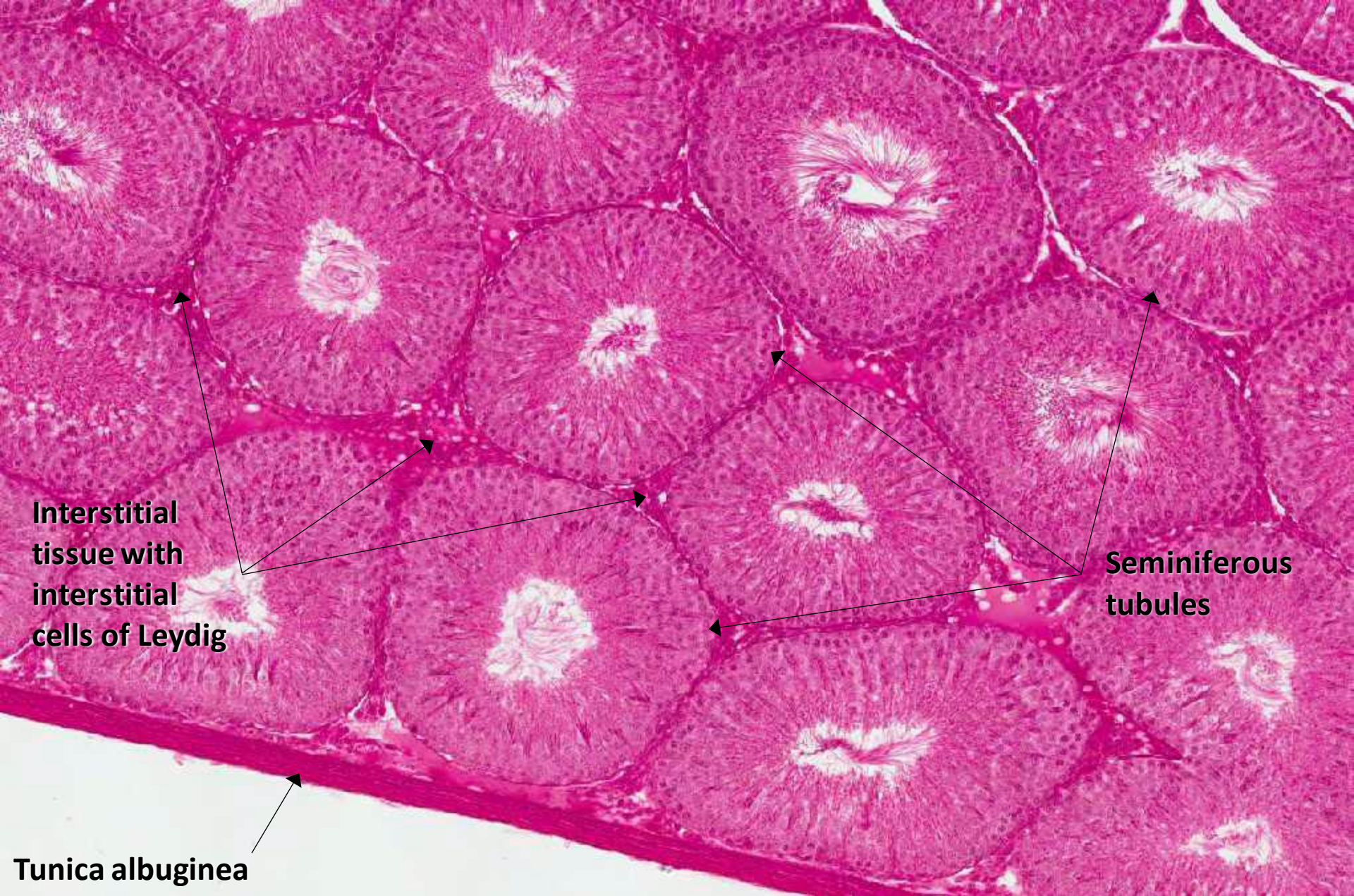

© 2020 KSU ANATOMY



## Testis – Overview





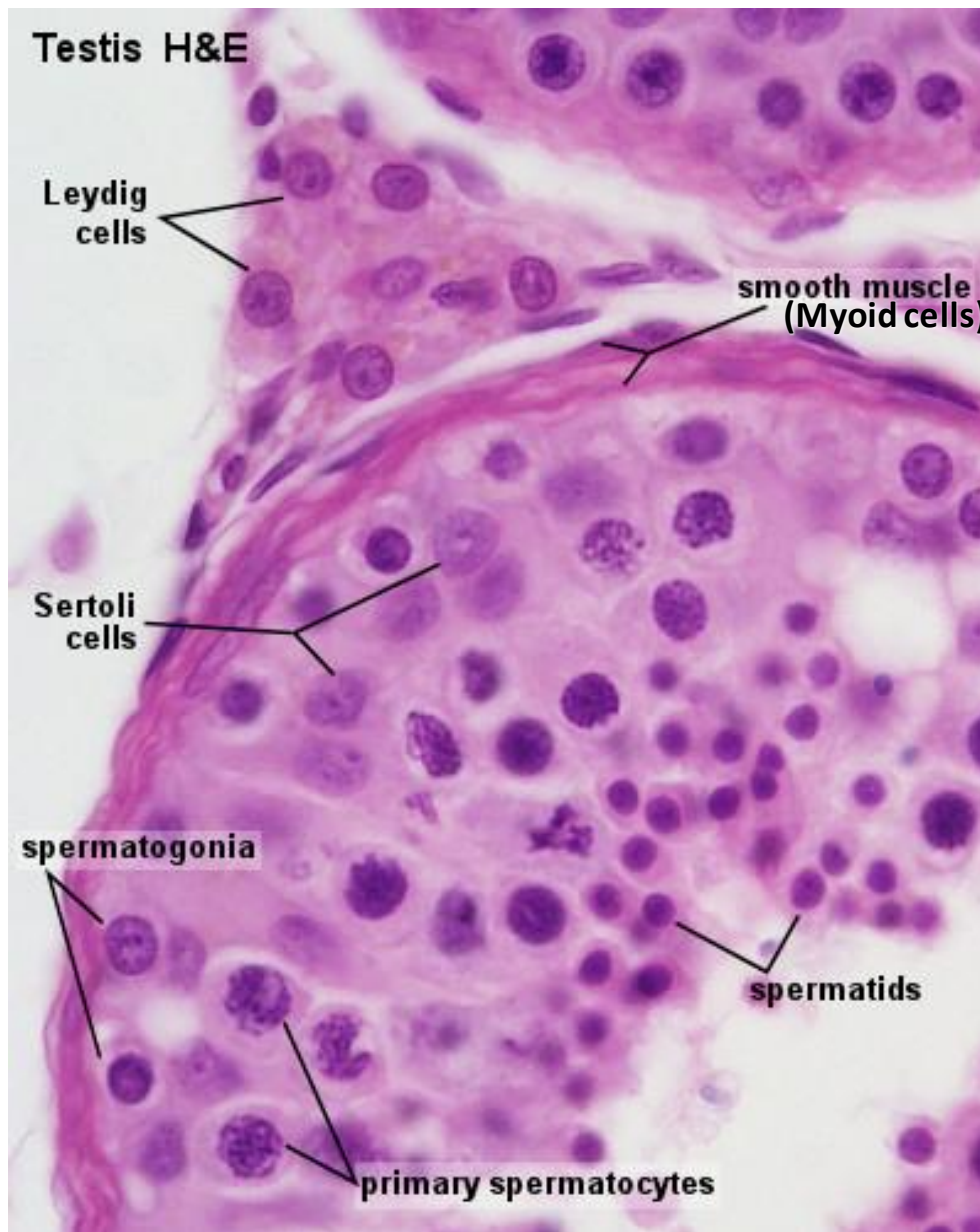
**Interstitial  
tissue with  
interstitial  
cells of Leydig**

**Seminiferous  
tubules**

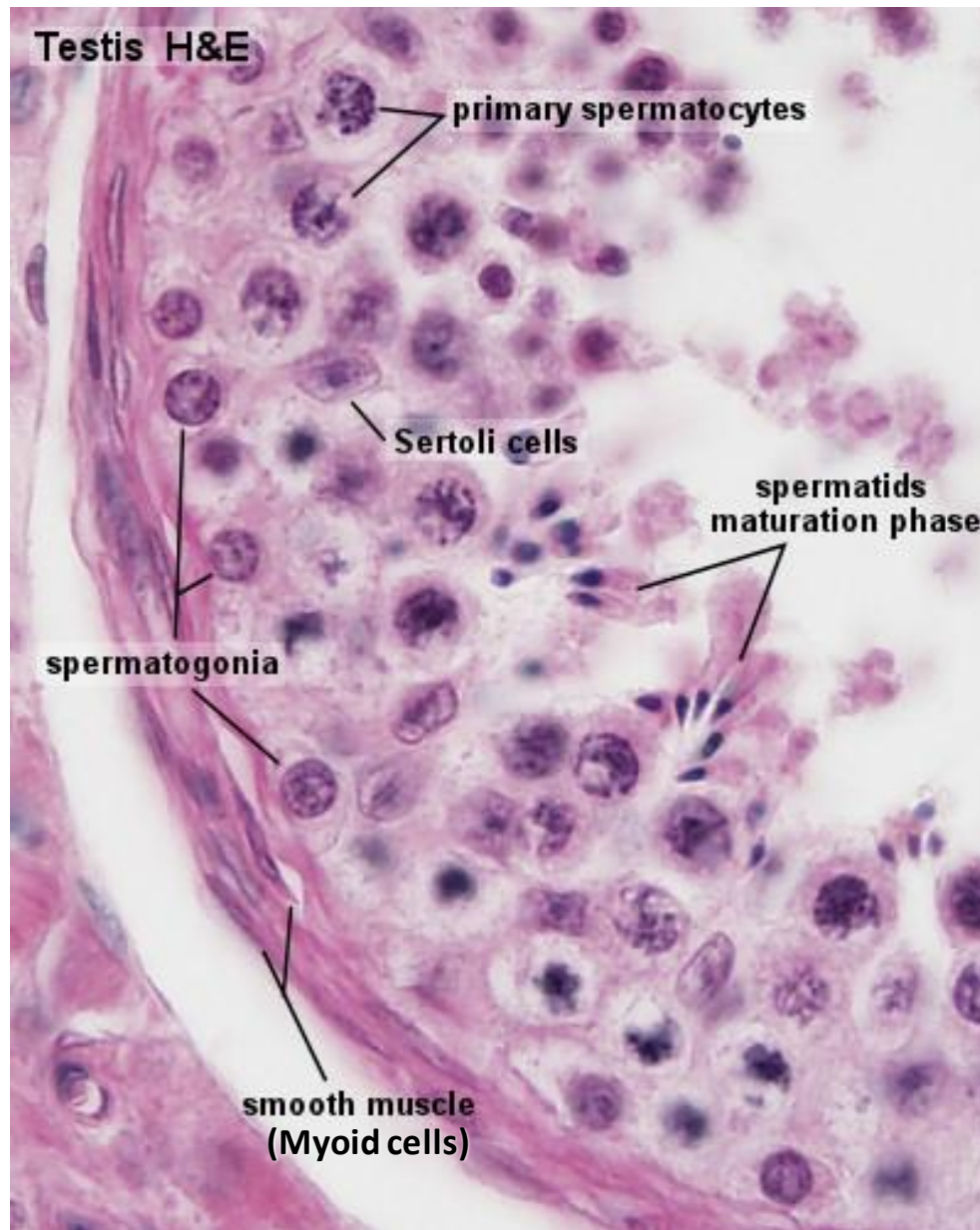
**Tunica albuginea**

# Testis



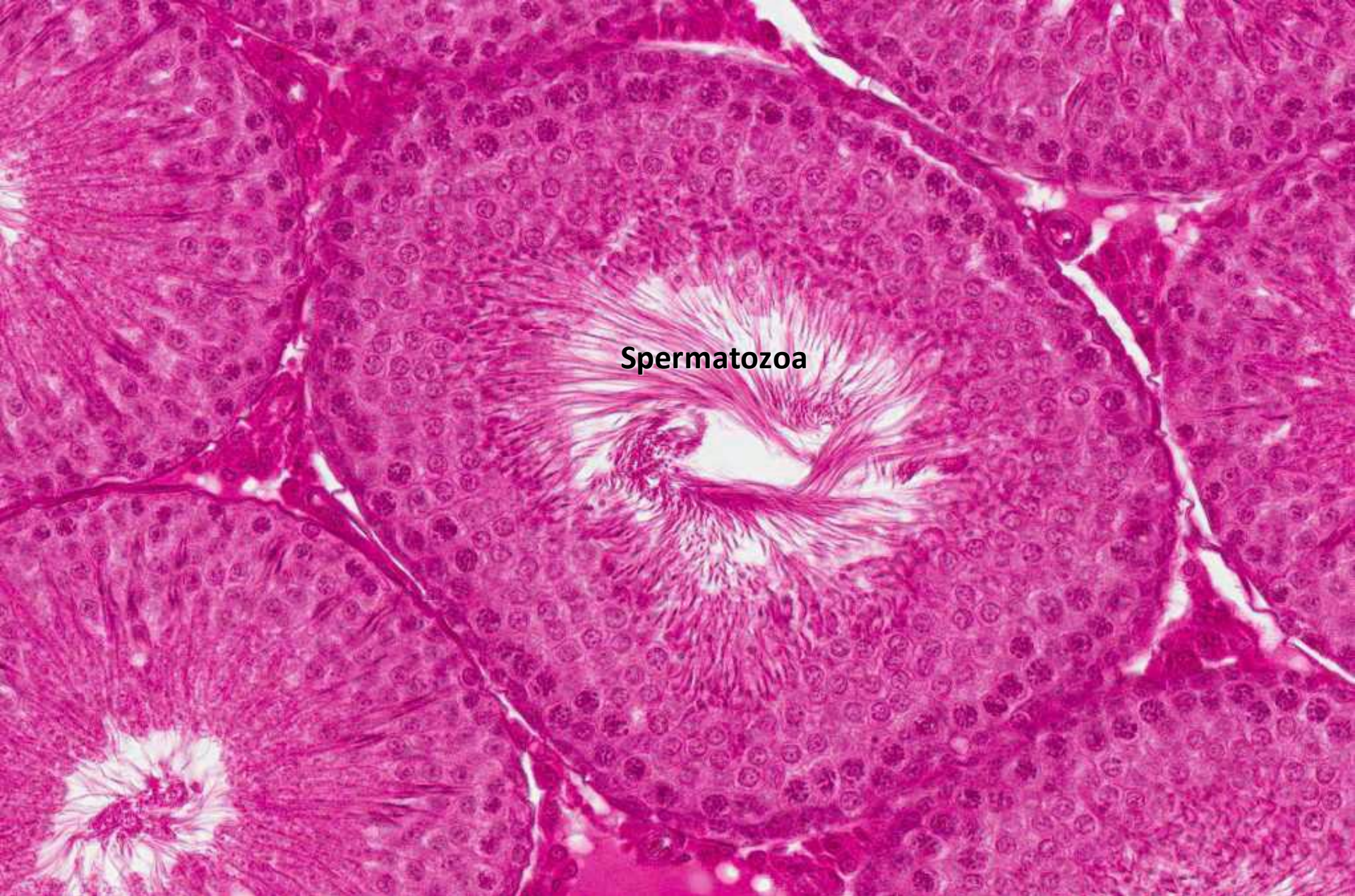

## Testis – Spermatogenic Epithelium



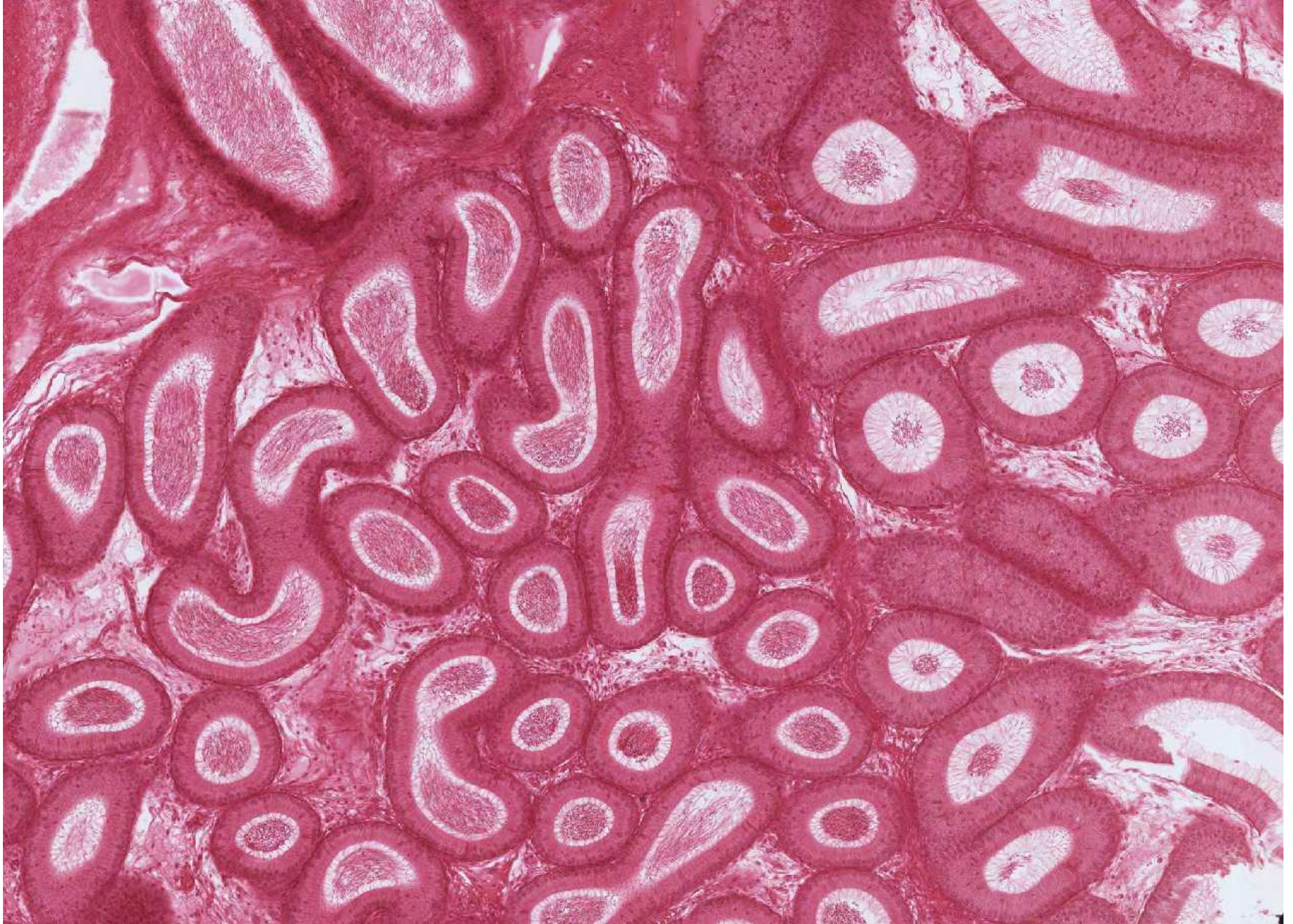
## Testis – Spermatogenic Epithelium





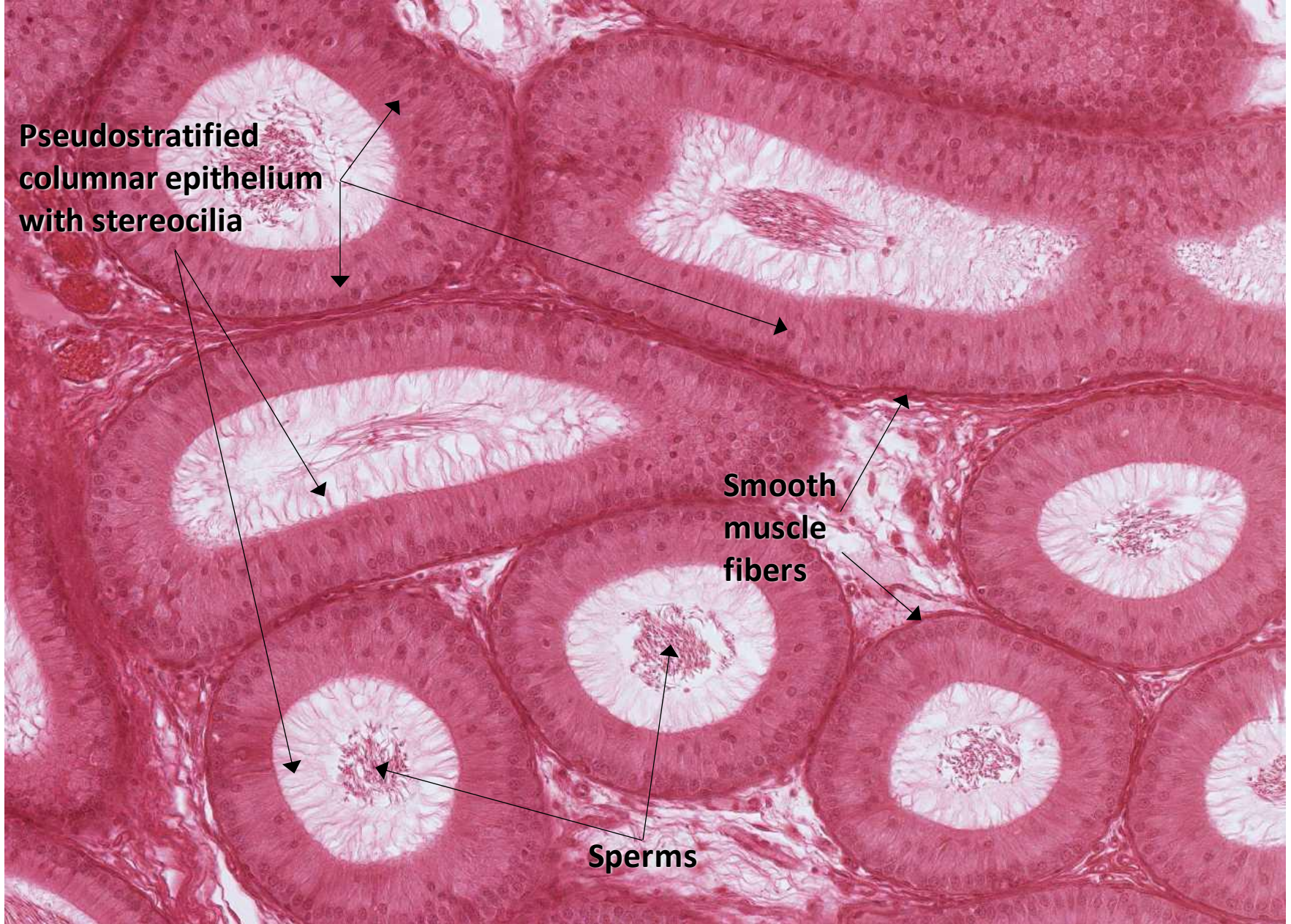
Spermatozoa





## Epididymis





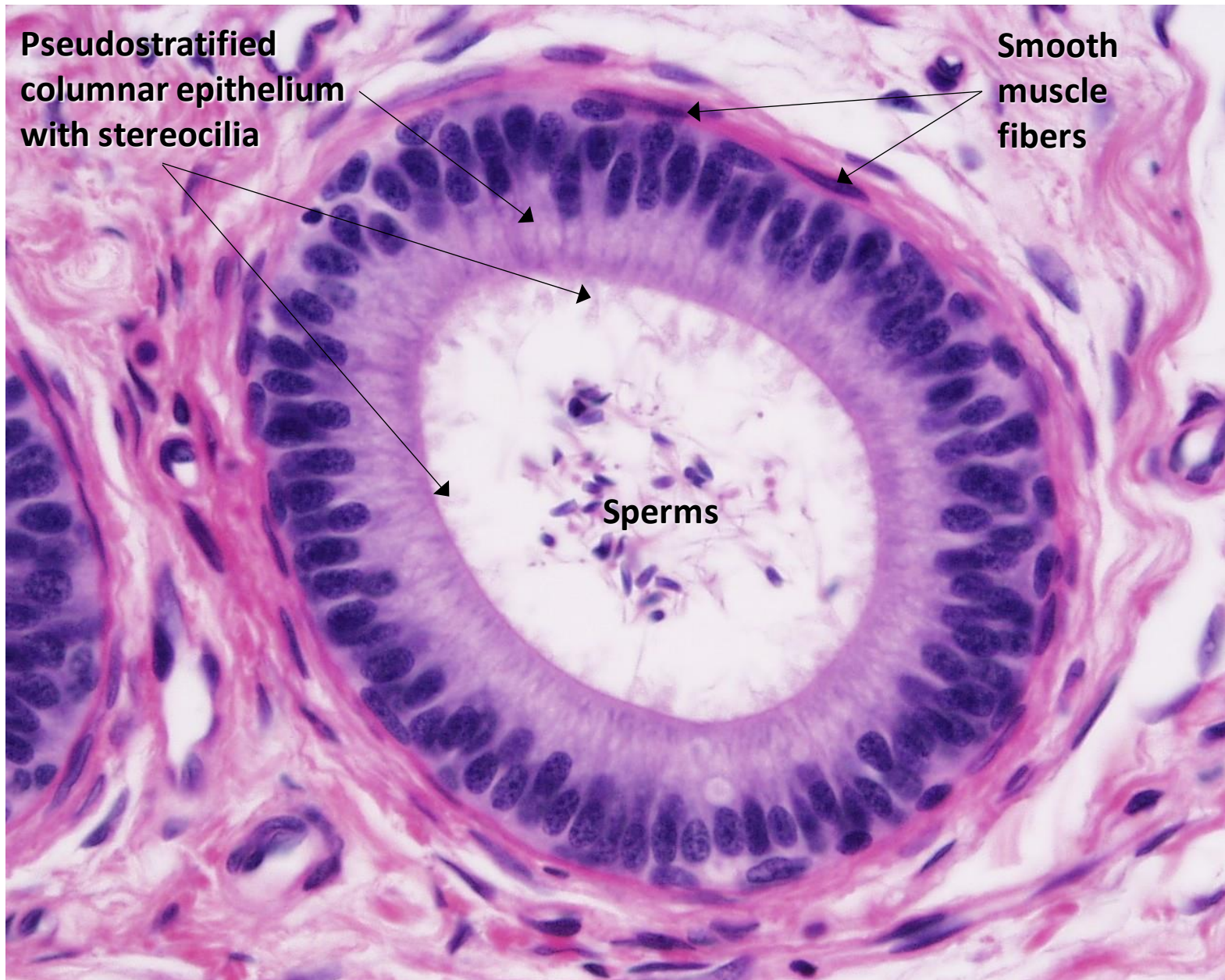
**Pseudostratified columnar epithelium with stereocilia**

**Smooth muscle fibers**

**Sperms**

## **Epididymis**





Pseudostratified columnar epithelium with stereocilia

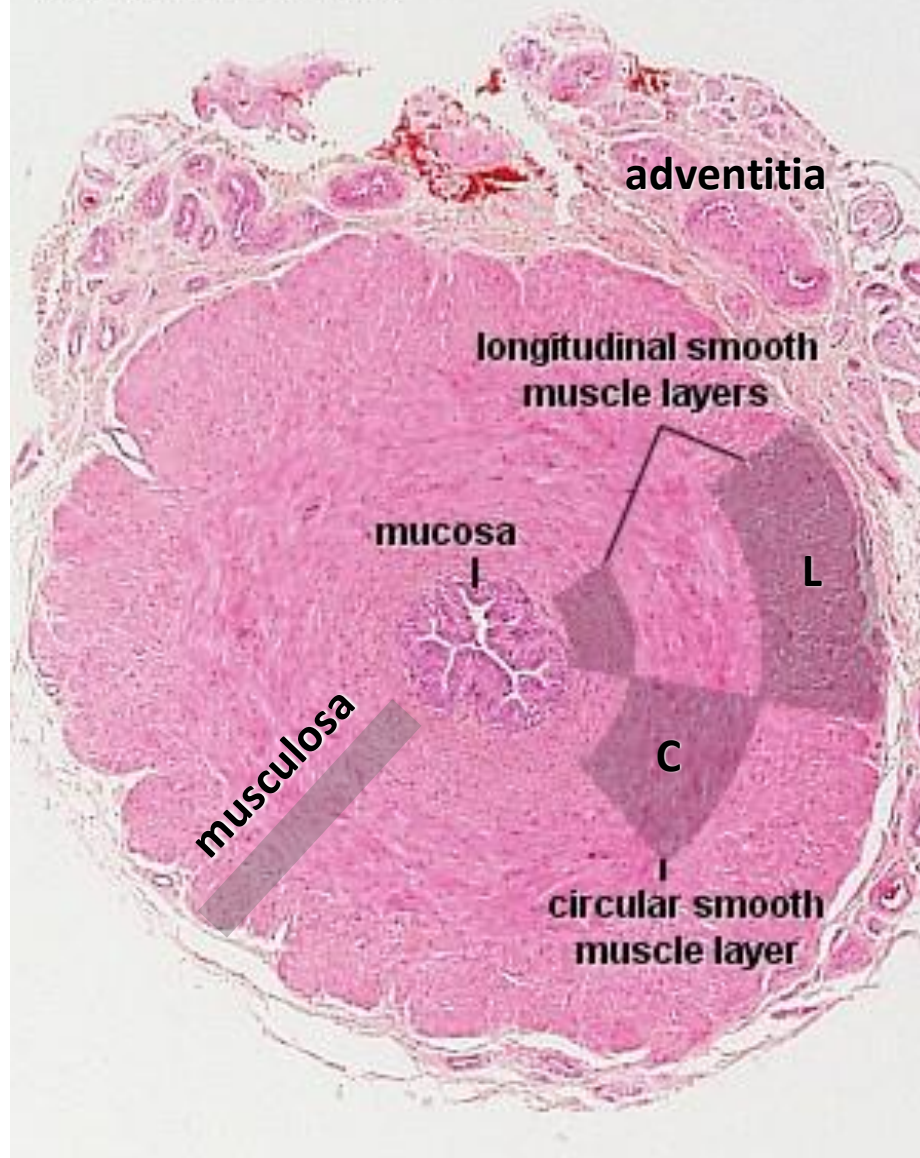
Smooth muscle fibers

Sperms

## Epididymis



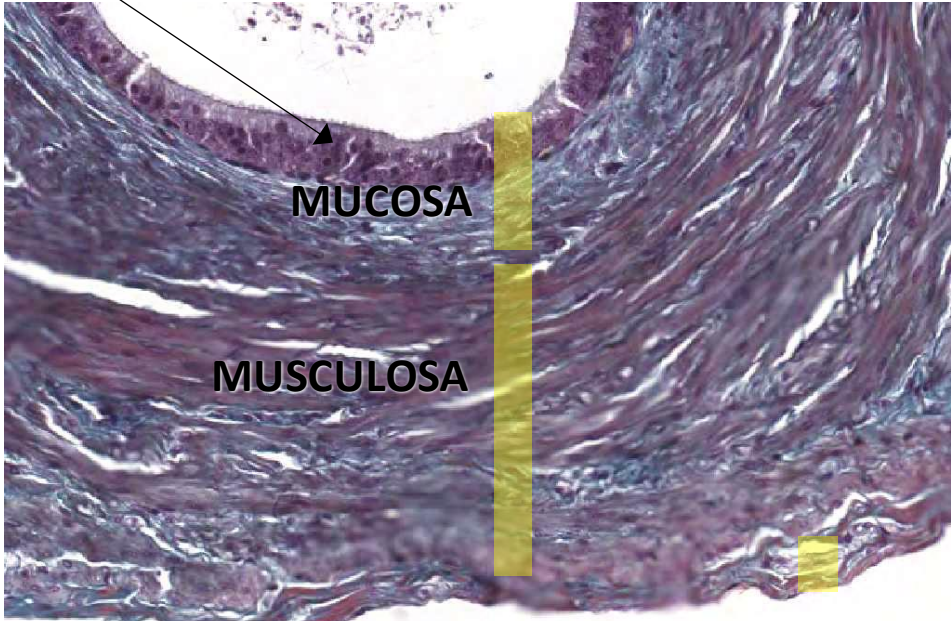
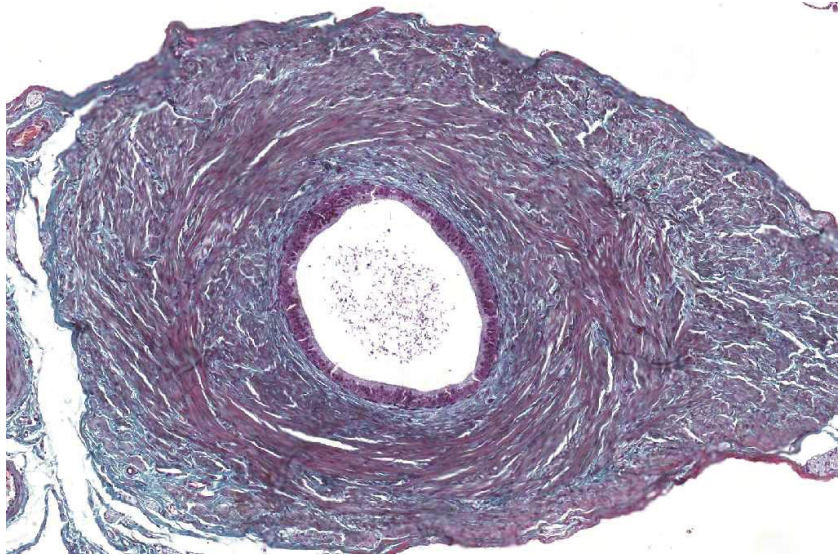
## Vas deferens H&E



# Vas Deferens



**Pseudostratified  
columnar epithelium  
with stereocilia**



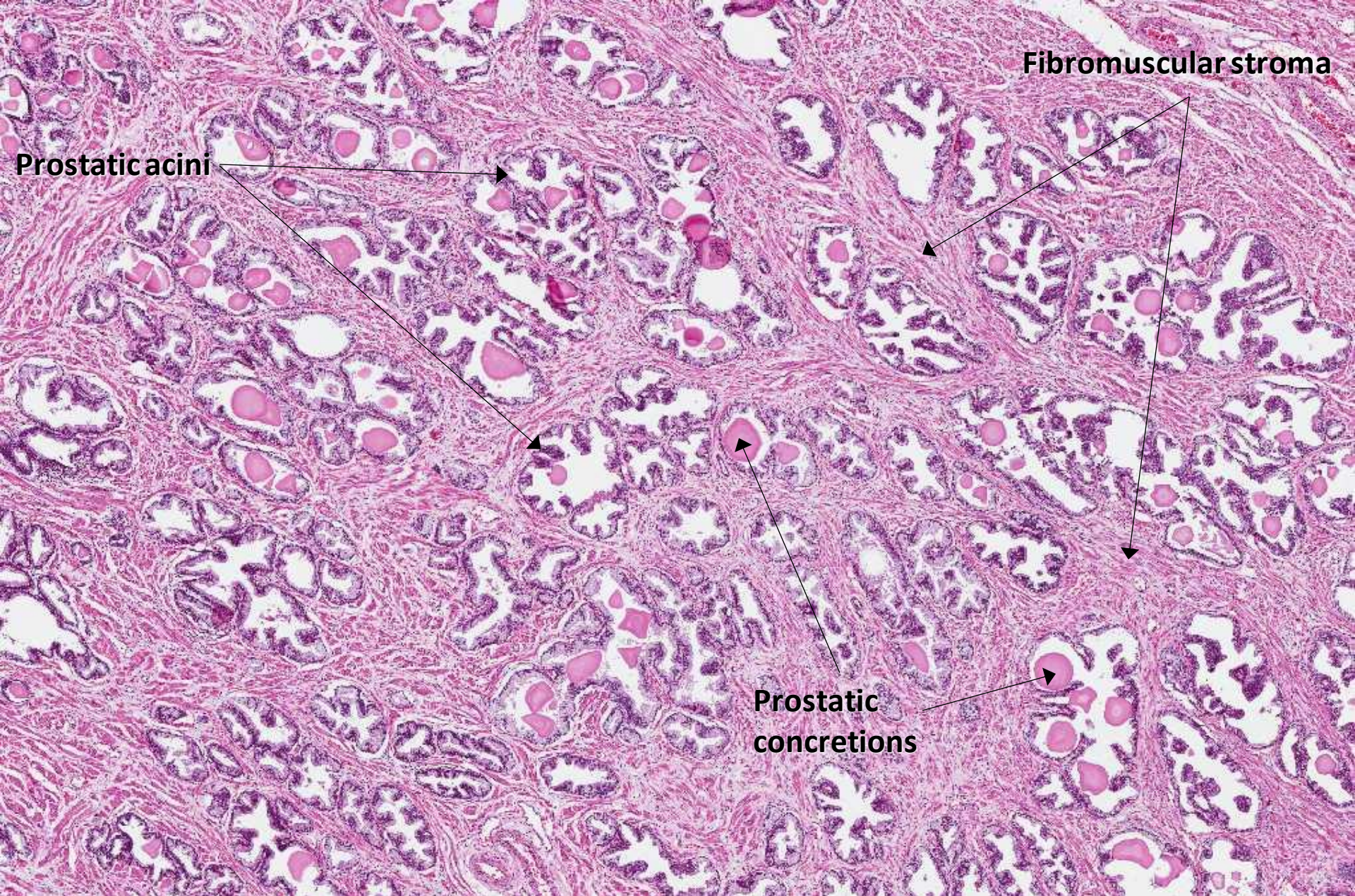
**MUCOSA**

**MUSCULOSA**

**ADVENTITIA**

# Vas Deferens





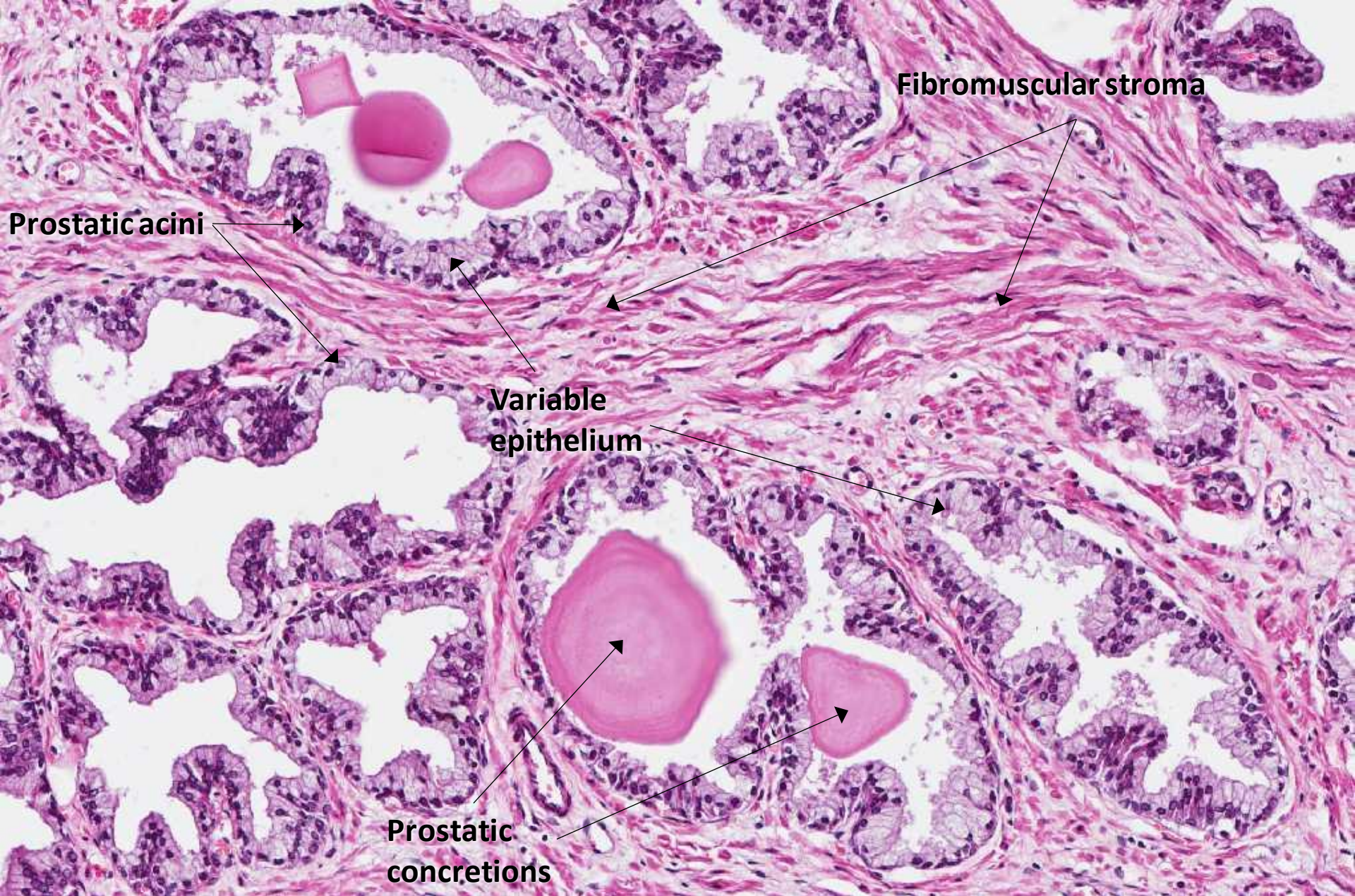
Fibromuscular stroma

Prostatic acini

Prostatic concretions

# Prostate





**Fibromuscular stroma**

**Prostatic acini**

**Variable  
epithelium**

**Prostatic  
concretions**

# Prostate



Thank You



© 2020 KSU ANATOMY



## Disclosure

Please be advised that this work is intended for non-profit purely educational purposes. We used some images from the internet and other sources. We did our best to link all images to their original sources to preserve copyrights. If you are the owner of one of those images, and you are not satisfied with our copyright level, please contact us and let us know how to make things right. We deeply appreciate your cooperation and consideration.

Contact: [anatomy@ksu.edu.sa](mailto:anatomy@ksu.edu.sa)



© 2020 KSU ANATOMY