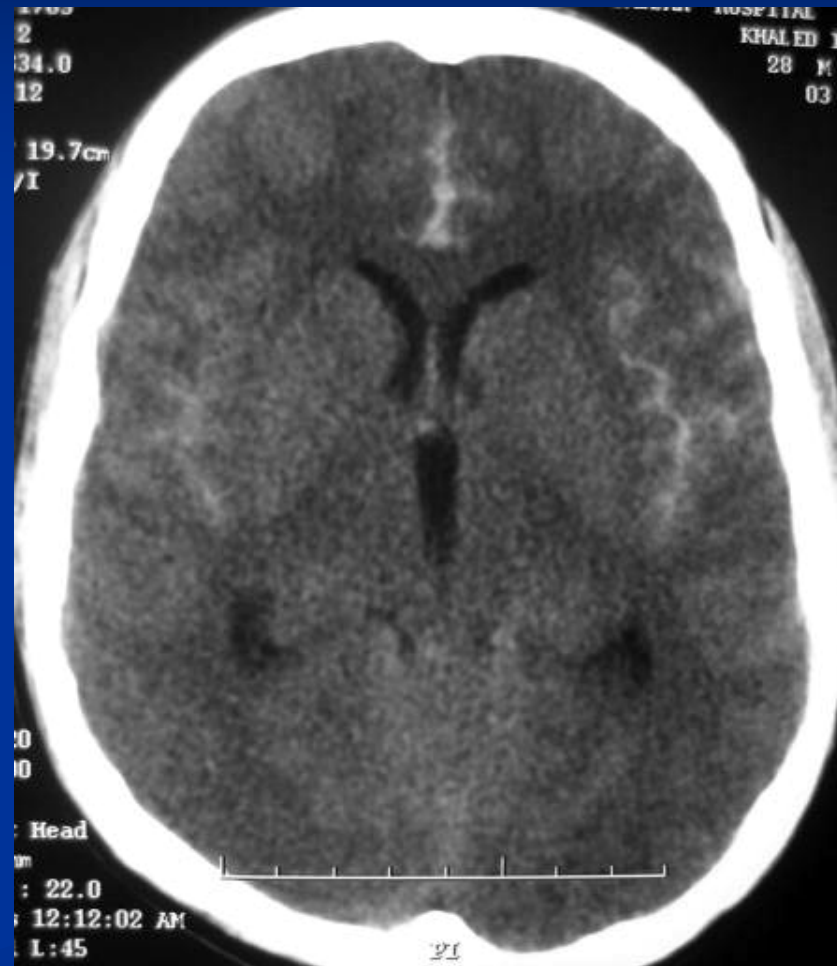


This patient presented with sudden headache. CT shows:

- A. Brain edema
- B. Subfalcine herniation
- C. Subarachnoid hemorrhage
- D. Brain abscess
- E. Brain tumor



This CT shows:

- A. Infarction
- B. Skull fracture
- C. Epidural hematoma
- D. Meningioma
- E. Falx hematoma

