

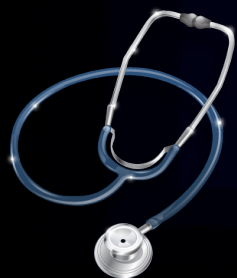

INTERACTIVE SESSION CHEST & CARDIOVASCULAR RADIOLOGY

AHMAD AMER AL-BOUKAI

KING KHALID UNIVERSITY HOSPITAL
KING SAUD UNIVERSITY

22/10/2011

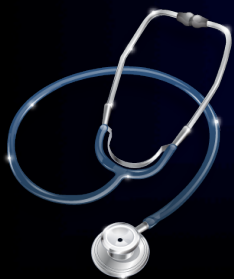



OBJECTIVES

Students at the end of the lecture will be able to:

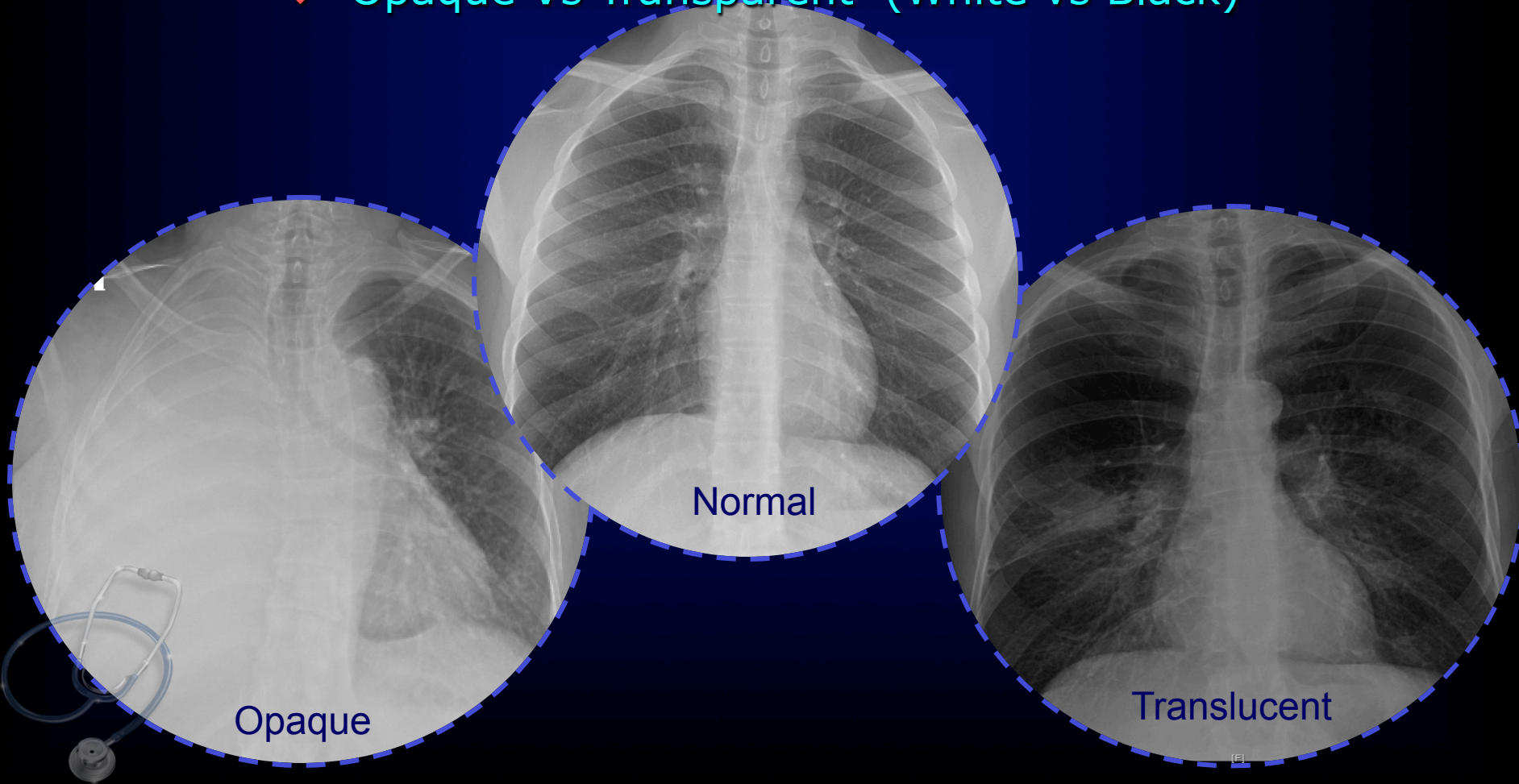
- ❖ Recognize different terms utilized in chest & cardiovascular radiography
- ❖ Develop a consistent and simplified technique for reading CXR
- ❖ Define the chest pattern of abnormality seen on the CXR





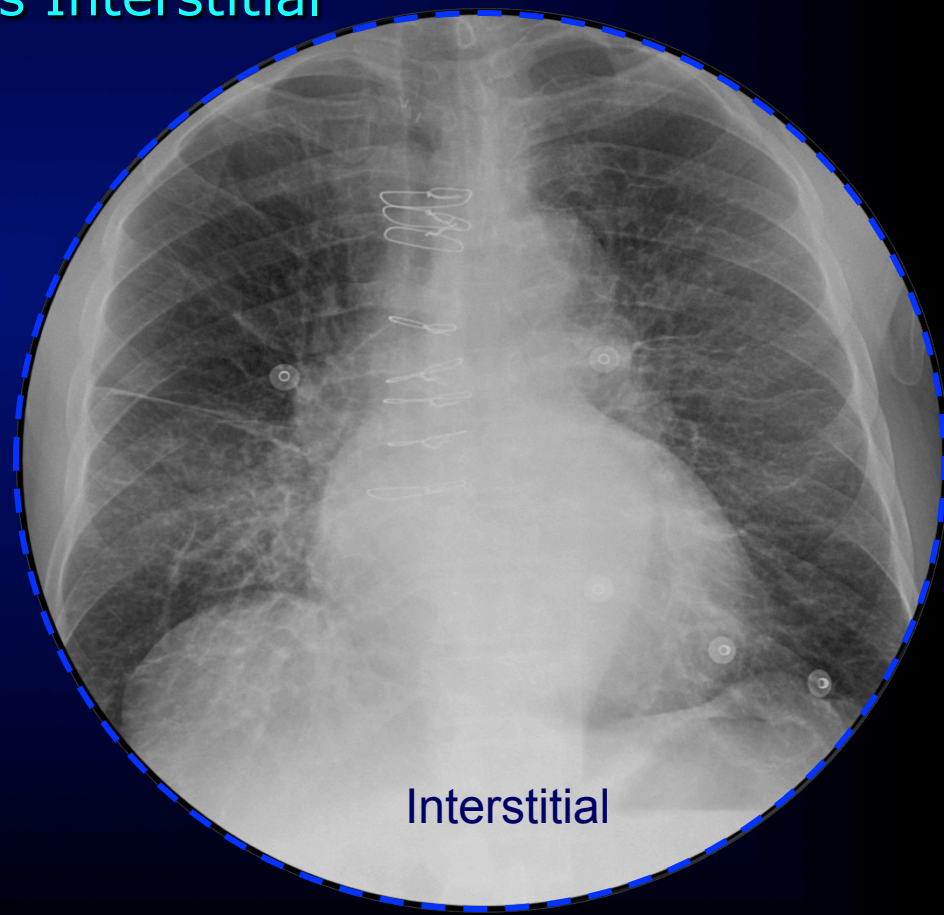
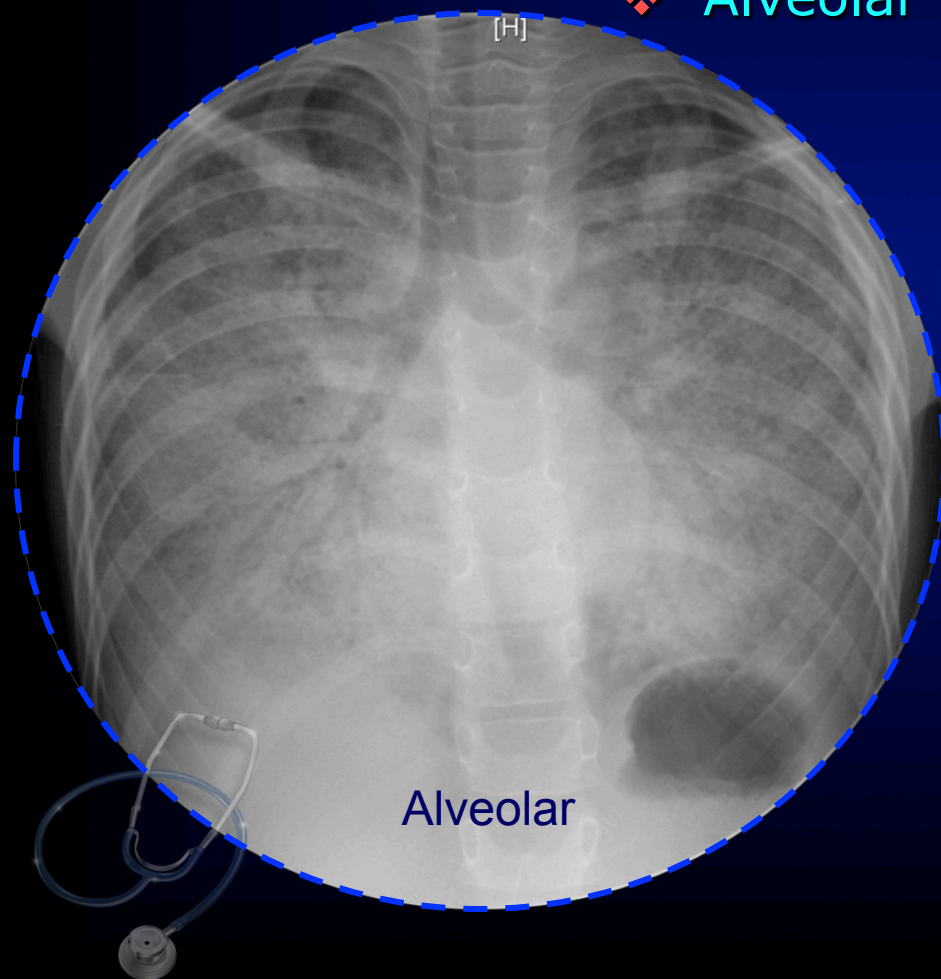
IMPORTANT TERMS

❖ Opaque Vs Transparent (White vs Black)



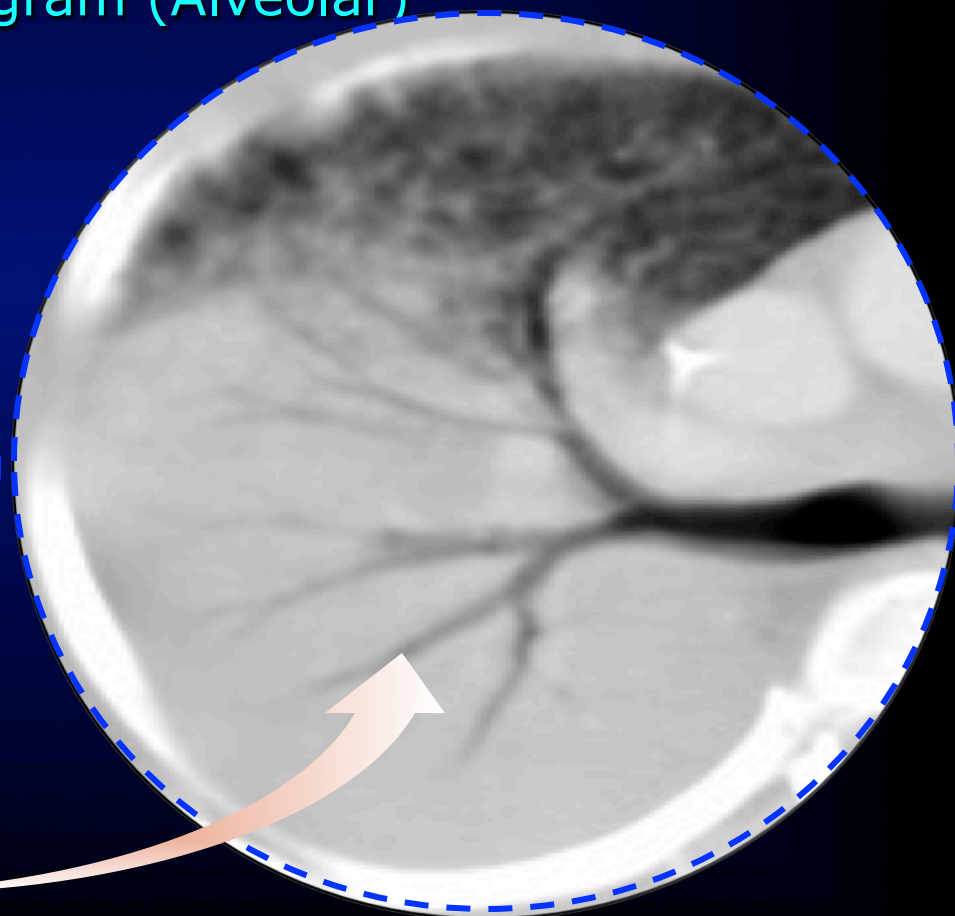
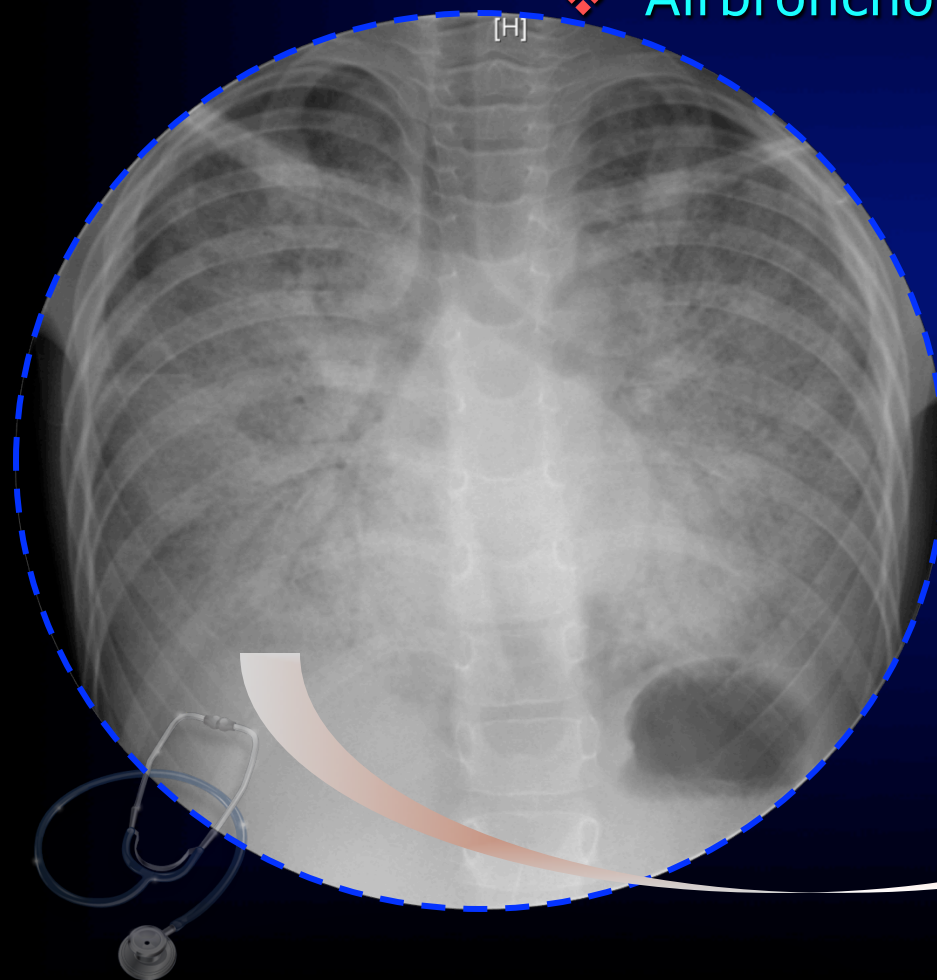
IMPORTANT TERMS

❖ Alveolar Vs Interstitial



IMPORTANT TERMS

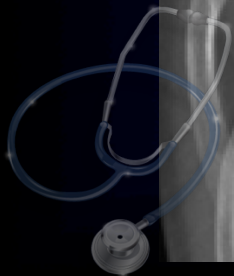❖ Airbronchogram (Alveolar)





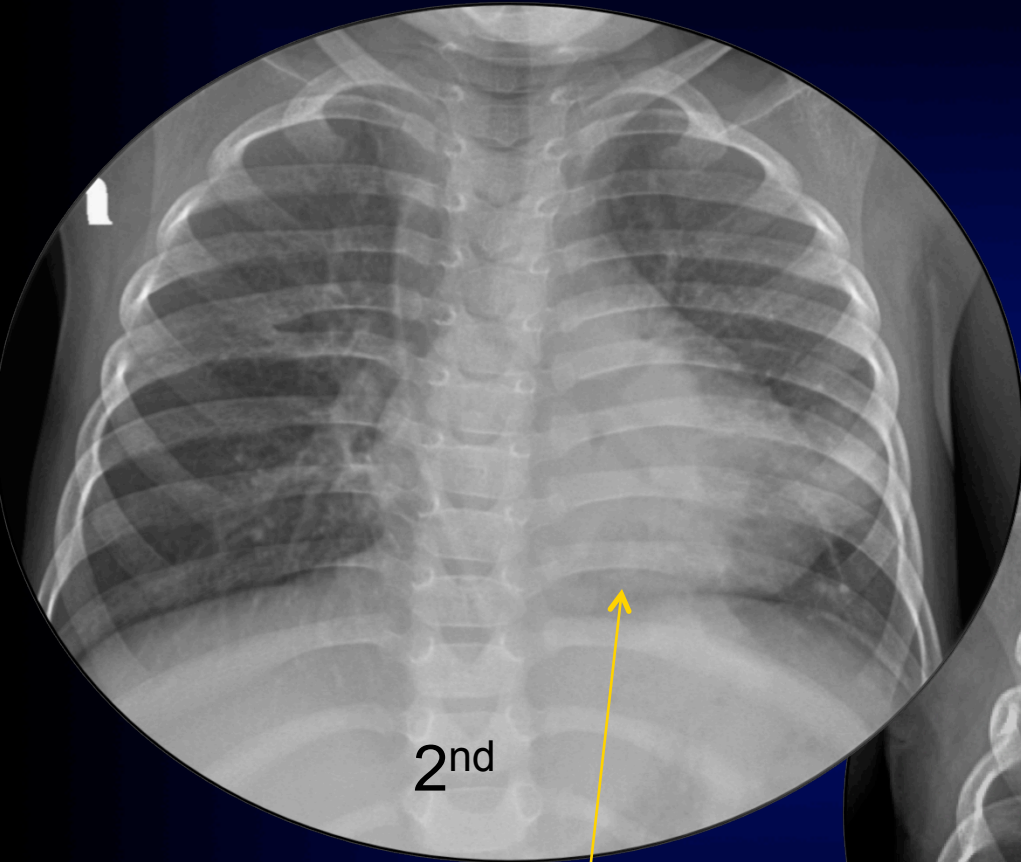
SUPINE

Child presenting
with cough and fever



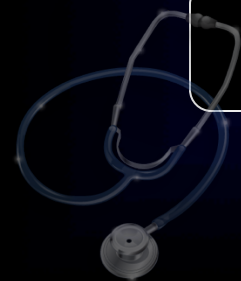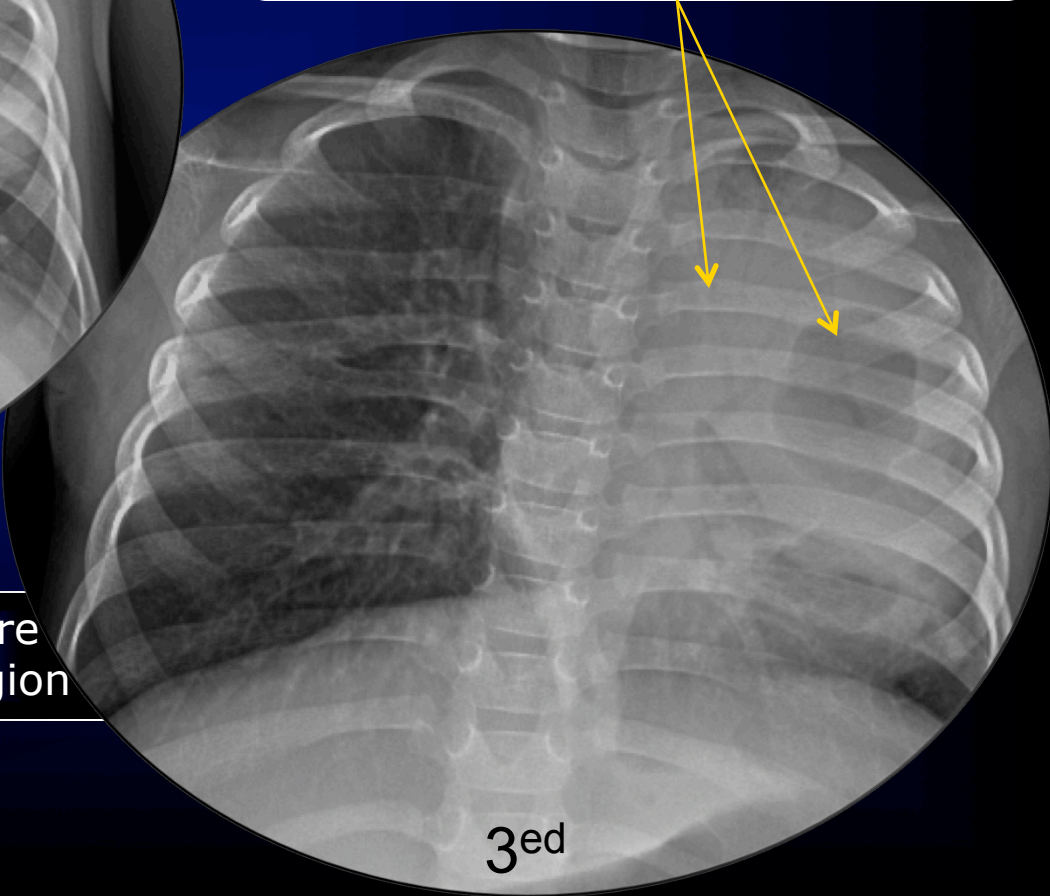


Child presenting with cough and fever



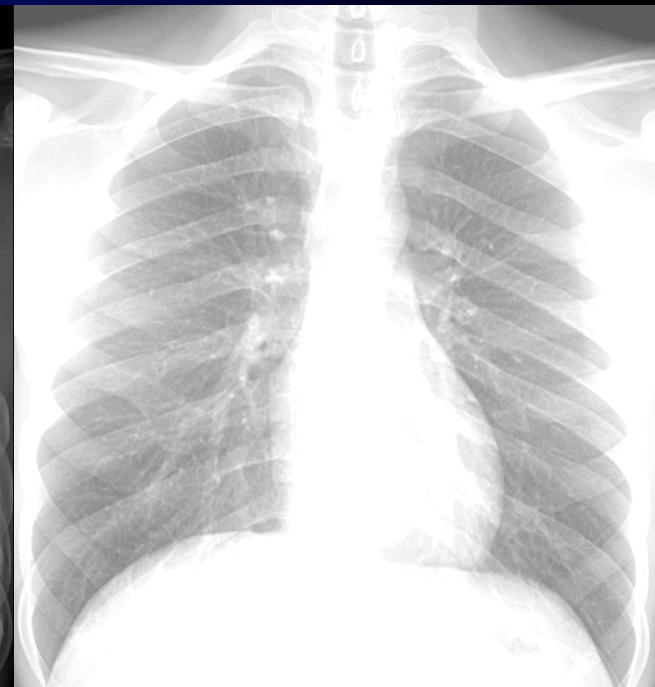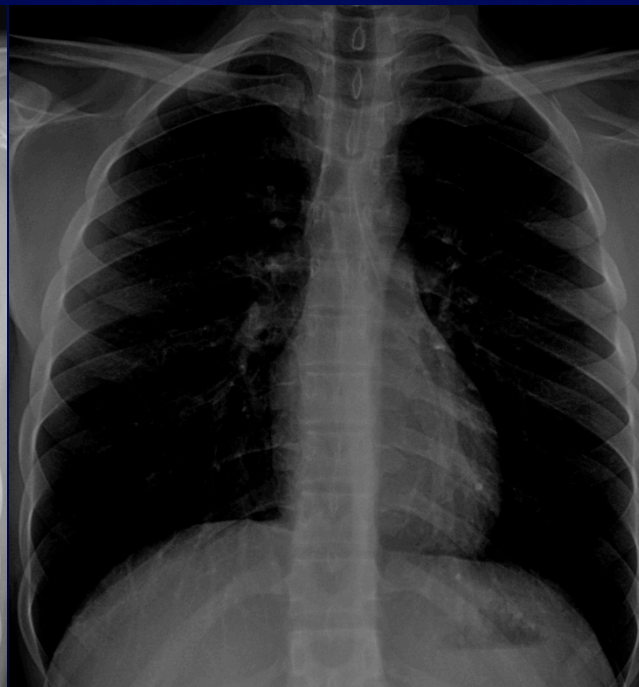
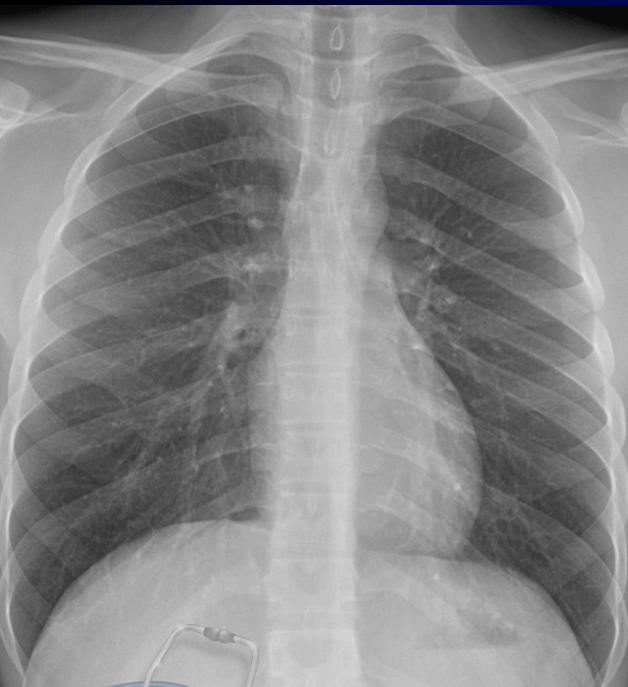Consolidation become more obvious in retro-cardiac region

Air-bronchogram is more clear here with development of cavitation



IMPORTANT TERMS

❖ Adequate Exposure



ADEQUATE

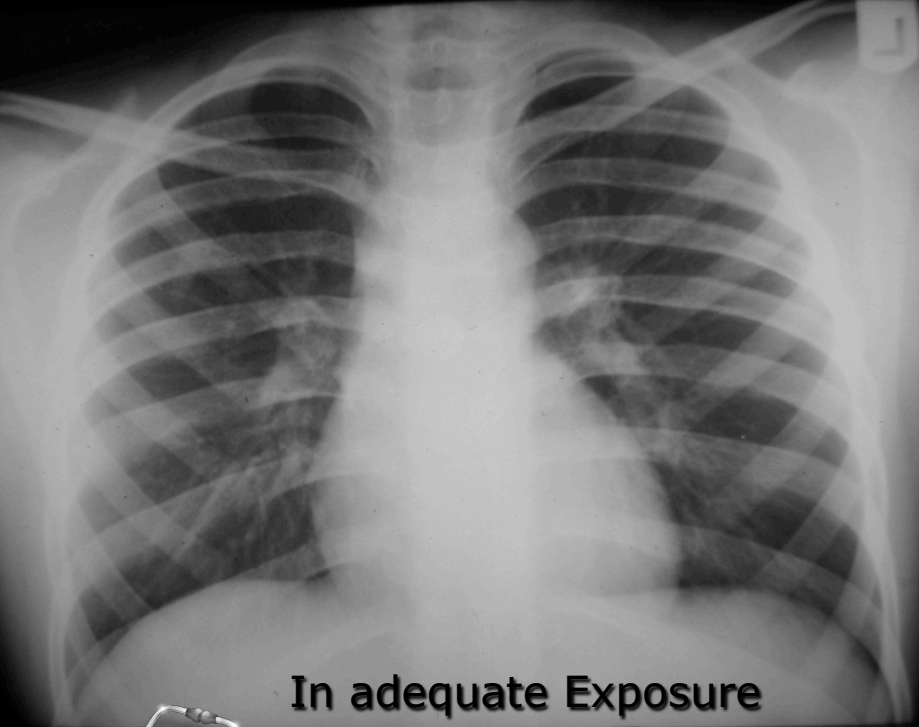
OVER

UNDER

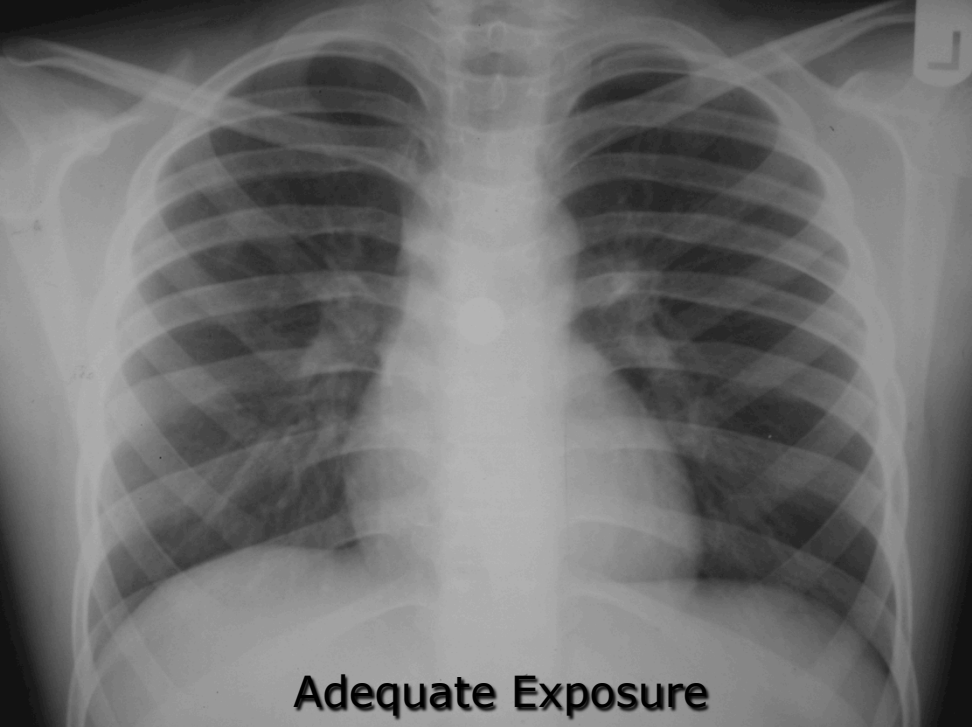
IMPORTANT TERMS



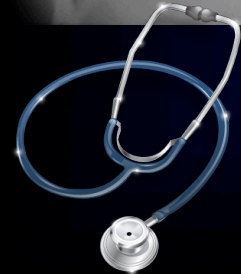❖ Adequate Exposure



In adequate Exposure



Adequate Exposure



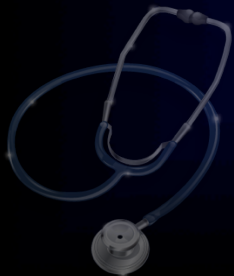

Interpretation

In radiology

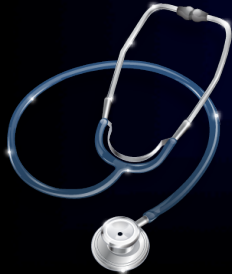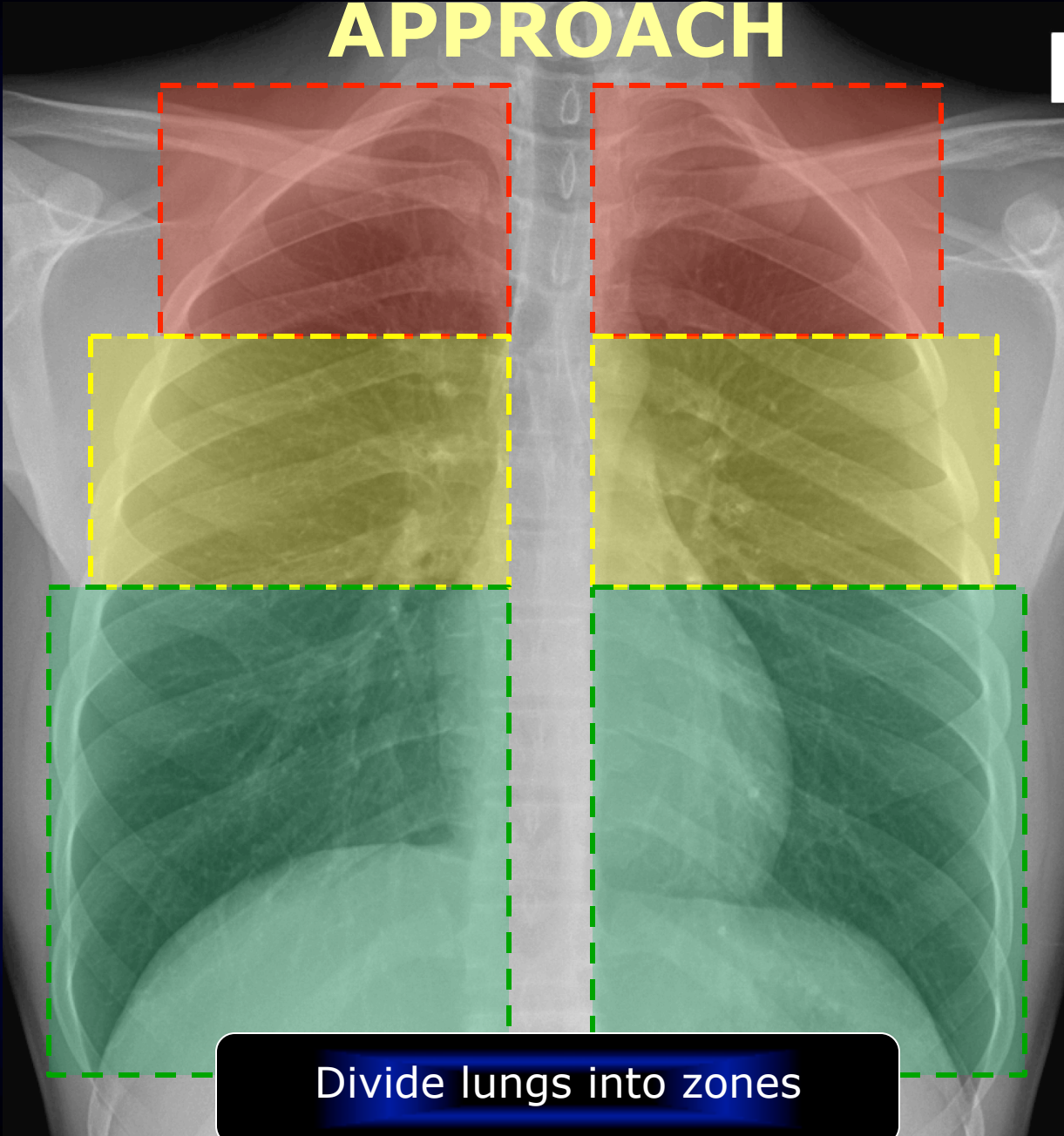
should develop systematic approach

Should memorize the normal image in his mental status



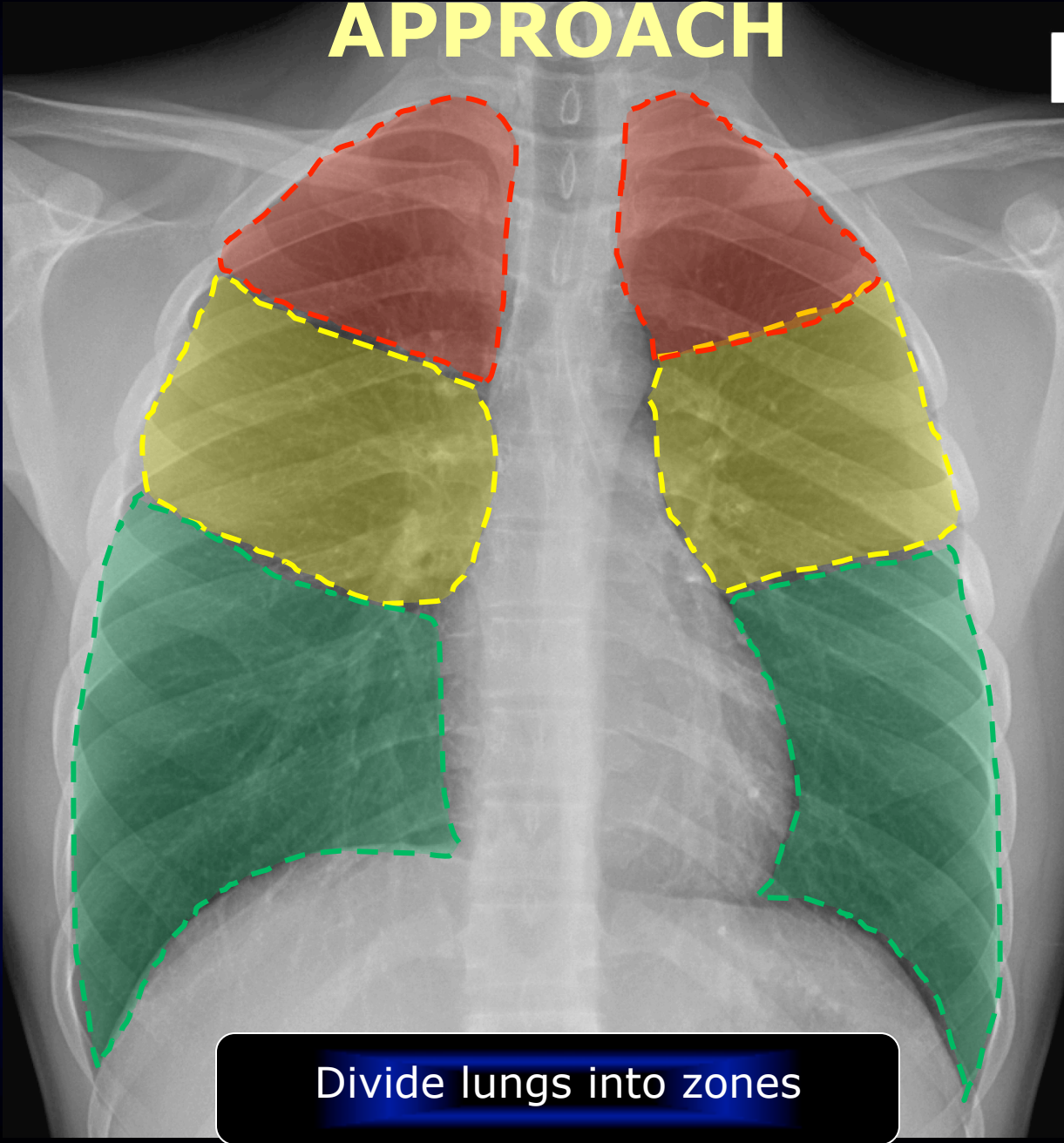


APPROACH





APPROACH

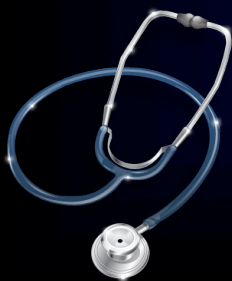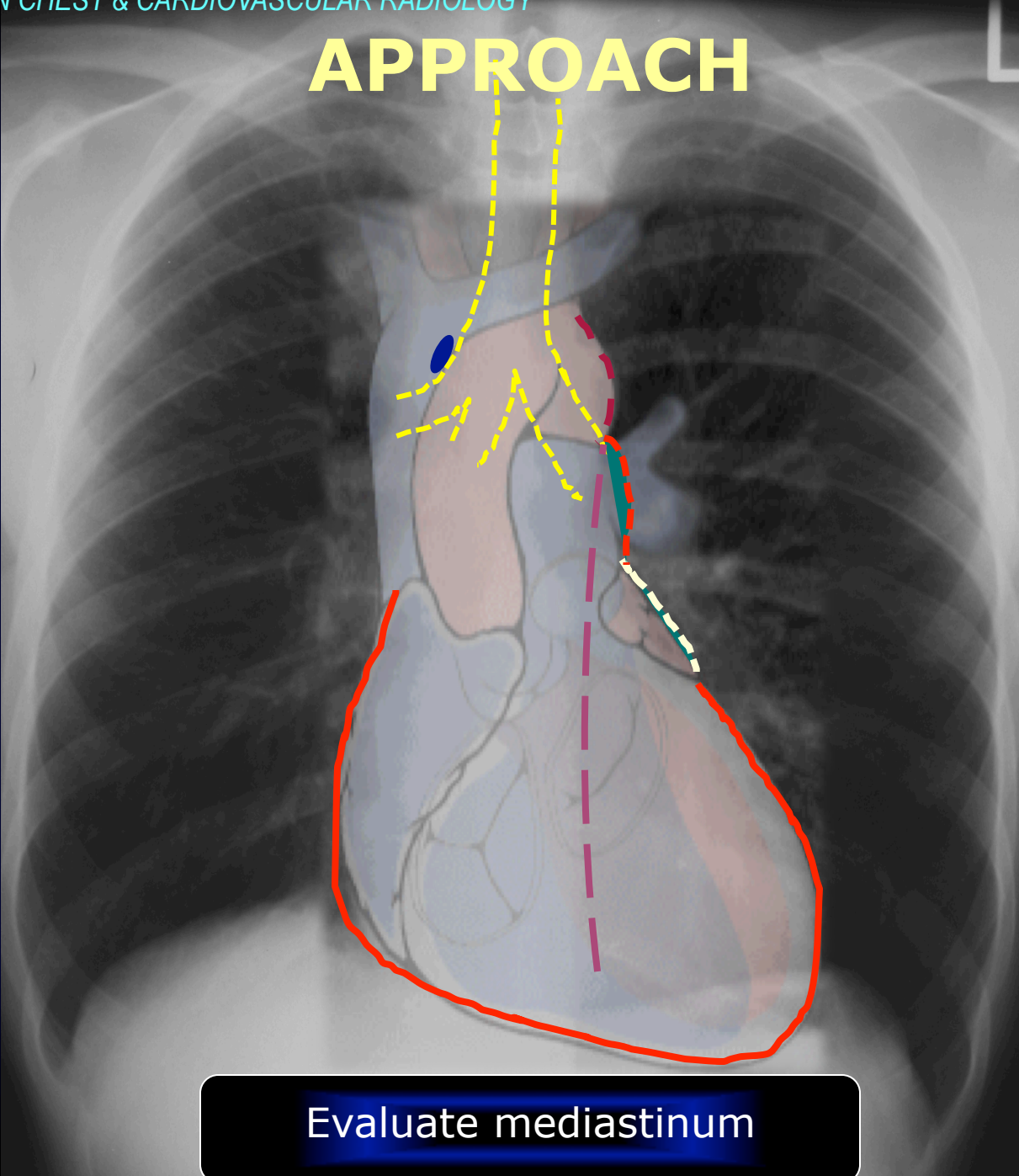


Divide lungs into zones





APPROACH



Evaluate mediastinum



CHEST PATTERNS

- Define the pattern of abnormality seen on the chest X-ray.
- Develop appropriate differential for such pattern recognized.
- Decrease your differential by
 - * Careful analysis of the findings
 - * Consider evaluation of previous exams
 - * Correlate with clinical and laboratory data
- Decide for the next step

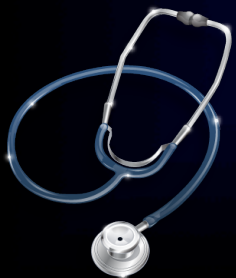



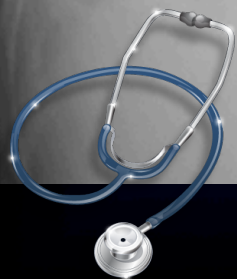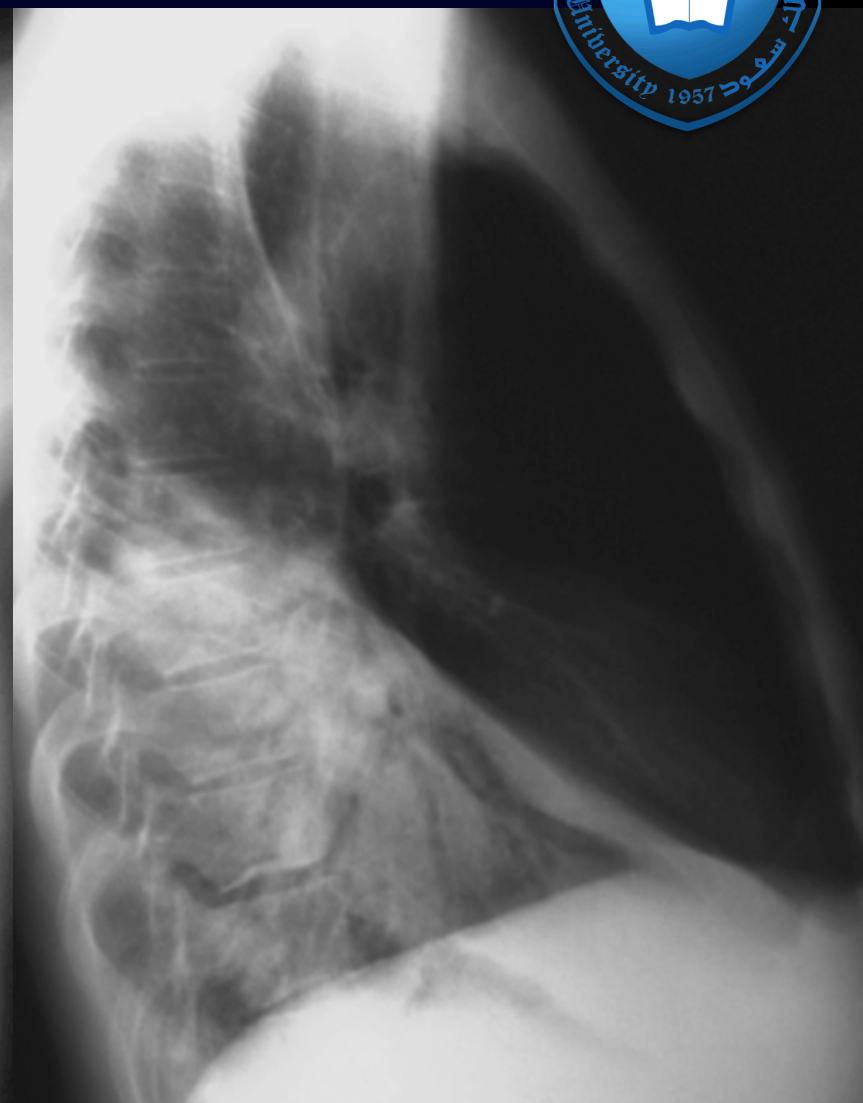
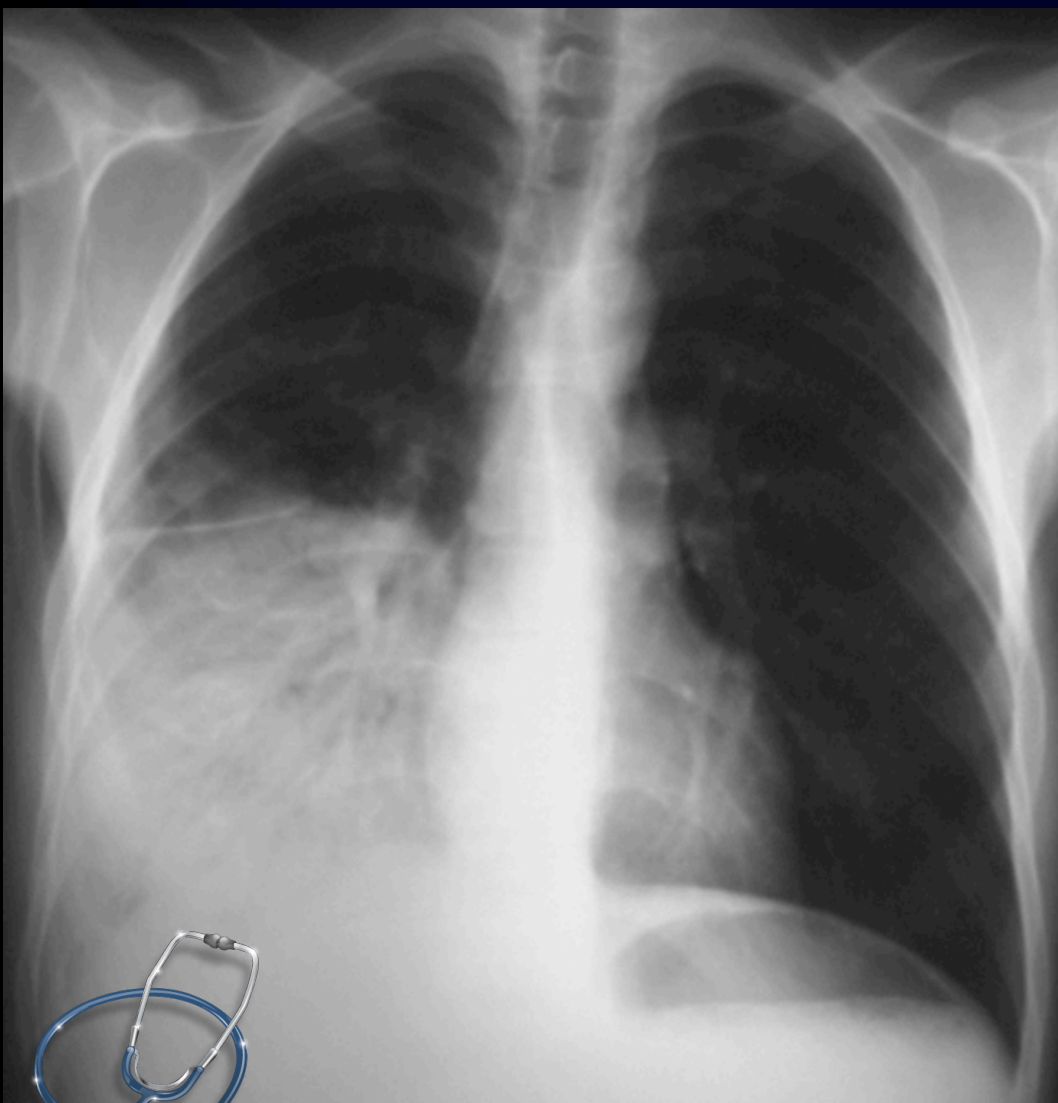
CHEST PATTERNS

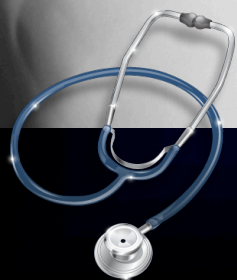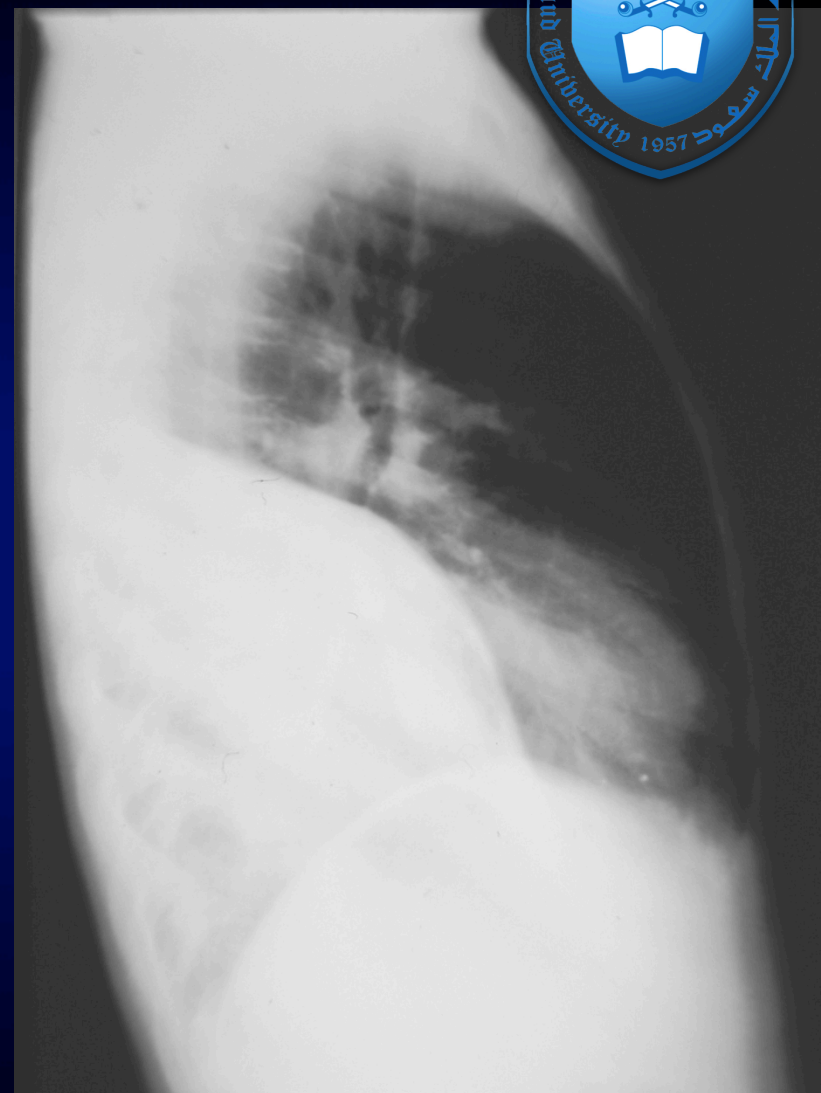
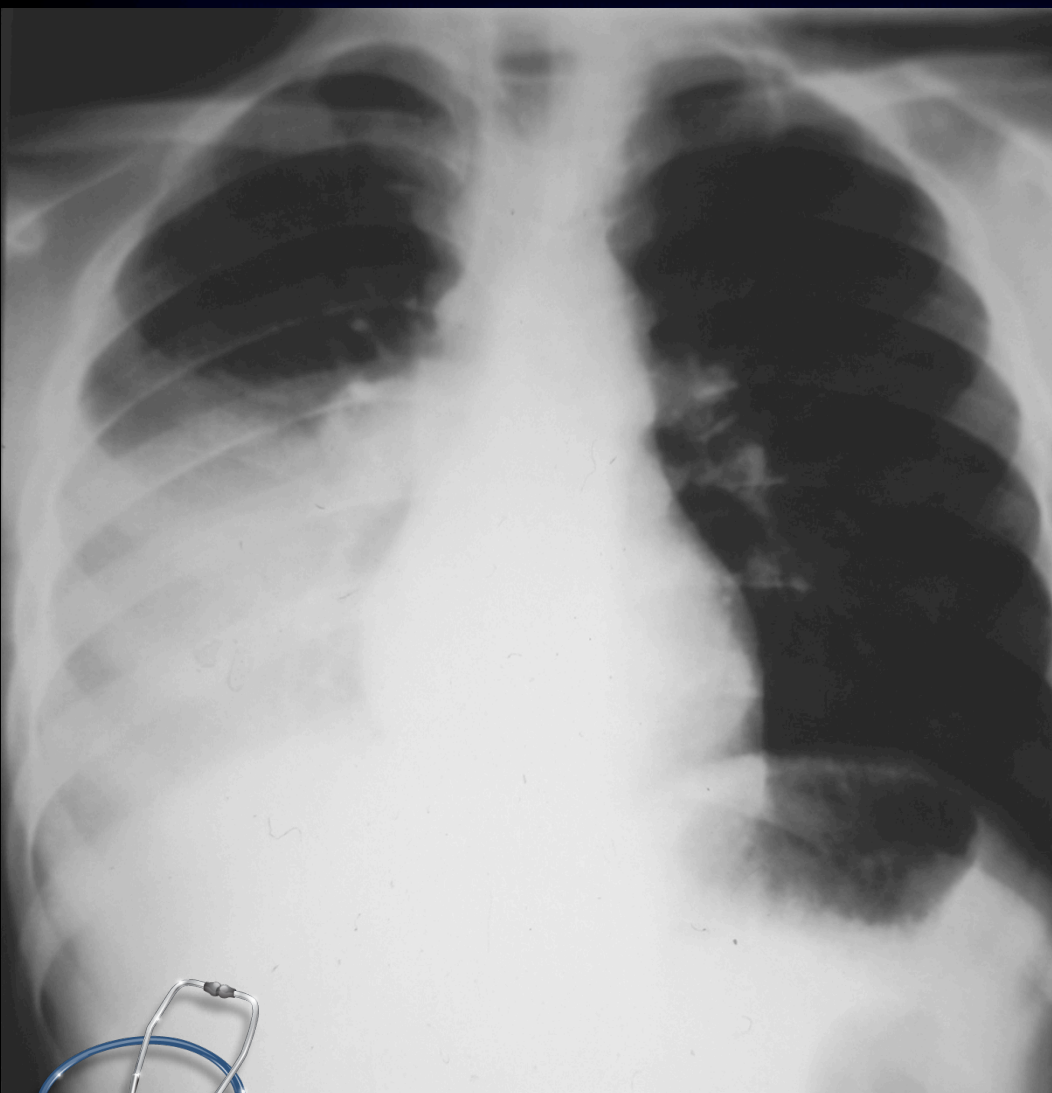Examples

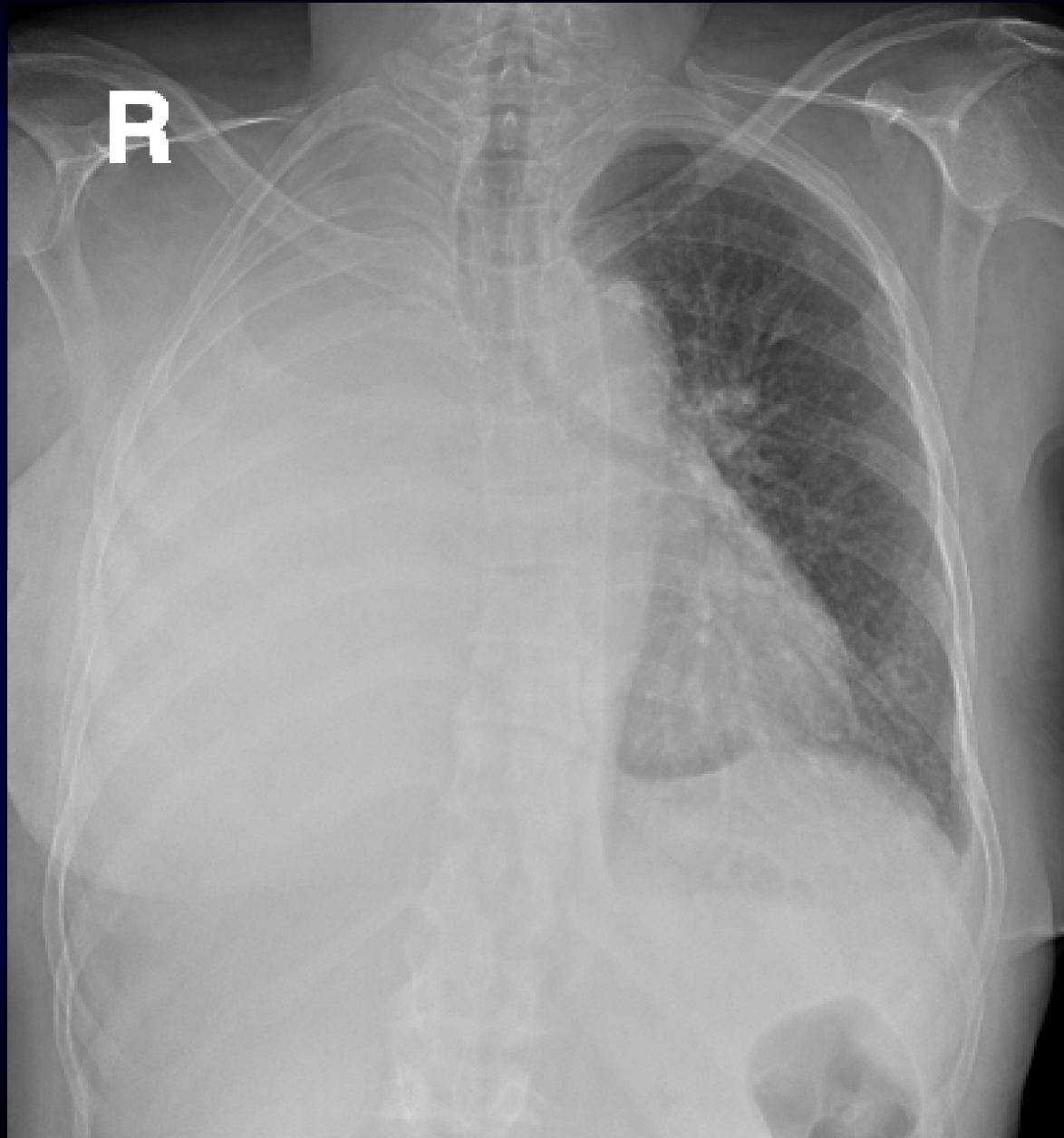
Increased Pulmonary Densities



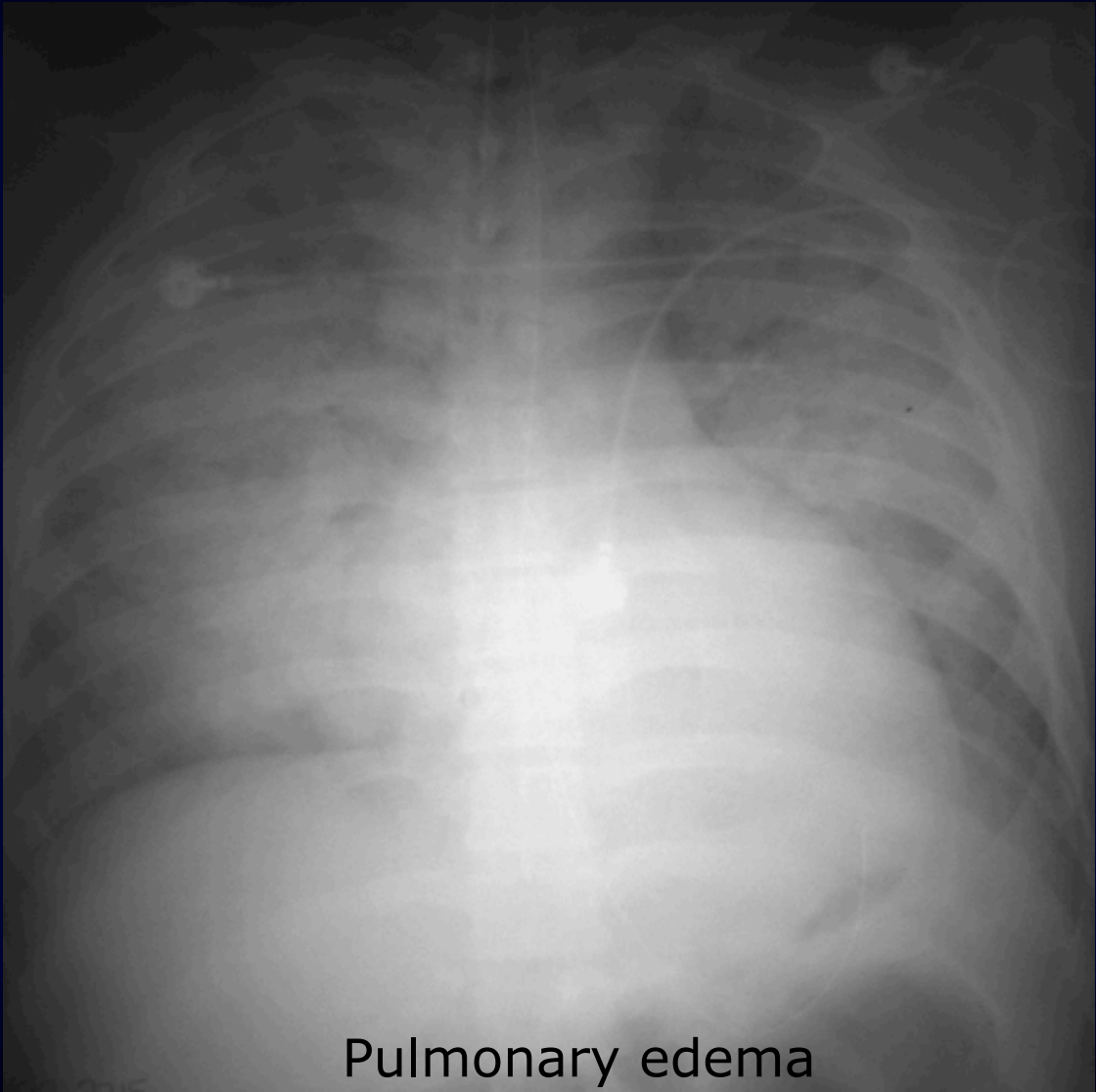
Adult patient presenting with cough and fever





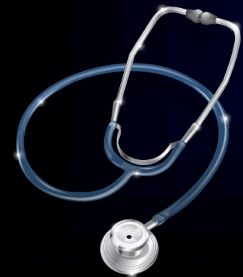

Elderly patient presenting with
dyspnea, cough and lower limbs edema. No fever



Pulmonary edema

Wide spared air space shadow in both lungs
Heart enlarged



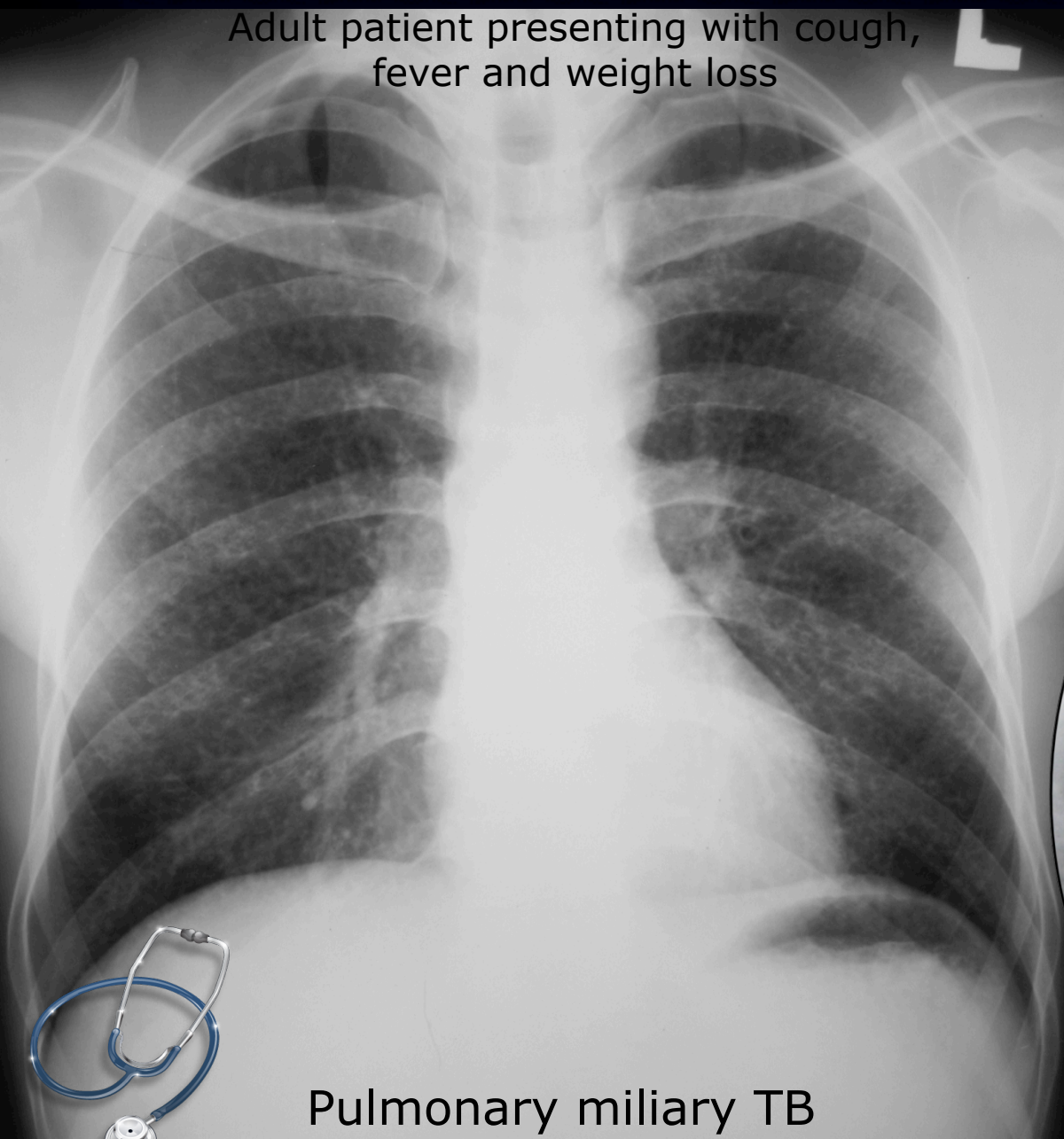

CHEST PATTERNS

Increased Nodular Pulmonary Densities

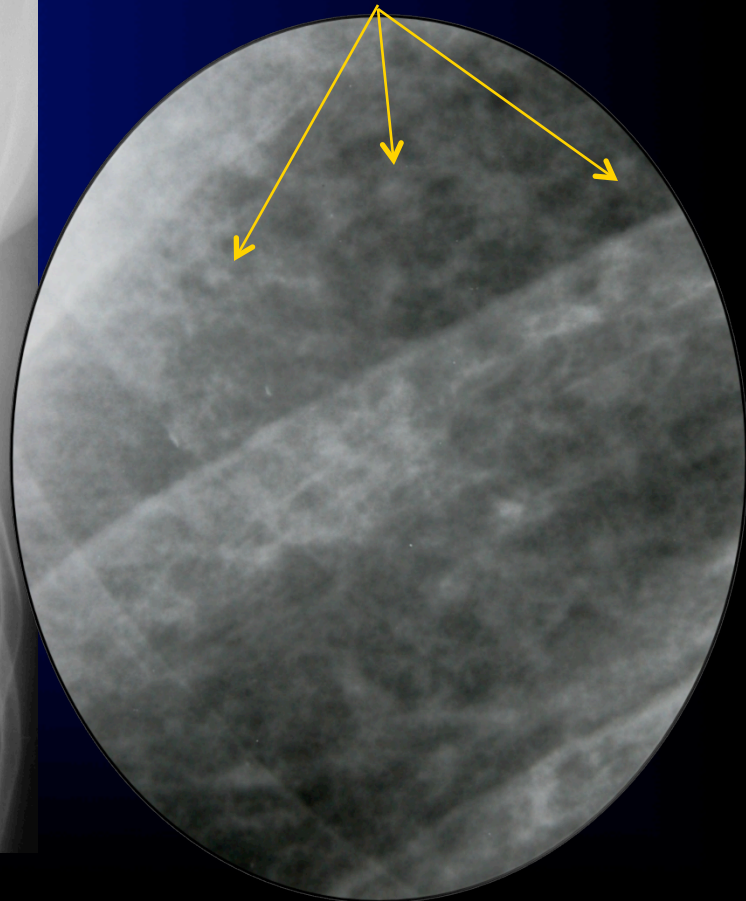


Adult patient presenting with cough,
fever and weight loss



Pulmonary miliary TB

Diffuse miliary nodules

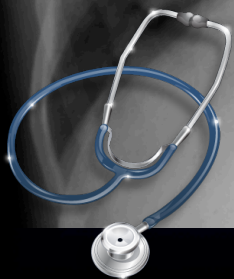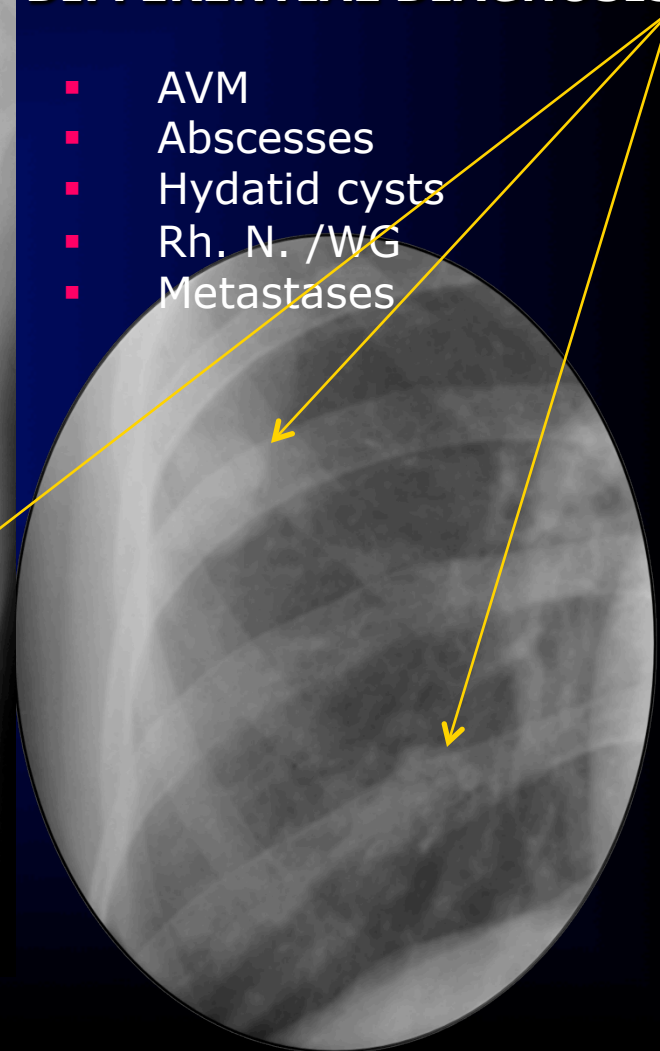


Adult female presenting with cough & weight loss



DIFFERENTIAL DIAGNOSIS

- AVM
- Abscesses
- Hydatid cysts
- Rh. N. /WG
- Metastases

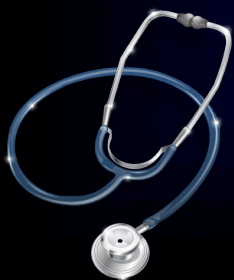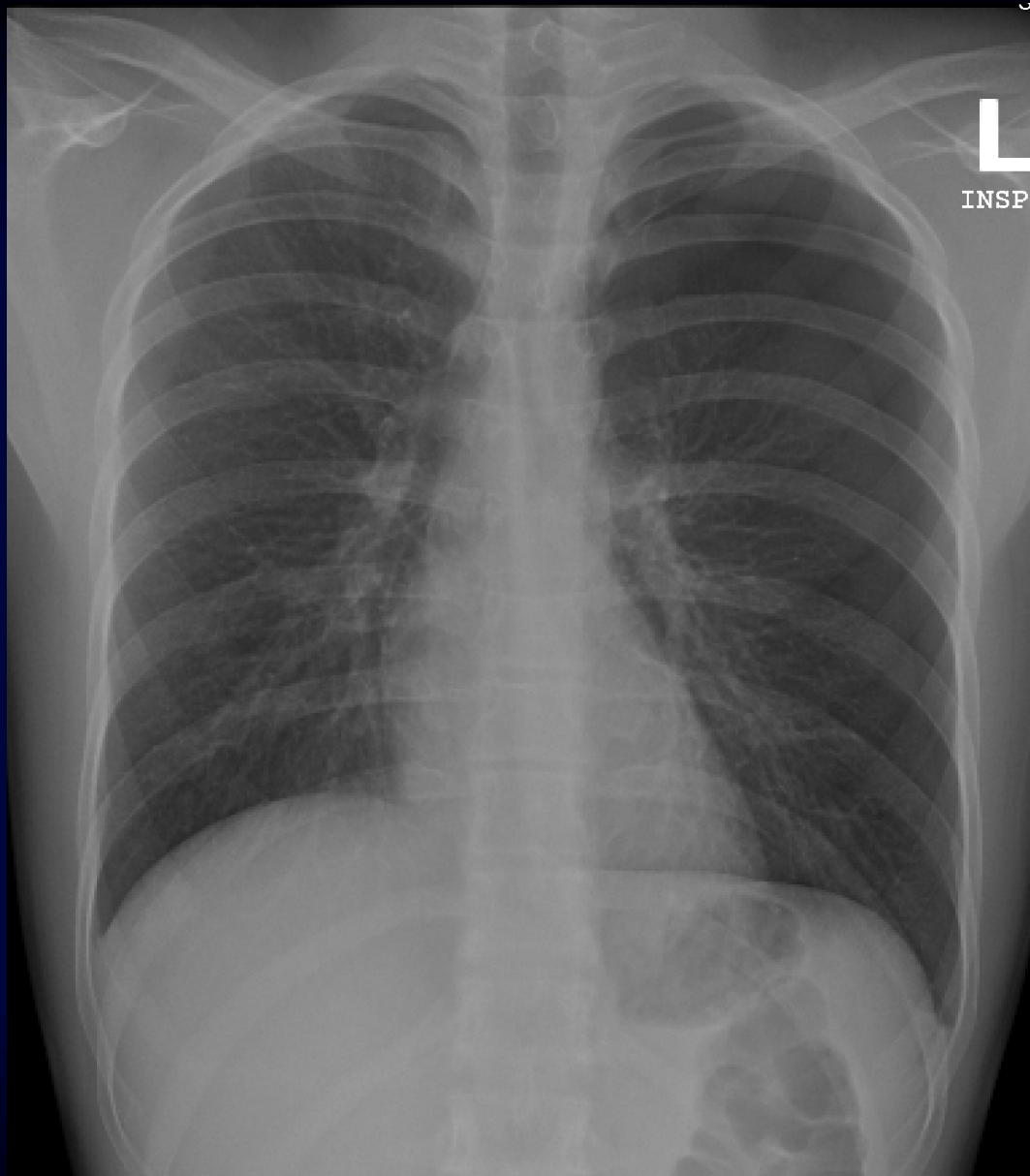




CHEST PATTERNS

Decreased Pulmonary Densities

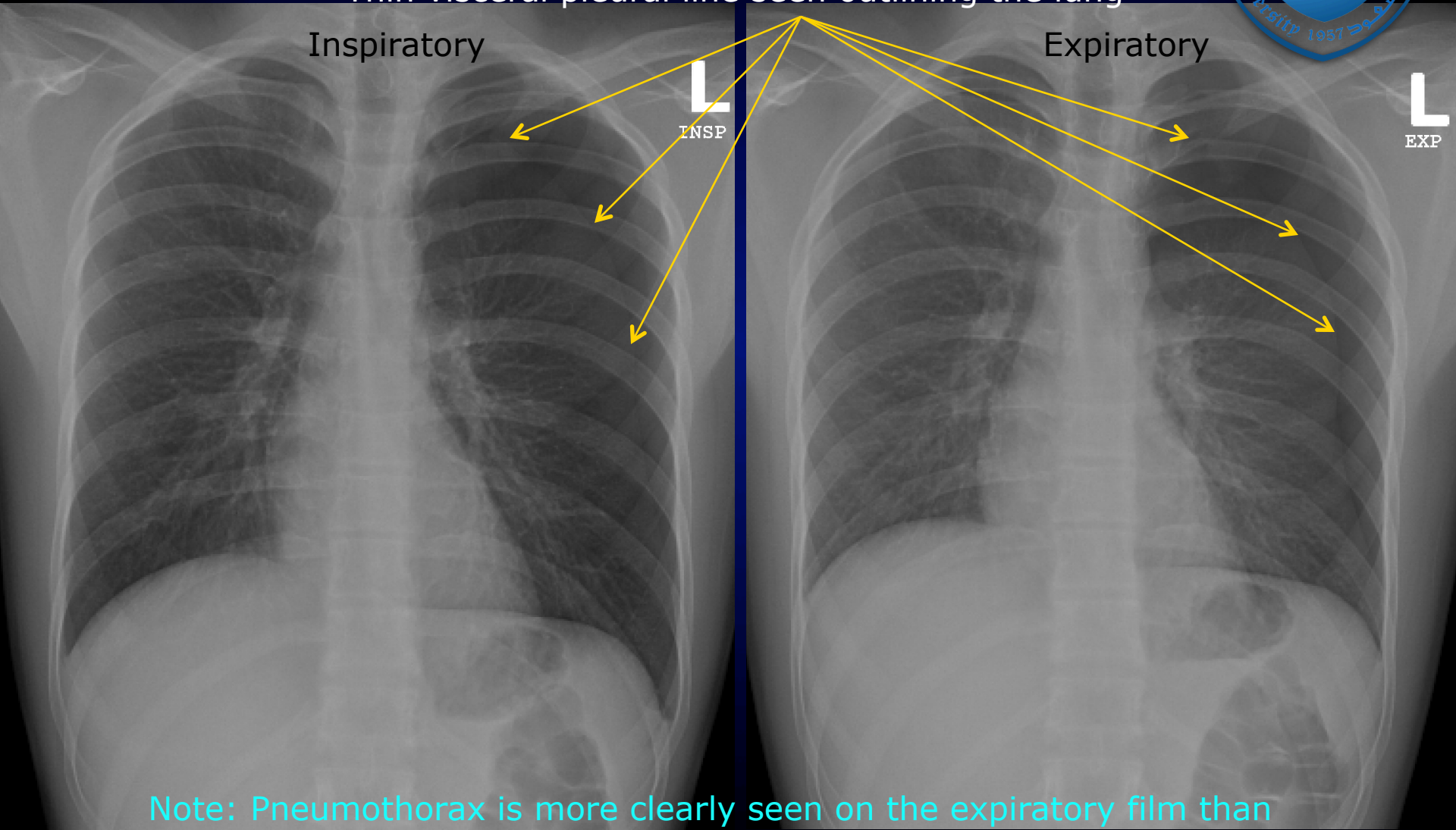




Young Adult presenting with acute chest pain
Known to have bronchial asthma



Pneumothorax on the left side
Evident by increased decreased density of the periphery of the lung
No vascular marking in that region
Thin visceral pleural line seen outlining the lung



Note: Pneumothorax is more clearly seen on the expiratory film than inspiratory one



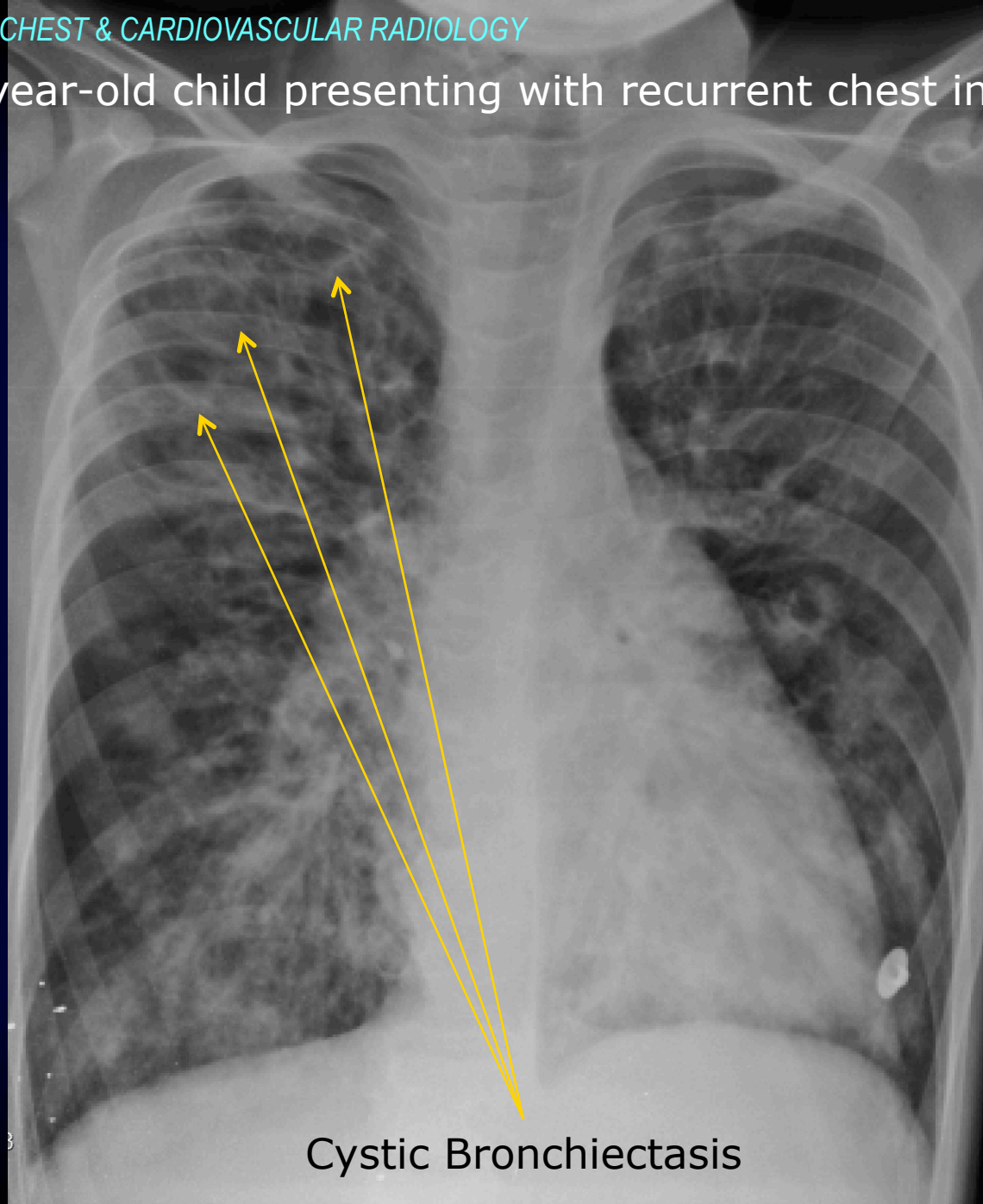


CHEST PATTERNS

Cavitary/Cystic pulmonic lesions

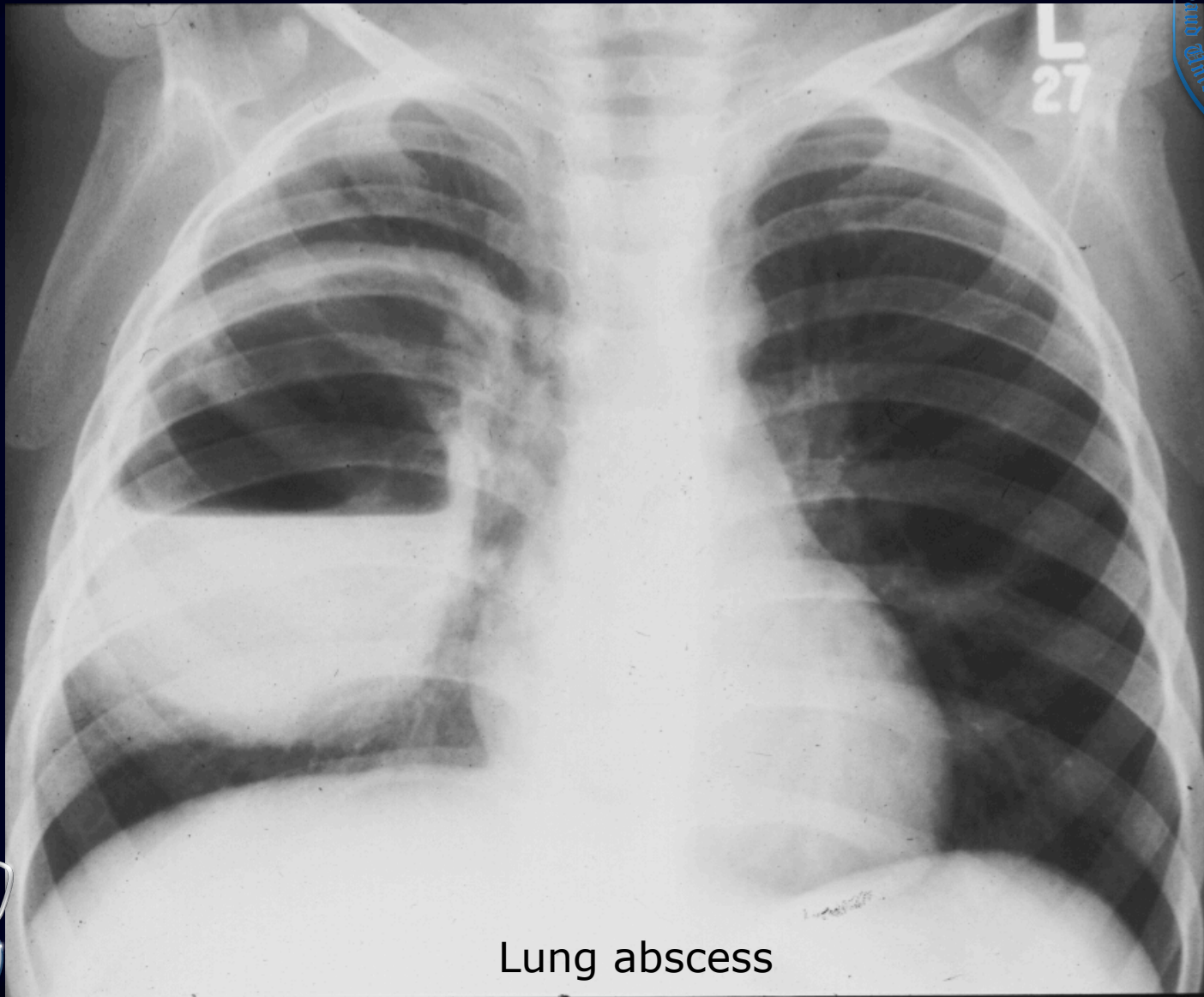


12 year-old child presenting with recurrent chest infection

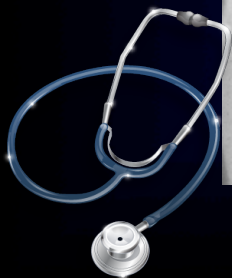

Cystic Bronchiectasis





Lung abscess





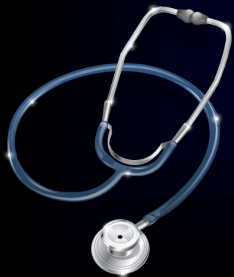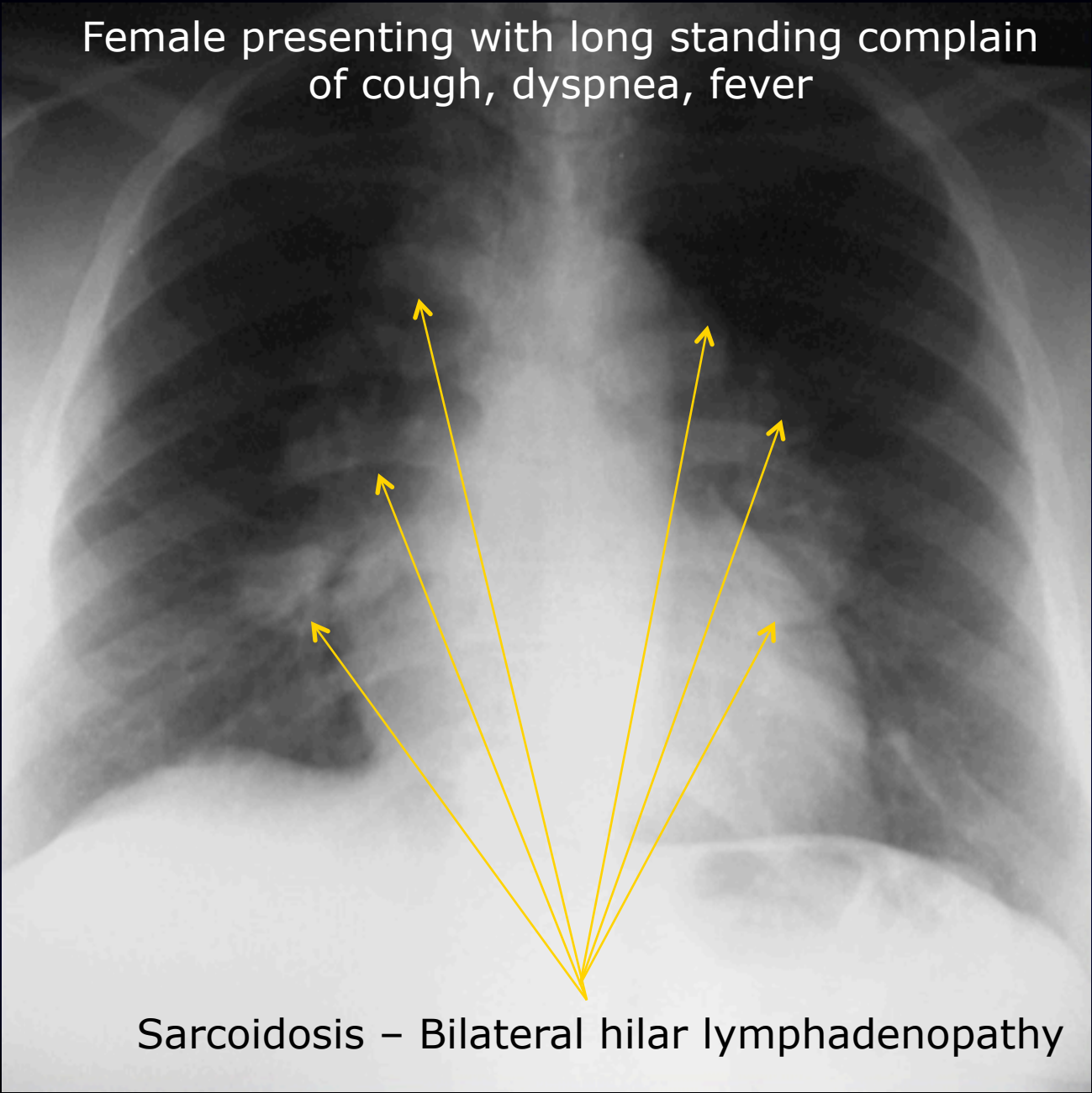
CHEST PATTERNS

Mediastinal Masses





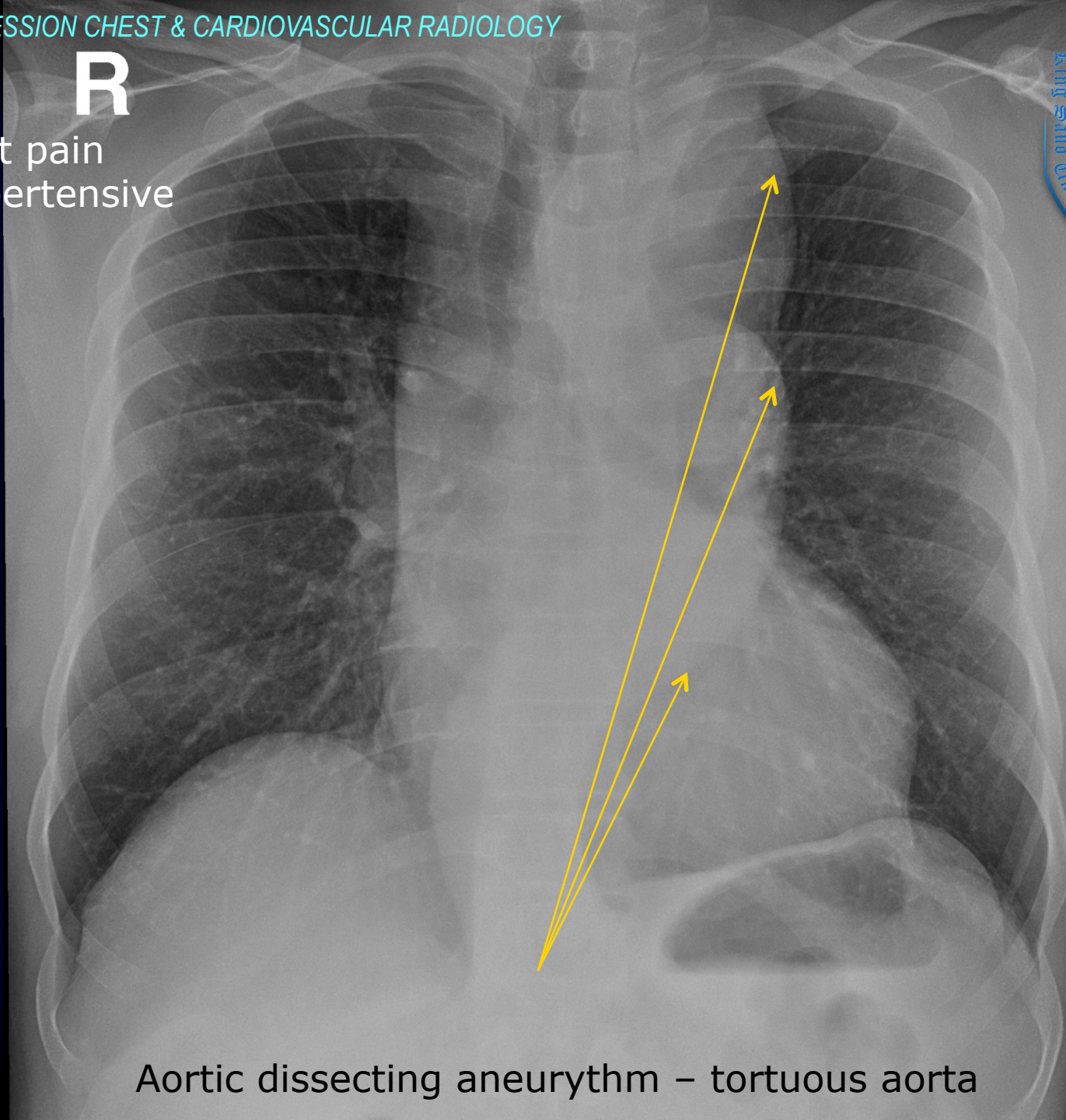
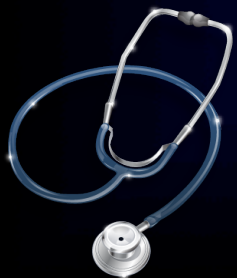Female presenting with long standing complain
of cough, dyspnea, fever



Sarcoidosis – Bilateral hilar lymphadenopathy

R

Acute chest pain
Known hypertensive



Aortic dissecting aneurysm – tortuous aorta



Reference Book and Other Resources

- ✓ [“Diagnostic Imaging” book by Peter Armstrong](#)
- ✓ <http://www.med-ed.virginia.edu/courses/rad/cxr/>
- ✓ <http://www.radiologyanatomy.com/index.php>
- ✓ <http://eradiology.bidmc.harvard.edu/LearningLab/>





AHMAD AMER AL-BOUKAI

THANK YOU

