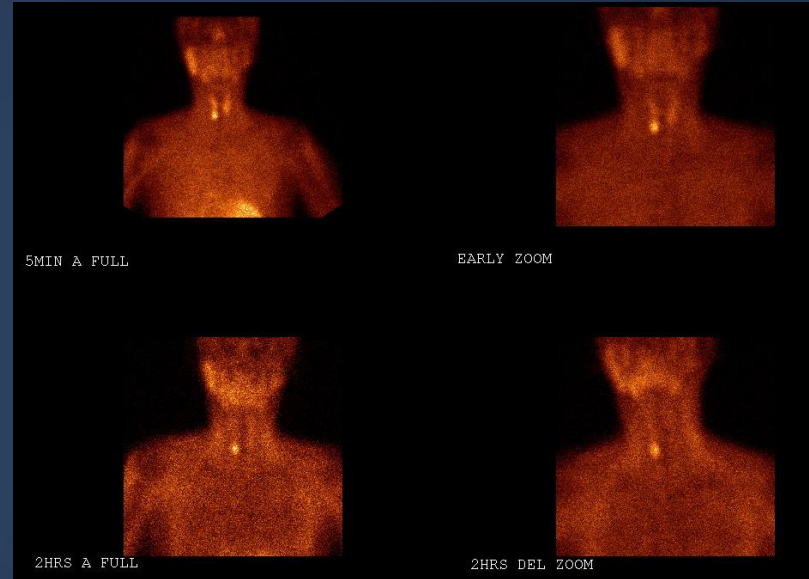
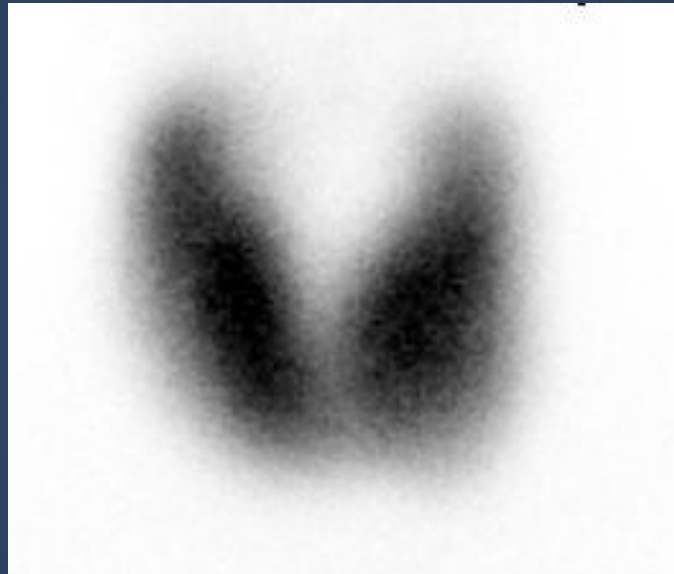

# Thyroid and Parathyroid Scans

## Basic Principles and Clinical Applications



**Saleh Othman , MD**

A. Prof.& Consultant Nuclear Medicine

King Khalid University Hospital & School Of Medicine

King Saud University

*Date: To be announced*

# Thyroid Scan

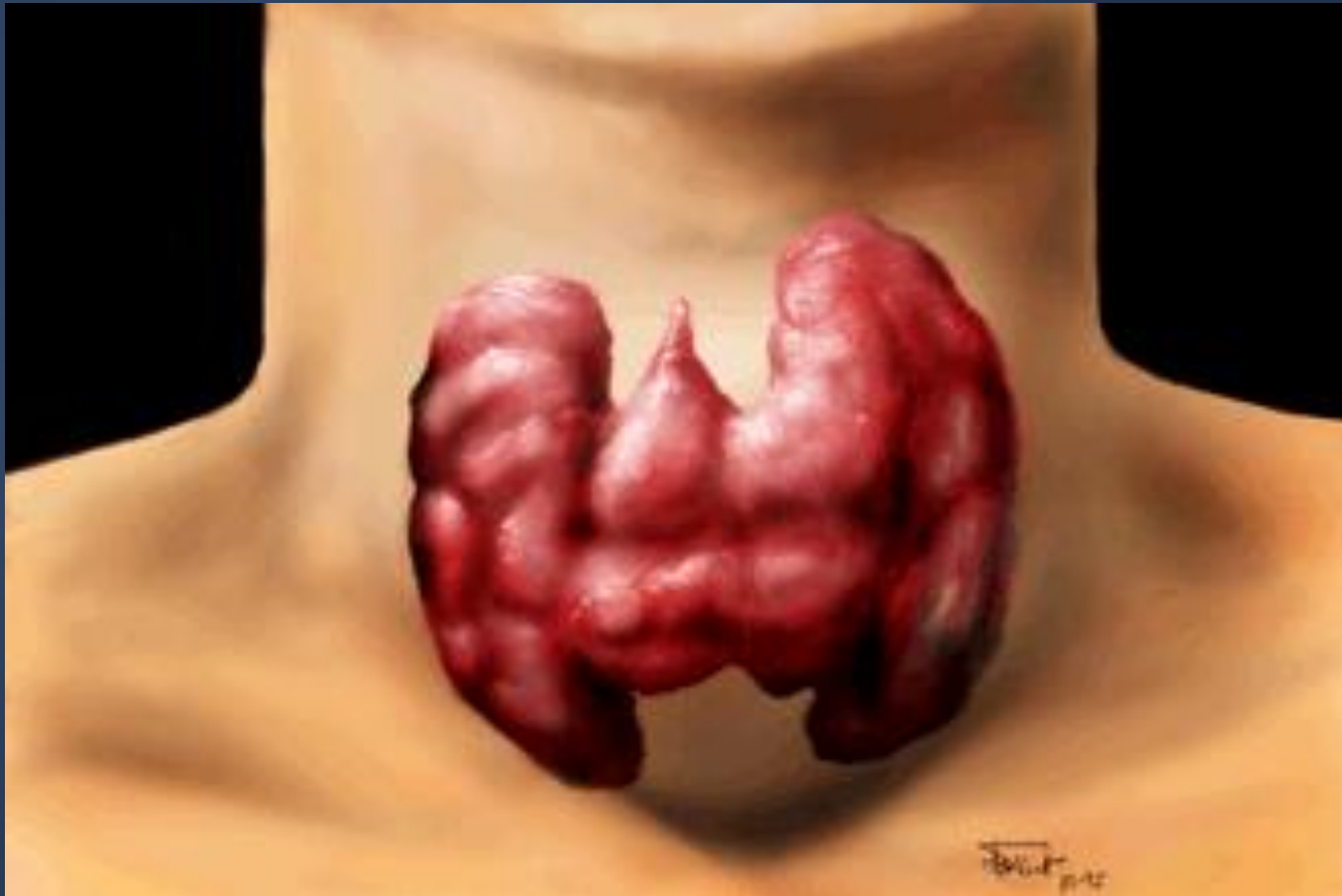## LEARNING OBJECTIVES...



At the end of the lecture you will be able to answer the following questions:

- How is the thyroid scan performed?
- When is thyroid scanning helpful?
- What is significant about whether a nodule is "hot" or "cold?"
- What is the role of nuclear medicine in the treatment of thyroid disorders?

# How is the thyroid scan performed?



# Thyroid Scan : Procedure

## Tc-99m Pertechnetate

## I-123

Dose

0.5-4.0 mCi given IV

0.5 mCi orally

Half Life

6 Hours

13 Hours

Cost

Not Expensive (Generator)

Expensive (Cyclotrone)

Time of imaging

20 min post injection

6 and 24 hours post ingestion

Remarks

Trapped not organified

Trapped and organified

# Thyroid Scan : Procedure

## Patient Preparation:

The patient must be off thyroid hormones :

1. Thyroxine (T-4) for at least 3-4 weeks.
2. Triiodothyronine (T-3) for at least 10 days.

The patient must not be taking antithyroid medications:

1. Propylthiouracil (PTU) and tapazole for at least 3-5 days.

The patient must not i.v iodinated contrast agents

(IVP, CT with contrast, myelogram, angiogram) for at least 3 weeks.

## Radiopharmaceutical and dose:

Tc-99m as sodium pertechnetate 0.5 -4.0 mCi given Intravenously. OR

I-123 Sodium Iodide 0.5 mCi orally

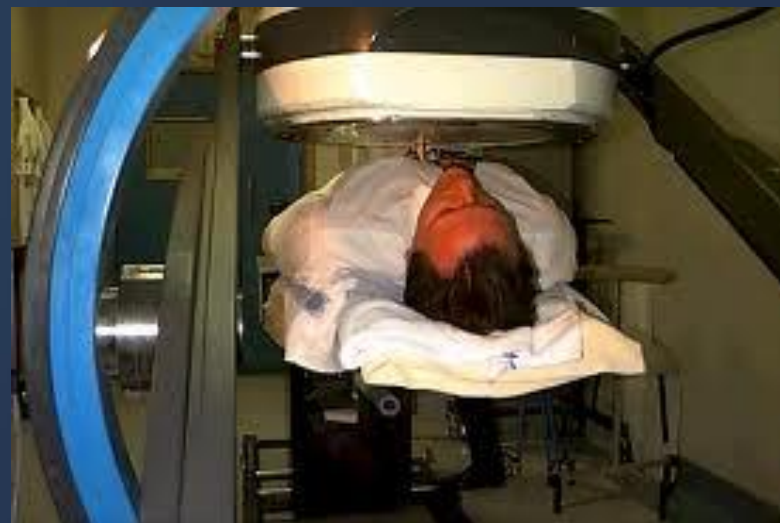Gamma camera: Small or large field of view.

Patient position: Supine with chin tilted up.

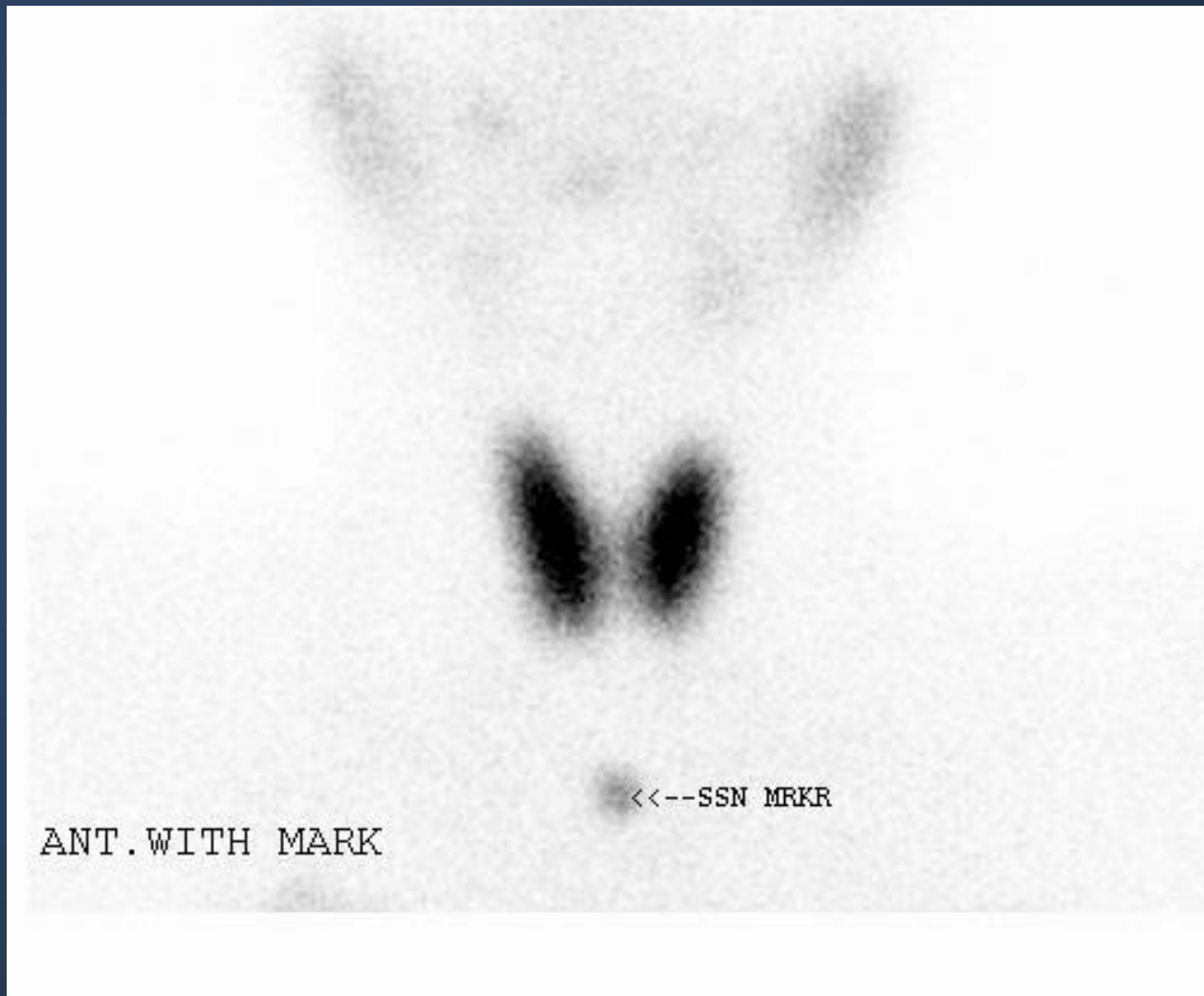## Imaging:

20 min. post injection of Tc99 m : ANT, LAO and RAO images obtained.

6 and 24 hours post oral dose for I123 : ANT, LAO and RAO images .



# Normal Thyroid Scan



# THYROID UPTAKE MEASUREMENT (I-123 Sodium Iodide)



- The Thyroid Uptake Measurement measures the metabolic activity of the thyroid gland as reflected by its extraction of iodine from the blood.

## Indications

- Diagnosis of Grave's disease .
- Evaluation of subacute and chronic thyroiditis .
- Thyroid Cancer

## Patient Preparation :

- **Must be off thyroid hormones :**

1. Thyroxine (T-4) for at least 3-4 weeks.
2. Triiodothyronine (T-3) for at least 10 days.

- **Must not be taking antithyroid medications :**

1. Propylthiouracil (PTU) and tapazole for at least 3-5 days.

- **Must not have had intravenous or intrathecal iodinated contrast material (IVP, CT with contrast, myelogram, angiogram) for at least 3 weeks .**

- **Other agents may interfere, but usually only to a small extent .**

- **NPO 2-4 hours before and for at least 1 hour after ingesting the radiopharmaceutical**



# THYROID UPTAKE MEASUREMENT WITH /WITHOUT IMAGING (I-123 Sodium Iodide)



## Equipment :

**Uptake only :** Uptake probe (single crystal probe with flat field collimator).

**Imaging plus uptake studies:** Gamma camera

## Radiopharmaceutical : dose given orally

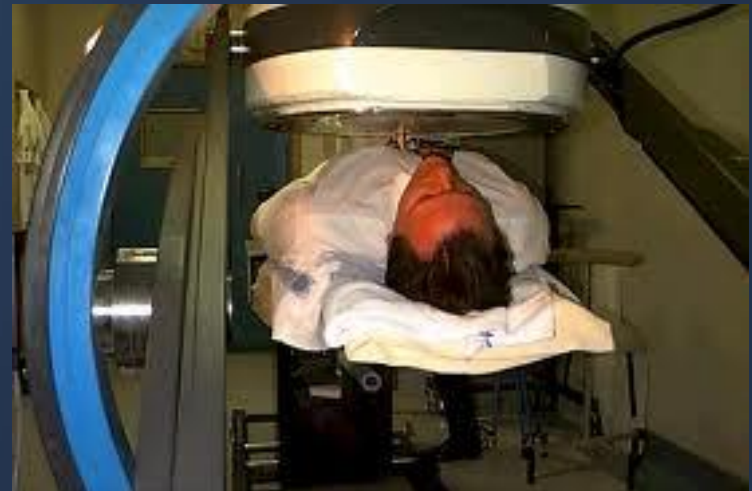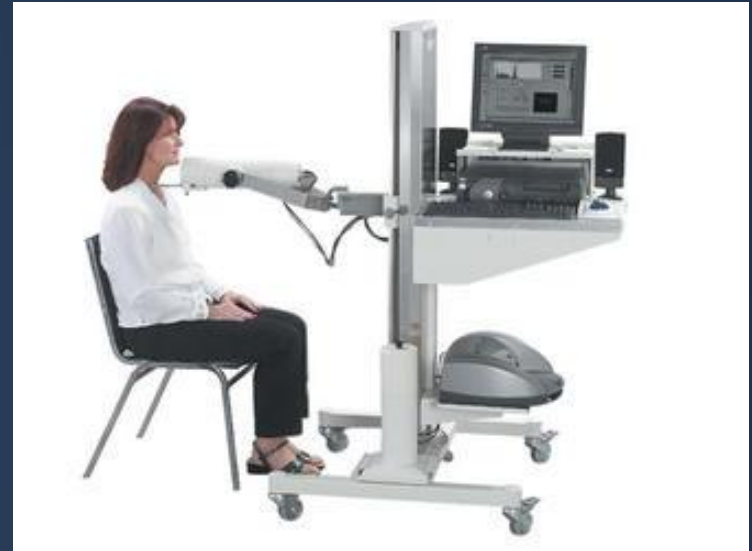**Imaging plus uptake studies:** I-123: 500  $\mu\text{Ci}$  .

**Uptake study only:**  
I-123: 100  $\mu\text{Ci}$

*Thyroid uptake measurements may be determined using Tc-99m-pertechnetate.*

**Patient position:** Sitting.

**Detector field of view:** Neck.





# THYROID UPTAKE MEASUREMENT WITHOUT IMAGING (I-123 Sodium Iodide)



## Acquisition Protocol:

- Place I123 capsule(s) in neck phantom.
- Acquire counts for 1 minute , record the counts, time of acquisition, and time of day on the thyroid Uptake Worksheet.
- Immediately administer the capsule(s) to the patient.
- At 6 hours position the probe in front of the patient's neck .
- Acquire counts for 1 minute for I-123 and record the counts, time of acquisition, and time of day on the Worksheet.
- Position the probe over the thigh for 6 hour “background” measurement.
- Acquire counts for 1 minute for I-123 and for 2 minutes for I-131; record the counts, time of acquisition, and time of day on the Worksheet.
- Using the Thyroid Uptake Worksheet, calculate the 6 hour thyroid uptakes. Remember to correct the standard counts for decay.

***Twenty four hour uptake measurement in the same way as the 6 hours.***

# Normal Values Of Thyroid Uptake



- I131 OR I-123 RAIU (4 & 24 hours) :

Normal 4 hour RAIU : 5 - 15%

Normal 24 hour RAIU : 8 - 35%

- Tc- 99m Uptake (20 min Uptake) : N (0.5 -4 .0%)

# Causes of High Thyroid Uptake



- **Hyperthyroidism : Grave's Disease or TSH-secreting pituitary adenoma**
- **Autonomous toxic nodule**
- **Multinodular toxic goiter (Plumer's Disease)**
- **Enzyme defects : Dyshormonogenesis.**
- **Iodine starvation (Iodine deficiency)**
- **Lithium Therapy**
- **Recovery phase of thyroiditis.**
- **Rebound following abrupt withdrawal of antithyroid meds**

# Causes of Low Thyroid Uptake

- **Parenchymal Destruction:**
  - Acute, Subacute and Chronic Lymphocytic Thyroiditis
- **Hypothyroidism:**
  - Primary or Secondary (insufficient pituitary TSH secretion)
  - Surgical/Radioiodine Ablation of Thyroid
- **Blocked Trapping:**
  - Iodine load (most common): Iodinated contrast material, Food rich in iodide: fish , cabbage ,...etc
  - Exogenous thyroid hormone replacement depressing TSH levels (thyrotoxicosis factitia)
  - Ectopic thyroid: Struma Ovarii
- **Blocked Organification:**
  - Antithyroid medication (PTU): Note- Tc-99m uptake should not be affected

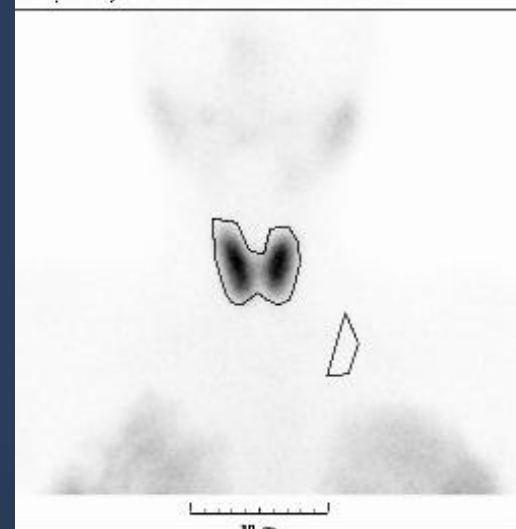
# Tc-99m Thyroid scan and uptake

## Imaging plus uptake studies

ALYAMI EBTISAM HUSS

843223

Study Date  
Study Time



THYROID UPTAKE : 2.96 %

Area	29.8	(sqcm)
Mass	53.0	g

Patient Name : ALYAMI EBTISAM HUSS

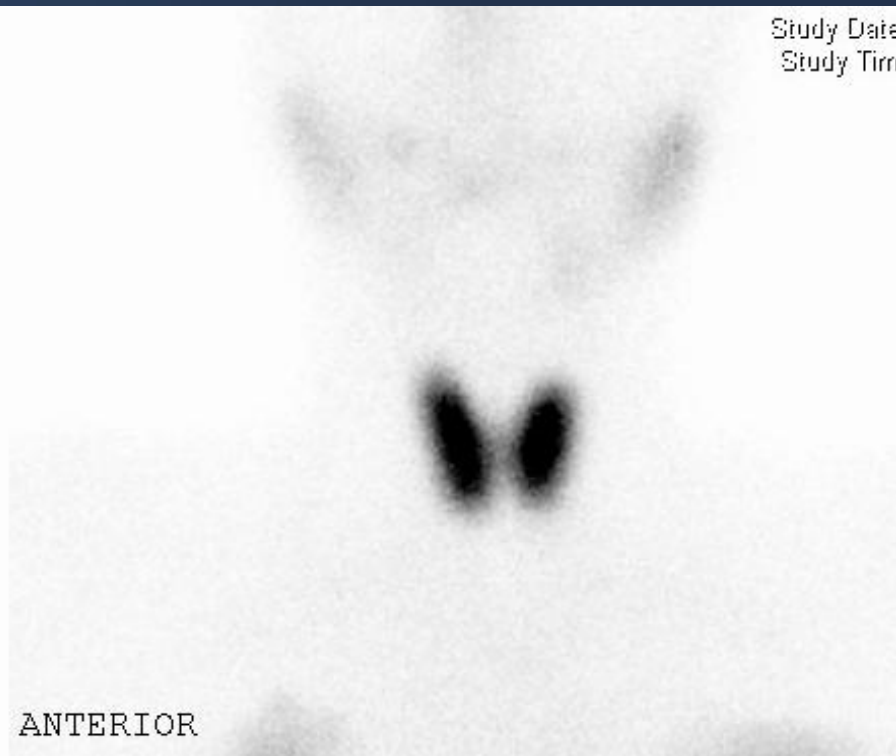Patient ID : 843223

Exam Date : 03Jun2007

THYROID UPTAKE

Adac Laboratories BV  
Maarsse  
The Netherlands

ANTERIOR



# THYROID METASTASES STUDY (I-123 or I-131 as Sodium Iodide)



## Indications

- Detection and localization of persistent or recurrent functioning thyroid cancer

## Patient Preparation

- Stimulation of potentially functioning thyroid tissue:

**A. Inject recombinant human thyrotropin on 2 consecutive days** and administer the radiopharmaceutical on the third day .

**B. Withdraw thyroid replacement hormones :**

1. Thyroxine (T-4) for at least 4 weeks.
2. Triiodothyronine (T-3) for at least 10 days.

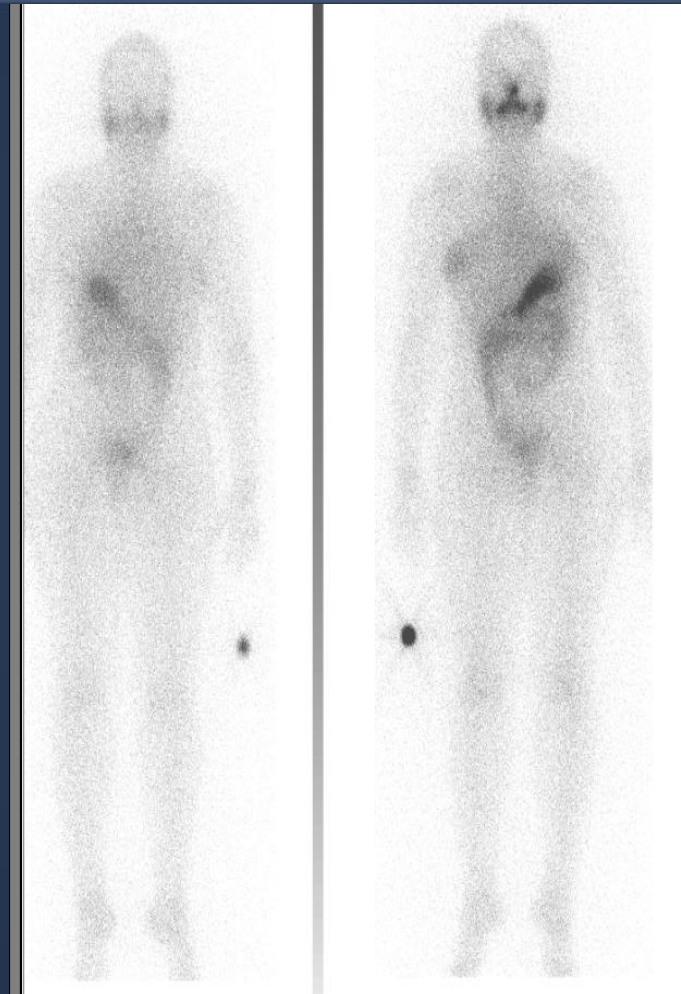
- The patient must not have had i.v iodinated contrast material (IVP, CT with contrast, myelogram, angiogram) for at least 3 weeks .

- The patient should be NPO for at least 4 hours prior to radiopharmaceutical administration and for at least 1 hour afterwards .

## Radiopharmaceutical, Dose, & Technique of Administration

- Radiopharmaceutical: Oral administration
  - a. I-123 as sodium iodide : 2 mCi
  - b. I-131 as sodium iodide : 2-10 mCi

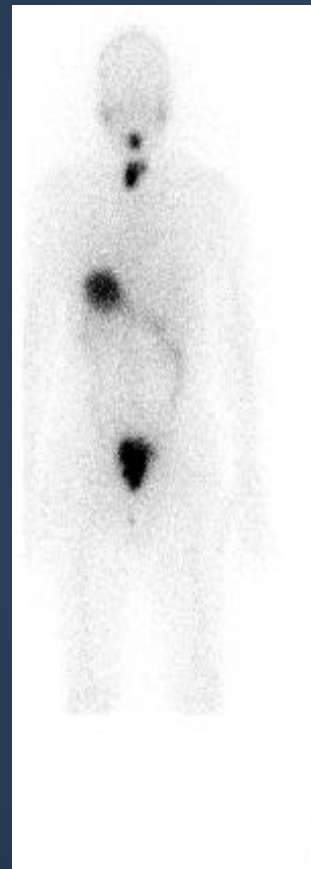Imaging using Gamma camera : Whole body scan



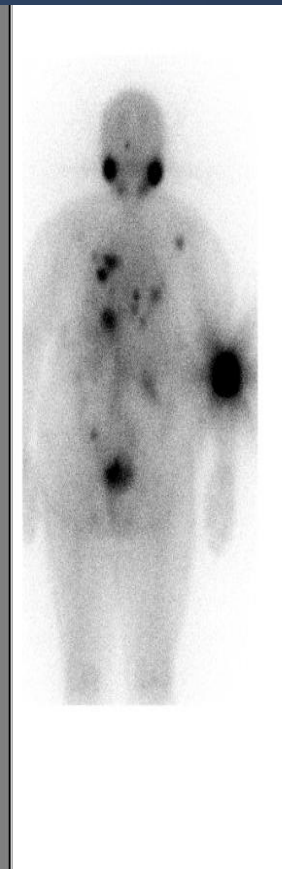
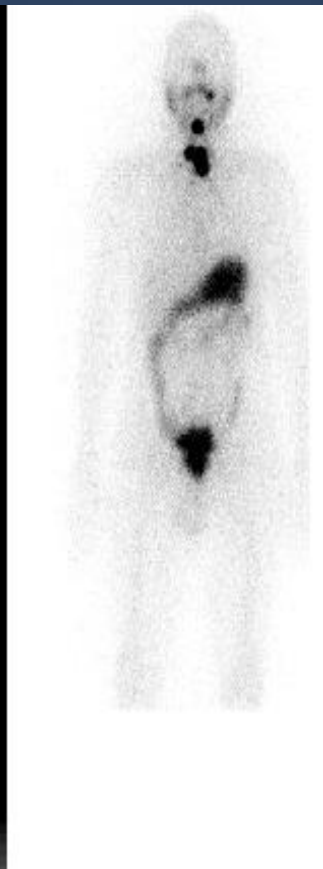Negative WBS

# THYROID METASTASES STUDY

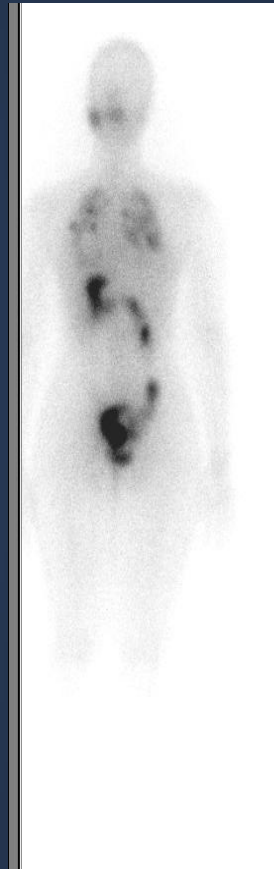
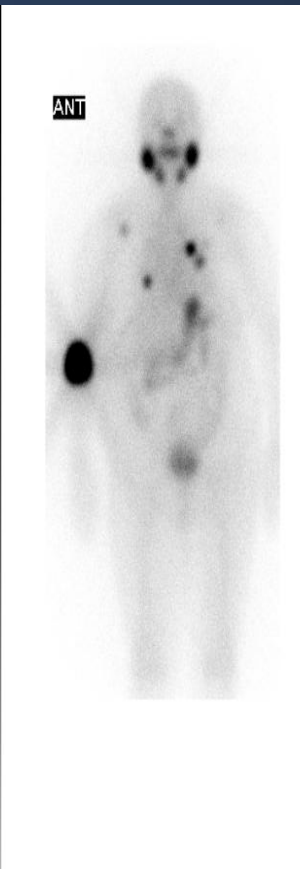
(I-123 or I-131 as Sodium Iodide)



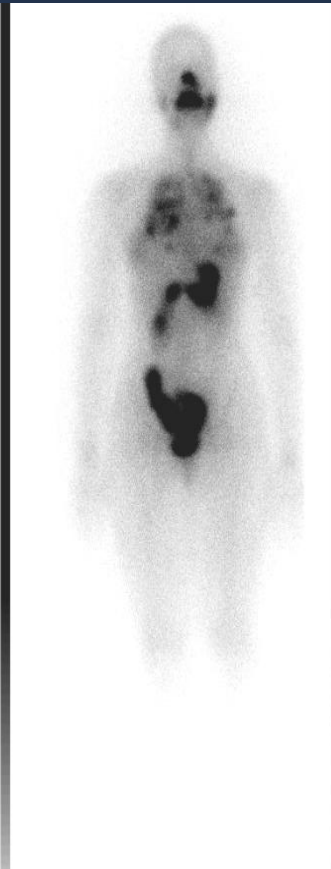
Local Recurrence



Bone Metastases



Lung Metastases





# When is thyroid scanning helpful?

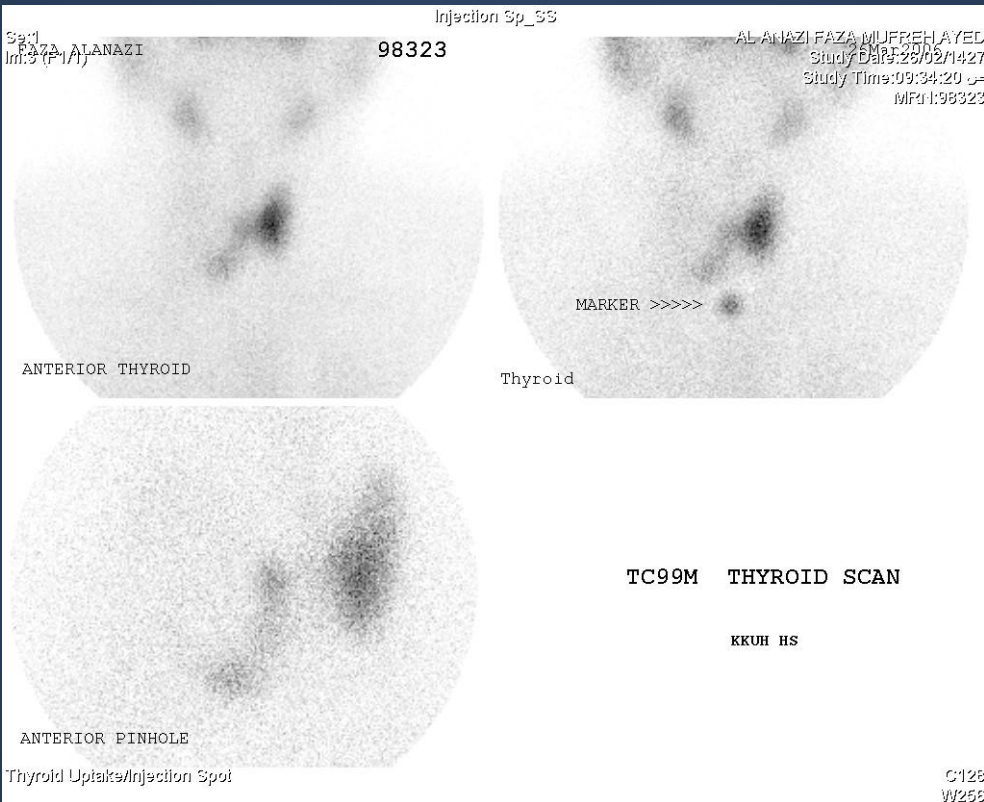
## Indications for Thyroid Scan



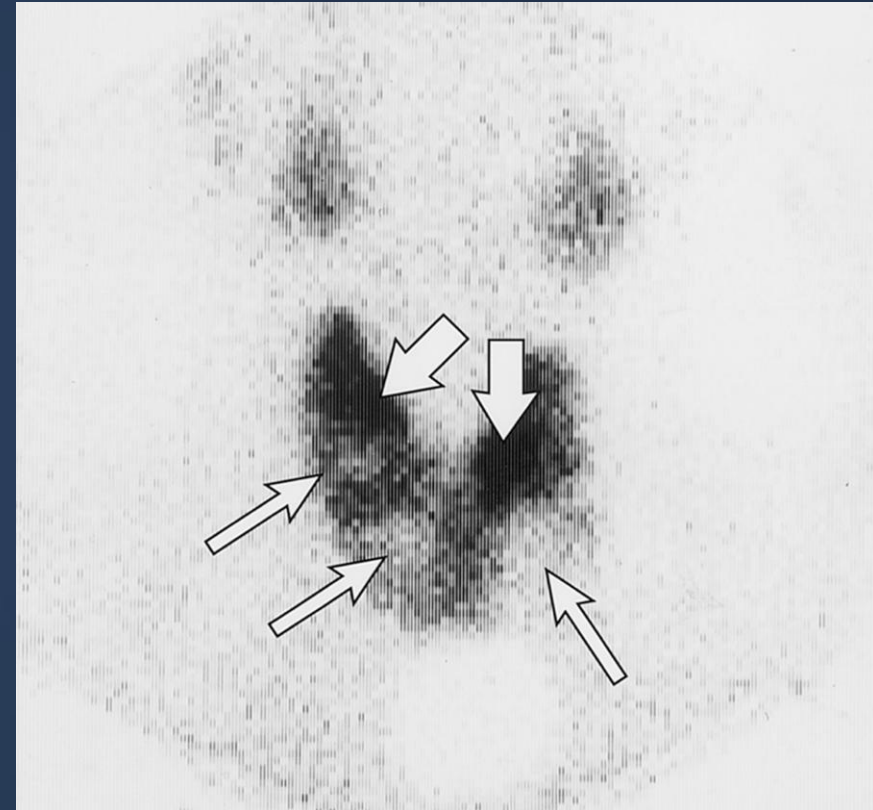
- Evaluation of thyroid nodules : No. & type
- Evaluation of congenital hypothyroidism : Agenesis Vs. Dyshormonogenesis.
- Evaluation of neck masses : ectopic thyroid, thyroglobulin cyst.
- Evaluation of thyrotoxicosis.

# Evaluation of thyroid nodules

## Single vs MNG



**Solitary cold nodule**

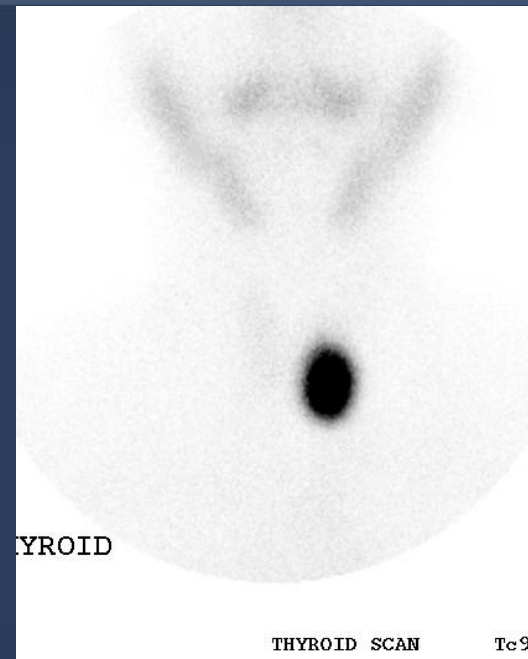


**Multinodular goiter**

**The chance of malignancy is more in Solitary cold nodule than in MNG**

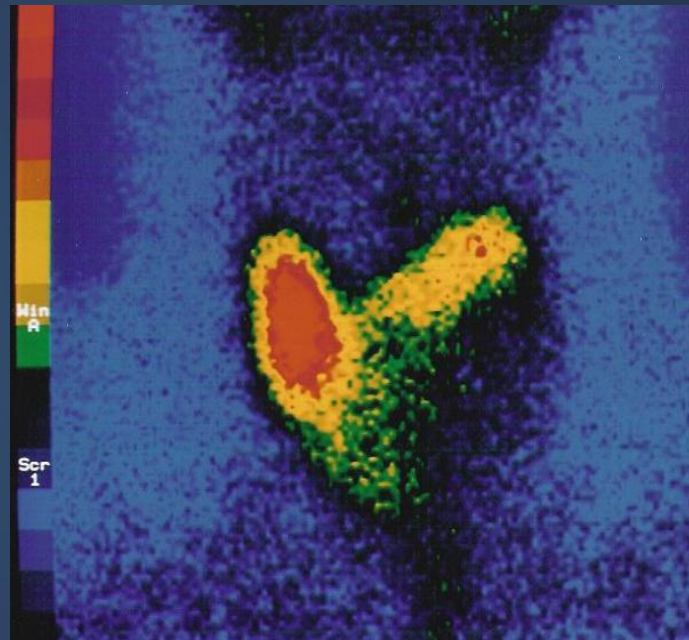
# Evaluation of thyroid nodules

## Hot vs Cold vs warm



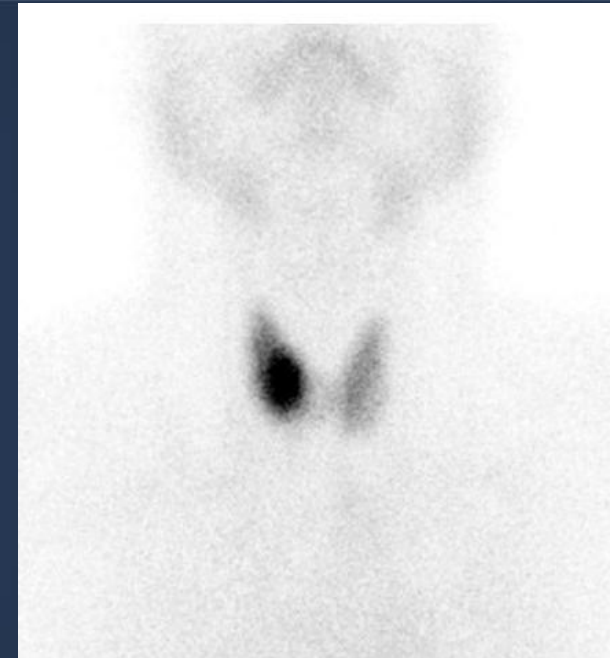
**Hot**

**< 5% Malignant**



**Cold**

**15-20% Malignant**

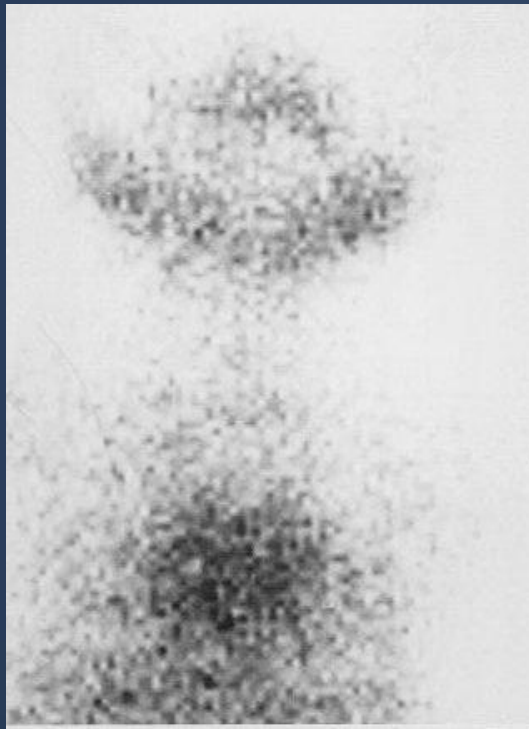


**warm**

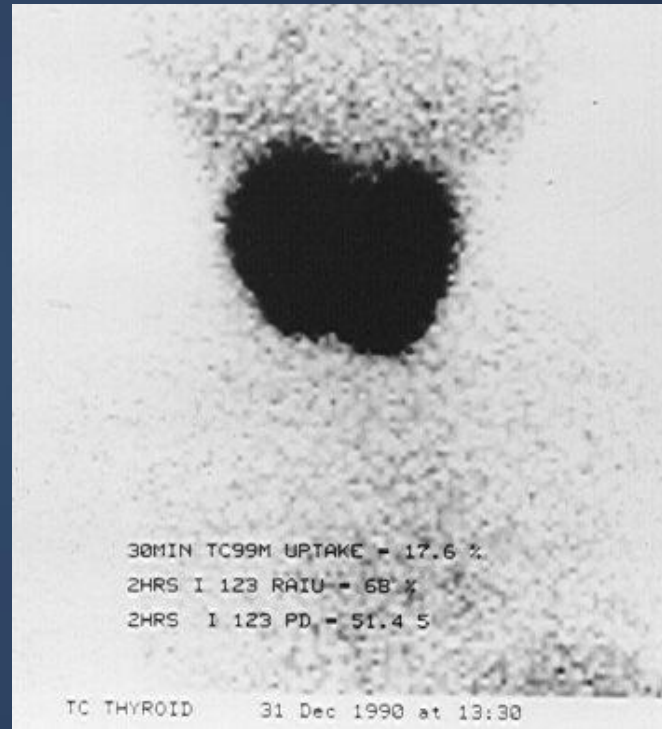
**Suspicious**

# Evaluation of congenital hypothyroidism

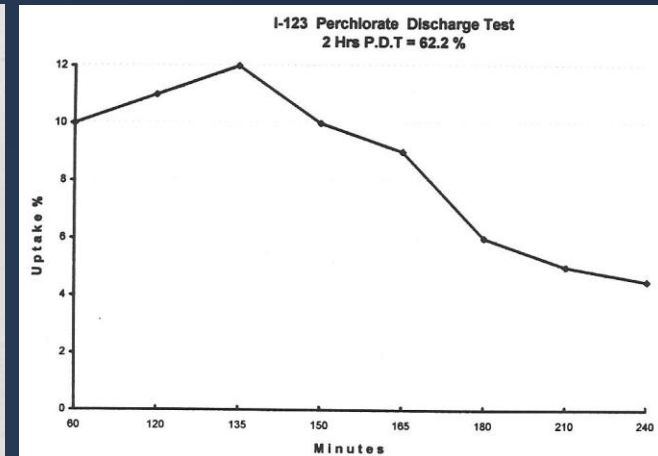
## Agenesis vs Dyshormonogenesis



Agenesis



Dyshormonogenesis



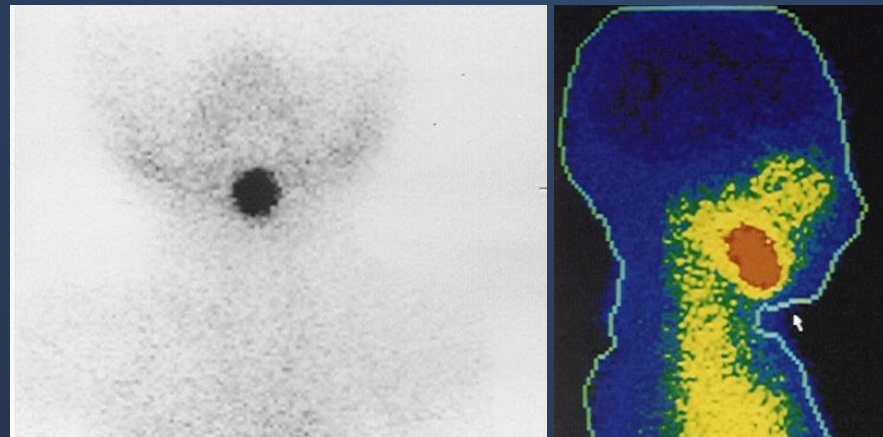
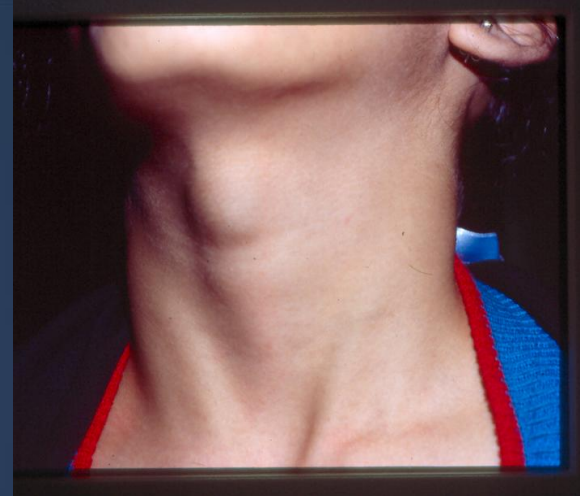
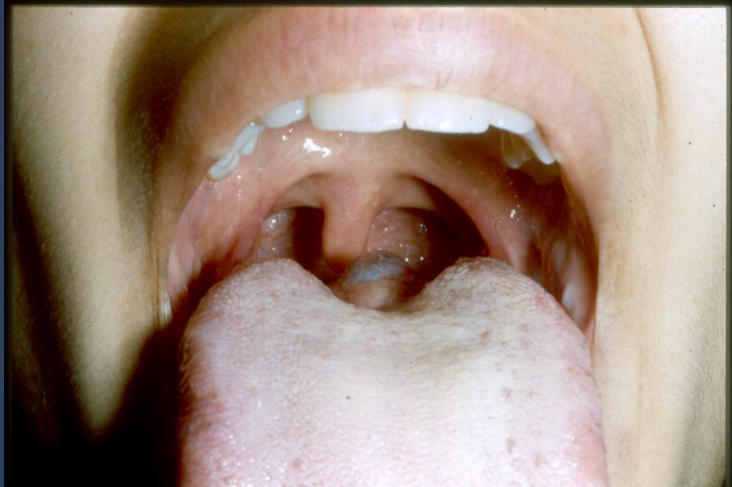### Perchlorate Discharge Test

- 50 - 80 uCi  $I^{123}$  orally.
- 2 hrs RAIU
- 400 mg Kclo<sub>4</sub>
- RAIU/ 15 min for 2 hrs.
- Positive test :  $\geq 15$  fall of RAIU below 2 hrs. uptake.

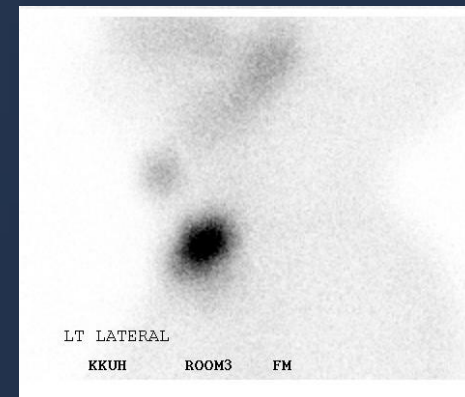
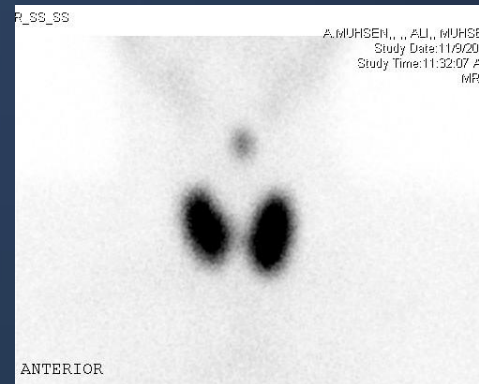


# Evaluation of neck masses

## ectopic thyroid vs thyroglossal cyst



Lingual thyroid



Thyroglossal cyst

# Evaluation of thyrotoxicosis

## Thyrotoxicosis **with** hyperthyroidism



- **Graves' Disease .**
- **Neonatal hyperthyroidism.**
- **Toxic nodular goiter :**

MNTG or Plummer's disease

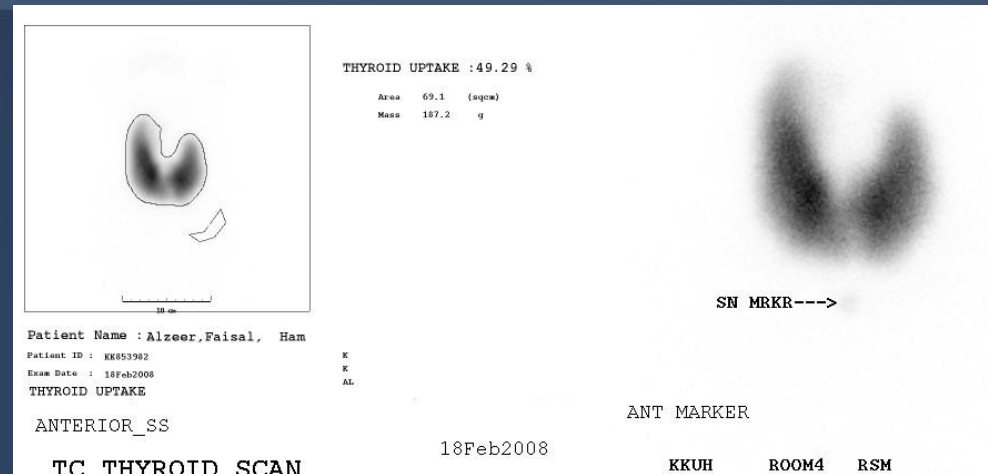
ATN or toxic adenoma

- **Iodine induced**  
( Jod-Basedow disease )

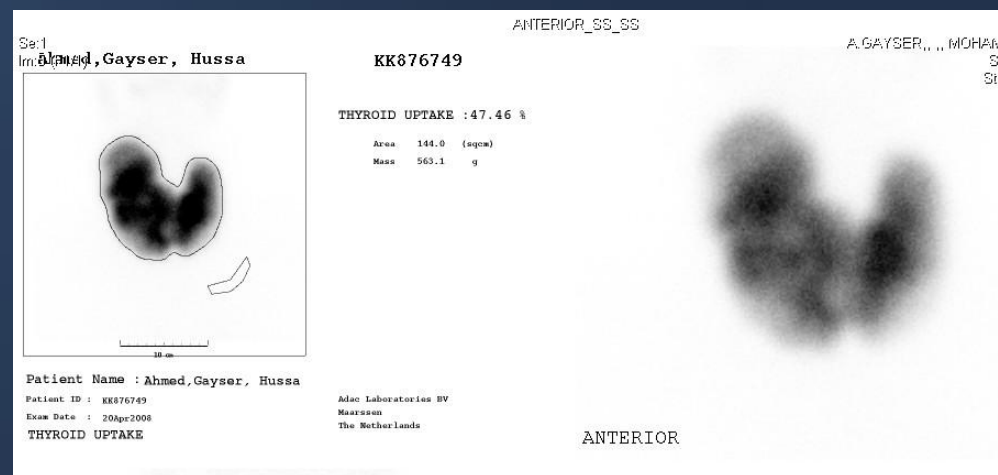
- **Rare causes :**

Excessive HCG by  
trophoblastic tumor

Hypothalamic pituitary  
neoplasms (TSH induced)



**Graves disease**



**MNTG**

# Evaluation of thyrotoxicosis

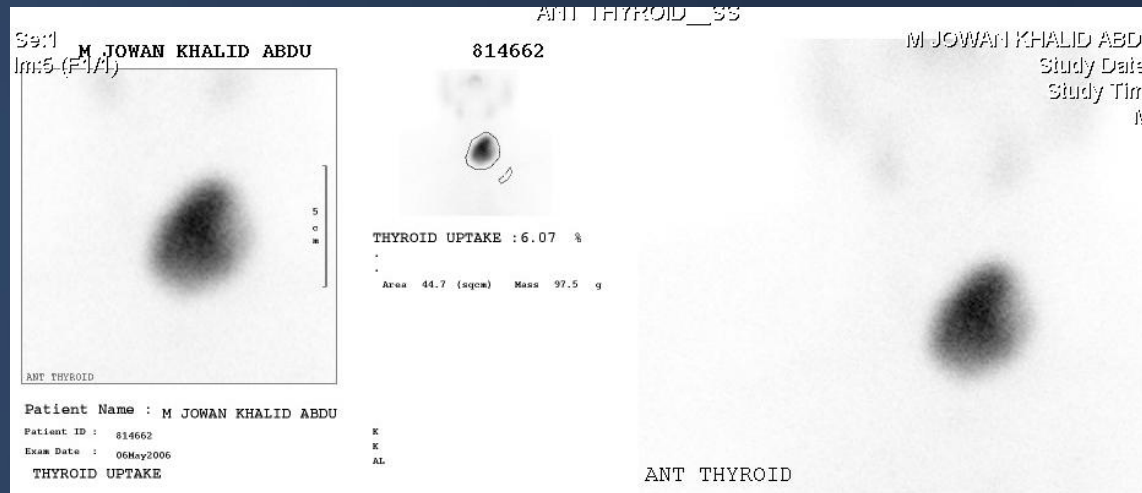
## Thyrotoxicosis **with** hyperthyroidism



- **Graves' Disease .**
- **Neonatal hyperthyroidism.**
- **Toxic nodular goiter :**
  - MNTG or Plummer's disease
  - ATN or toxic adenoma
- **Iodine induced**  
( Jod-Basedow disease )
- **Rare causes :**

Excessive HCG by  
trophoblastic tumor

Hypothalamic pituitary  
neoplasms (TSH induced)



**ATN**

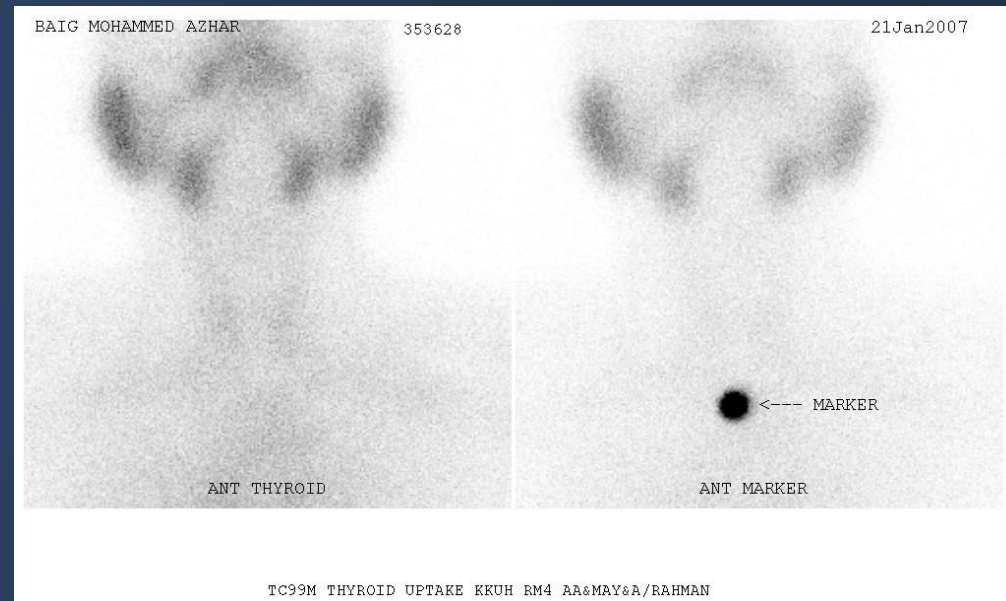


# Evaluation of thyrotoxicosis

## Thyrotoxicosis **without** hyperthyroidism



- **Subacute thyroiditis.**
- **Chronic thyroiditis with transient thyrotoxicosis**
- **Thyrotoxicosis factitia** (exogenous hormone).
- **Thyroid extract** (e.g. Hamburger thyrotoxicosis)
- **Ectopic thyroid :**  
Metastatic thyroid carcinoma  
Struma ovari



**SAT**

# Radioactive Iodine Therapy for Hyperthyroidism



- **Isotope used : I131**
- **Physical Properties:** Solution or capsule
- **Main side effect : Hypothyroidism**
- **Dose :**
  - a. **Calculated : Considering weight and uptake of the gland**
  - b. **Empirical :**
    - Graves: 5-15 mCi**
    - ATN : 15-20 mCi**

# Radioactive Iodine Therapy for Thyroid Cancer

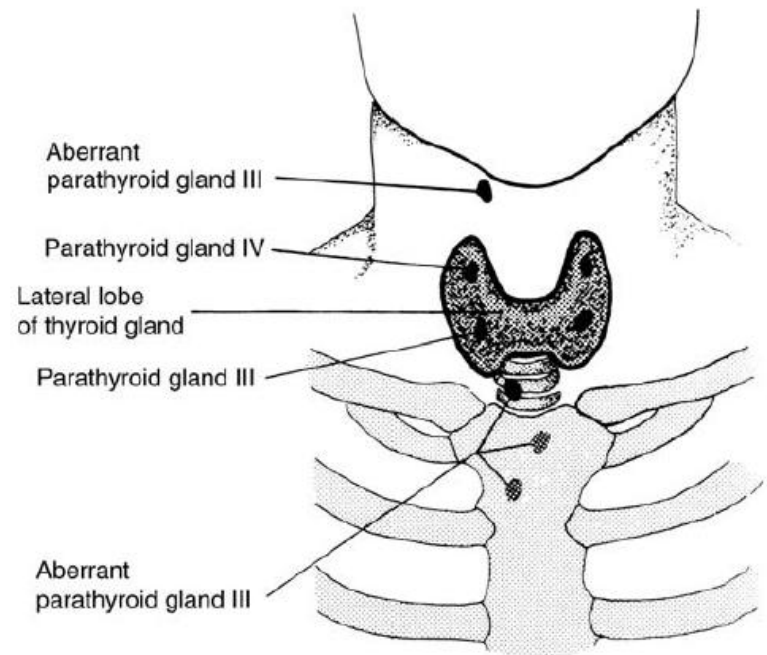
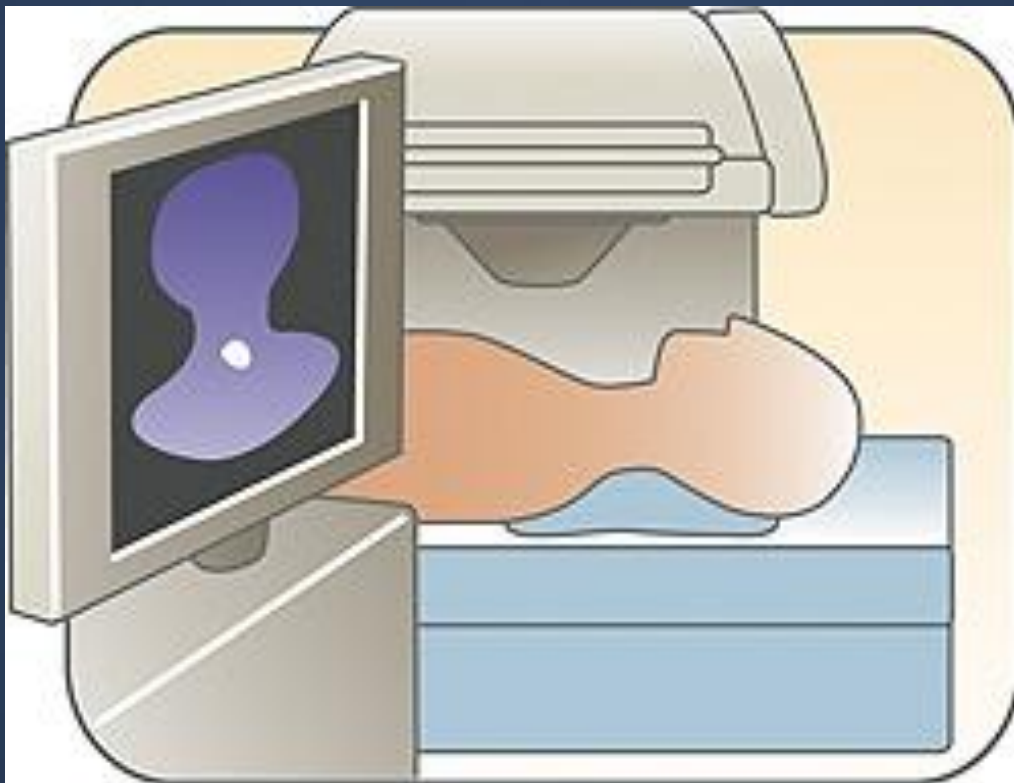


**Isotope used : I131**

**Physical Properties: Solution or capsule**

- **Thyroid remnant : 80-100 mCi**
- **Lymph Node Mets : 100 mCi**
- **Local Recurrence : 100 mCi**
- **Lung Mets : 150 mCi**
- **Bone Mets : 200 mCi**

# Parathyroid Scan



**Figure 13.10.** Normal and aberrant distribution of the parathyroid glands.

# Parathyroid Scan

## LEARNING OBJECTIVES...



At the end of the lecture you will be able to answer the following questions:

- Discuss the principles of dual-phase and dual-isotope parathyroid imaging.
- Identify the common imaging features of pathologic parathyroid glands.
- Discuss causes of false negative scans.
- Identify causes of false negative and false positive scans.

# Parathyroid Scan Techniques



- TL-201 \_ Tc-99m subtraction
- Tc-99m Sestamibi ( Dual Phase )
- Tc-99m Tetrofosmin ( Dual Phase )

# Parathyroid imaging



<u>Radiopharmaceutical</u>	<u>99mTc / 201Tl Subtraction</u>	<u>99mTc sestamibi</u>
<b>Activity administered</b>	80 MBq (2 mCi) 201Tl; 370 MBq (10 mCi) 99mTc	925 MBq (25 mCi)
<b>Images acquired</b>	Inject Tl first and acquire 15-min 100 000 count view of neck and mediastinum. Then acquire similar Tc images without moving patient. Subtract Tc data from Tl after normalization to equal count densities	Anterior (and oblique) views at 15 min and at 2–3 h; SPECT as needed



# PARATHYROID IMAGING



## Tc-99m-Sestamibi

- The Parathyroid Study depicts hypertrophied parathyroid tissue, probably because of uptake of Tc-99m-sestamibi in the mitochondria of hyperactive cells.

**Indications :** Detect and localize parathyroid adenomas .

**Patient Preparation :**None.

## **Radiopharmaceutical, Dose, & Technique of Administration**

- **Radiopharmaceutical:** 25 mCi Tc-99m-sestamibi i.v.
- **Patient position:** Supine with head and neck extended and immobilized.
- **Gamma camera Imaging field:**
  1. Neck.
  2. Upper two thirds of the mediastinum.

**Acquire images at 15 minutes and 2-3 hours post injection.**

**SPECT images improves localization.**

- **TI – Tc99m subtraction :** Several protocols have been developed for routine subtraction of thyroid tissue from parathyroid tissue

# Parathyroid Scan

Dual phase MIBI Scan ( Or Tetrofosmin )



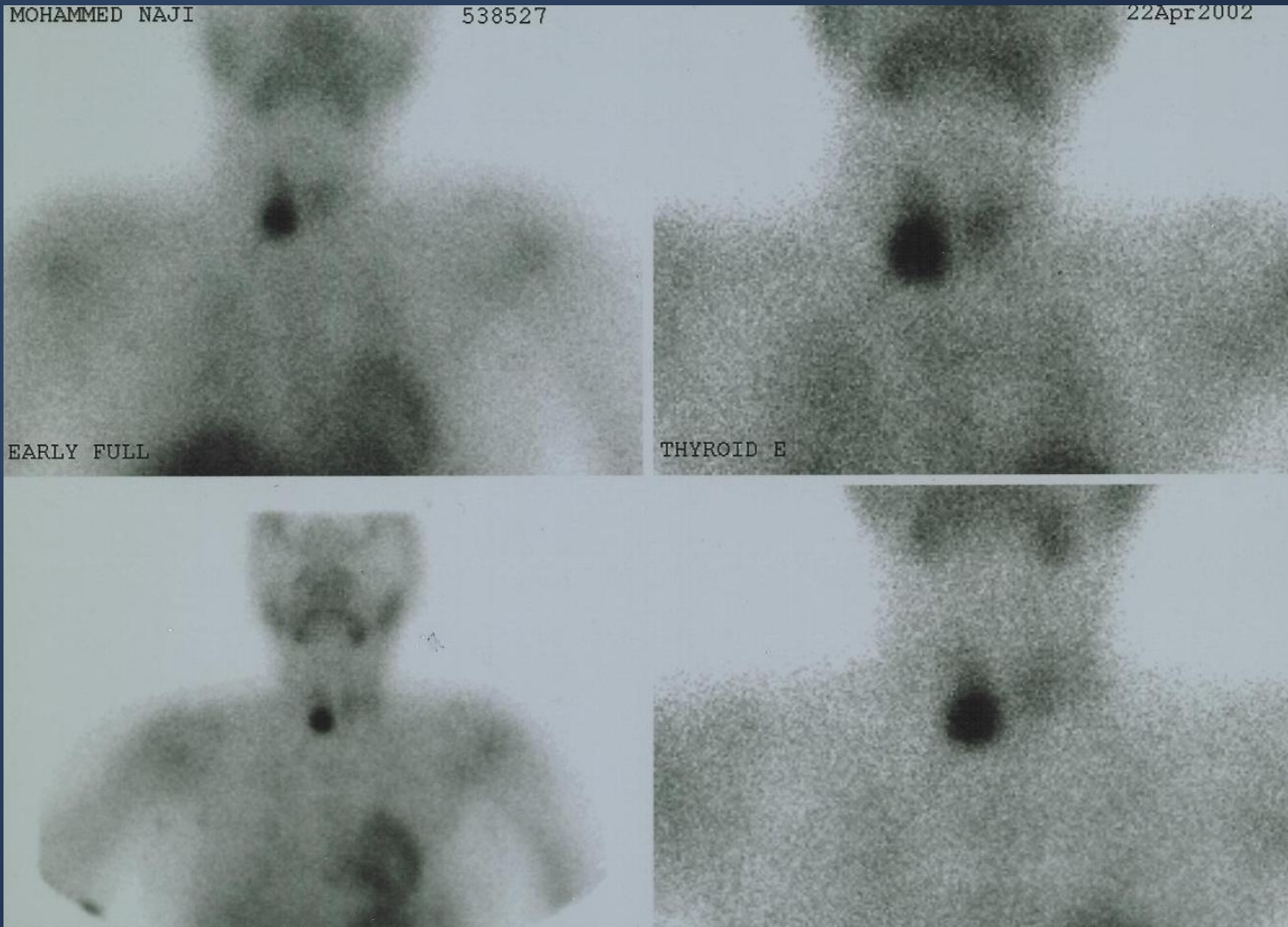MOHAMMED NAJI

538527

22Apr2002

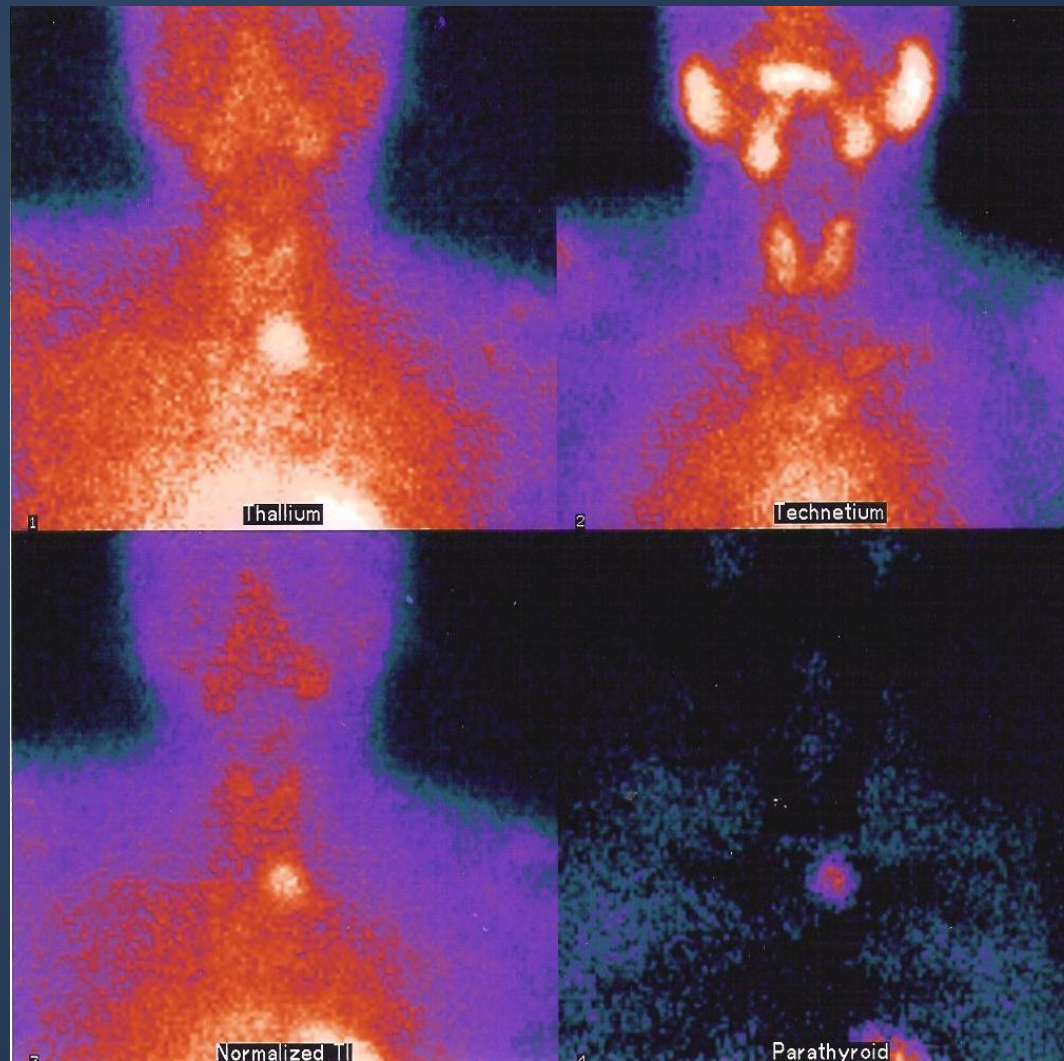
EARLY FULL

THYROID E



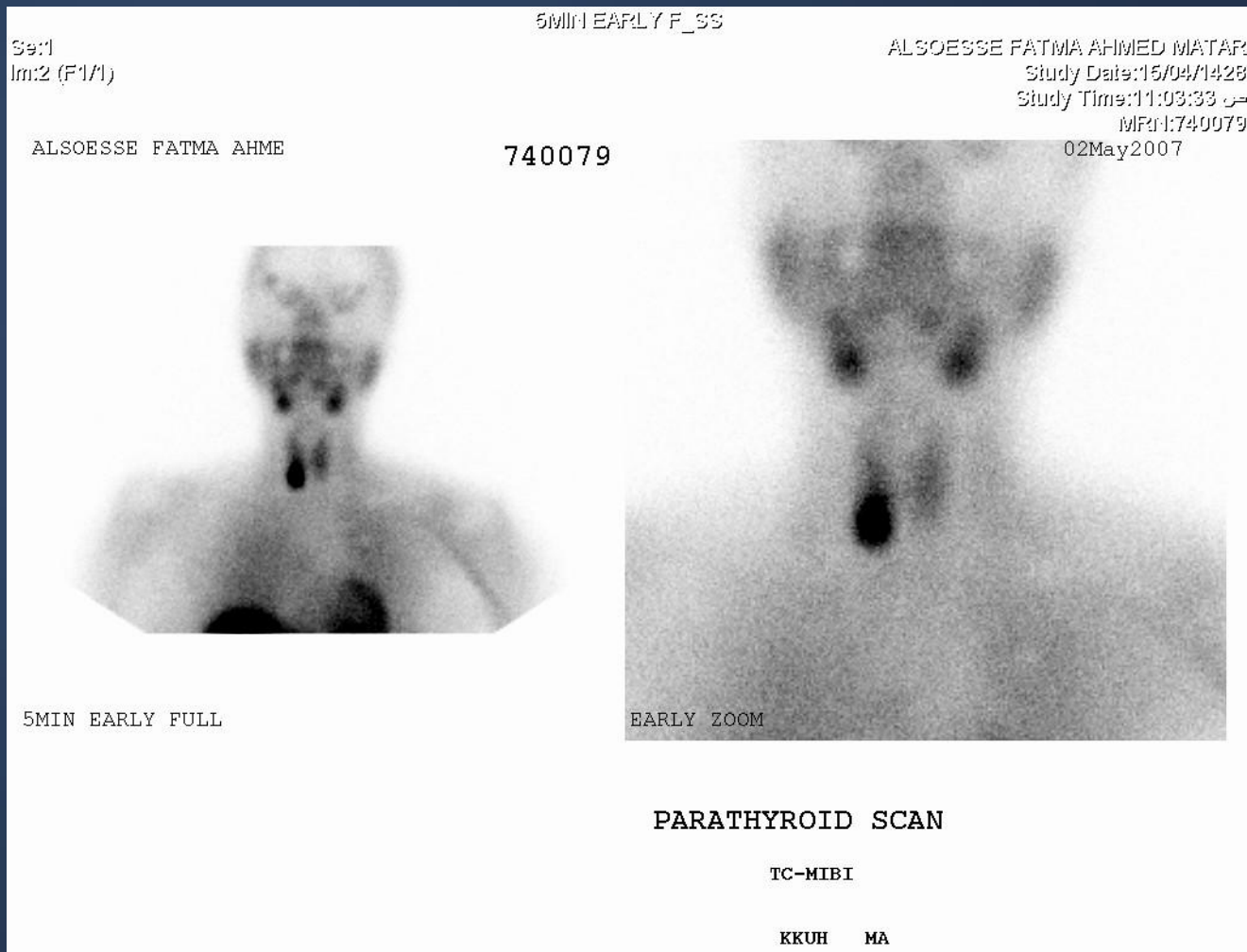# Parathyroid Scan

## Tc-Tl Subtraction Scan



# Parathyroid Scan

## Sestamibi dual phase



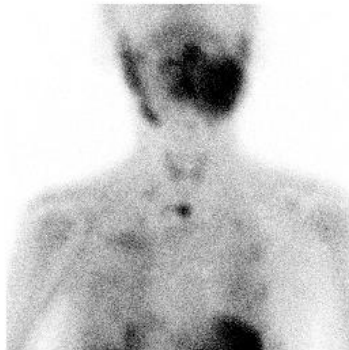

# Parathyroid Scan

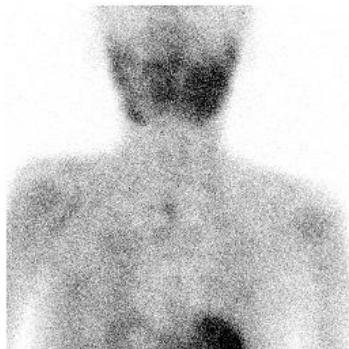## Ectopic Parathyroid



IM2 (F171)



5MIN A FULL



5MIN A FULL

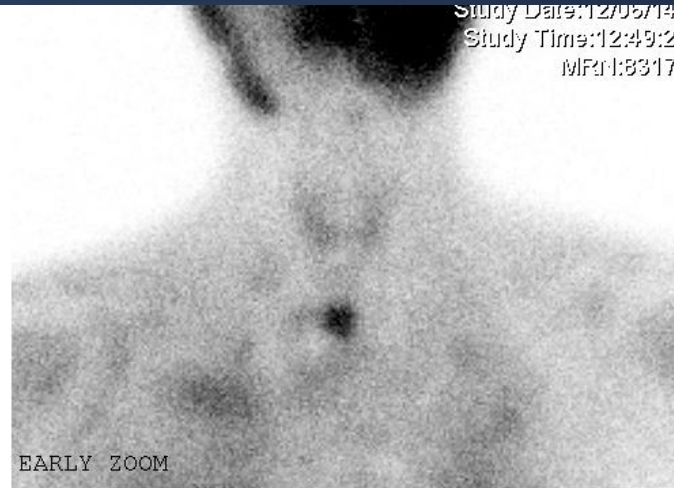**PARATHYROID MIBI**

27Jun2007

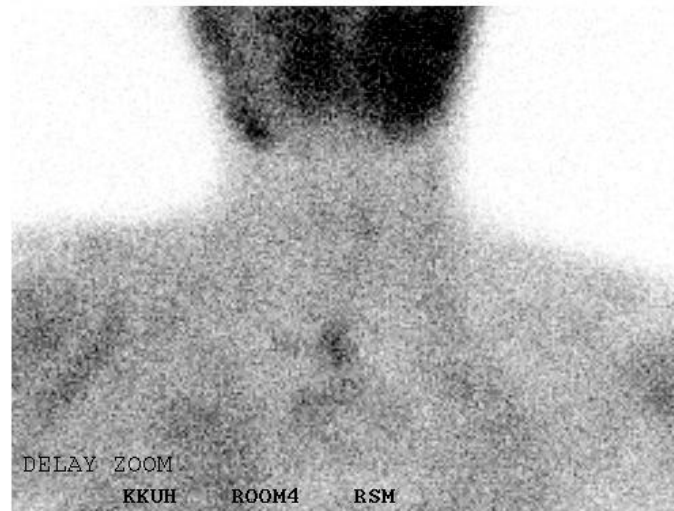
Study Date: 12/06/1428

Study Time: 12:49:29

MPN: 831769



EARLY ZOOM



DELAY ZOOM

KKUH

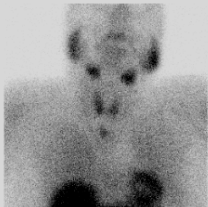ROOM4

RSM

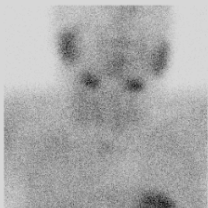C80  
W160

# PLANAR vs SPECT/CT

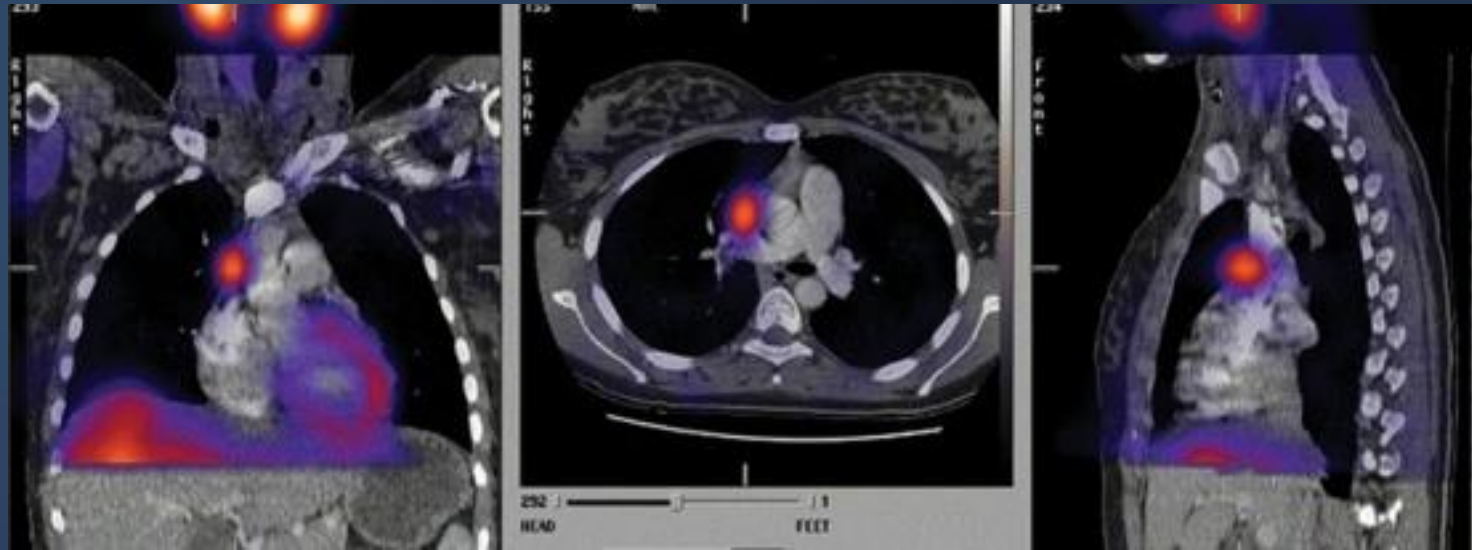
KK16289



5MIN A FULL



2HRS DEL ZOOM

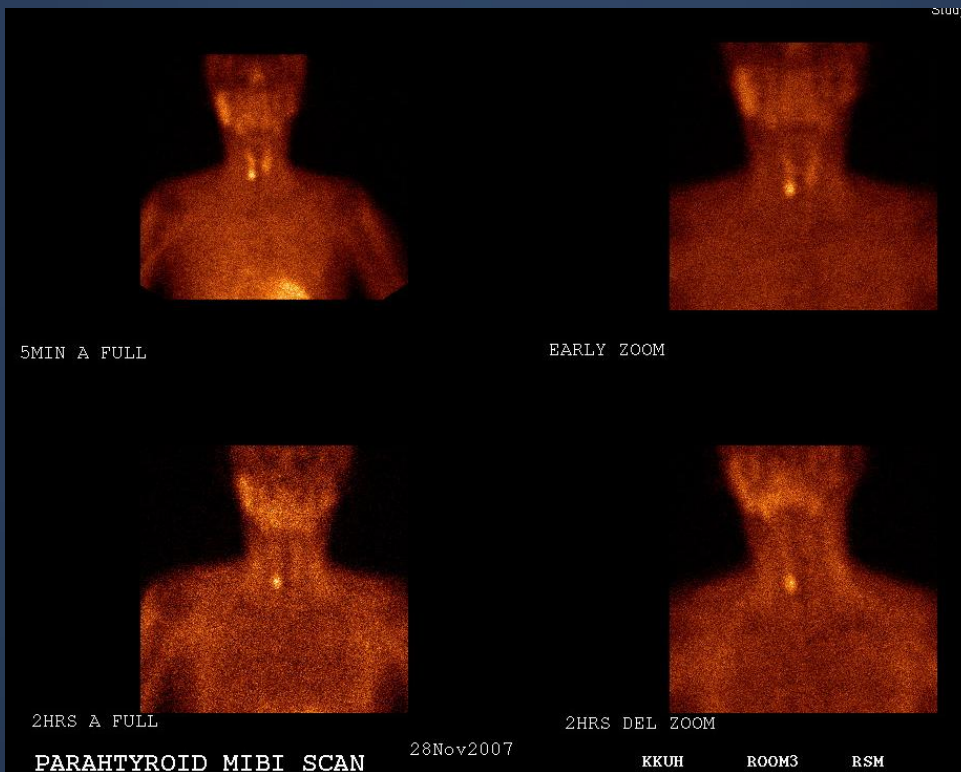

*SPECT-CT images accurately localize the adenoma and guide the surgeon to the best surgical approach*

# Sestamibi Parathyroid Scan Result

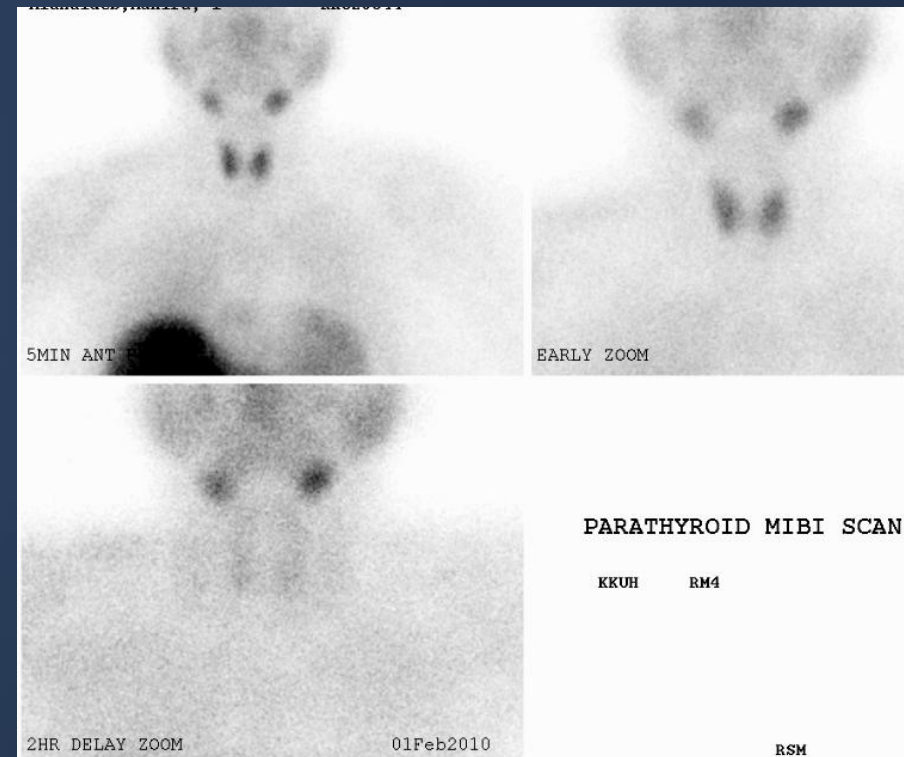


High PTH / High Ca



TP

High PTH / High Ca



FN

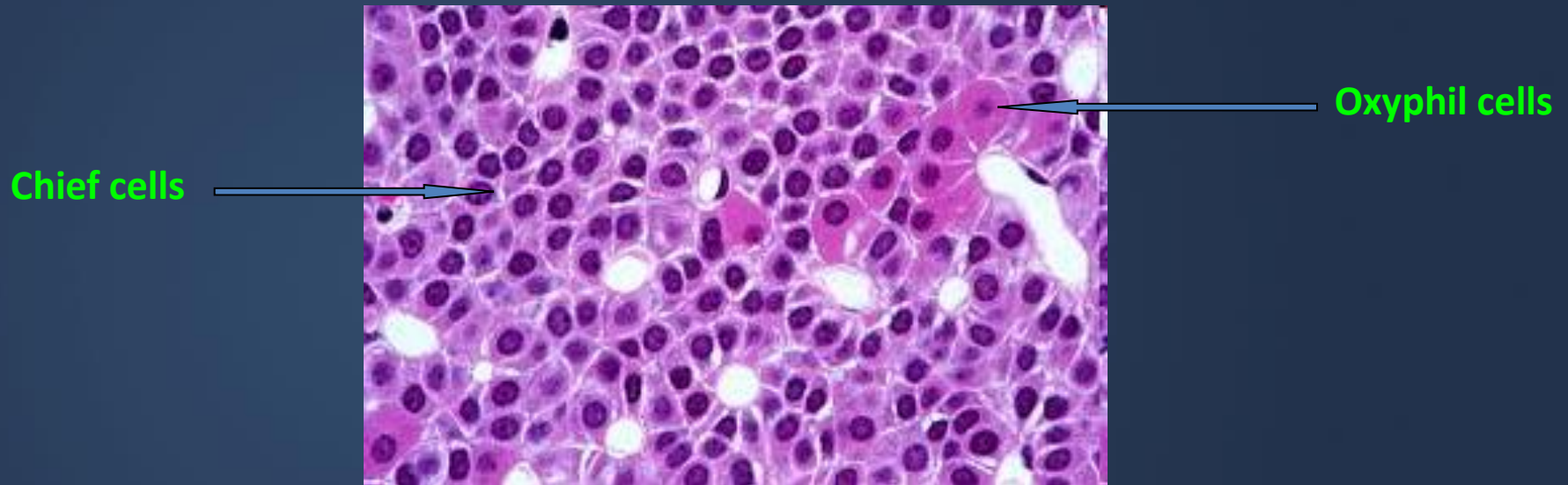


**Q:What is the cause of the  
FN result...?**



**A: Mechanism of sestamibi uptake**

# Parathyroid Cells



Normal parathyroid glands comprise 2 cell types:

- i. **Chief cells:** responsible for PTH production
- ii. **Oxyphil cells:** eosinophilic cells whose cytoplasm is composed almost entirely of mitochondria.

*While the normal oxyphil cell does not synthesize and secrete PTH, the oxyphil cells of pathologic parathyroid glands do secrete the hormone.*

# Mechanism of Sestamibi uptake

## SESTAMIBI : METHOXYISOBUTYLISONITRILE

- Its parathyroid uptake was first reported by Coakley et al. in 1989
- Mechanism of MIBI uptake and retention is still unclear. Multifactors have been proposed:

### a. Biochemical properties of the tracer :

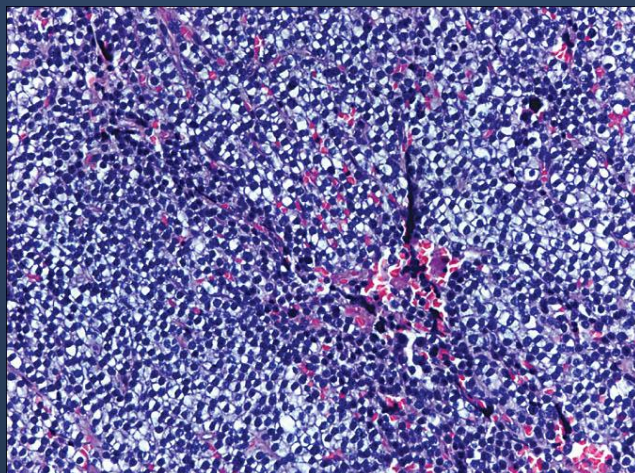
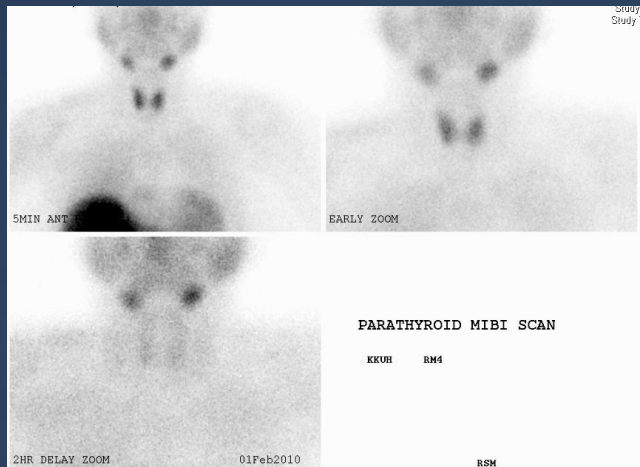
**Lipophilicity** : The lipophilic sestamibi molecule is concentrated by mitochondria. This explains why adenomas with an abundance of mitochondrial-rich oxyphil cells retain the sestamibi

Cationic charge

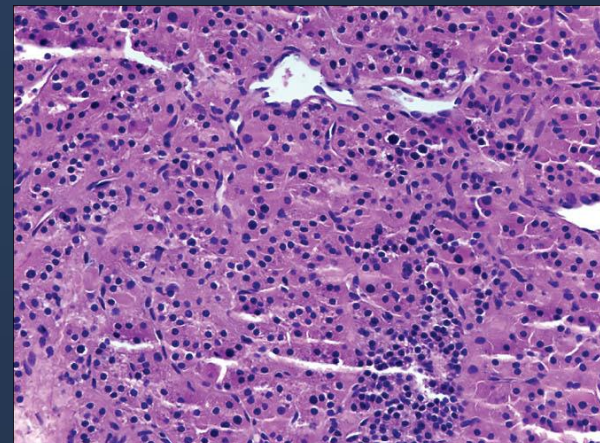
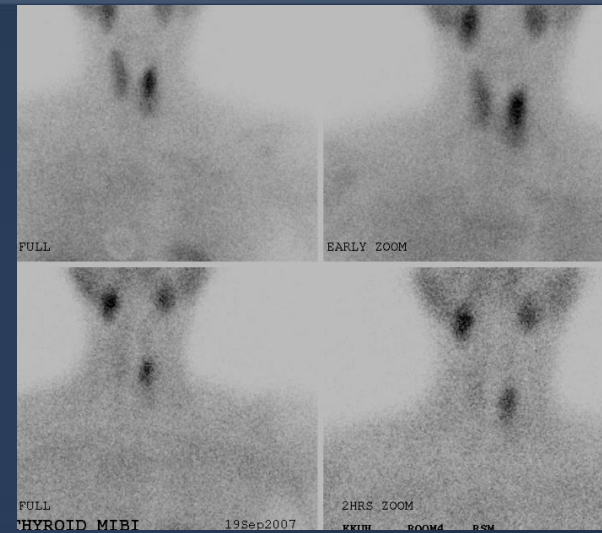b. Cell Type : A predominance of oxyphil cells within an adenoma is more likely to lead to a positive scan.

c. Local factors: blood flow, trans-capillary exchange, interstitial transport and negative intracellular charge of both mitochondria and membranes.

# Cell Type and Scan Result



Parathyroid adenoma composed entirely of  
**glycogen-rich chief cells.**



Parathyroid adenoma composed mainly  
**of mitochondrial-rich oxyphil cells.**

# Q



**What is the cause of the  
FN result...?**



# “FN” Sestamibi Scan...?

- **Histologic type** : False-negative scans can occur with parathyroid glands containing predominantly clear cells.
- **Size and Location**: Smaller-volume parathyroid adenomas and those in the upper position are less likely to be localized with sestamibi scans.
- **Number of adenomas**: FN rate is increased with MGD compared with patients with a single adenoma .
- **Decreased tracer concentration** : Possible association.
  - a. P-glycoprotein expression
  - b. Multidrug resistance–related protein expression
- **Variability of radiotracer uptake in parathyroid adenomas**:  
Related to differences in perfusion and metabolic activity

*Even with refinements in sestamibi scanning, the fact that all parathyroid adenomas are not created equal on a cellular level may inevitably lead to FN scans in a certain number of cases.*

# False-Positive Scintigraphic Findings



- Solitary thyroid adenoma or a multinodular goiter
- Benign or malignant tumors : breast, lung, and head and neck carcinomas and their lymph node and osseous metastases, as well as bronchial carcinoids.
- Primary thyroid lymphomas.
- Cervical L.N. metastasis from PTC carcinoma
- Reactive lymph nodes
- Remnant thymus
- PTH-secreting paraganglioma
- Enlarged submandibular salivary gland .

■ *In the clinical setting of hyperparathyroidism, false-positive findings are uncommon.*



# Points To Remember Before Proceeding For Parathyroid Imaging



- **Imaging is not for diagnosis:** High Ca and PTH establish the diagnosis
- **Imaging does not identify normal parathyroids:** These are too small to be seen (20-30mg)
- **Imaging should detect abnormal parathyroid(s) and indicate the approximate size and the precise relationship to the thyroid gland:** lateral , SPECT and SPECT /CT
- **Imaging should identify ectopic glands :** SPECT and SPECT/CT
- **Optimal imaging should be able to differentiate patients with single adenoma from those with MGD**
- **Imaging should identify thyroid nodules which may require concurrent surgical resection.**

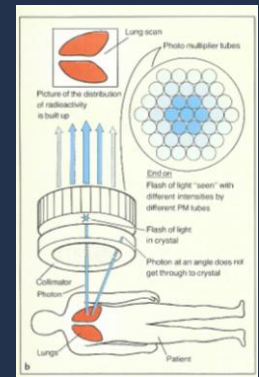
# Reference book and the relevant page numbers..



Nuclear Medicine  
Basic Principles And Clinical Applications  
Dr. Saleh Othman

- **Handout Nuclear Medicine**

Dr. Saleh Othman -kkuh




- **Nuclear Medicine: The Requisites, Third Edition (Requisites in Radiology) [Hardcover]**

Harvey A. Ziessman MD, Janis P. O'Malley MD, James H. Thrall MD

**Relevant Pages :**

**I- Thyroid and Parathyroid : 71-105**

**II- Oncology : 264-274 , 279 -283 ,302 -345 ,119-133  
109 -112 ,296 -299**



# Thank You ☺



Radiology (Nuclear Medicine)

Dr. Saleh Othman

XX-XX-XXXX