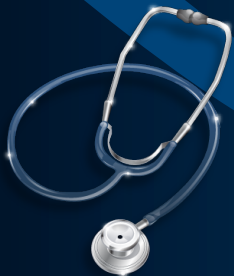



Imaging the Musculoskeletal System

AHMAD AMER AI-BOUKAI

**Associate Professor & Consultant Radiologist
Radiology & Medical Imaging Department
King Khalid University Hospital
PART 2 - 2012**





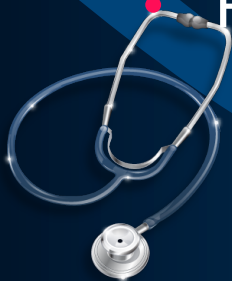OBJECTIVES

The main focus and objective of this lecture is to help student to be competent in looking at MSK images and interpreting findings, by learning:

- Normal radiological anatomic landmarks
- System of analyzing findings

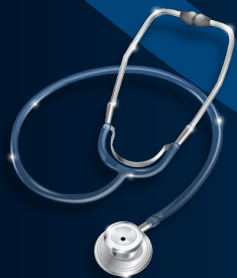“Where to look & What to look for”

- Recognize features of certain disease entity





METABOLIC & ENDOCRINE BONE DISORDERS

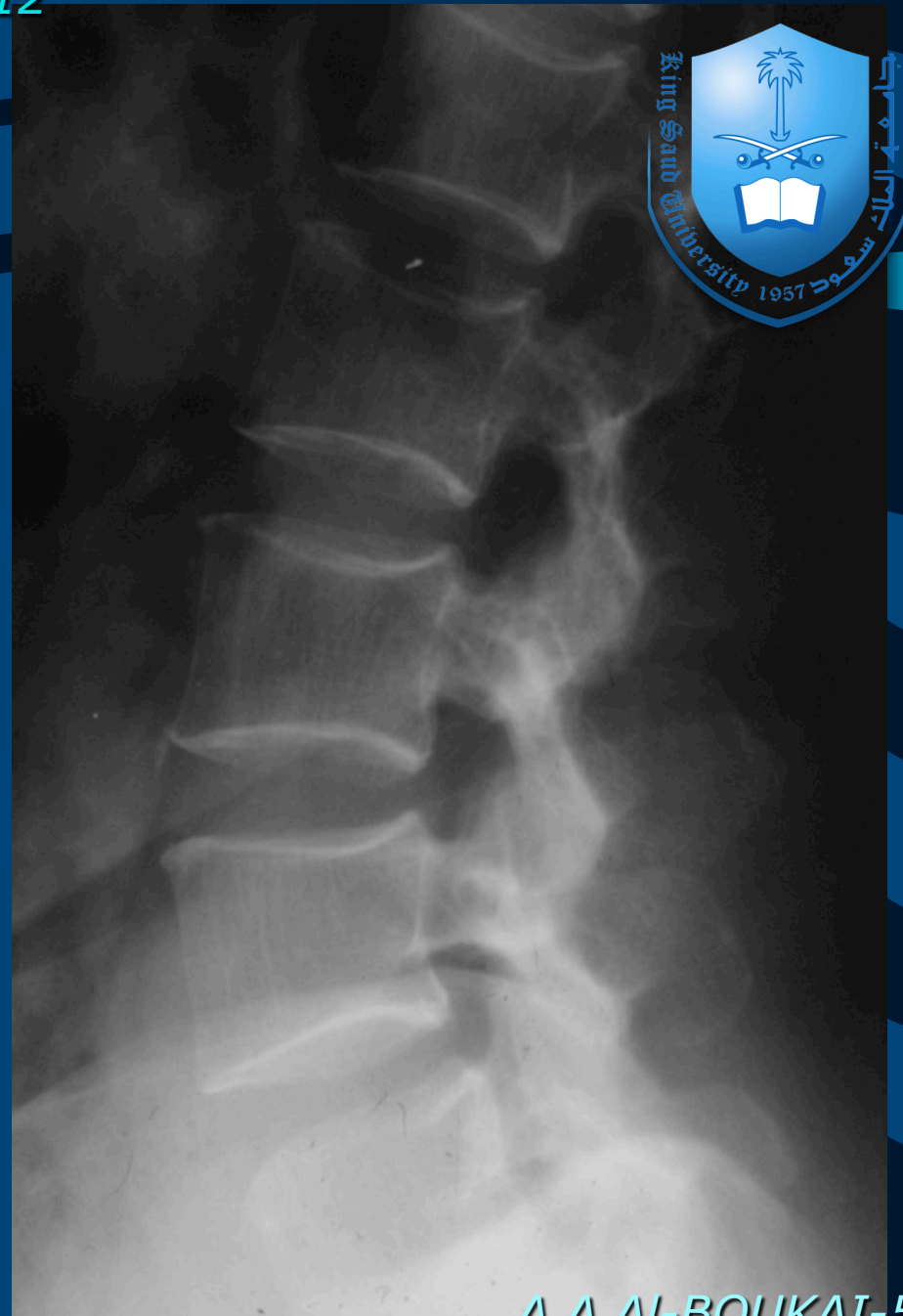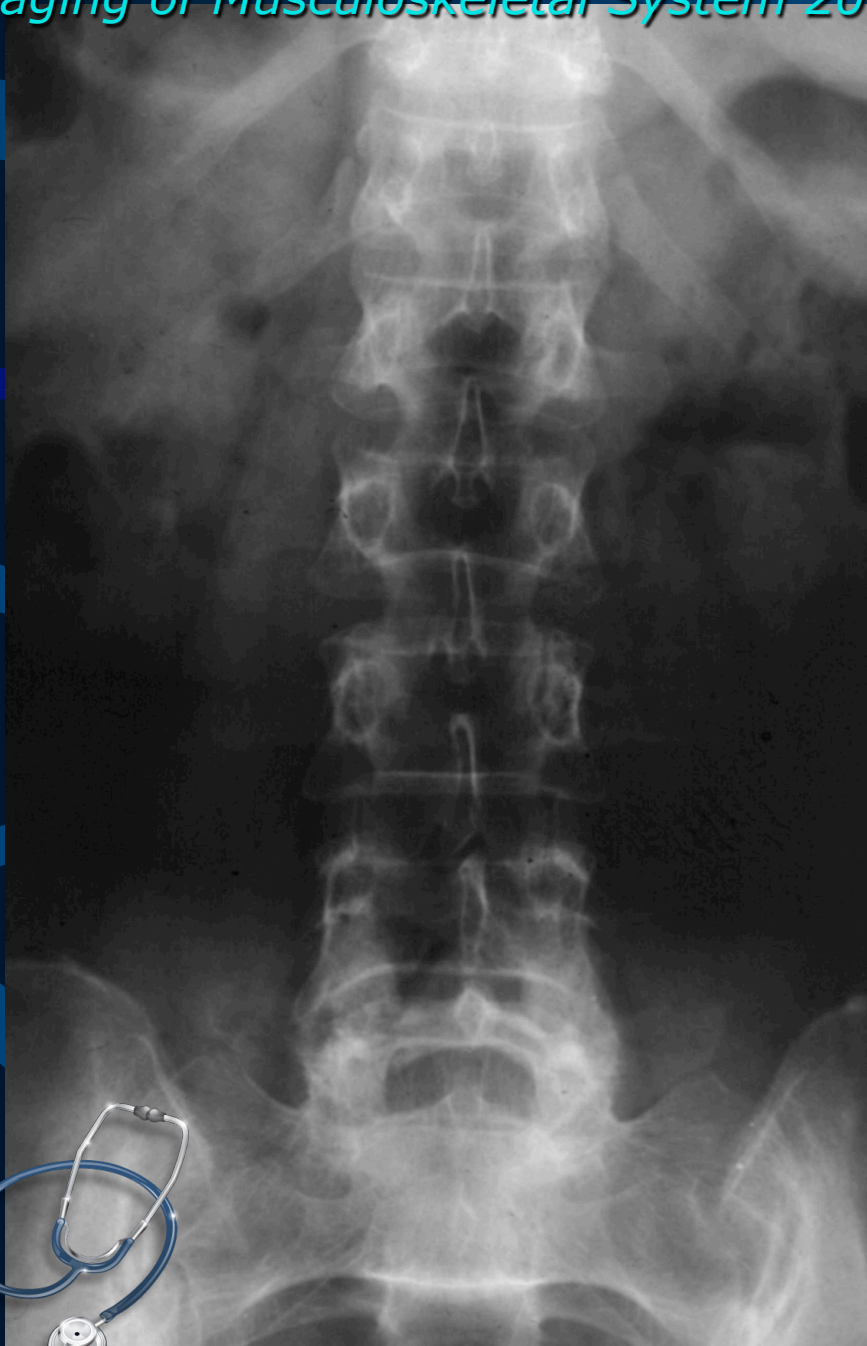


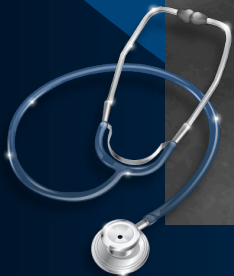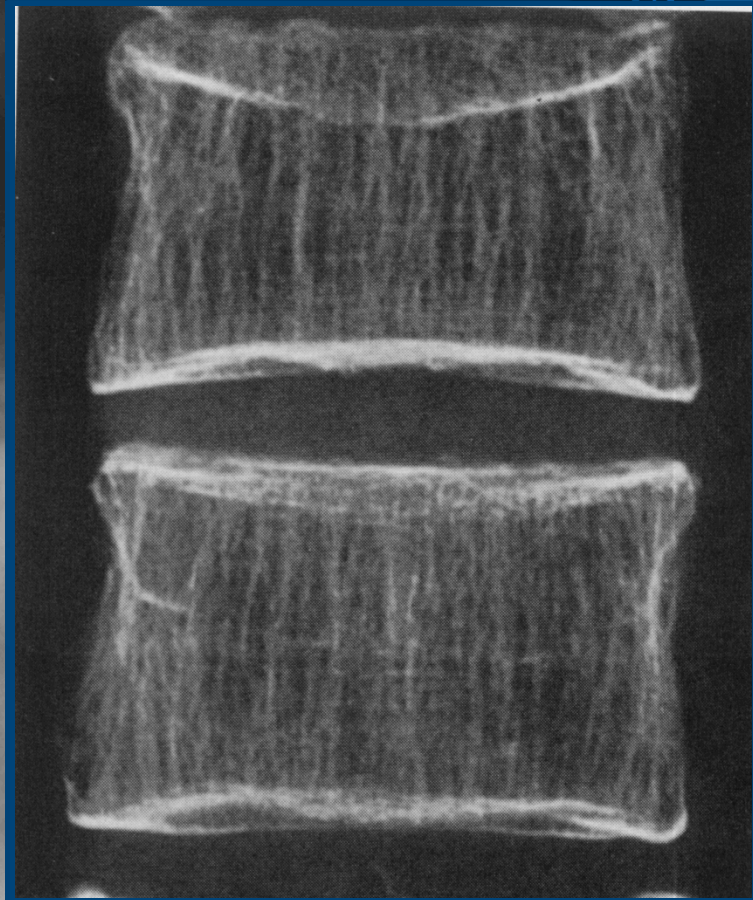


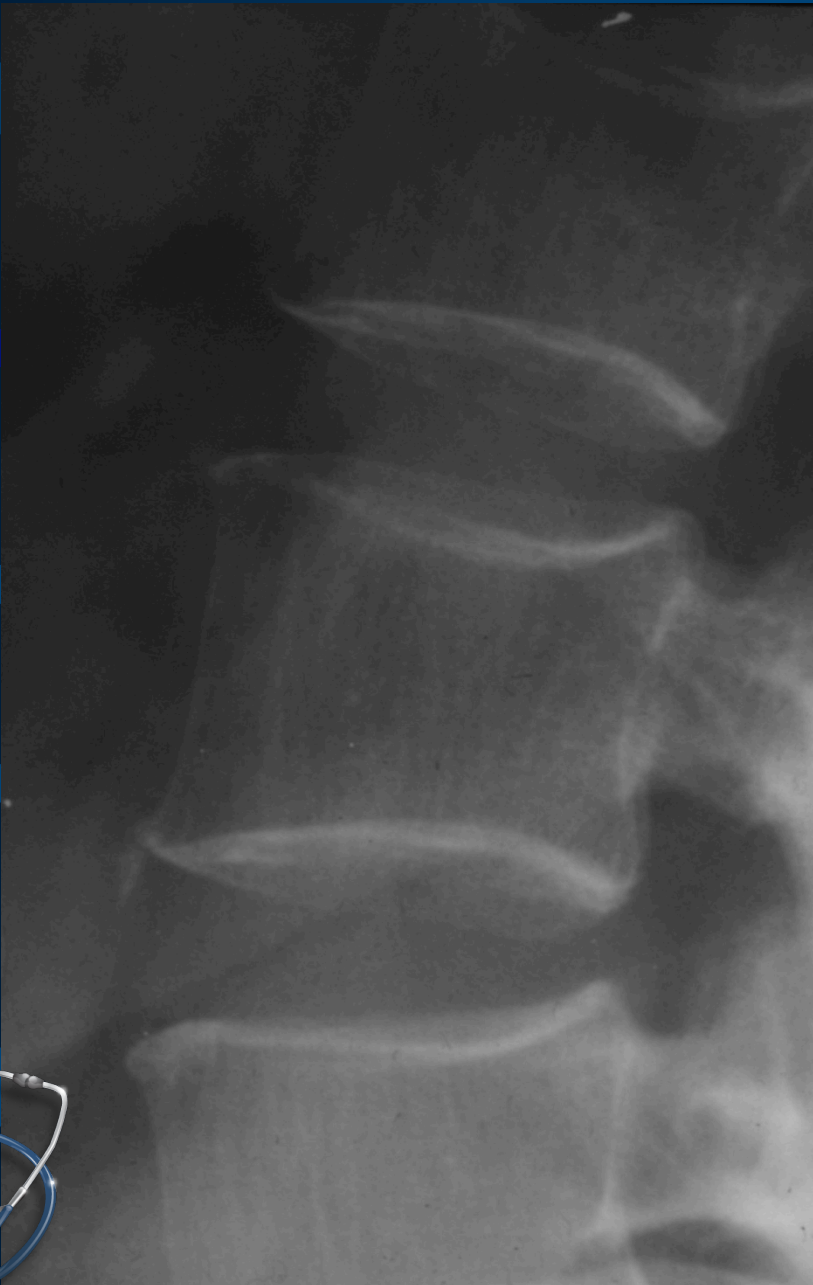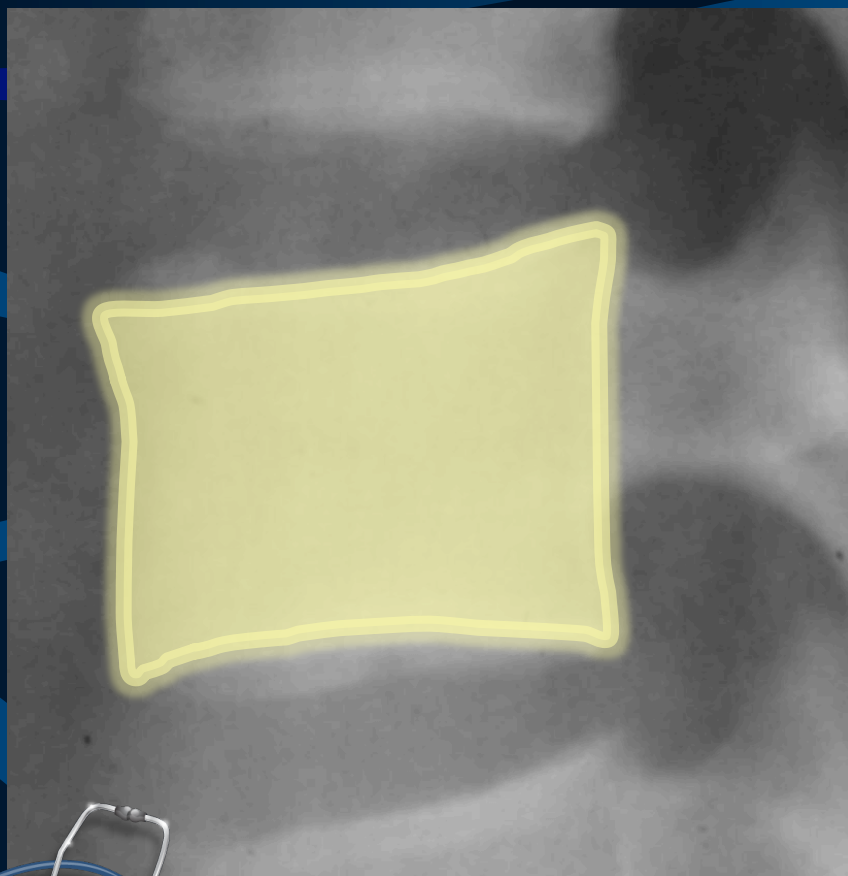
CASE NO. 1

54 years- old female with low back pain
X-ray of lumbosacral spine requested

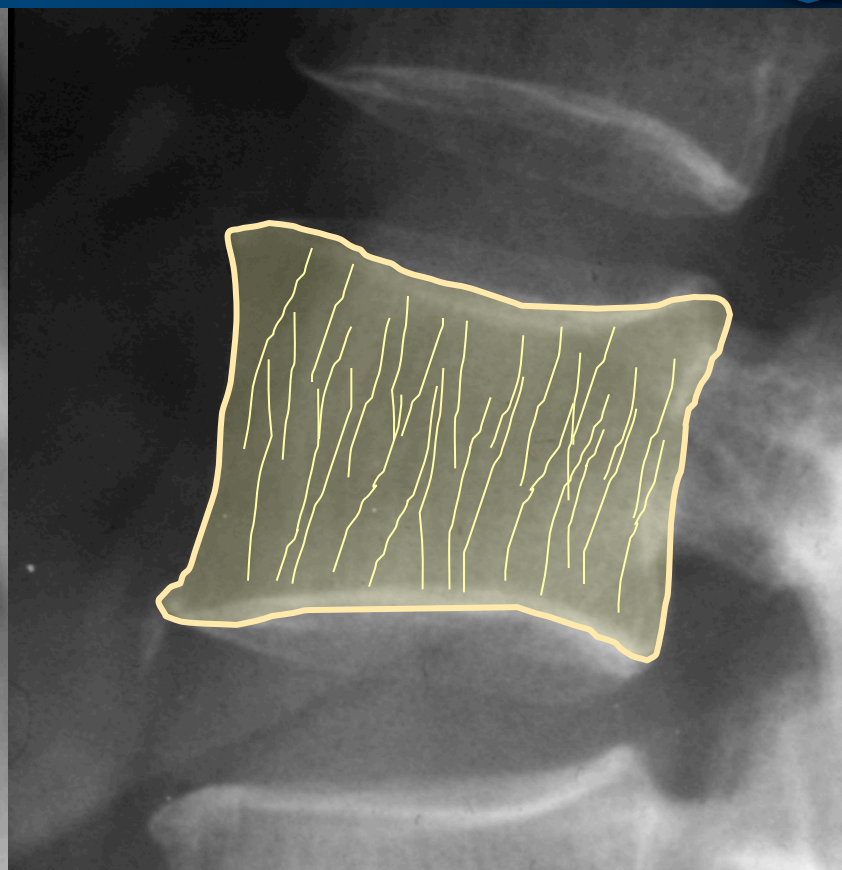




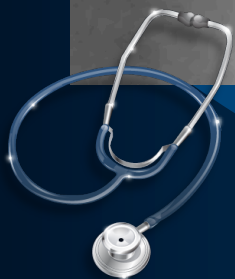



Osteomalacia



Osteoporosis

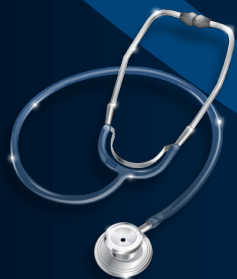


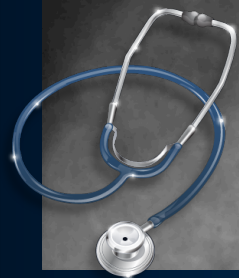
CASE NO. 2

27 years- old male with long standing history
of renal failure

X-ray of lumbosacral spine requested





Osteosclerosis
"Rugger Jersey Spine"



METABOLIC & ENDOCRINE BONE DISORDERS

Renal Osteodystrophy

Osteoporosis

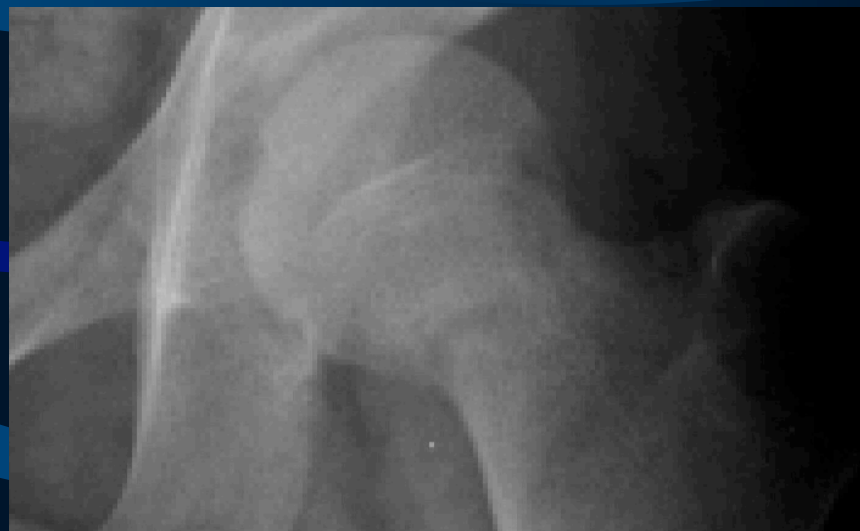Osteomalacia

Secondary Hyperparathyroidism

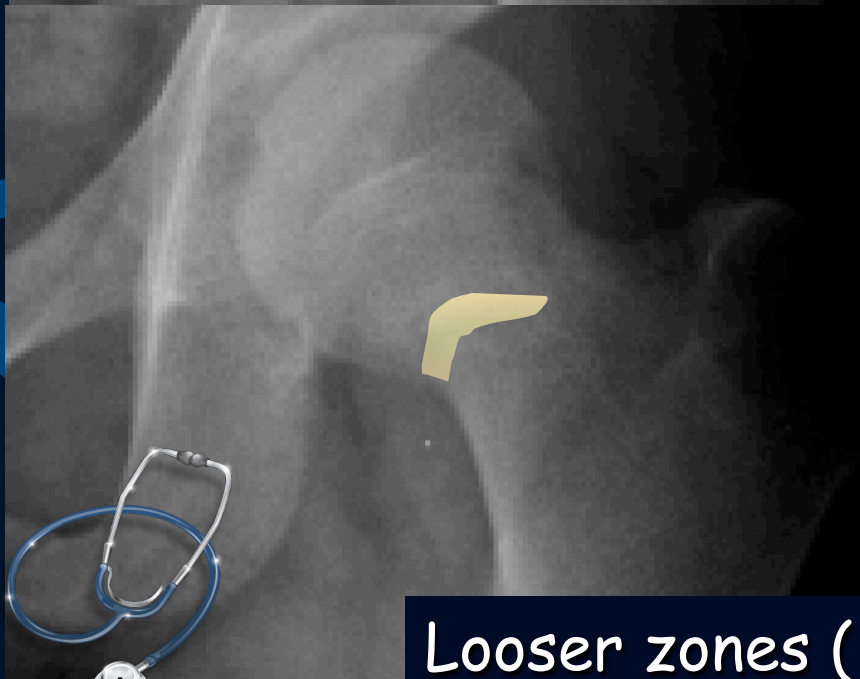
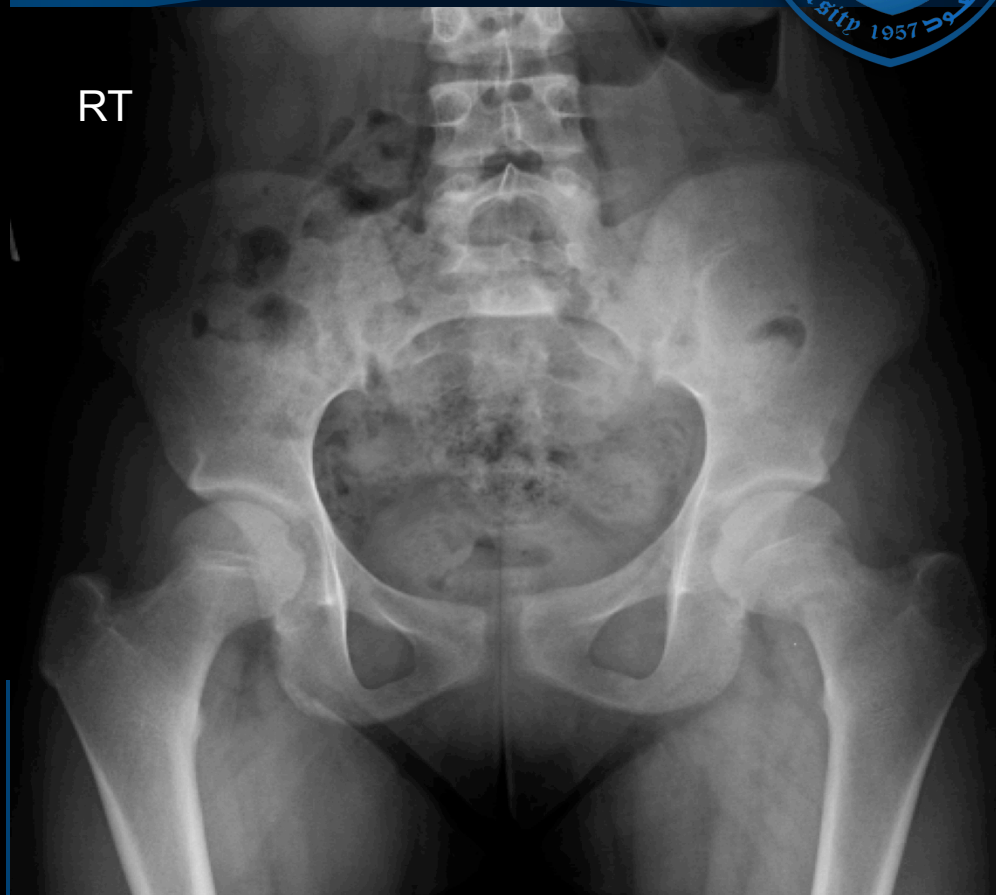
Osteosclerosis



20 years old lady, weakness and lower limbs pain



RT



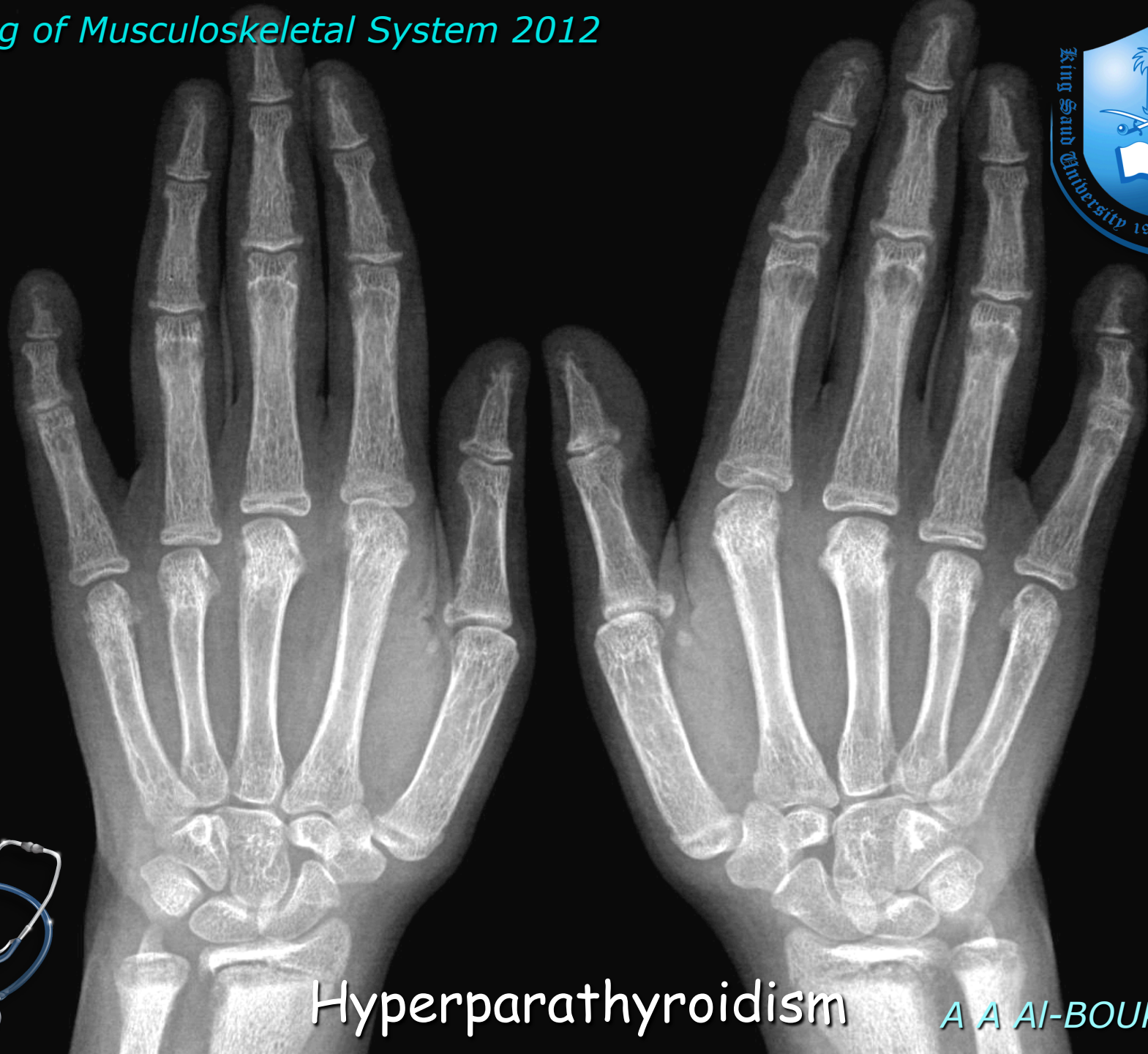
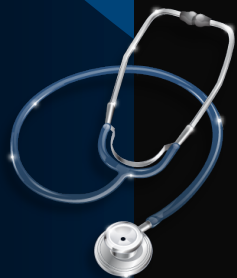Looser zones (OSTEOMALACIA)



HYPERPARATHYROIDISM

- ✓ Bone Resorption
- ✓ Bone Softening
- ✓ Brown Tumors
- ✓ Osteosclerosis
- ✓ Soft tissue calcifications





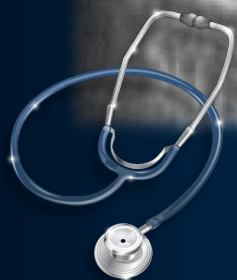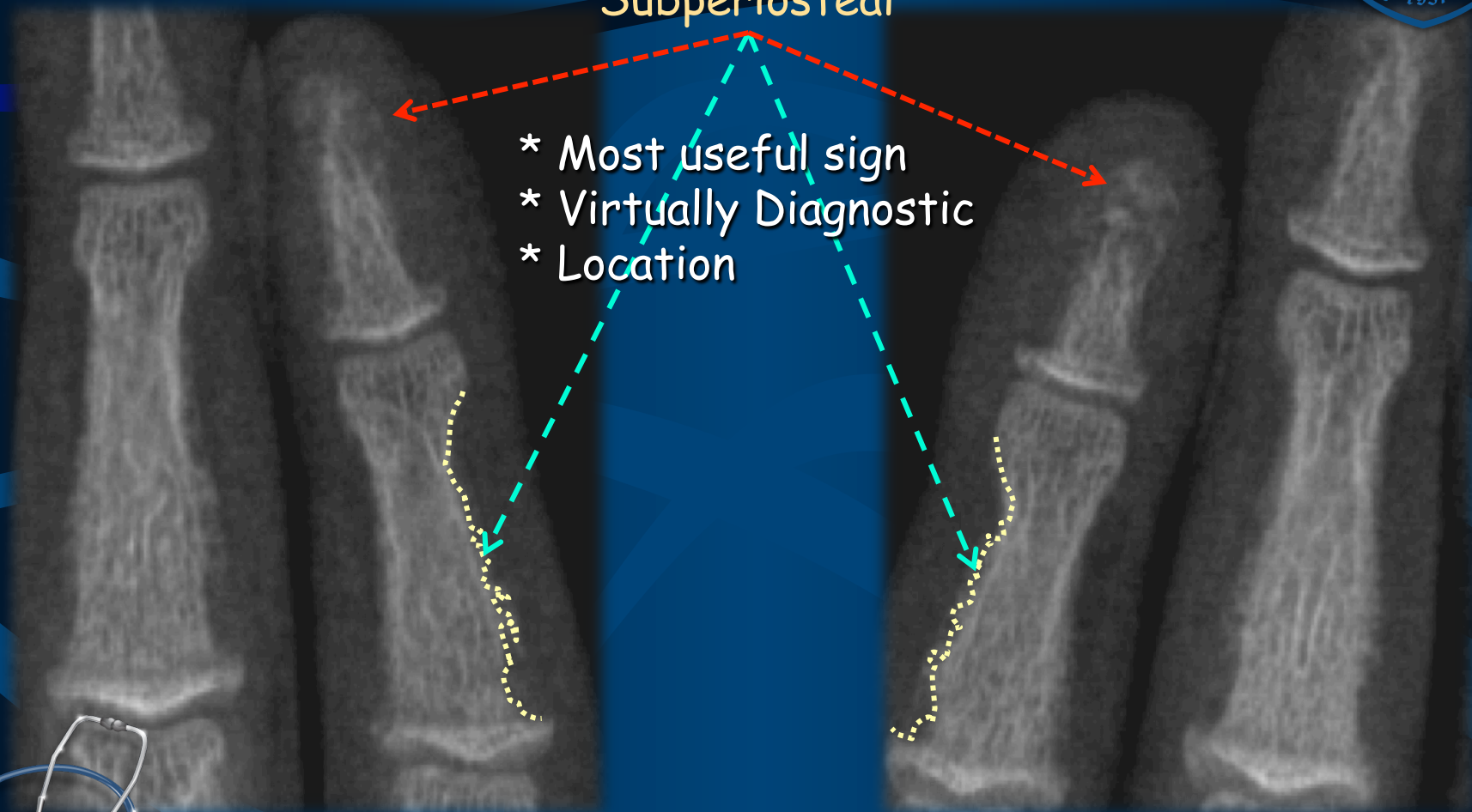
Hyperparathyroidism

A A AI-BOUKAI-13

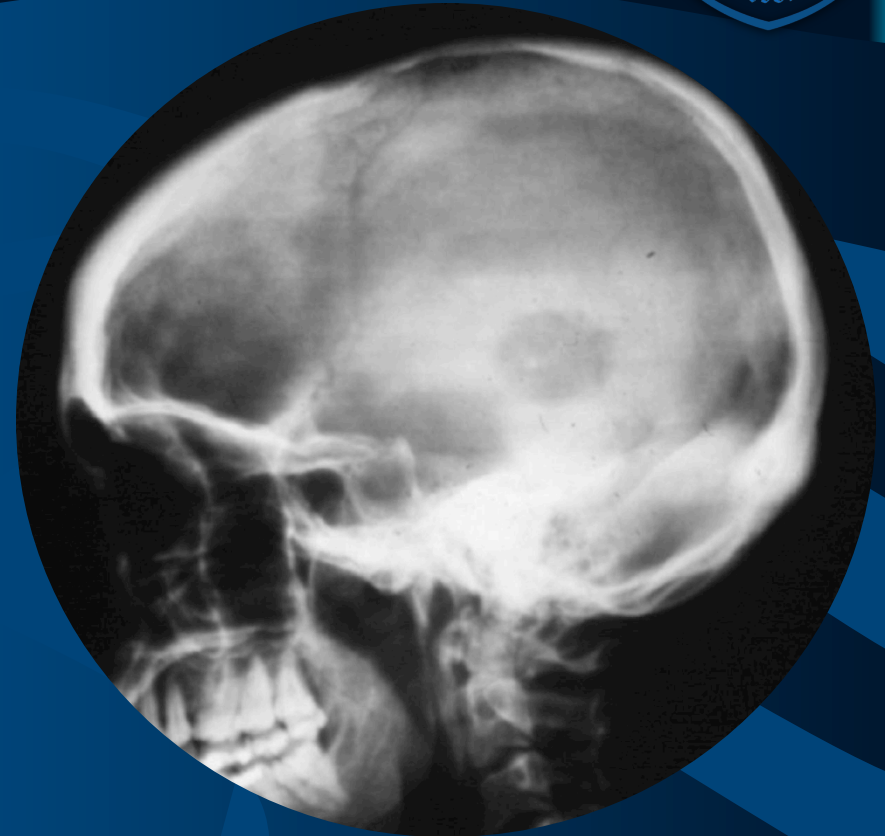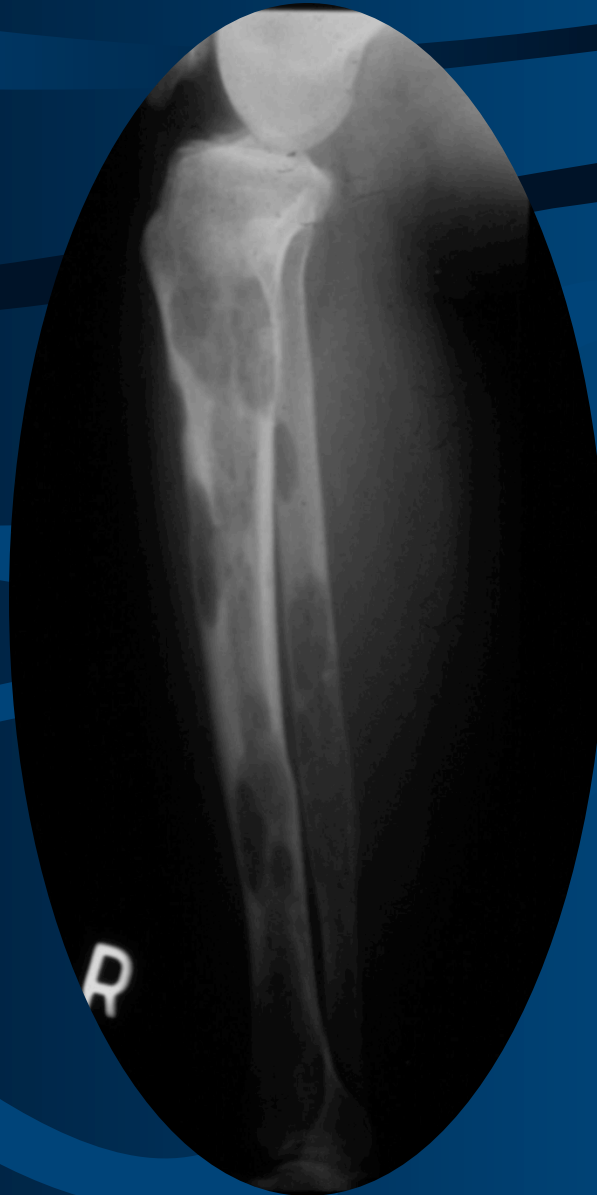
Bone Resorption

Subperiosteal

- * Most useful sign
- * Virtually Diagnostic
- * Location



Hyperparathyroidism



Brown Tumors

A A AI-BOUKAI-15



CASE NO. 3

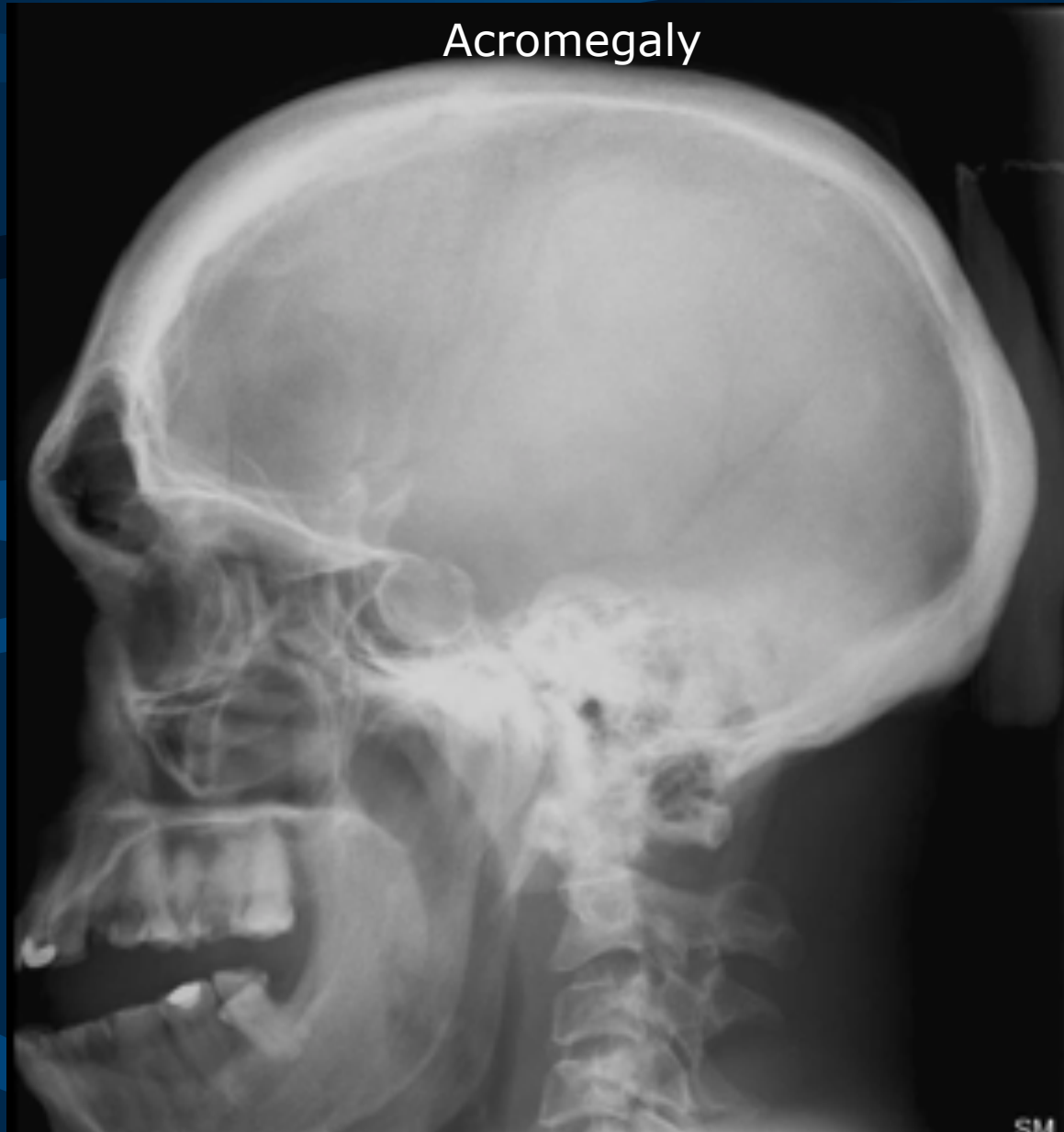45 years- old male presented with history of
bone enlargement

X-ray of skull and hand are requested

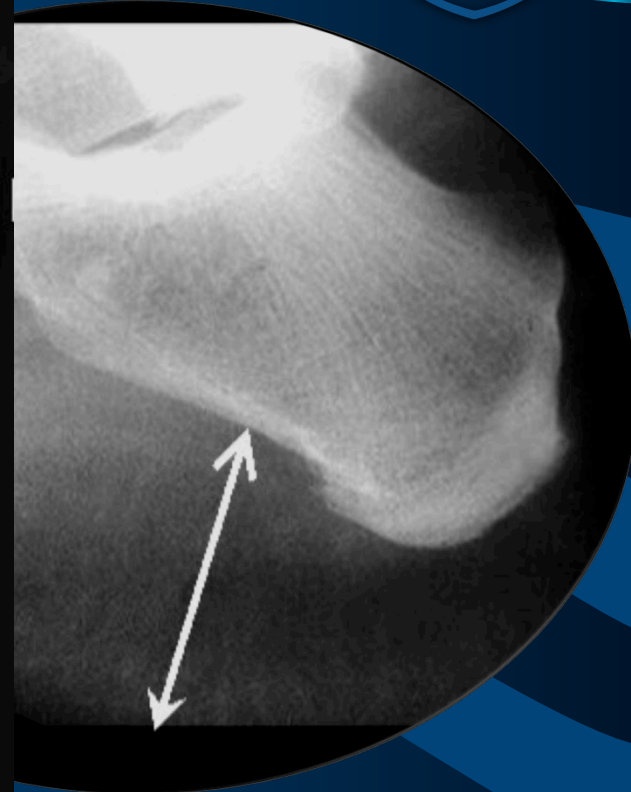
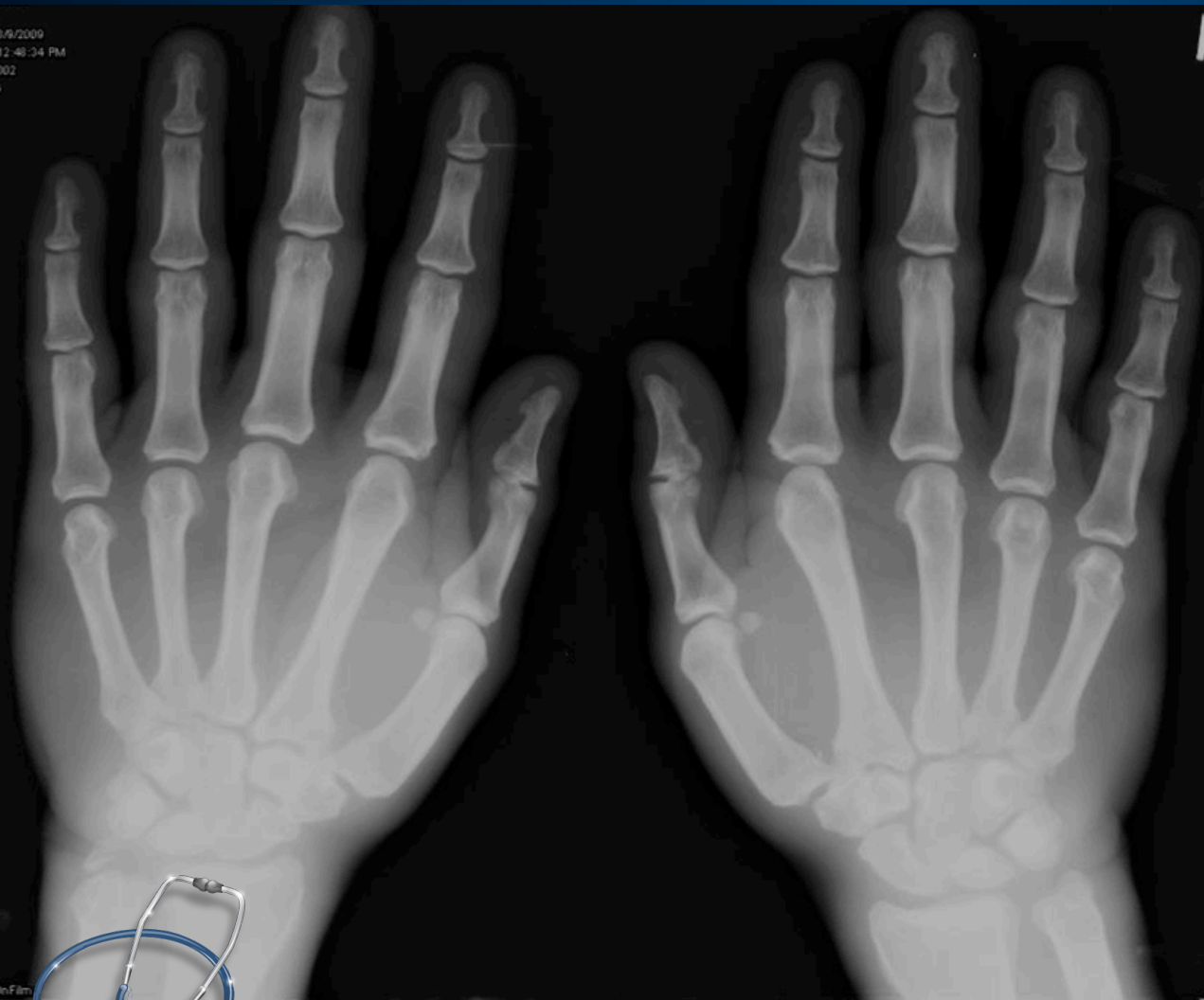


Acromegaly



Acromegaly





ARTHRITIS

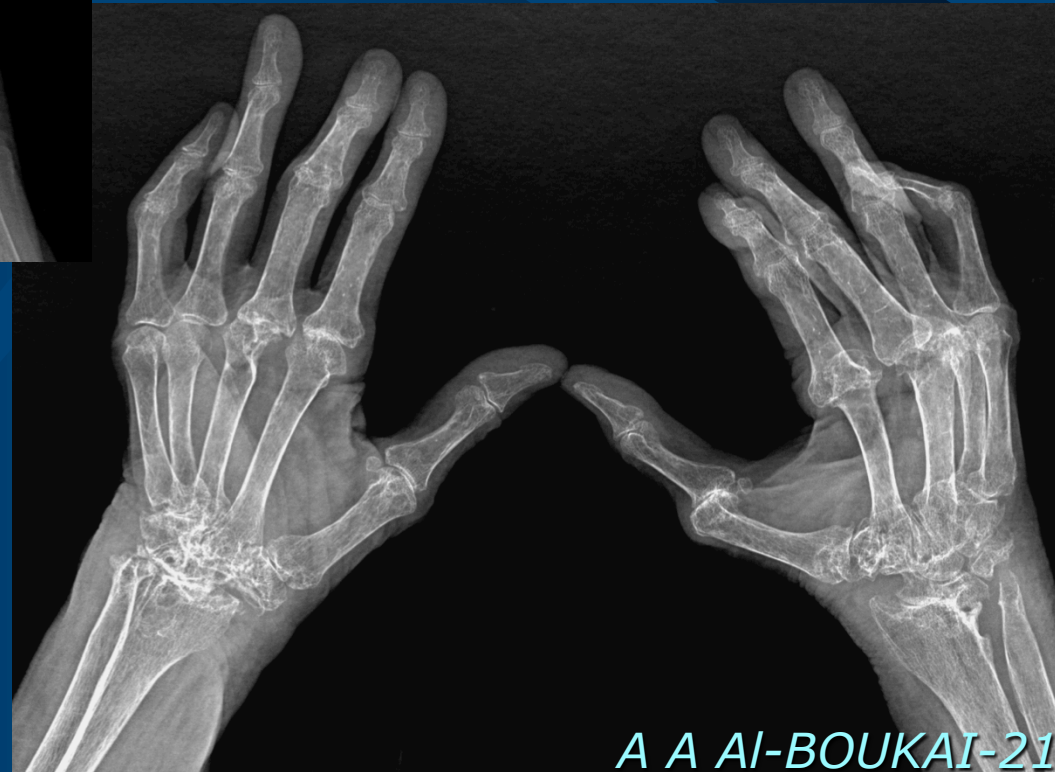
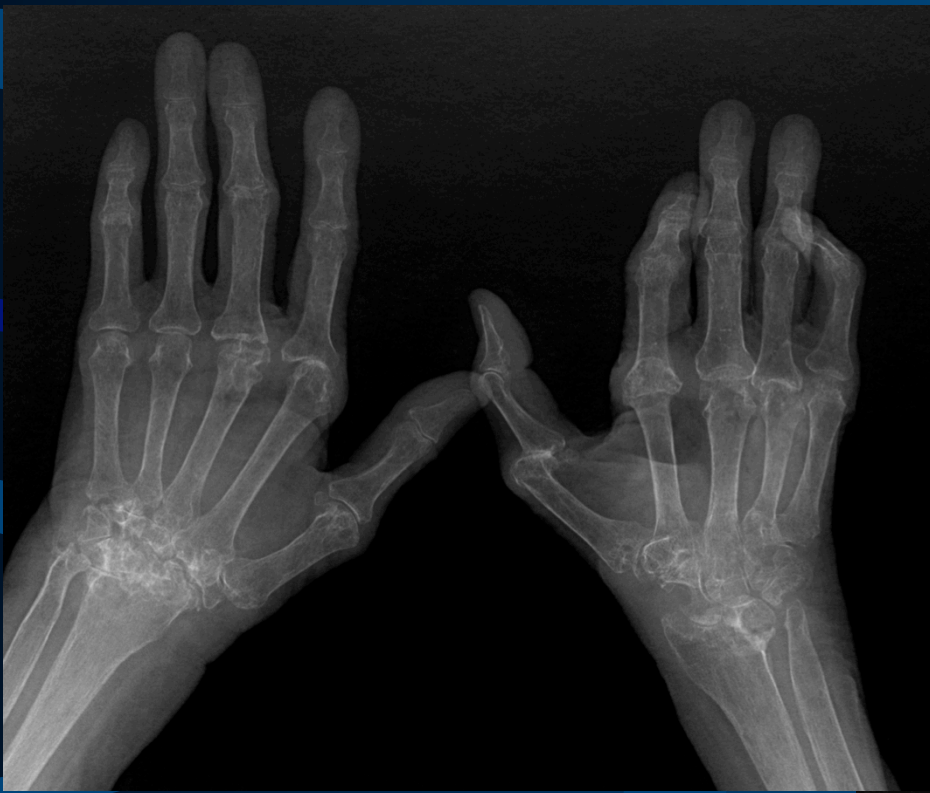


CASE NO. 4

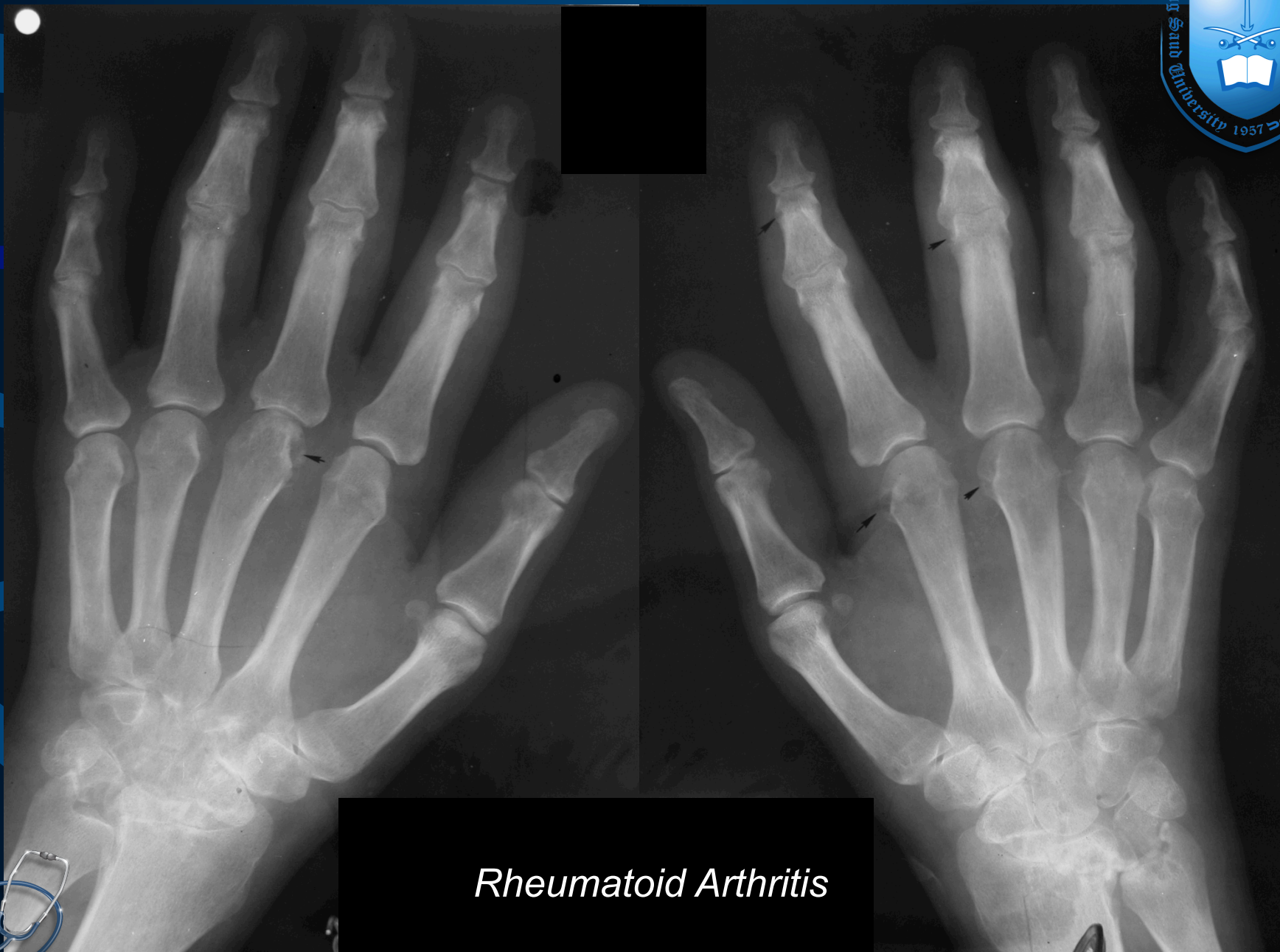48 years- old female presented with joint
pain of the hands & feet
X-ray of hand requested



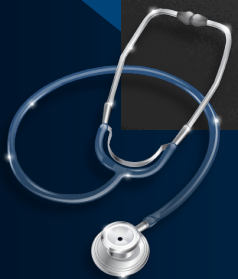
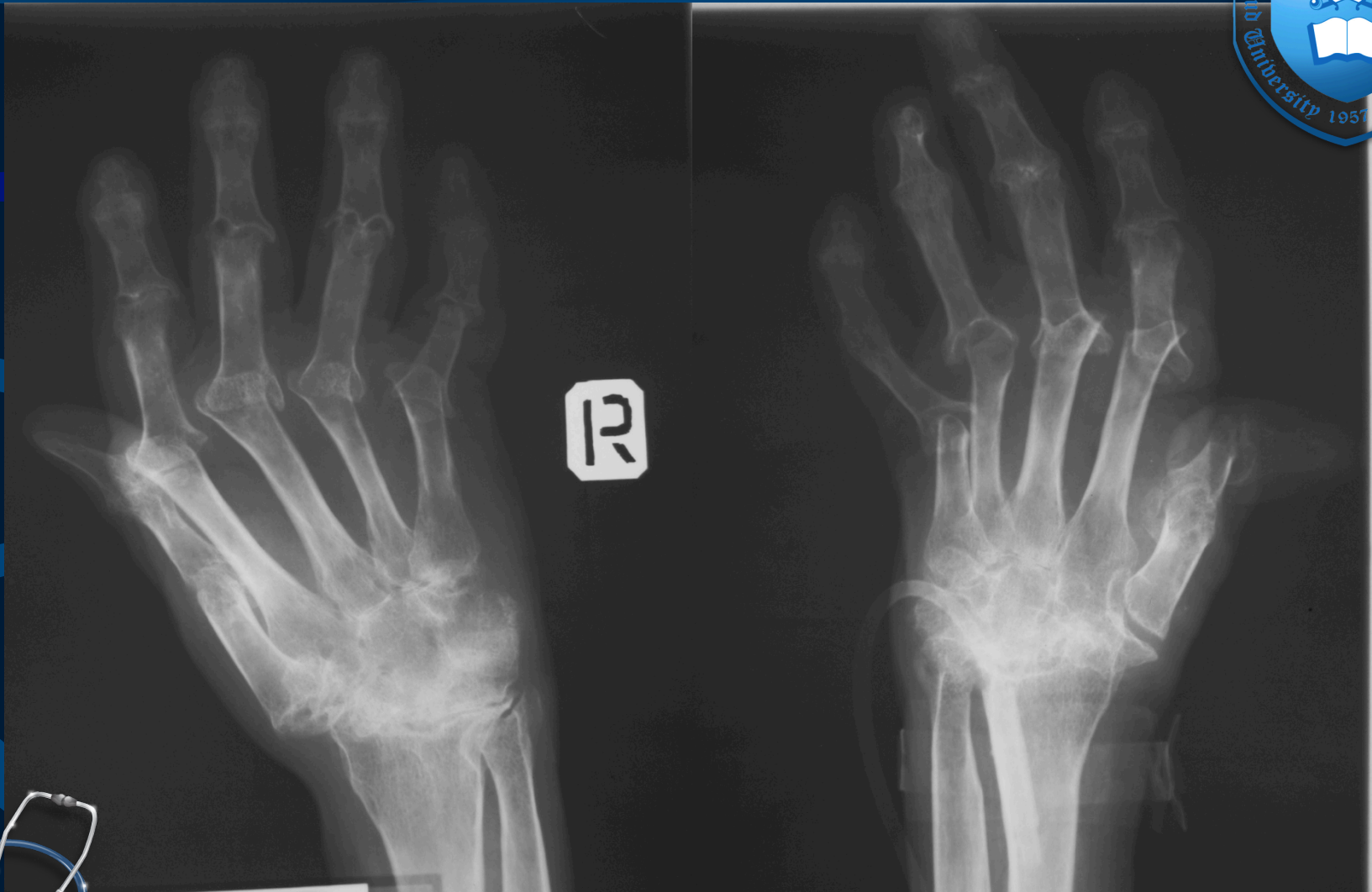
Rheumatoid Arthritis

A A AI-BOUKAI-21



Rheumatoid Arthritis



Rheumatoid Arthritis

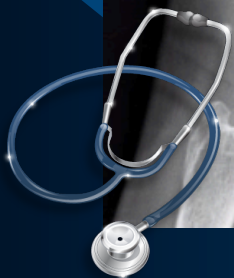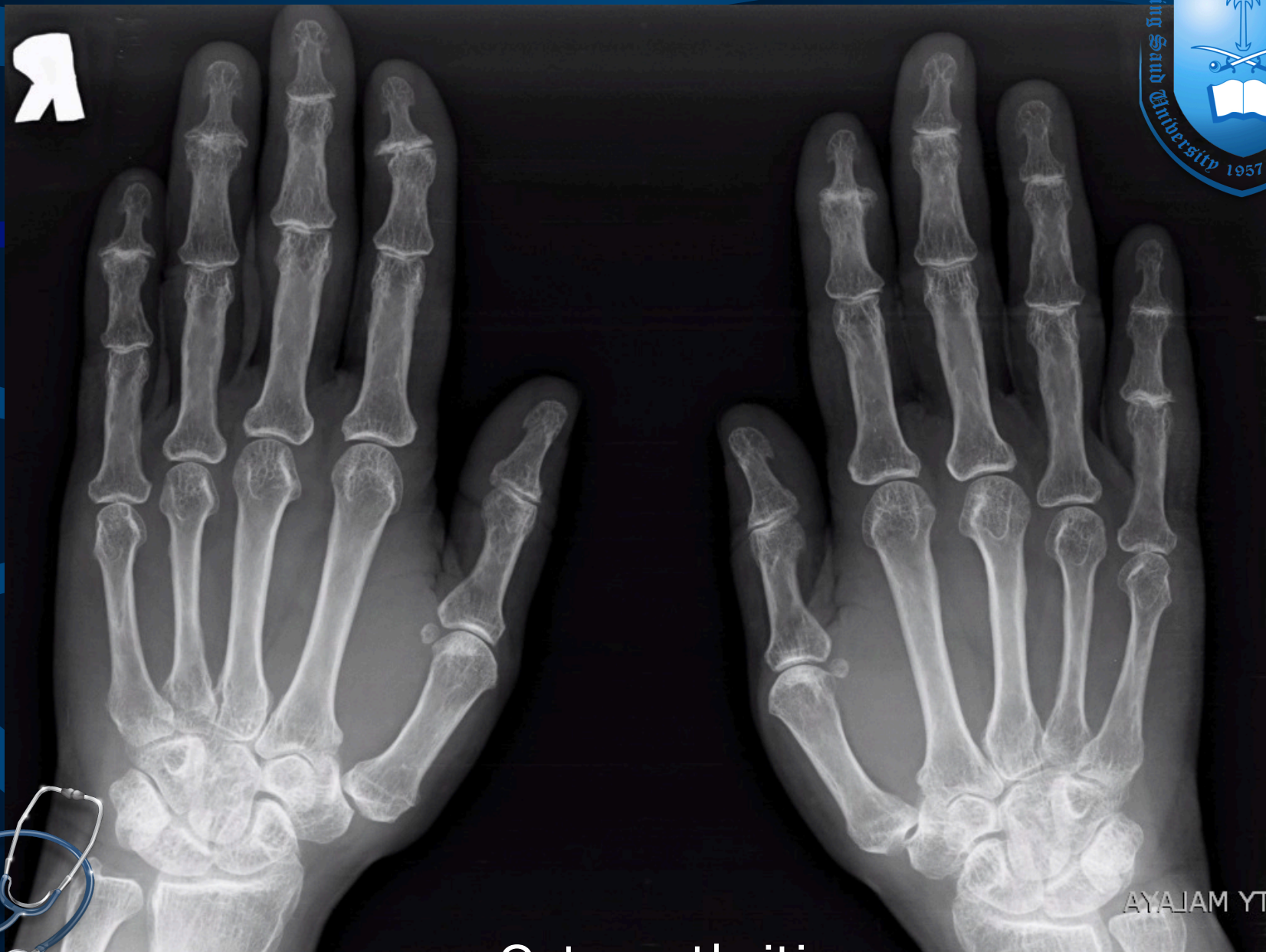A A AI-BOUKAI-23



CASE NO. 5

Elderly male patient presented with joint pain
of the hands X-ray of hand requested

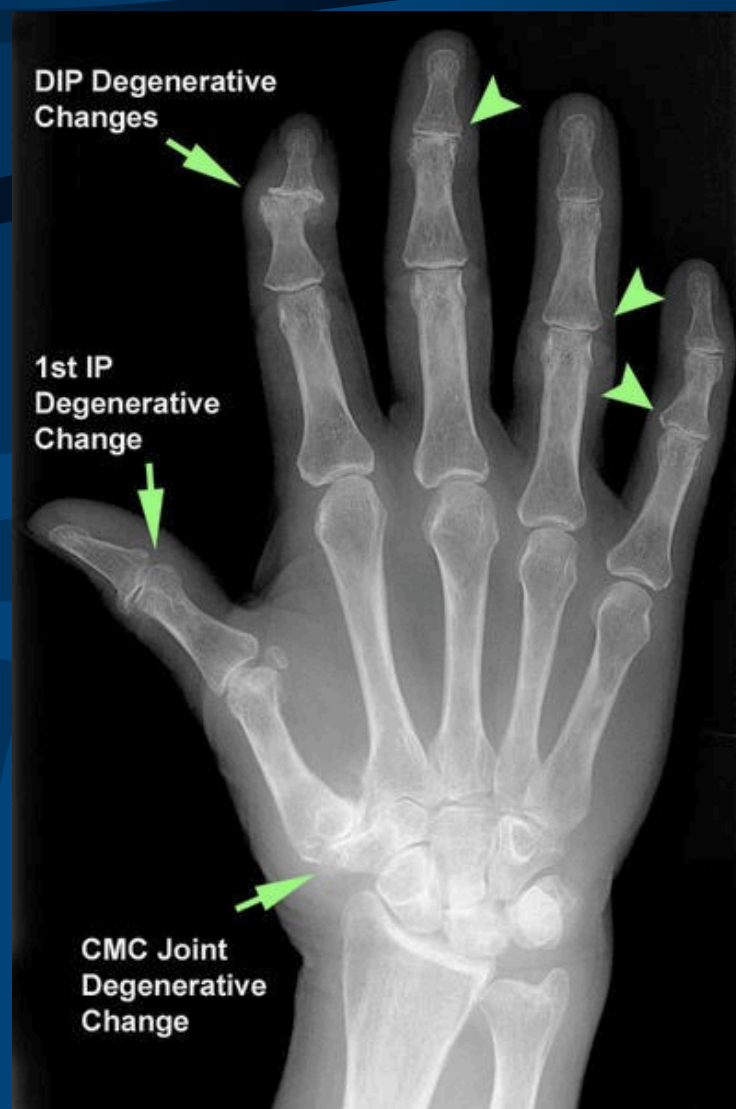



Osteoarthritis

AYAJAM YT

A A Al-BOUKAI-25



Osteoarthritis

A A AI-BOUKAI-26

Se: /3
Im: 1/1

HAND
SUPINE

Mag: 0.4x
Lat: L

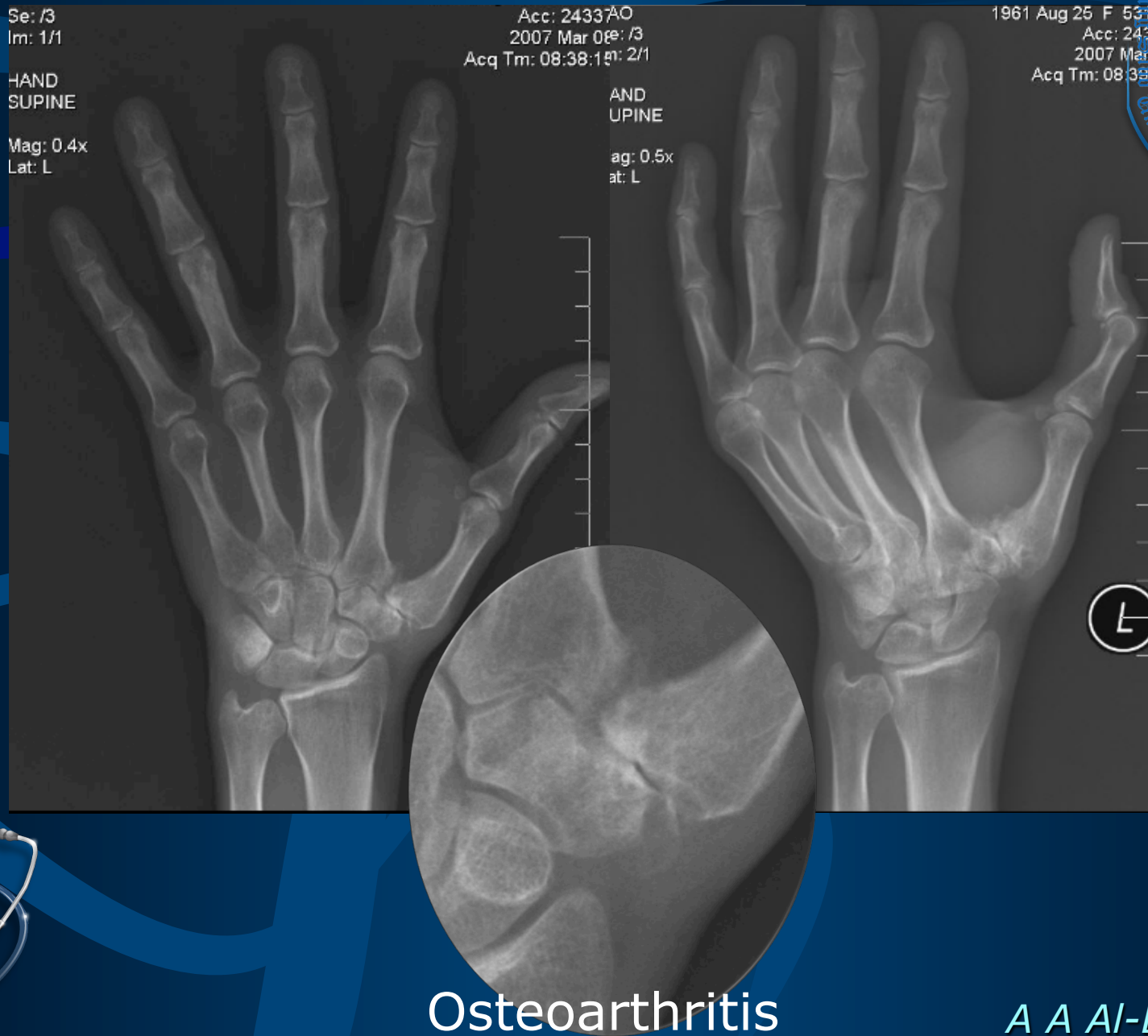Acc: 24337AO
2007 Mar 08: /3
Acq Tm: 08:38:15: 2/1

AND
UPINE

Mag: 0.5x
Lat: L

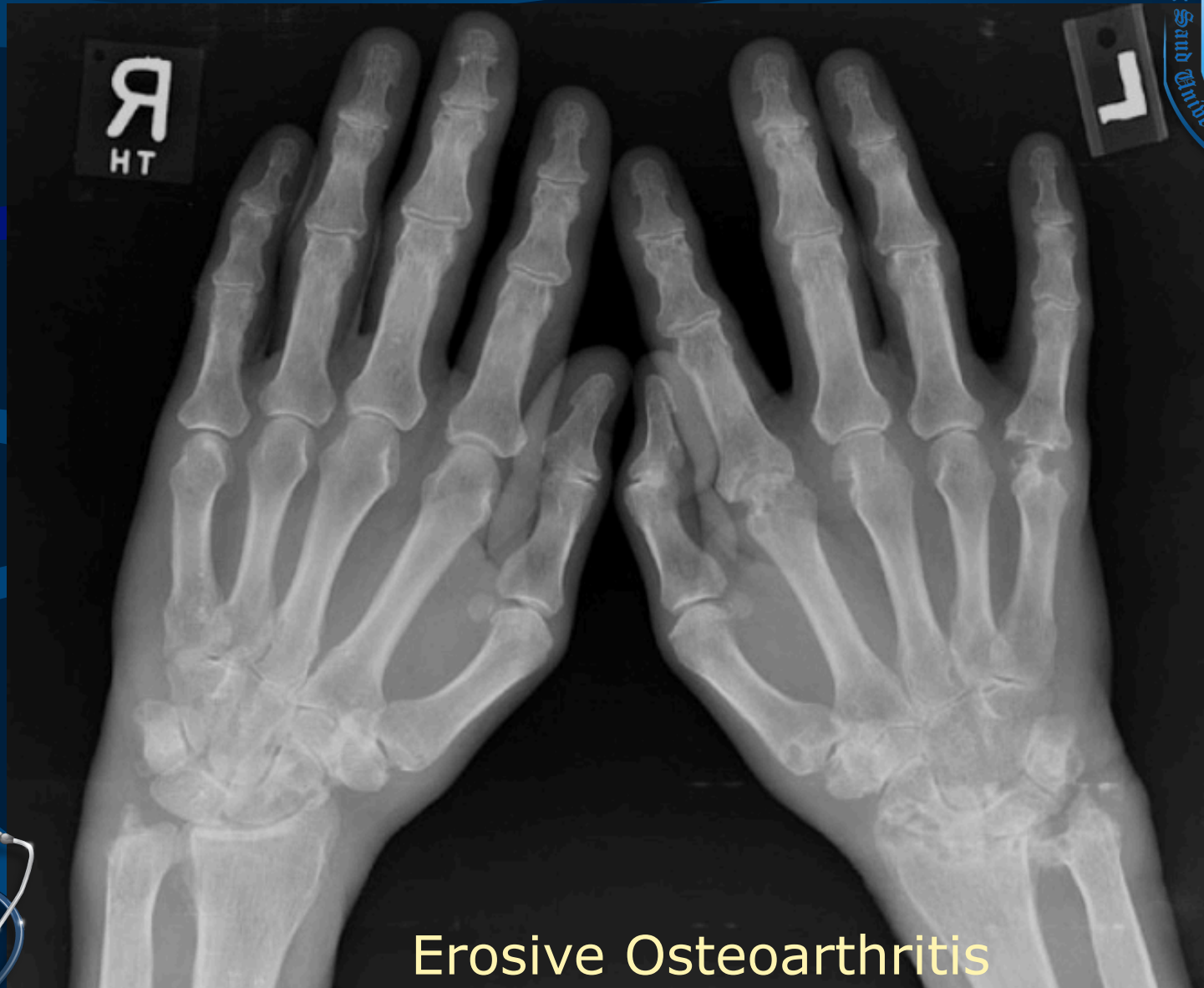1961 Aug 25 F 53:1

Acc: 24337
2007 Mar 08: /3
Acq Tm: 08:39:15: 2/1

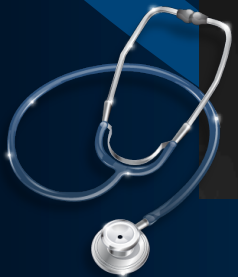

Osteoarthritis



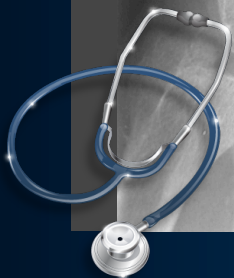

Erosive Osteoarthritis





RT



Psoriatic Arthritis

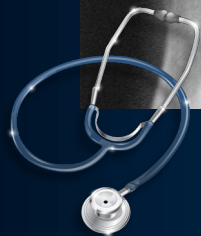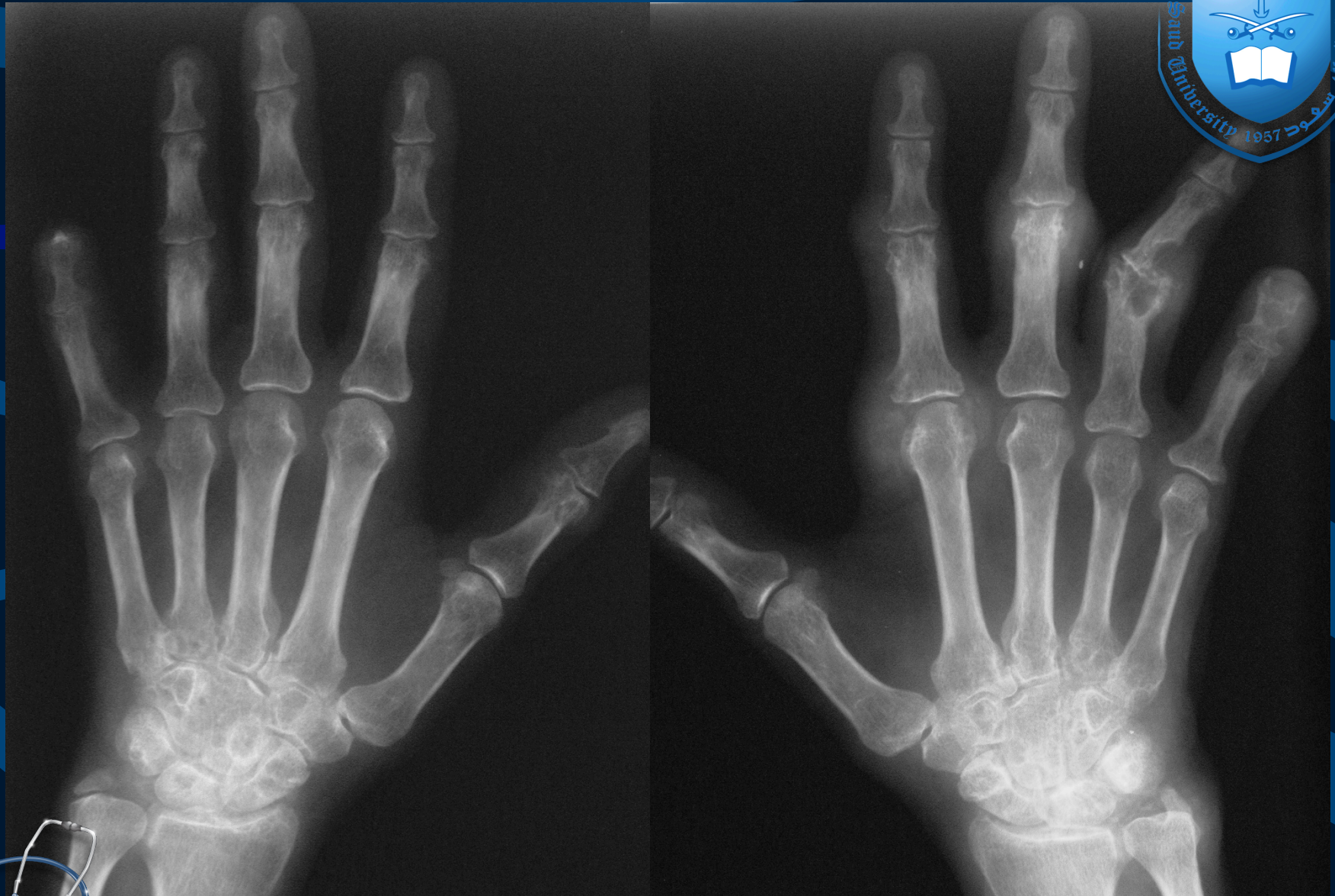A A Al-BOUKAI-29



CASE NO. 6

43 year-old male patient presented with
hands and feet pain and swelling
X-ray of hand requested





Gouty Arthritis

A A Al-BOUKAI-31



Musculoskeletal Tumors

- ✓ Osseous
- ✓ Chondral
- ✓ Fibrous
- ✓ Soft tissue





Musculoskeletal Tumors

KEY FEATURES

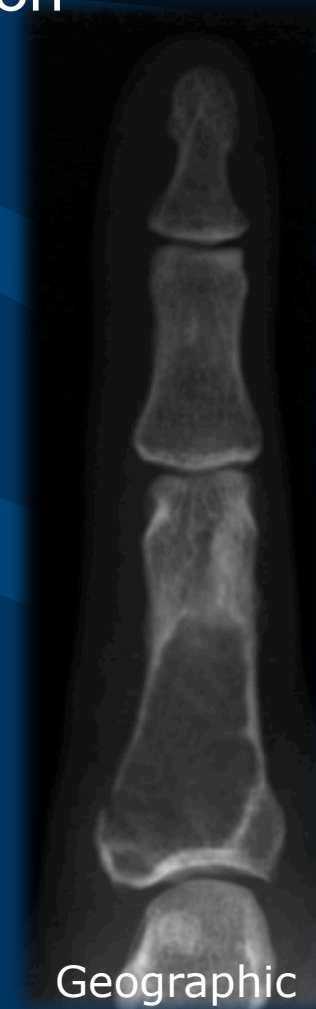
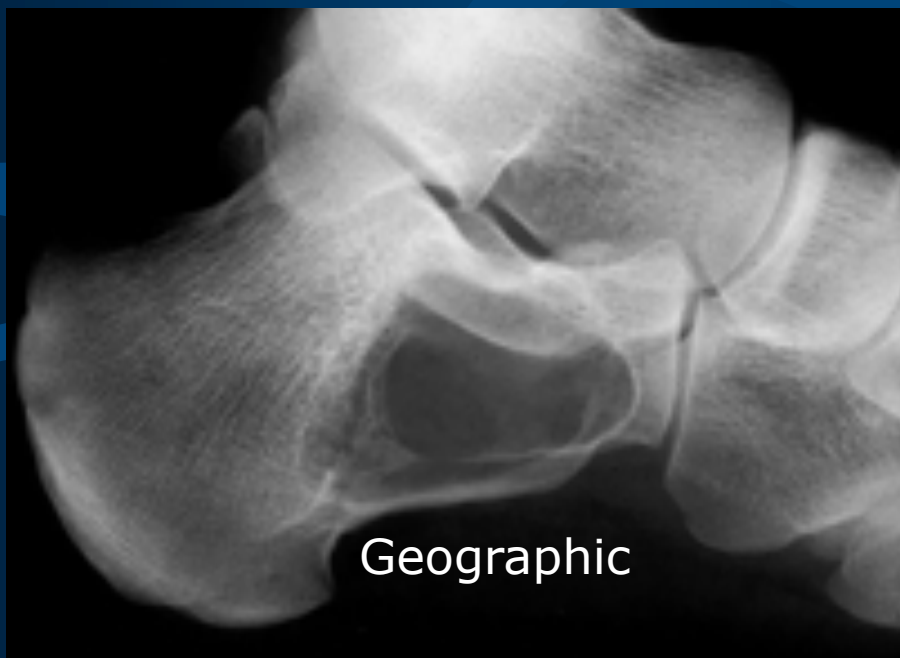- ✓ Morphology
- ✓ Behavior of lesion
- ✓ Age of patient
- ✓ Site (Location)

Pattern of bone destruction
Size, Shape & Margin of lesion
Texture of lesion Matrix
Cortex & Periosteal reaction



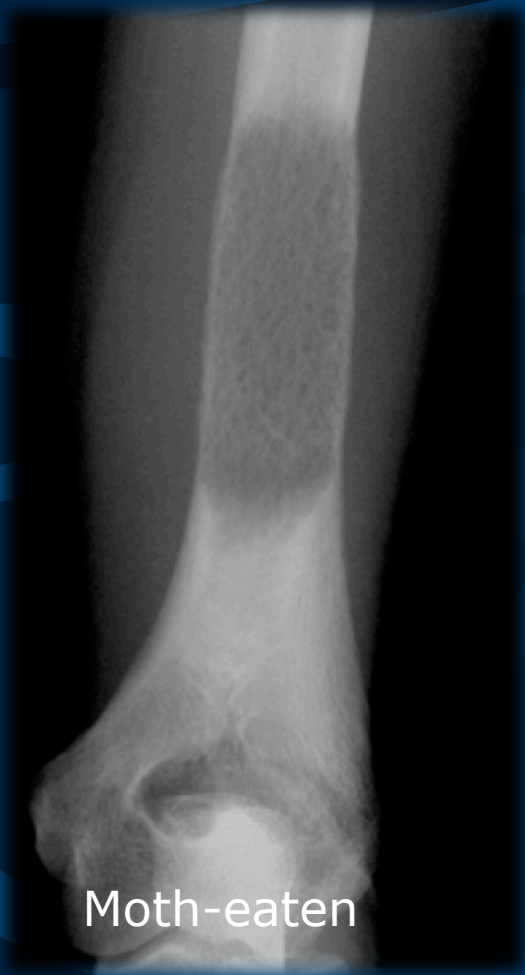Musculoskeletal Tumors

Pattern of bone destruction

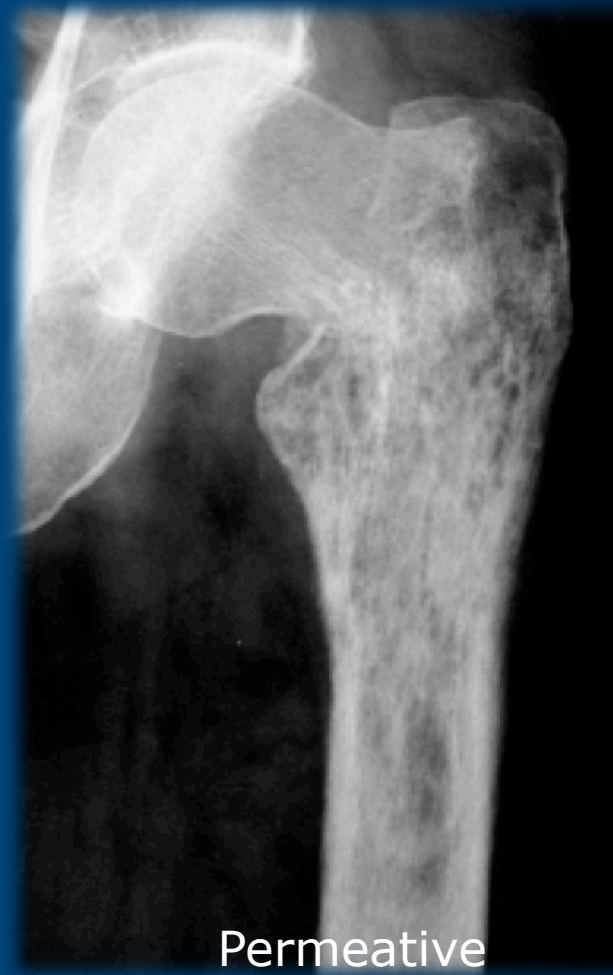

Musculoskeletal Tumors

Pattern of bone destruction



Moth-eaten

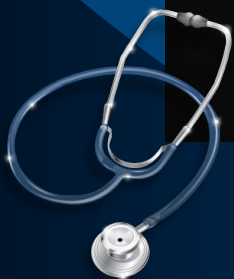
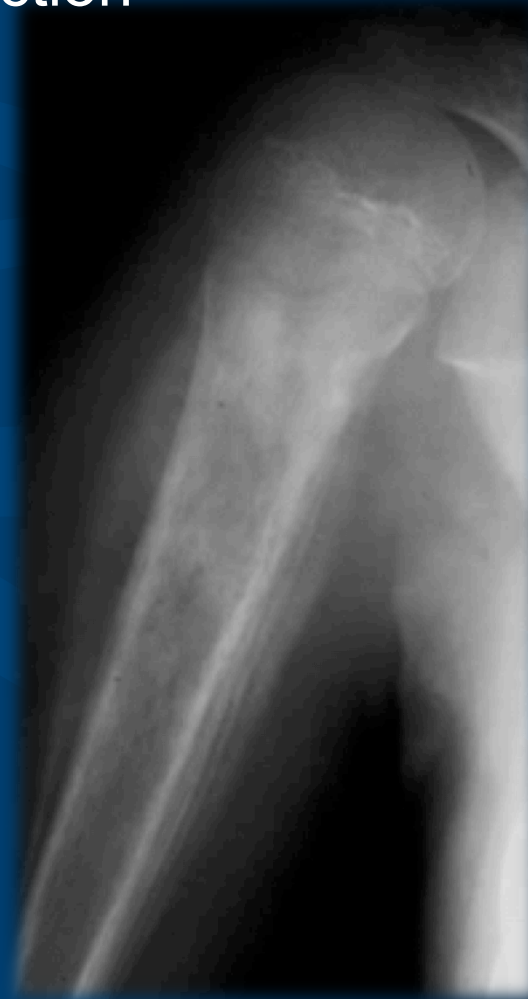
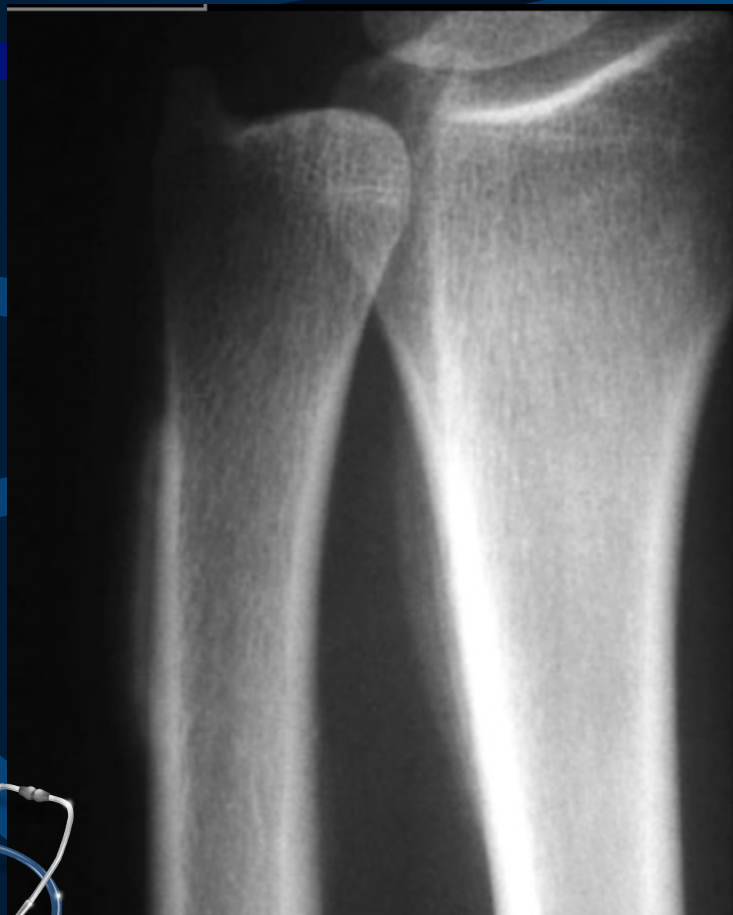Permeative



Musculoskeletal Tumors

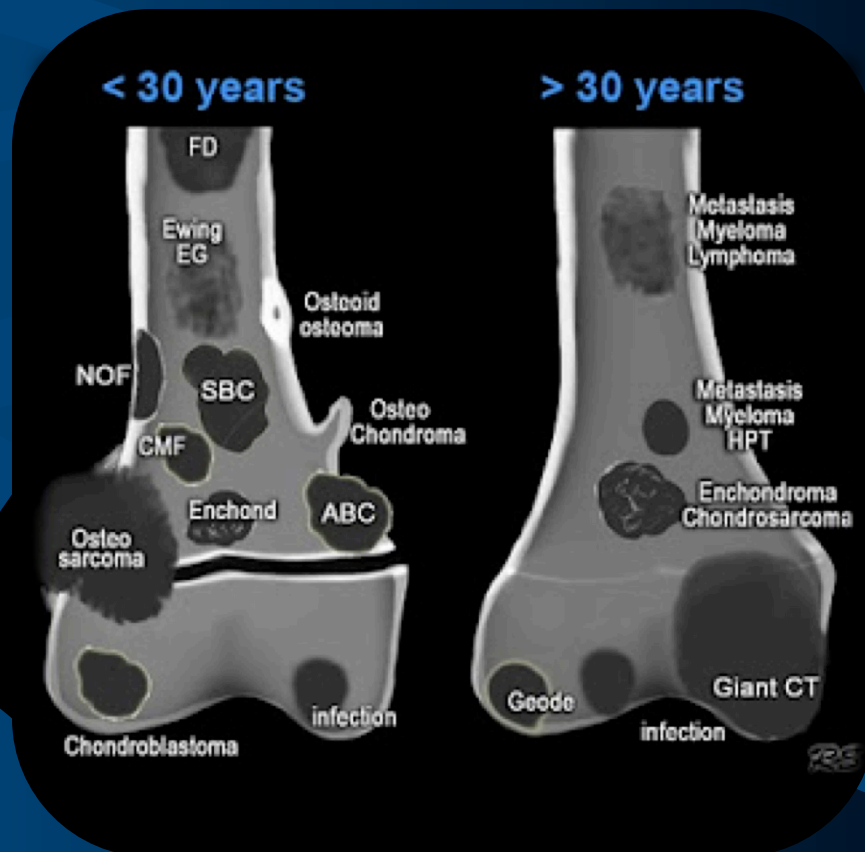Periosteal reaction



Musculoskeletal Tumors

KEY FEATURES

- ✓ Morphology
- ✓ Behavior of lesion
- ✓ Age of patient
- ✓ Site (Location)




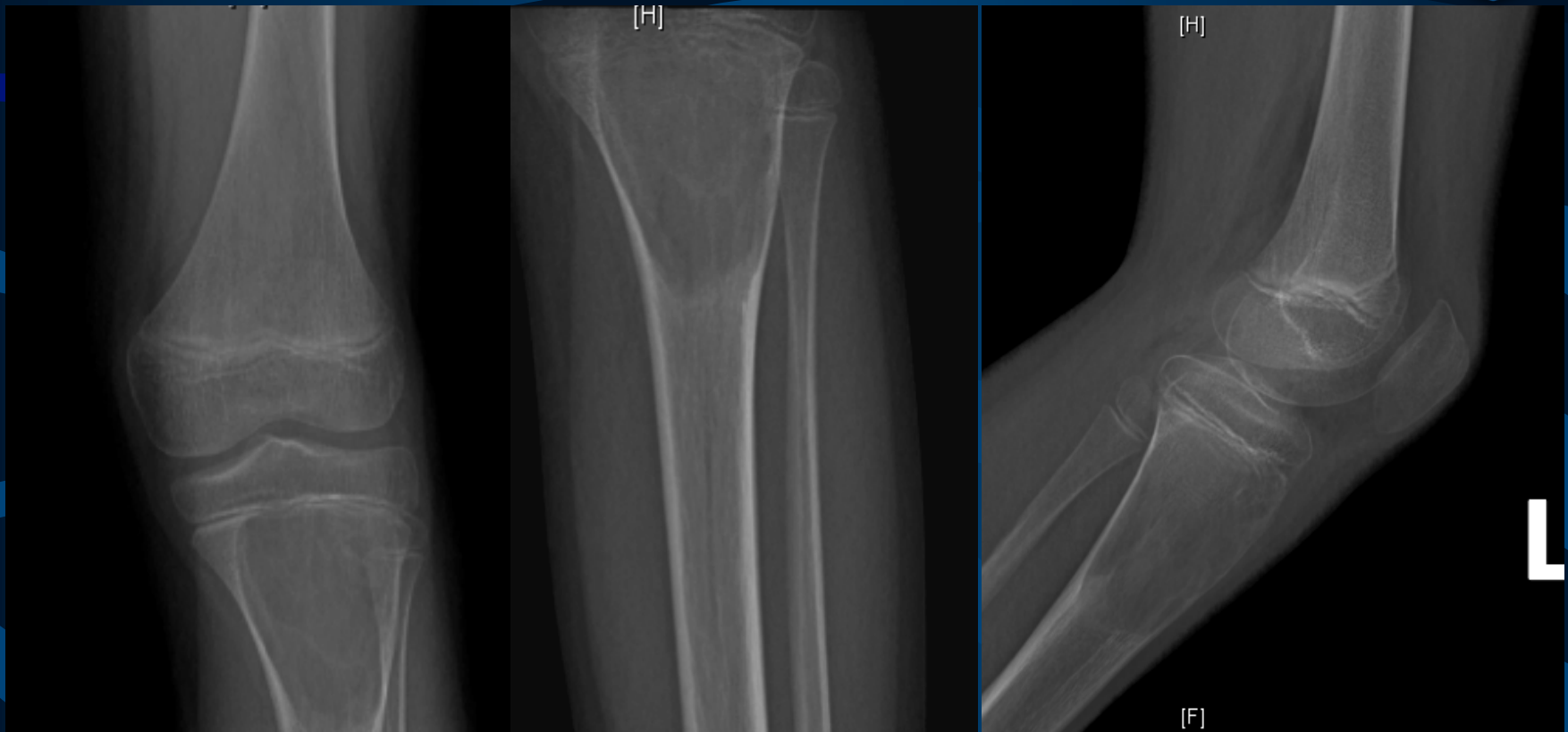
CASE NO. 7

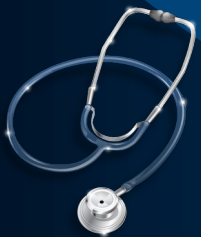13 year-old boy patient presented with knee
pain and swelling

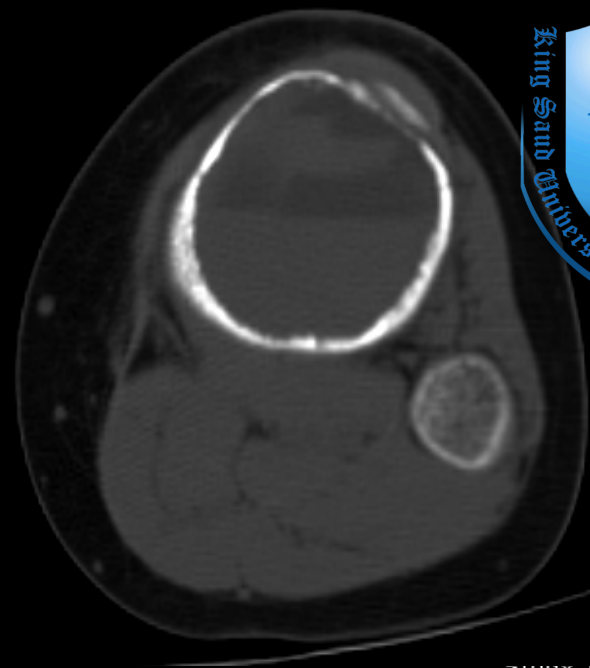
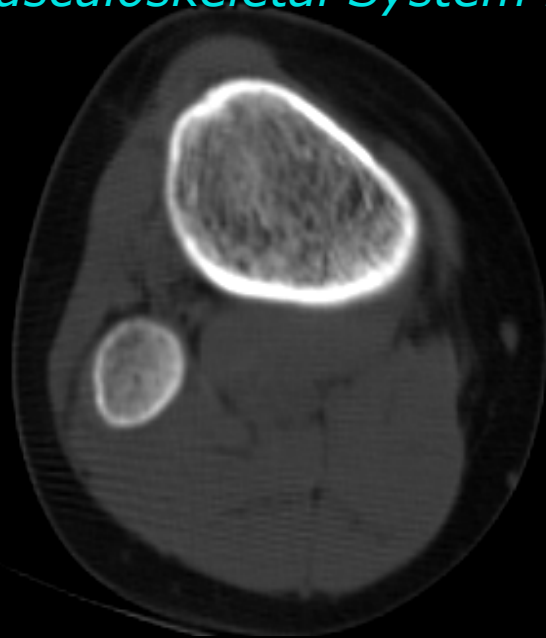
X-ray of knee requested



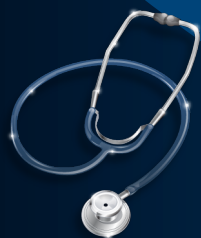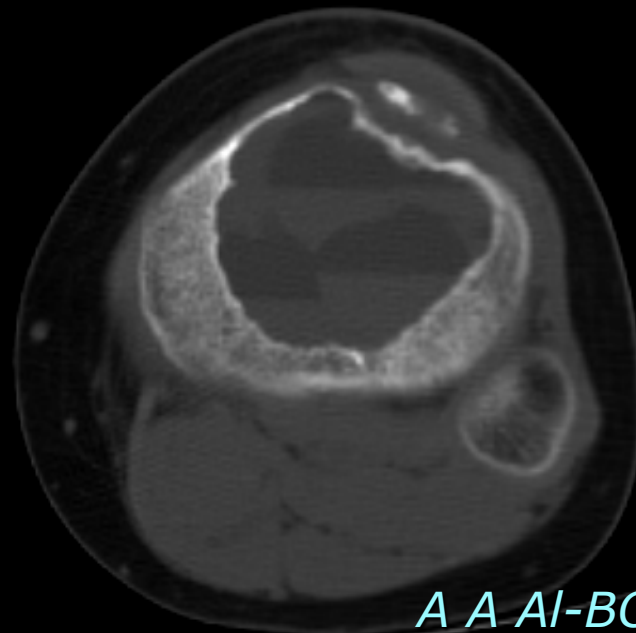
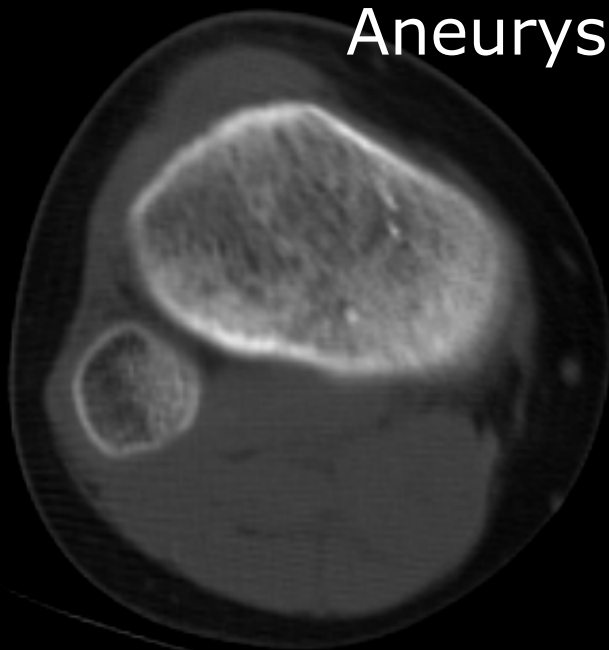


Aneurysmal Bone Cyst

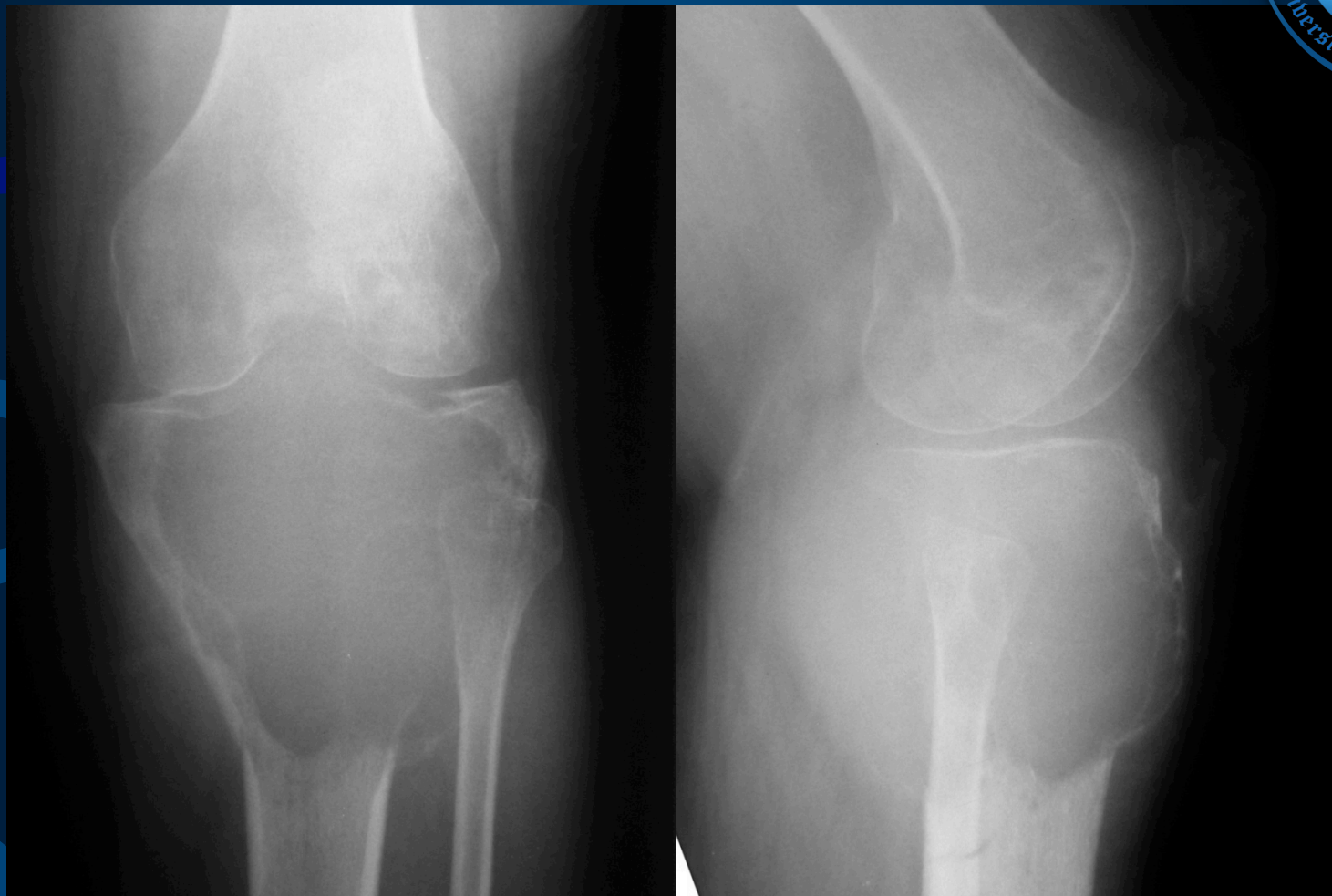



Aneurysmal Bone Cyst

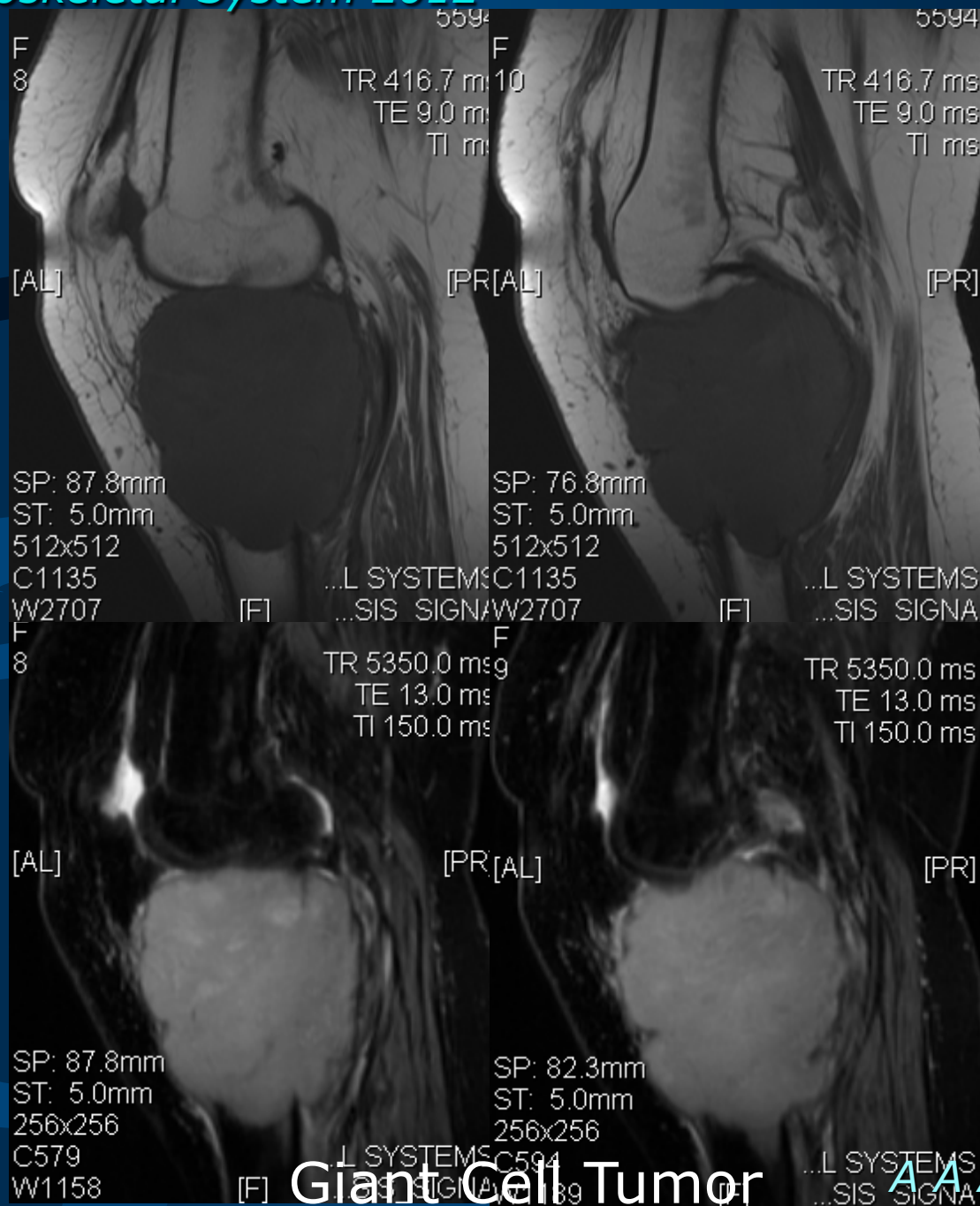


Adult Patient



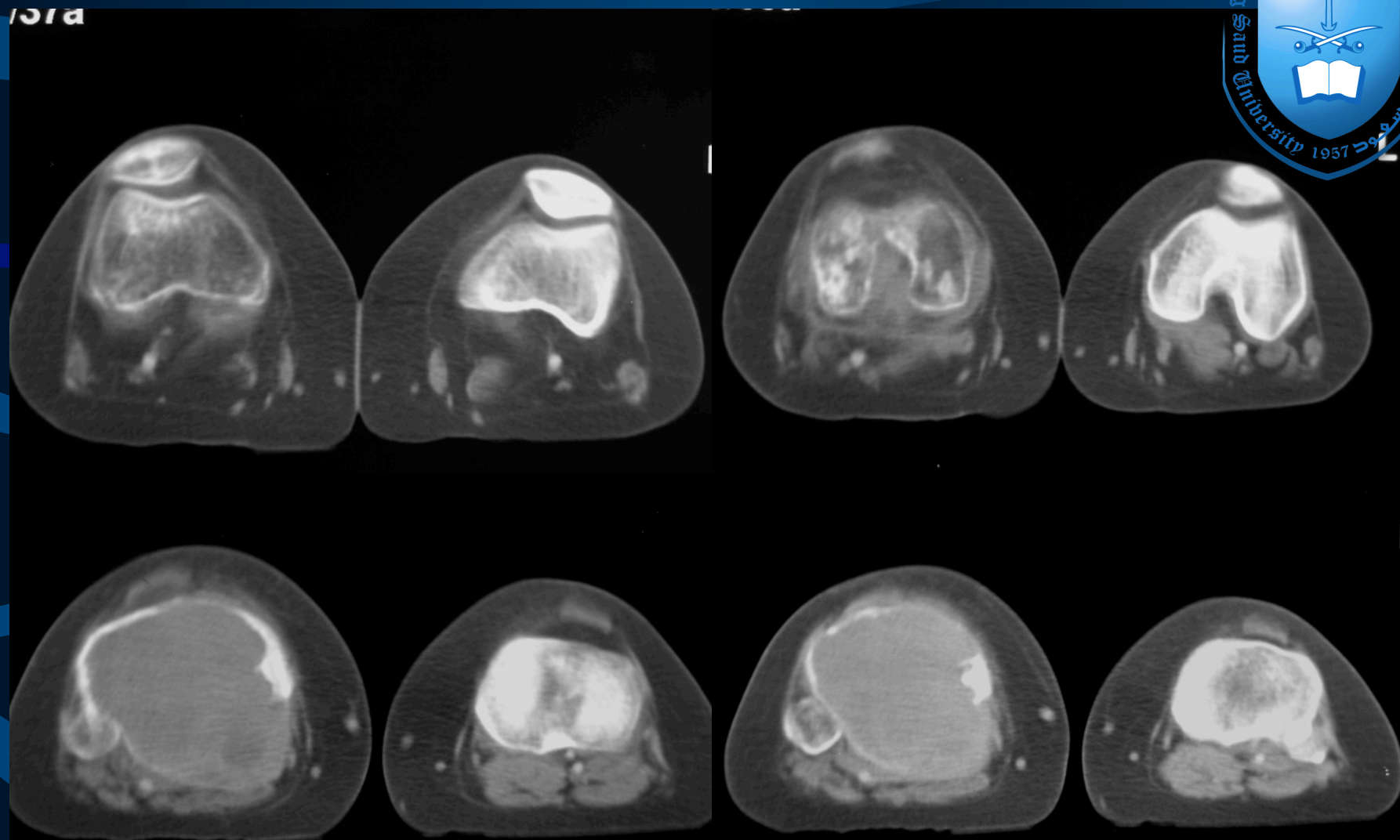
Giant Cell Tumor



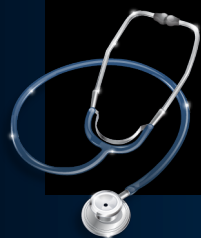

Giant Cell Tumor

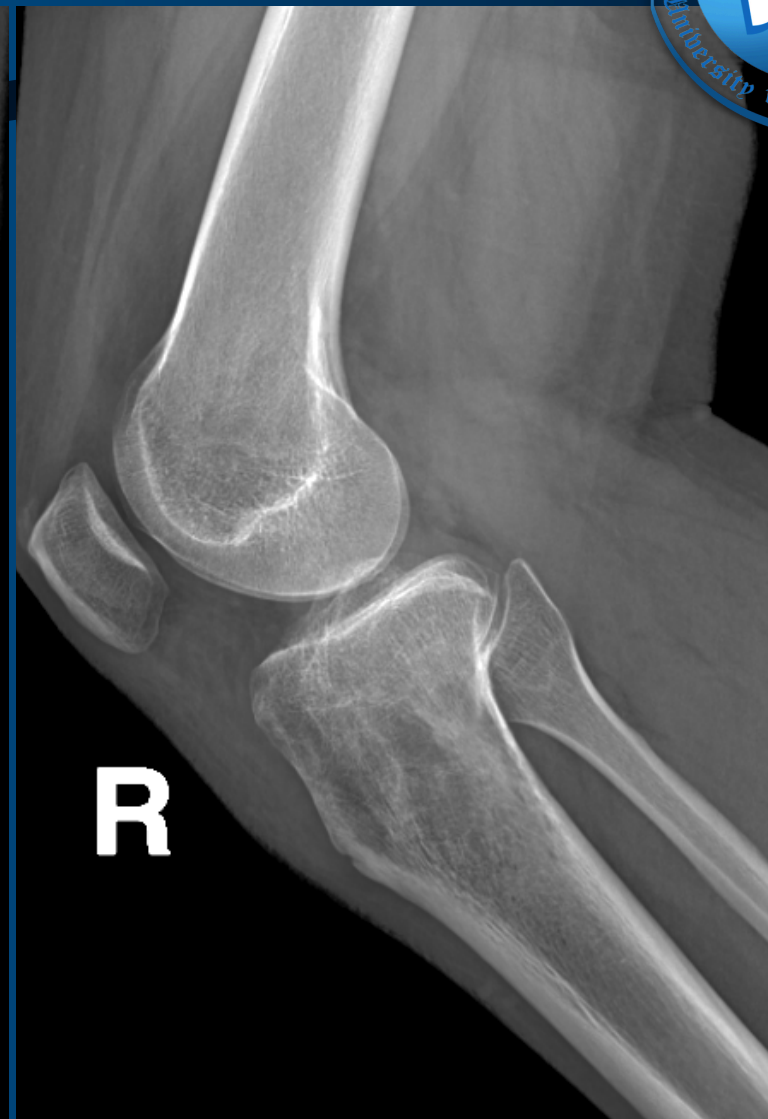
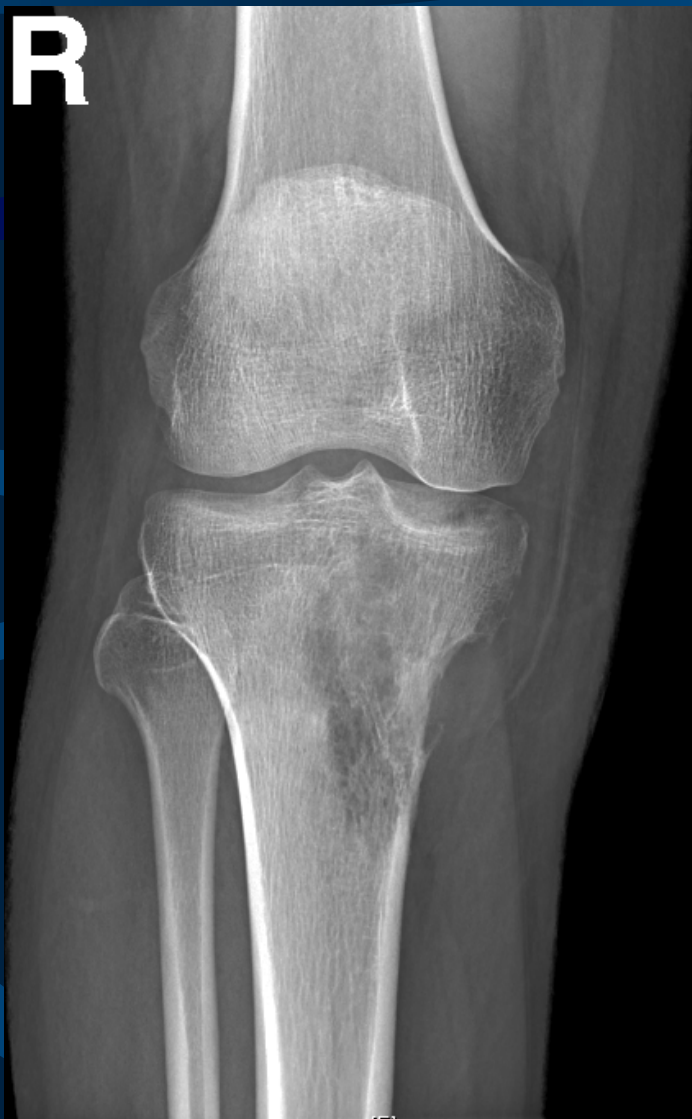


Giant Cell Tumor



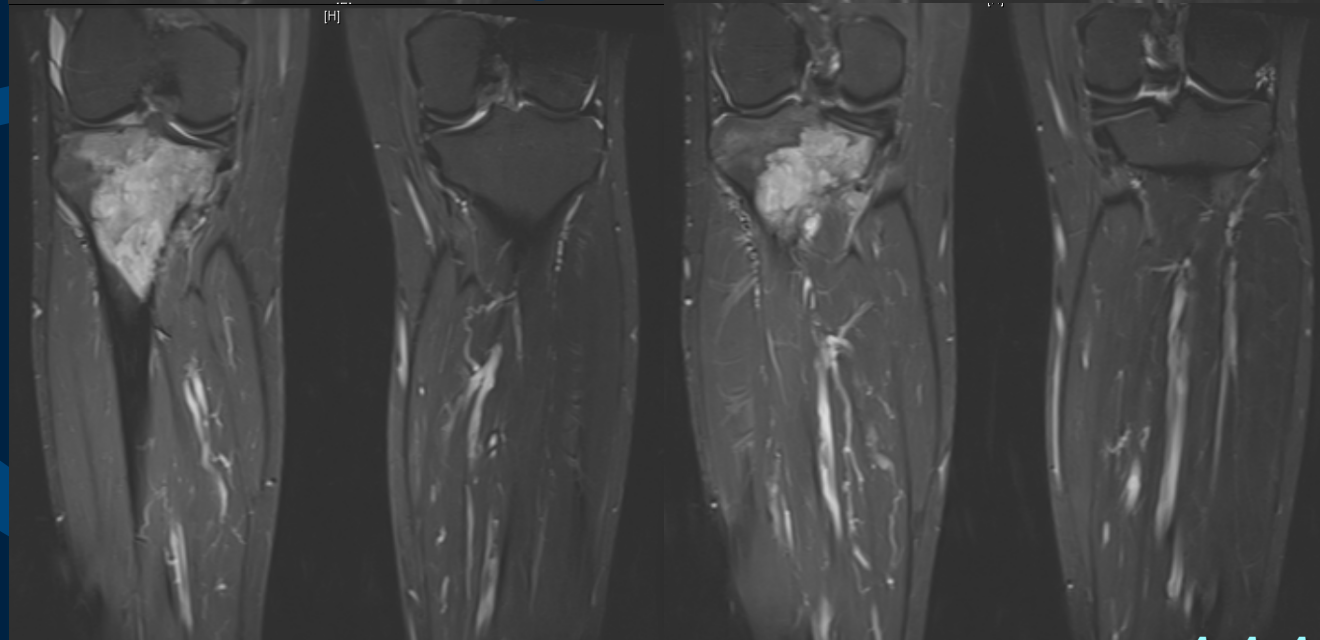
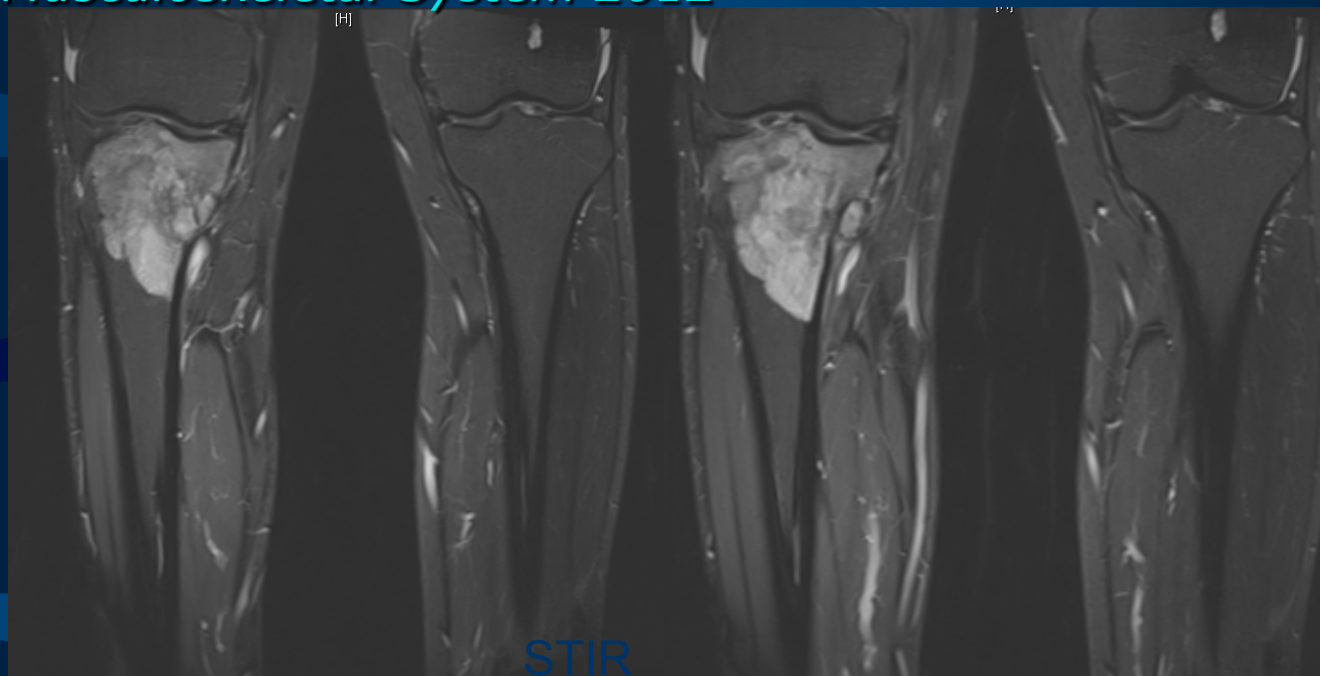
Permeative Pattern

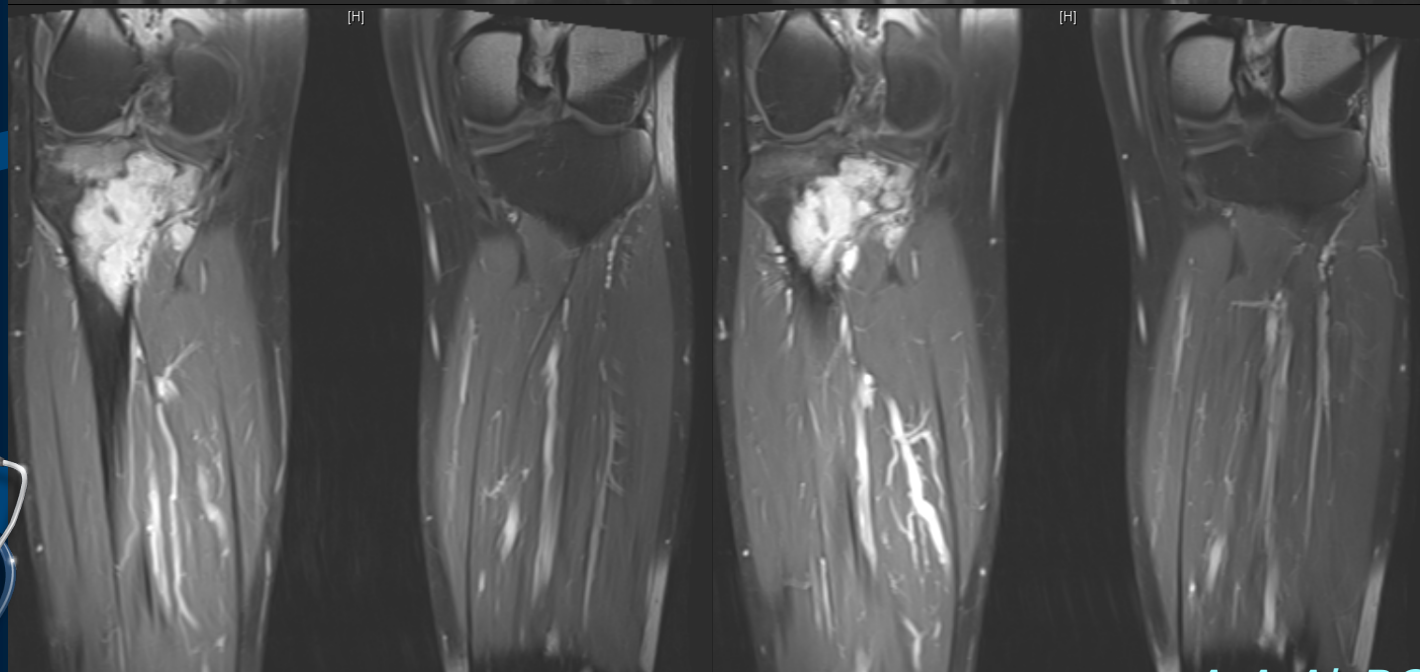
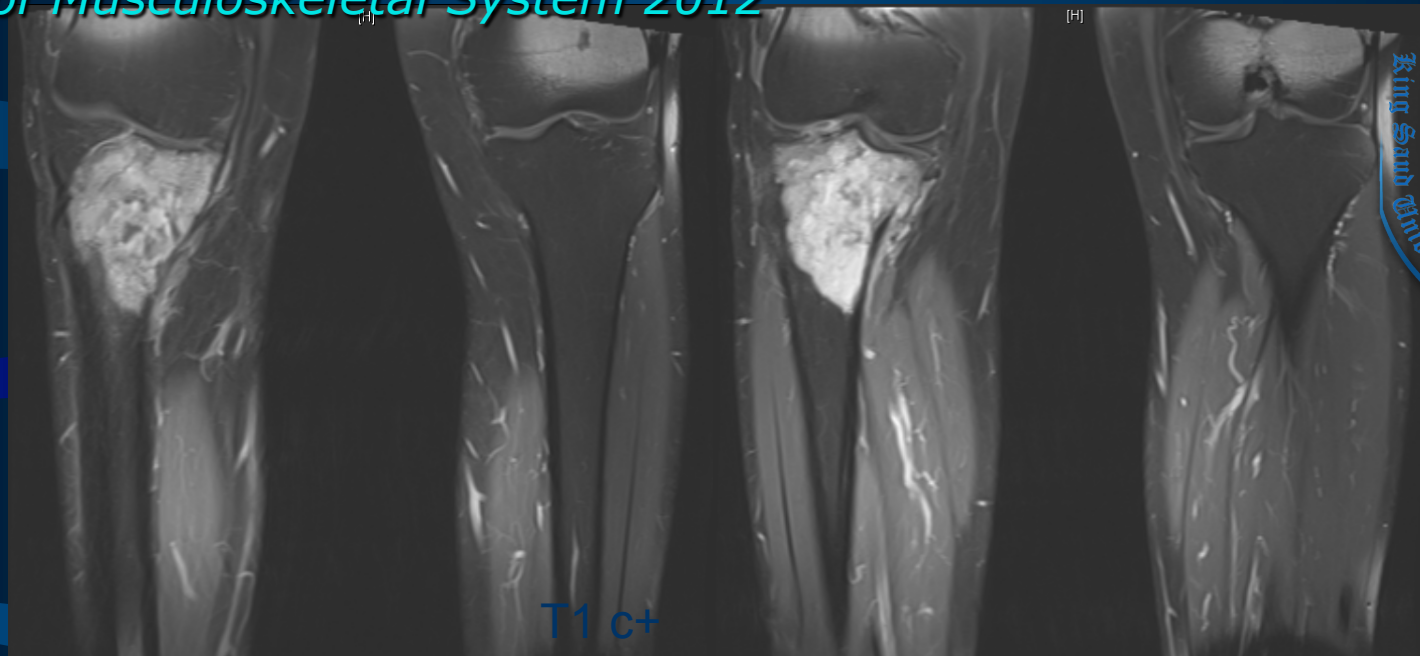

Osteosarcoma / Lymphoma

A A AI-BOUKAI-44






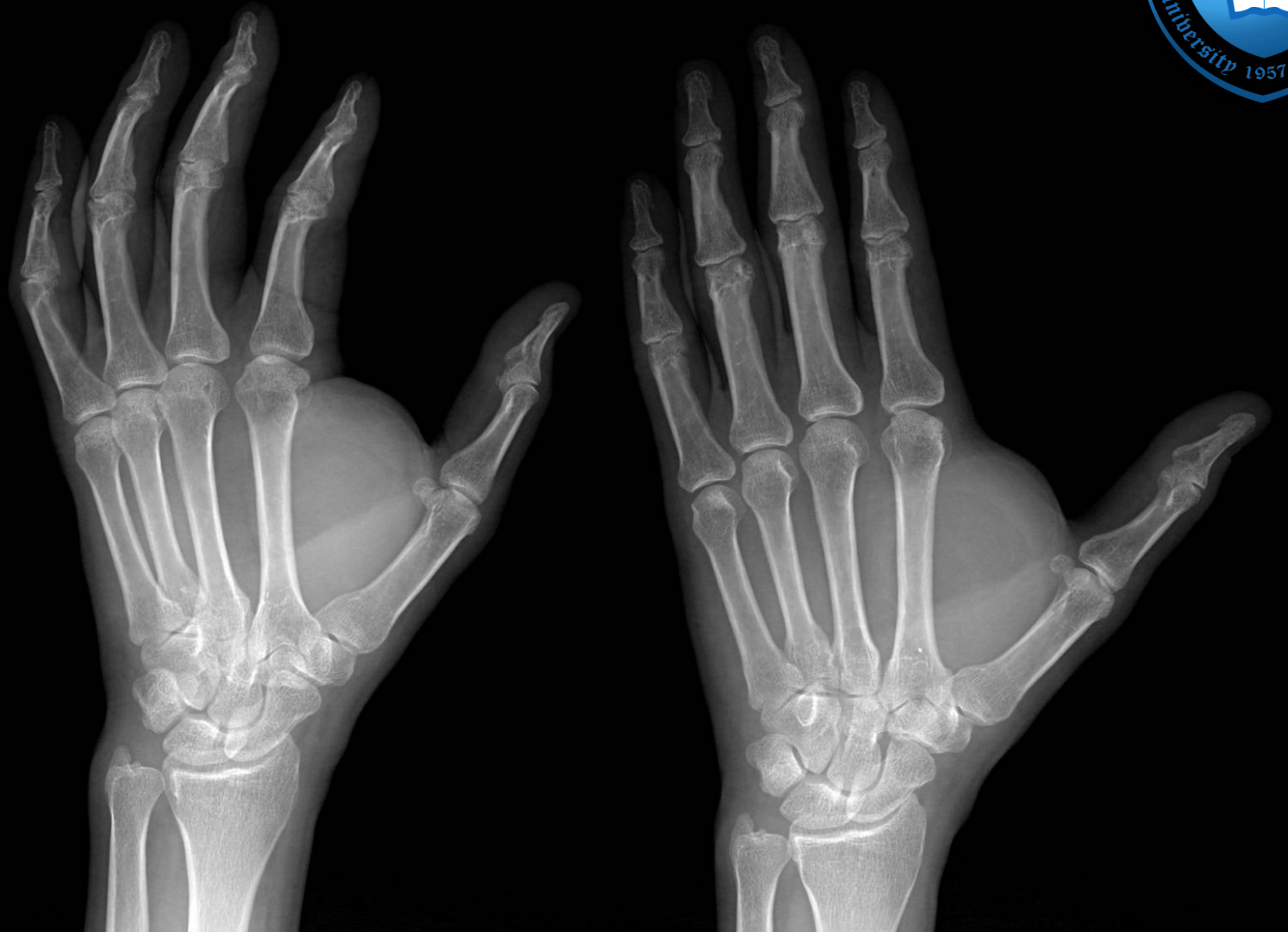


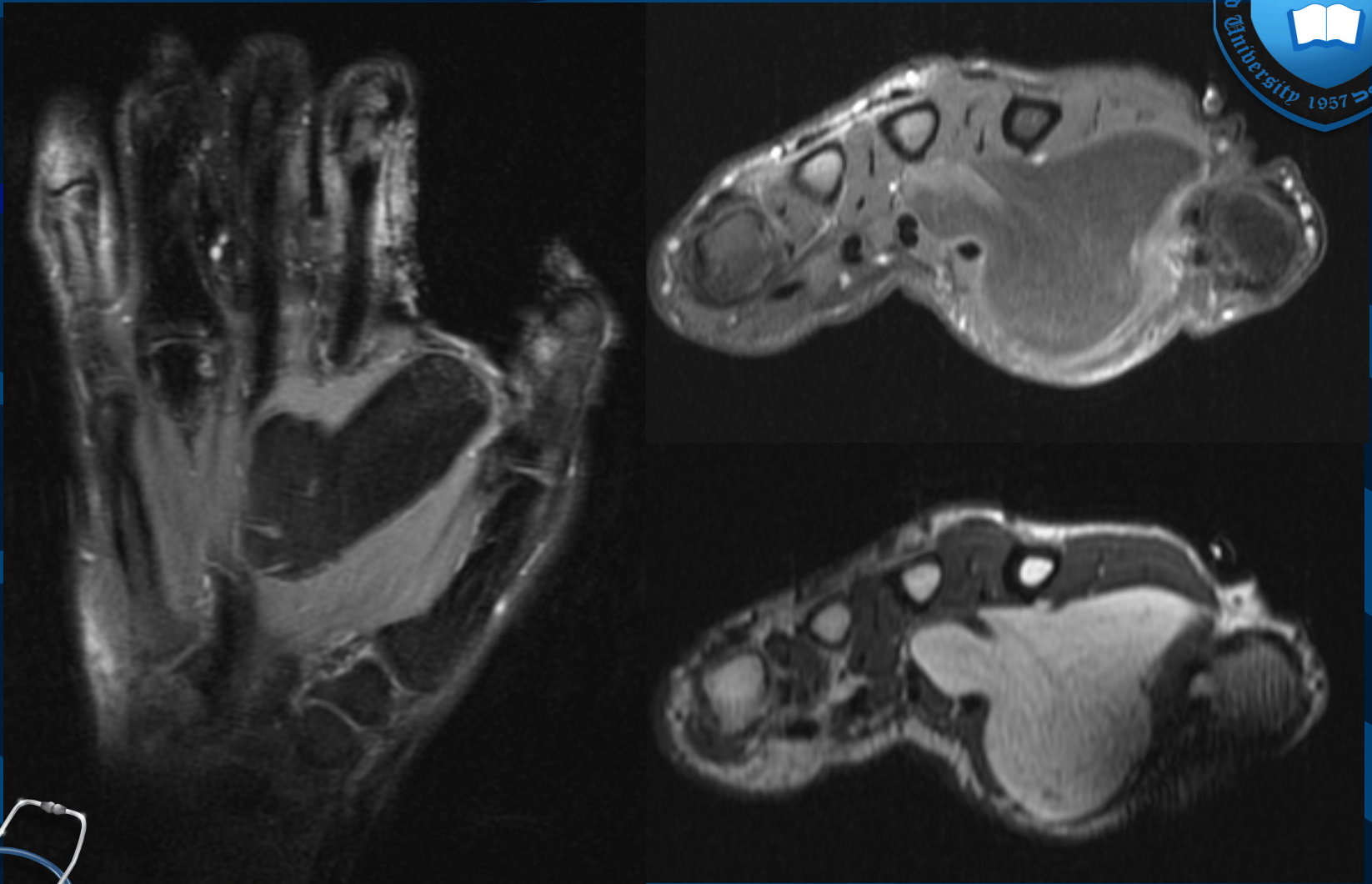
CASE NO. 8

Adult female patient presented with hand swelling
X-ray of hand requested





Soft Tissue Lipoma



Soft Tissue Lipoma

A A AI-BOUKAI-49



THANKS

