



Lecture (3)

Radiology of thyroid and parathyroid diseases

Suliman Alshammari

Ghadeer Alwuhayd

Hanan Alrabiah

Dalal Alqadi

Ayshah Almahboob

Hanan Alsalman

Khawla Alothman

Maha Alkubaidan

Reem Aljurayyad

Rawabi Alghamdi

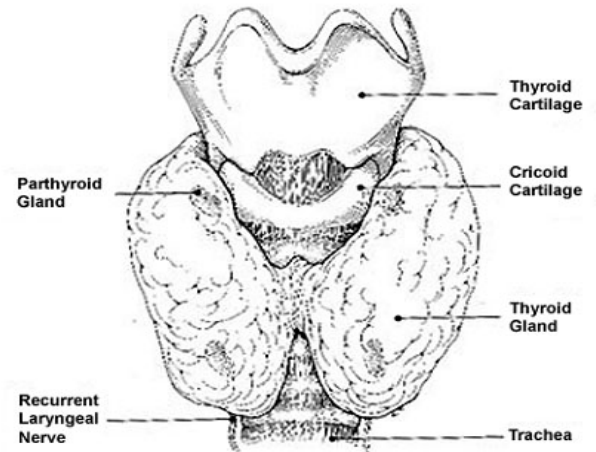
Resources:

- Lecture by **Dr. Fahad Al Bader**

Thyroid Gland

Anatomy of the Thyroid Gland:

- **Location:** anterior neck at C5-T1, overlays 2nd – 4th tracheal rings.
- Average **width:** 12-15 mm (each lobe).
- Average **height:** 50-60 mm long



Thyroid Diseases:

1- Thyrotoxicosis:

Causes of Thyrotoxicosis:

1- Hyperthyroidism:

- A. Diffuse toxic goiter (Graves' disease)
- B. Single toxic nodule
- C. Toxic multi-nodular goiter

2- Early phase sub-acute thyroiditis

3- Exogenous thyroid hormone intake

2- Hypothyroidism: Thyroid scan does not have significant diagnostic value.

3- Thyroid nodules: We have to check if it is benign or malignant.

Thyrotoxicosis VS Hyperthyroidism:

- **Thyrotoxicosis:** a group of symptoms and signs due to elevated thyroid hormones in the body of any cause.
- **Hyperthyroidism:** a group of symptoms and signs due to increased production of thyroid hormones by hyper functioning thyroid gland.

IMP:

What is the difference between hyperthyroidism and thyrotoxicosis?

Hyperthyroidism: hyper functioning thyroid gland. So, it is diagnosed with radiological methods.

Thyrotoxicosis: elevated thyroid hormones in the body due to exogenous source or other causes. If the cause is exogenous, we don't need radiological methods for diagnosis.

Why is it important to differentiate?
different treatment and investigation.

Thyroid function test (TFT):

- **Findings in thyrotoxicosis:** suppressed TSH and elevated T3/T4.
- We use TFT first to diagnose thyrotoxicosis **BUT** the exact cause of thyrotoxicosis **can't be determined**.
- **Thyroid scan** is a very helpful tool in **differentiating** between various causes of thyrotoxicosis.

Thyroid scan and uptake:

- Radioactive Iodine (RAI) is used for thyroid scan and uptake.
- RAI is given orally.
- Image and uptake are obtained after 24 hours
- Follicular cell traps Iodine and organifies it to be incorporated with thyroid hormone.
- **Imaging findings: IMP**
 - A. Symmetric or asymmetric lobes.
 - B. Homogeneous or inhomogeneous uptake
 - C. Nodules; cold or hot

Symptoms of hyperthyroidism:

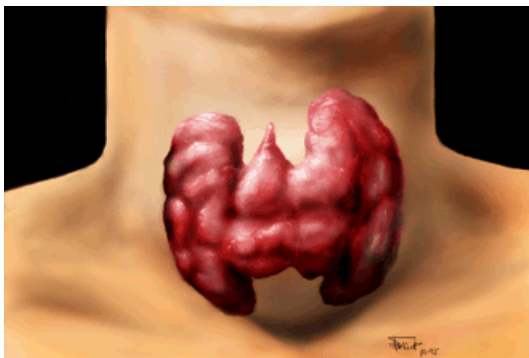
- Fatigue
- Increased sweating
- Frequent bowel movements
- Goiter (visibly enlarged thyroid gland)
- Heat intolerance
- Increased appetite
- Irregular menstrual periods
- Nervousness
- Restlessness
- Weight loss

❖ Thyrotoxicosis:

1. Hyperthyroidism:

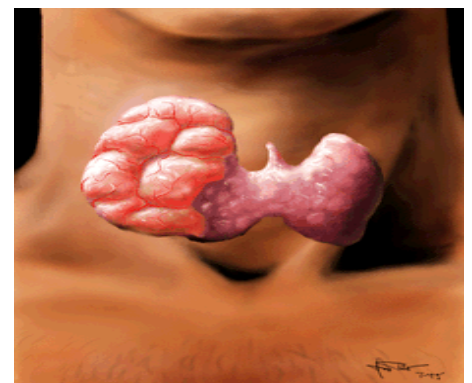
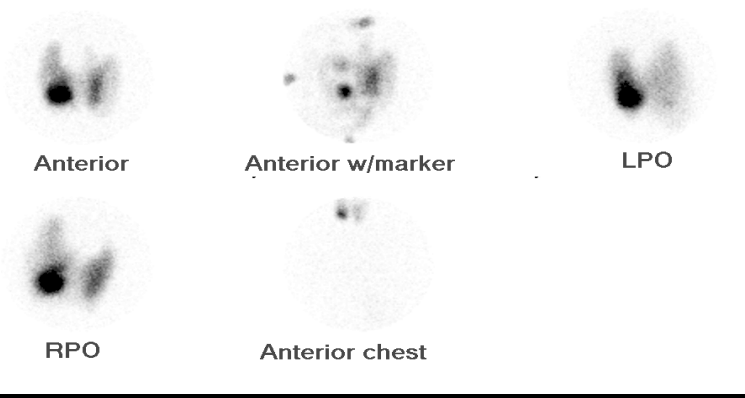
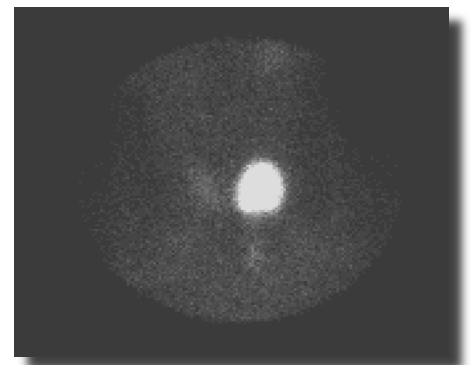
1. Diffuse Toxic goiter (Graves' Disease):

- Diffuse enlargement of thyroid gland.
- Homogeneous uptake.
- No significant focal abnormalities (nodules).
- 24-hour RAI uptake is elevated, usually $> 35\%$ (mean of 40%).



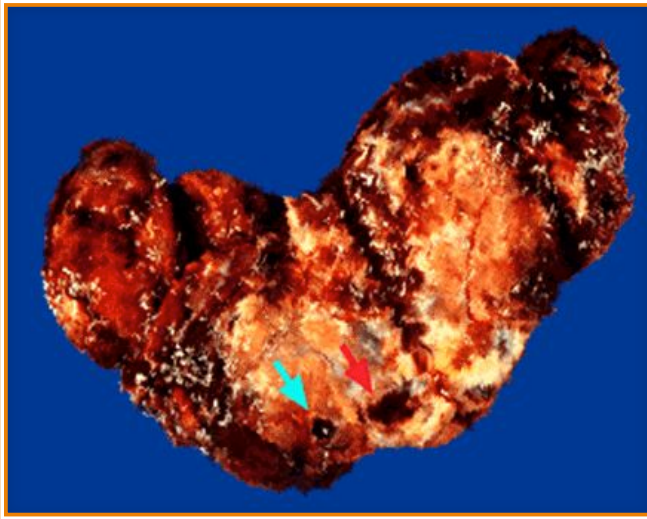
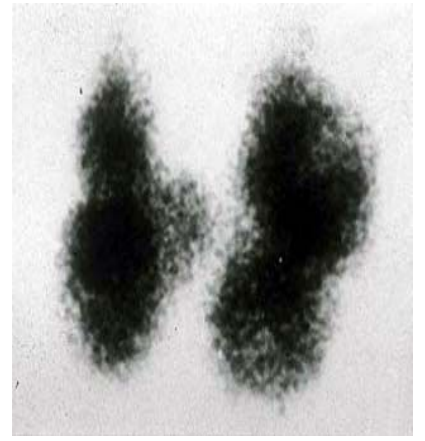
2. Single Toxic Nodule:

- Single hot nodule (independent of TSH or autonomous).
- Rest of thyroid gland is poorly visualized due to low TSH level (TSH dependant).
- 24-hour RAI uptake is slightly elevated, usually around 20%.
- **Hot Nodule: (right lobe hot in imaging)**



3. Toxic Multi-Nodular Goiter:

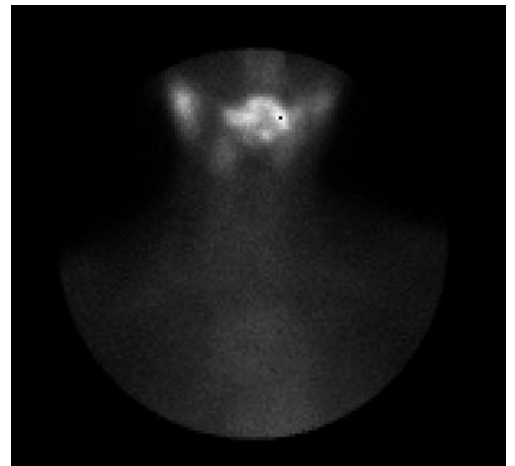
- Mild inhomogeneous uptake in thyroid gland.
- Multiple cold and hot nodules in both thyroid lobes.
- 24-hour uptake is mildly elevated, usually between 20%-30%



- Cut surface of one lobe of thyroid gland showing ill-defined nodules.
- Thyroid gland is replaced by solid and cystic nodules. However, they will necrotize and degenerate.
- Degeneration seen (blue arrow).
- Some hemorrhage (red arrow) and some scarring.

2. Early Phase Sub-acute Thyroiditis:

- Inhomogeneous uptake could be mild or severe. In some cases thyroid gland is not visualized.
- No significant focal abnormalities (nodules).
- 24-hour RAI uptake is low (**no uptake**), usually < 5%.
- Mainly, it will cause **hypothyroidism**.



IMP:

Why do we need to differentiate between these causes?

- Because the medical and surgical treatment is totally different.

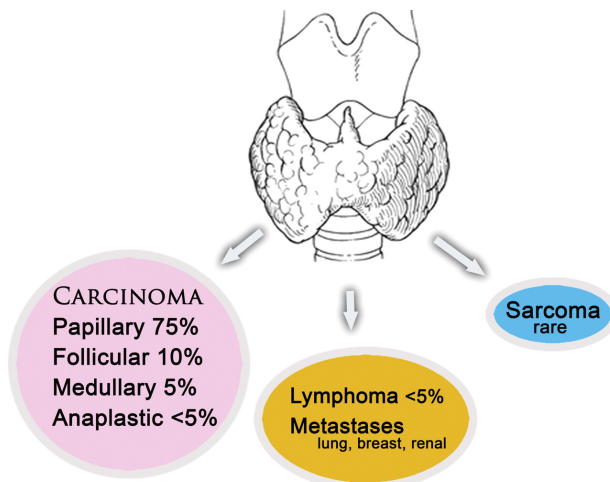
❖ Hypothyroidism:

- The main cause is chronic thyroiditis (Hashimoto's thyroiditis).
- TSH is elevated.
- **Thyroid scan does not have significant diagnostic value in this entity.**
- However, if there is nodule/nodules confirmed by **physical examination, ultrasound and thyroid scan** may be helpful.

❖ Thyroid Nodules:

- Thyroid nodules are common, perhaps existing in almost half the population
- Nodules are usually found by physical examination or by ultrasound.
- **US is the first modality used to investigate a palpable thyroid nodule**
- Scintigraphy is reserved for characterizing functioning nodules and for staging follicular and papillary carcinomas.
- The patient is usually **euthyroid** (normal thyroid gland function).
- If the patient is hyperthyroid do nuclear scan otherwise do FNA.
- FNA (**Fine-Needle Aspiration**) is the most accurate and cost-effective method for diagnostic evaluation of thyroid nodules.
- FNA have a sensitivity of 76%–98%, specificity of 71%–100%

Frequency of Occurrence of Thyroid Malignancies:



Risk factors for thyroid cancer:

- Family history of thyroid cancer.
- A history of head and neck irradiation.
- Male sex.
- Age of less than 30 years or more than 60 years.
- Previous diagnosis of type 2 multiple endocrine neoplasia

US features of thyroid nodules: **IMP!!!**

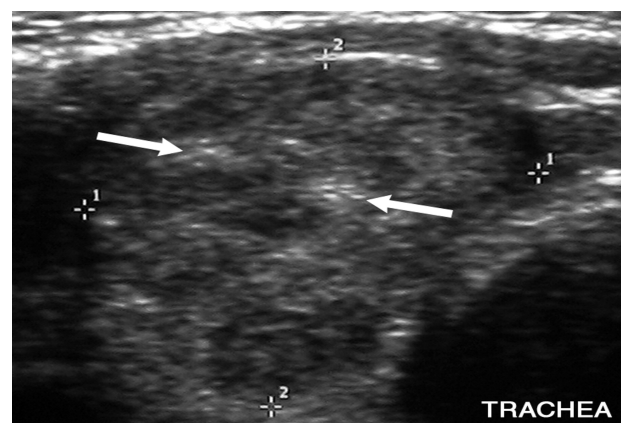
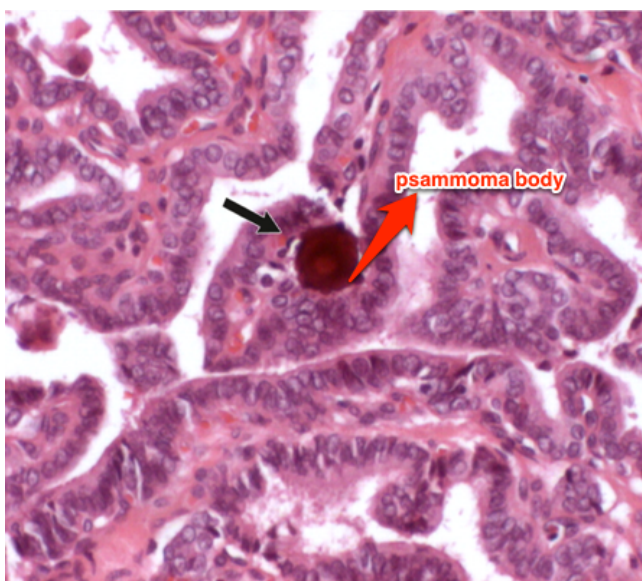
- Thyroid nodules are common in the community. US will help us to differentiate between benign and malignant nodules.
- There is some overlap between the US appearance of benign nodules and that of malignant nodules
- Certain US features are helpful in differentiating between the two. **These features include:**
 1. **Micro-calcifications.**
 2. **Local invasion.**
 3. **Lymph node metastases.**
 4. **A nodule that is taller than it is wide.**
 5. **Markedly reduced echogenicity.**
- **Other features**, such as the **absence of a halo**, **ill-defined irregular margins**, **solid composition**, and **vasculature**, **are less specific but may be useful.**

US Feature*	Sensitivity (%)	Specificity (%)	Positive Predictive Value (%)	Negative Predictive Value (%)
Microcalcifications (1–5)	26.1–59.1	85.8–95.0	24.3–70.7	41.8–94.2
Hypoechoogenicity (2–5)	26.5–87.1	43.4–94.3	11.4–68.4	73.5–93.8
Irregular margins or no halo (2–5)	17.4–77.5	38.9–85.0	9.3–60.0	38.9–97.8
Solid (4–6)	69.0–75.0	52.5–55.9	15.6–27.0	88.0–92.1
Intranodule vascularity (3, 6)	54.3–74.2	78.6–80.8	24.0–41.9	85.7–97.4
More tall than wide (2)	32.7	92.5	66.7	74.8

1. Thyroid micro-calcifications:

- They are **psammoma bodies**, which are 10–100-µm round laminar crystalline calcific deposits. They are one of the **most specific features of thyroid malignancy**, with a specificity of 85.8%–95% and a positive predictive value of 41.8%–94.2%

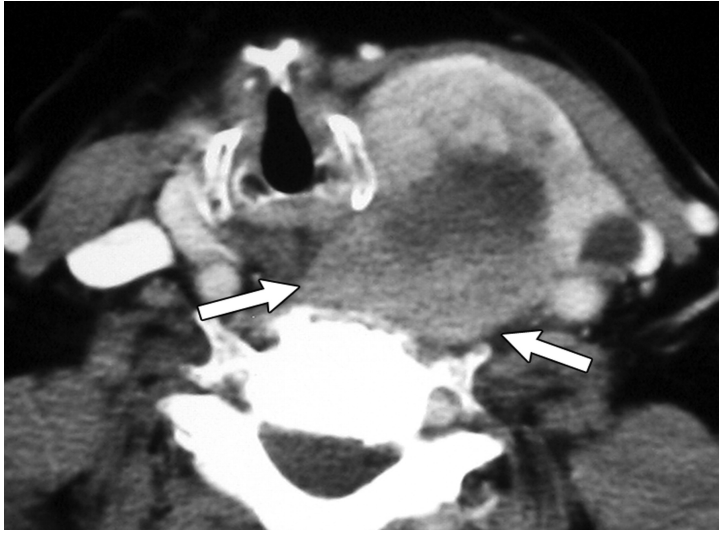
- **Papillary thyroid carcinoma** (Common disease, curable and the issue is to diagnose them early)



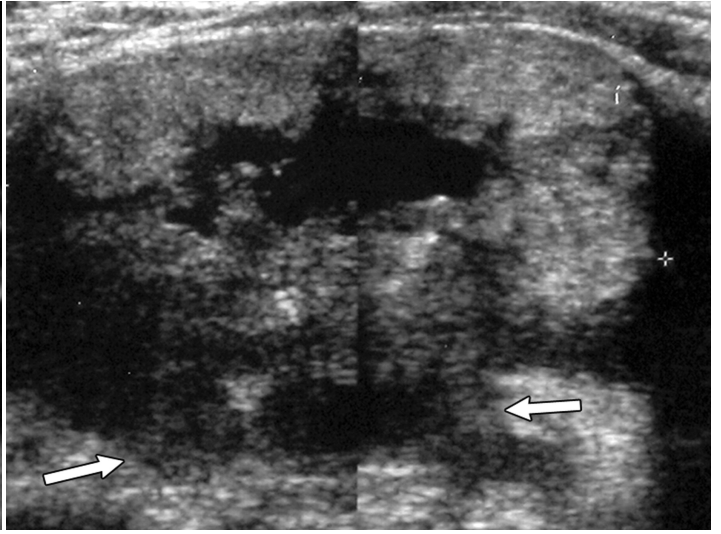
Punctate echogenic foci without posterior acoustic shadowing, findings indicative of microcalcifications (arrows).

2. Local Invasion and Lymph Node Metastases: IMP

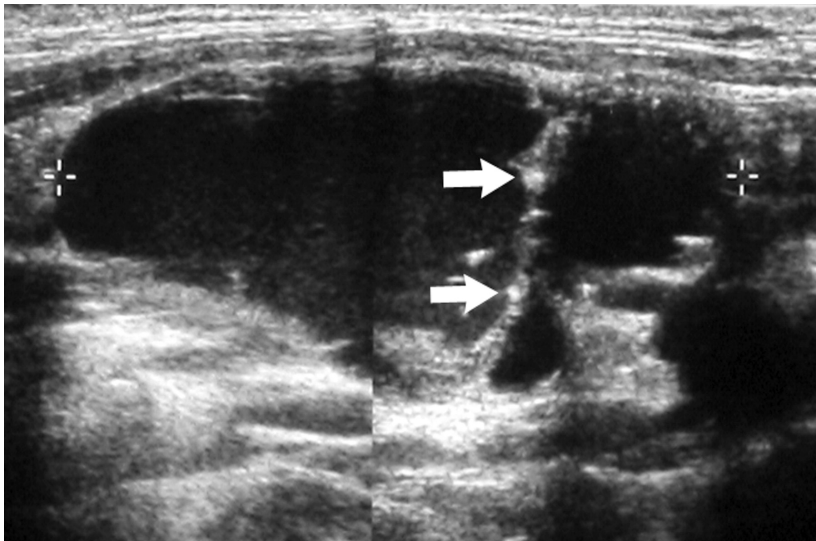
- US features that should arouse suspicion about lymph node metastases include a **rounded bulging shape, increased size, replaced fatty hilum, irregular margins, heterogeneous echotexture, calcifications, cystic areas and vascularity** throughout the lymph node instead of normal central hilar vessels at Doppler imaging



Axial contrast-enhanced CT image
Large tumour that has invaded the capsule and prevertebral muscle (arrows)



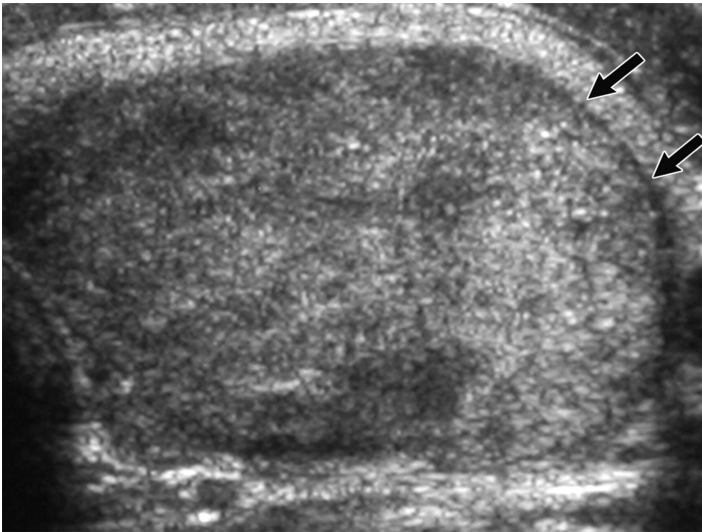
Transverse sonogram (Ultrasound)
Tumour with infiltrative posterior margins (arrows)



Longitudinal sonogram of the right neck
cystic level 5 nodal metastasis with internal septation and foci of calcification (arrows)

3. Margins, Contour, and Shape:

- A completely **uniform halo around a nodule** is highly suggestive of benignity, with a specificity of 95%

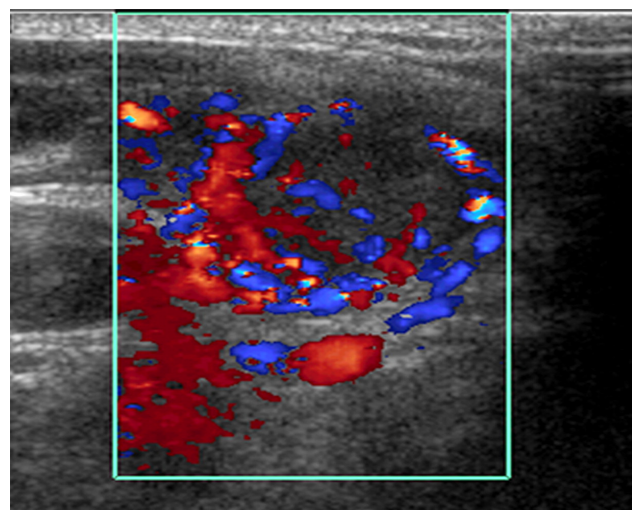
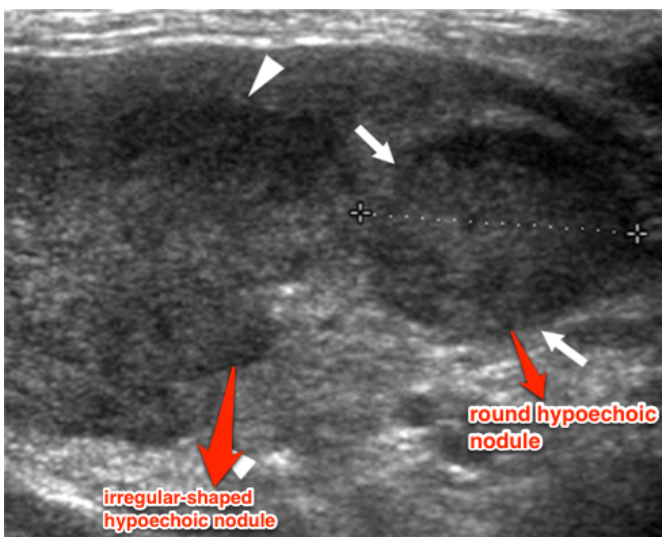


Transverse sonogram of the left lobe of the thyroid shows a follicular adenoma with a hypoechoic halo (arrows)

The Presence of a halo suggests benign lesion (IMP)

4. Vascularity:

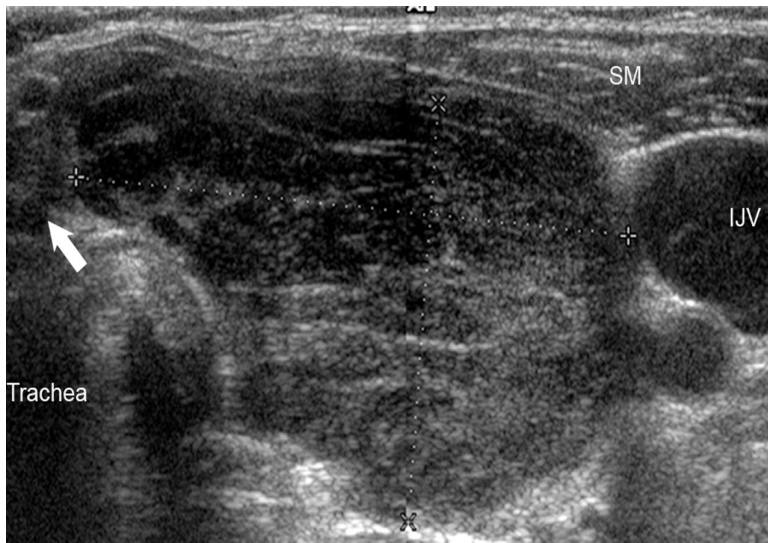- Papillary thyroid carcinomas had some intrinsic blood flow
- avascular (**lacking blood vessels**) nodule is very **unlikely to be malignant**.



Color Doppler sonogram of the round nodule shows increased internal vascularity.

5. Hypoechoic Solid Nodule:

- Marked **hypoechoogenicity** is very suggestive of **malignancy**.



a large heterogeneous mass (between calipers) with marked hypoechoogenicity when compared with the strap muscles (SM). A normal isthmus (arrow) also is visible. IJV = internal jugular vein.

Nonspecific US Features:

1. Size of a nodule:

- The size of a nodule is **not helpful for predicting or excluding malignancy**. There is a common but mistaken practice of selecting the largest nodule in a multinodular thyroid for FNA.

2. Number of Nodules:

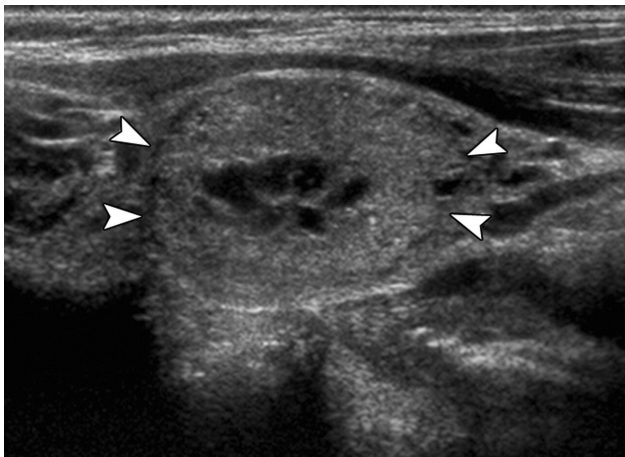
- Although most patients with nodular hyperplasia have multiple thyroid nodules and some patients with thyroid carcinoma have solitary nodules, the presence of multiple nodules should never be dismissed as a sign of benignity.

3. Interval Growth of a Nodule:

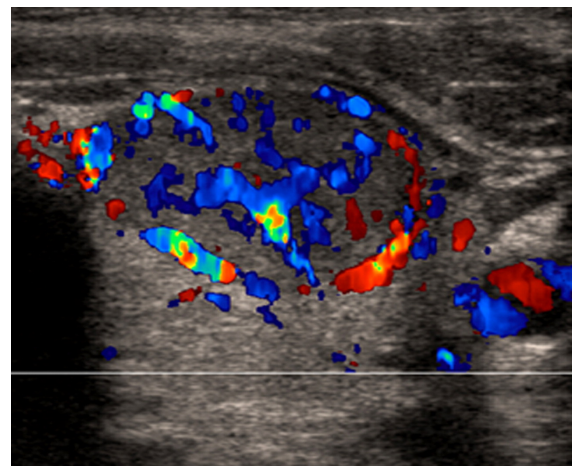
- In general, interval growth of a thyroid nodule is **a poor indicator of malignancy**. Benign thyroid nodules may change in size and appearance over time.
- The exception is clinically detectable rapid interval growth, which most commonly occurs in anaplastic thyroid carcinoma but also may occur in lymphoma, sarcoma, and, occasionally, high-grade carcinoma.

Recommendations for Thyroid Nodules 1 cm or Larger in Maximum Diameter: **IMP**

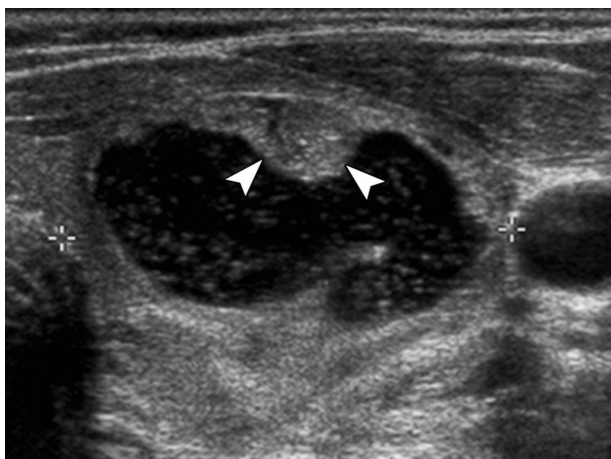
US Feature	Recommendation
Solitary nodule	
Microcalcifications	Strongly consider US-guided FNA if ≥ 1 cm
Solid (or almost entirely solid) or coarse calcifications	Strongly consider US-guided FNA if ≥ 1.5 cm
Mixed solid and cystic or almost entirely cystic with solid mural component	Consider US-guided FNA if ≥ 2 cm
None of the above but substantial growth since prior US examination	Consider US-guided FNA
Almost entirely cystic and none of the above and no substantial growth (or no prior US)	US-guided FNA probably unnecessary
Multiple nodules	Consider US-guided FNA of one or more nodules, with selection prioritized on basis of criteria (in order listed) for solitary nodule*



The Presence of a halo suggests a benign lesion (IMP)



Color Doppler mode shows marked internal vascularity



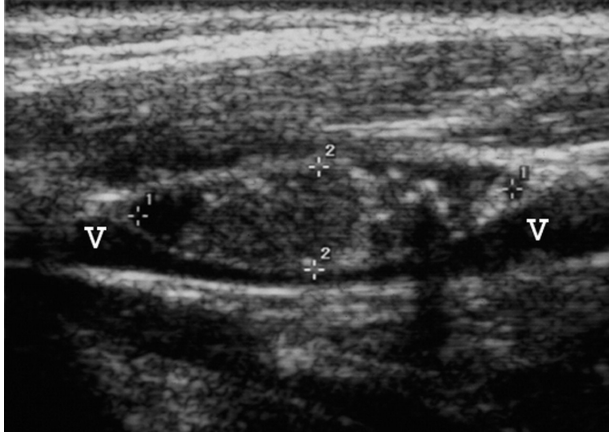
Cystic nodule (calipers) with small solid-appearing mural component (arrowheads)

US-guided FNA can be directed into this area.

The lesion was benign at cytologic examination

US features of malignant lymph node: **IMP**

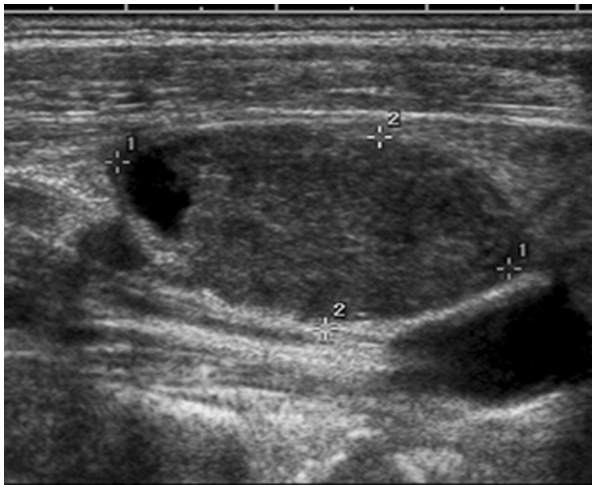
- Rounded bulging shape
- Increased size,
- Replaced fatty hilum
- Irregular margins
- Heterogeneous echotexture
- Calcifications
- Cystic areas
- Vascularity throughout the lymph node instead of normal central hilar vessels at Doppler imaging



Abnormal cervical lymph nodes.

US image of enlarged node (calipers) with central punctate echogenicities, consistent with microcalcifications, shows mass effect on internal jugular vein (V).

Node was proved to be metastatic papillary carcinoma.



Abnormal cervical lymph nodes.

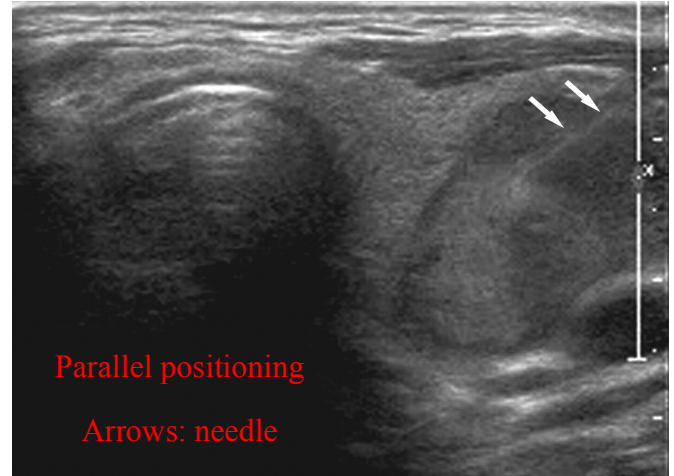
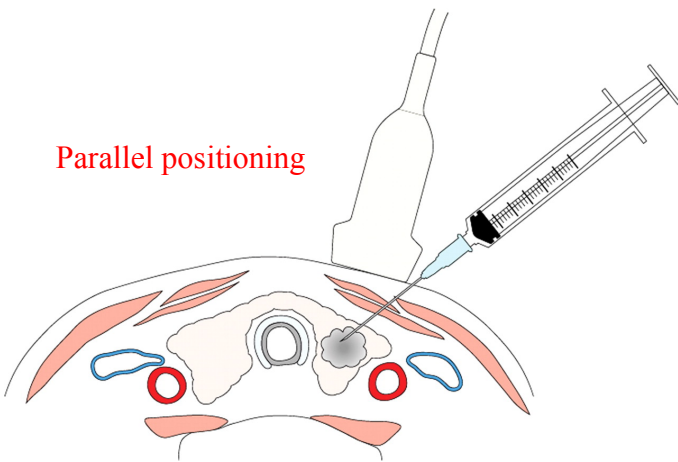
US image of enlarged node (calipers) with cystic component.

Node was proved to be metastatic papillary carcinoma.

US-guided FNA Technique:

- The needle may be introduced **parallel** or **perpendicular** to the transducer, and the needle tip should be carefully monitored during the procedure.

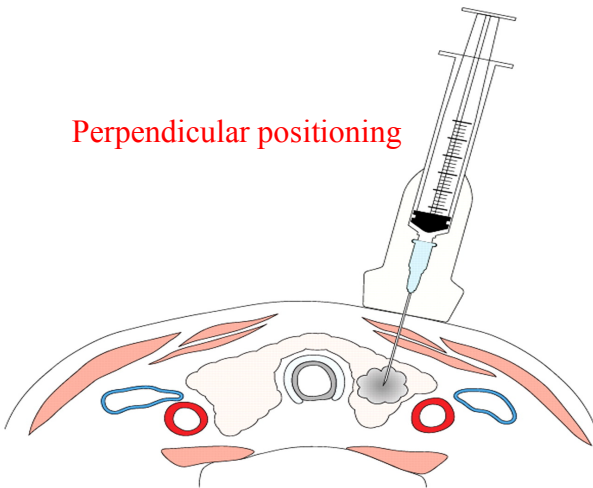
Parallel positioning



Parallel positioning

Arrows: needle

Perpendicular positioning



- We should take care when inserting the needle because it will go medial to blood vessels (carotid artery)
- The needle should target the nodule NOT the normal tissue, so that we don't get normal results.

Thyroid Ophthalmopathy Graves' Disease

- **Clinical history:** Slow onset (months), painless
- **Patterns of muscle involvement** in thyroid ophthalmopathy:
Bilateral (85%), Unilateral (5%), Normal muscles (10%)
- ALL muscles involved is most common scenario of **extraocular muscle enlargement**.
- If only individual muscles involved, typically then are **inferior and medial recti muscles**
- Lateral rectus muscle: last to become involved; rarely/never the only muscle involved
- Muscle enlargement characteristically involves the body of the muscle, **sparing the tendinous attachment to the globe**.
- **I'M SLow:** (a mnemonic helps in knowing the first muscles to be involved)
The **I**nferior is the first then the **M**edial then the **S**uperior and lastly the **L**ateral.
- **Coronal imaging is the method of choice for assessing muscle thickness**
- Patients need not be hyperthyroid (some are euthyroid)

IMP:

What are the clinical symptoms of thyroid eye disease?

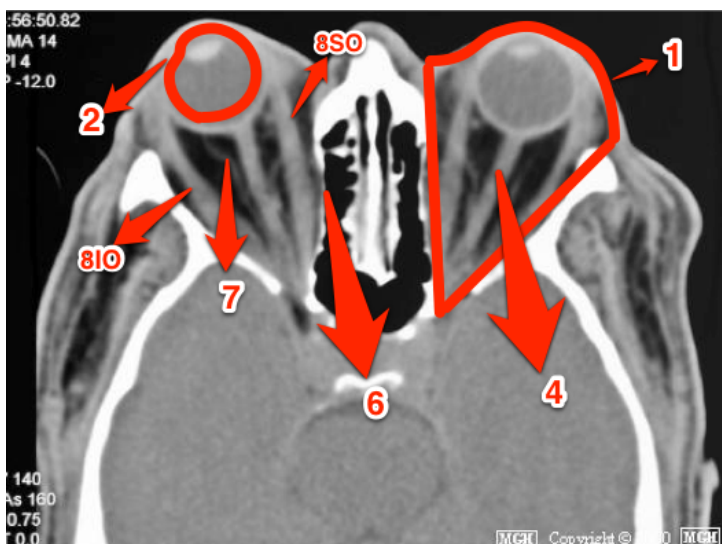
- **Exophthalmos:** bulging of the eye anteriorly out of the orbit.
In Graves' disease: painless, bilateral and symmetry.
In Orbital pseudo tumor: painful and unilateral
- **Redness**
- **Chemosis:** edema of the conjunctiva.
- **Lid lag (lid retraction):** a condition where the lid retracts.

Normal position of eyelids:

Upper eyelid: between the pupil and the superior limbus.
Lower eyelid: between the pupil and the inferior limbus

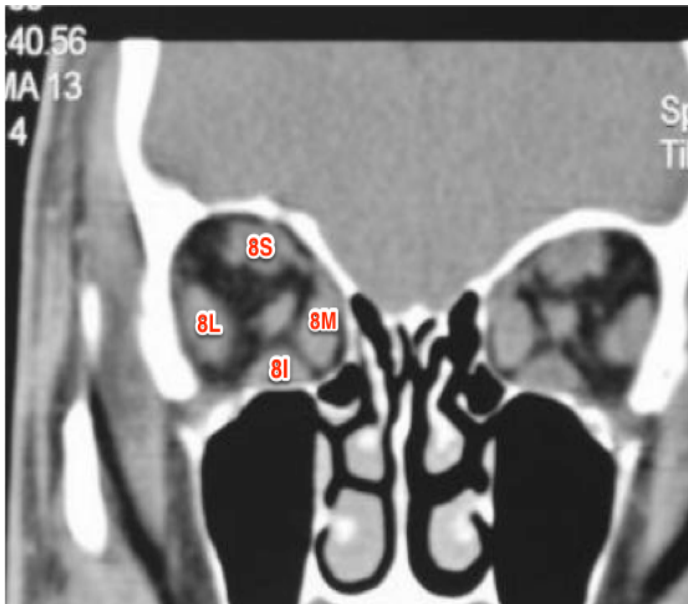Radiological manifestations of thyroid eye disease: IMP

- **Eye globe out side orbital cavity**
- **Symmetrical enlargement of extraocular muscles and sparing the tendinous**
- **Stretching of optic nerve**
- **Abundant of retrobulbar fat**
- **Impression of the lamina papyracea**



Coronal CT scan:

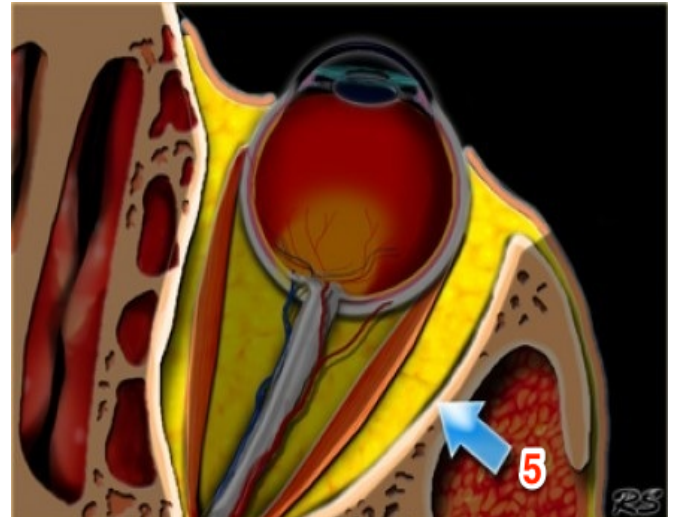
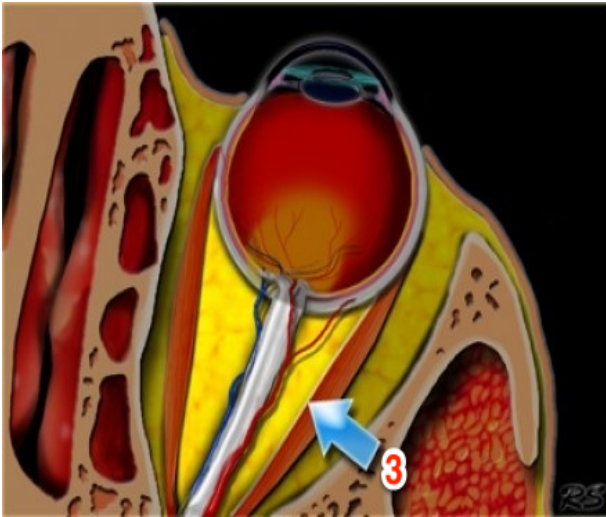
- 1- **Orbit**
- 2- **Globe**
- 3- **Intraconal space:** within the muscle cone. (Contains the optic nerve)
- 4- **Optic nerve**
- 5- **Extraconal space:** area outside the muscle cone
- 6- **Lamina papyracea:** lateral wall of ethmoid sinus and medial wall of orbital cavity
- 7- **Retrobulbar fat**



8- Extraocular muscles:

S - Superior rectus I - Inferior rectus
 L - Lateral rectus M - Medial rectus
 SO - Superior oblique IO - Inferior oblique

Enophthalmos (opposite to **exophthalmos**):
 Recession of the eyeball within the orbit.



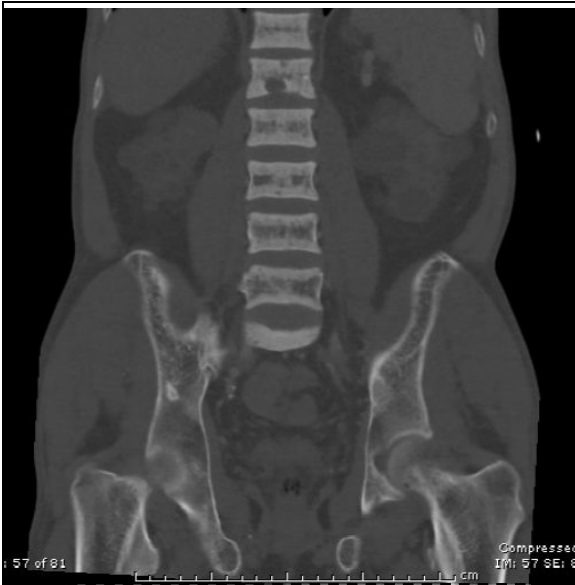Renal osteo-dystrophy

- Seen in setting of **chronic, end-stage renal disease**.
- Related to combination of **secondary hyperparathyroidism and osteomalacia**.
- Osteopenia is most common finding; however, 10-20% of patients also exhibit osteosclerosis.
- Characteristic finding of **osteosclerosis is "Rugger jersey spine"**
- Bands of hazy sclerosis that parallels the vertebral body endplates
- Additional signs of hyperparathyroidism such as resorption of secondary trabeculae, cortical thinning, subperiosteal bone resorption, or brown tumors are often present.
- Both axial and appendicular skeleton involved.
- Increased risk for pathologic fracture.

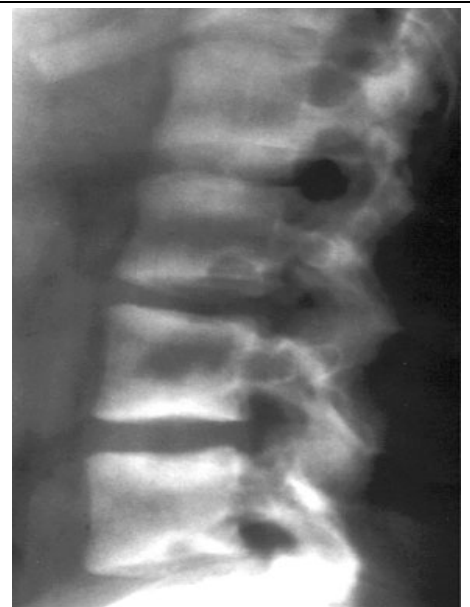Function of parathyroid hormone: to stabilize the level of calcium

ESRD causes hypocalcaemia. Therefore, the parathyroid will be active to elevate the Calcium level from the bone.

Hypocalcaemia resulting from chronic renal failure is the **most common cause of secondary hyperparathyroidism**.

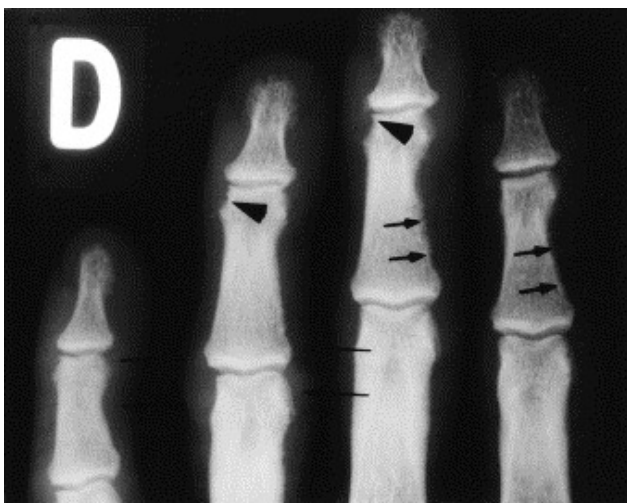


CT scan imaging
Osteosclerosis at the end plate

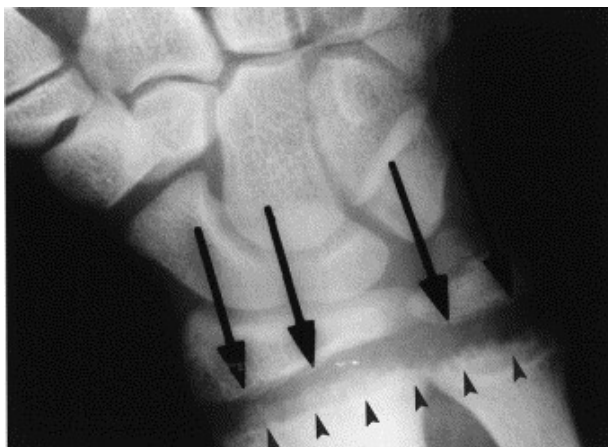


Lateral X-ray imaging
Osteosclerosis at the end plate

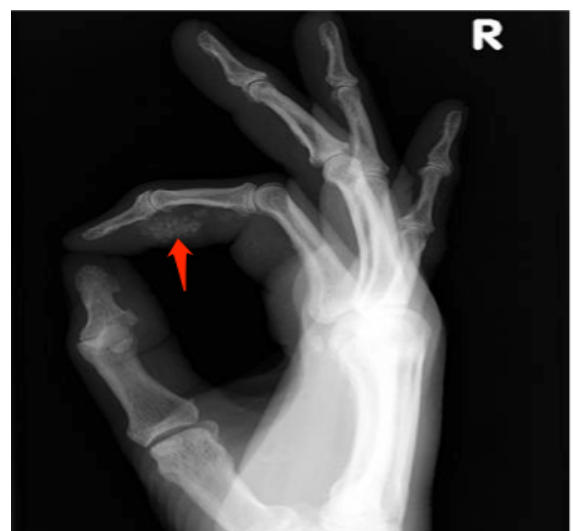The **rugger jersey spine sign** is said to be almost **diagnostic of the osteosclerosis** associated with secondary hyperparathyroidism of chronic renal failure.
The major skeletal components **of renal osteodystrophy** that can be seen on radiographs include **osteomalacia, osteosclerosis, and soft-tissue calcification**.



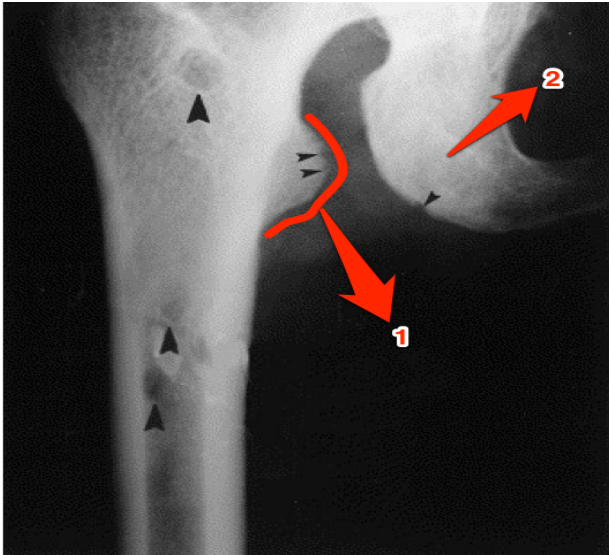
Typical **subperiosteal bone resorption** at the radial aspects of the middle phalanges (small arrows) with bone resorption at the margins of the distal interphalangeal joints (arrowheads) and paraarticular soft tissue swelling of the proximal interphalangeal joint (thin arrows).



Subchondral resorption:
Reduction mineralize bone



Calcification of soft tissue



Big arrowheads:
brown tumor

Small arrowheads:
subligamentous resorption

1- lesser trochanter
2- ischium

Manifestations of renal osteodystrophy: IMP

Subperiosteal resorption
Subchondral resorption
Subligamentous resorption
Brown tumor
Osteosclerosis

Summary

- Difference between hyperthyroidism and thyrotoxicosis
- Imaging findings in thyroid scan
- US features of thyroid nodules
- US features of malignant lymph node
- Clinical symptoms of thyroid eye disease
- Radiological manifestations of thyroid eye disease
- Manifestation of renal osteodystrophy