



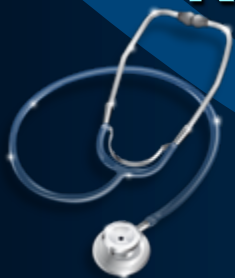# Imaging The Musculoskeletal System

## Part - 2

**Shagran Binkhamis, MBBS, FRCPC, dABR**

**Assistant Professor & Consultant Musculoskeletal,  
Vascular & Interventional Radiologist**

**Radiology & Medical Imaging Department  
King Khalid University Hospital**





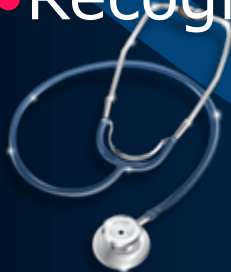
# OBJECTIVES

The main focus and objective of this lecture is to help student to be competent in looking at MSK images and interpreting findings, by learning:

- Normal radiological anatomic landmarks
- System of analyzing findings

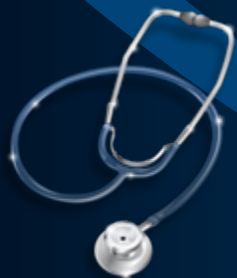“Where to look & What to look for”

- Recognize features of certain disease entity





# *METABOLIC & ENDOCRINE BONE DISORDERS*



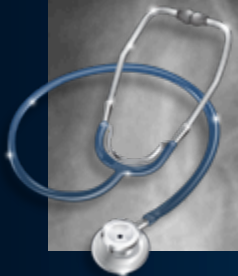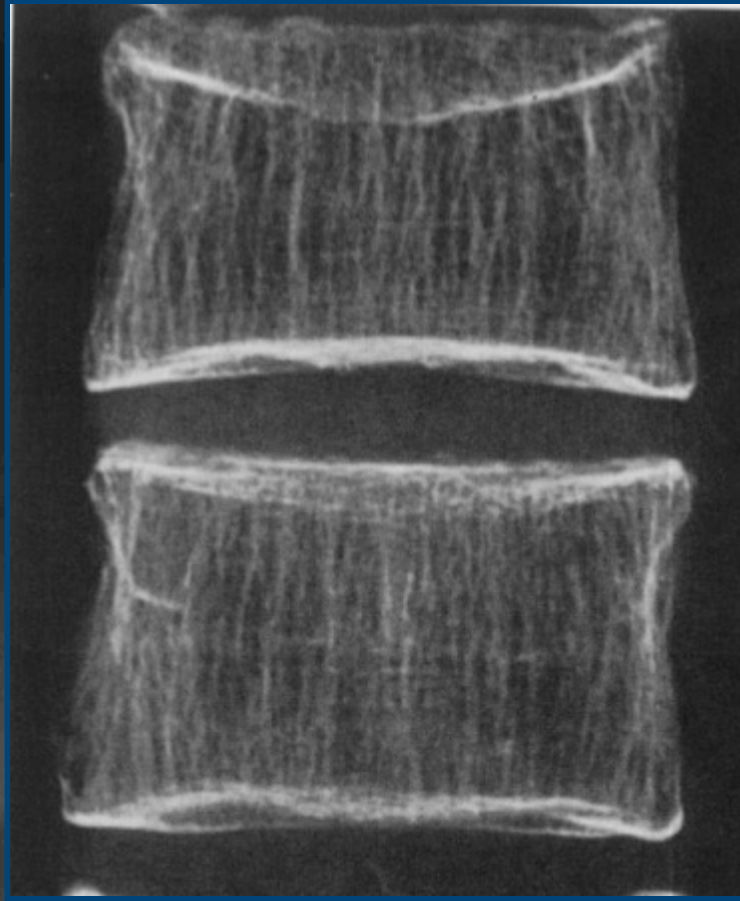


## CASE NO. 1

54 years- old female with low back pain  
X-ray of lumbosacral spine requested

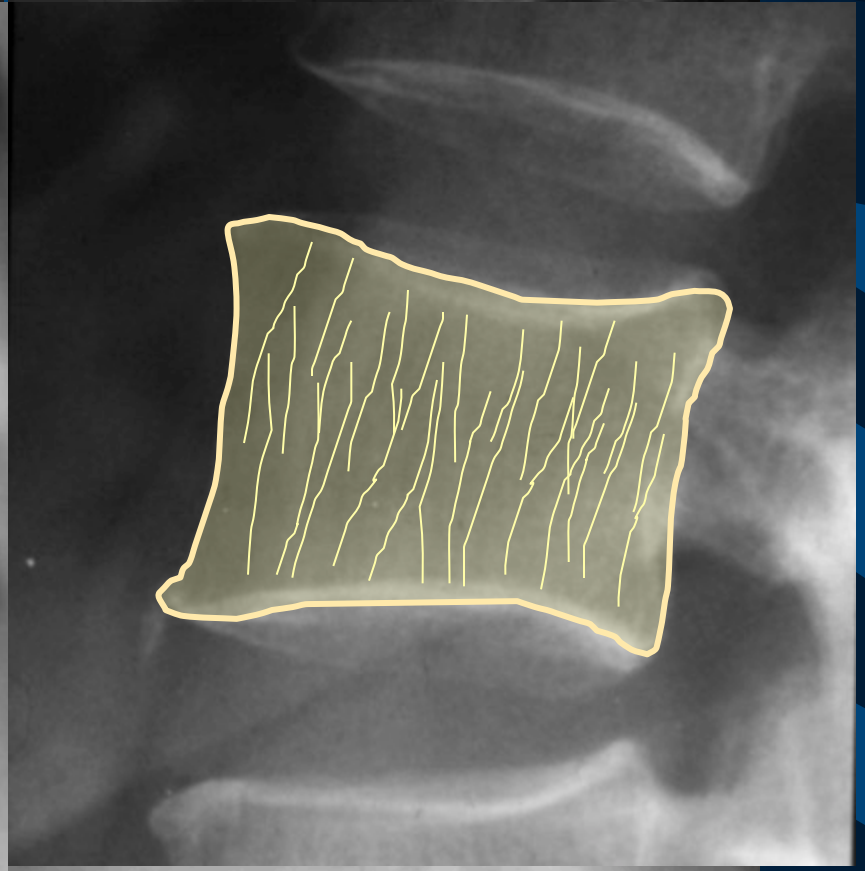
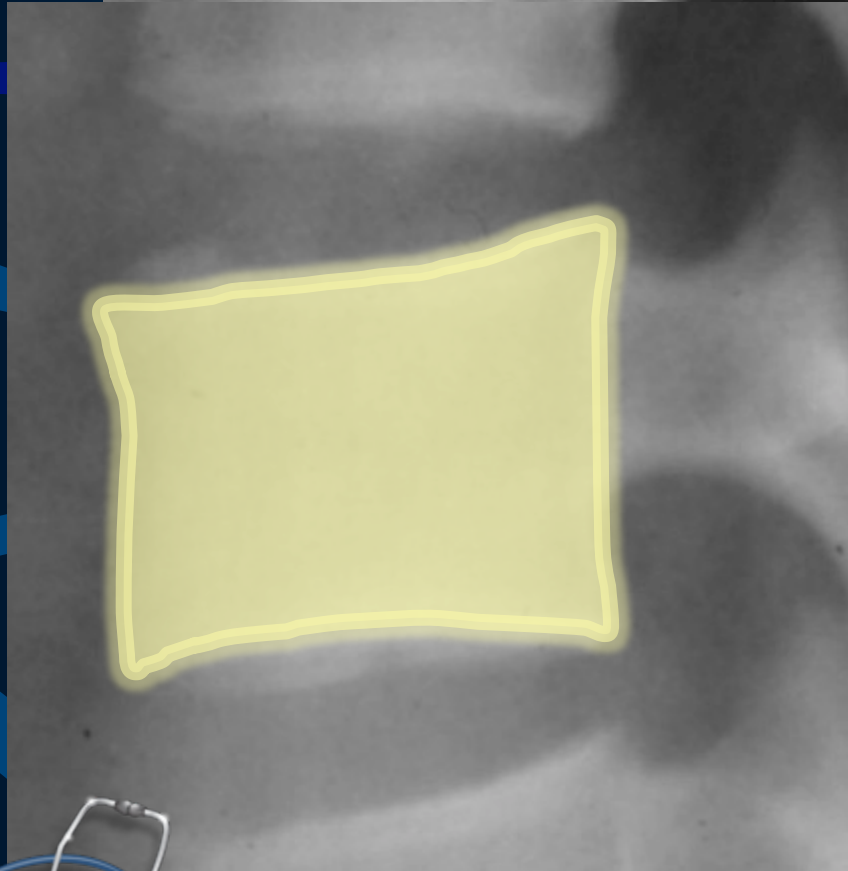






Patient A

Patient B



Osteomalacia

Osteoporosis

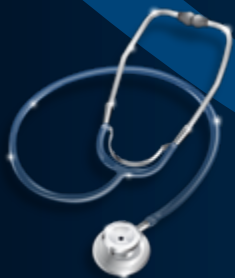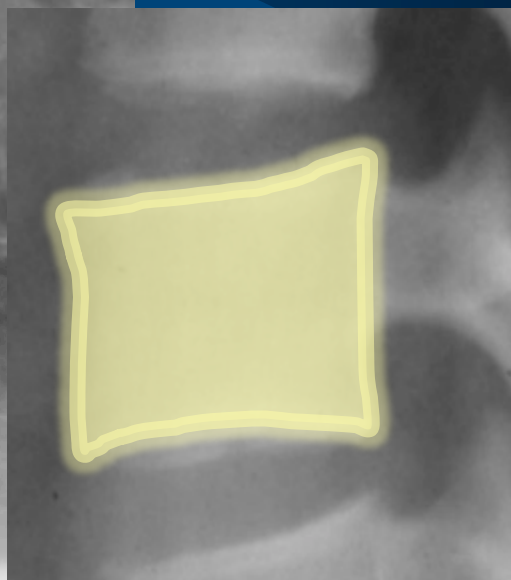
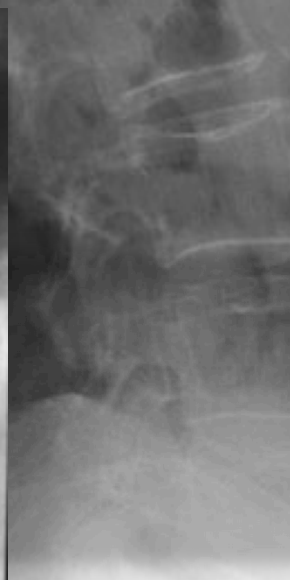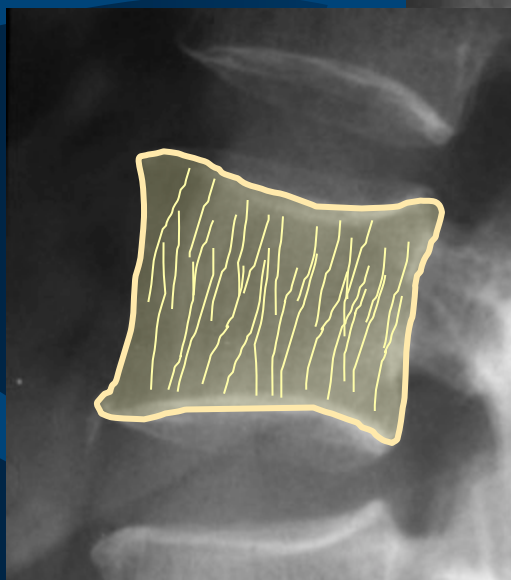


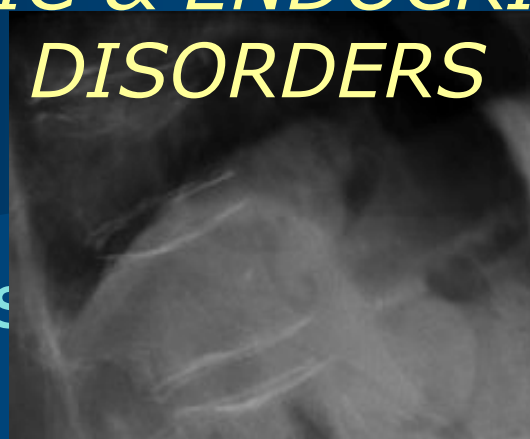

# METABOLIC & ENDOCRINE BONE DISORDERS

Osteoporosis

Osteomalacia




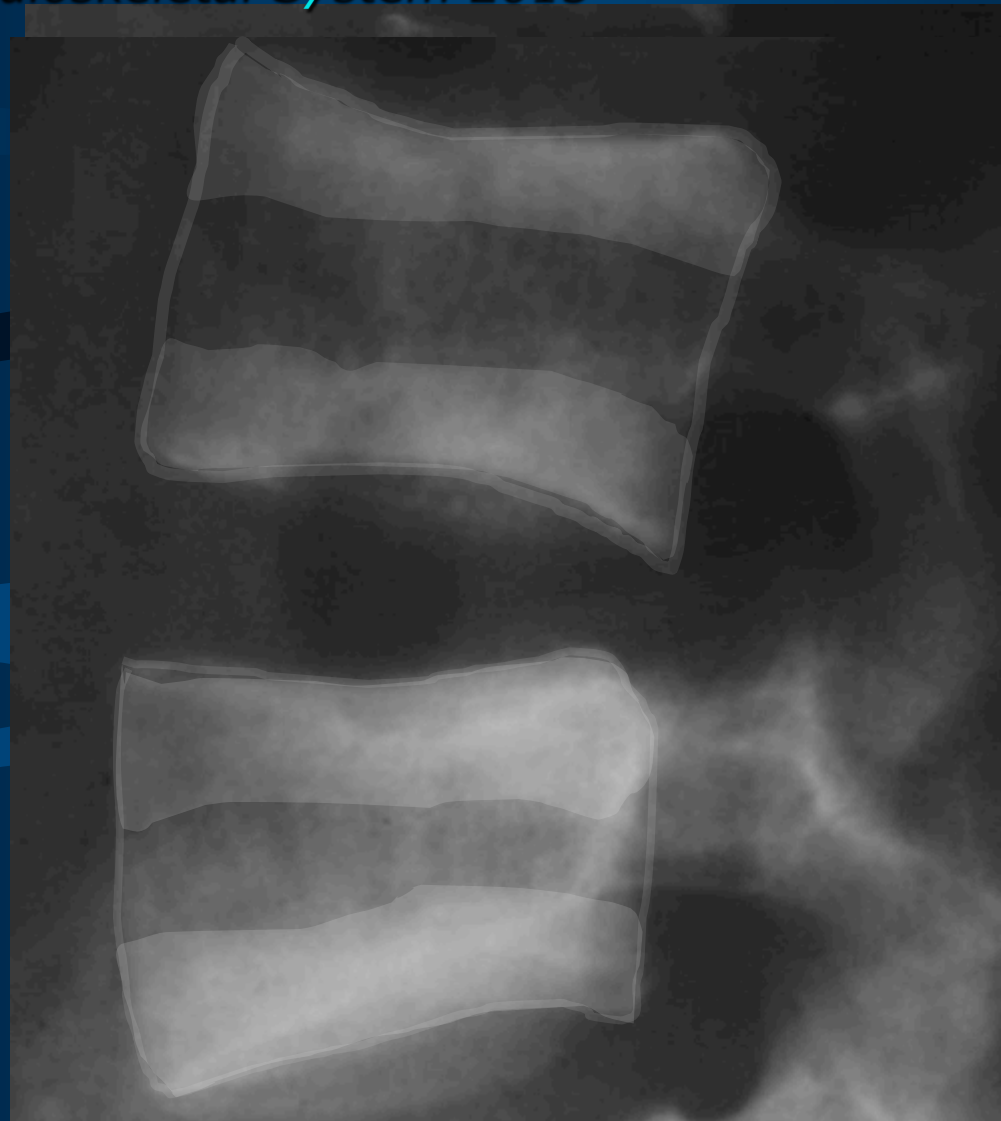
## CASE NO. 2

27 years- old male with long standing history  
of renal failure

X-ray of lumbosacral spine requested





Osteosclerosis  
"Rugger Jersey Spine"





# *METABOLIC & ENDOCRINE BONE DISORDERS*

## Renal Osteodystrophy

Osteoporosis

Osteomalacia

Secondary Hyperparathyroidism

Osteosclerosis

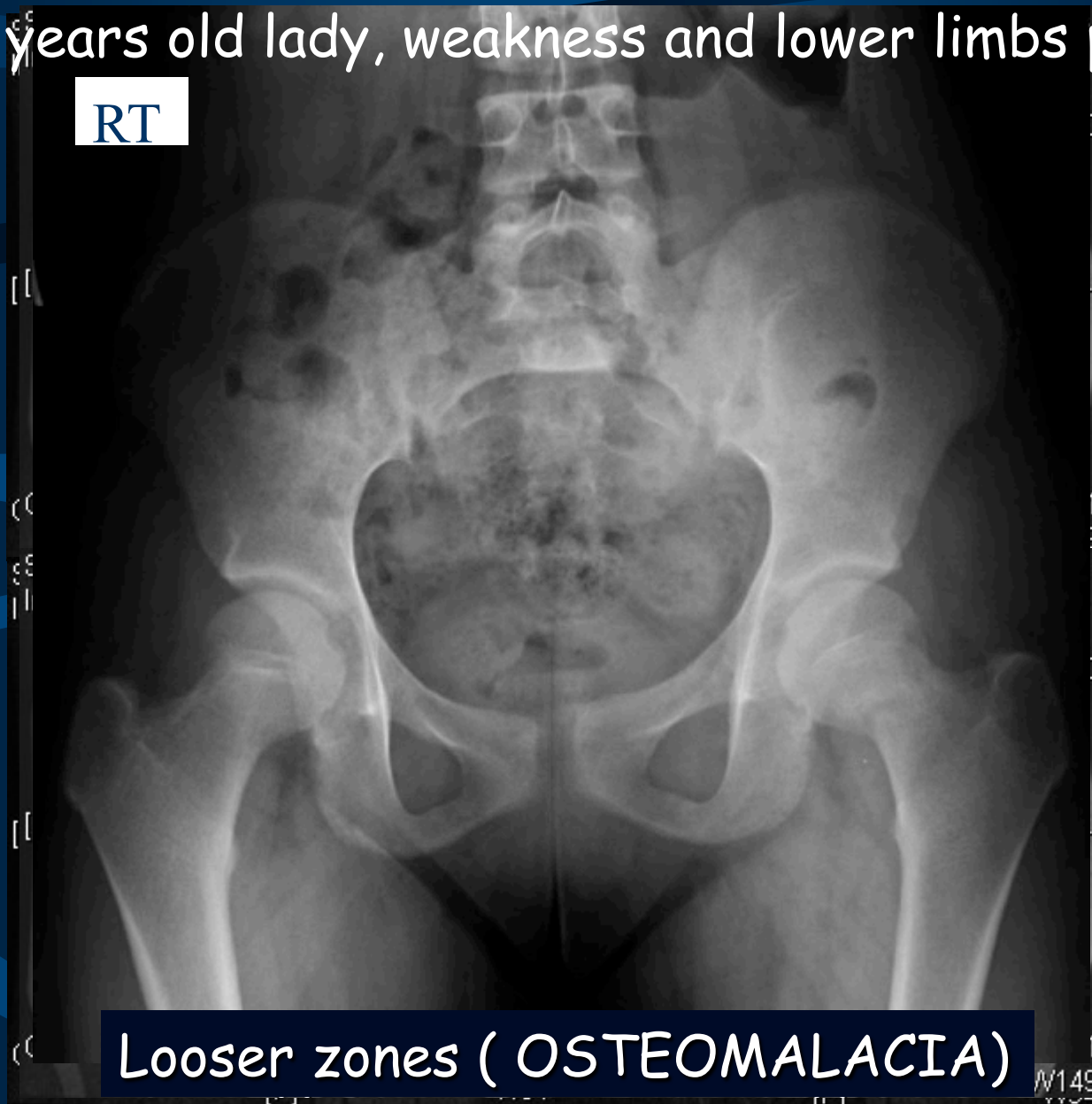






20 years old lady, weakness and lower limbs pain

RT



Looser zones ( OSTEOMALACIA)

W149  
V157





# HYPERPARATHYROIDISM

- ✓ Bone Resorption
- ✓ Bone Softening
- ✓ Brown Tumors
- ✓ Osteosclerosis
- ✓ Soft tissue calcifications

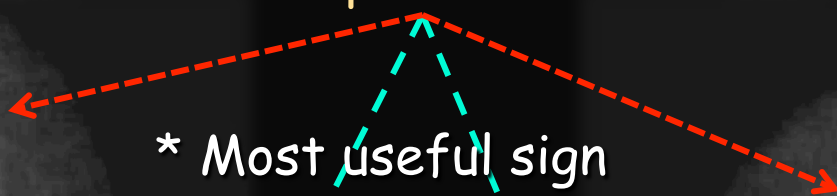



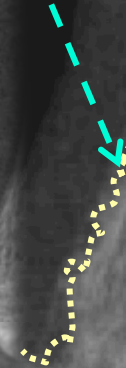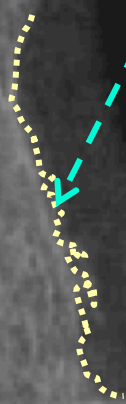
Bone Resorption



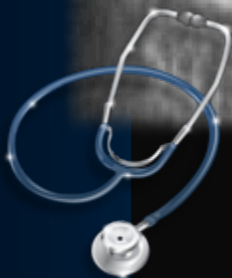Subperiosteal

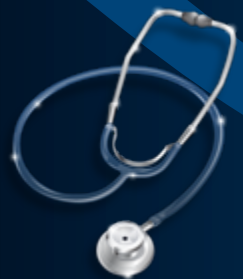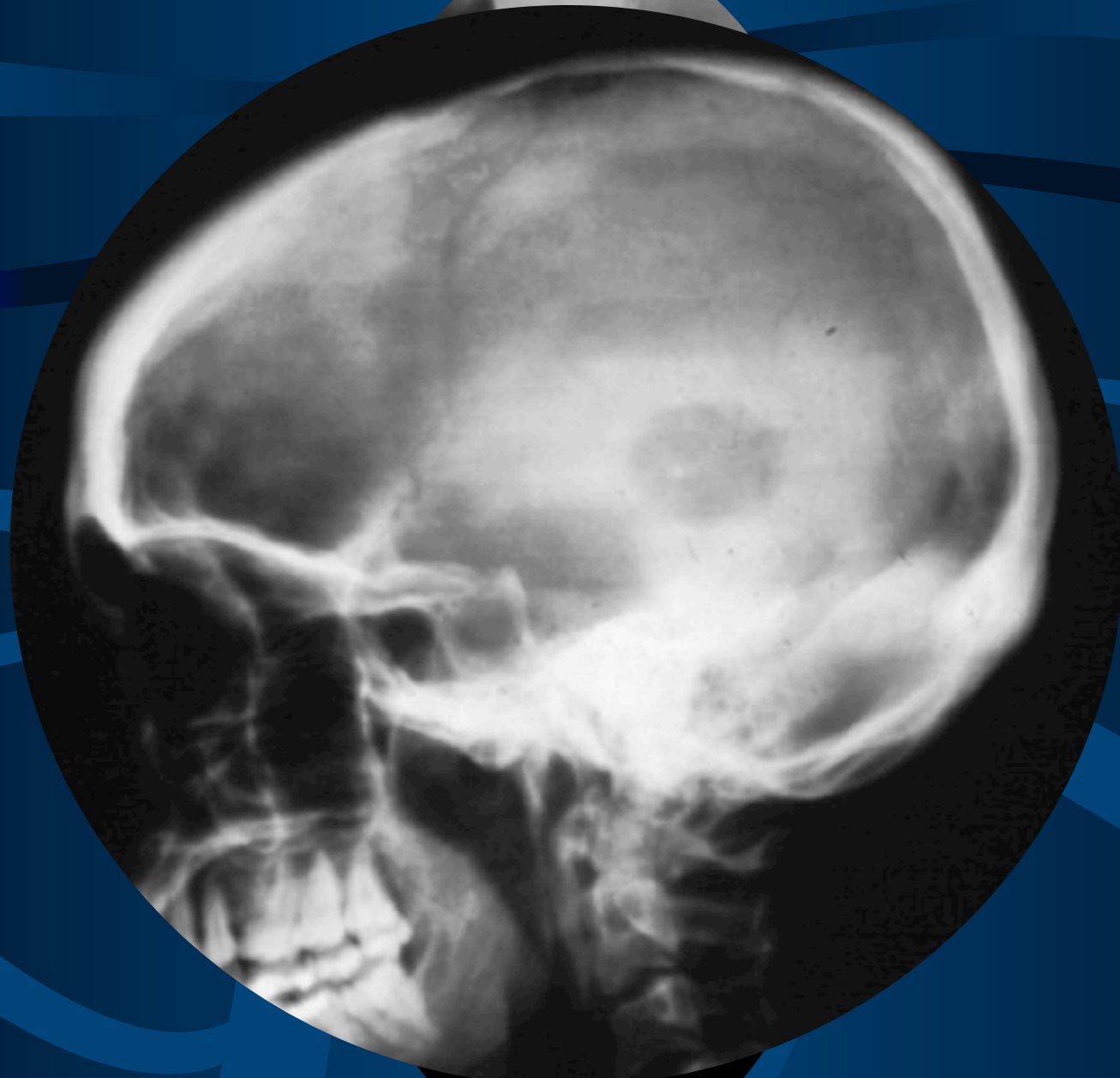


- \* Most useful sign
- \* Virtually Diagnostic
- \* Location



Hyperparathyroidism



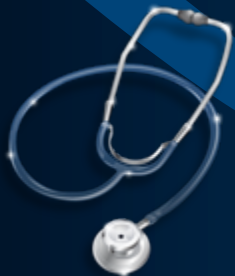

Brown Tumors



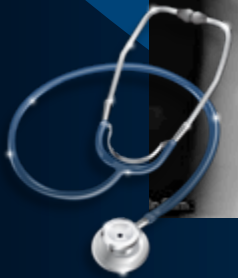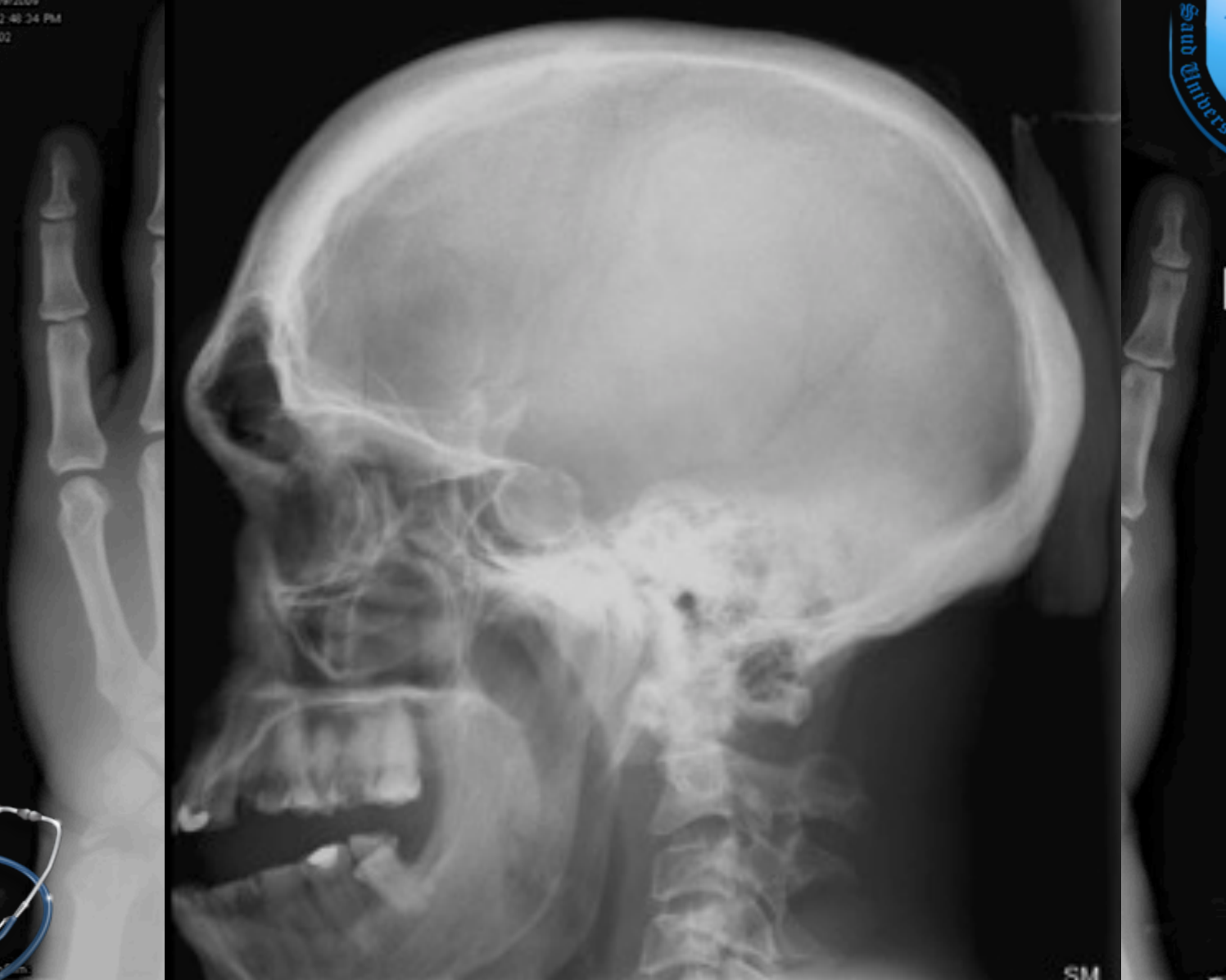## **CASE NO. 3**

45 years- old male presented with history of  
bone enlargement  
X-ray of skull and hand are requested





09/2009  
12:48:34 PM  
102





# **ARTHRITIS**



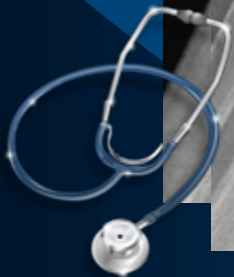
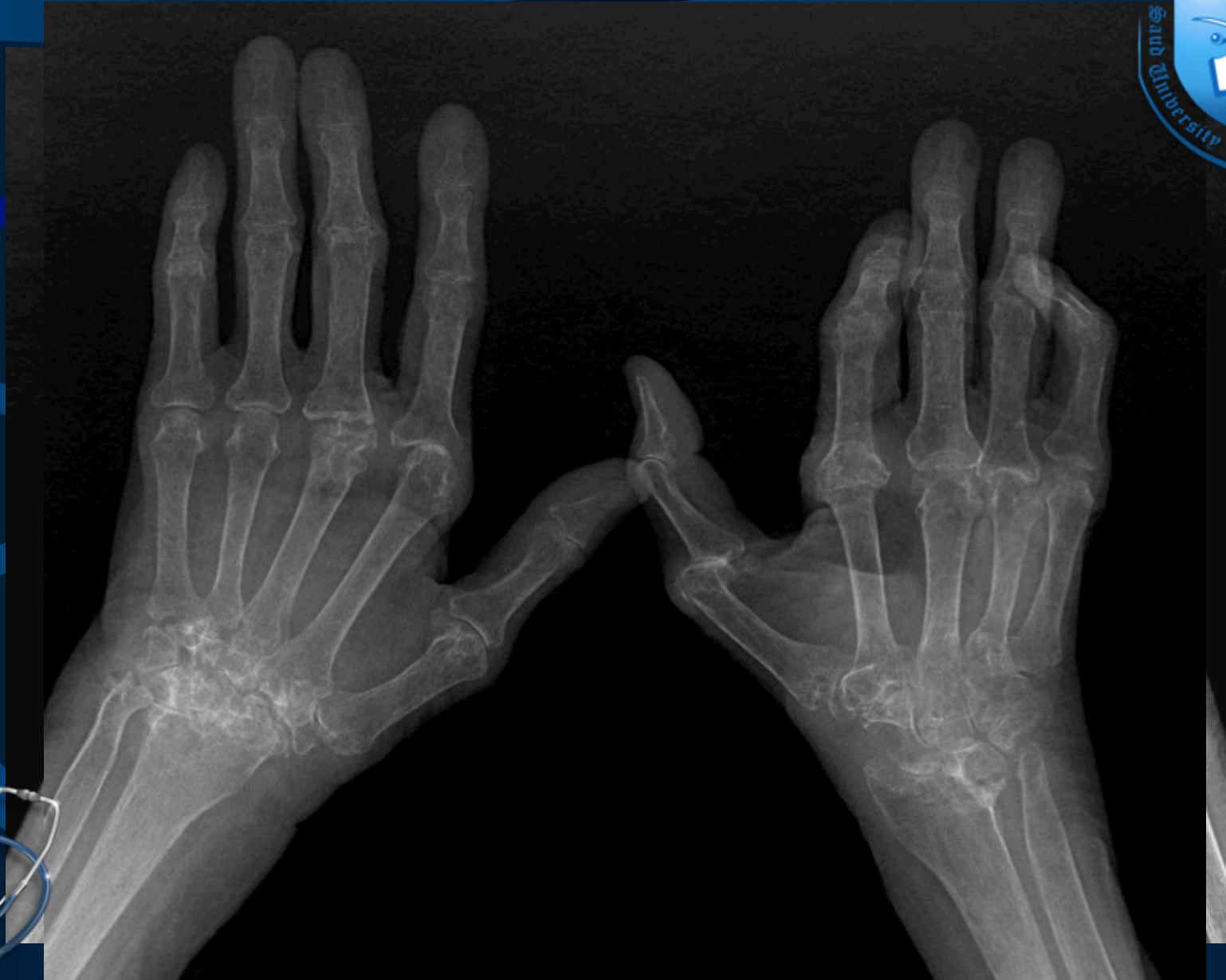
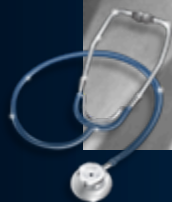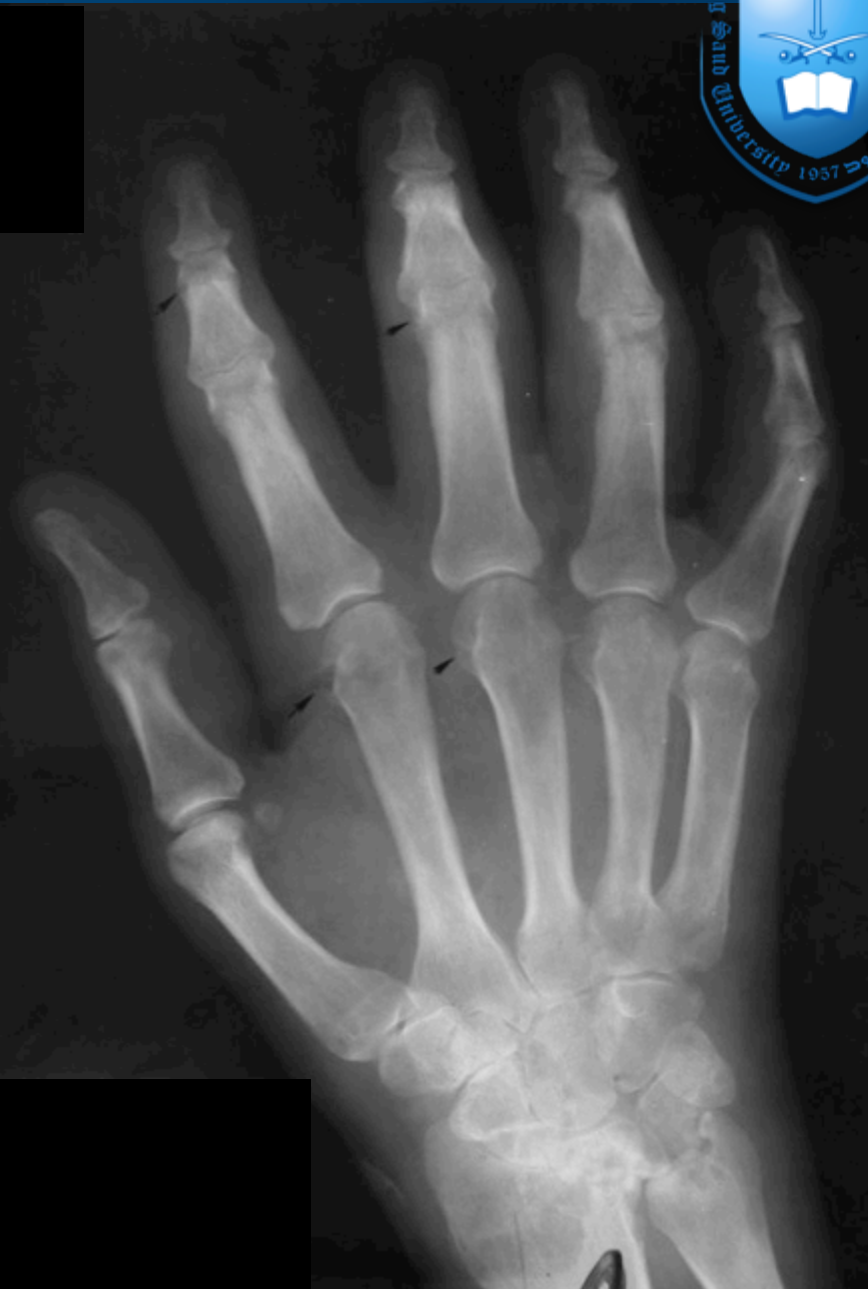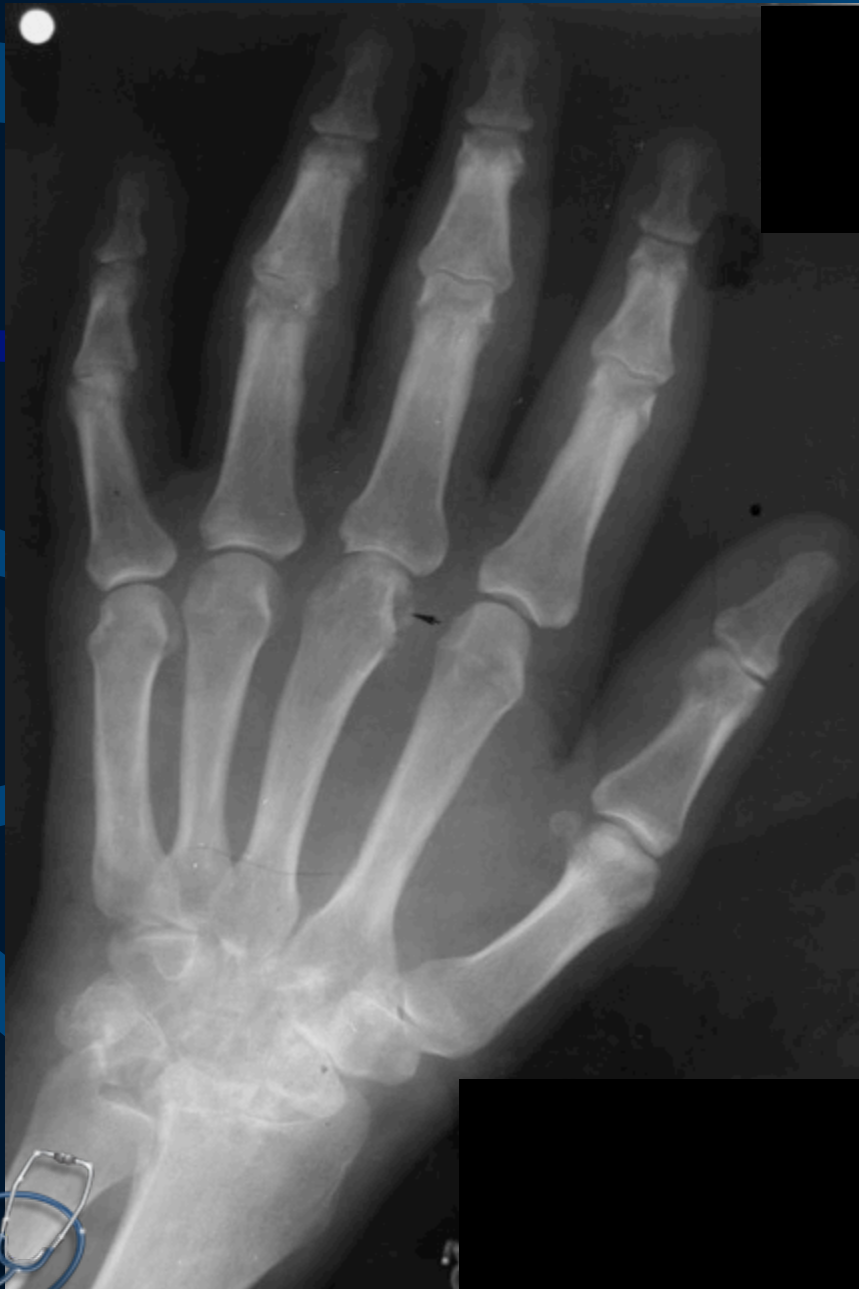
## **CASE NO. 4**

48 years- old female presented with joint  
pain of the hands & feet  
X-ray of hand requested

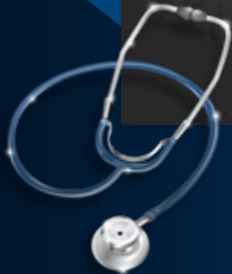
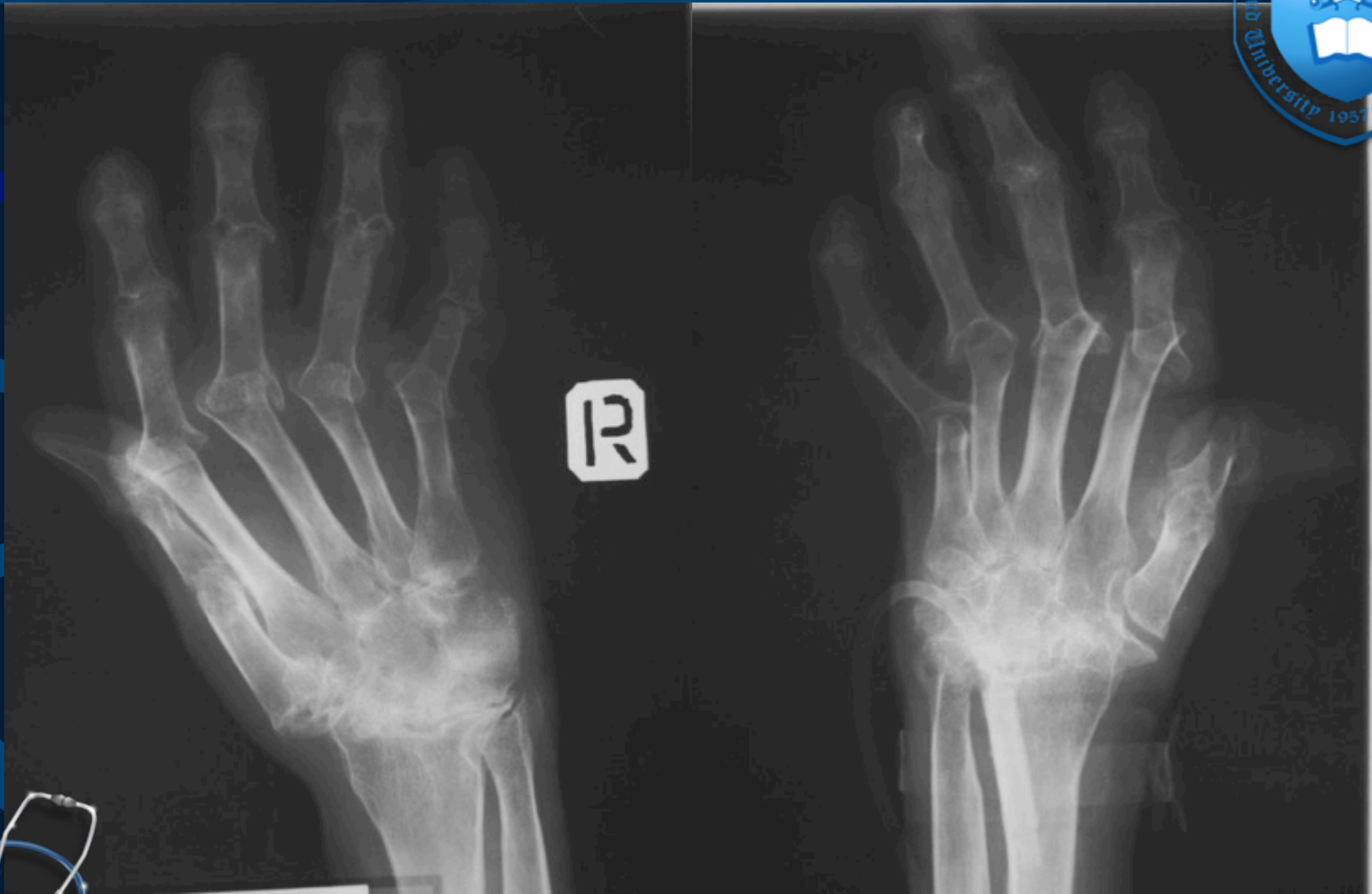










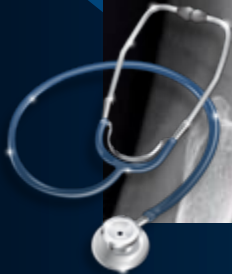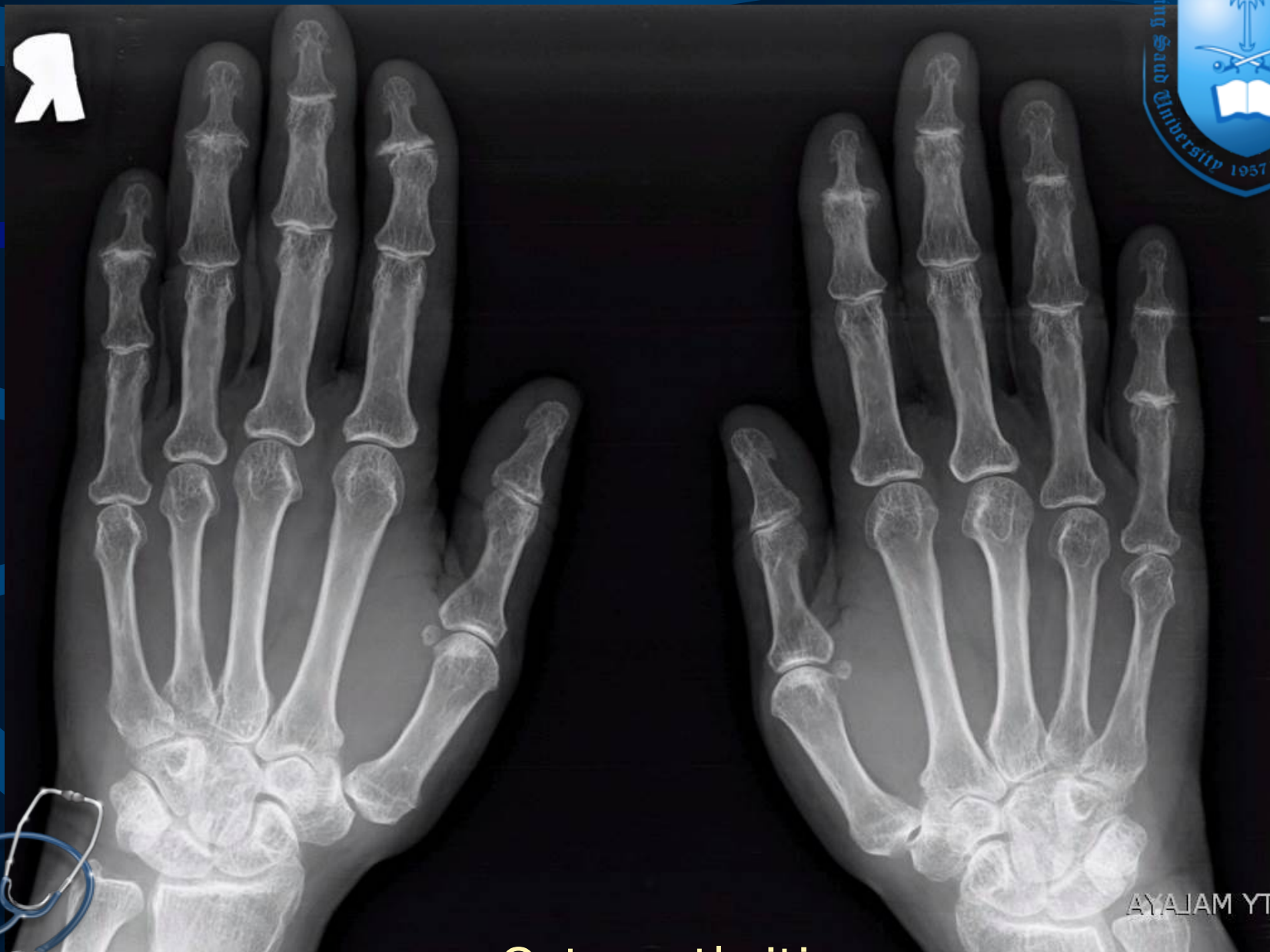
***Rheumatoid Arthritis***



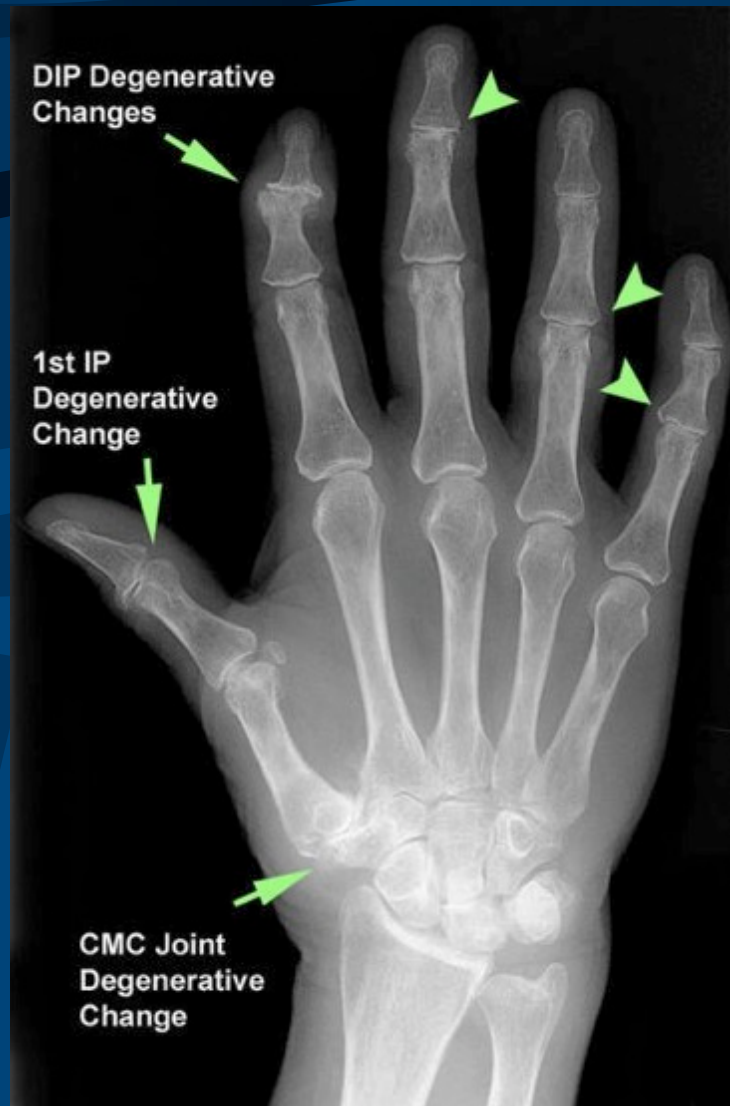## **CASE NO. 5**

Elderly male patient presented with joint pain  
of the hands X-ray of hand requested





Osteoarthritis



# Imaging the Musculoskeletal System 2015

Se: /3  
Im: 1/1

HAND  
SUPINE

Mag: 0.4x  
Lat: L

Acc: 24337AO  
2007 Mar 08: /3  
Acq Tm: 08:38:15: 2/1

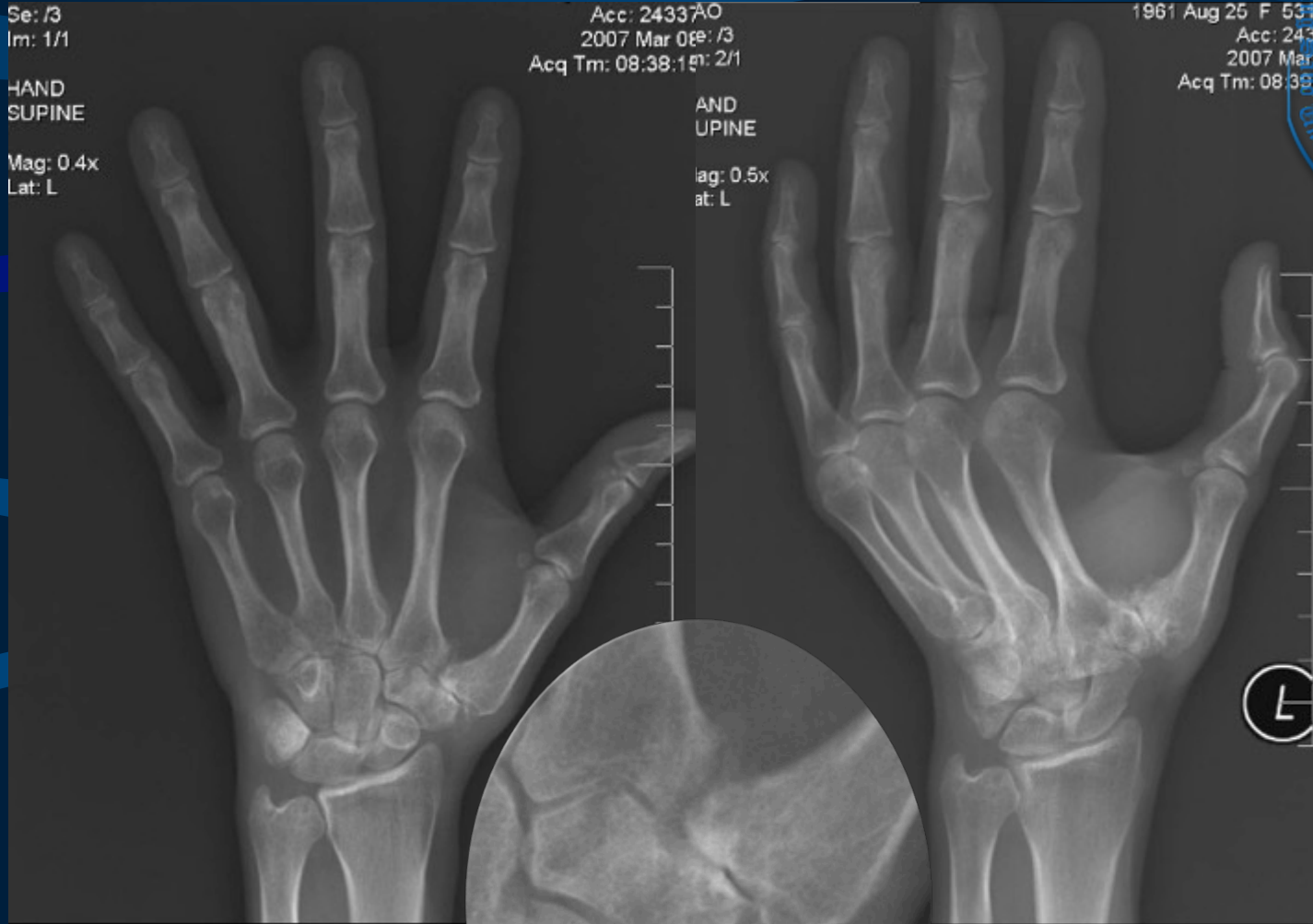AND  
UPINE

Mag: 0.5x  
Lat: L

1961 Aug 25 F 53:4

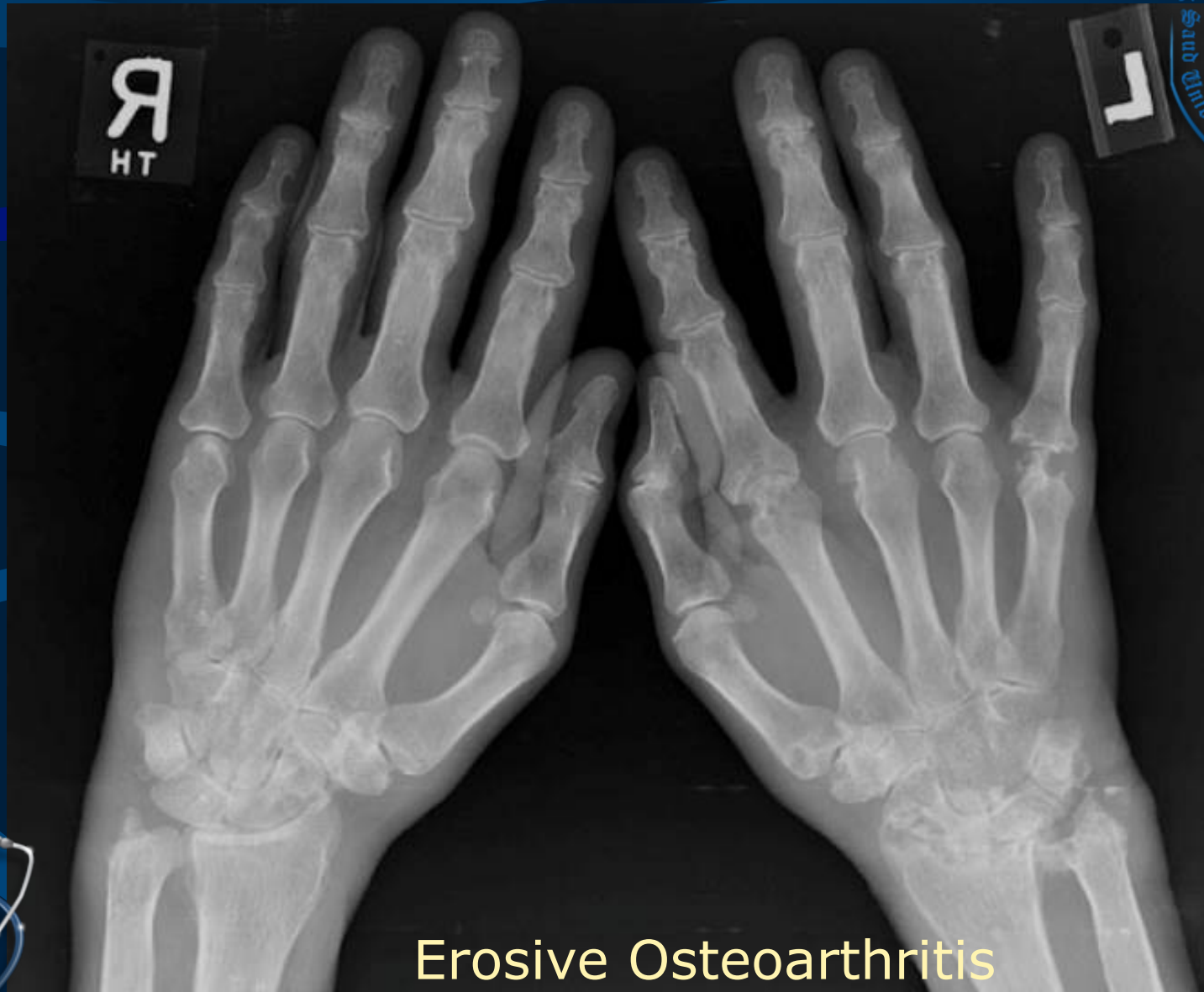Acc: 24337  
2007 Mar 08: /3

Acq Tm: 08:39:33

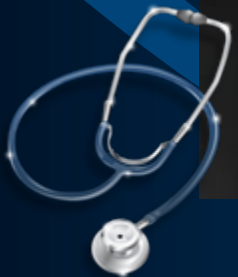

Osteoarthritis



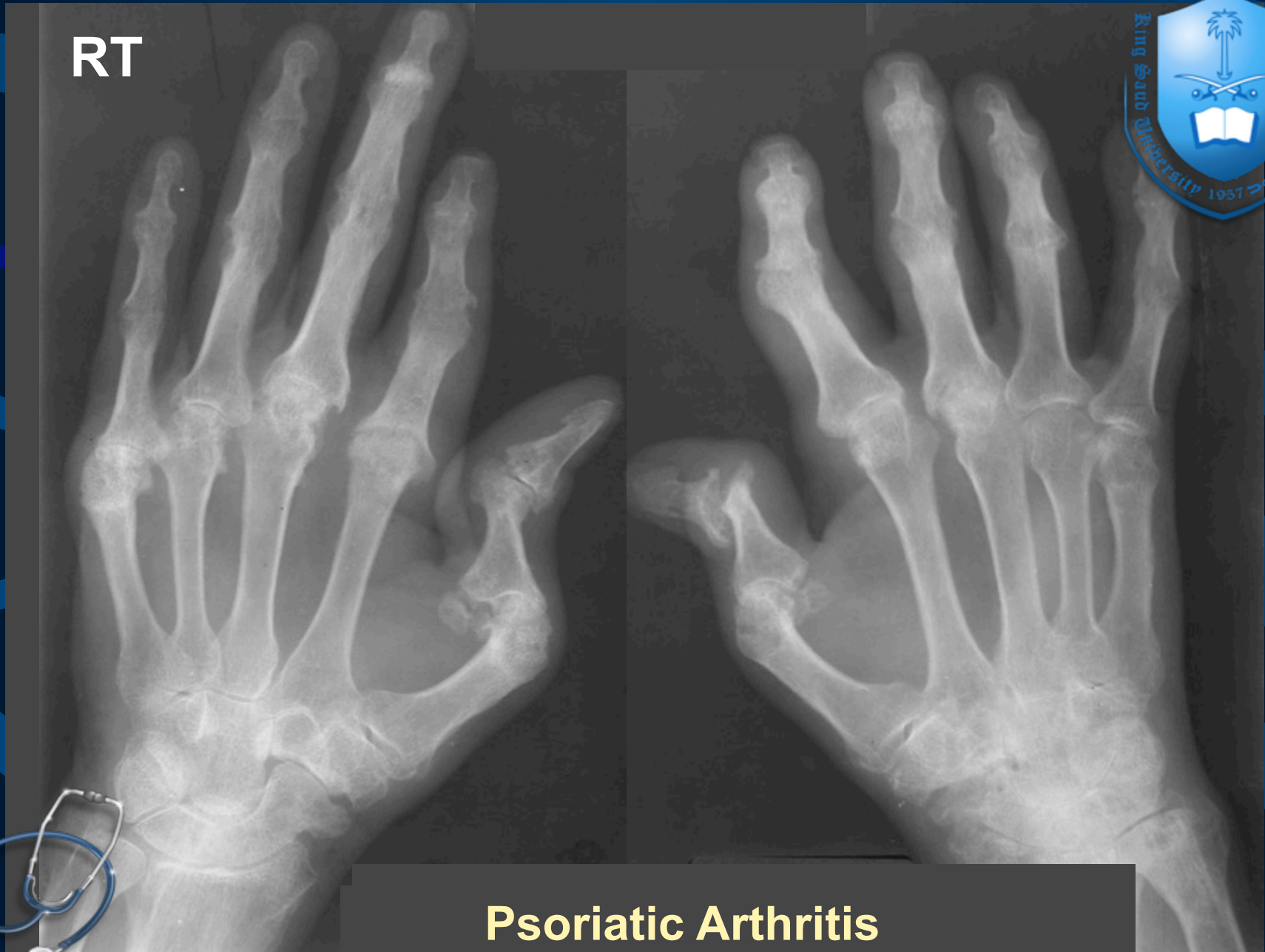

Erosive Osteoarthritis





RT



**Psoriatic Arthritis**

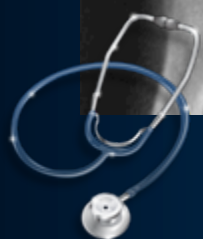
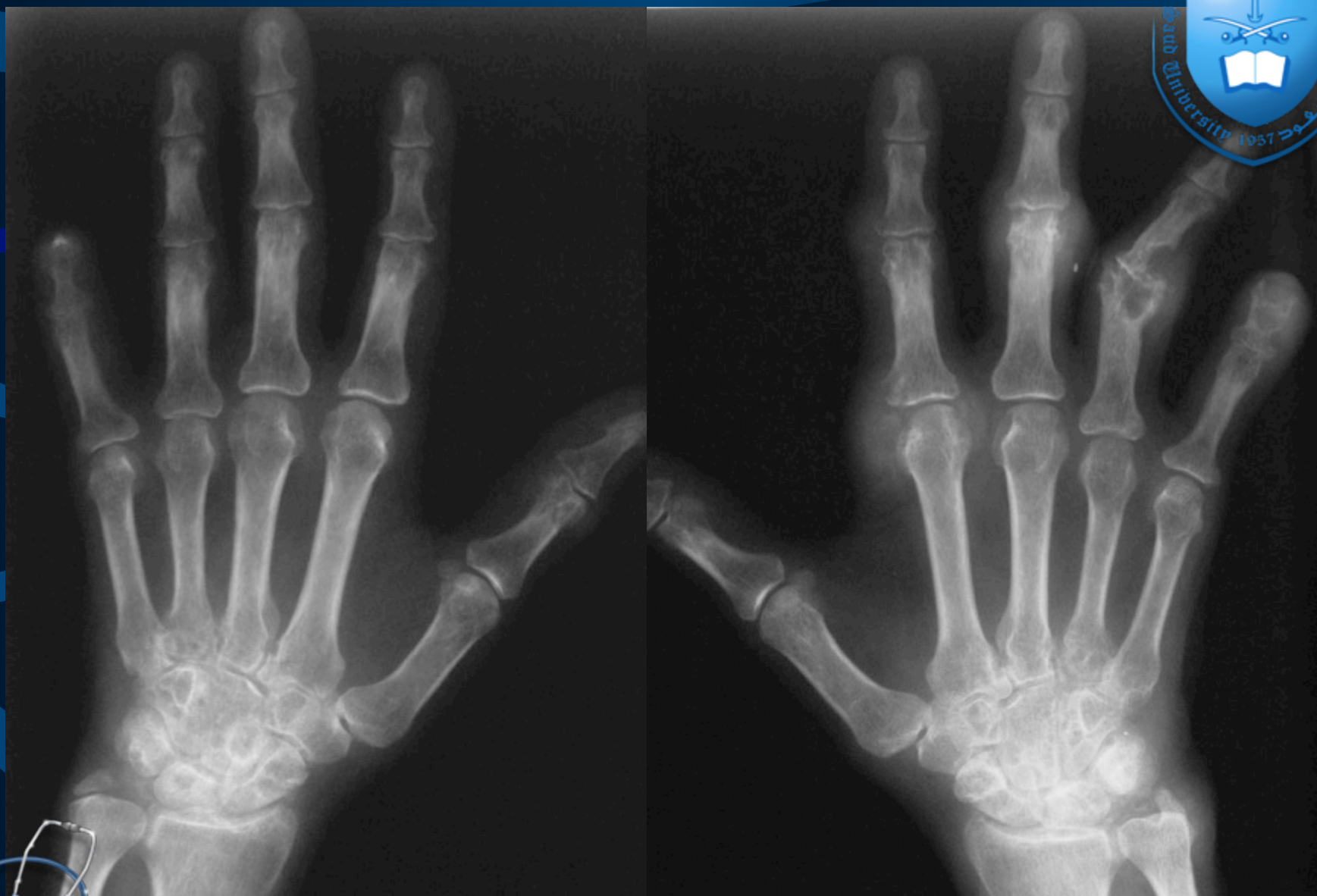
## **CASE NO. 6**

43 year-old male patient presented with  
hands and feet pain and swelling  
X-ray of hand requested







Gouty Arthritis



# *Musculoskeletal Tumors*

- ✓ Osseous
- ✓ Chondral
- ✓ Fibrous
- ✓ Soft tissue





# Musculoskeletal Tumors

## KEY FEATURES

- ✓ Morphology
- ✓ Behavior of lesion
- ✓ Age of patient
- ✓ Site (Location)

*Pattern of bone destruction*

*Size, Shape & Margin of lesion*

*Texture of lesion Matrix*

*Cortex & Periosteal reaction*



# Musculoskeletal Tumors

## KEY FEATURES

- ✓ **Morphology**
- ✓ **Behavior of lesion**
- ✓ Age of patient
- ✓ Site (Location)

*Pattern of bone destruction*  
*Size, Shape & Margin of lesion*

*Texture of lesion Matrix*  
*Cortex & Periosteal reaction*

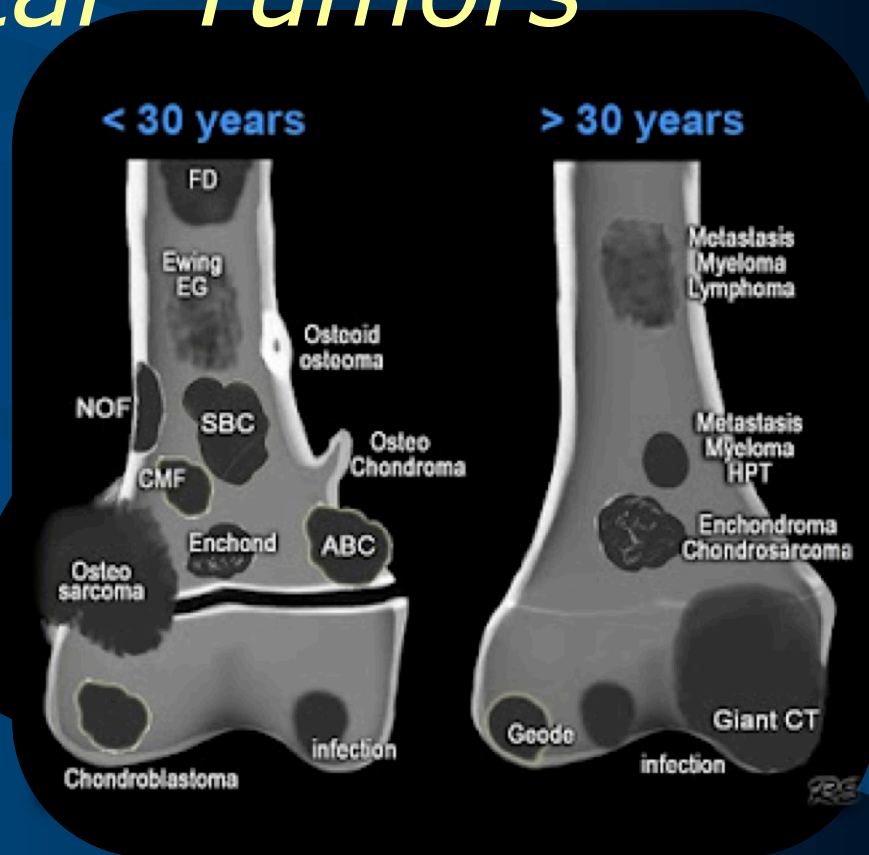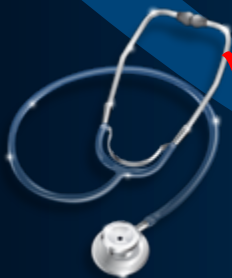Geographic



# Musculoskeletal Tumors

## KEY FEATURES

- ✓ Morphology
- ✓ Behavior of lesion
- ✓ Age of patient
- ✓ Site (Location)





# Musculoskeletal Tumors

Osseous

Sclerotic

Lytic

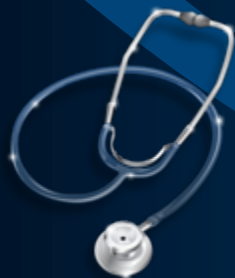Mixed



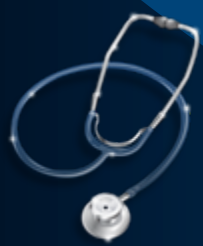
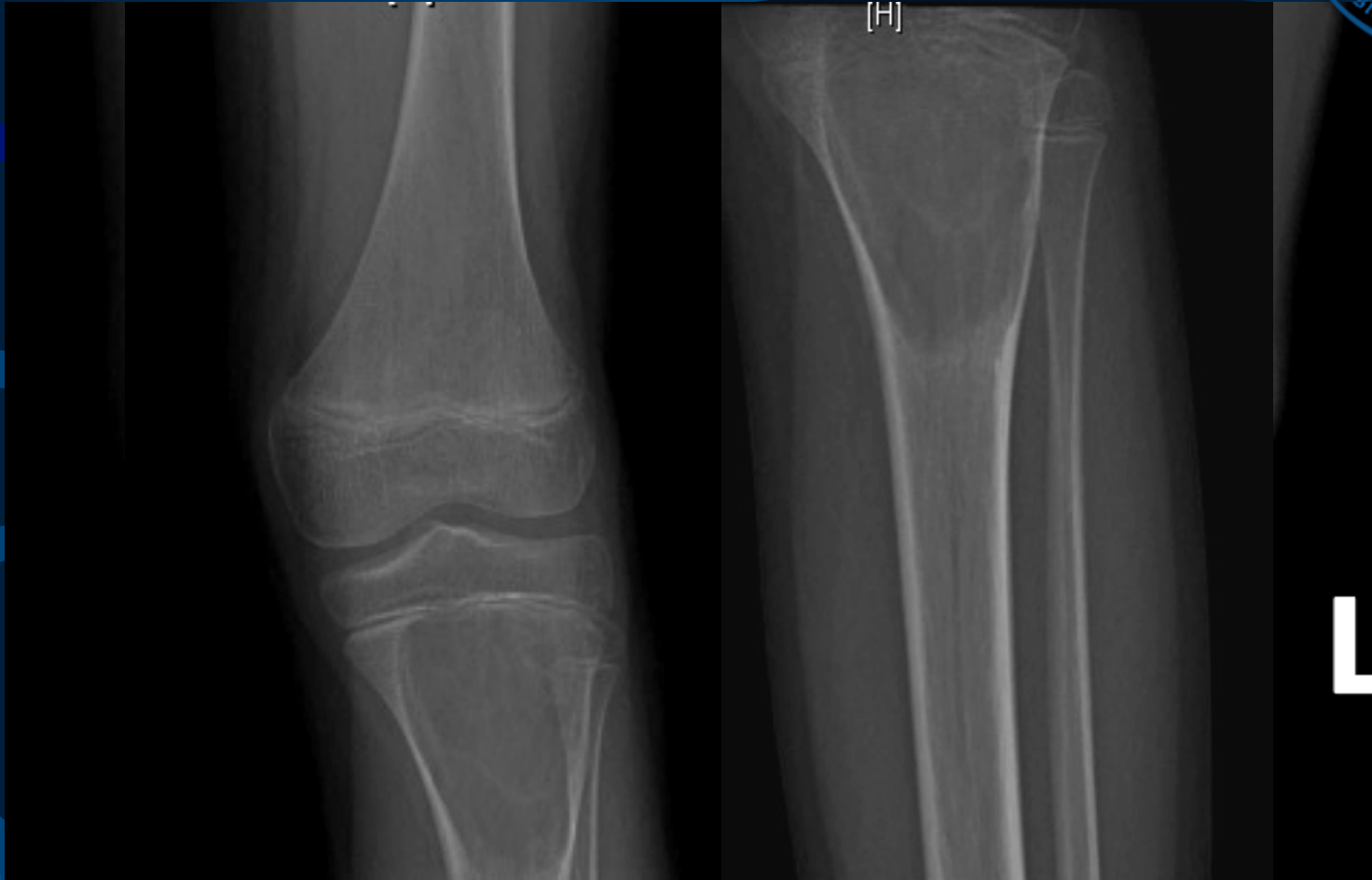
## CASE NO. 7

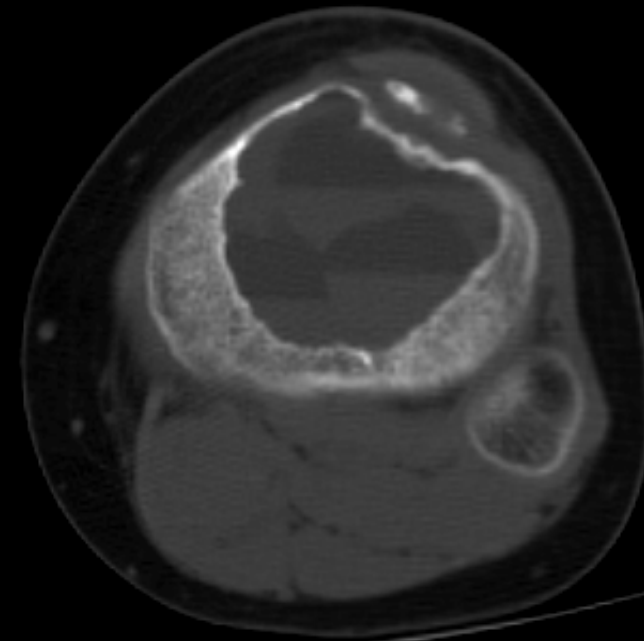
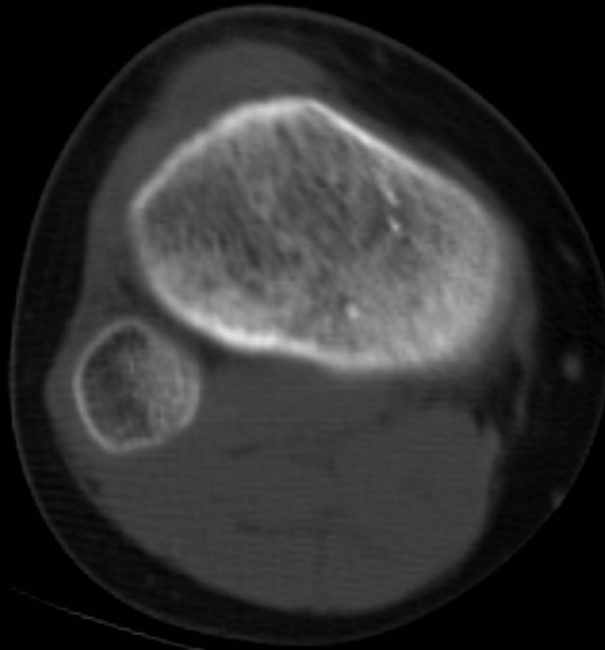
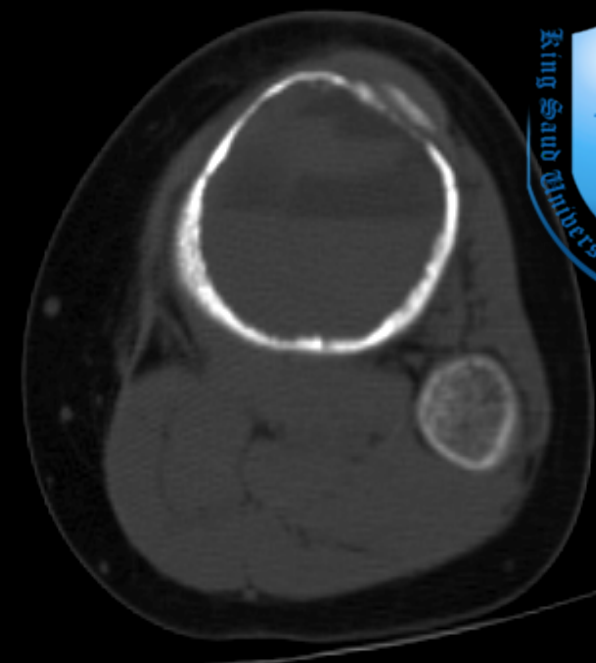
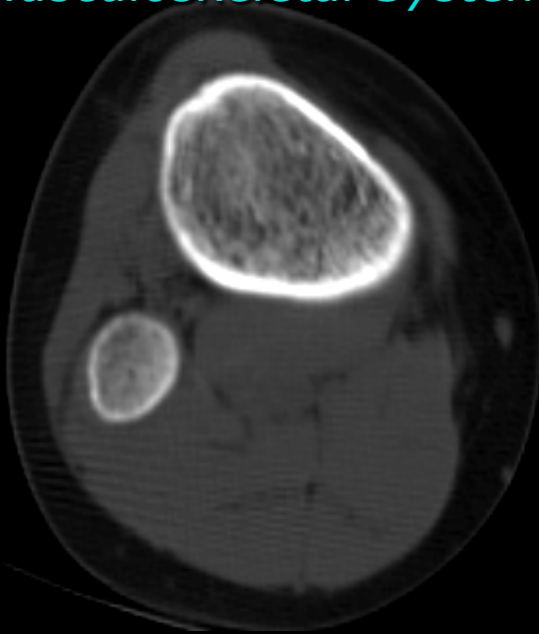
13 year-old boy patient presented with knee  
pain and swelling  
X-ray of knee requested



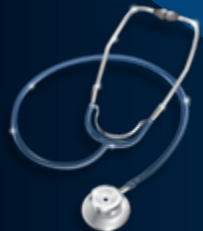

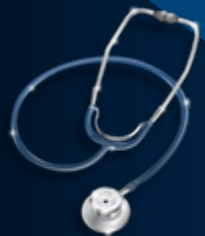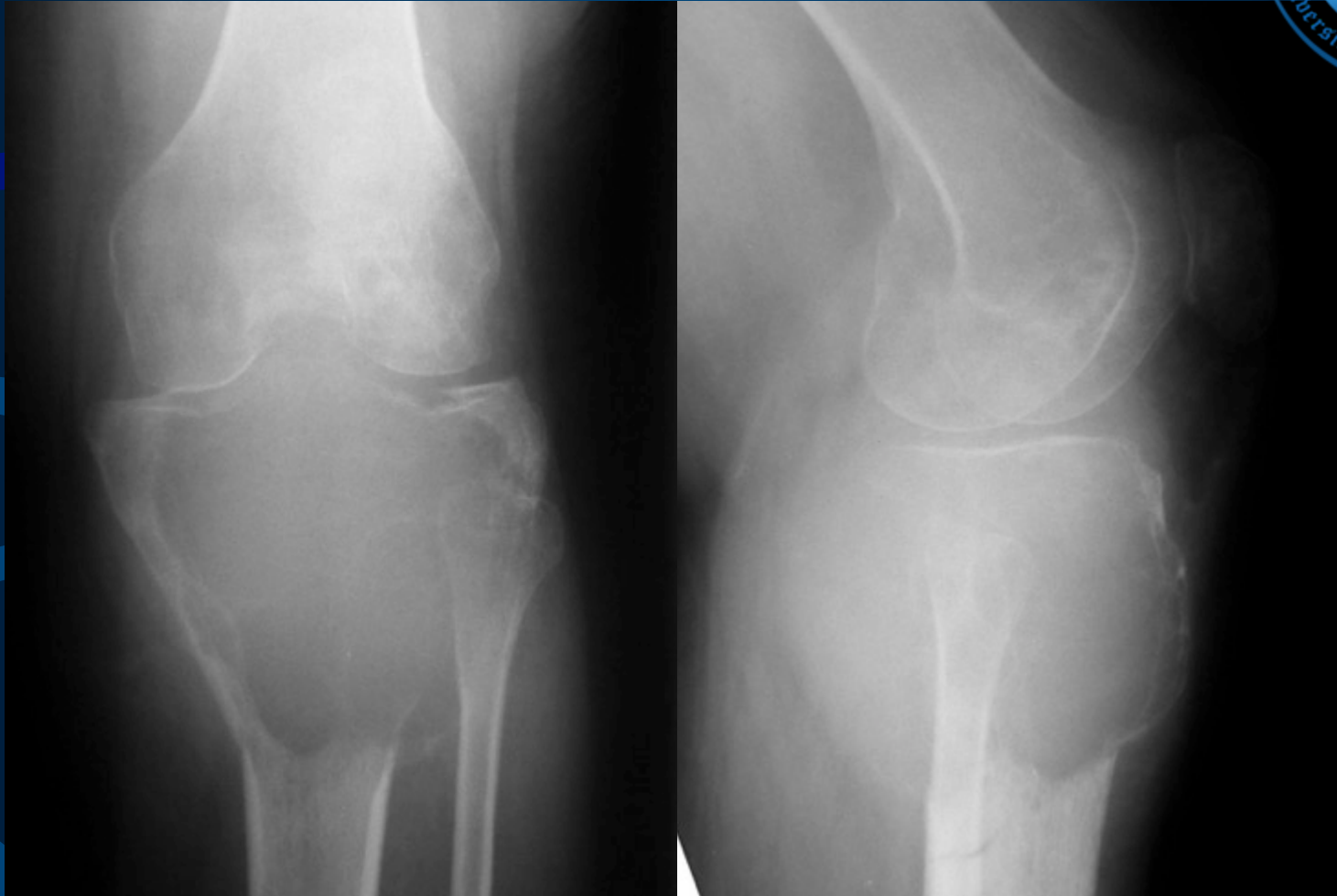






study 11  
R

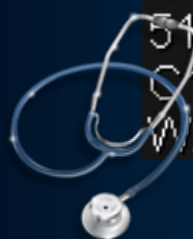





[H] ...LOWER EXT. 11/4/2001 64-30-46 5594  
F 8 TR 416.7 ms 10  
TE 9.0 ms  
TI ms  
[AL]  
SP: 87.8mm  
ST: 5.0mm  
512x512  
C1135  
W2707  
[F] ...L SYSTEMS C1135  
...SIS\_SIGNA W2707

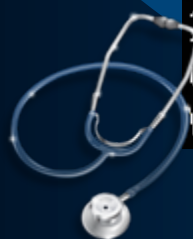[H] ...LOWER EXT. 11/4/2001 64-30-46 5594  
F 8 TR 416.7 ms 10  
TE 9.0 ms  
TI ms  
[PR] [AL]  
SP: 76.8mm  
ST: 5.0mm  
512x512  
C1135  
W2707  
[F] ...L SYSTEMS C1135  
...SIS\_SIGNA W2707

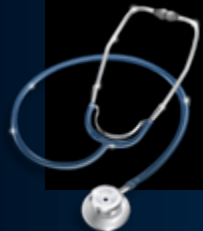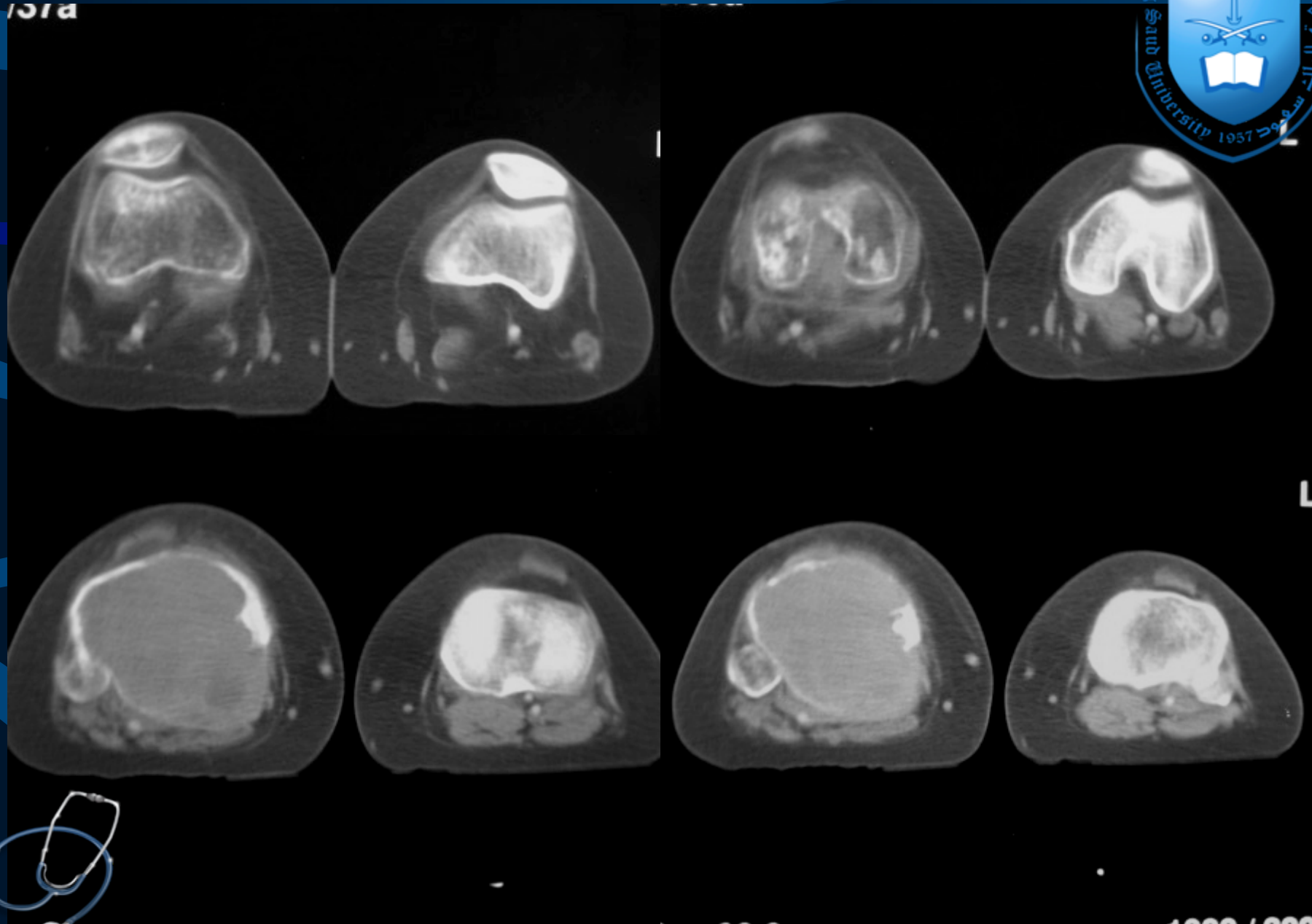




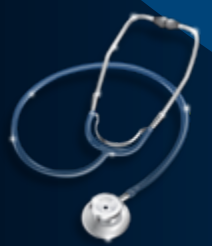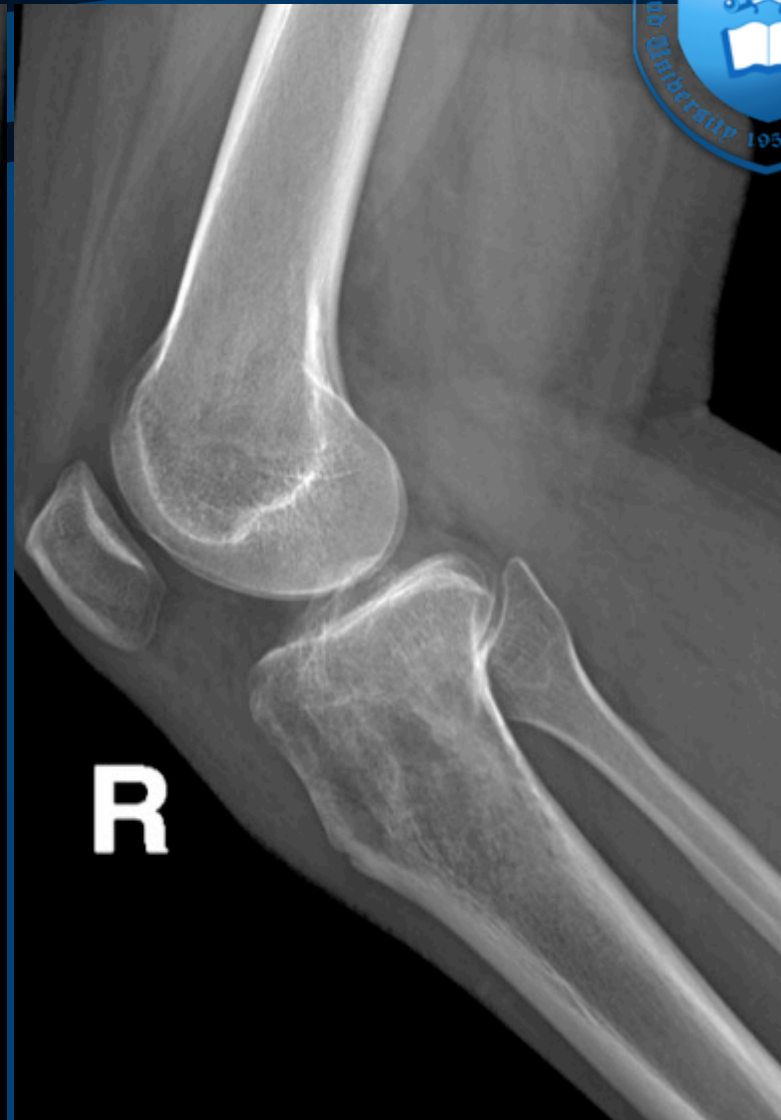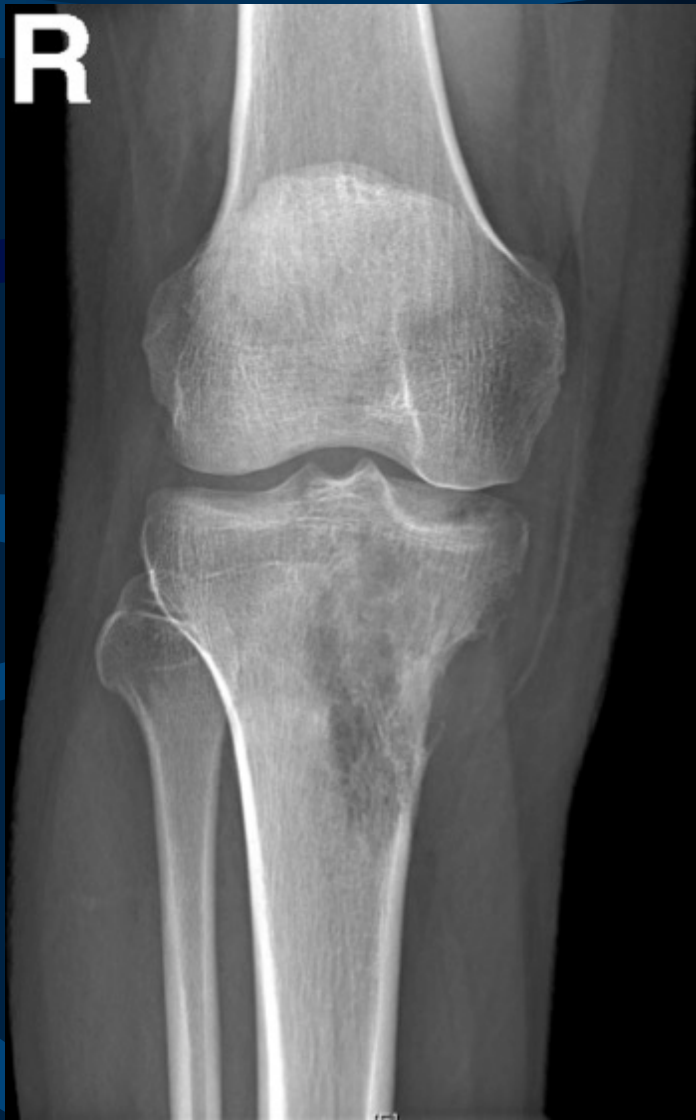[H] ...LOWER EXT. 11/4/2001 64-30-46 5594  
F 8 TR 5350.0 ms TE 13.0 ms TI 150.0 ms  
[AL] [PR] [AL]  
SP: 87.8mm ST: 5.0mm 256x256  
C579 ...L SYSTEMS C594  
W1158 [F] ...SIS\_SIGNA W1189

[H] ...LOWER EXT. 11/4/2001 64-30-46 5594  
F 9 TR 5350.0 ms TE 13.0 ms TI 150.0 ms  
[AL] [PR] [AL]  
SP: 82.3mm ST: 5.0mm 256x256  
...L SYSTEMS C594  
[F] ...SIS\_SIGNA W1189

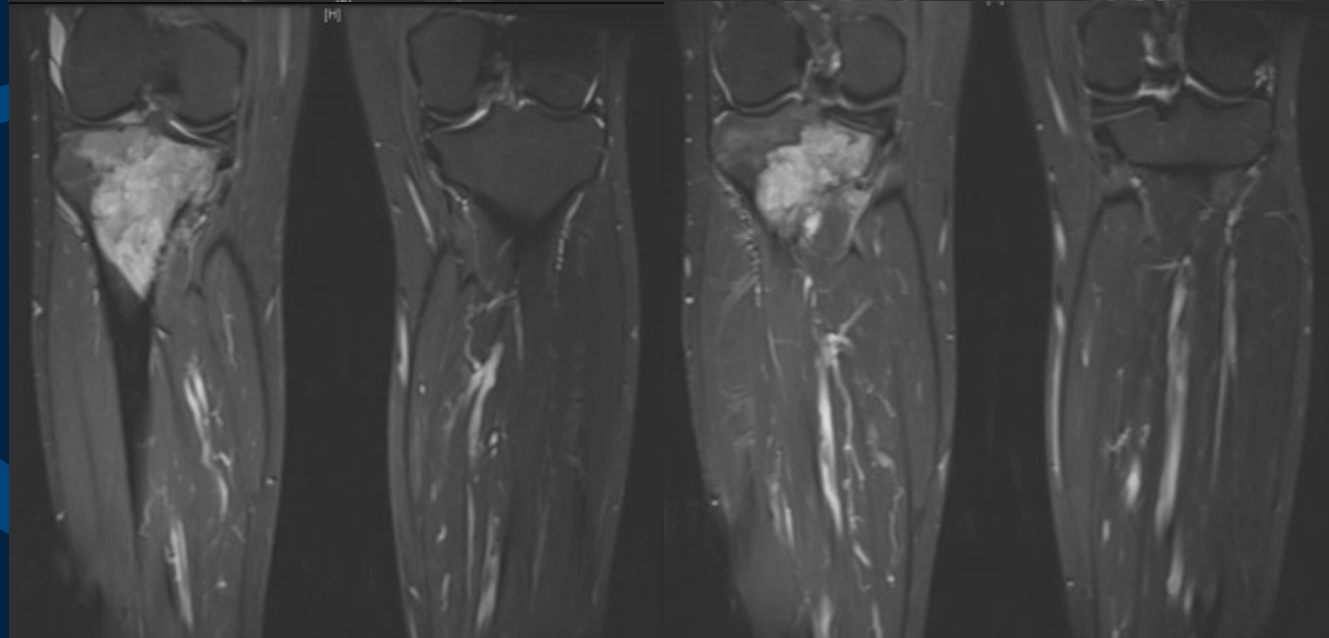
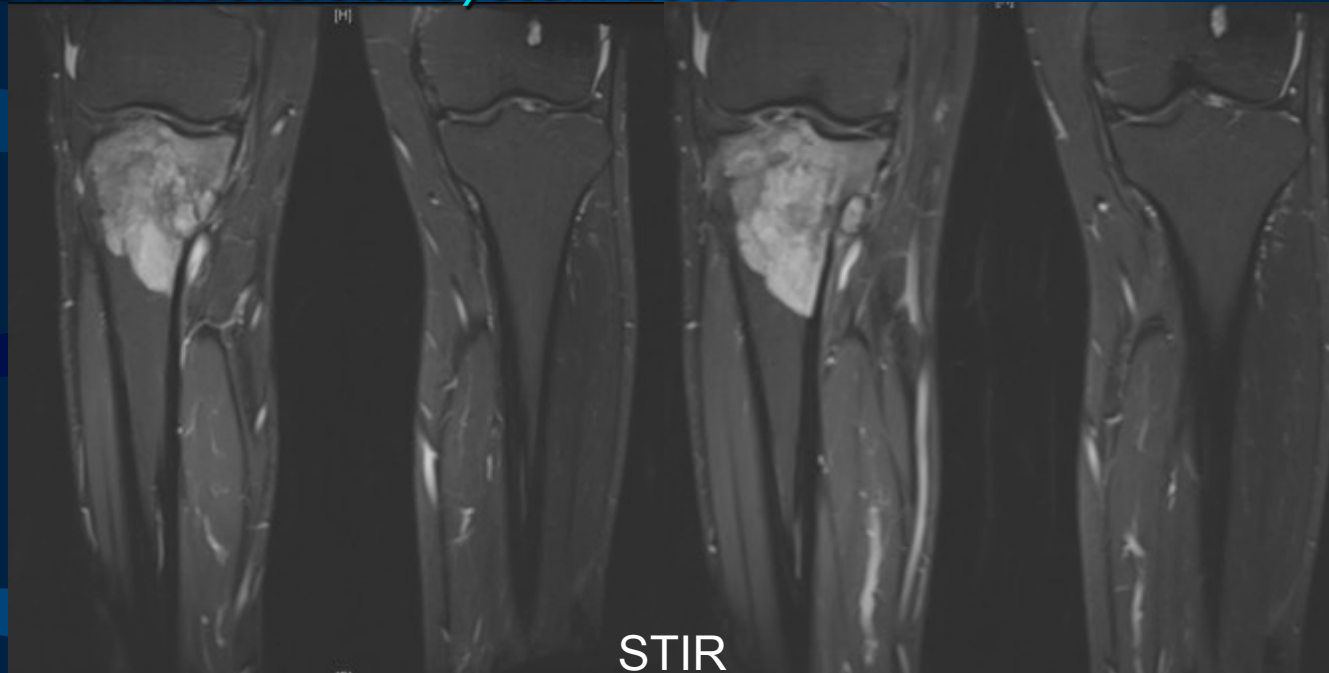


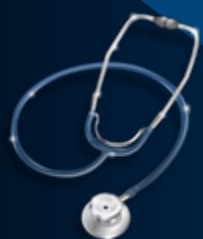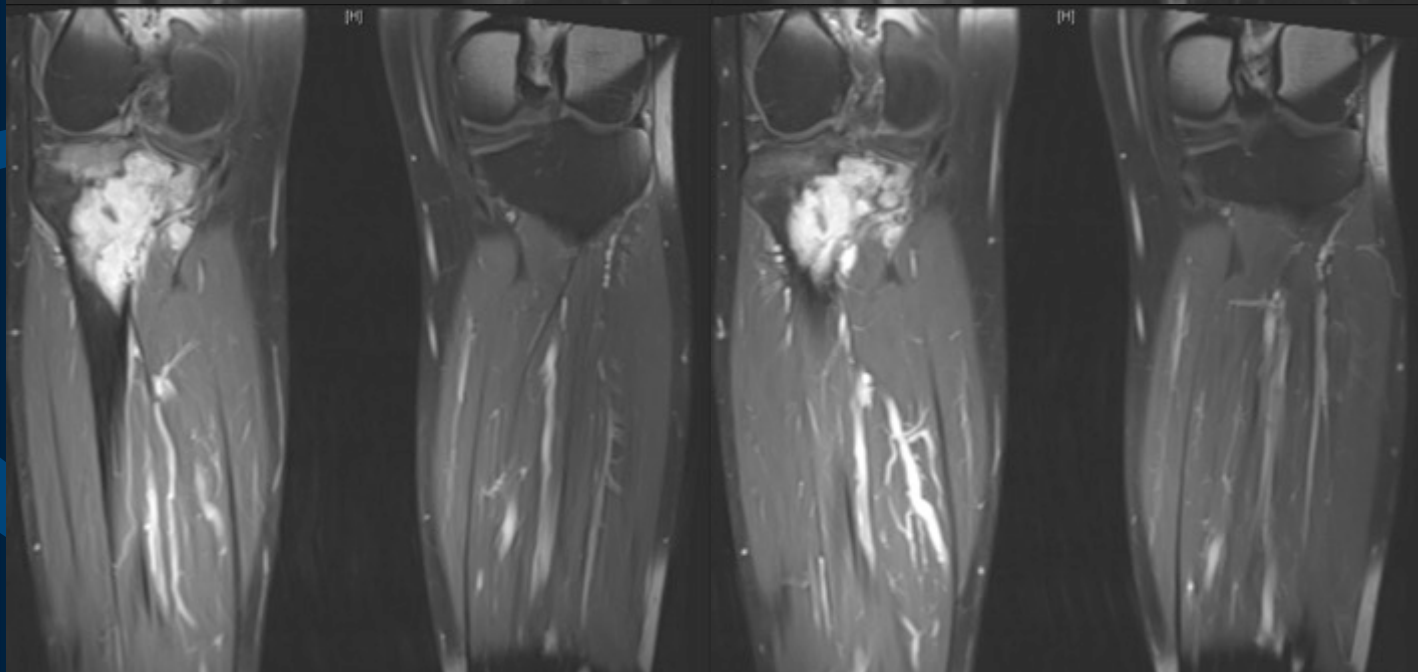


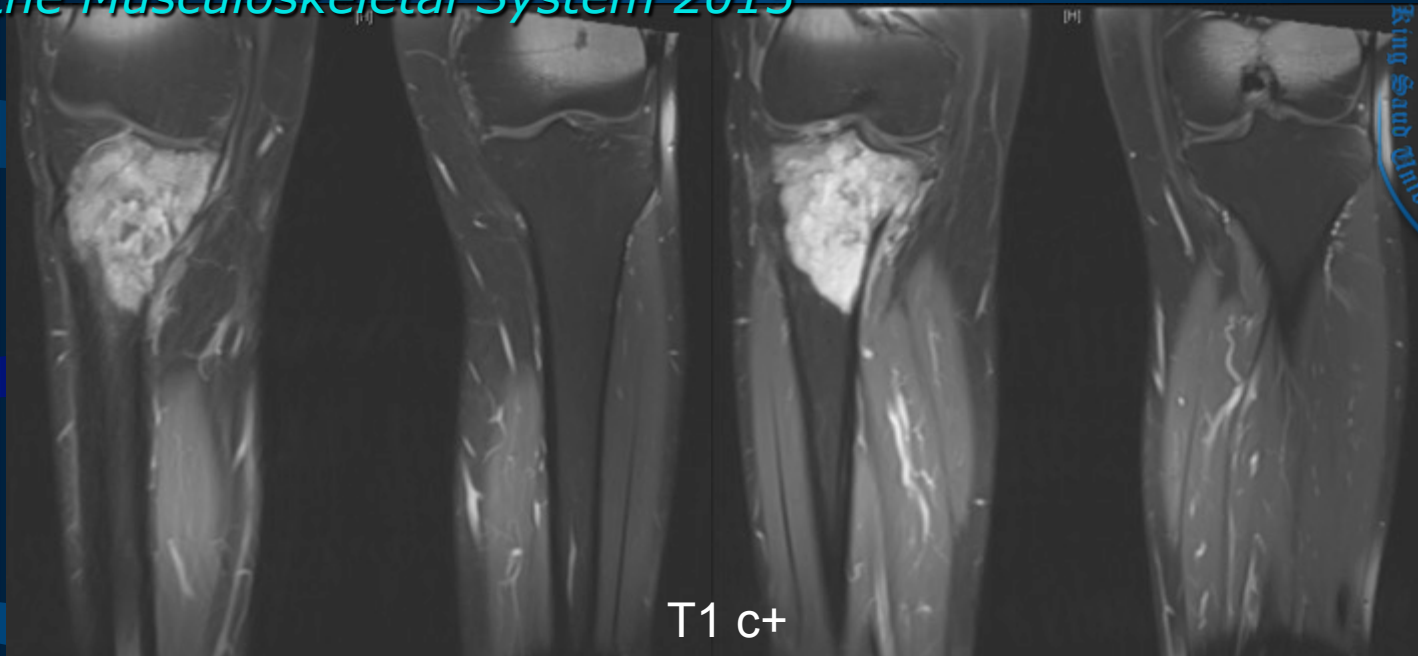









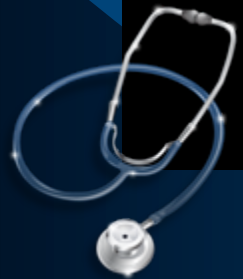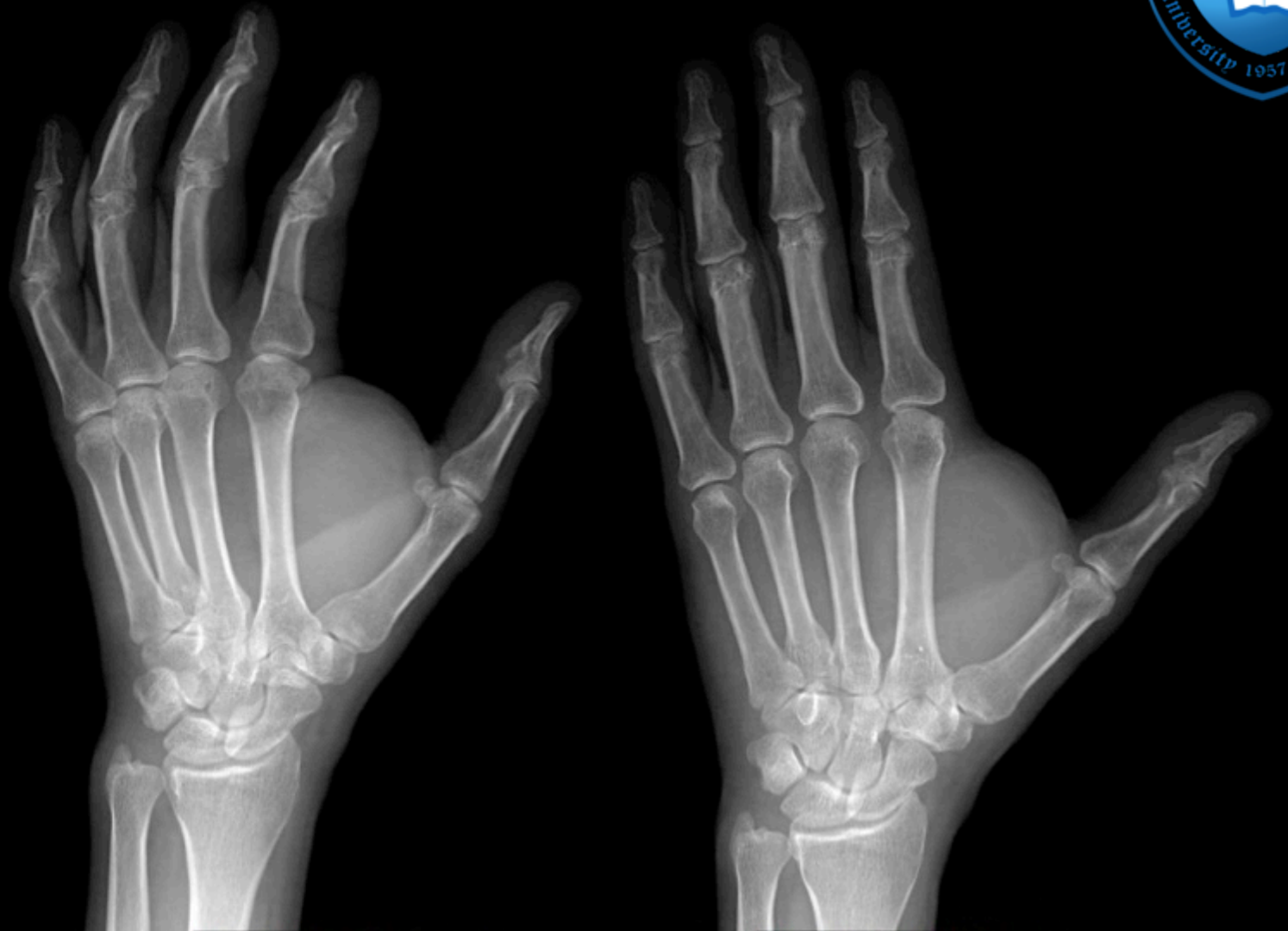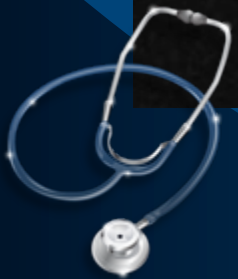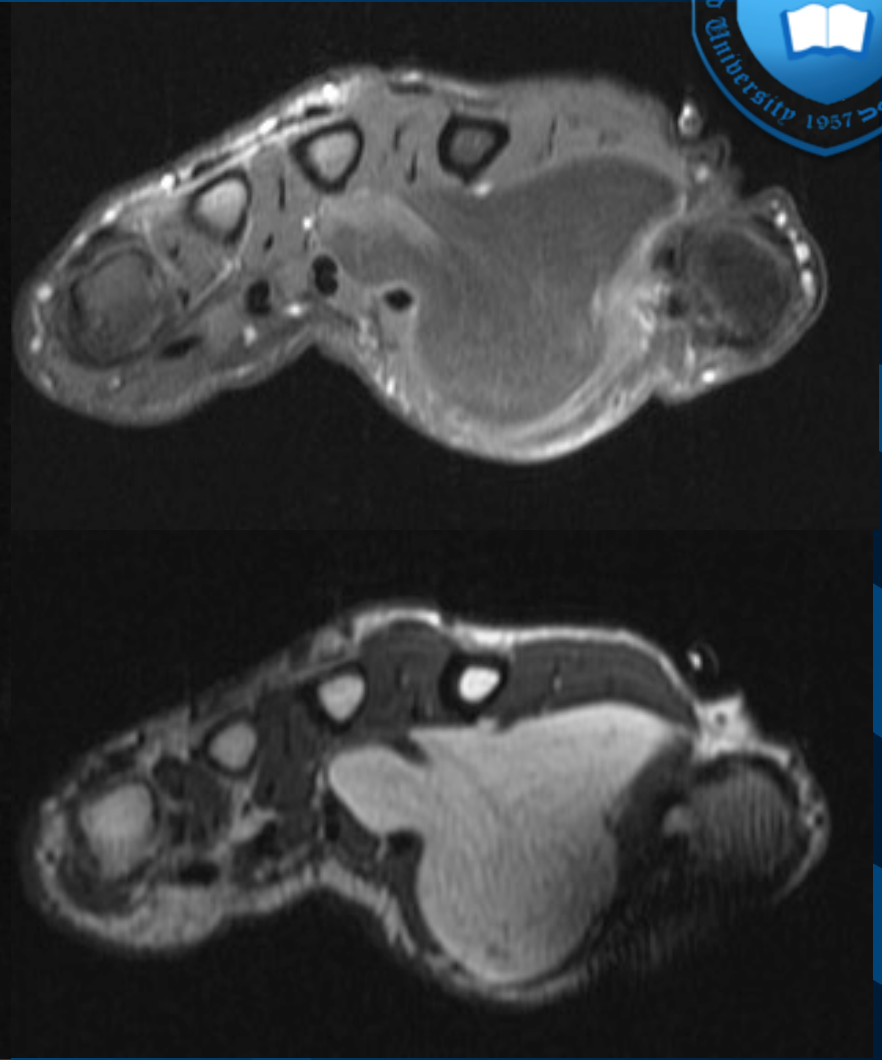
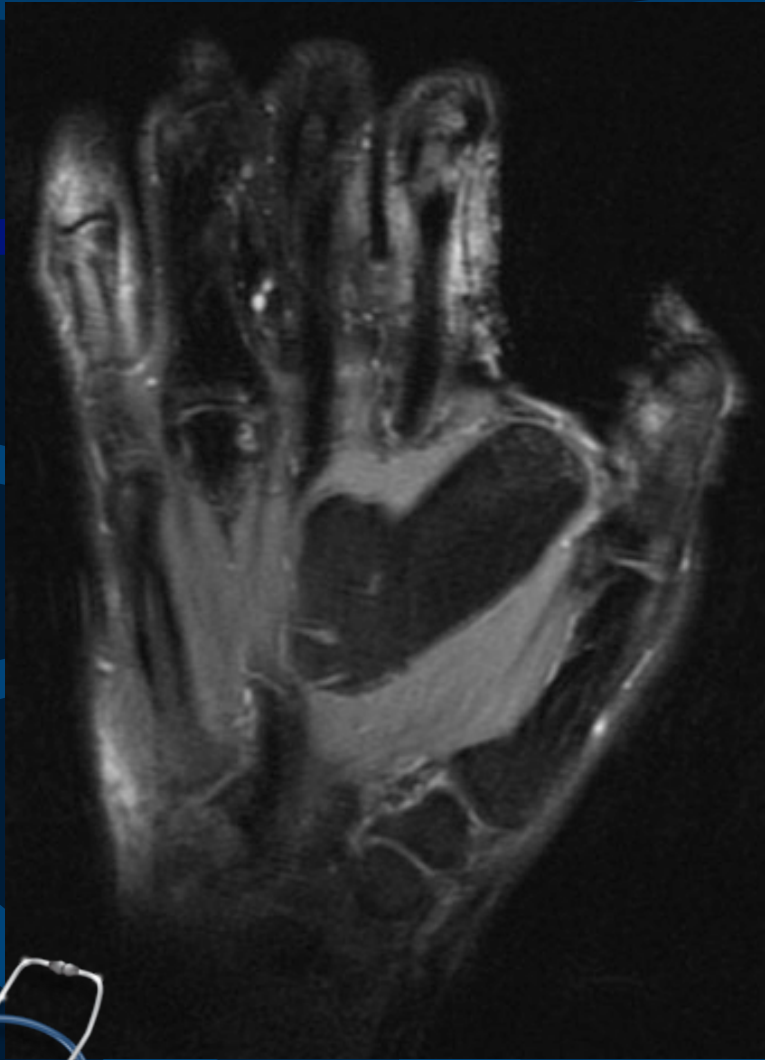


## **CASE NO. 8**

Adult female patient presented with hand swelling  
X-ray of hand requested








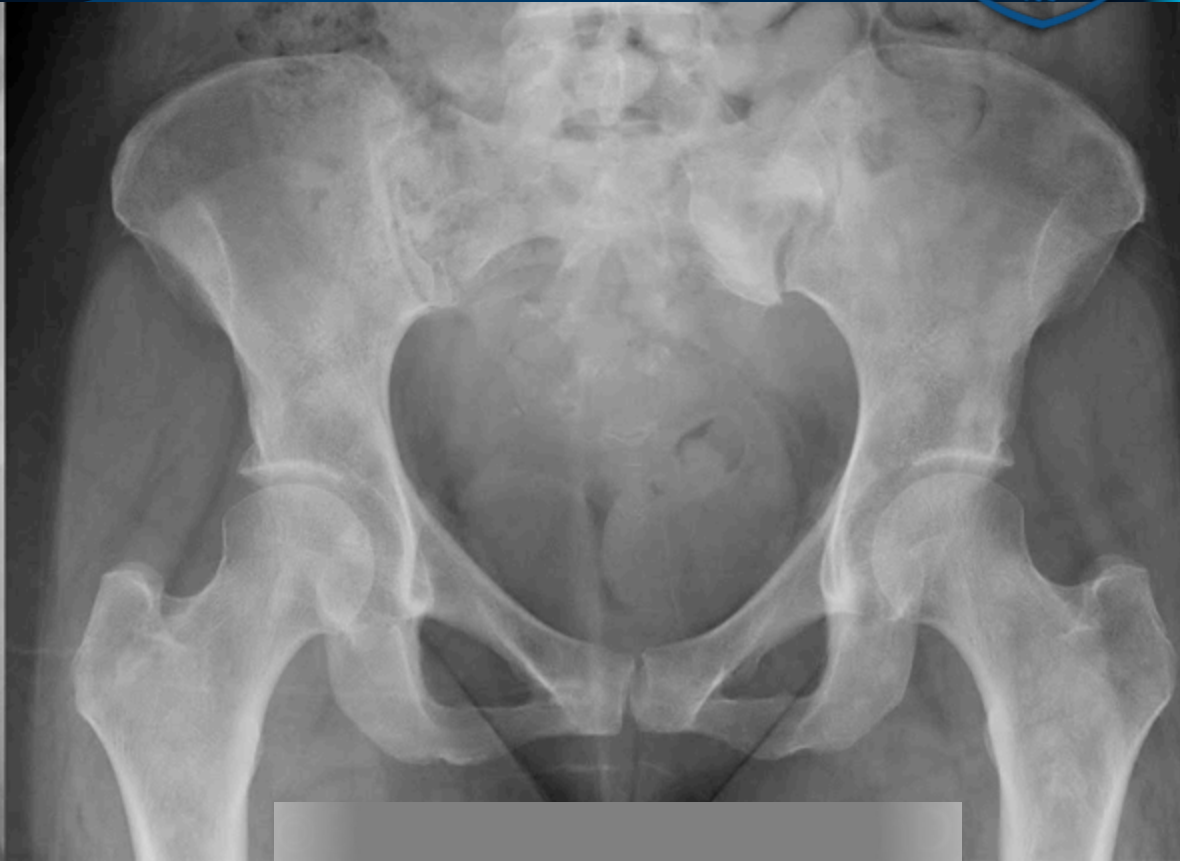
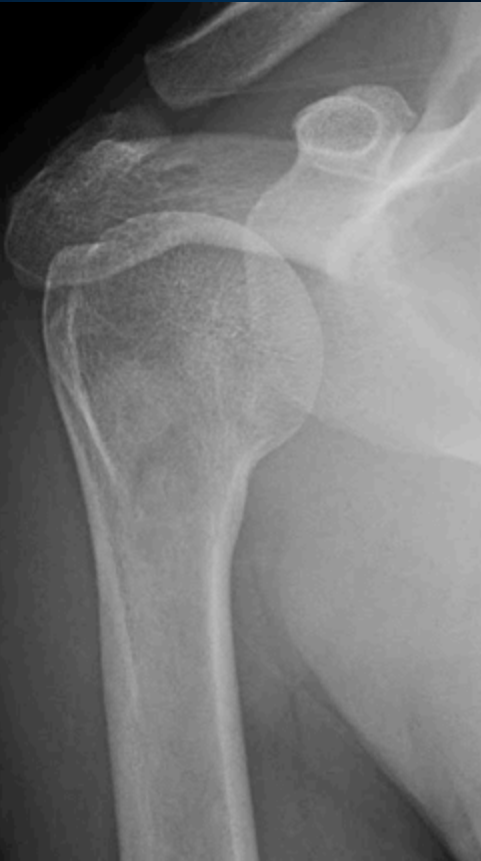## **CASE NO. 9**

57 years old female patient presented with bone ache  
Had history of breast carcinoma









# Summary

- Metabolic & Endocrine Disorders:
  - Osteomalacia.
  - Osteoporosis.
  - HPT/ROD.
  - Acromegaly.
- Arthritis.
  - Rheumatoid Arthritis.
  - Osteoarthritis.
  - Psoriatic Arthritis.
  - Gout.
- Musculoskeletal Tumors:
  - Benign (Non-aggressive).
  - Malignant (Aggressive).

