



Nuclear Medicine Interactive Session

DR. Saleh Othman



▪ **For each case, please answer the following:**

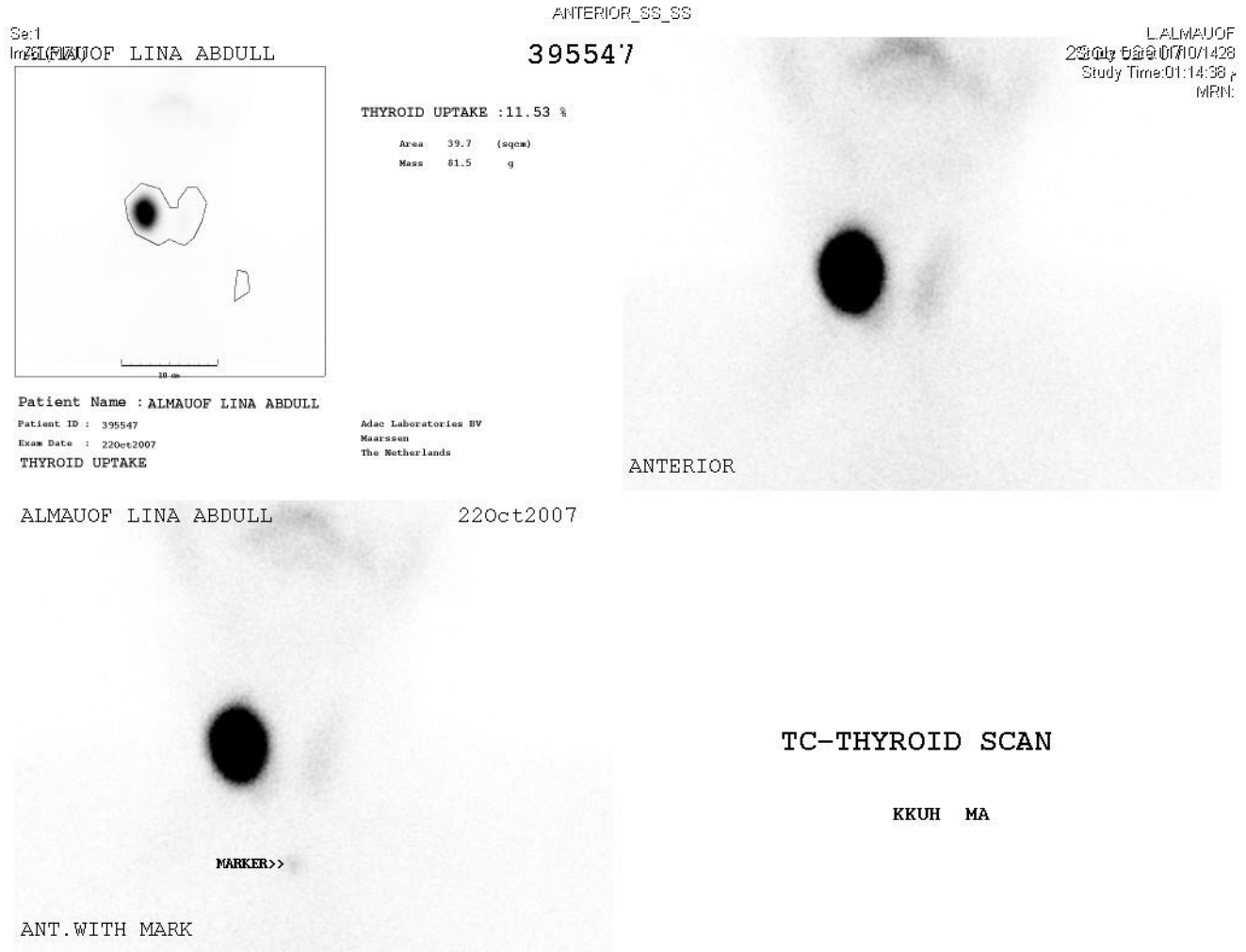
What is the study?

What is the agent used?

What are the imaging findings?

What is the most likely diagnosis?

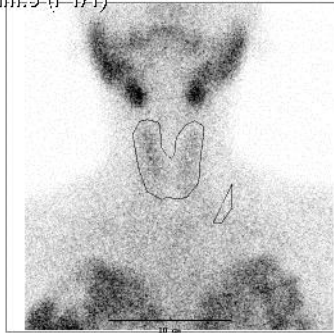
Elevated T4 and suppressed TSH



Elevated T4 and suppressed TSH

Se1
ALBALBISH QADIR
Im5 (F17)

676226



THYROID UPTAKE : 0.20 %

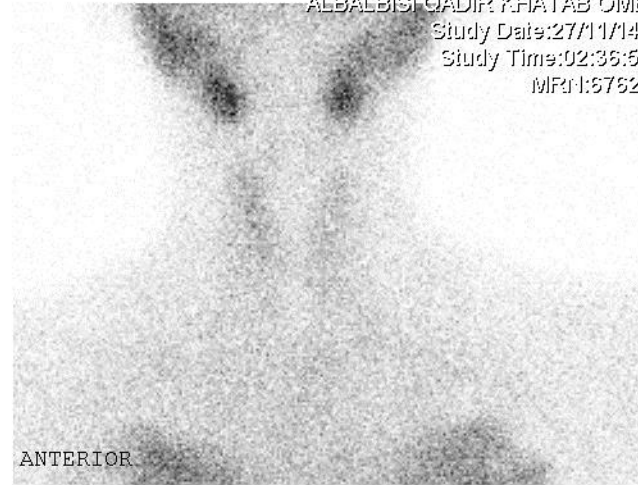Area 28.3 (sqcm)
Mass 49.1 g

Patient Name : ALBALBISH QADIR
Patient ID : 676226
Exam Date : 17Dec2006
THYROID UPTAKE

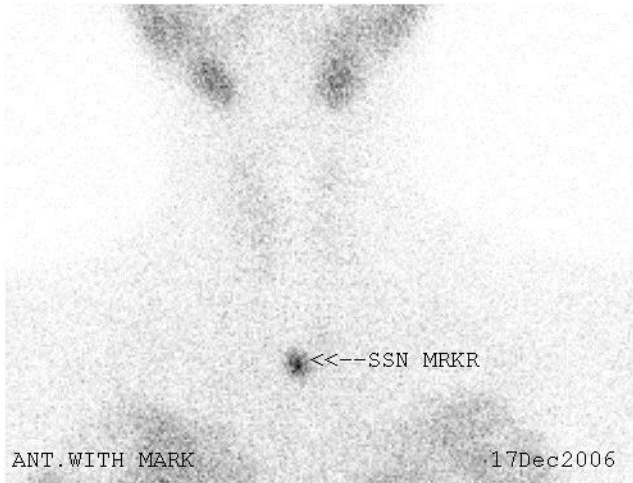Adac Laboratories BV
Maarsse
The Netherlands

ANTERIOR_SS_SS

ALBALBISH QADIR KHATAB OMER
Study Date:27/11/2007
Study Time:02:36:52 p
MFR1:676226



ANTERIOR



ANT. WITH MARK
TH THYROID UPTAKE

17Dec2006

TC THYROID SCAN

KKUH RM3

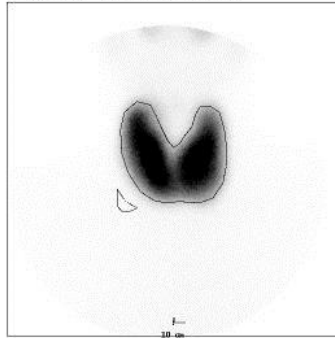
RSM

C128
W256

Elevated T4 and suppressed TSH

Seq:1
Im:9 (F1/I)
SALHA ALSHAHRANI

793268



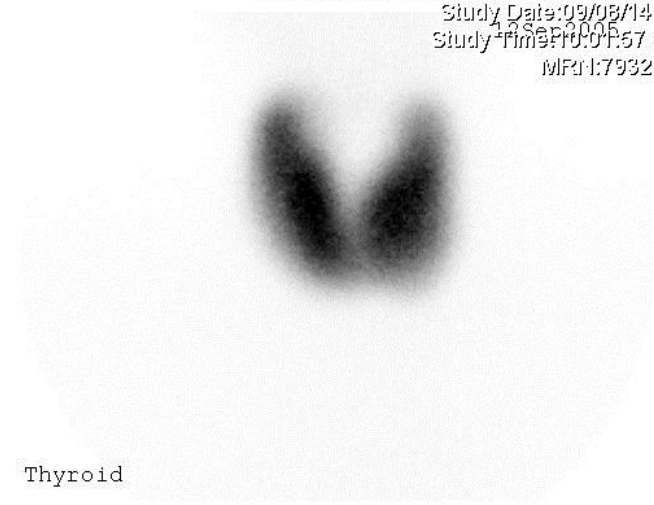THYROID UPTAKE : 24.13 %

Area	0.0	(sqcm)
Mass	0.0	g

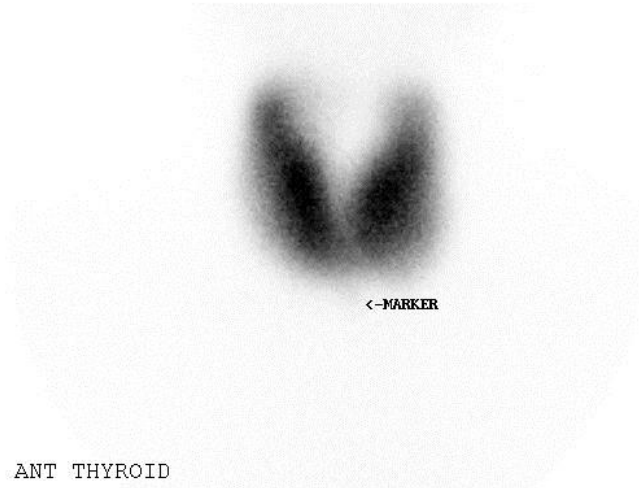Patient Name : SALHA ALSHAHRANI
Patient ID : 793268
Exam Date : 12Sep2005
THYROID UPTAKE

Adac Laboratories BV
Maarsse
The Netherlands

ALSHAHRANI SALHA SAAD ABDULLAH
Study Date: 09/08/1426
12 SEP 2005
Study Time: 09:57
MRN: 793268



Thyroid



<-MARKER

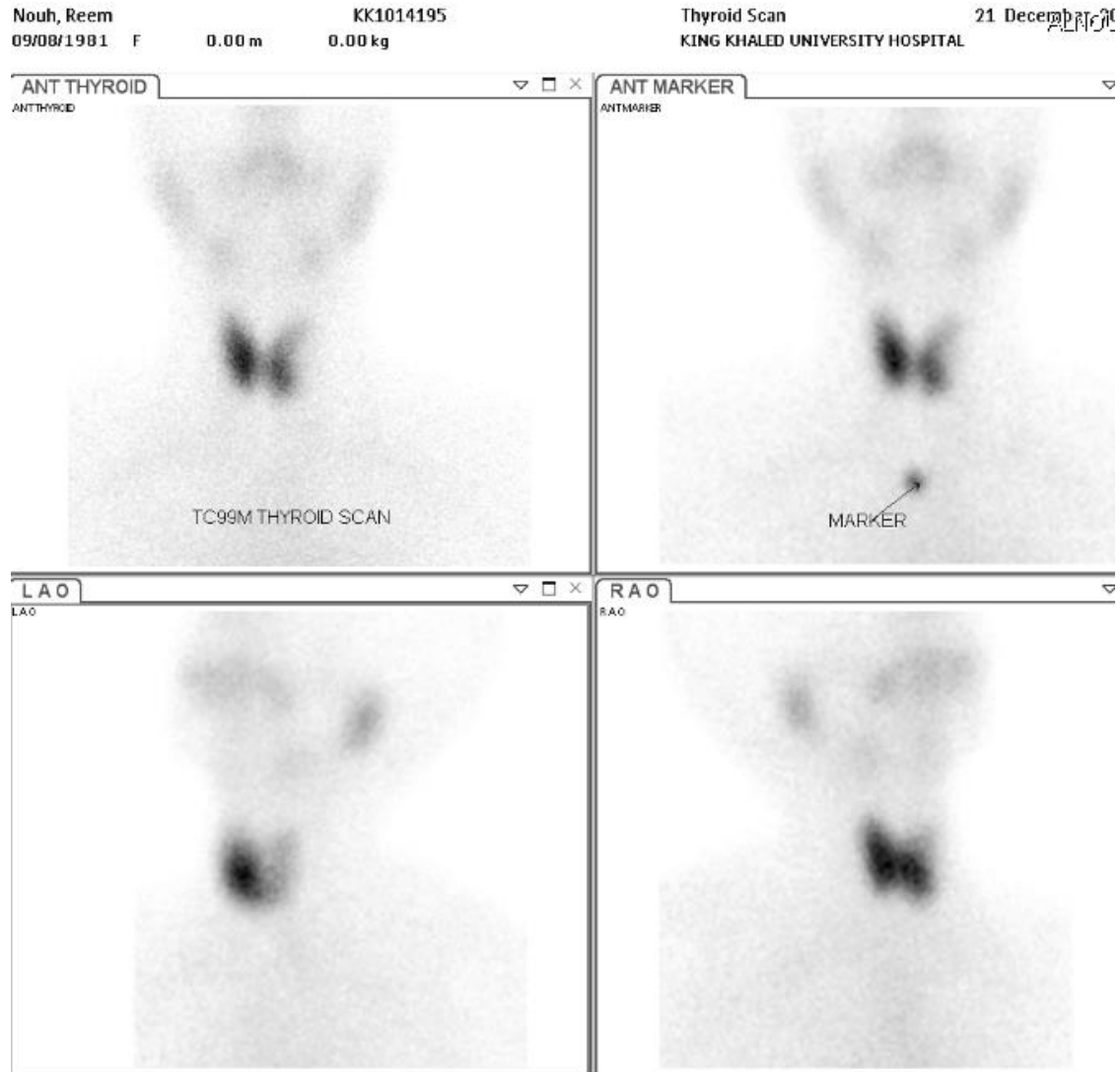
ANT THYROID
Thyroid_SS_SS

TC THYROID UPTAKE

KKUH HS

C128
W256

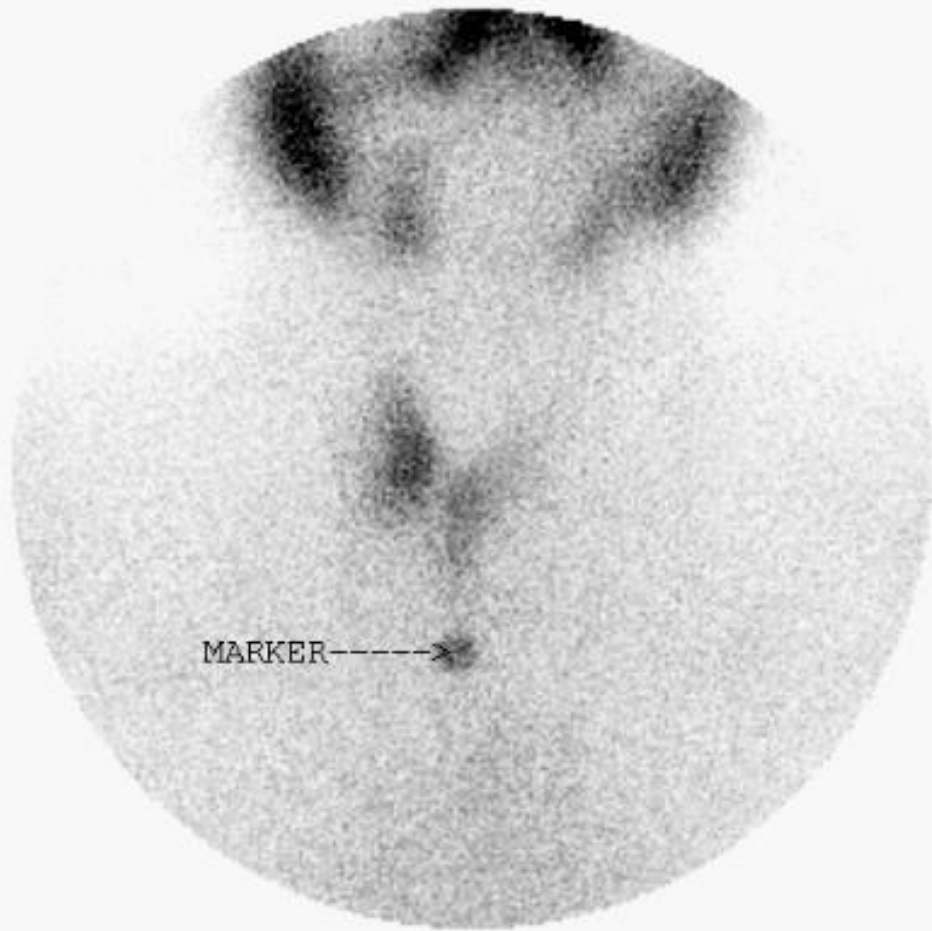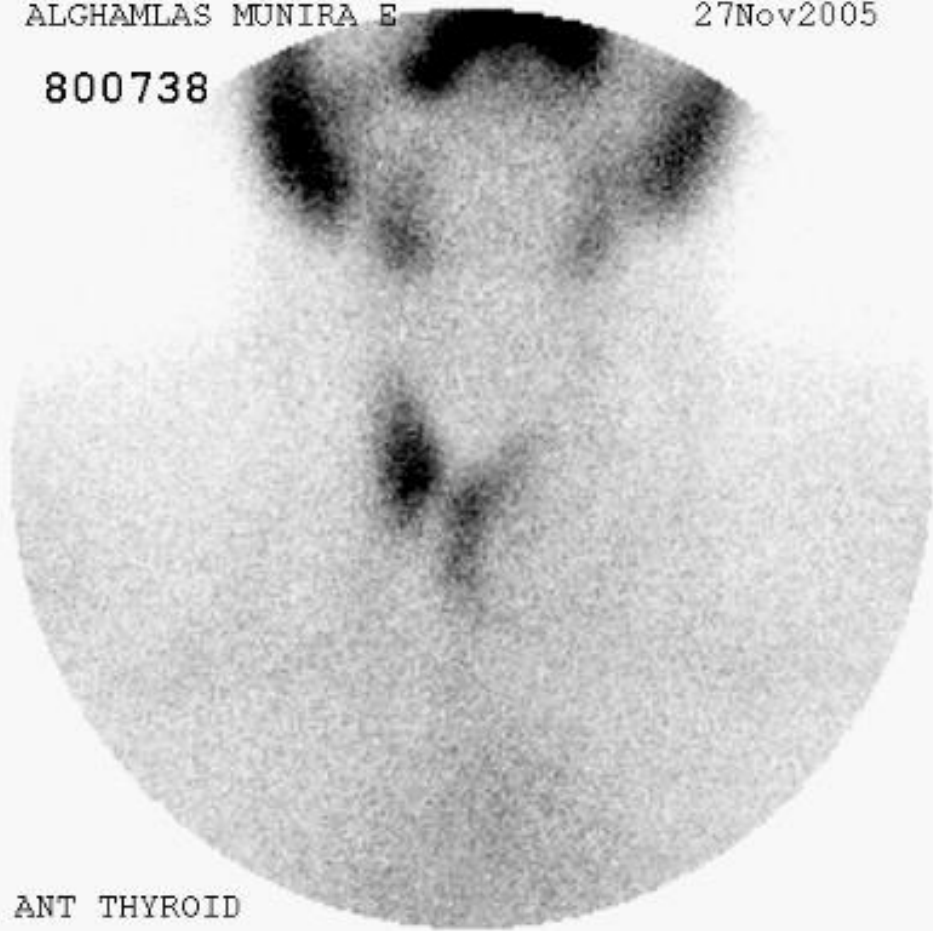
Palpable Neck Mass



ALGHAMLAS MUNIRA E

27Nov2005

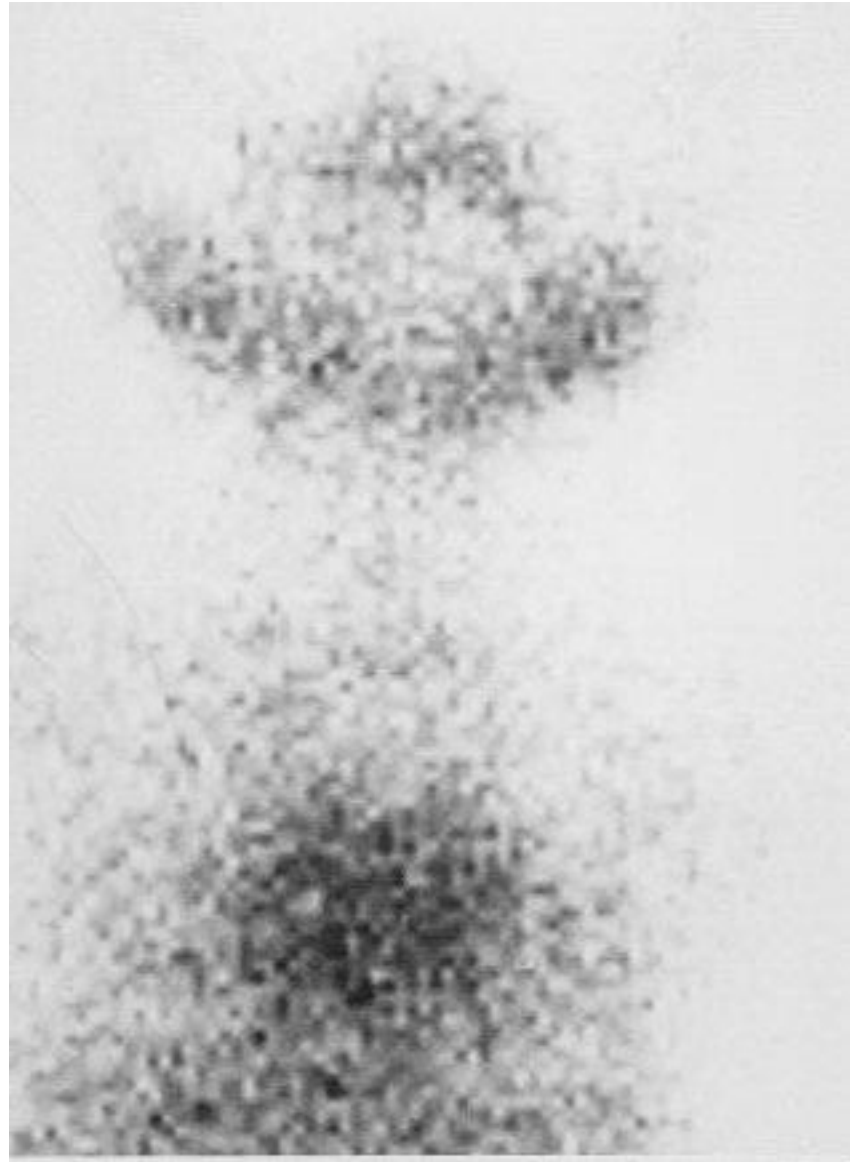
800738



ANT THYROID

MARKER----->

Elevated TSH and low T4



Elevated TSH and low T4

Sex: Im:24 (F11)
HEBA ALAHMED

771183

HEBA ALAHMED

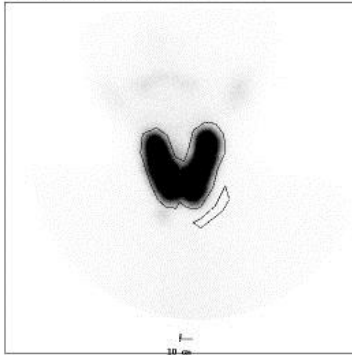ALAHMED HEBA KHALID YOUSEF

Study Date: 15/10/1425

01 Dec 2004

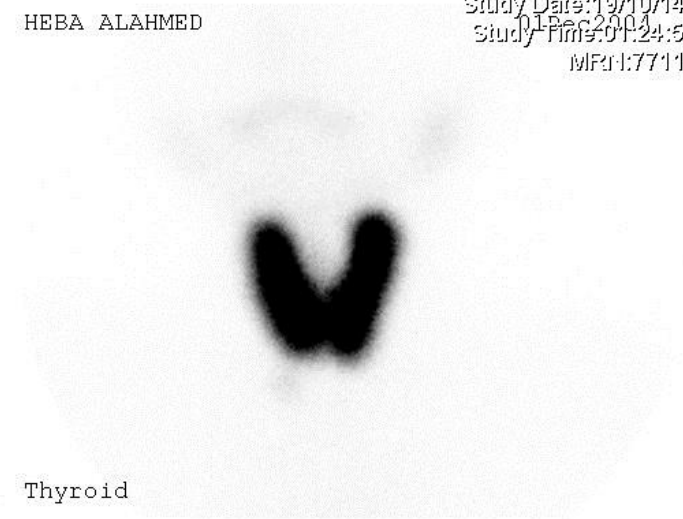Study Time: 01:24:55 p

MRI:771183



THYROID UPTAKE : 41.84 %

Area	0.0	(sqcm)
Mass	0.0	g



Thyroid

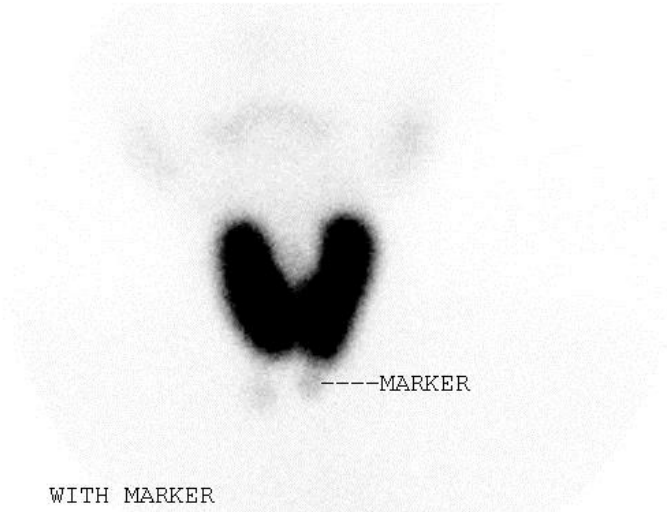
Patient Name : HEBA ALAHMED

Patient ID : 771183

Exam Date : 01Dec2004

THYROID UPTAKE

KKUH RIYADH
NUCLEAR MEDICINE DEPARTMENT
RIYADH



WITH MARKER

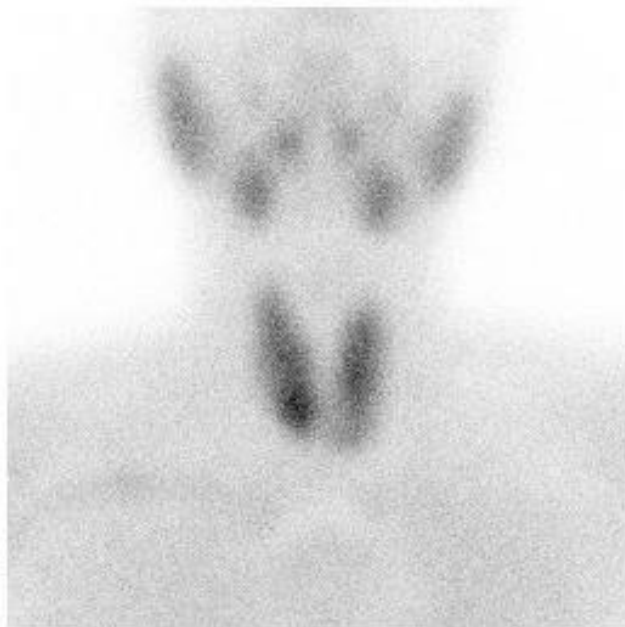Thyroid_SS_SS

C12B
W256

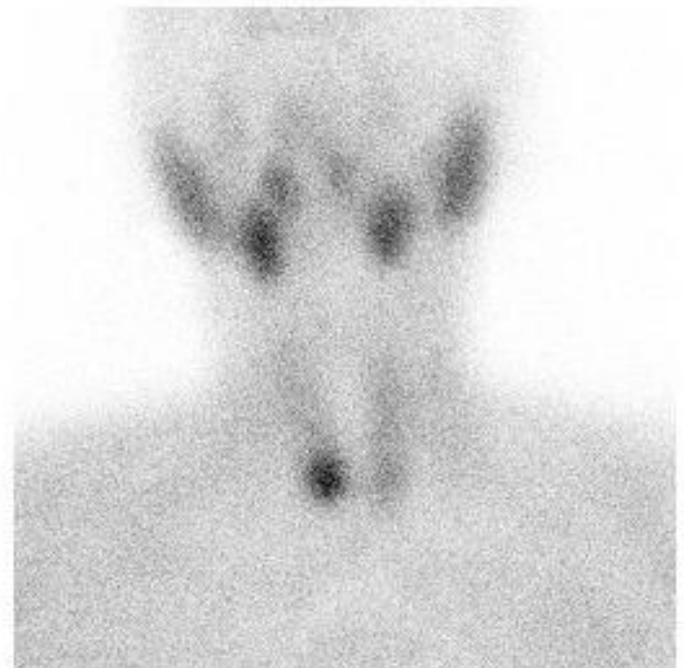
High PTH and High Ca

1

A. IBTESAM, , , ABDU
1504
Study T

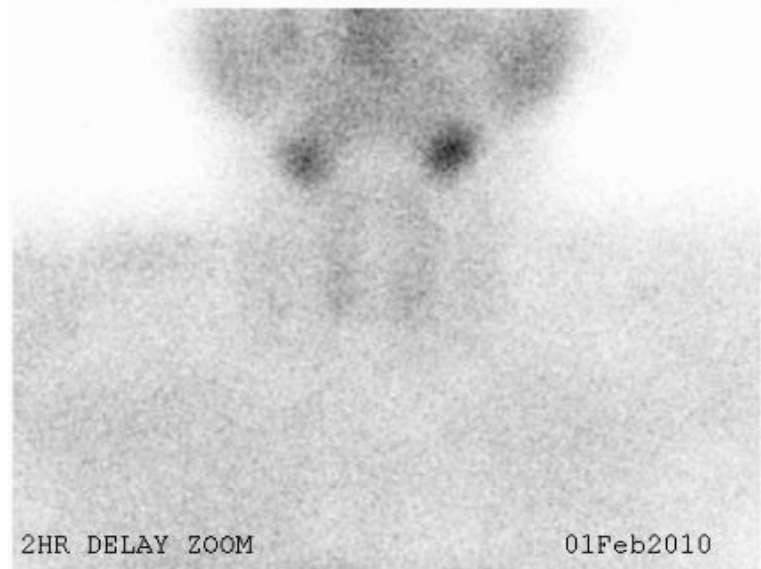
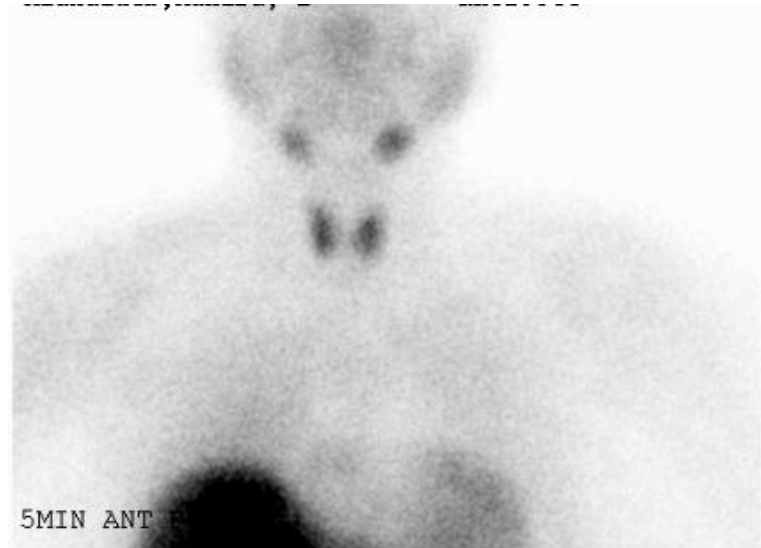
EARLY ZOOM

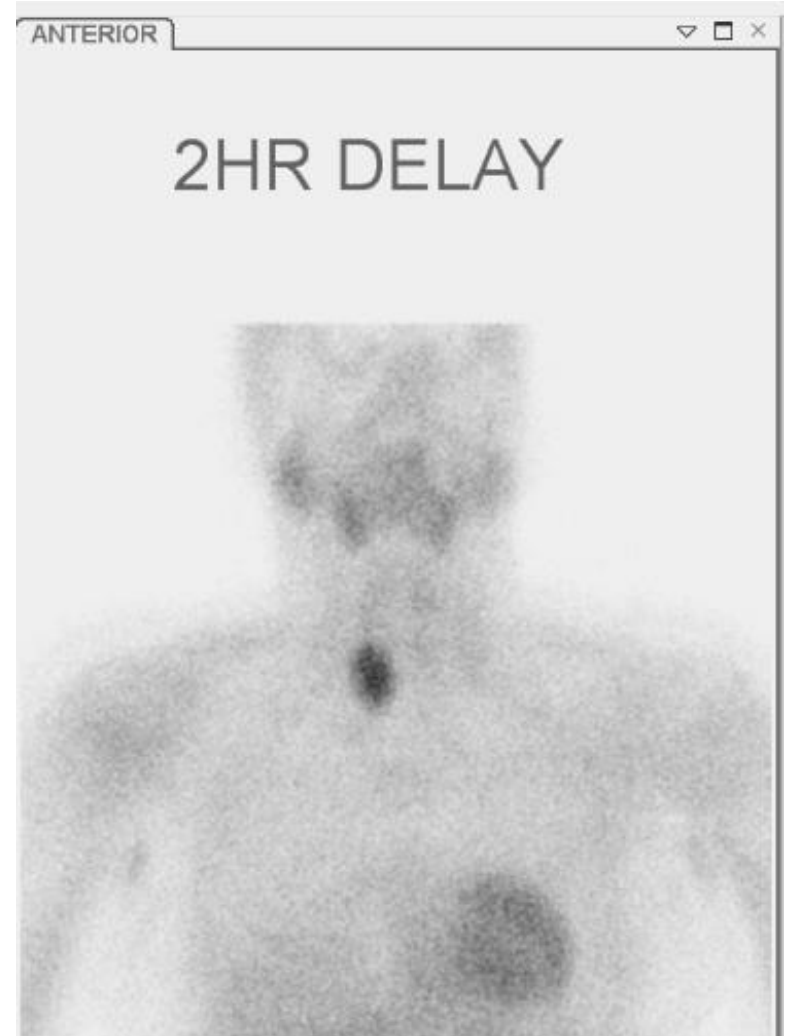
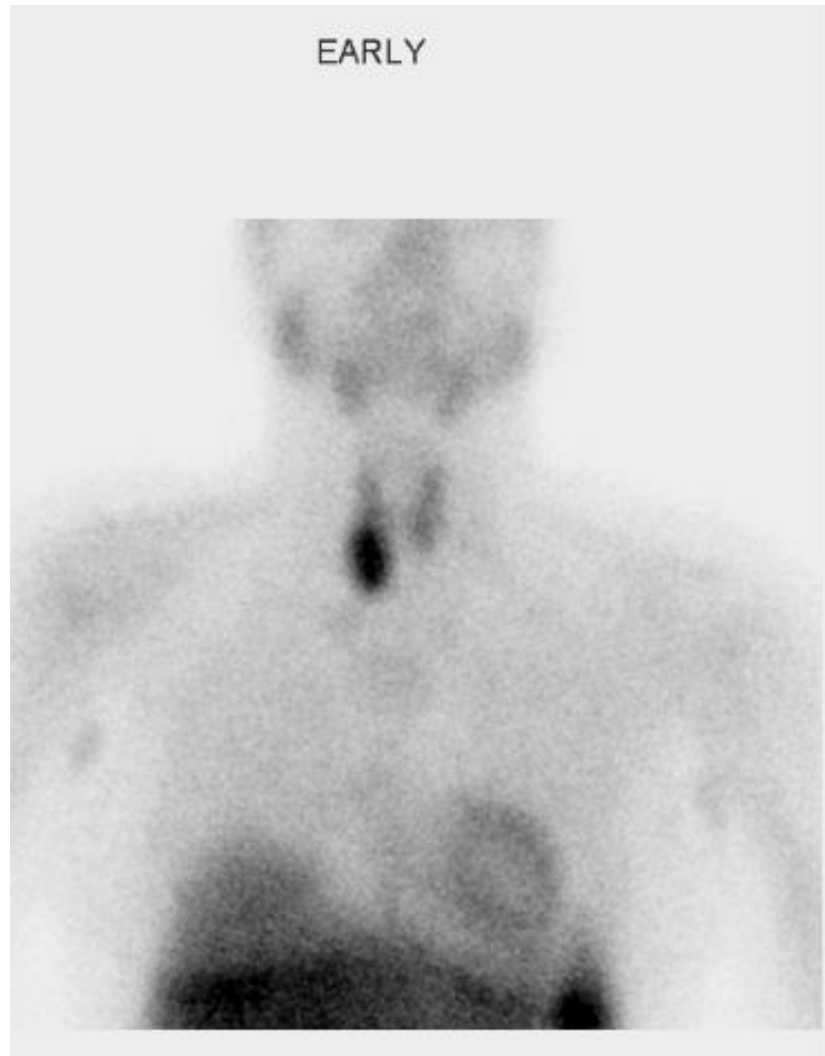

2HRS DEL ZOOM

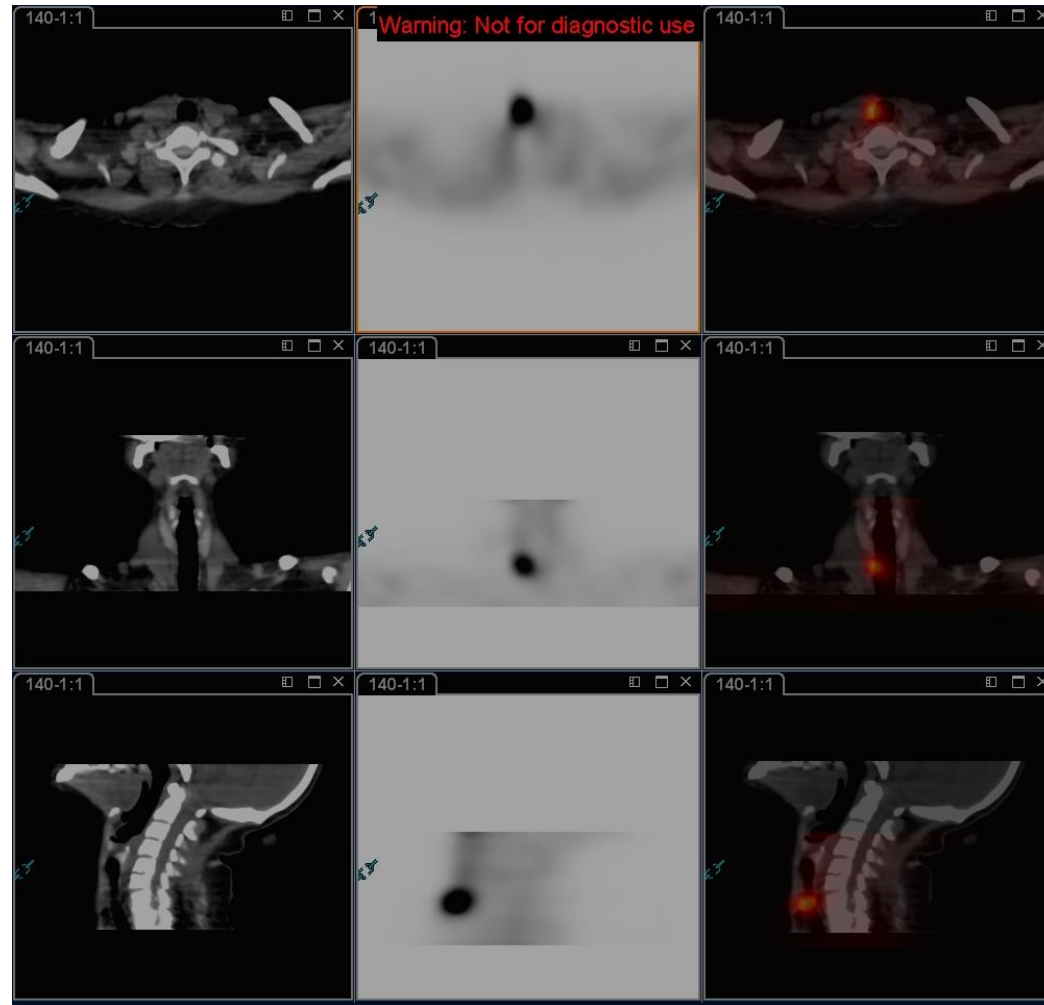
High PTH and High Ca



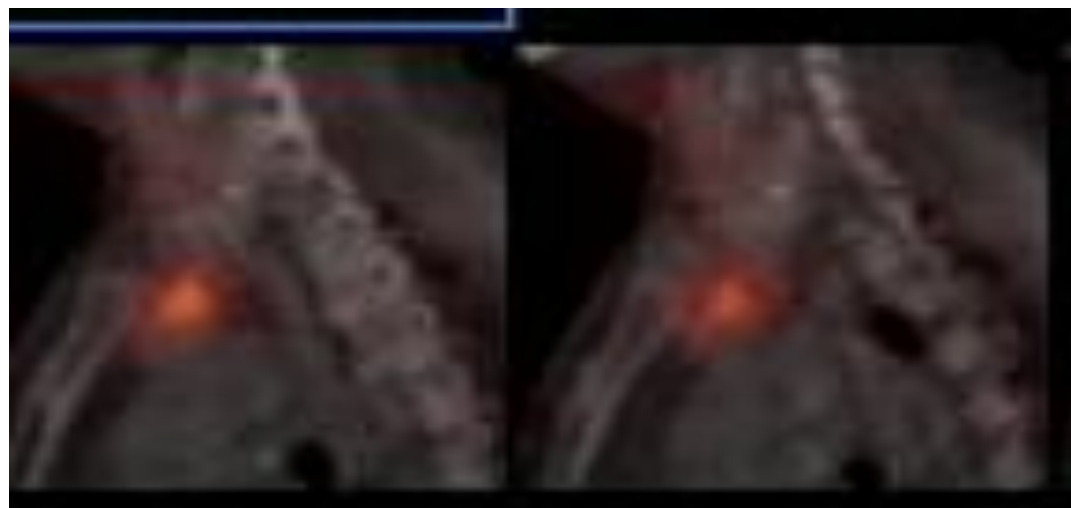
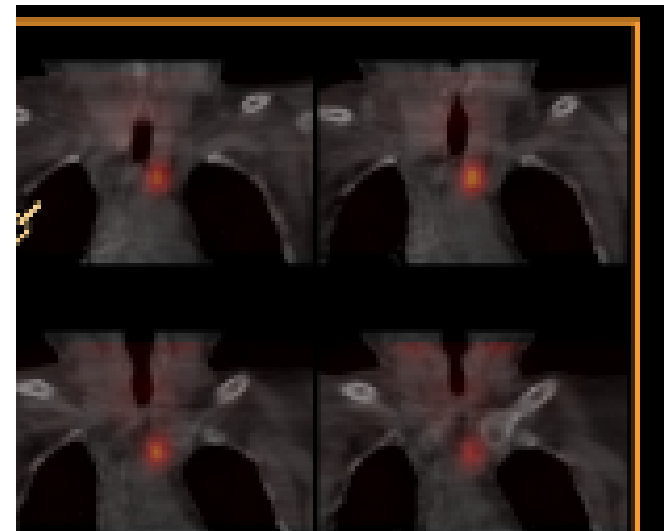
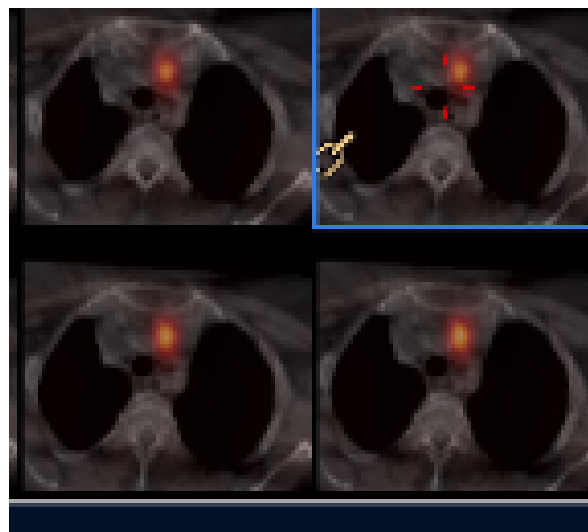
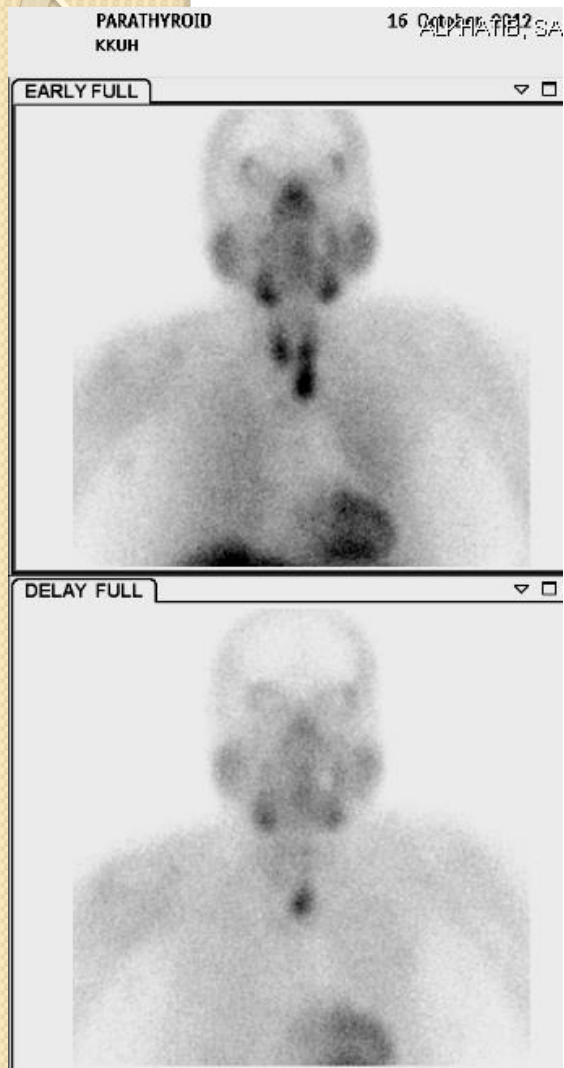High PTH and High Ca



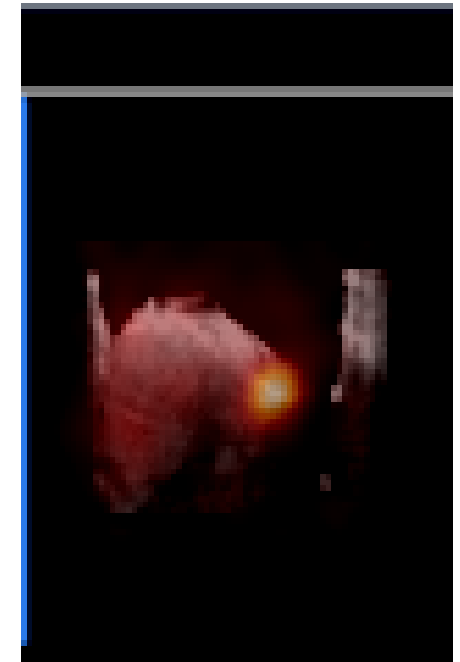
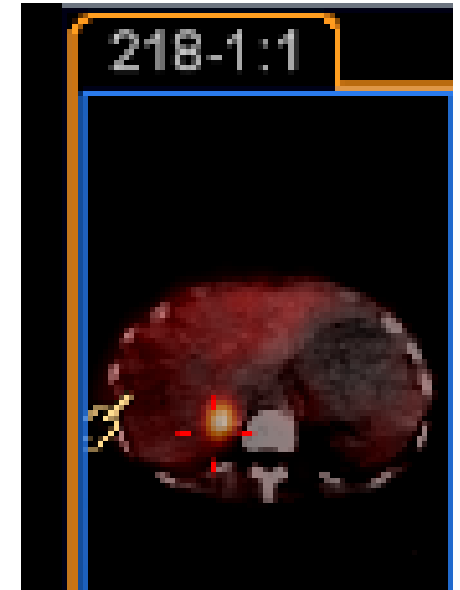
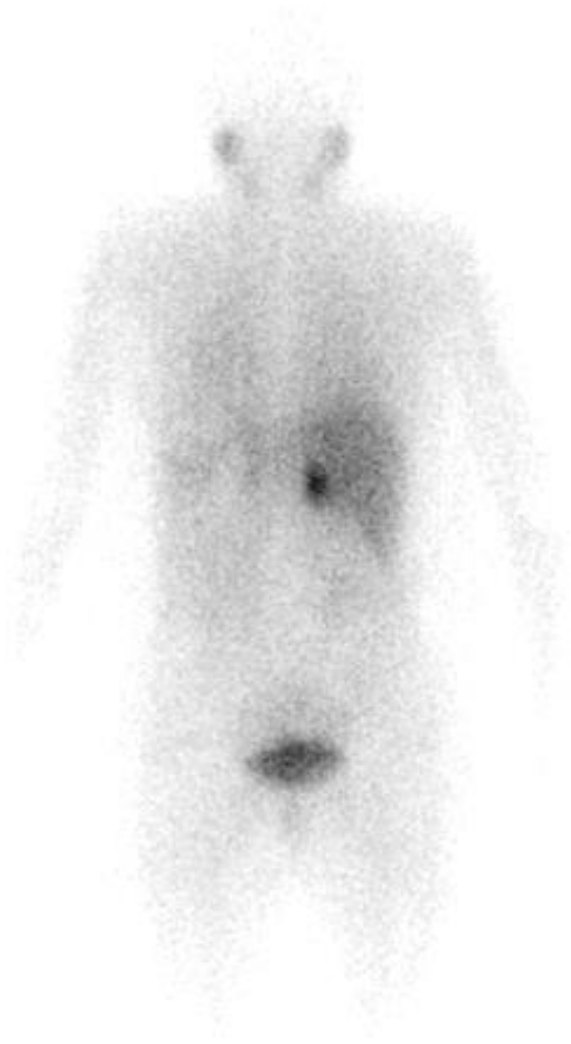High PTH and High Ca



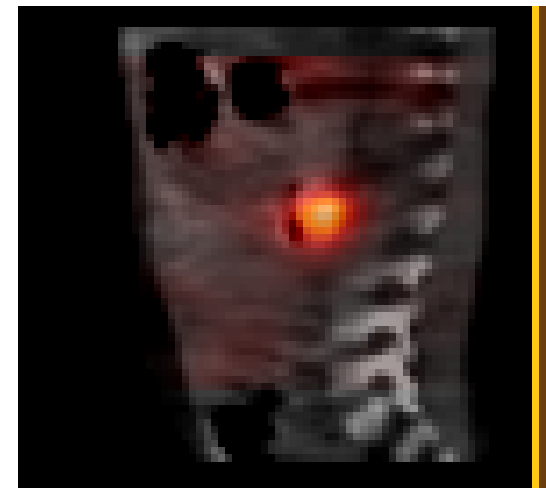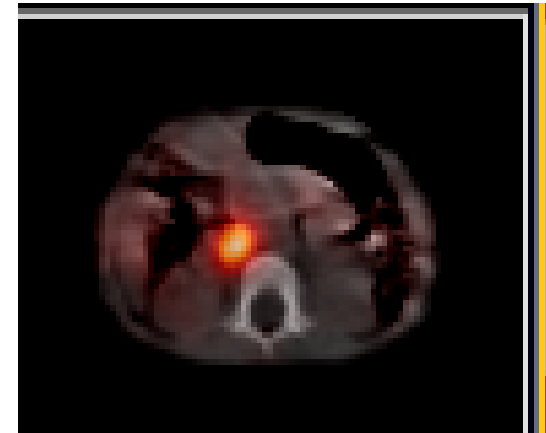
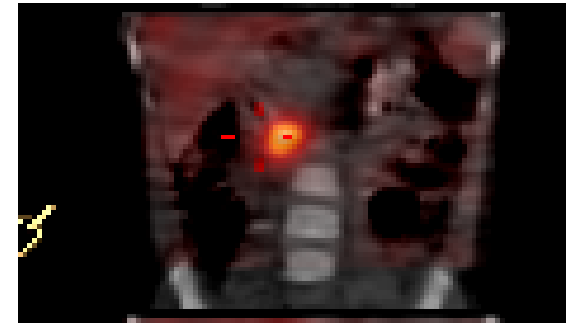
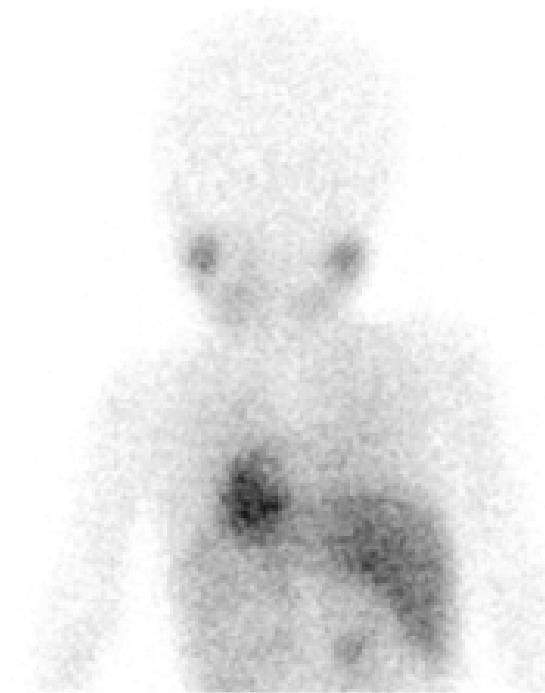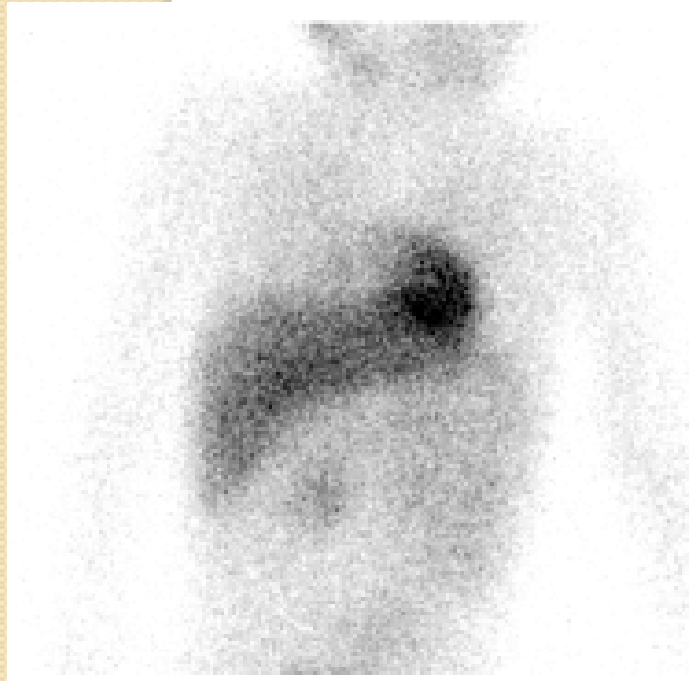
High PTH and High Ca



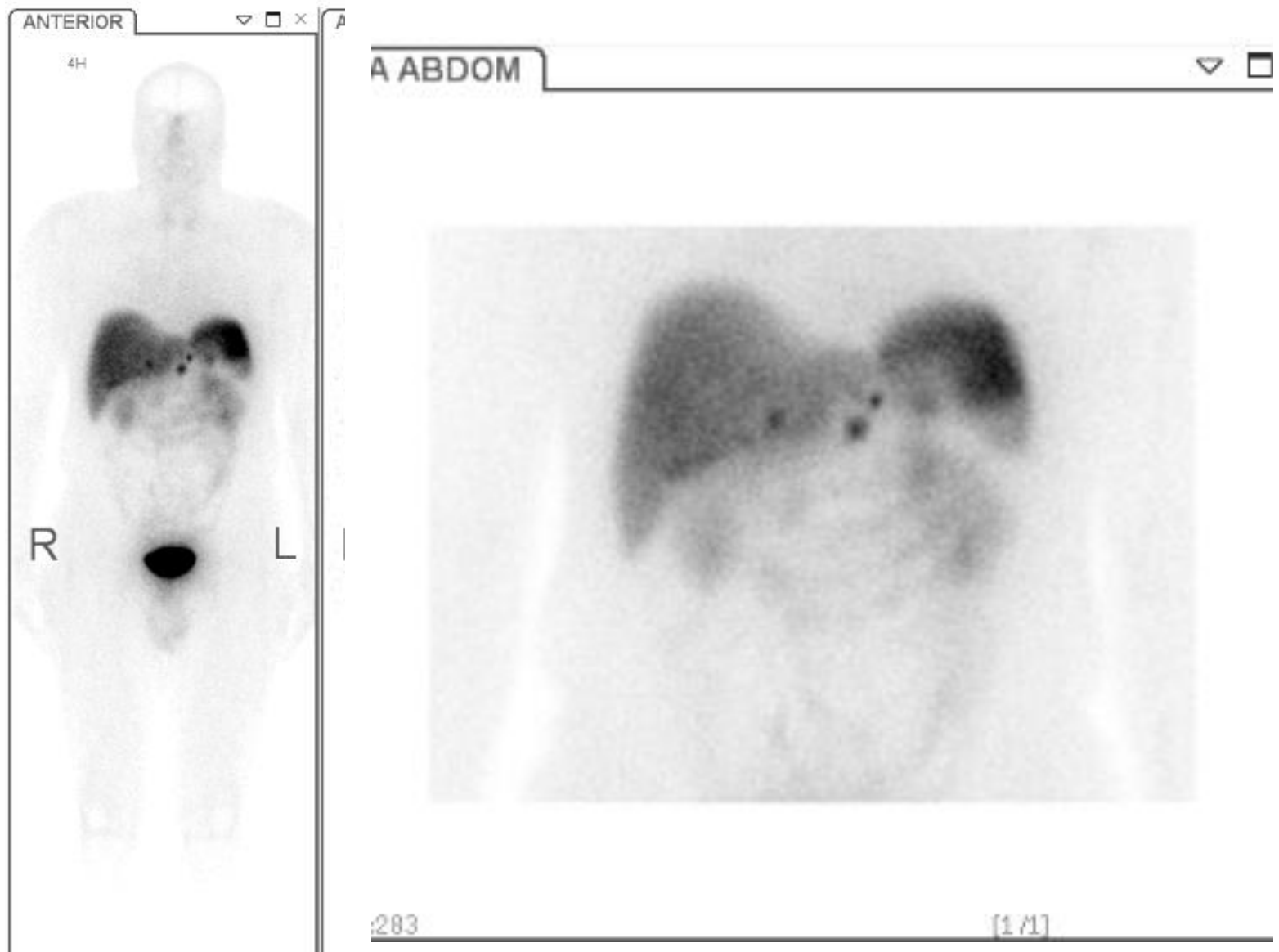
41 years old female patient is with hypertension. ? Secondary HTN



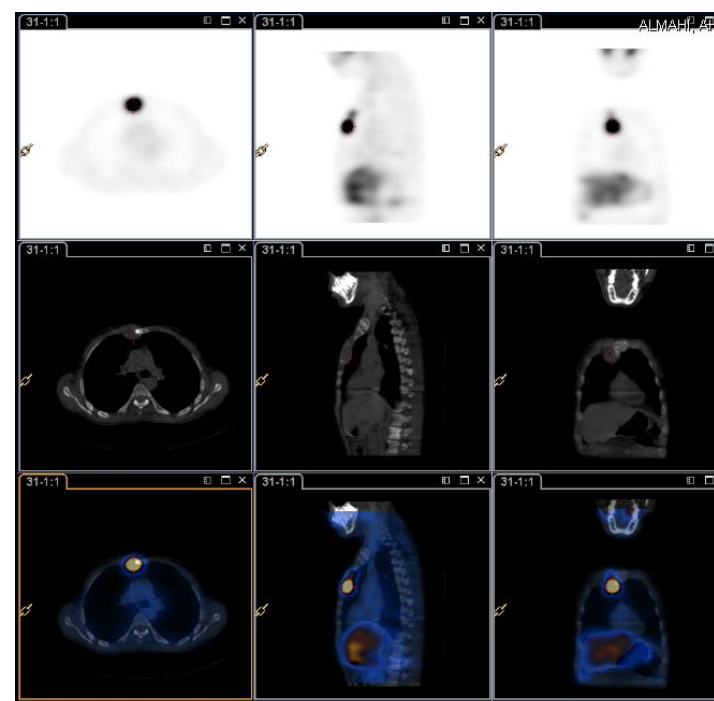
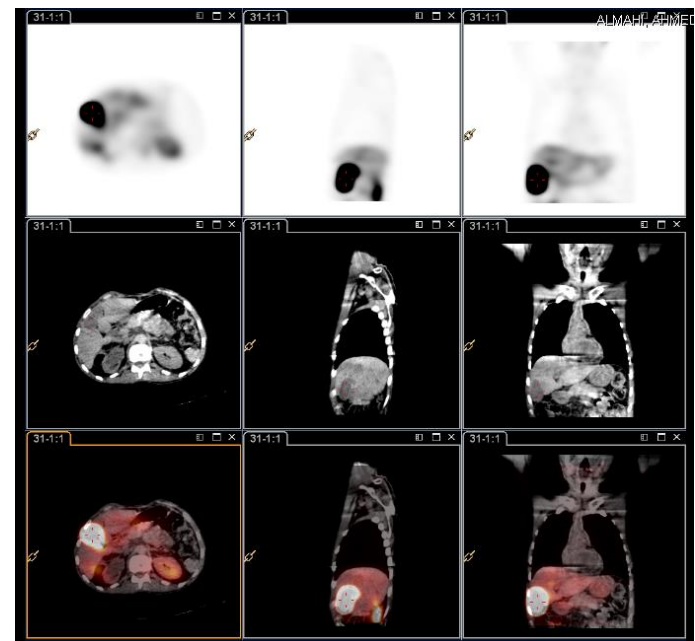
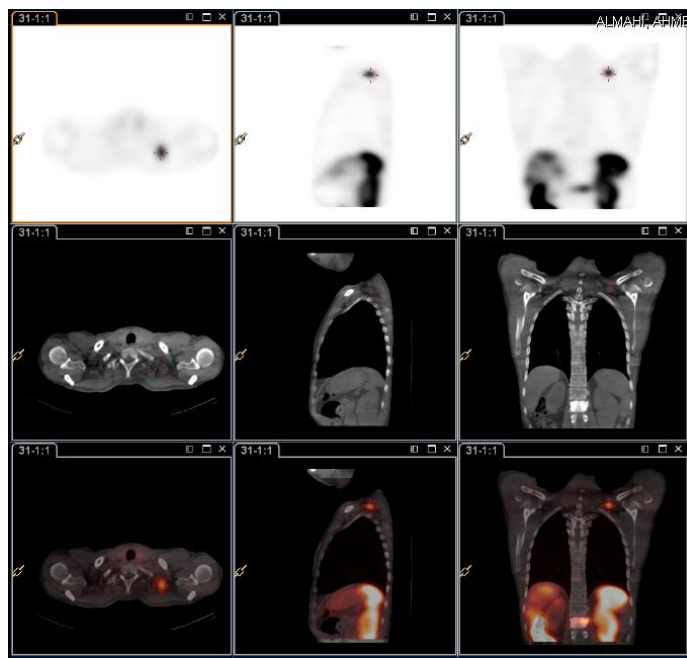
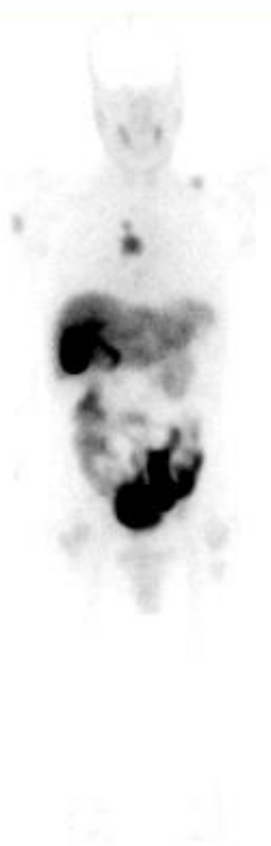Two years old female with abdominal mass



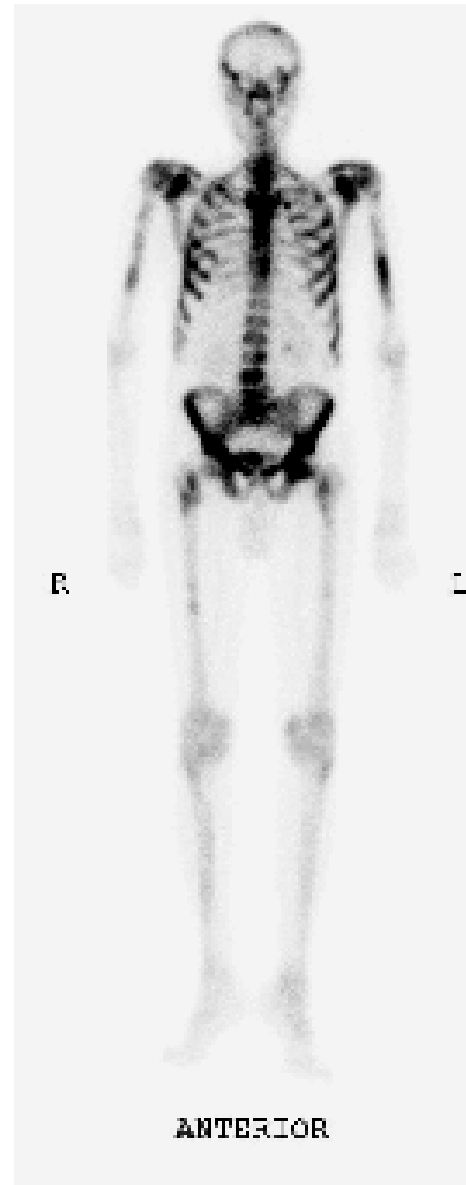
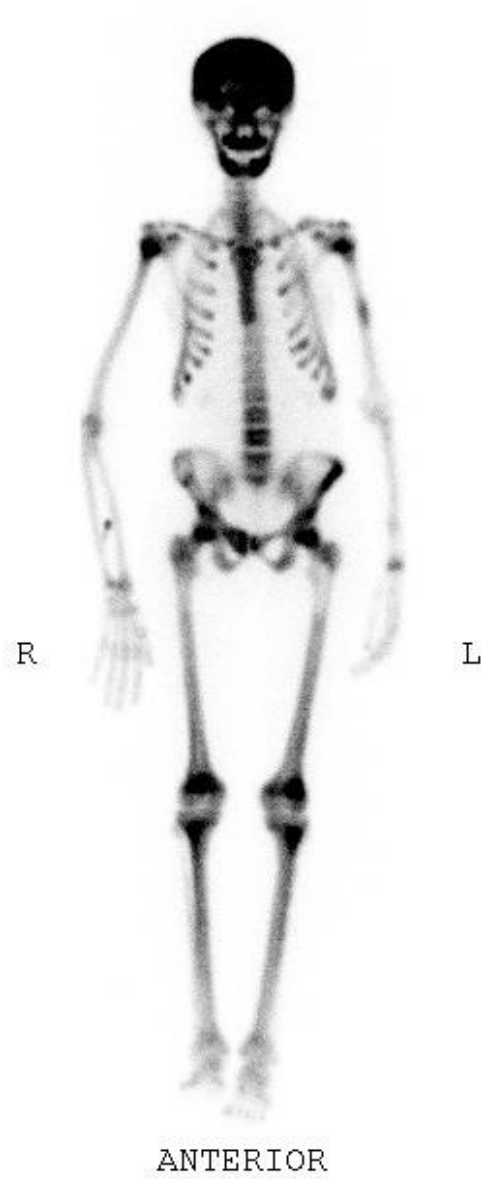
Patient with neuroendocrine tumor



Patient with neuroendocrine tumor



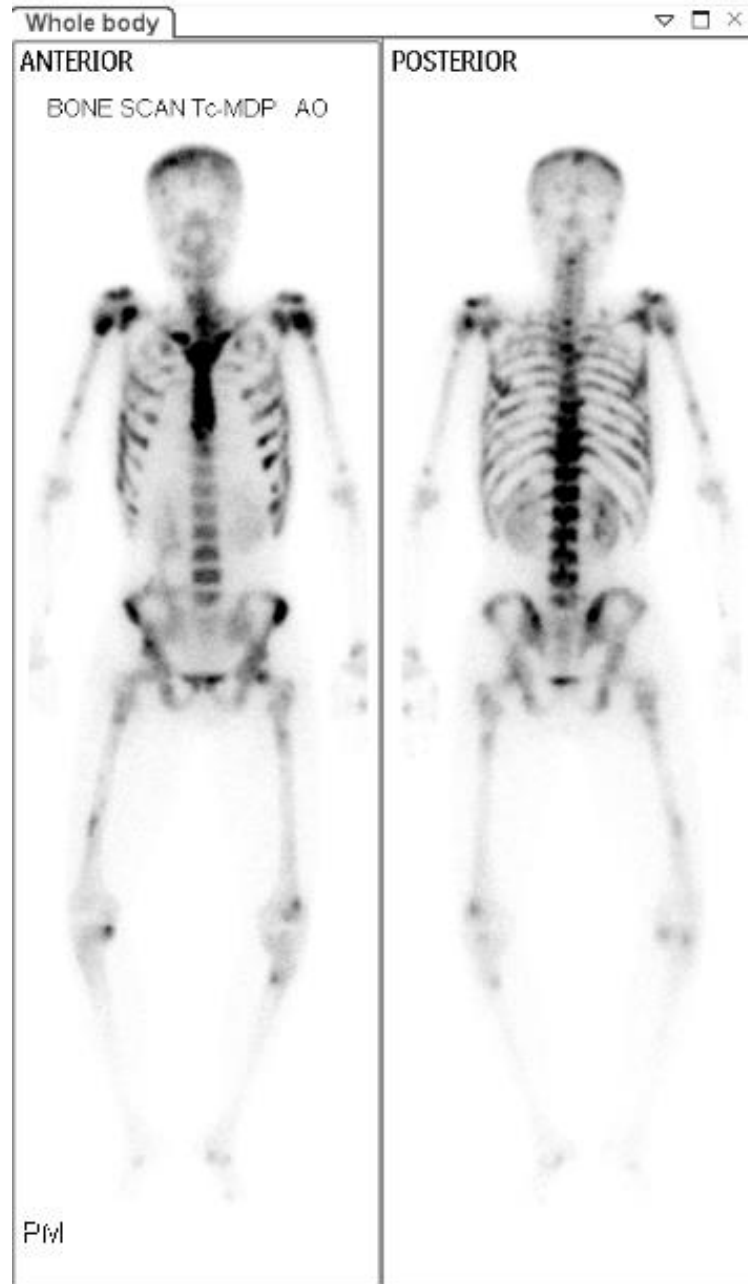
Superscan



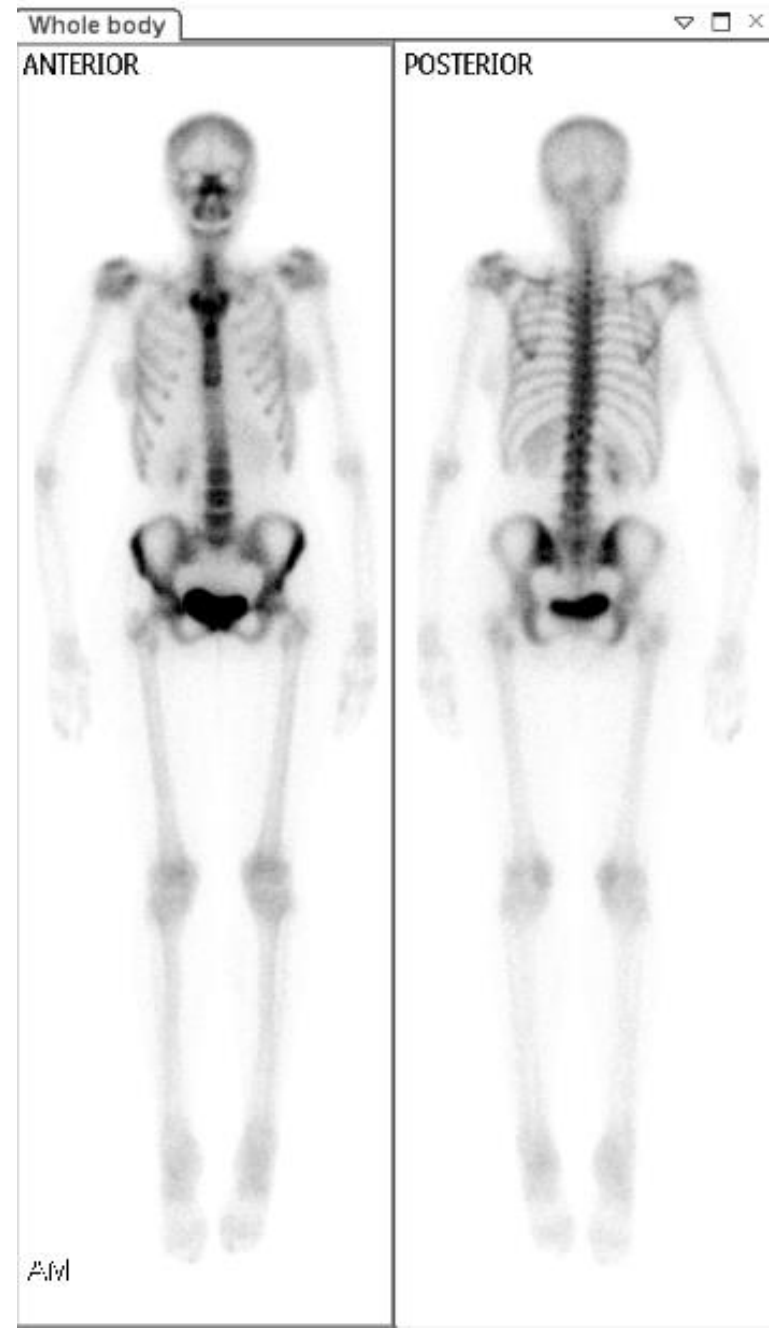
Alkhalifa, Saleh
02/06/1976 M

0.00 m

KK950765
0.00 kg

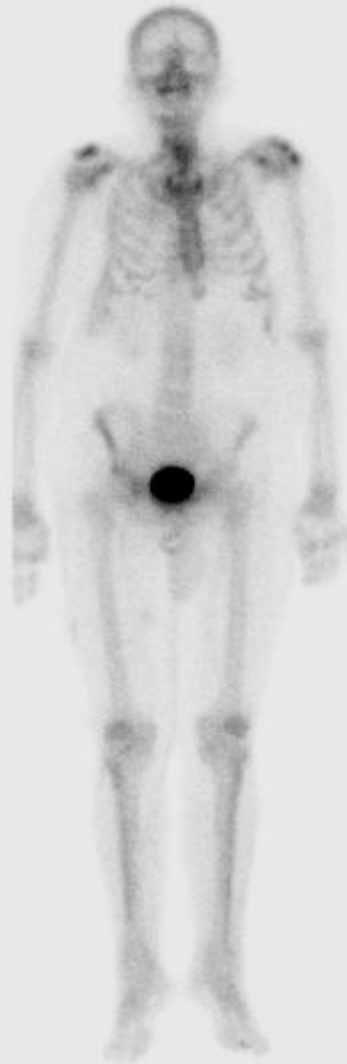


**Patient with cancer
and bone mets on CT**



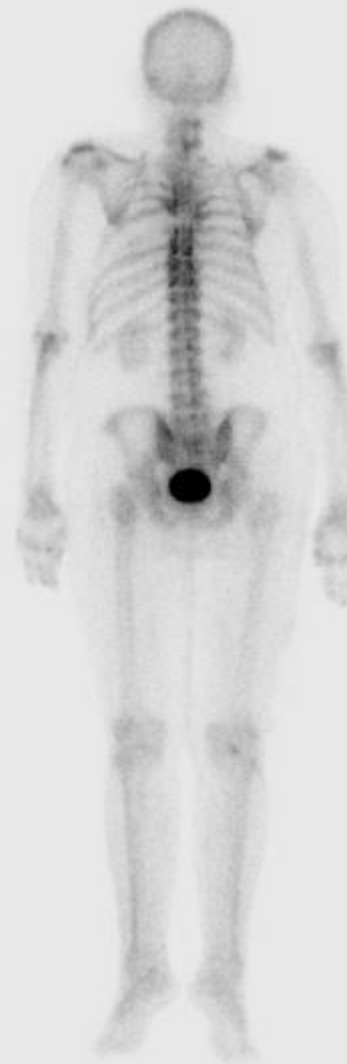Whole Body

▾ □ ×



LL:0 UL:256

BONE SCAN
Tc99m-MDP



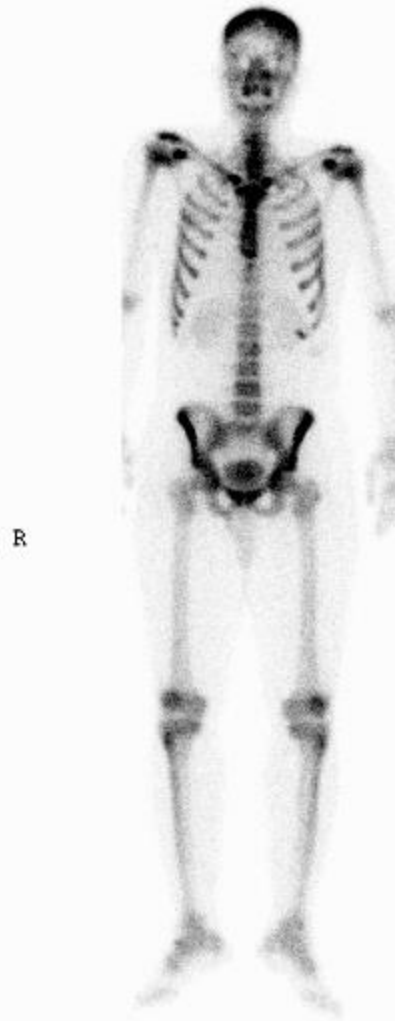LL:0 UL:256

YA

ALDOSARI MUNIF MENA

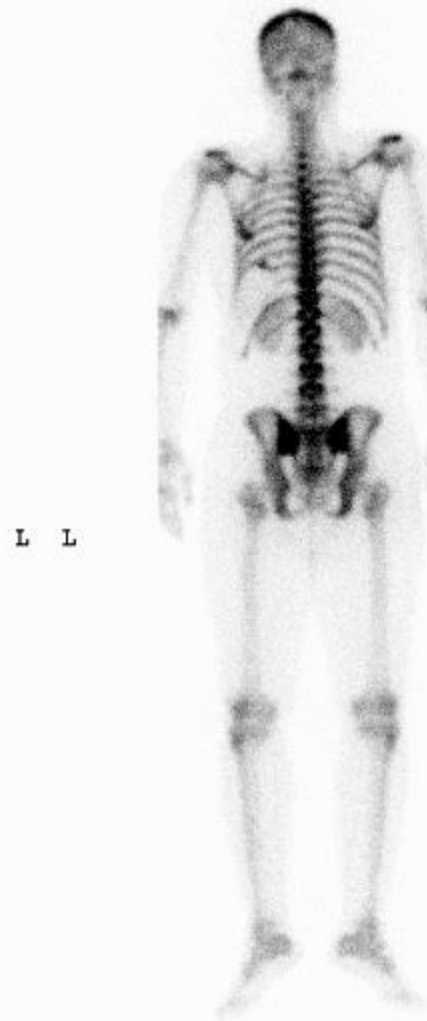
495089

10Sep2005



R

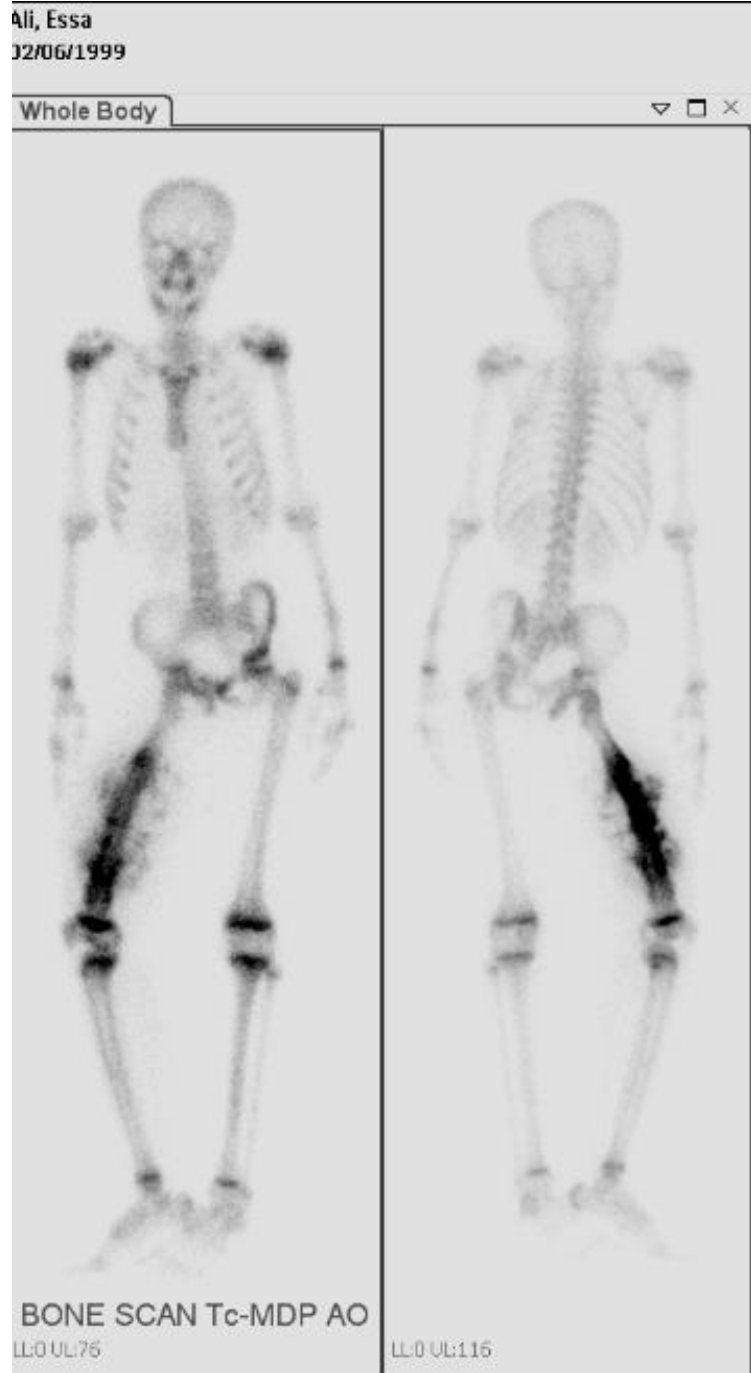
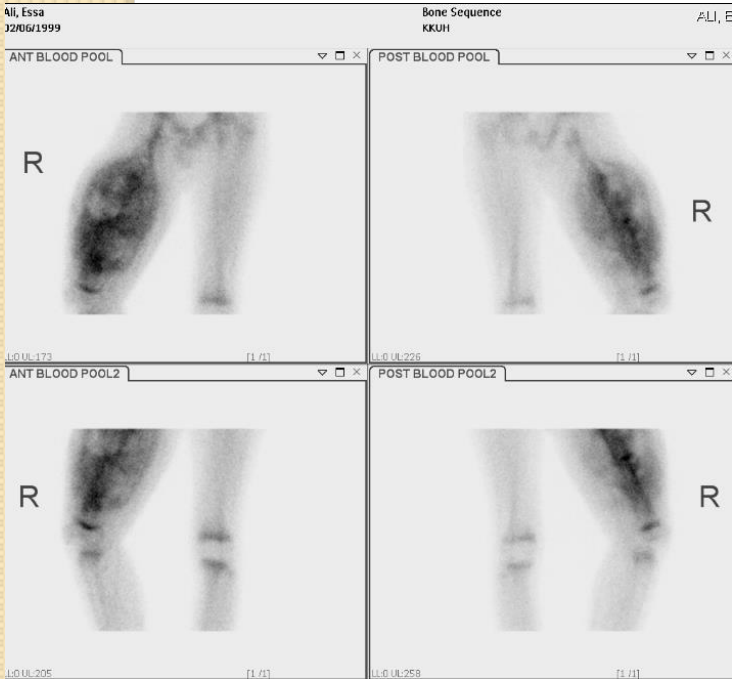
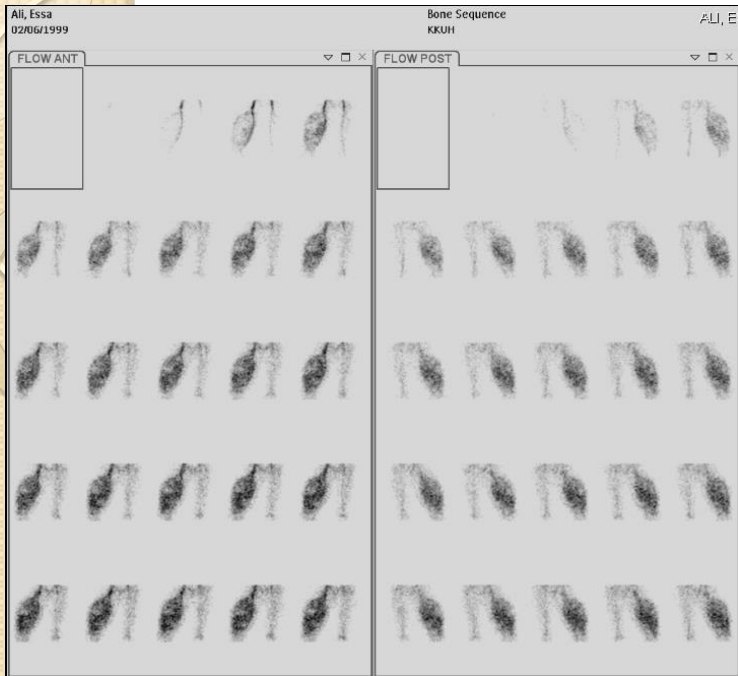
ANTERIOR



L L

R

POSTERIOR



ANTERIOR_SS_SS

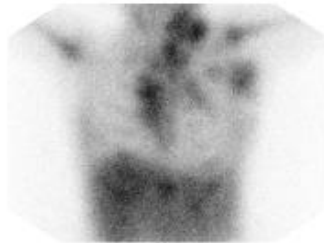
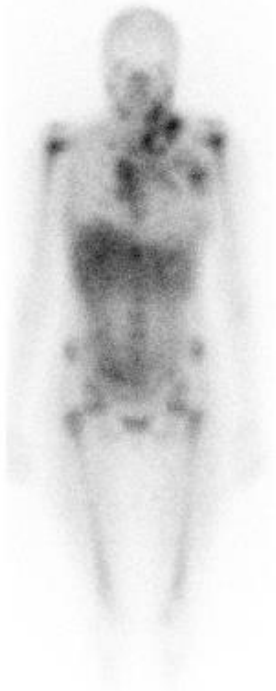
Alshaikh, Safiah, Ab

KK359947

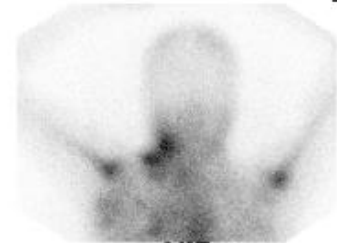
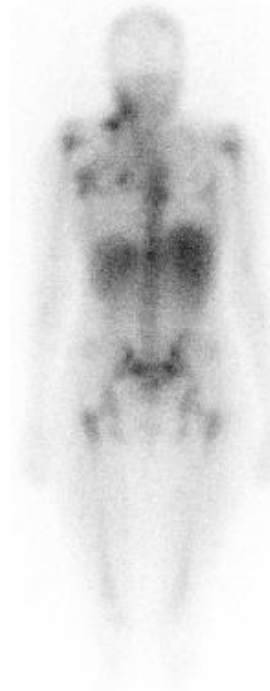ALSHAIKH, SAFIAH, ABDUL

08Dec2010

ES



ANTERIOR



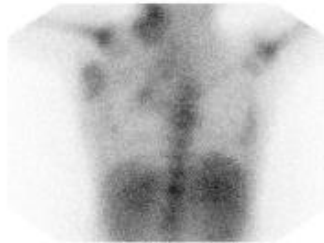
ANT

R

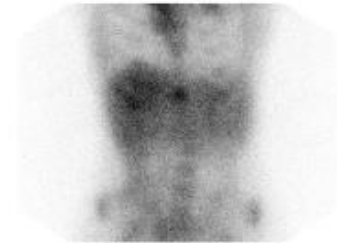
L

L

R

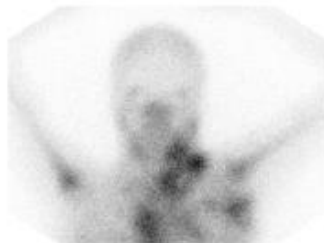


POSTERIOR

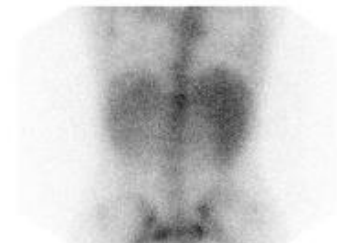

ANTERIOR

GA-67 SCAN KKHU R4



ANT



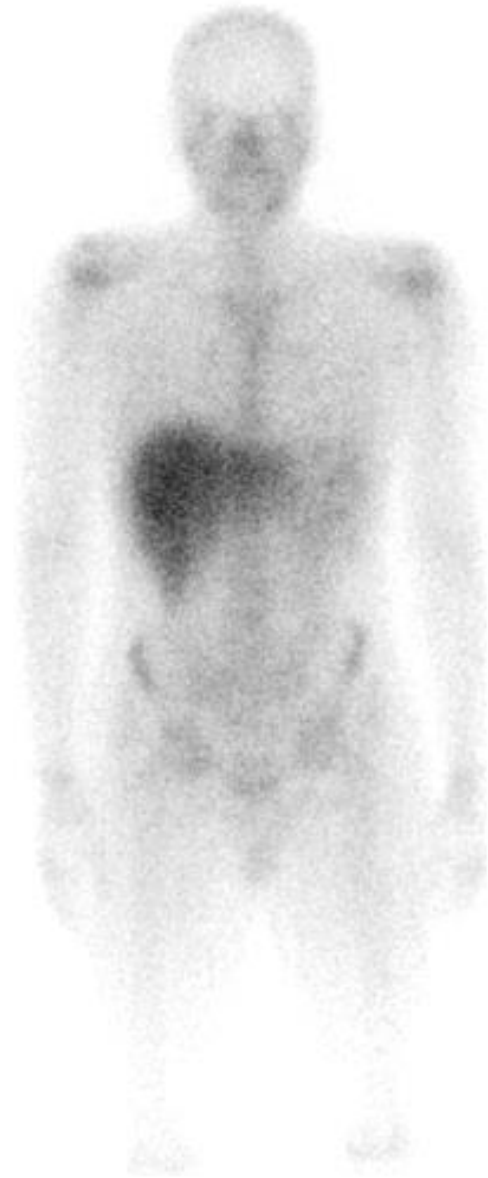POSTERIOR

ANTERIOR
L BODY

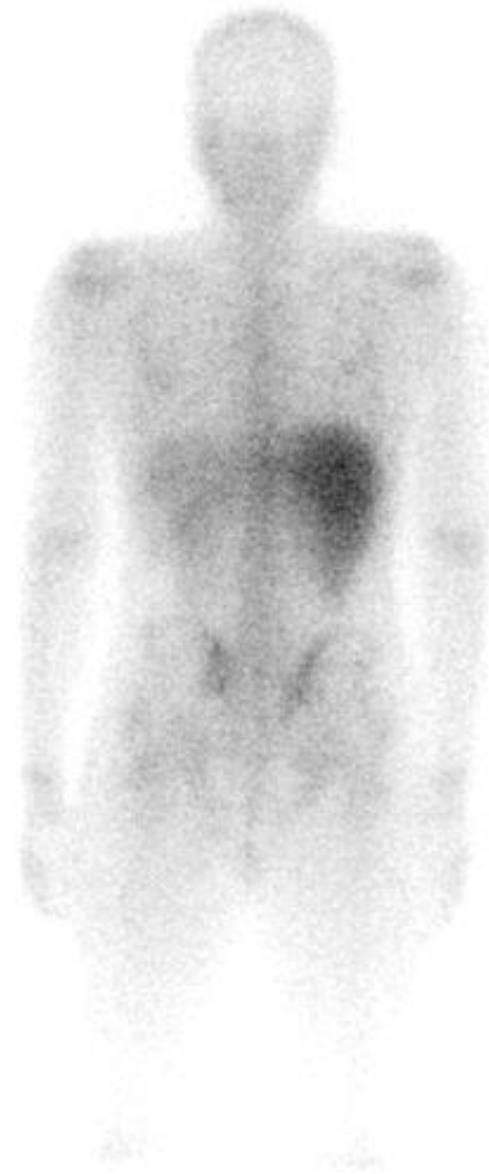08Dec2010

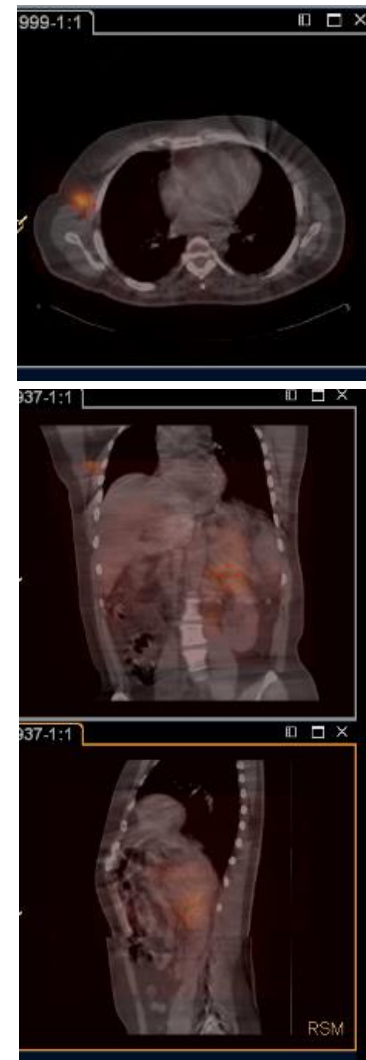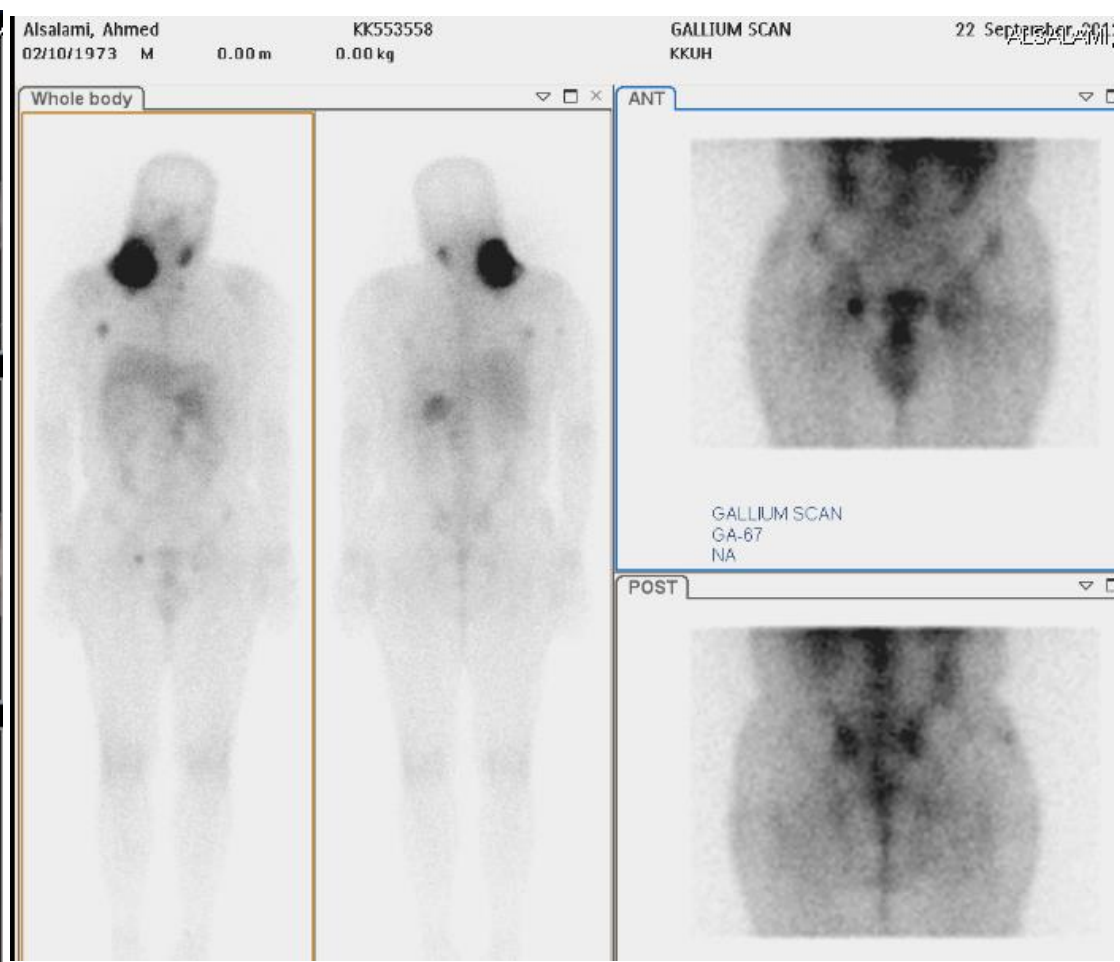
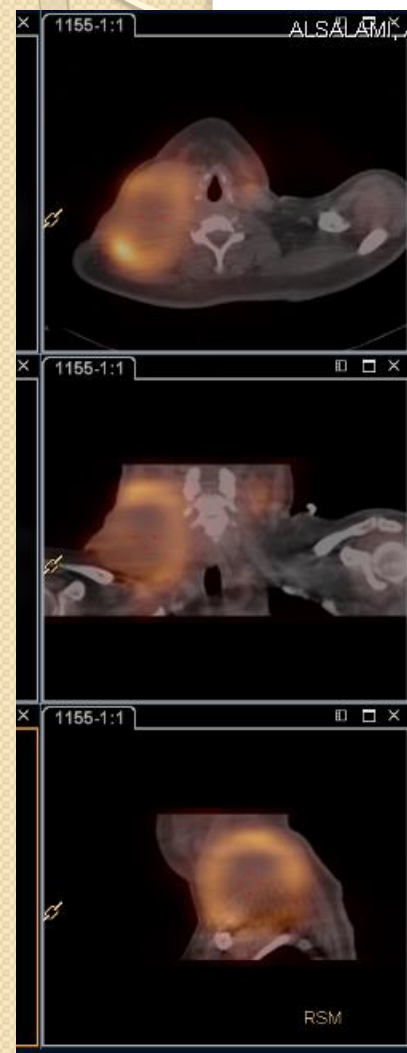POSTERIOR

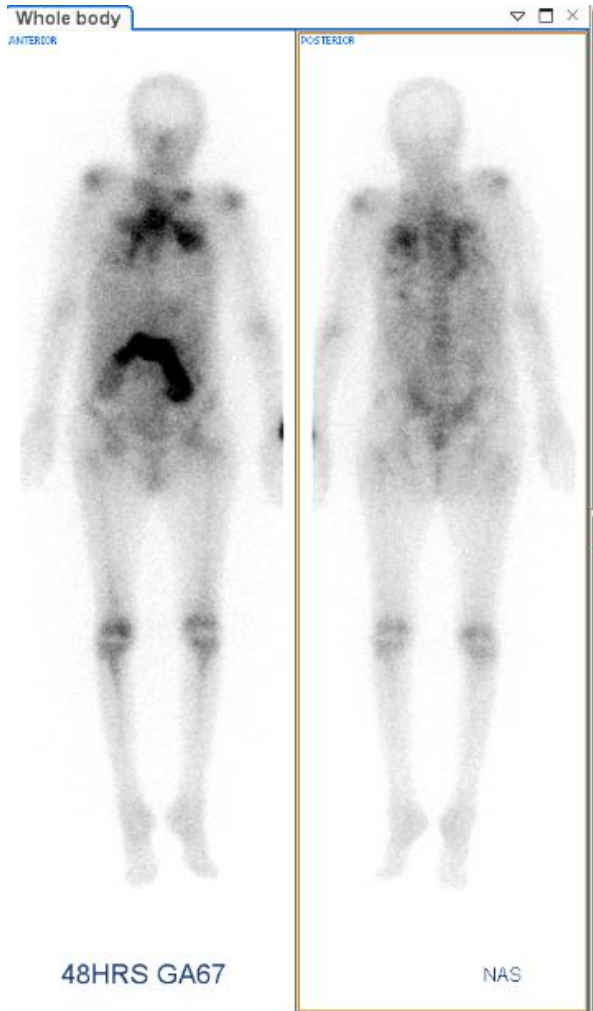
GA-67 WB SCAN



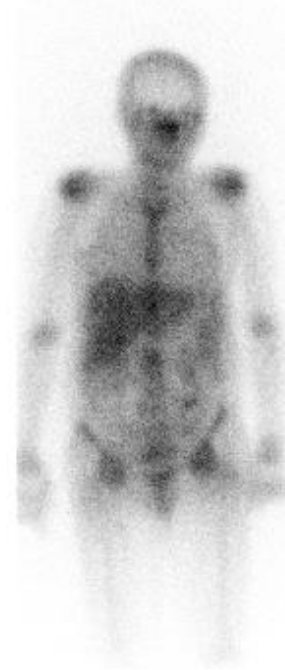POSTERIOR





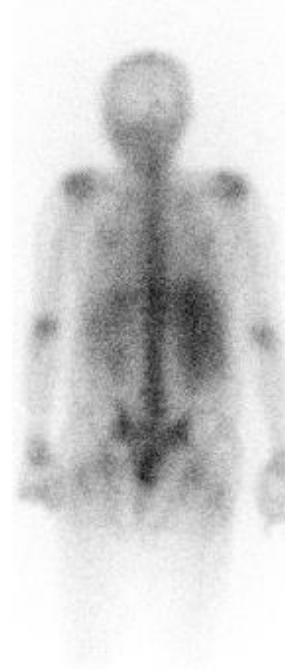

Al Qahtani, Nora, Ho




ANTERIOR

ANTERIOR_SS
KK924345



L L

POSTERIOR



Ighamdi, Sultan
4/09/1990

KK1030971

GALLIUM SCAN
KKUH

Ighamdi, Sultan
M 0.00 m

0.00 kg

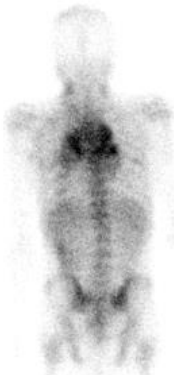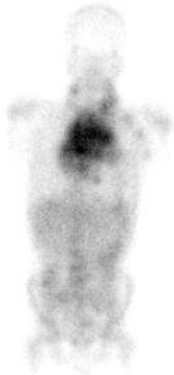KK1030971

GALLIUM SCAN
KKUH

14 April, 2012

Whole Body Whole Body

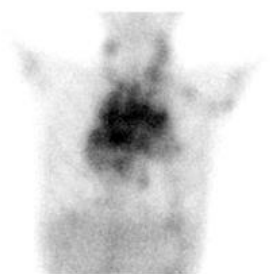
POST



LL 0 VL 176

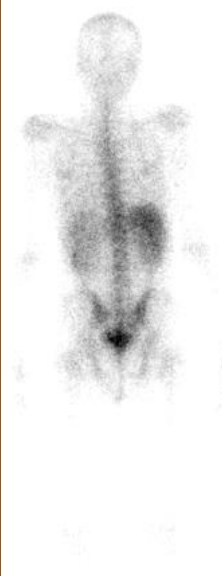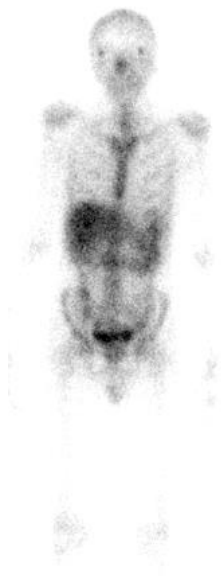11 / 11

ANT

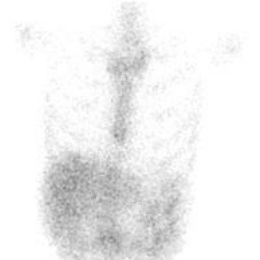

Whole body

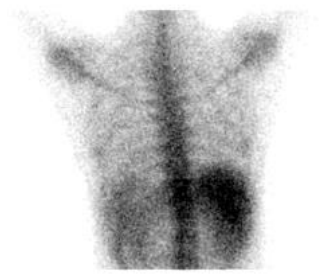POST

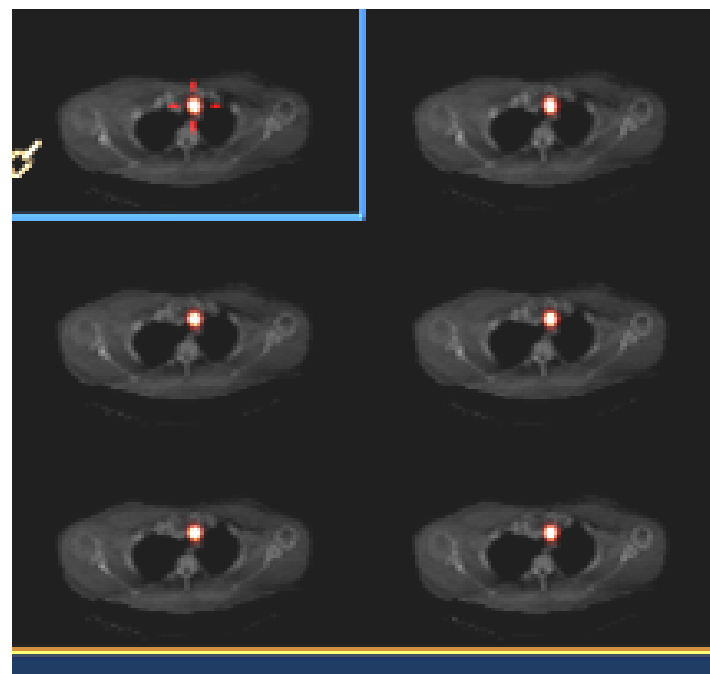
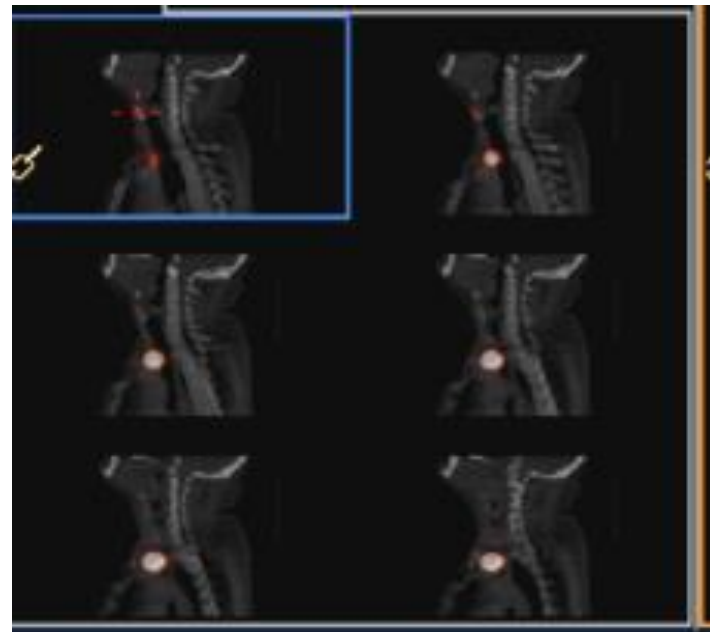
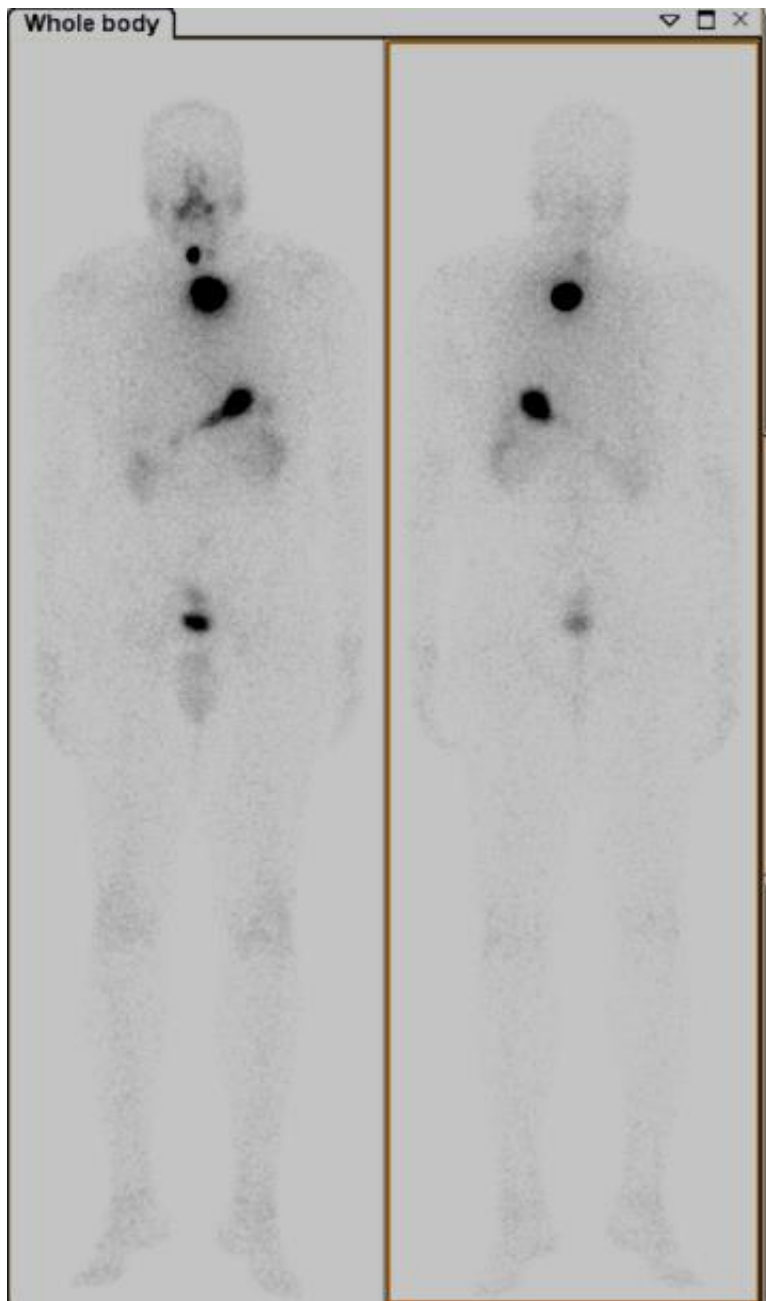



ANT

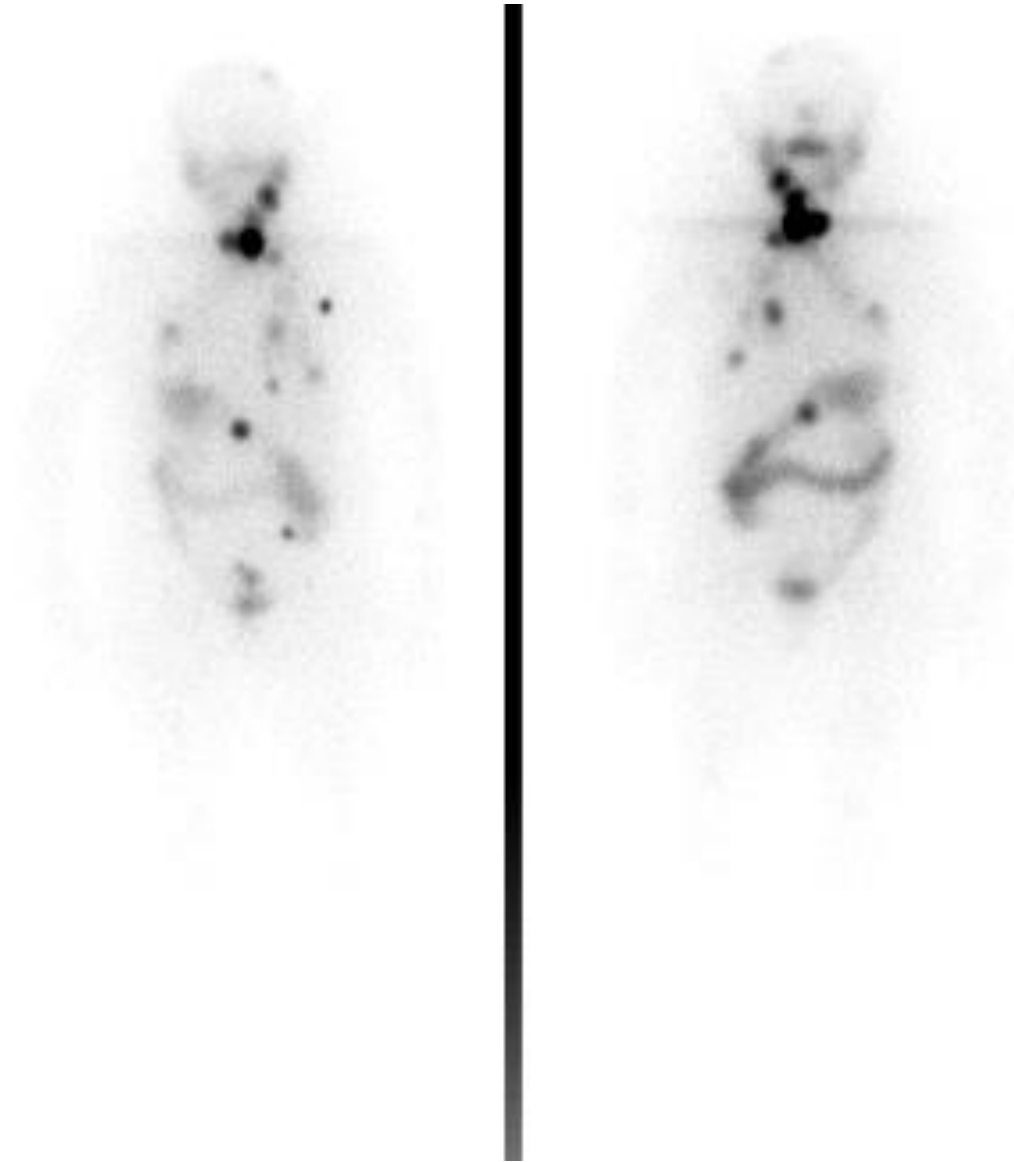


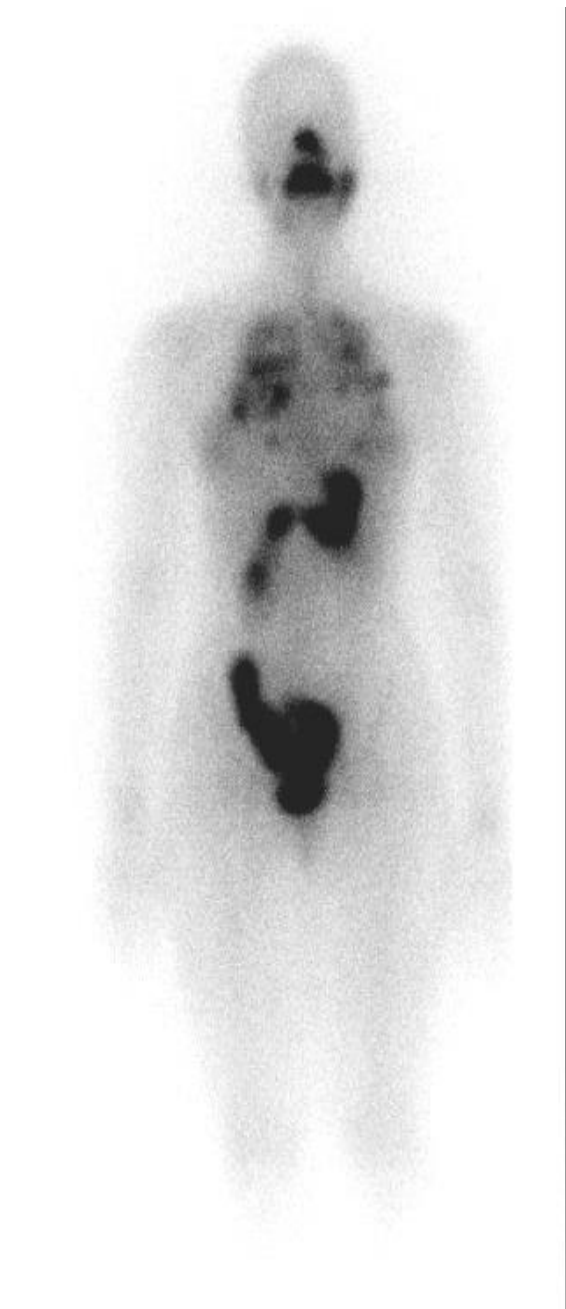
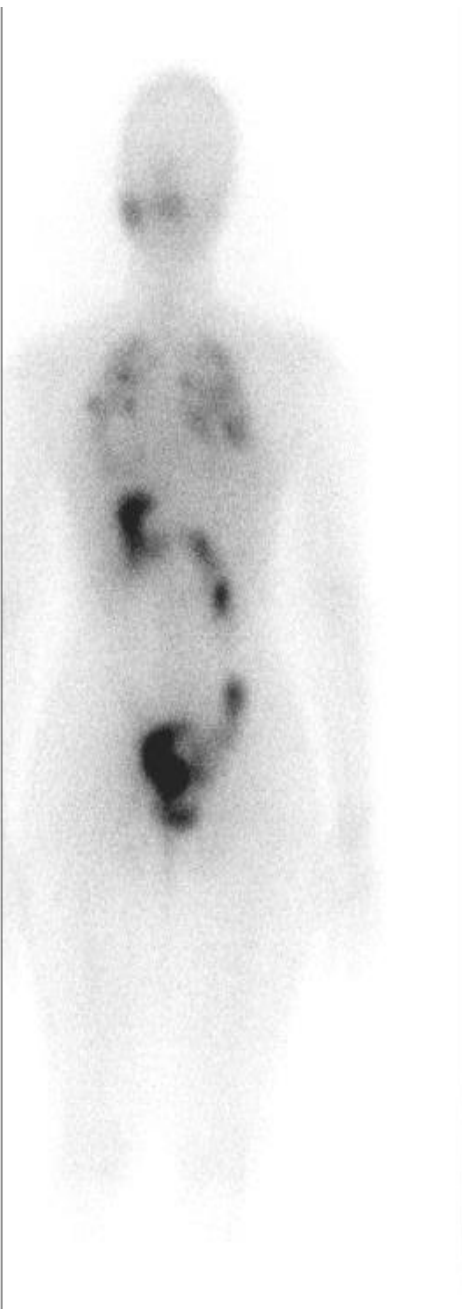POST





Thyroid Cancer





Thyroid Cancer

I-123 WB Scan

