

# Nuclear Oncology



**Saleh Othman , MD**

Asso. Prof.& Consultant Nuclear Medicine  
King Khalid University Hospital & School Of Medicine  
King Saud University

# Nuclear Oncology

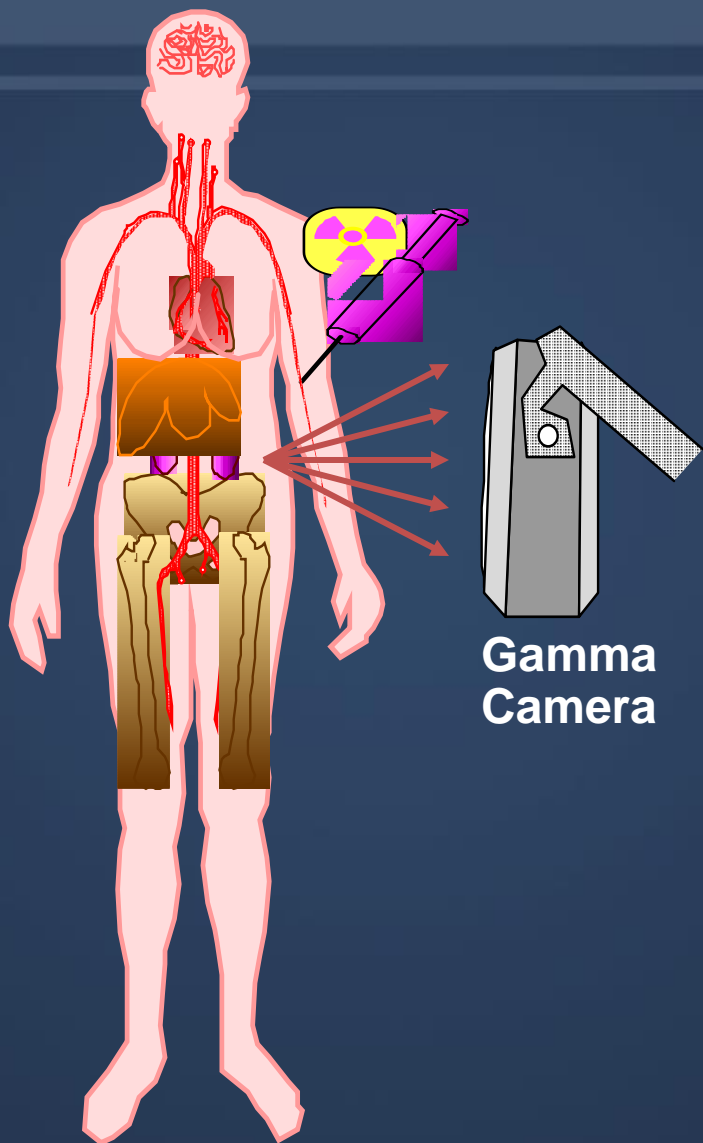
## LEARNING OBJECTIVES...



At the end of the lecture you will be able to answer the following questions:

- What are the tumor imaging and therapeutic radiopharmaceuticals?
- What are the nuclear medicine tumor imaging methods?
- What are the objectives of tumor imaging?
- What are the potential values of nuclear medicine tumor imaging methods?
- What is the role of nuclear medicine in the treatment of tumors?

# Nuclear Medicine Procedure



- *Patient injected with small amount of radioactive material .*
- *Radiopharmaceutical localizes in patient according to metabolic properties of that drug.*
- *Radioactivity decays, emitting gamma rays.*
- *Gamma rays that exit the patient are imaged.*

# Tumors

## Metabolic properties



- ❖ Increased vascularization
- ❖ Increased capillary permeability
- ❖ Newly proliferated capillaries
- ❖ Increased blood flow
- ❖ Metabolically active cells
- ❖ Increased energy demand

# Tumor cells

## Specific useful properties



- ❖ High density of some common receptors
- ❖ Expression of several specific receptors
- ❖ Expression of some specific tumor antigens

All these properties could be used for  
imaging and therapy

# Tumor Non-specific Diagnostic radiopharmaceuticals



- **PET or PET-CT**
  - ❖ F-18 FDG – anaerobic metabolism
- **Planar, SPECT or SPECT-CT**
  - ❖ Diphosphonates – bone scan
  - ❖ Ga-67 citrate – similar to FDG – localising agent
  - ❖ Tc99m Nanocolloid – bone marrow scan
  - ❖ Tc99m MIBI / Thallium 201 – several tumors

Demonstrate tumor sites but are *not specific for malignancy*

# Tumor Specific Diagnostic radiopharmaceuticals



- PET or PET/CT
- Planar, SPECT or SPECT/CT
  - ❖ I-123/131 MIBG for neuroendocrine tumours
  - ❖ I-131 for differentiated thyroid carcinomas
  - ❖ In-111 or Tc99m octreotide for tumours expressing somatostatin receptors.
  - ❖ Monoclonal antibodies labelled with In-111, I-123/131 or Tc-99m

*Binds directly to special tumor antigens or receptors  
or are accumulated by special metabolic pathway*



# Therapeutic radiopharmaceuticals

- **Non-specific**

- ❖ Sr-89, Sm-153, Re-189

- ❖ Bone pain palliation

- **Specific**

- ❖ I-131

- Thyroid cancer, as specific diagnostic if tumor significantly accumulates

- ❖ Y-90

- Zevalin – monoclonal antibody for B-cell lymphomas



# Physical Properties

## SPECT Radionuclides



Radionuclide	T/2 physical	Type of radiation	E(kev)
Technitium 99m(Tc-99m)	6 hrs	Gamma	140
Iodine I131	8 days	Gamma/ Beta	364/606
Iodine I123	13.2 hrs	Gamma	159
Gallium Citrate (Ga-67)	78.3 hrs	Gamma	90,190,290
Thallium Chloride 201 (Tl201)	73.1 hrs	X-ray	68-83
Indium 111 (In 111)	2.8 days	Gamma	173,247
Xenon 133	5.2 days	Gamma	81
Kripton 81m	13 secs.	Gamma	190

# Physical Properties of positron emitting ( **PET** ) Radionuclides



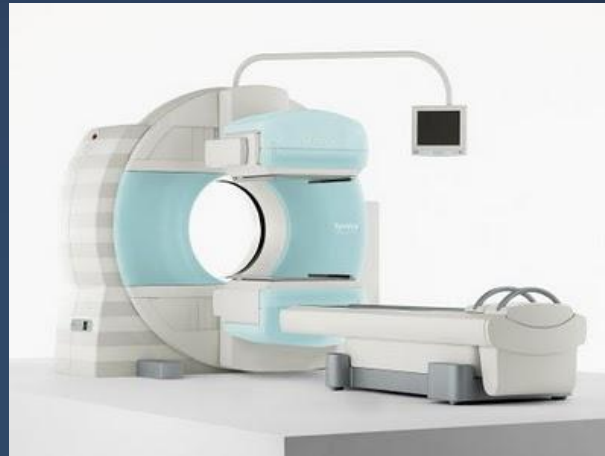Radionuclide	T/2 physical (min)	positron energy	Productivity
Carbon 11	20	0.96	accelerator
Nitrogen-13	10	1.19	accelerator
Oxygen-15	2	1.73	accelerator
Fluorine 18	110	0.635	accelerator
Gallium 68	68	1.9	generator (germanium 68)
Rubidium 82	1.3	3.15	generator (strontium-82)

# What are the nuclear medicine tumor imaging methods?

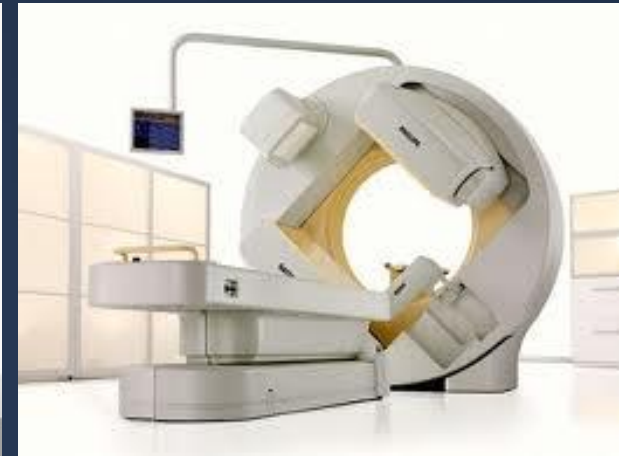

## Conventional tumor imaging :

- Planar
- SPECT
- SPECT-CT



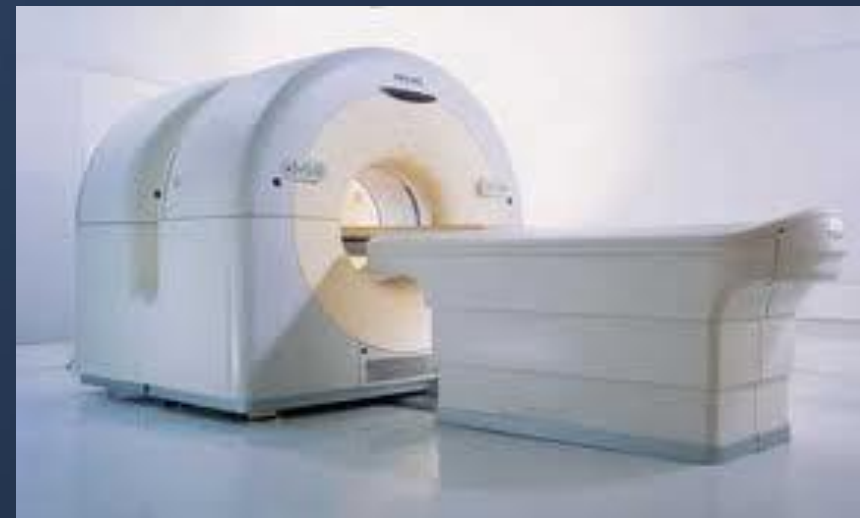PLANAR / SPECT



SPECT CT

## Onco PET :

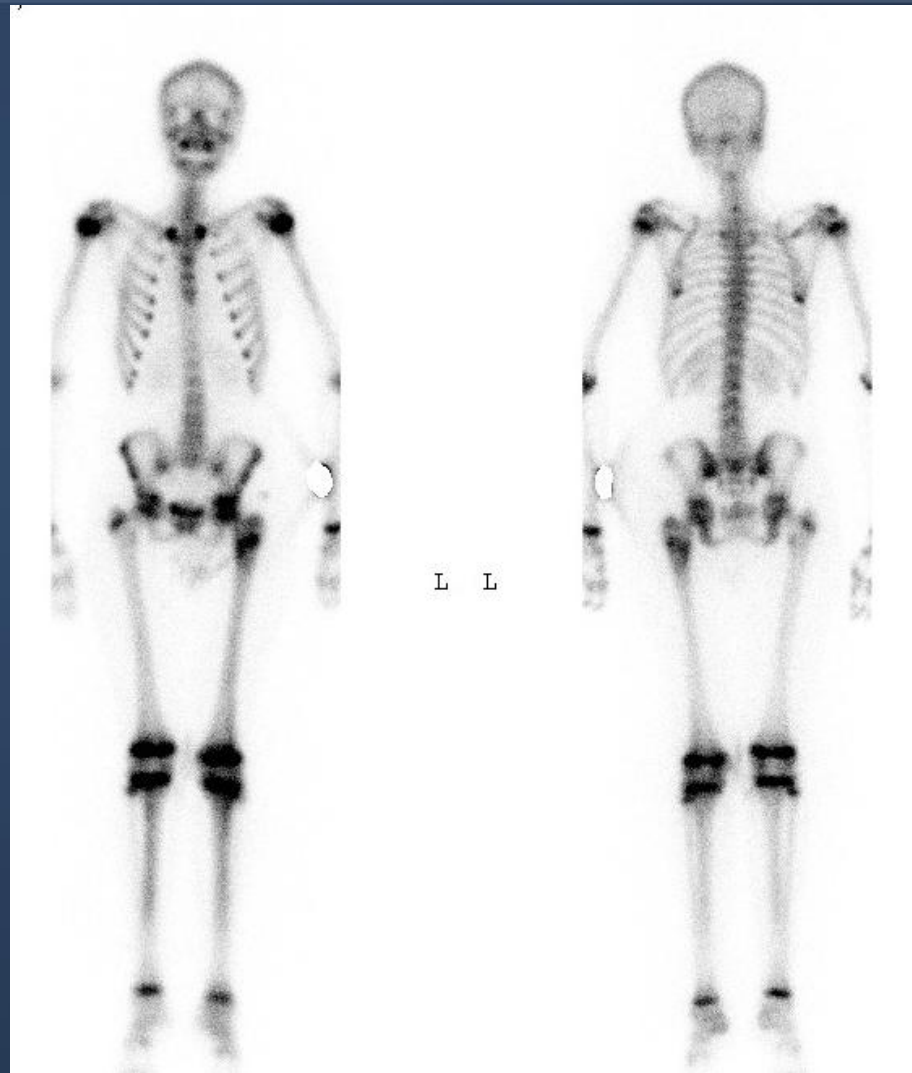
- PET
- PET -CT



PET CT

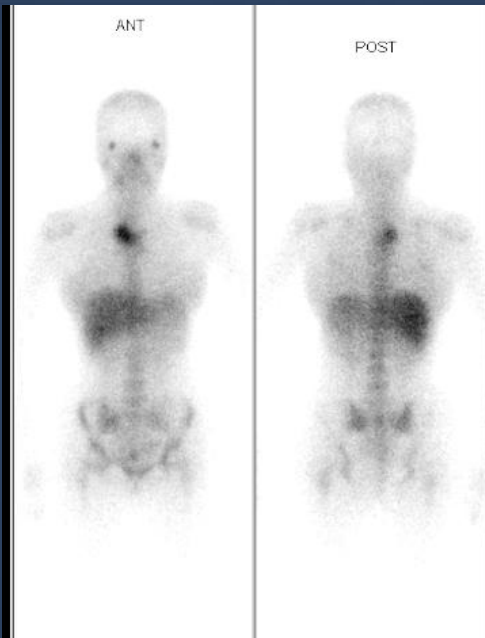
# NM Imaging modalities

## Planar Imaging

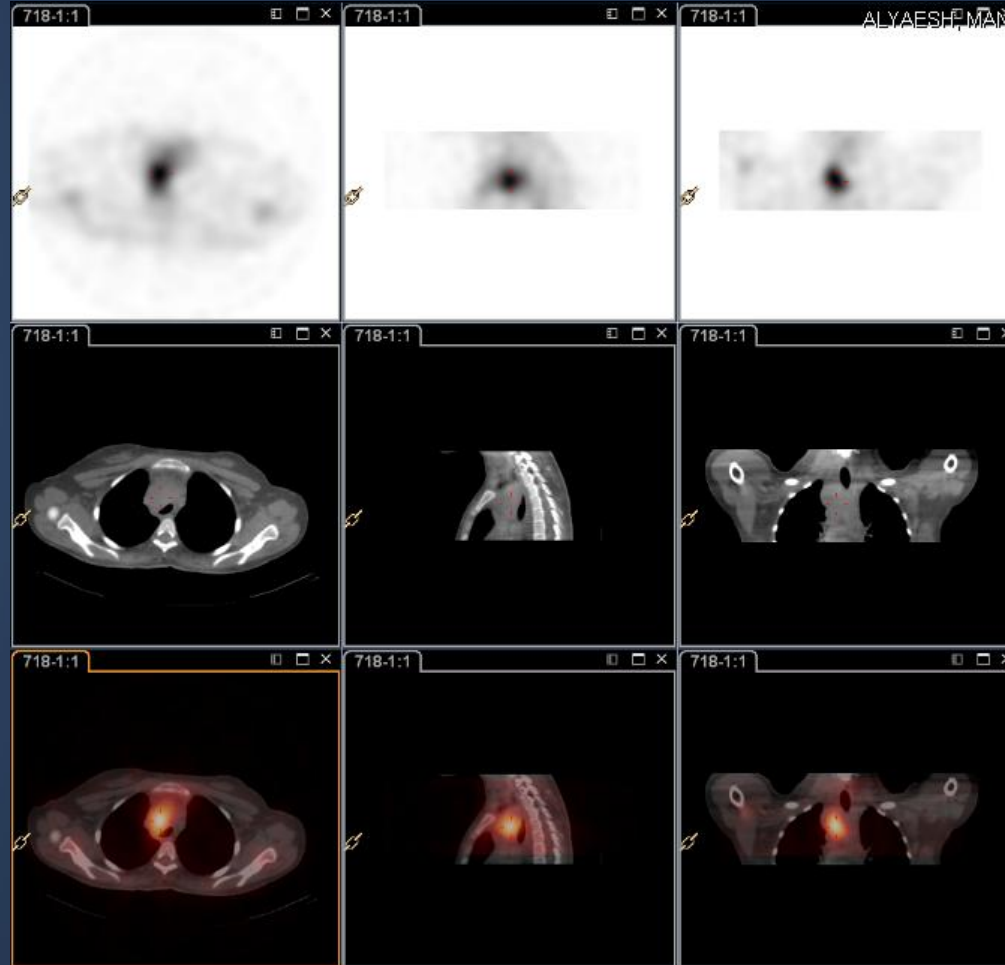


# NM Imaging modalities

Single Photon Emission Computed Tomography (SPECT) and SPECT CT



Whole Body Gallium Scan : Planar Image

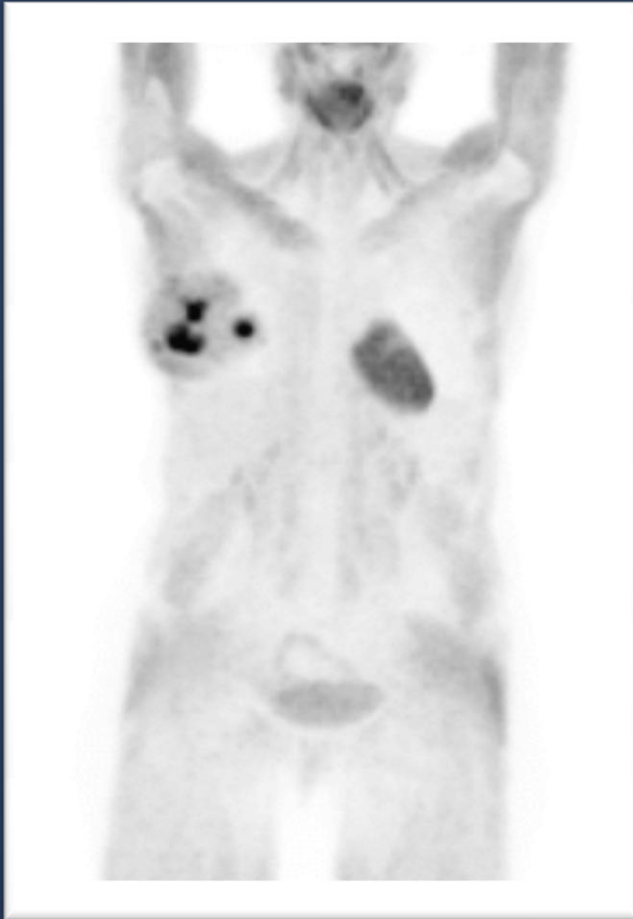

SPECT

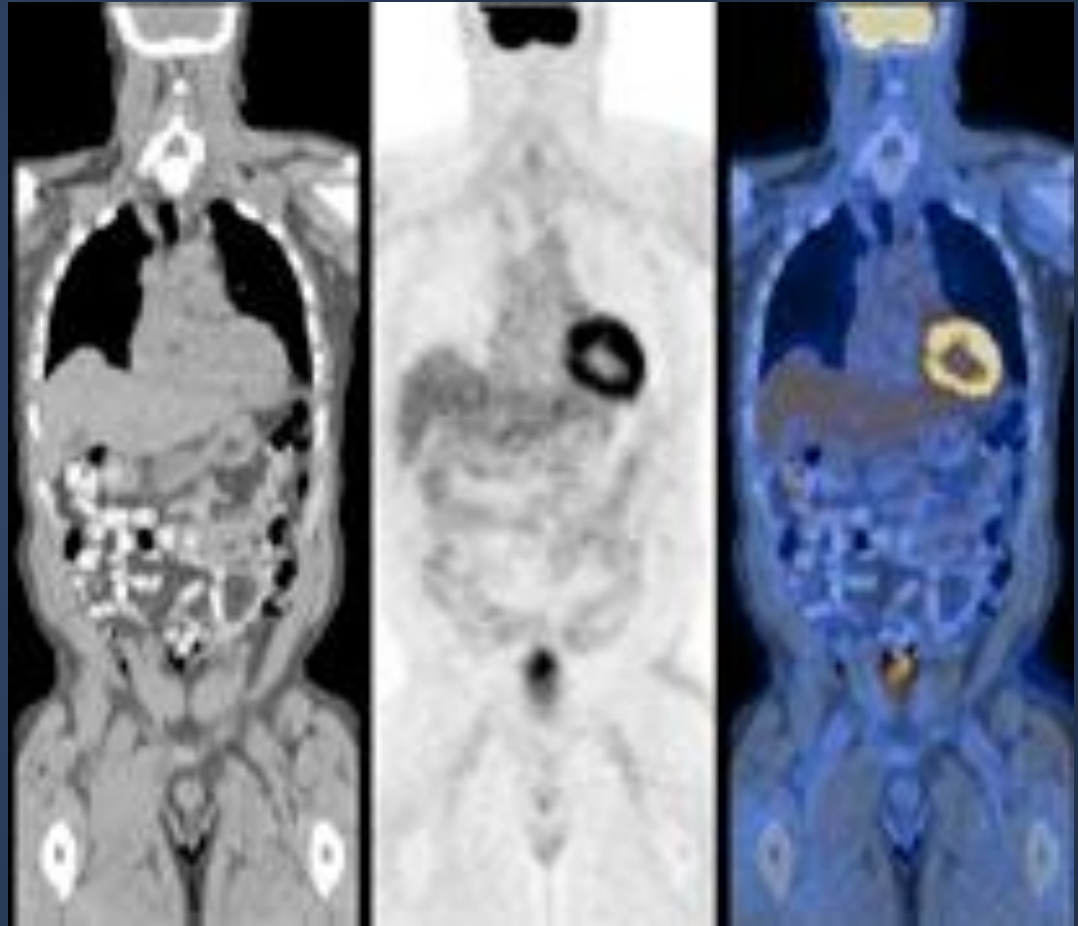
SPECT/CT

# NM Imaging modalities

Positron Emission Tomography (PET) and PET CT



PET



PET/CT

# Role for Nuclear Medicine In Oncology



- **Diagnosis**
  - Specific or non-specific
- **Staging**
  - Important for proper therapy
- **Follow-up**
  - Early detection of recurrence
- **Treatment**
  - Specific or non-specific

# Tumor Imaging



## Non specific tumor imaging agents:

- **Tc-99m MDP bone scan:** Detection and follow up of bone metastasis
- **Gallium 67 :** Staging ,Restaging & therapy assessment of HD , NHL , Lung cancer
- **Thallium 201 :** Tumor viability & tumor seeking.  
{Tc-99 m Agents (MIBI ,TETRO.).}
- **F18 – FDG :** Staging ,Restaging & therapy assessment of HD , NHL , Lung cancer

## Specific tumor imaging agents:

- **In-111 ( TC99m) Octreotide :** Neuroendocrine tumors
- **I -123 MIBG :** Neuroendocrine tumor
- **I -131 :** Lung mets. thyroid carcinoma



# Bone scan

## “Procedure”



- **Radiopharmaceuticals**

Technitium 99m **M**ethylene **D**iPhos**P**honate (Tc-99m **MDP**)

- **Tissue accumulation depends on**

- blood flow
- capillary permeability
- metabolic activity of osteoblasts and osteoclasts
- mineral turnover

- **Dose:** 500 to 800 MBq (Megabequerel) / 15- 20 mCi (millicurie)

- **Imaging time:** 2 to 3 hours postinjection – WB + SPECT

- **Potentials of bone scan:** Positivity many months before an abnormality can be detected on X ray

# Bone Scan In Oncology

## Indications



**I- Metastatic Disease:** Lung cancer, prostate, breast, thyroid, and renal tumours

- Diagnosis.
- Initial staging.
- Restaging.
- Asses response to therapy.

**II- Primary Bone Tumors :**

- Malignant or Benign
- Therapy planning for patients with primary bone malignancy ( e.g. Osteogenic & Ewings sarcoma)

**III- Soft tissue tumors :**

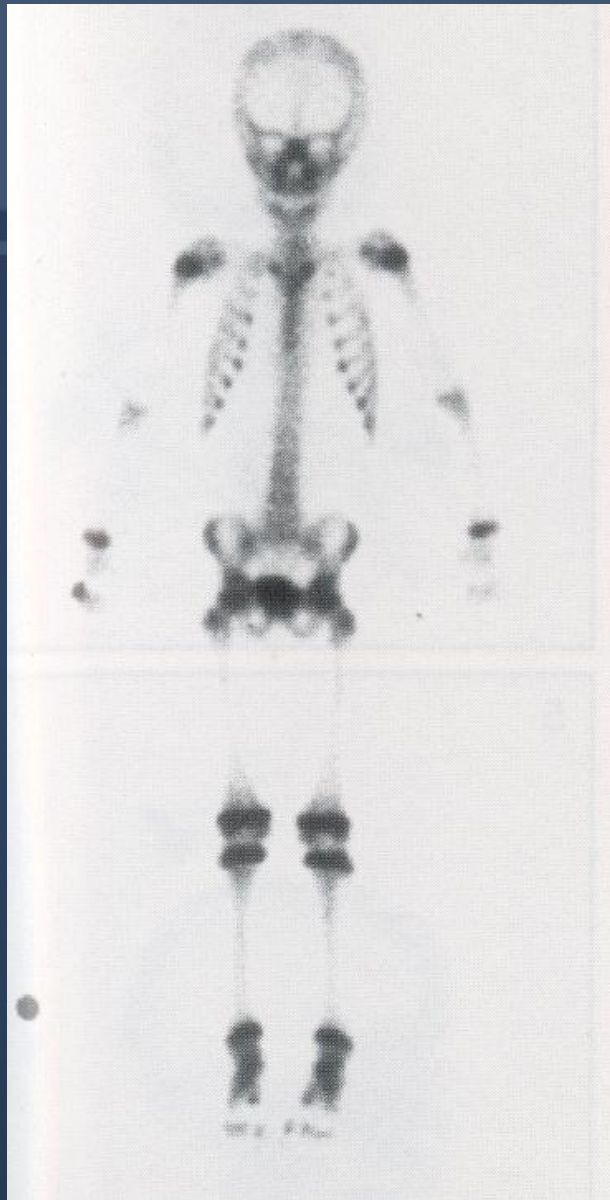
- Primary
- Metastases

# Bone Scan In Oncology

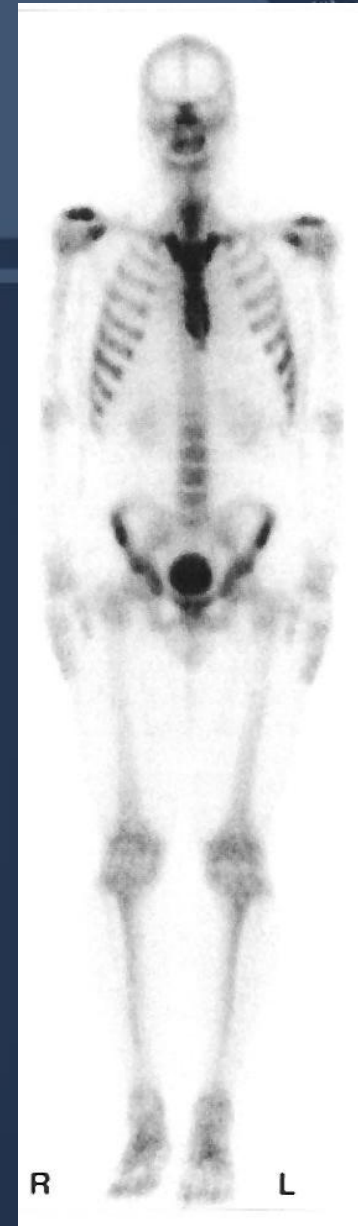## Imaging features



- a. Hot lesions** : Majority of bone tumors.
- b. Cold lesions** : Purely osteolytic tumors ( renal cell carcinoma, thyroid cancer, anaplastic tumors), radiation therapy
- c. Superscan** : Diffuse increased skeletal uptake with no soft tissue or kidney activity (e.g. CA prostate ,breast ,..etc).
- d. Normal distribution** : Marrow tumors  
(e.g. lymphomas, leukemia, multiple myeloma).
- e. Soft tissue uptake** : Soft tissue tumors may concentrate the tracer.
- f. Flare phenomenon** – increased number of lesions in the case of effective therapy



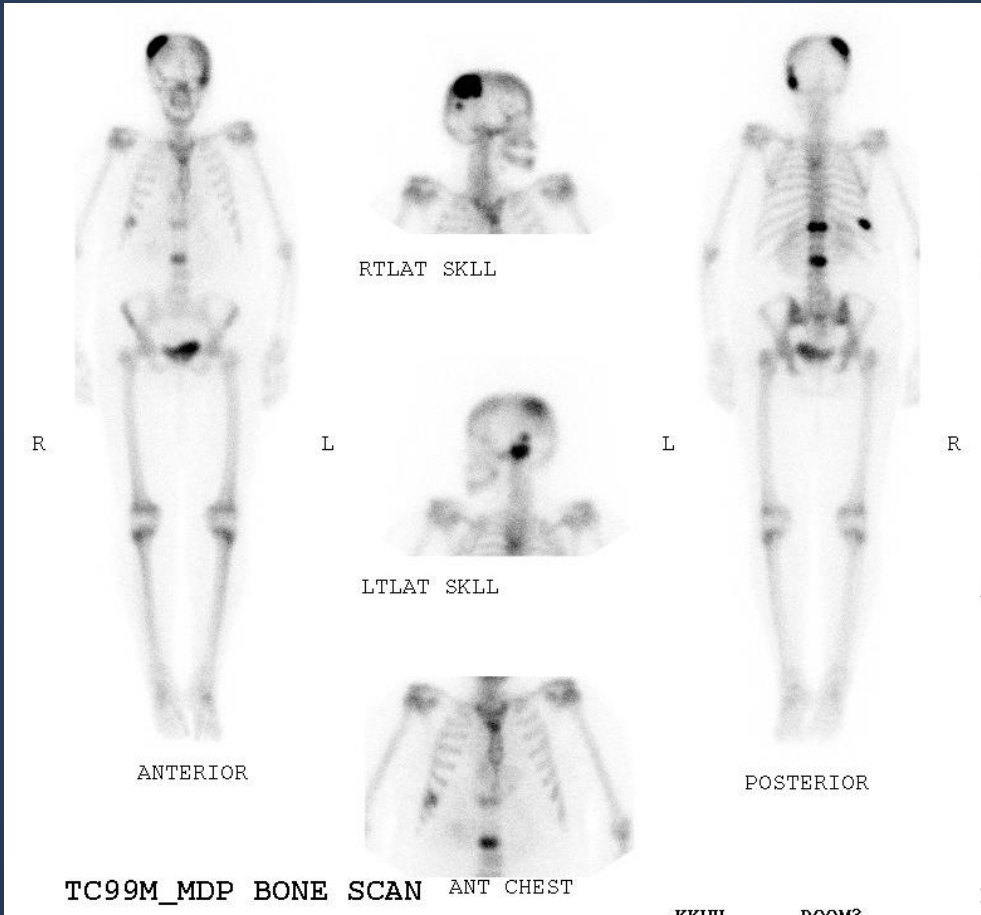
# Normal Whole Body Bone Scan



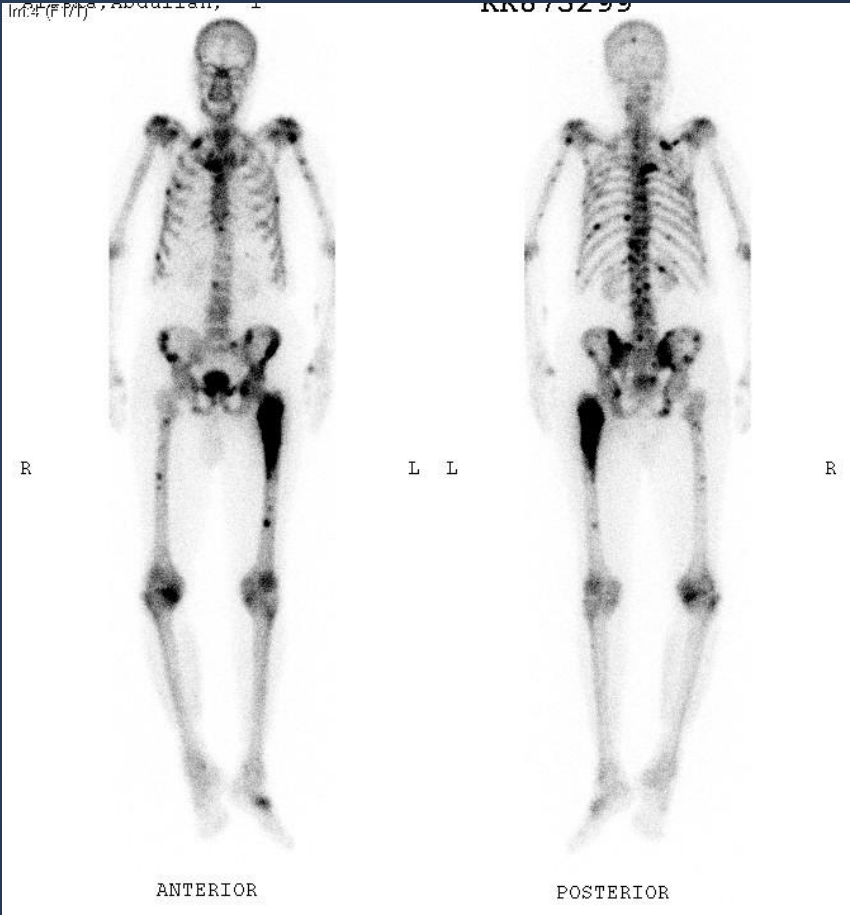
An 8 year old child

A 25 yrs old adult

# TUMOR STAGING

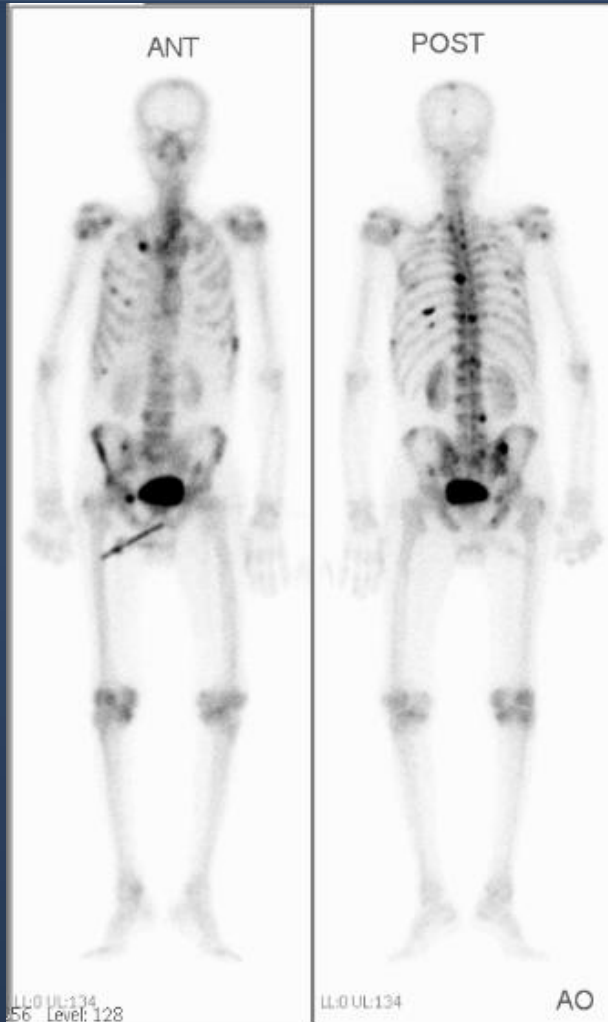


Ca Breast

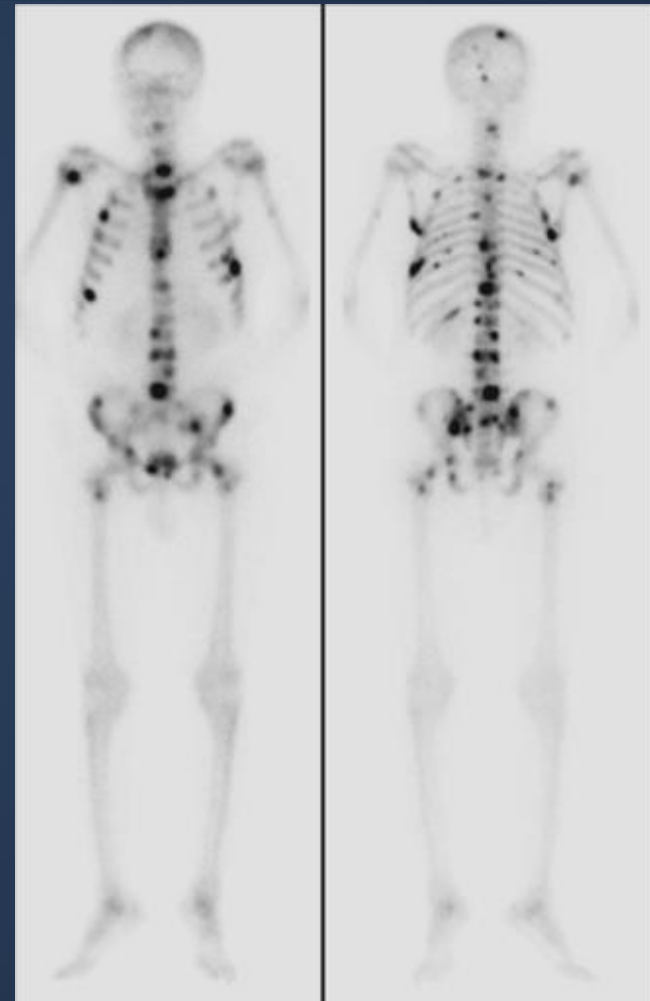


CA Prostate

# TUMOR STAGING



CA LUNG



CA STOMACH

# Bone Scan In Metastatic Disease

## Diffuse involvement ( Superscan )



**Definition :** Bone scan with diffuse symmetrical increased uptake and almost absence of soft tissue activity, lack of kidney activity and bone uptake seen in blood pool images.

### **Causes :**

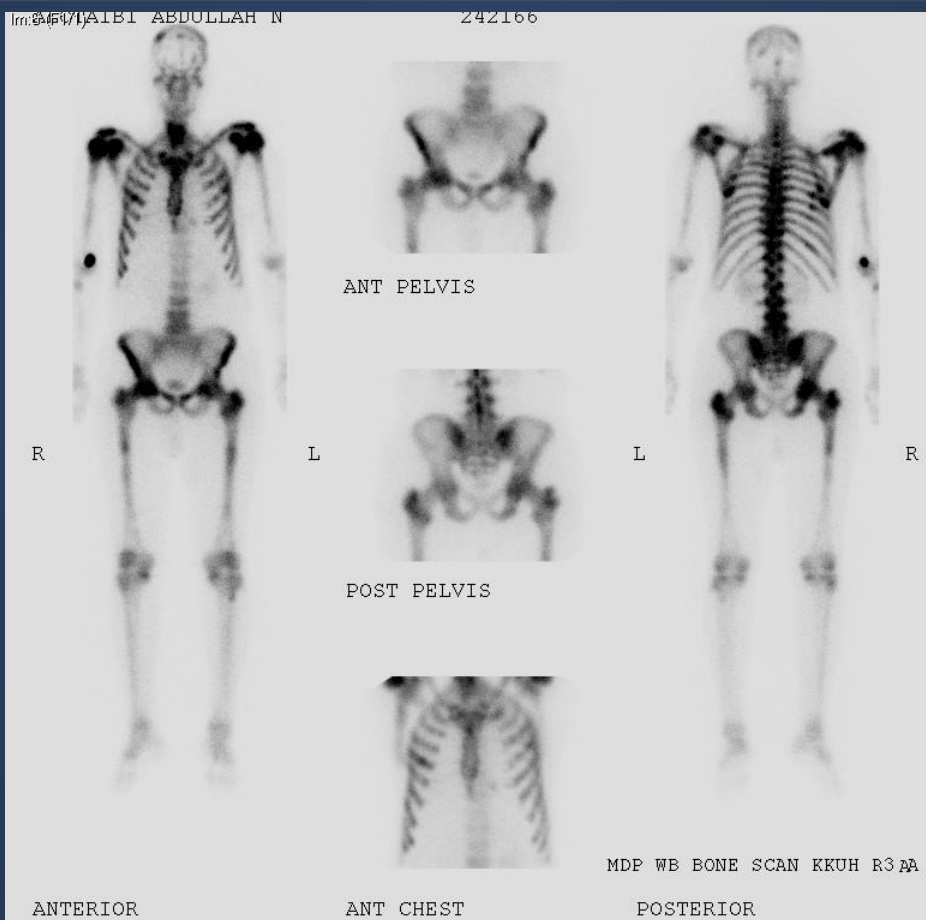
***a. Bone metastases :*** Prostate, breast, lung, bladder and lymphoma.

***b. Non tumor causes:*** HPT, osteomalacia, Pagets disease and fibrous dysplasia

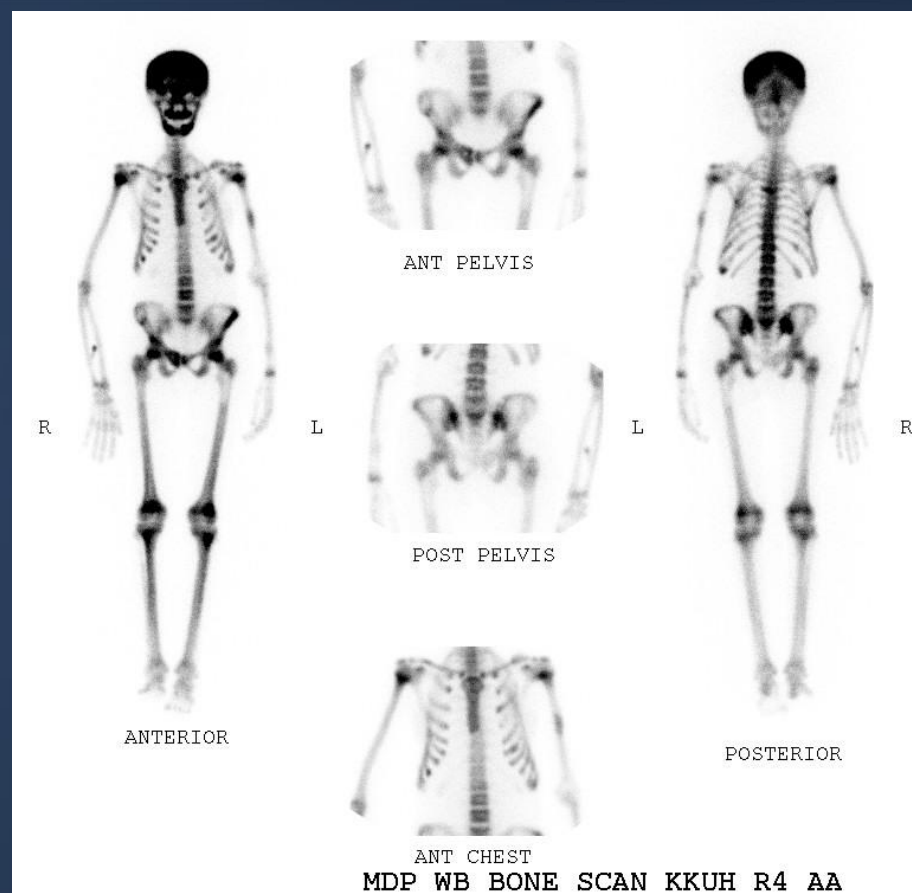
### **Important clues :**

In metabolic bone disease the calvarium and long bones are involved unlike in bone metastases.

# Superscan



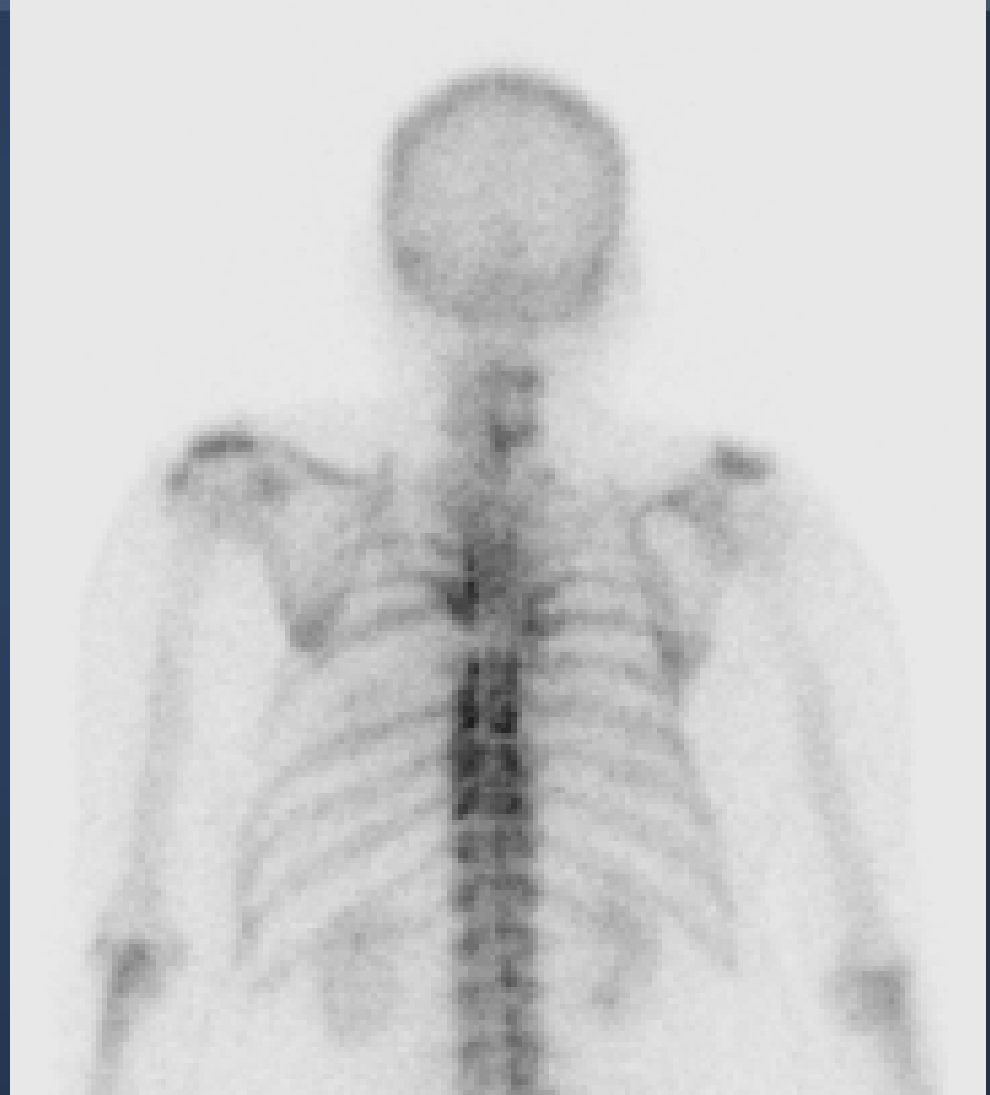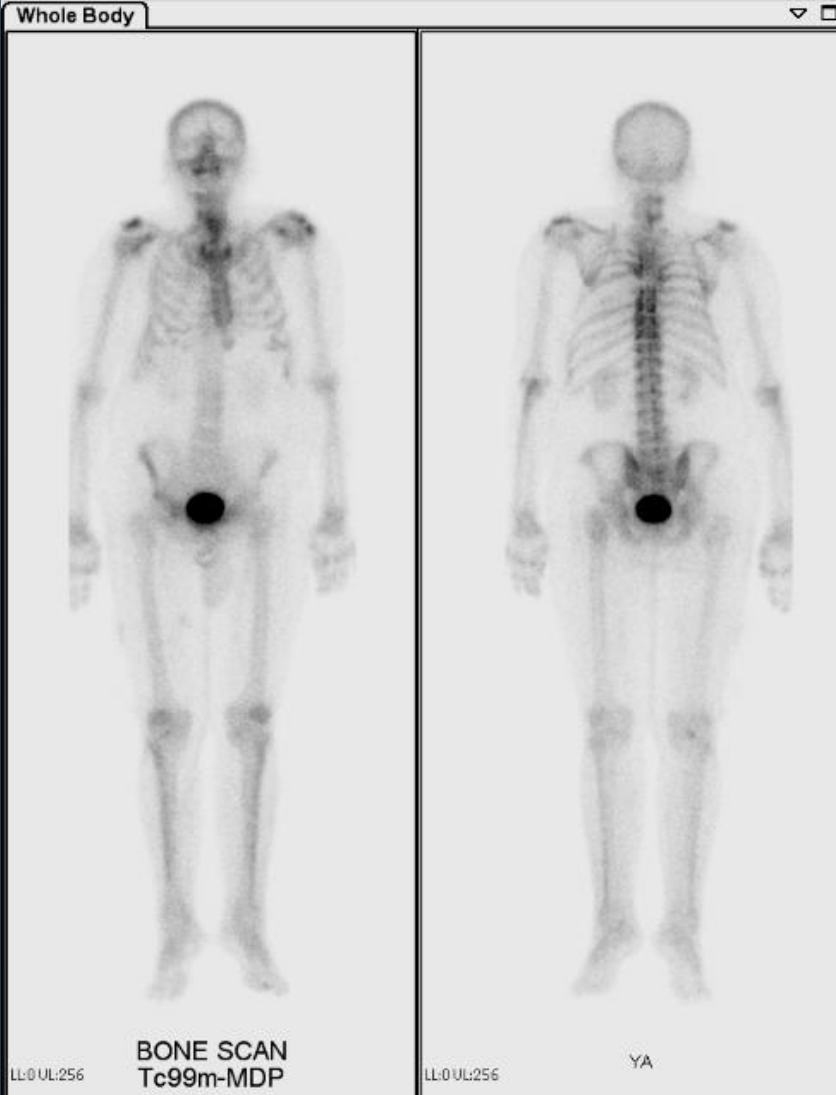**CA Prostate**



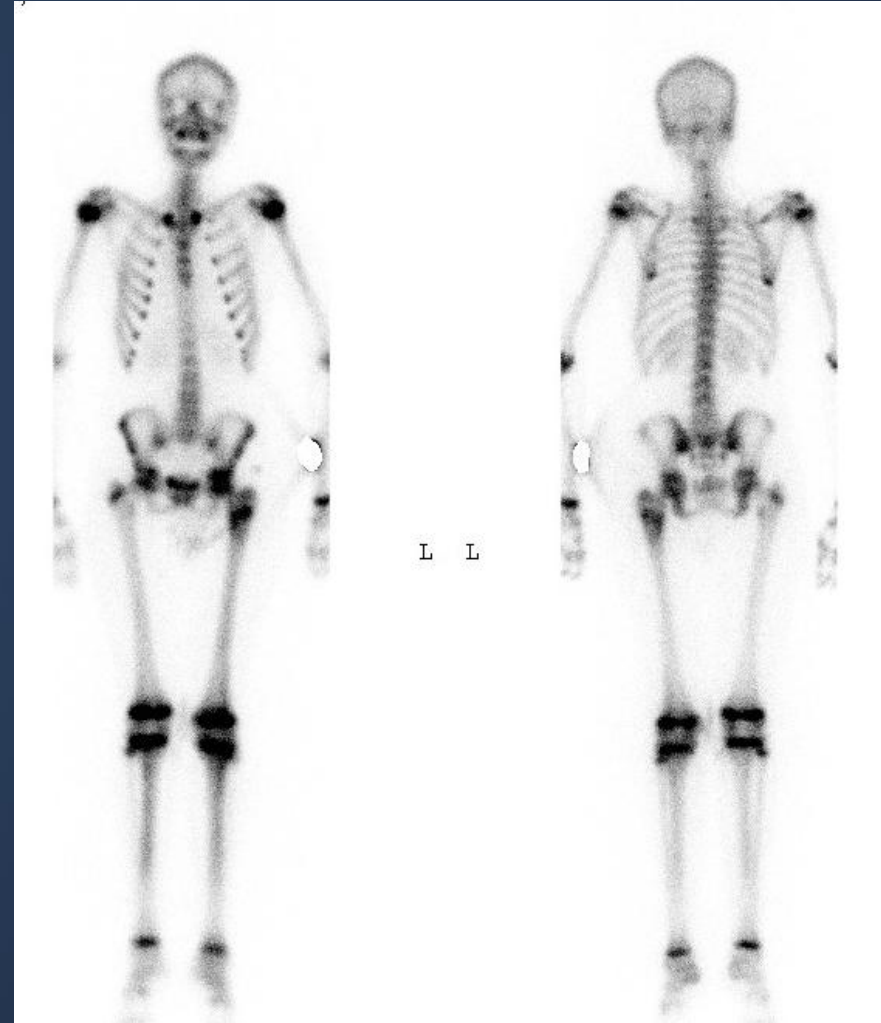
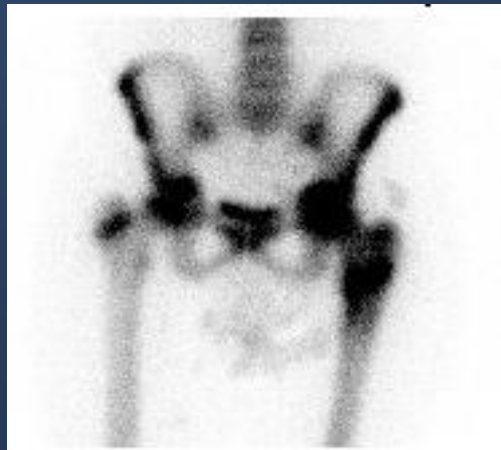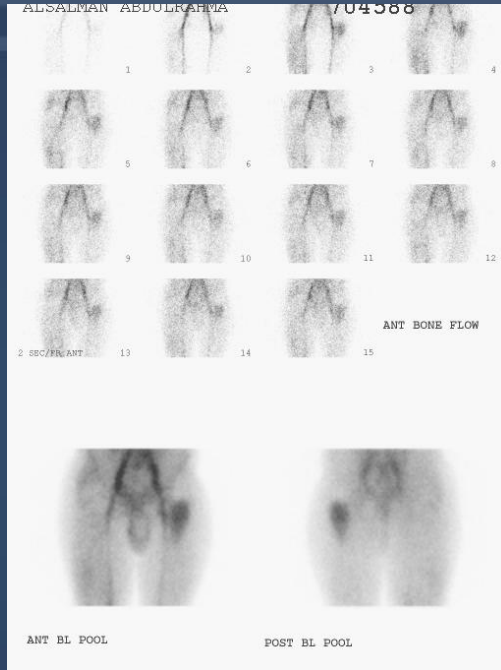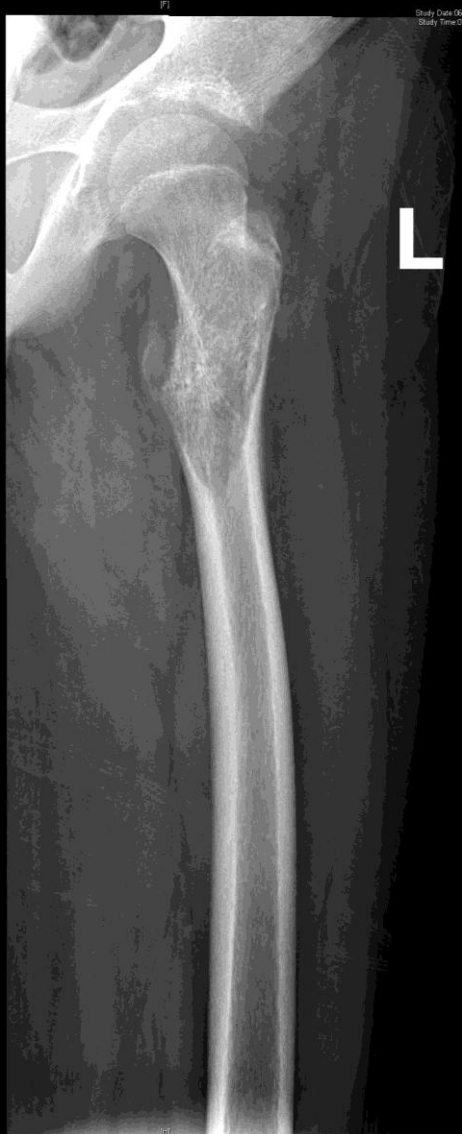**HPT**



# Pure Lytic Lesions

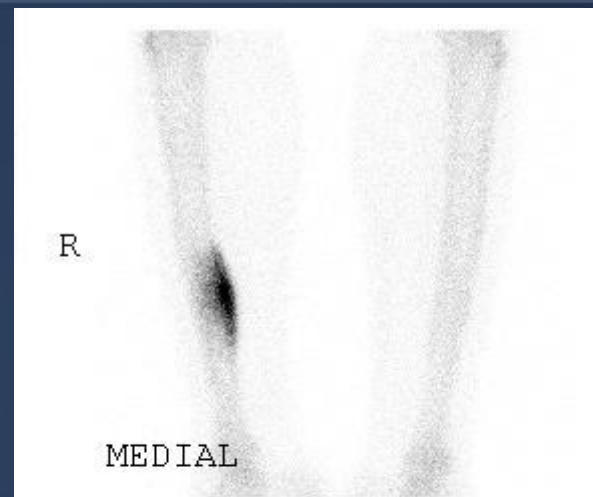
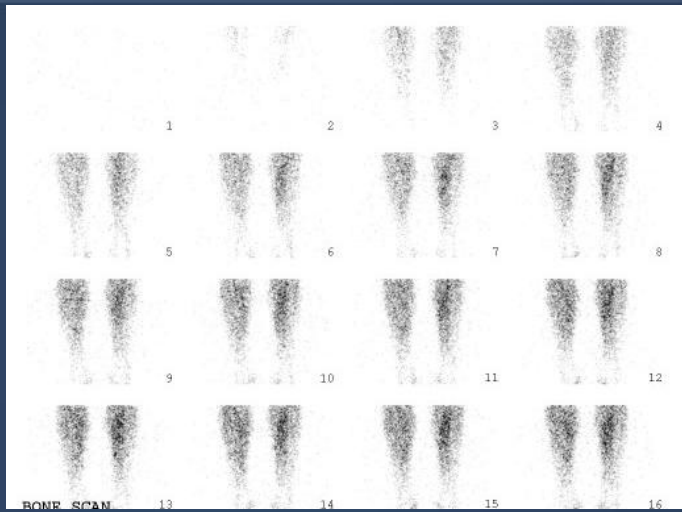


# Ewing's Sarcoma



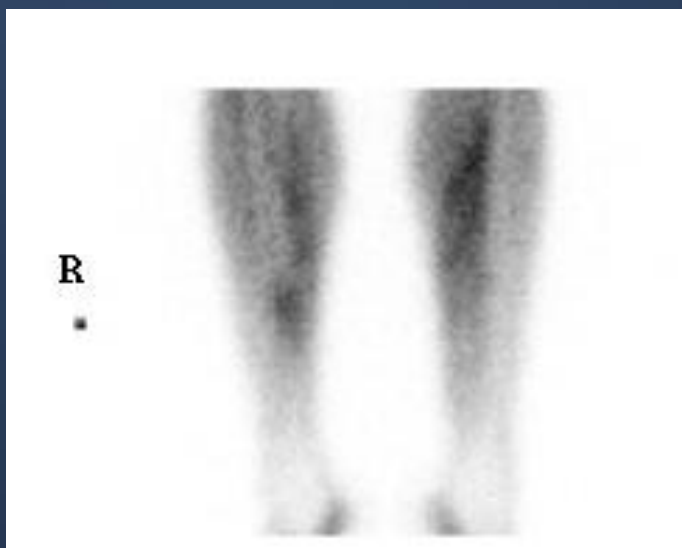
# Bone Scan In Bone Tumors

## Osteoid Osteoma

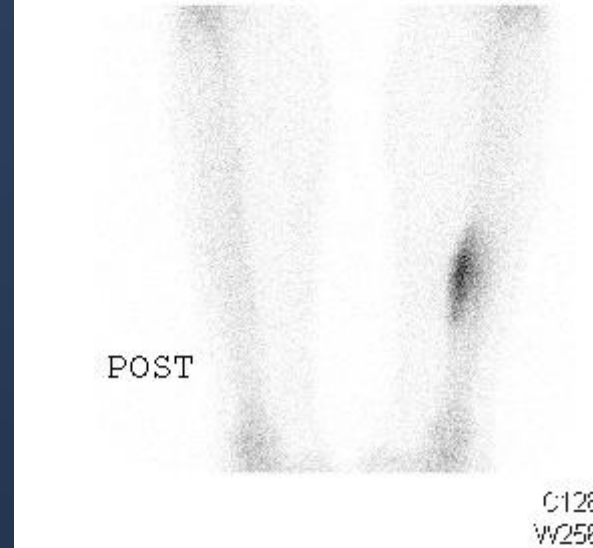


R

MEDIAL



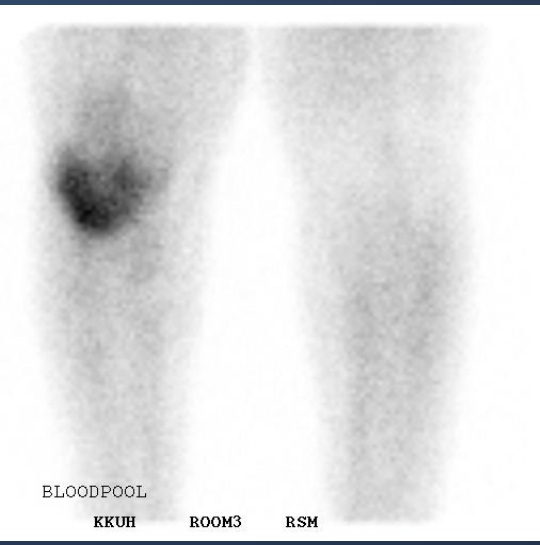
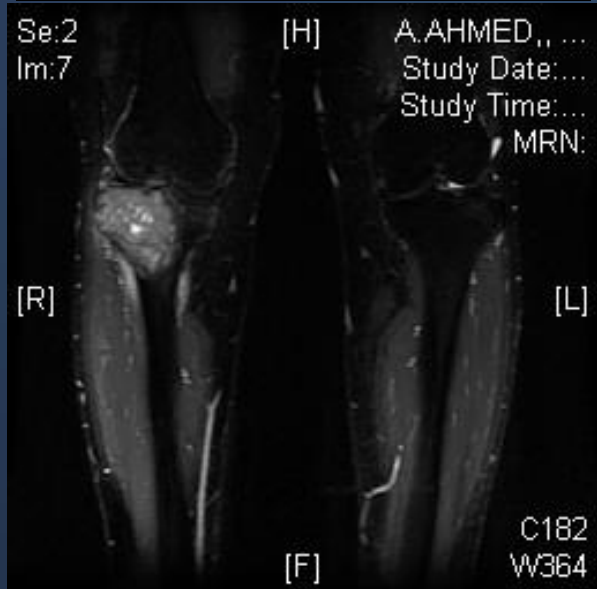
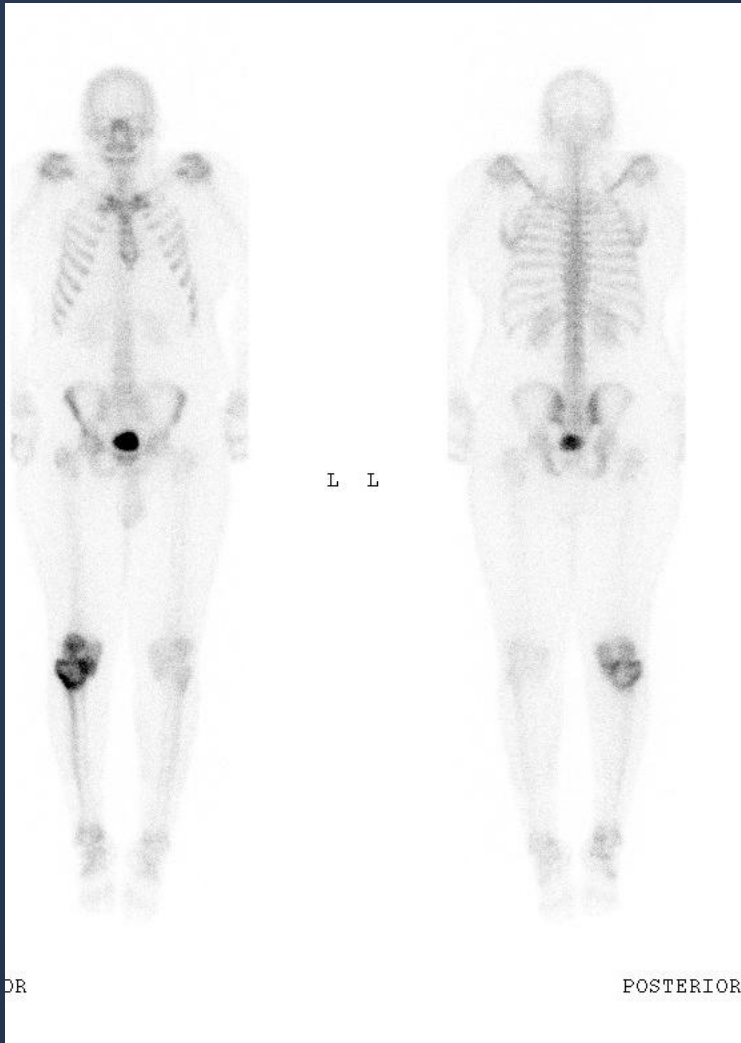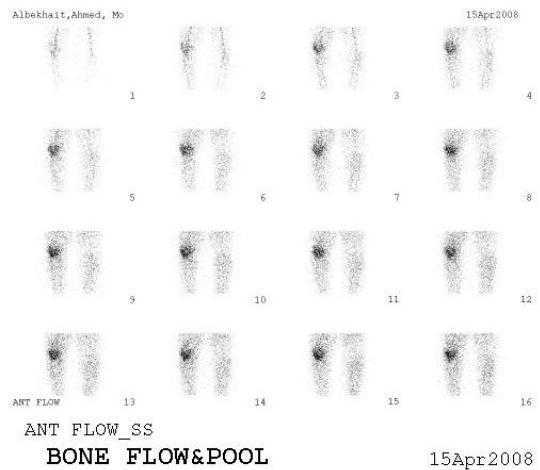
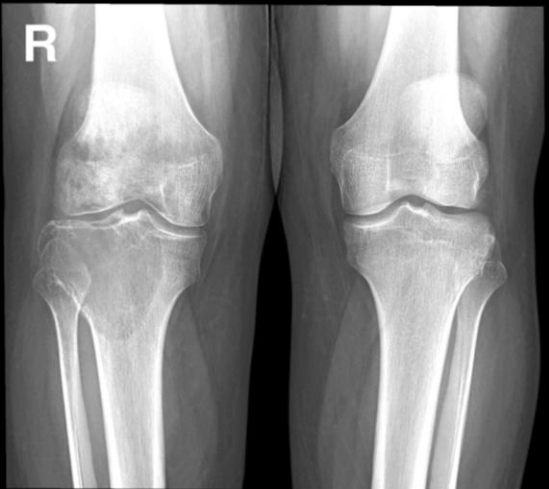R



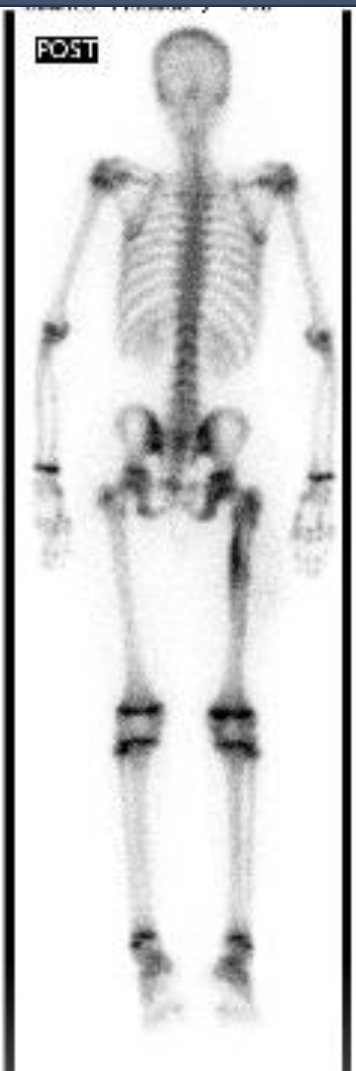
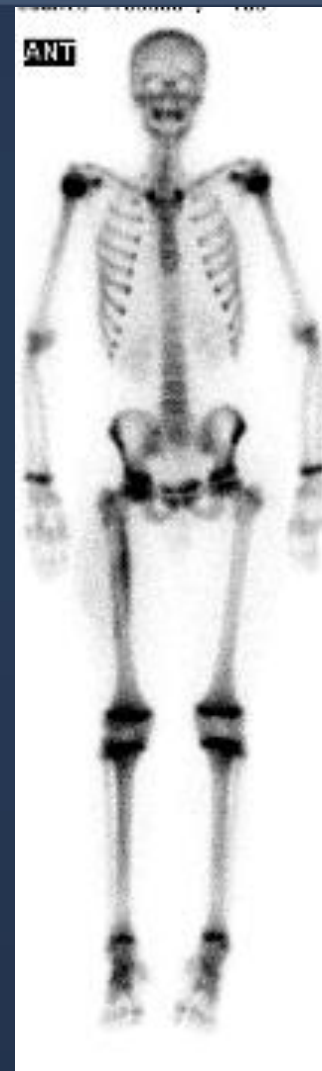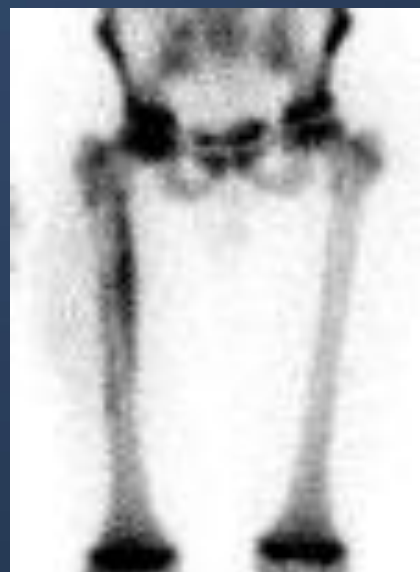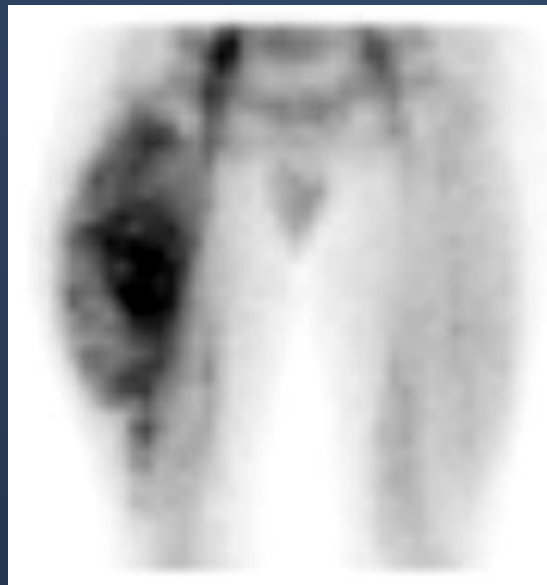
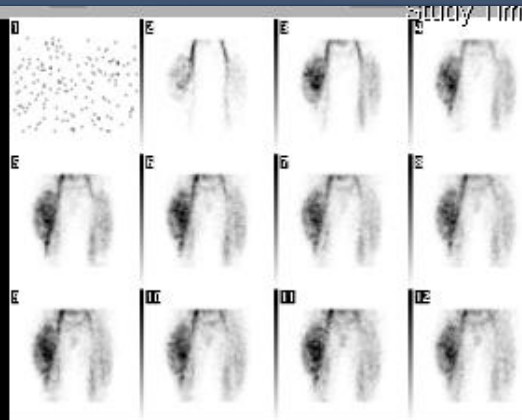
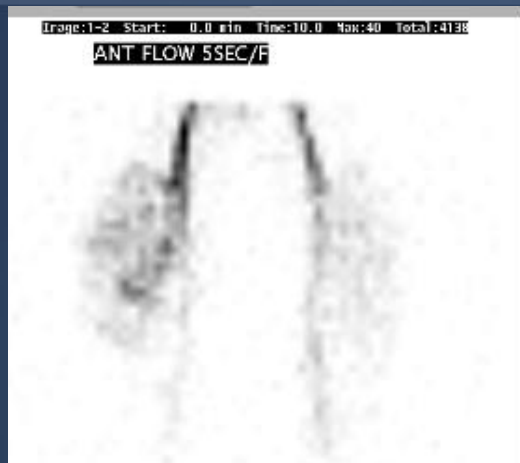POST

C128  
W256

# Giant Cell Tumor



# Soft Tissue Sarcoma



# Gallium 67 (Ga-67) scan



**Properties:** Introduced in seventies of 20th century for lymphomas

- **Mechanisms of accumulation**
  - Tumour viability
  - Blood flow
  - Capillary permeability
  - Lymphatic drainage
  - Binds to Transferrin receptors on the tumour cells
- **Non specific for infection-inflammation and tumors**
- **Excretion: Kidneys and large bowel**

## **Imaging Protocol:**

- **Patient preparation** : Laxatives for bowel preparation post injection, nothing else
- **Several weeks post tumor therapy (FN)**  
Radiation therapy and chemotherapy can alter the normal pattern of gallium distribution
- **180 MBq (4-5 mCi) is usually administered**  
Imaging follows after 48 – 72 hours  
WB + SPECT/SPECT CT, medium-energy collimator

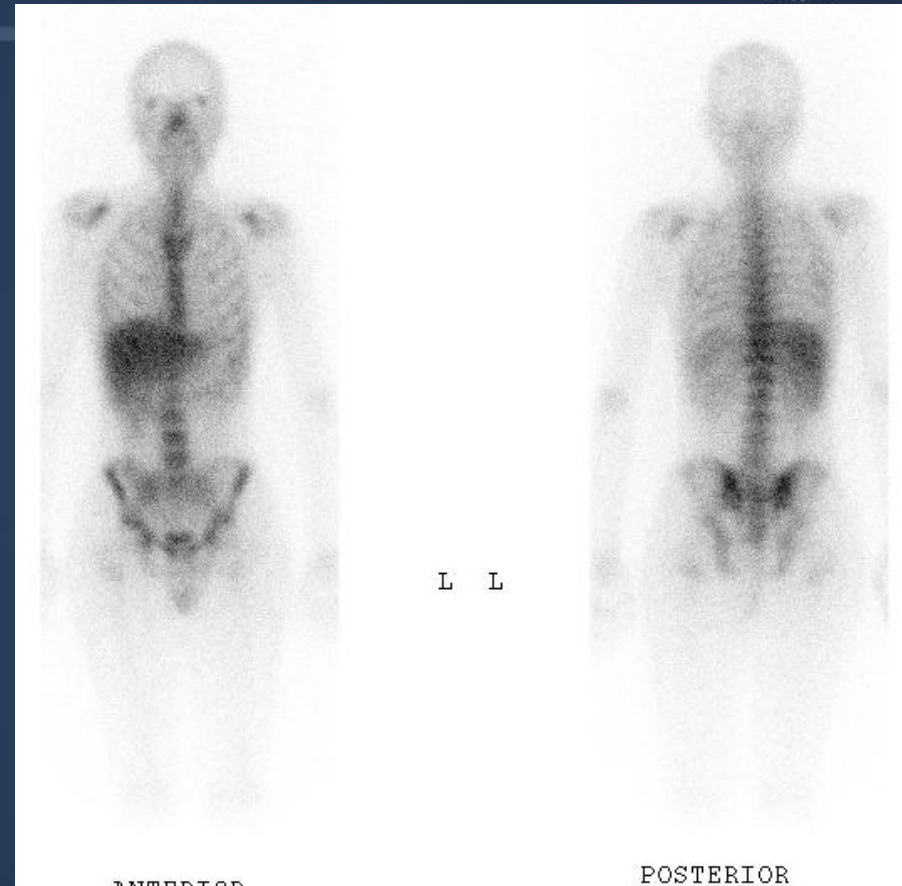
# Normal Ga-67 scan

## Normal scan

- Accumulates in bone marrow and liver.
- Splenic uptake is variable.
- The kidneys are usually visualized and also lacrimal, salivary, nasopharyngeal and genital activity is often present.
- Female breasts can be visualized, but accumulation is physiologically symmetrical
- Radioactivity is commonly seen in the colon

## Clinical indications

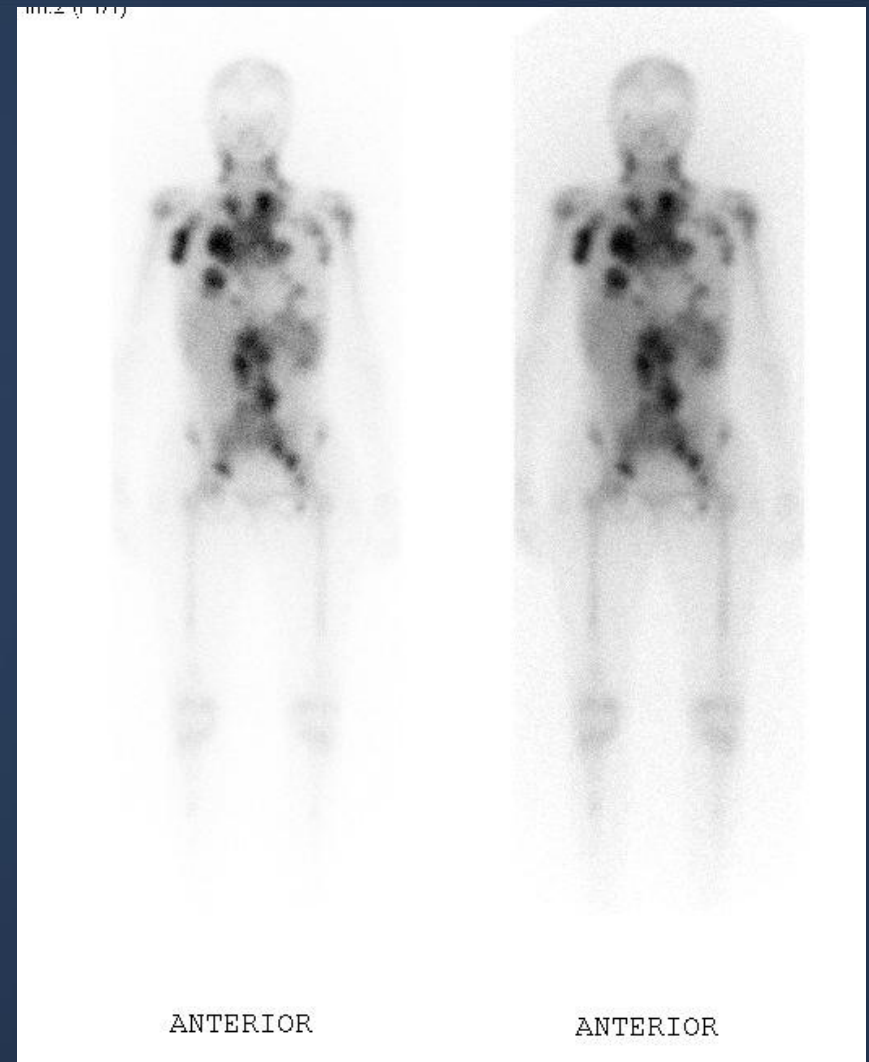
- Lymphoma
- Melanoma
- Lung cancer
- Hepatoma



# Gallium Scan in Lymphomas



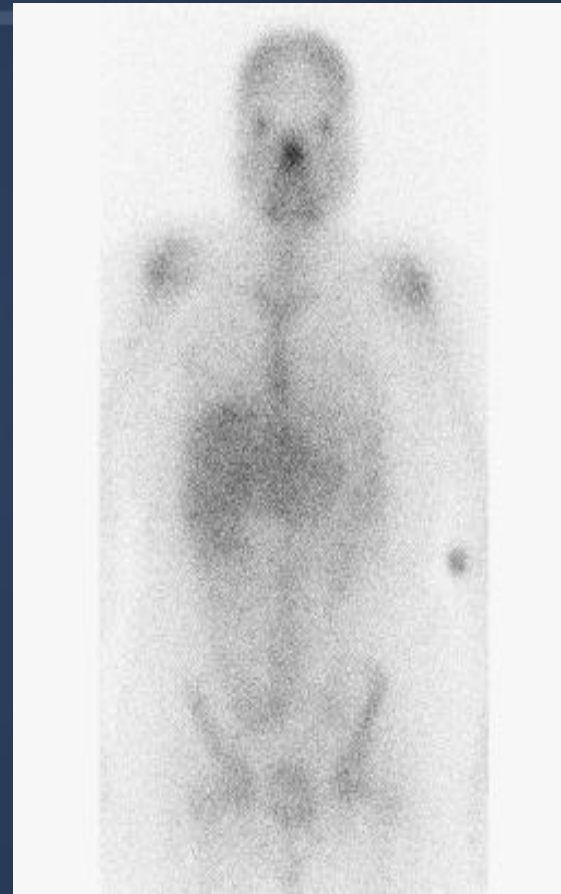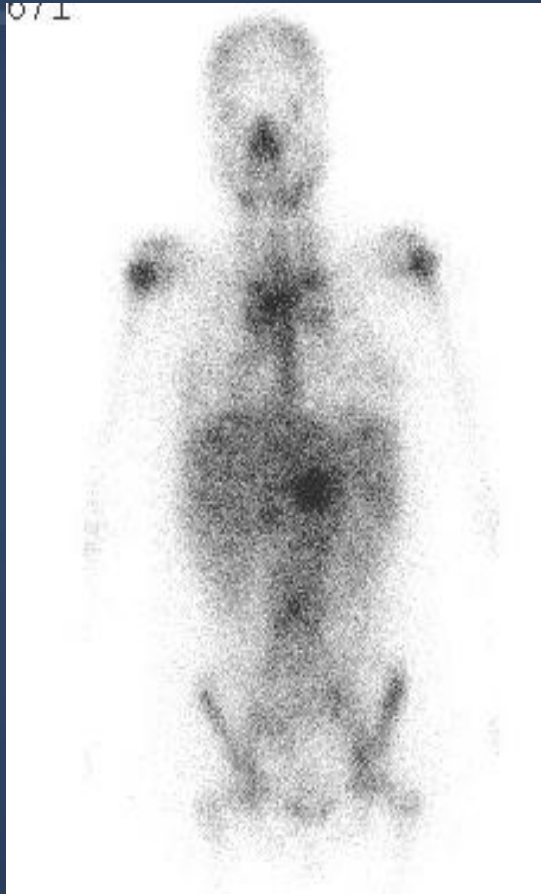- Staging
- Follow up and monitoring of therapy
- Detection of tumor recurrence
- Differentiate posttherapy changes : tissue necrosis and fibrosis from local recurrence.





# Ga-67 Scan In Lymphoma

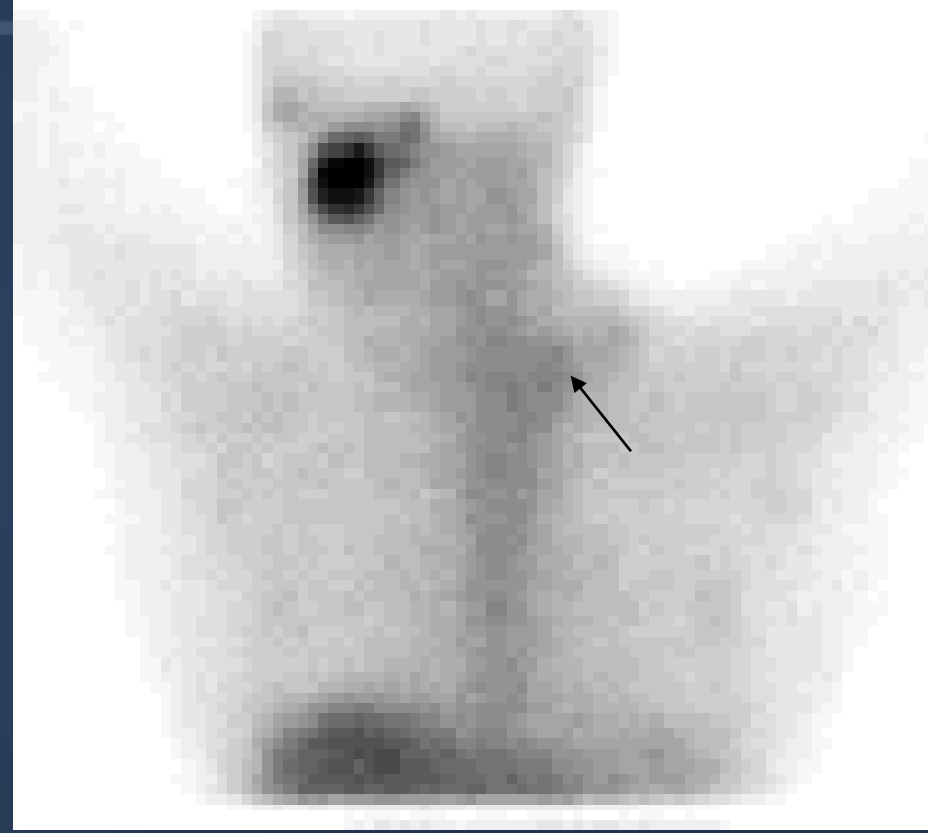
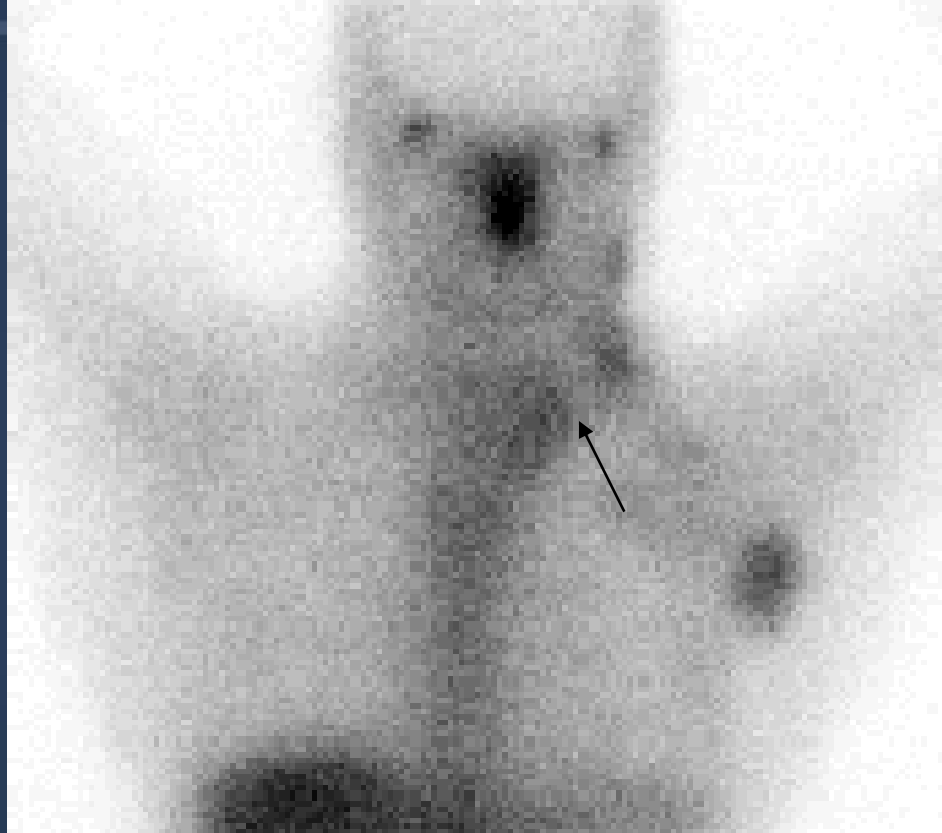
## Prediction of response to therapy



**Normalization of a positive pre-therapy scan** : A negative scan after one cycle or at mid cycle is associated with a high likelihood of complete response .

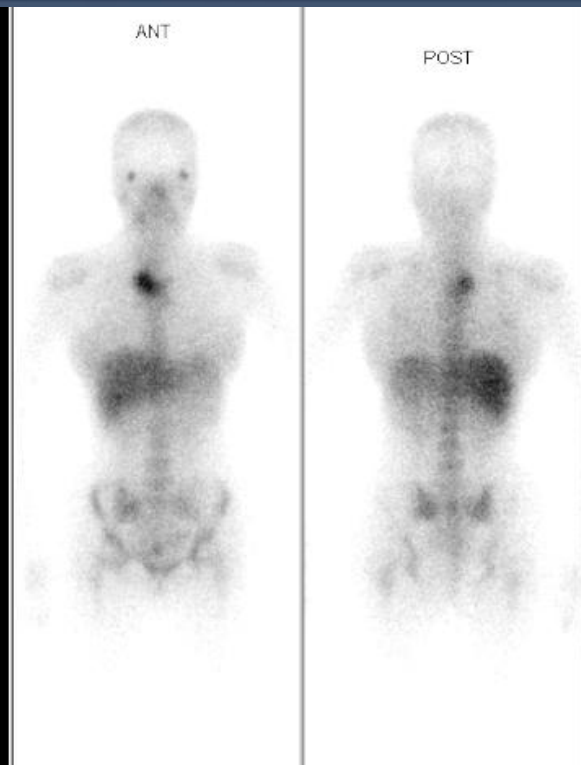
# Ga-67 Scan In Lymphoma

## Prediction of outcome

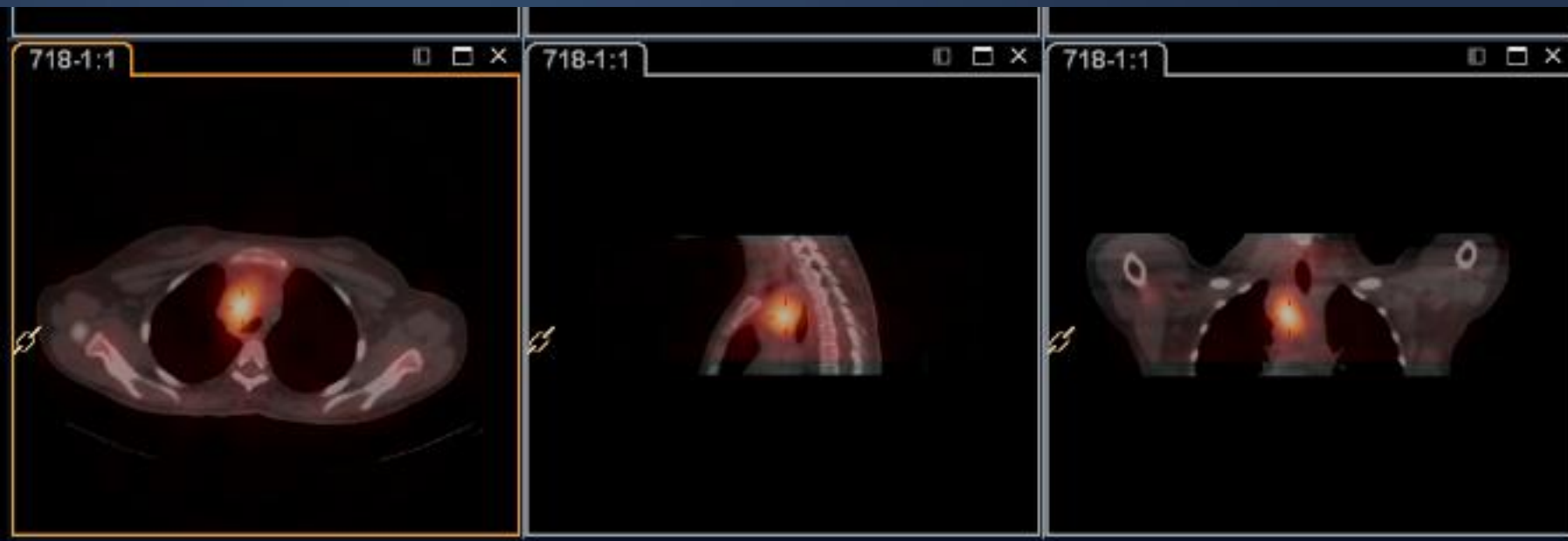

**Residual gallium uptake after treatment is a poor prognostic sign, indicates viable tumor and treatment should be modified.**

# Gallium Scan NHL



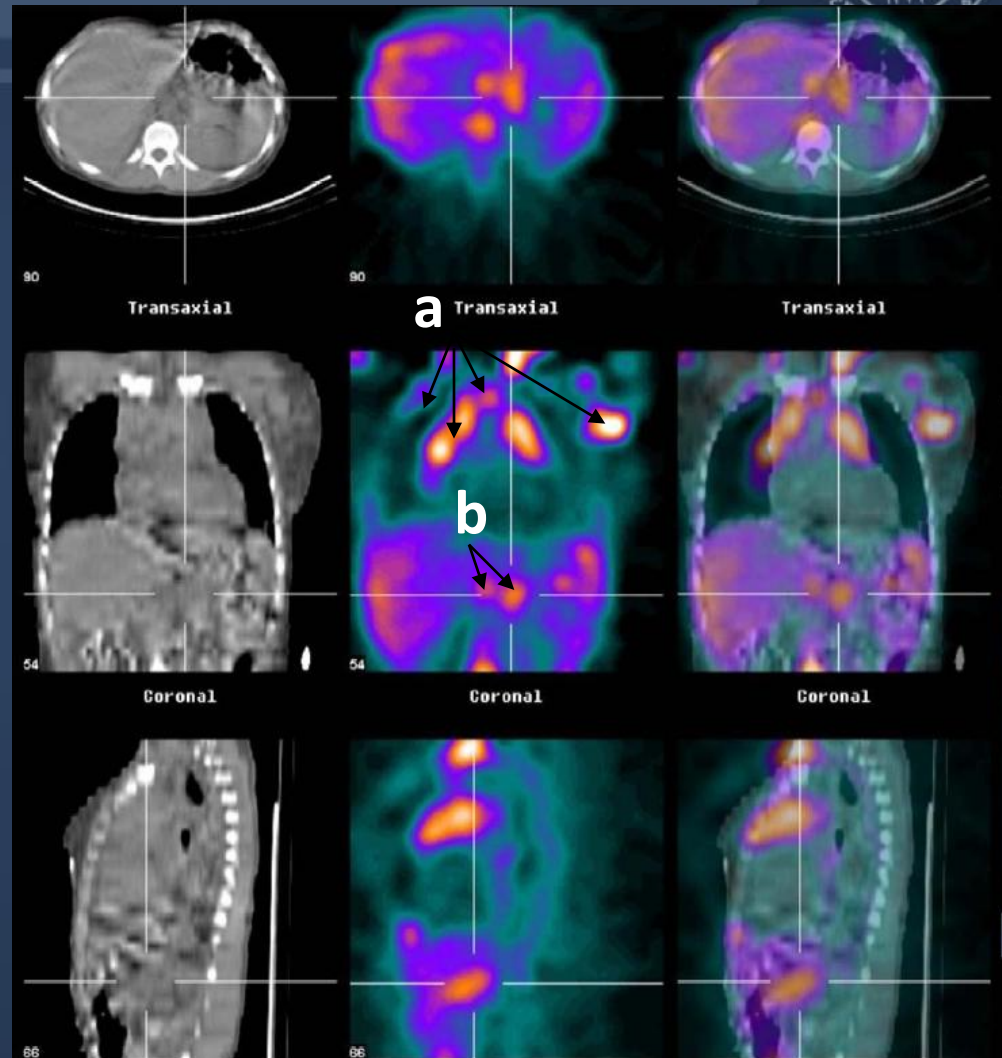
## Planar Vs SPECT CT



# Ga-67 SPECT/CT : Staging HD

Abnormal Ga uptake (a) in supraclavicular, axillary, Paratracheal, parahilar and para-aortic lymph nodes and in the spleen, at lesion sites corresponding to those observed on CT.

The para-aortic lymph node uptake (b) combined with CT findings allowed the diagnosis of subdiaphragmatic disease and excluding bowel activity.



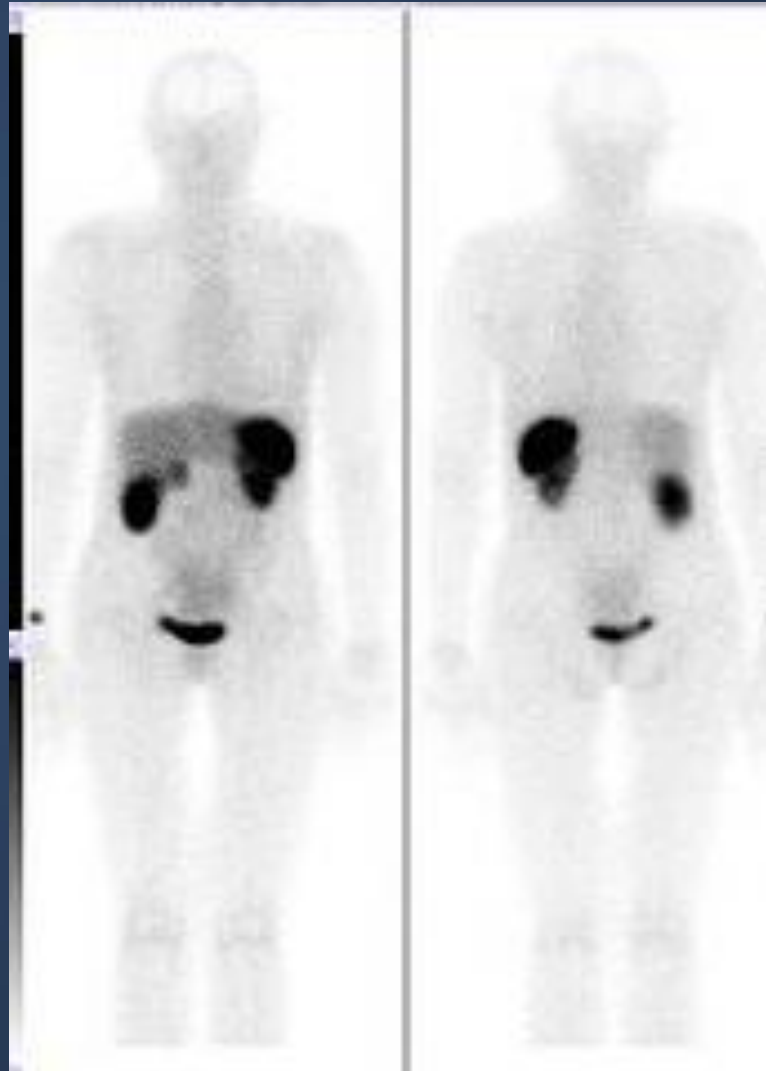
# Neuroendocrine Tumors



- In-111 octreoscan.
- I123 MIBG Scan.

# Somatostatin Receptor Imaging Indium-111 Octreoscan

**NORMAL STUDY**



# In - 111 octreoscan

## Insulinoma

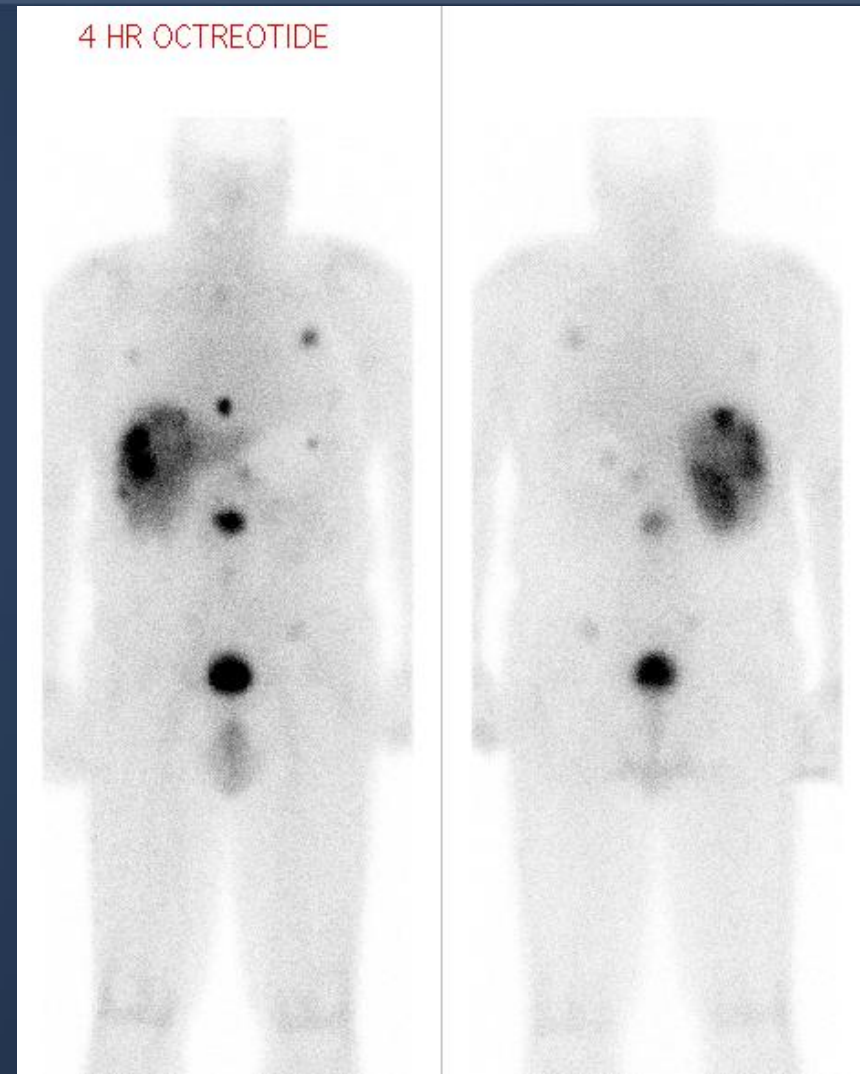


### Clinical History

The patient is a 66-ys male with insulinoma, now being evaluated for evidence of recurrent and/or metastatic disease.

### Findings :

Multiple lung, mediastinum , liver and abdominal metastases.



# I123 MIBG Scan



- MIBG : **M**eta **I**odo **B**enzyl **G**uanidine
- Is a nor adrenaline analog
- Localizes in adrenergic tissues: catecholamines producing tumors and their metastases.
- Patient preparation: stop drugs interfering with MIBG uptake. Lugols solution to protect thyroid gland



# I123 MIBG Scan

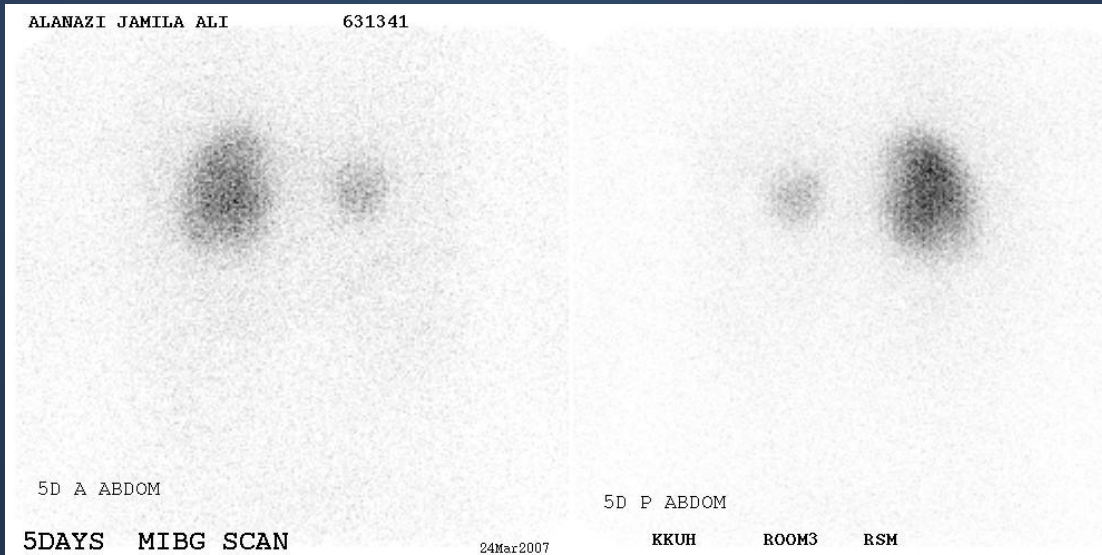
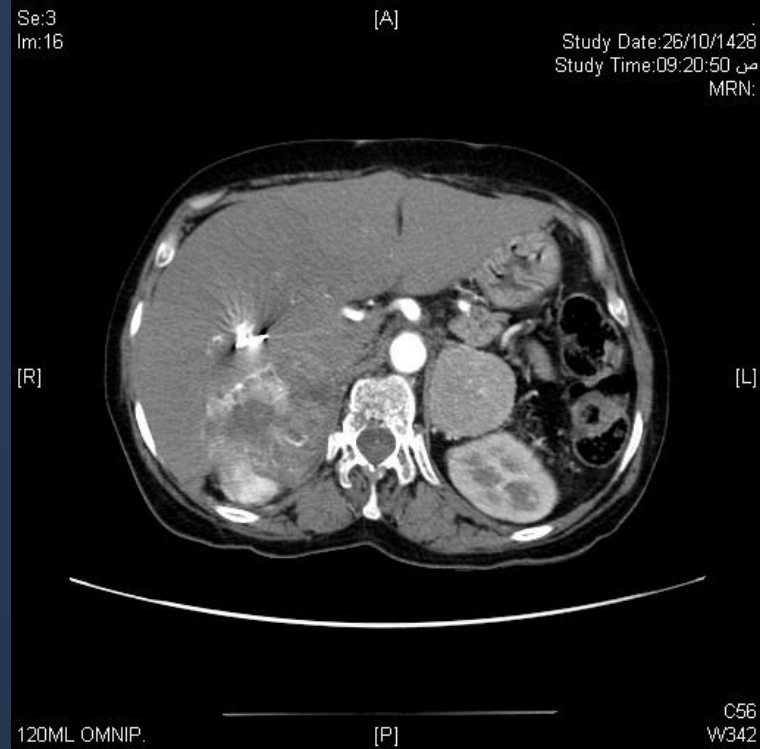
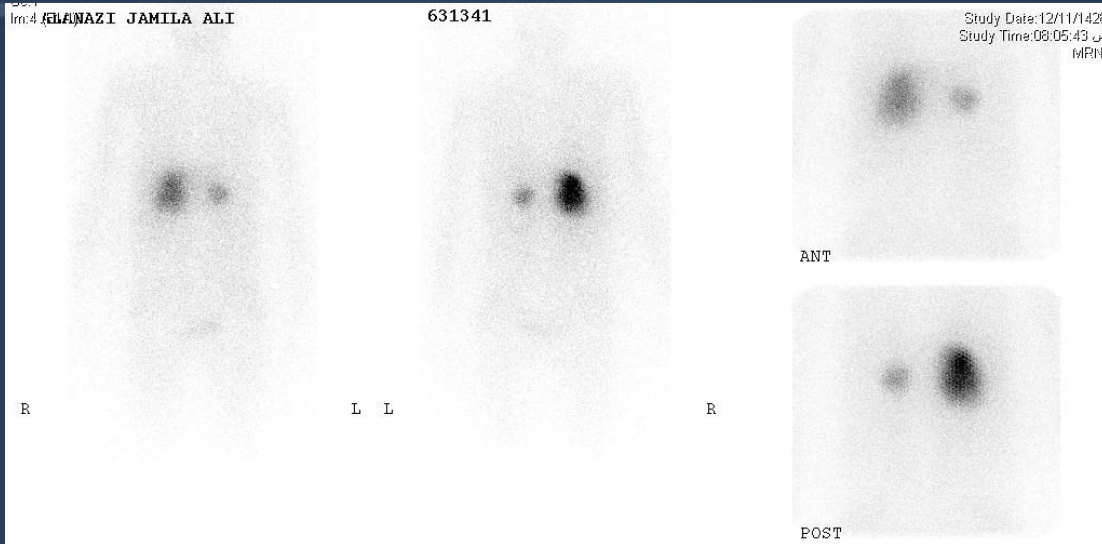
## Indications



- Pheochromocytoma
- Paraganglioma
- Insulinoma
- Neuroblastoma
- Medullary thyroid carcinoma
- Carcinoid tumors

# MIBG In Pheochromocytoma

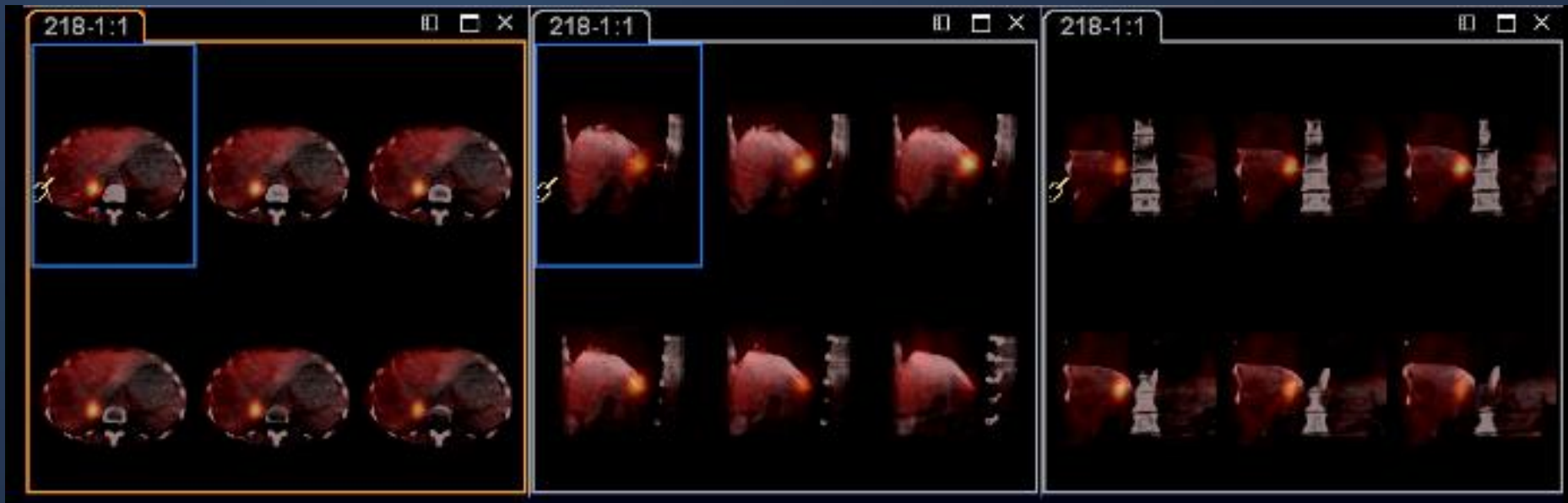
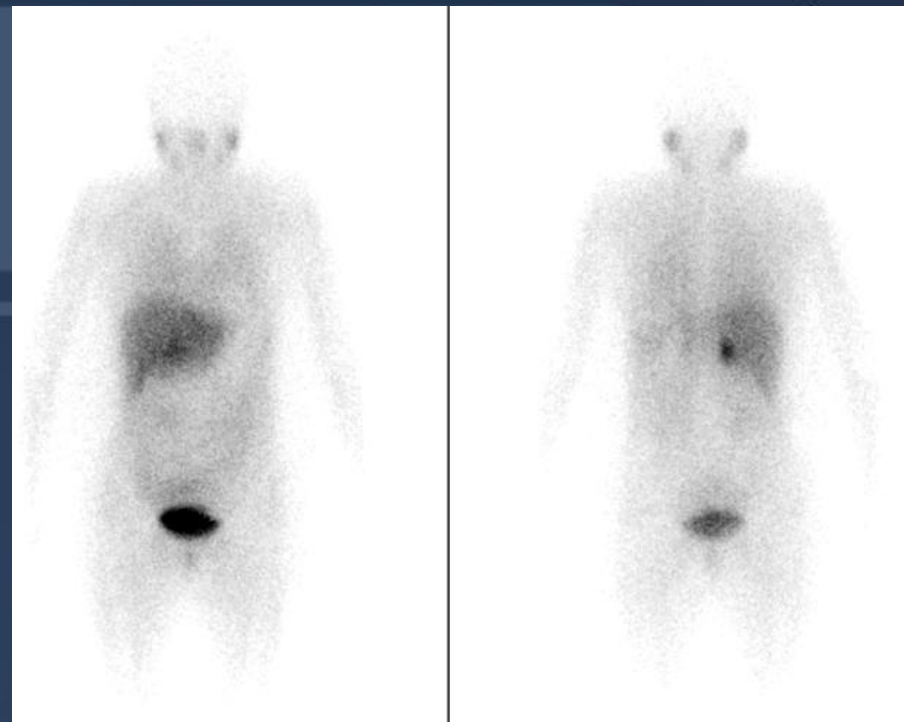
## Bilateral Disease



# Pheochromocytoma

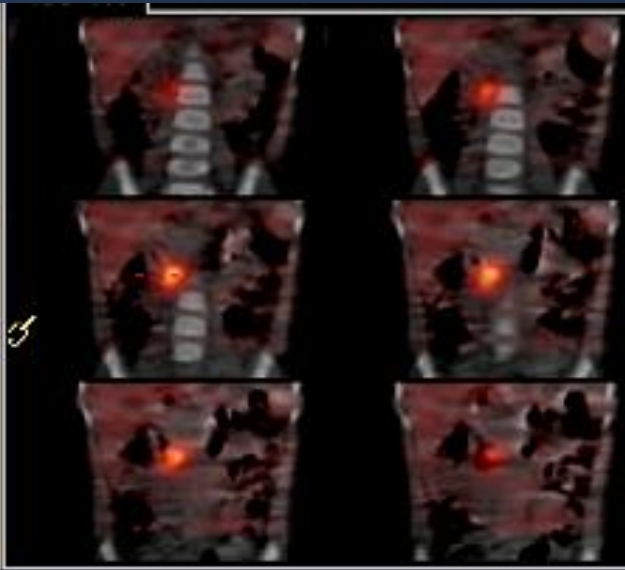
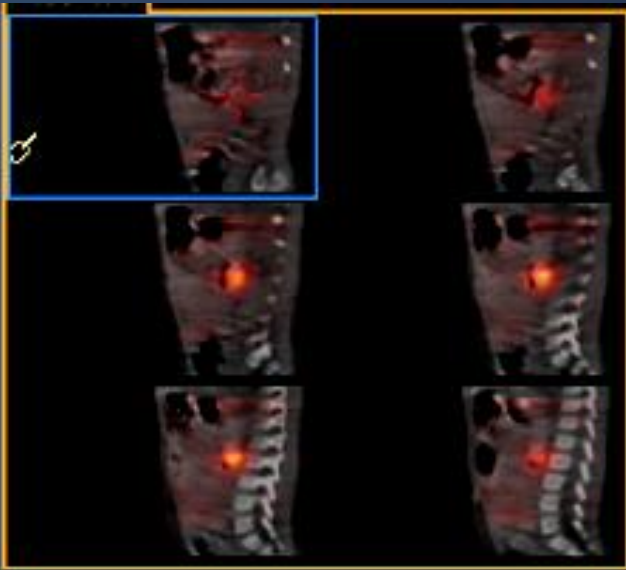
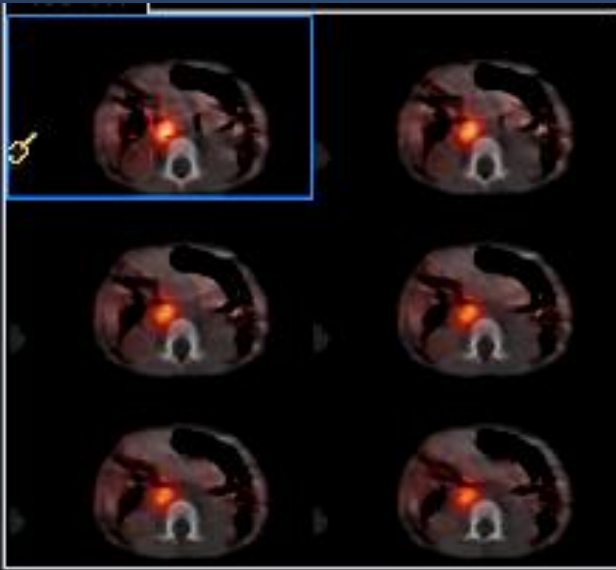
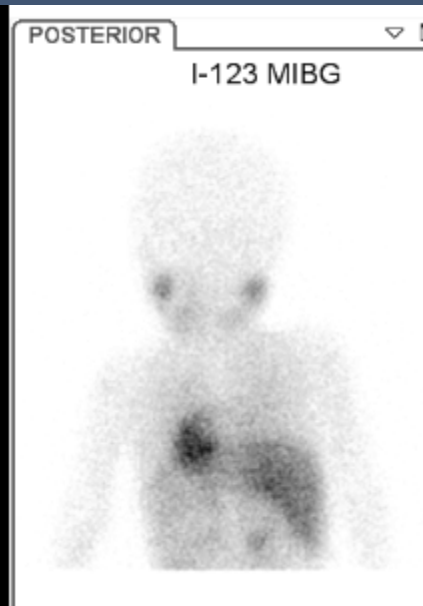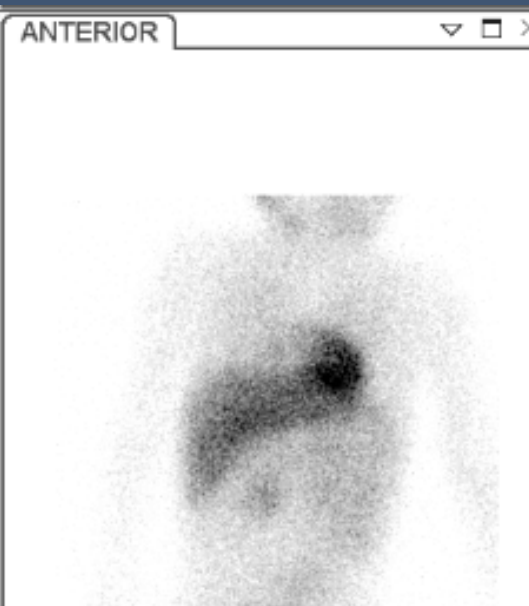
## Planar Vs SPECT CT

A 41 years old female patient is with 2ndary hypertension. Right adrenal mass.  
?Pheochromocytoma.



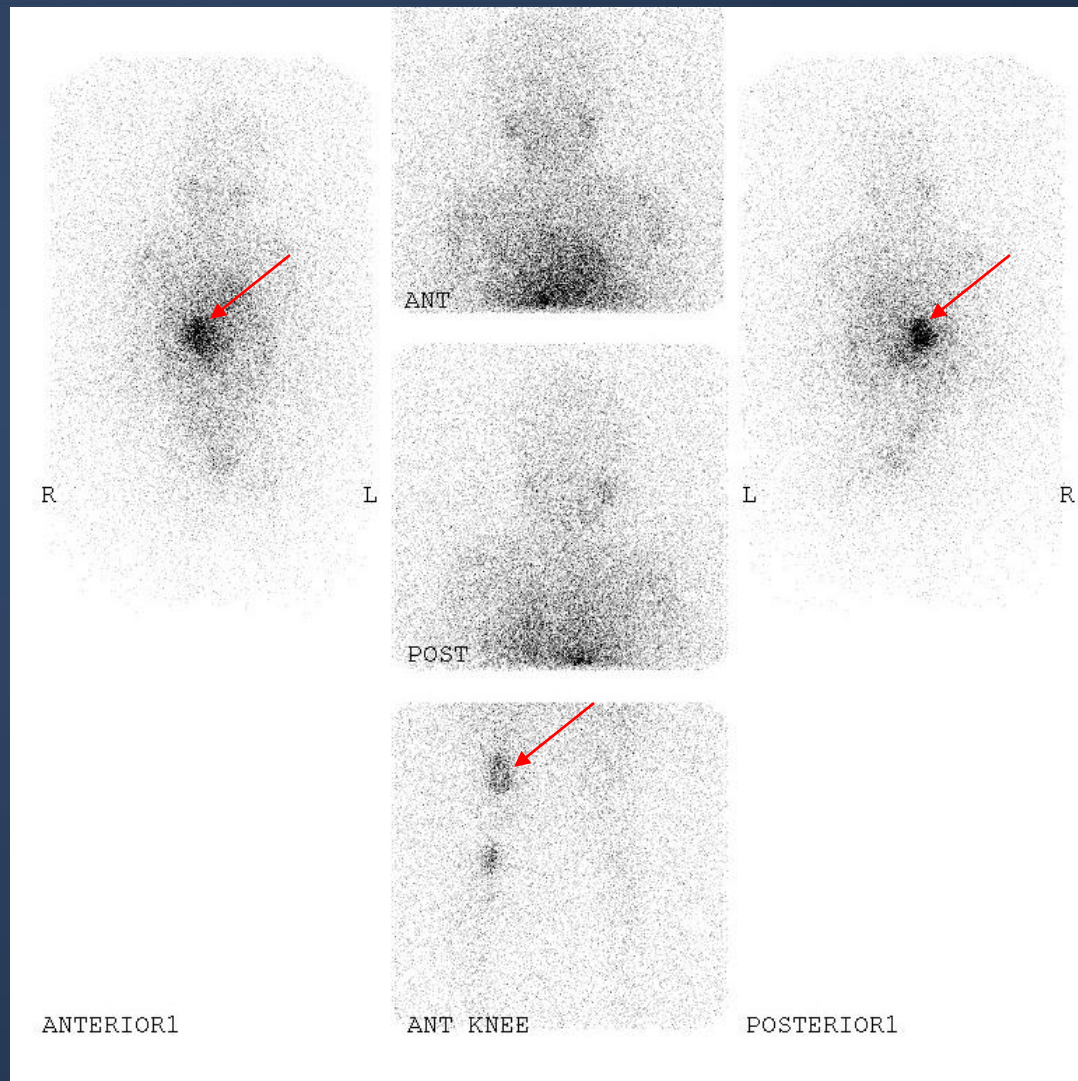
# Neuroblastoma

## Planar Vs SPECT CT



# I131 MIBG Total body scan

## 1ry neuroblastoma /bone mets



# THYROID METASTASES STUDY (I-123 or I-131 as Sodium Iodide)



## Indications

- Detection and localization of persistent or recurrent local or distant functioning thyroid cancer

## Patient Preparation

- **Stimulation of potentially functioning thyroid tissue:**
  - A. Inject recombinant human thyrotropin on 2 consecutive days and administer the iodine on the third day .**
  - B. Withdraw thyroid replacement hormones :**
    1. Thyroxine (T-4) for at least 4 weeks.
    2. Triiodothyronine (T-3) for at least 10 days.
- **The patient must not have had i.v iodinated contrast material (IVP, CT with contrast, myelogram, angiogram) for at least 3 weeks .**
- The patient should be NPO for at least 4 hours prior to radiopharmaceutical administration and for at least 1 hour afterwards .

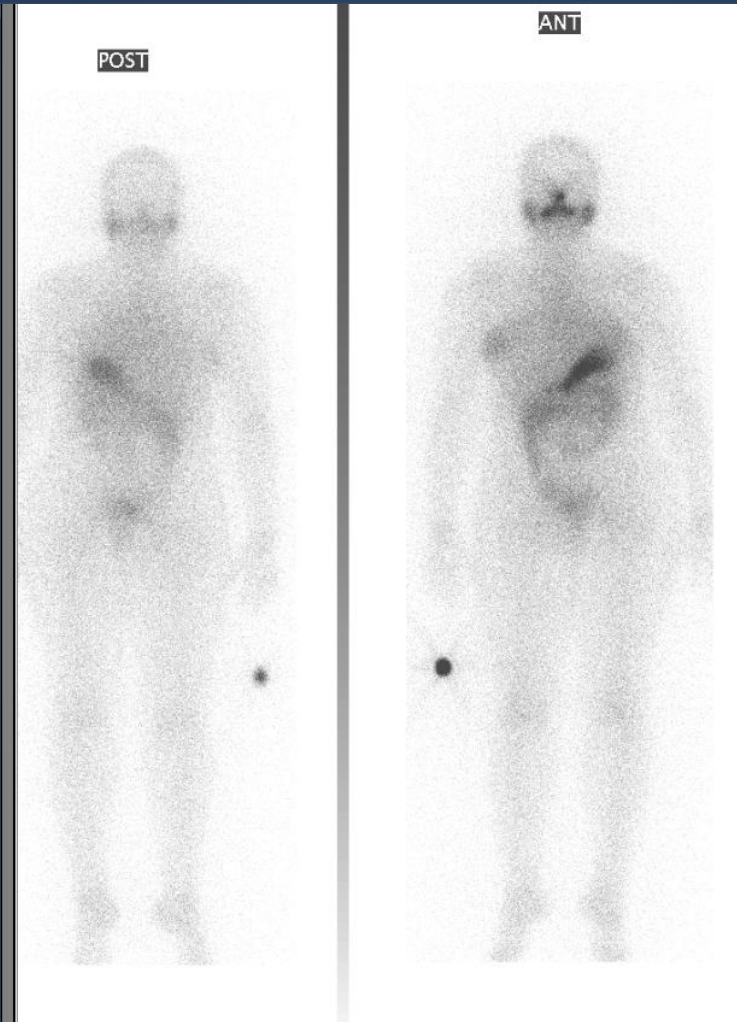
## Tracer , Dose, & Technique of Administration

- Radiopharmaceutical: Oral administration
  - a. I-123 as sodium iodide : 2 mCi
  - b. I-131 as sodium iodide : 2-10 mCi

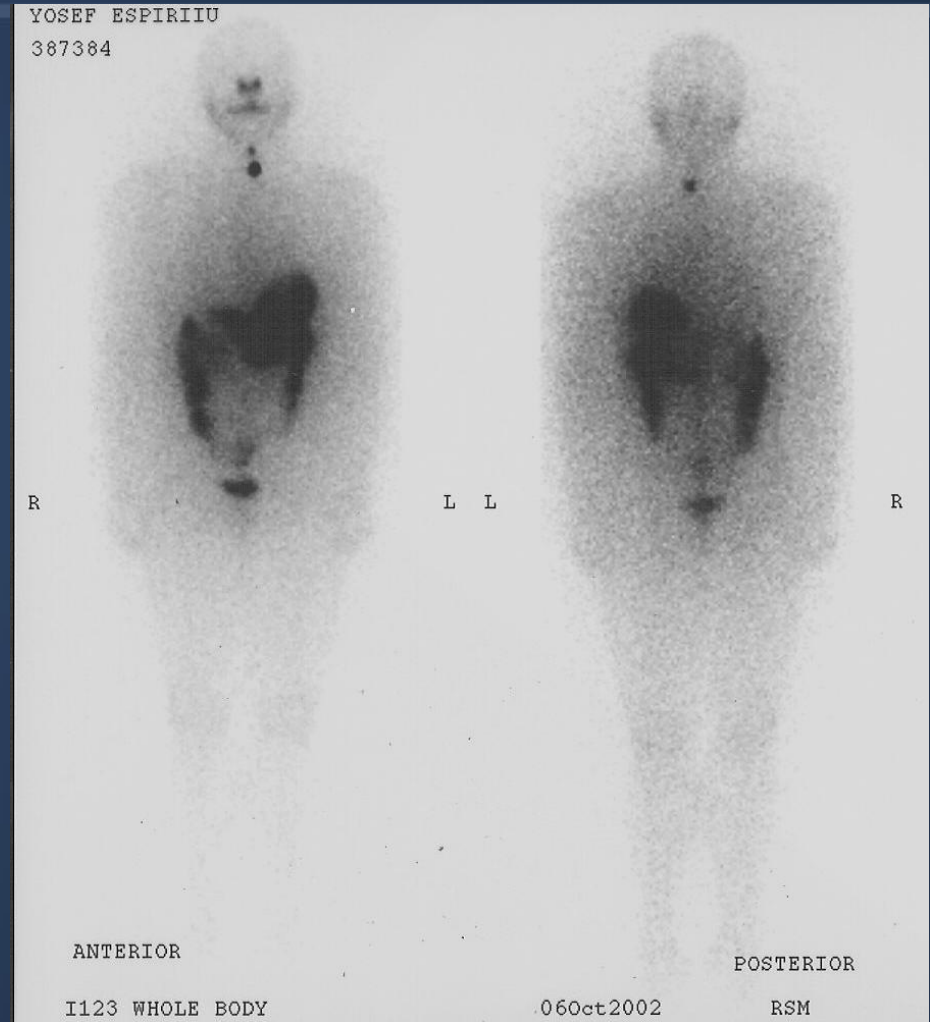**Imaging using Gamma camera :** Whole body scan

# Thyroid Cancer

## I-123 WB Scan



Negative I-123 WB Scan

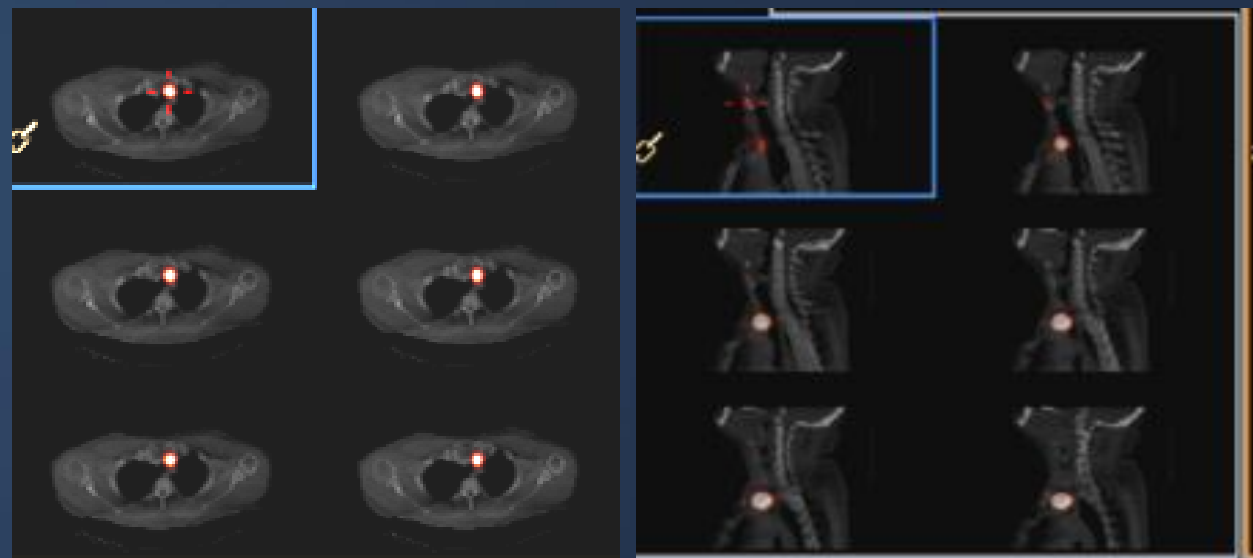
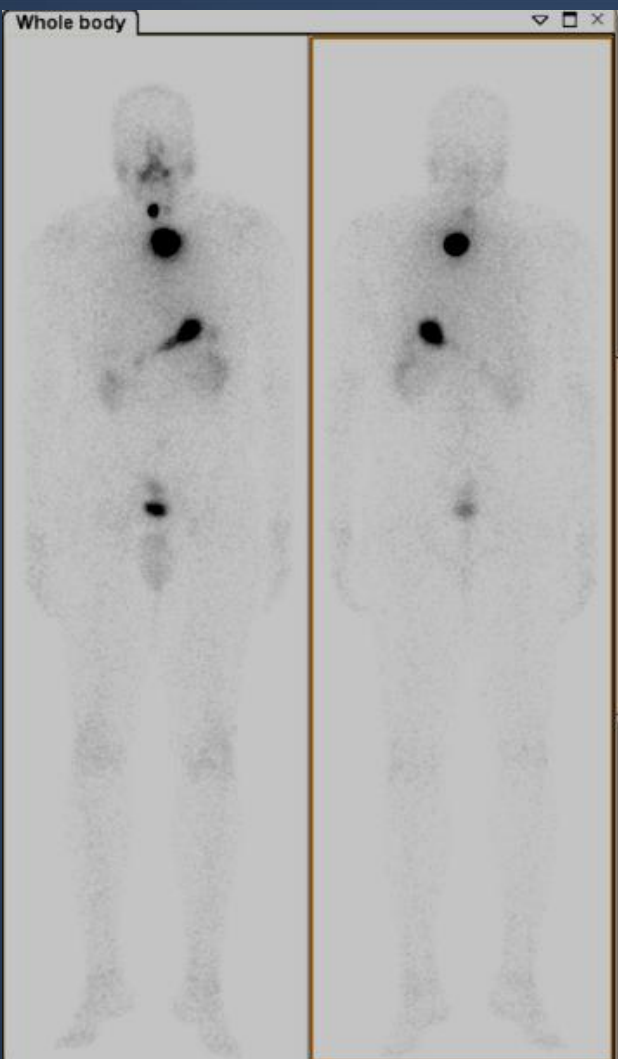


I-123 WB Scan : Post operative Thyroid remnants

# I-123 WB Scan

## Post operative Thyroid remnants

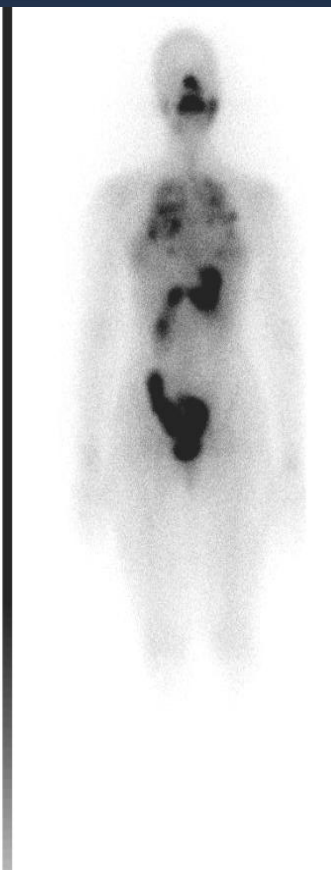
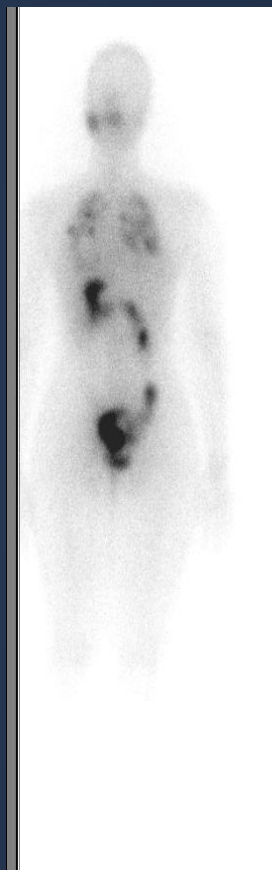
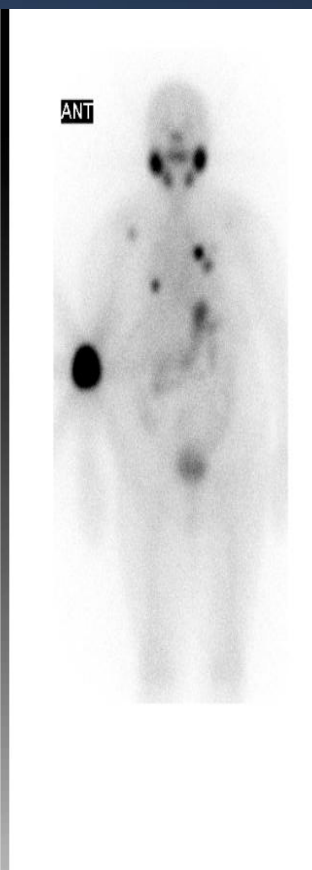
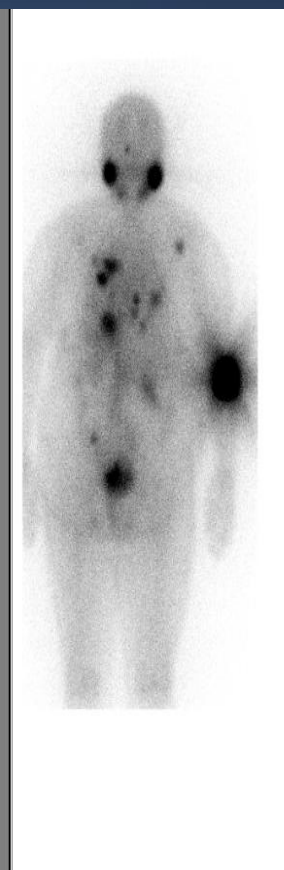
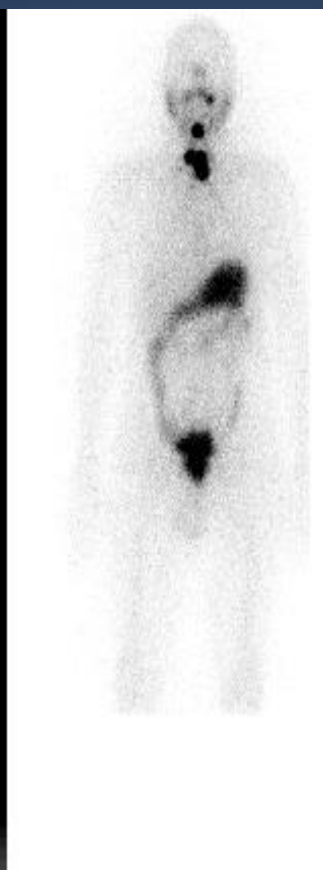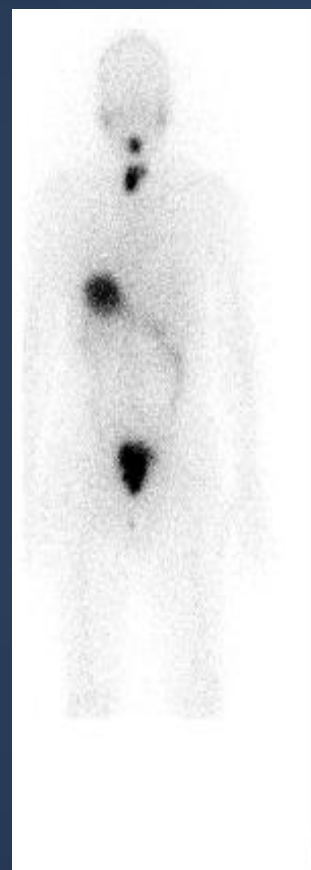### Planar Vs SPECT CT





# THYROID METASTASES STUDY

(I-123 or I-131 as Sodium Iodide)



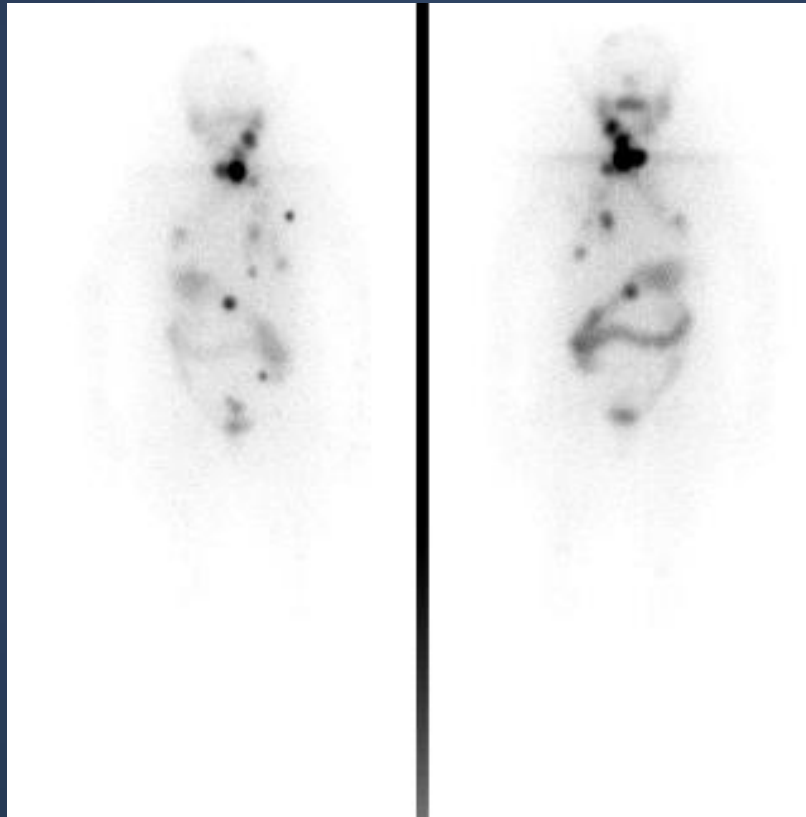
Local Recurrence

Bone Metastases

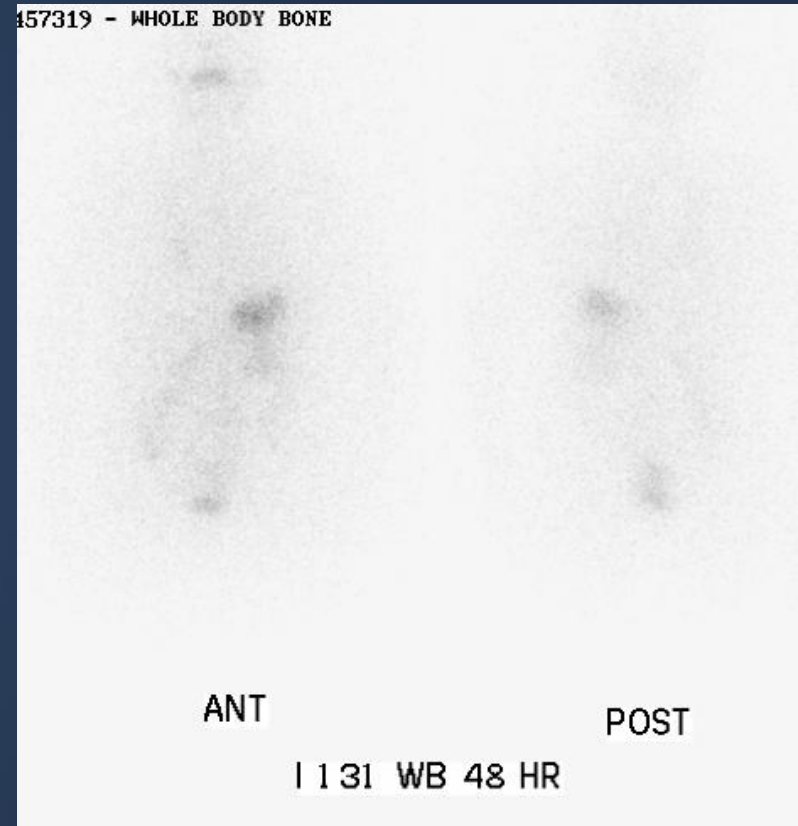Lung Metastases

# Thyroid Cancer

## I-131 Pre & Post therapy



Dec04

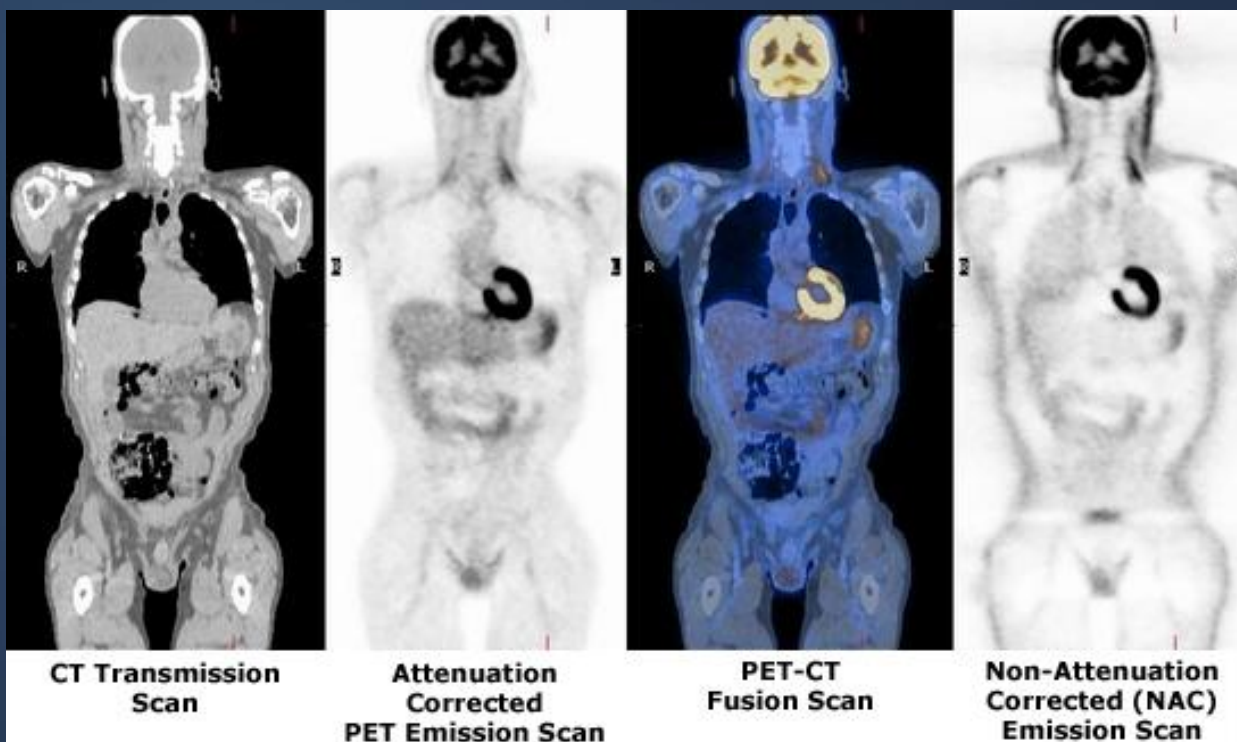


March06

# Onco PET ( PET and PET CT)

## What is PET - CT .....

- PET : Positron Emission Tomography.
- CT : Computerized Tomography.
- PET-CT is the fusion of functional and anatomic information acquired almost simultaneously from which we are able to visualize form and function.



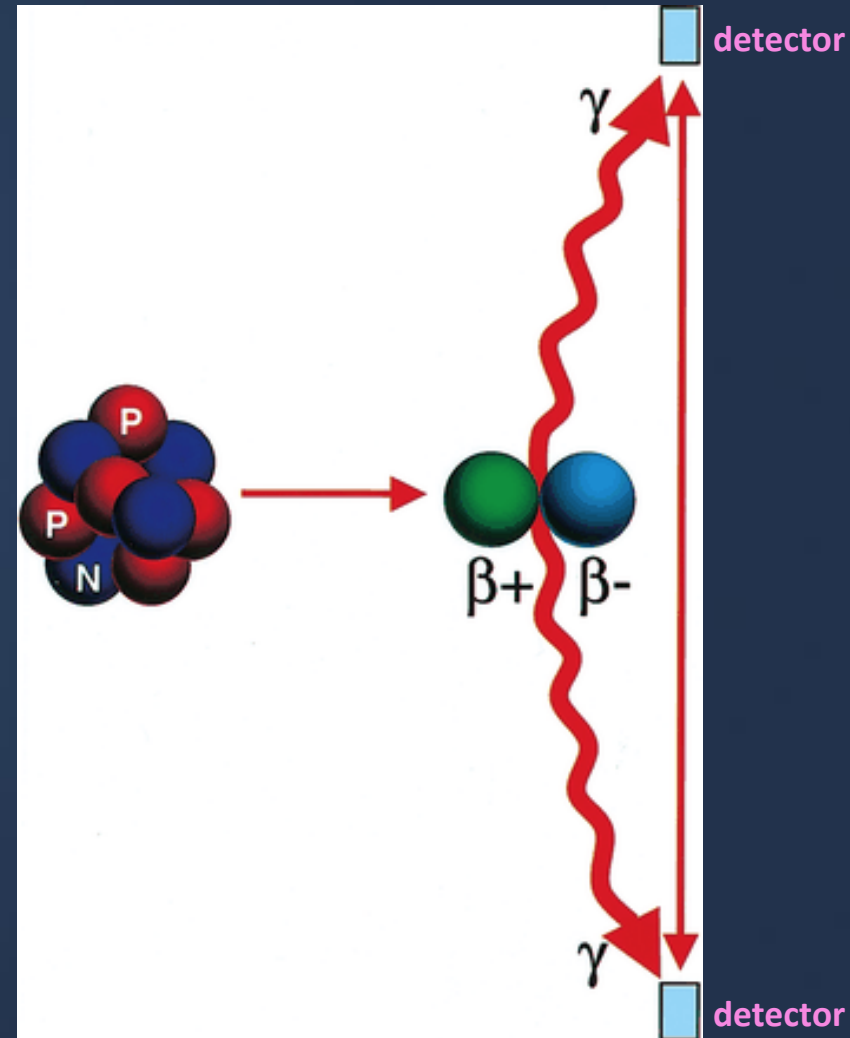
**PET CT = PET + CT = Function + Form**

# PET : How it is performed...?

**Positron emitters (e.g. F18)** labelled with biologically active natural compounds such as oxygen, carbon or glucose give intravenously and reacting in the body identically to their non-radioactive counterparts.

**Positrons** are emitted from F18 and react with tissue electrons.....Anihilation occurs...

**Two photons 511 kev** each in opposite direction are emitted and detected by PET SCANNER giving an image of the normal and abnormal distribution of tracer in the body.



# Positron Emitting Isotopes



Cyclotron produced isotopes:

Isotope

T/2

Oxygen-15

2 min

Nitrogen-13

10 min

Carbon-11

20 min

**Fluorine-18**

**110 min**

# FDG in Oncology



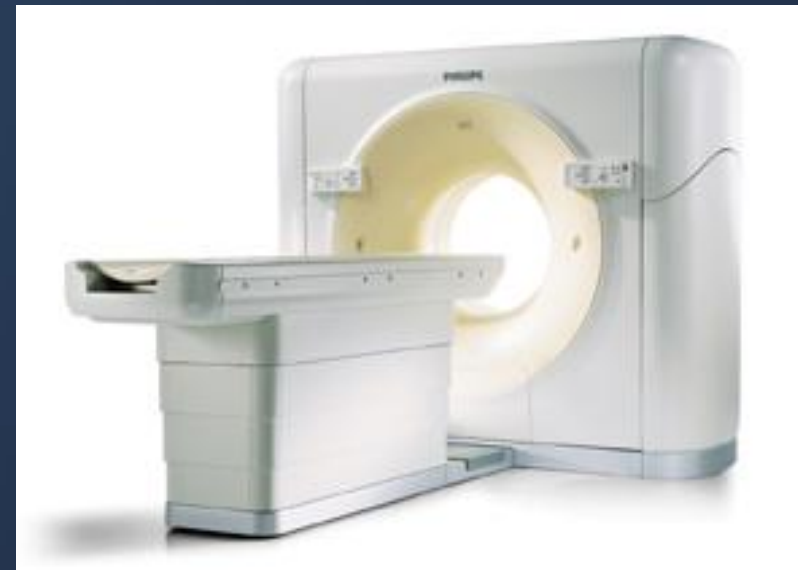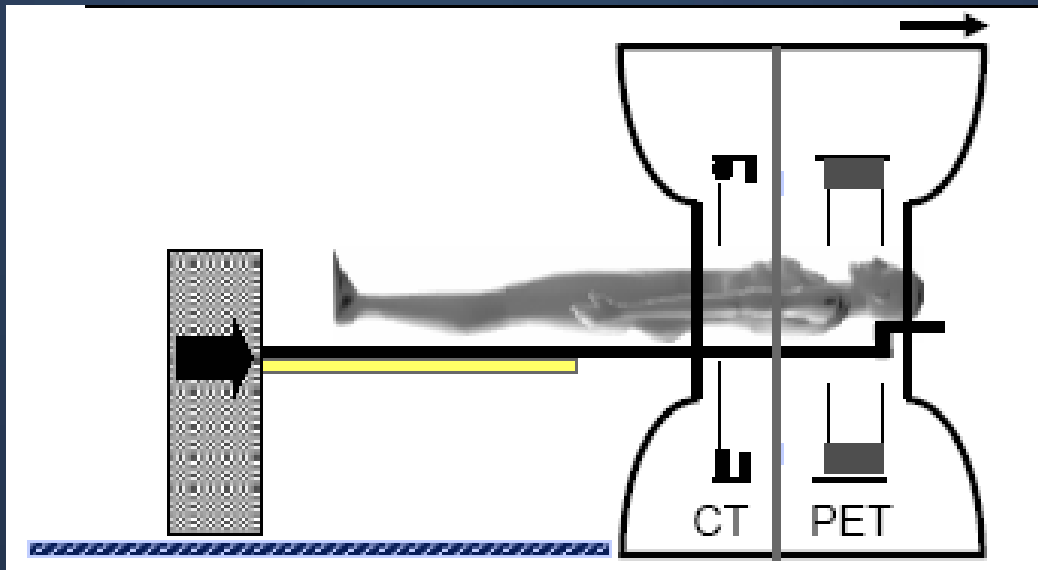
- Tumors do not have a blood tumor barrier
- FDG transport into tumors occurs at a *higher* rate than in the surrounding normal tissues.
- FDG is de-phosphorylated and can then leave the cell.
- The de-phosphorylation occurs at a *slower* rate in tumors.
- **Applications of FDG**
  - Locating unknown primaries
  - Differentiation of tumor from normal tissue
  - Pre-operative staging of disease (lung, breast, colorectal, melanoma, H&N, pancreas)
  - Recurrence vs necrosis
  - Recurrence vs post-operative changes (limitations with FDG)
  - Monitoring response to therapy

# PET CT

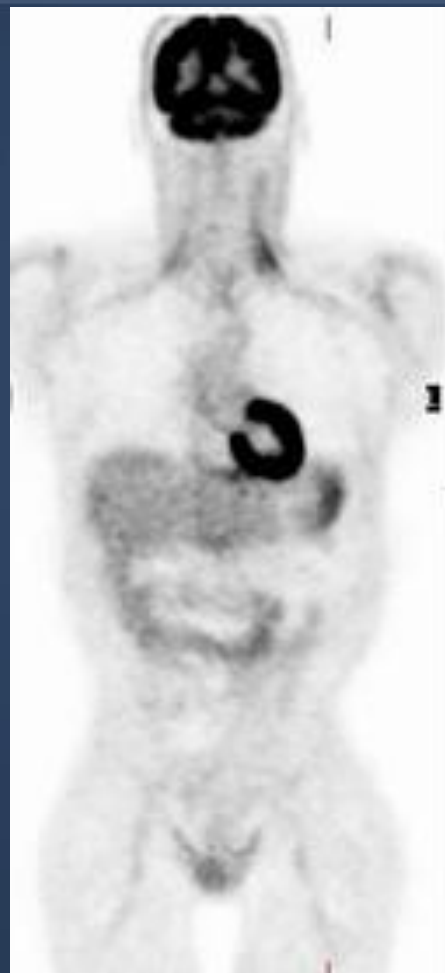## F18 FDG IMAGING PROTOCOL



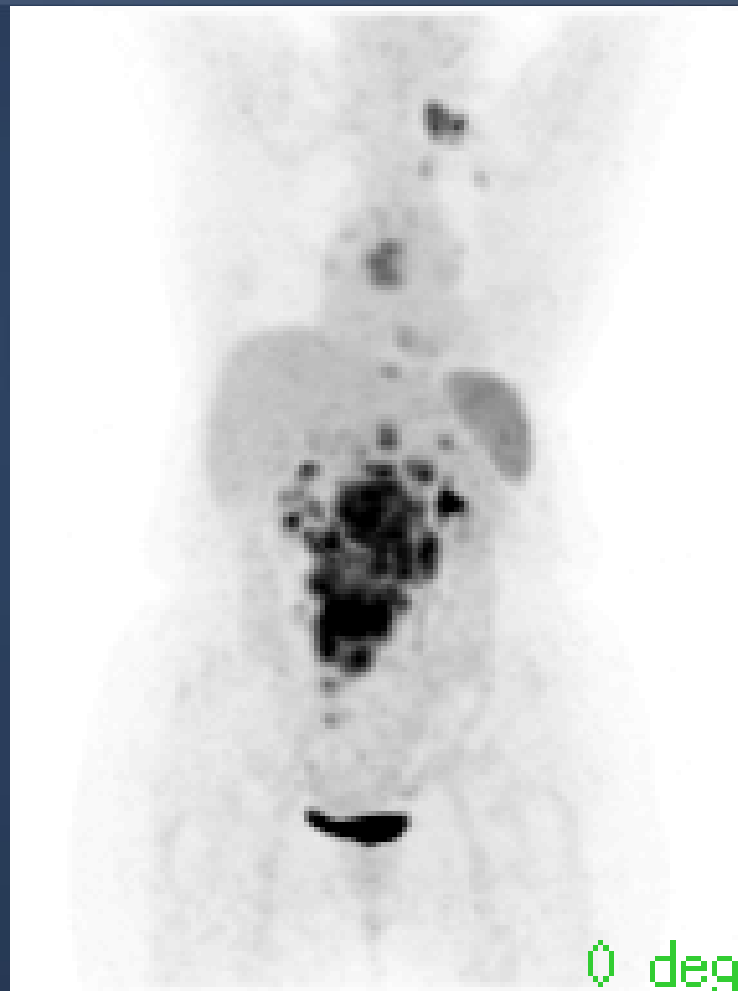- ❖ **Fasting** : 4 – 6 hours
- ❖ **Dose** : Inject 10 mCi **F18 FDG**
- ❖ **Wait (uptake phase)**: 45 -60 min then scan
- ❖ **Scanning time** : 30 min to complete PET CT study
- ❖ **SUV** : Standard uptake value ( N:0.5-2.5 and Tumors > 3.0 )



# FDG PET



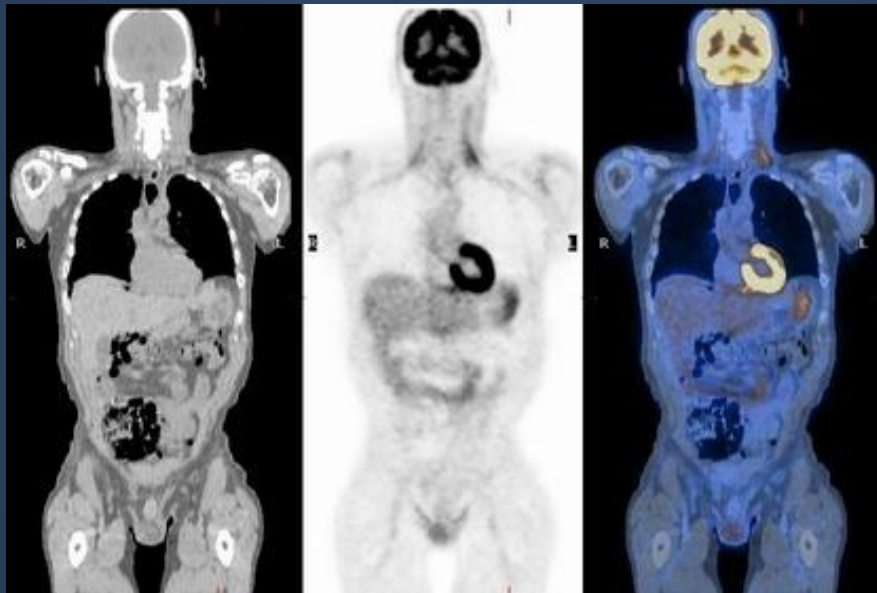
**FDG PET : Normal**



**FDG PET : Staging of NHL**

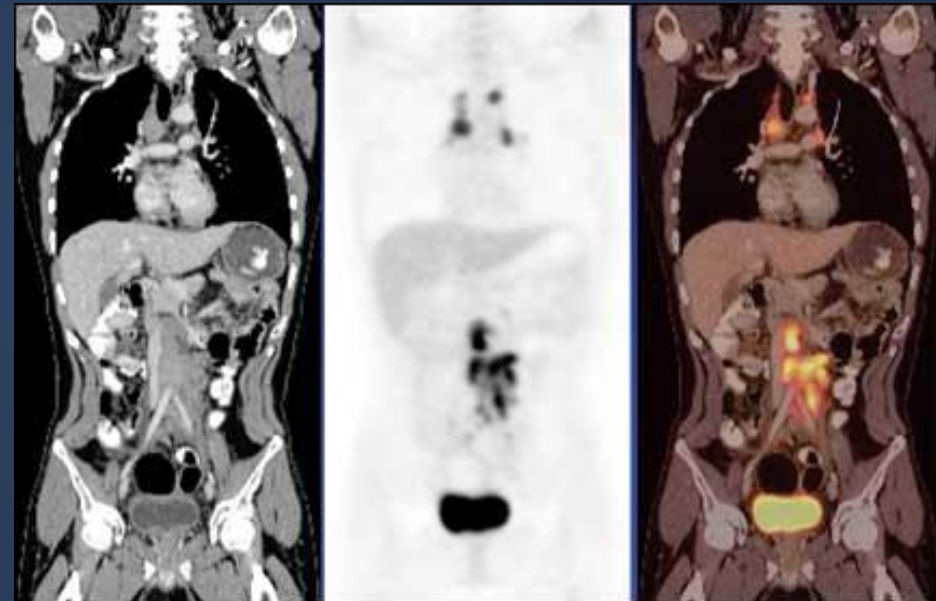


# FDG PET-CT



**FDG PET-CT**

Normal

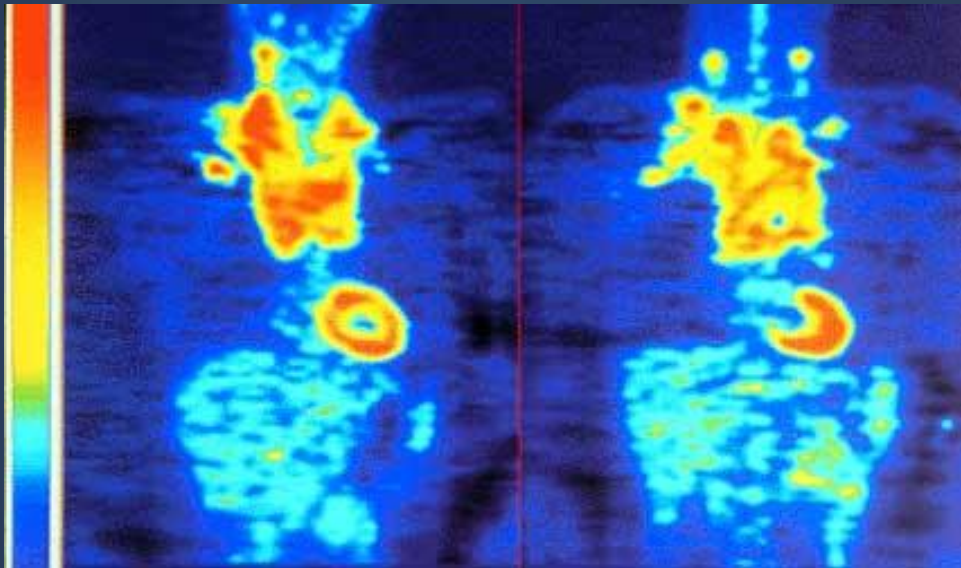


**FDG PET-CT**

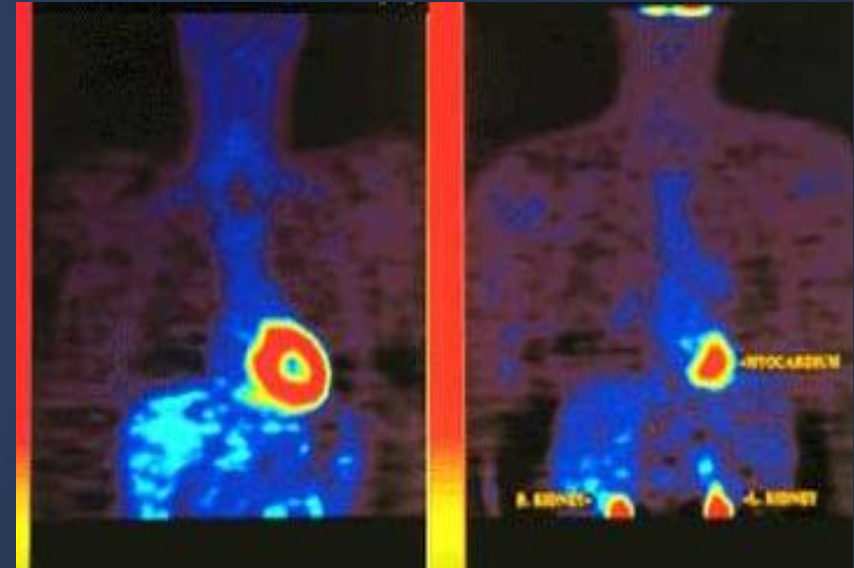
Staging Of Lymphoma

# Assessment of therapy response

## FDG PET in HD



**Baseline**

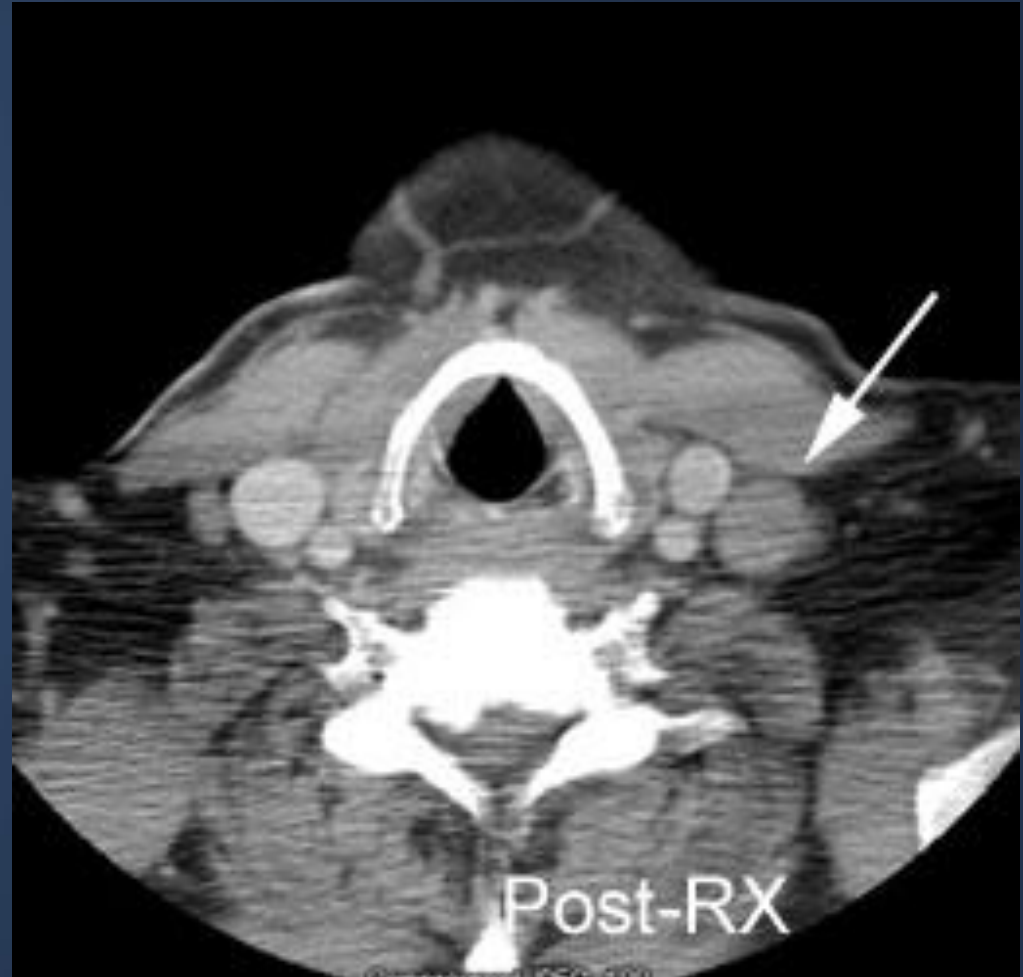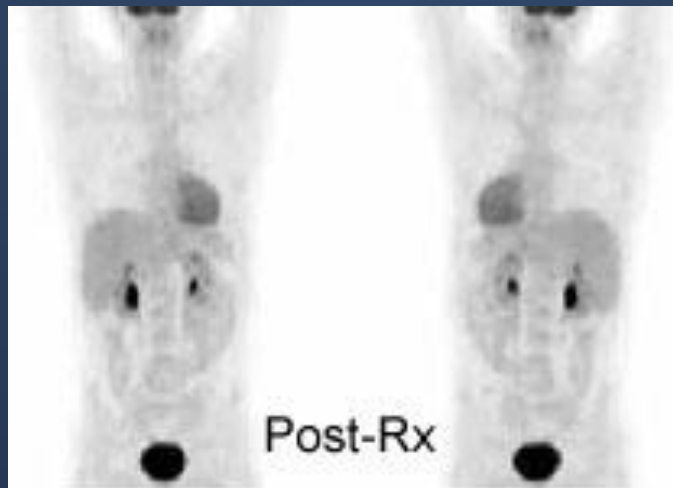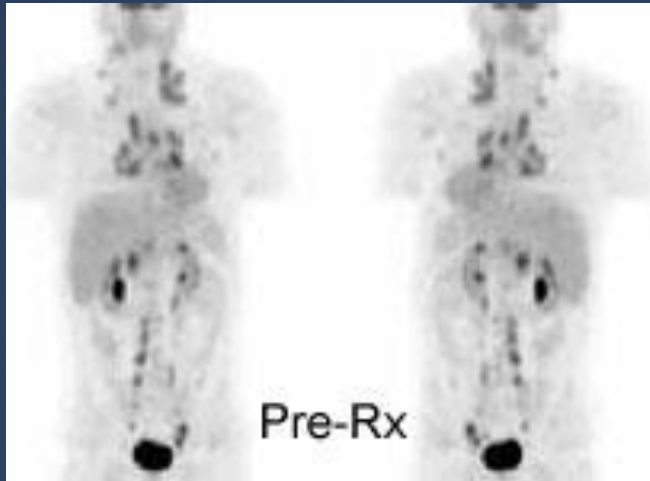


**Post therapy**

A 22 years old male patient with Hodgkin's lymphoma. Six months after chemotherapy, CT scan showed bilateral hilar abnormalities. FDG-PET scan did not show any activity in described CT changes.

# FDG in Non-Hodgkin's lymphoma

## Response to therapy



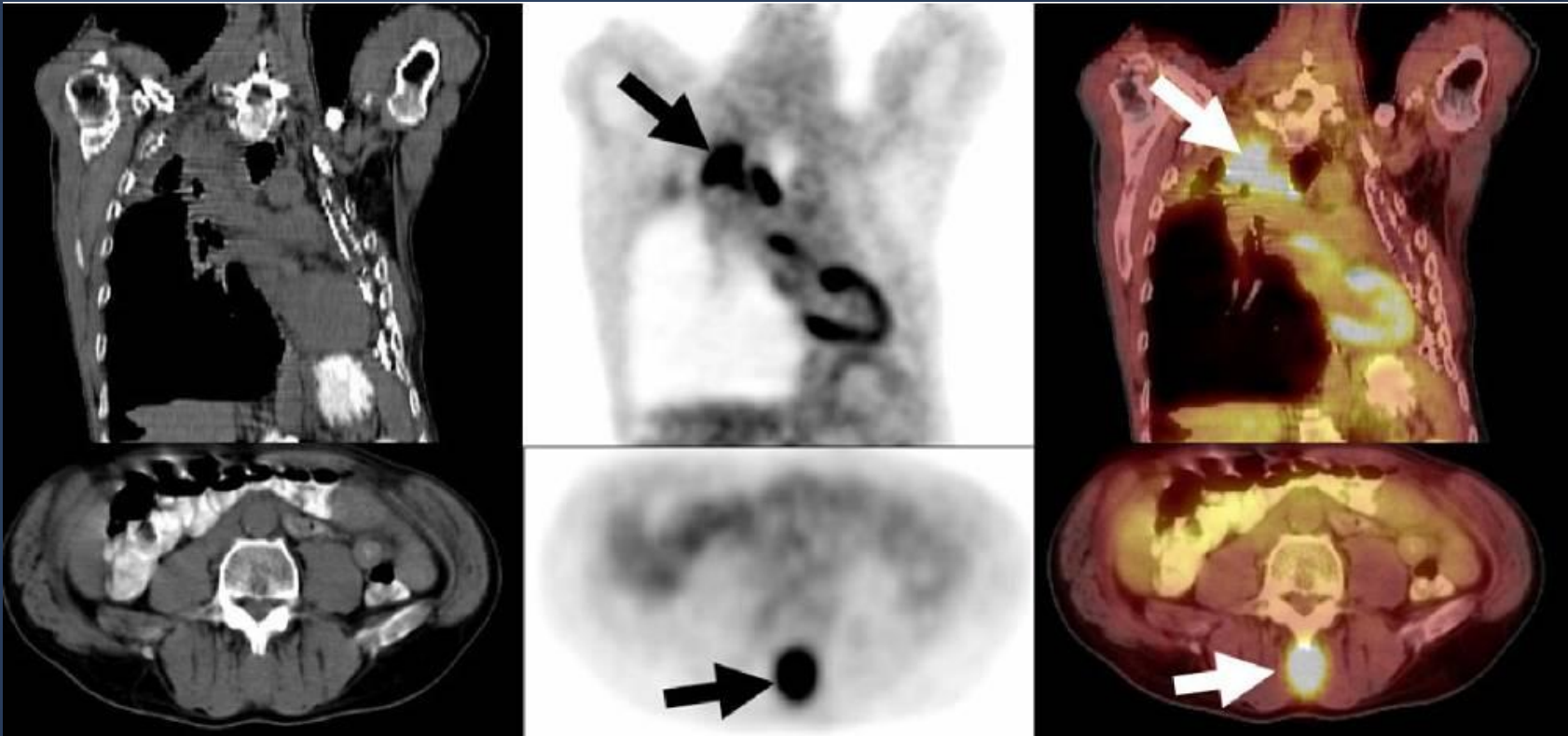
# PET CT In Lymphoma



	<b>Sensitivity</b>	<b>Specificity</b>
	<b>(%)</b>	<b>(%)</b>
<b>CT</b>	<b>61</b>	<b>89</b>
<b>FDG-PET</b>	<b>78</b>	<b>98</b>
<b>FDG-PET and CT</b>	<b>91</b>	<b>99</b>
<b>FDG-PET/CT</b>	<b>96</b>	<b>99</b>

# PET CT Lung Cancer

## Staging



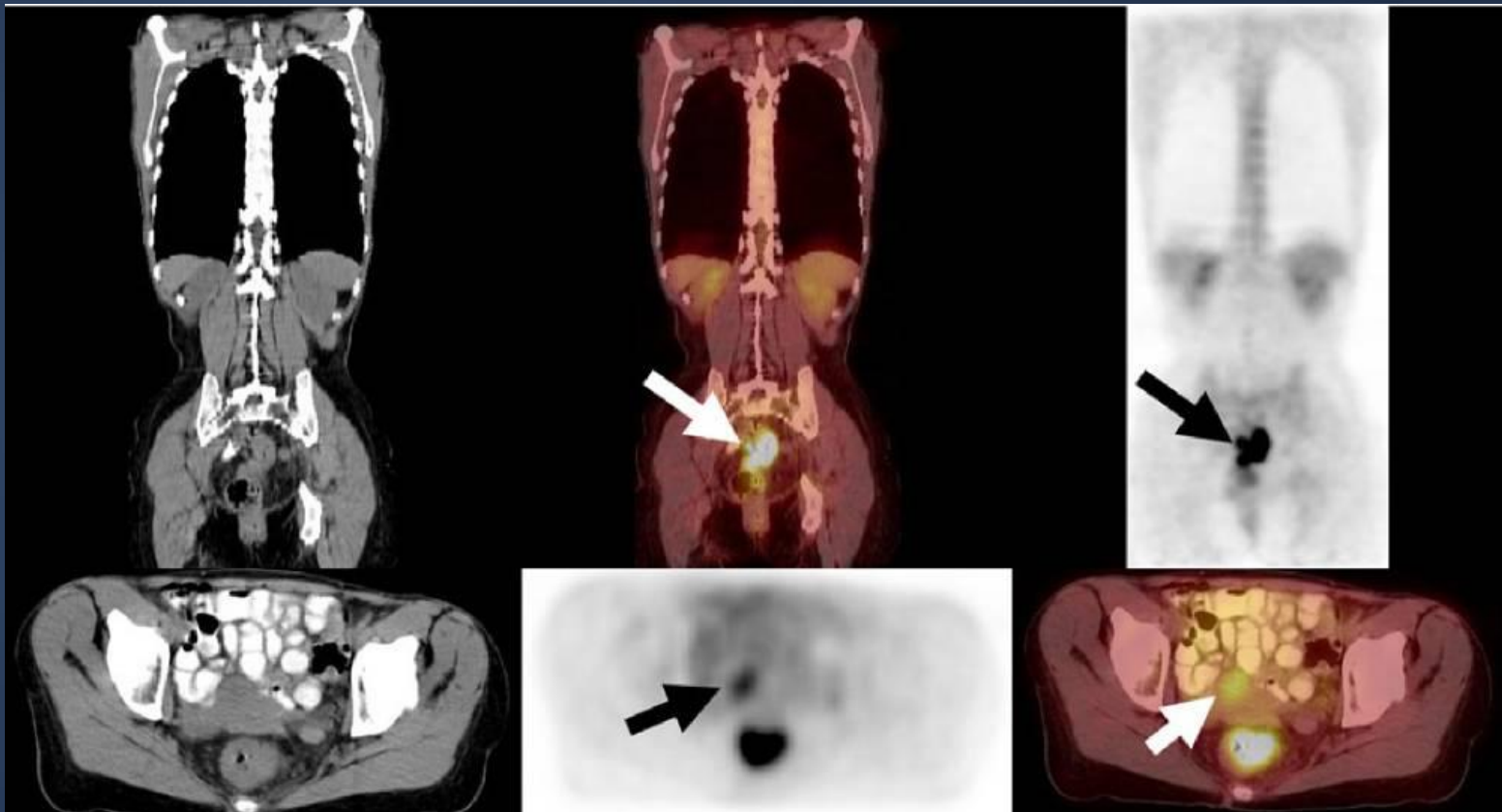
FDG avid soft tissue mass associated with a destructive L5 spinous process consistent with metastatic deposit (arrow).

### FDG PET CT in Solitary Pulmonary Nodule (SPN)

Sensitivity : 82 – 100 %

Specificity : 67 – 100 %

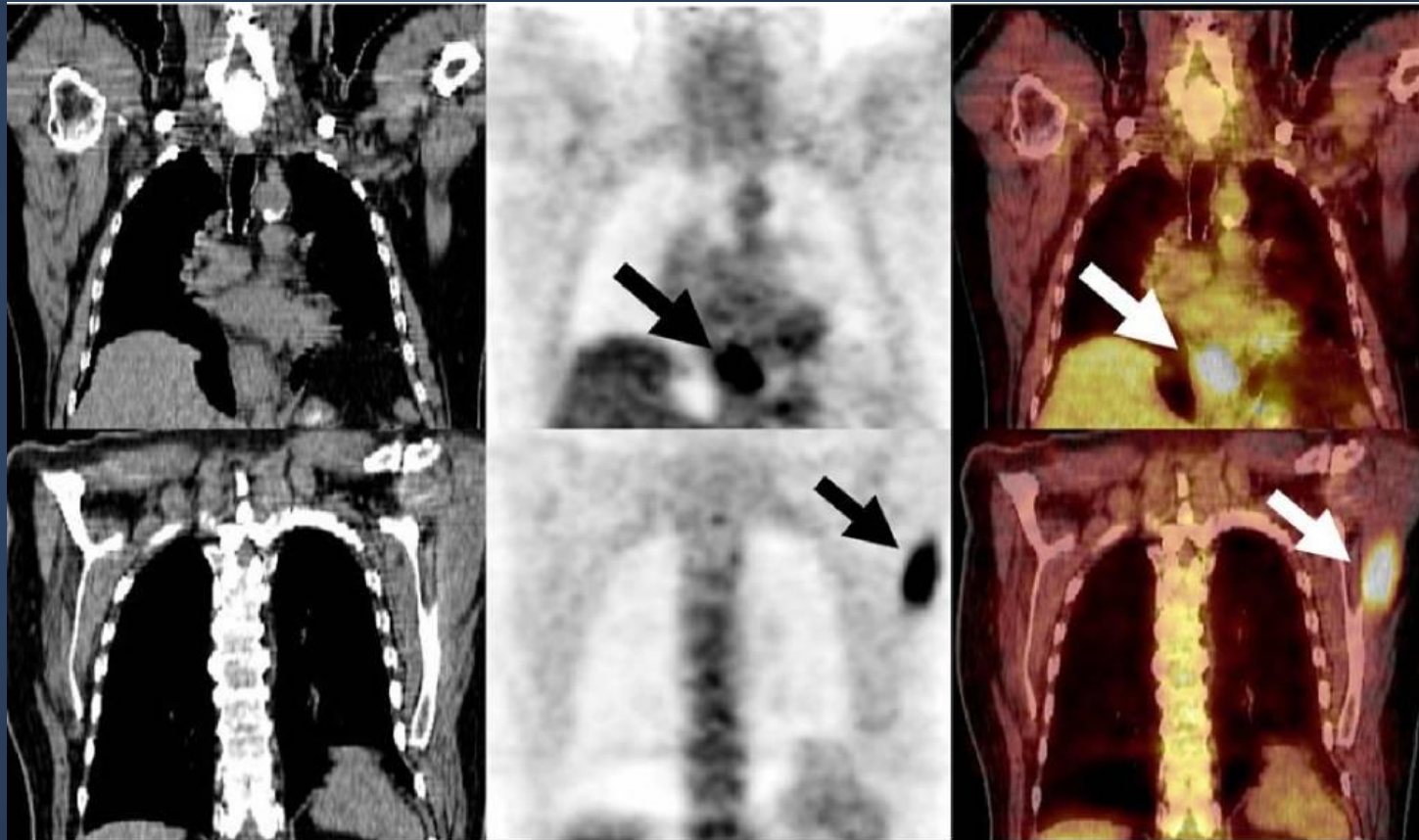
# CA Rectum Staging



A 57-year-old woman presented with pain and constipation and colonoscopy revealed an obstructing rectal mass. A staging FDG-PET/CT demonstrated intense FDG avidity in a circumscribed mass-like thickening of the proximal rectum (arrows in top row images) and a focus of mild metabolic activity anterior to the rectum (bottom row arrow) which was not avid as the rectal malignancy. This was located within the uterus as seen on CT images (bottom row), and was subsequently shown to be a uterine fibroid on other imaging studies.

# CA Esophagus

## Staging



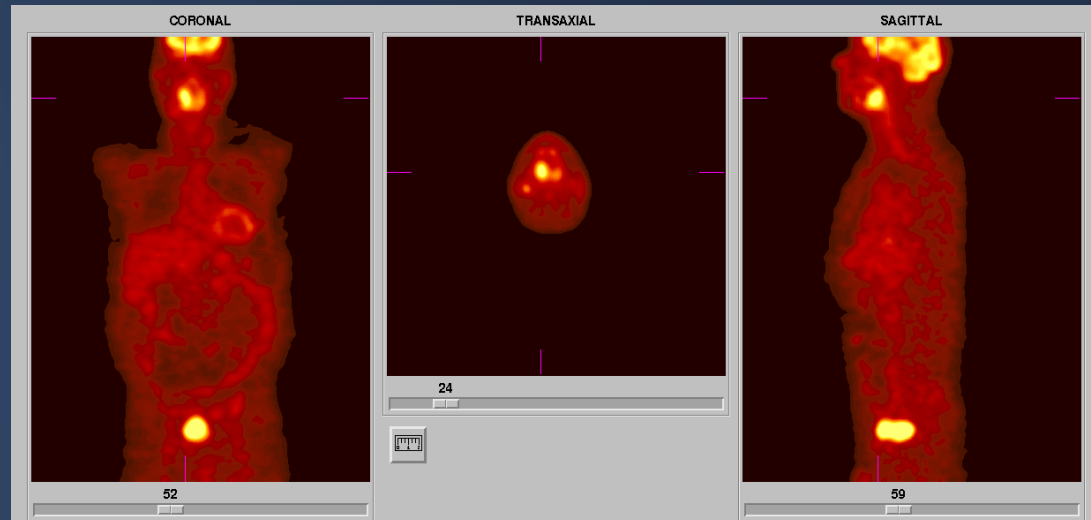
Based on FDG-PET/CT results the clinical management of this patient was changed from surgical resection of the primary tumor to combined chemo-radiation therapy.

# FDG PET

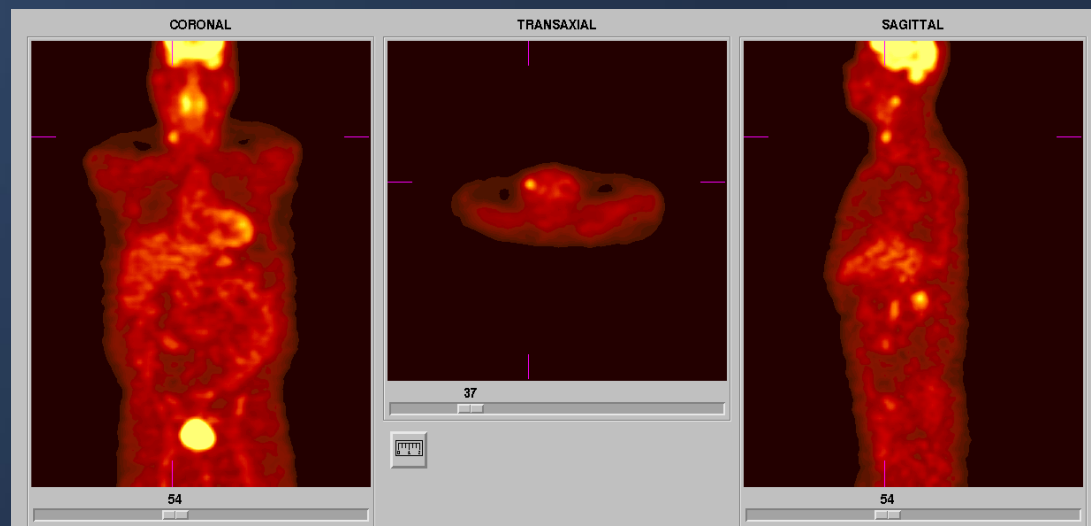
## Tumor of unknown origin



Pharyngeal cancer



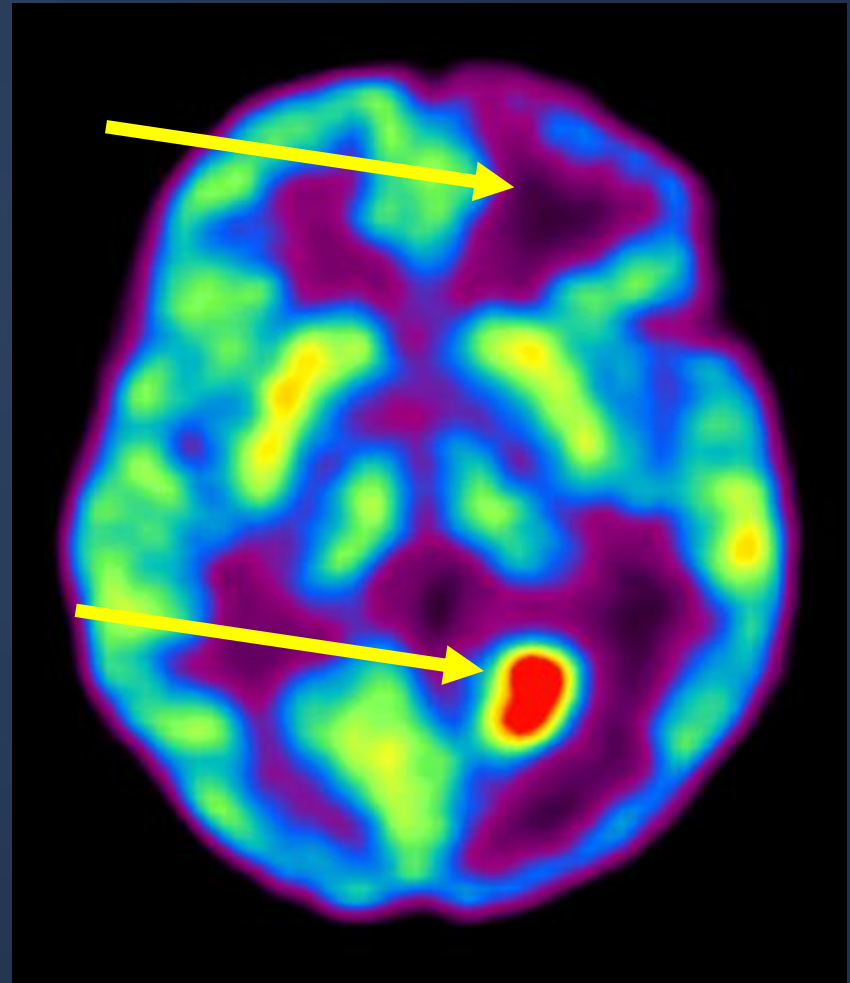
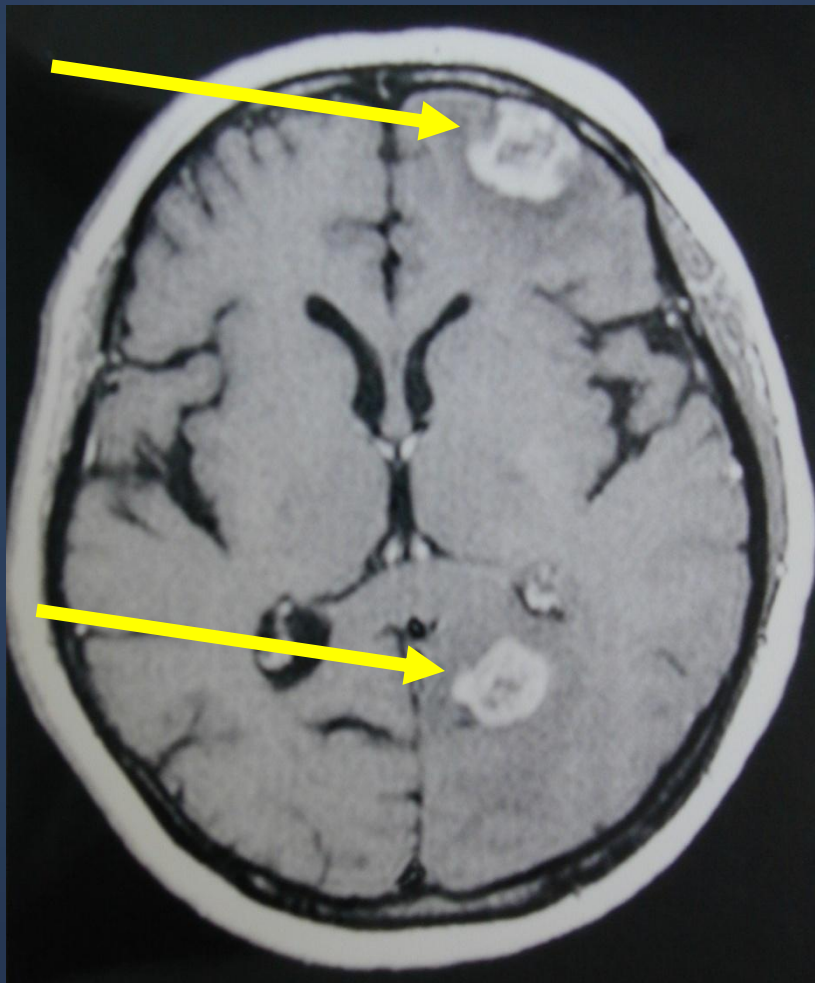
Metastatic involvement  
of neck lymph nodes





# FDG PET – brain tumor post therapy

Two foci on CT, only one viable tumor



# Indications of PET CT



<b>Breast Cancer*</b>	Staging*, restaging*, and monitoring response to therapy*
<b>Colorectal Cancer</b>	Diagnosis*, staging* and restaging*
<b>Esophageal Cancer</b>	Diagnosis*, staging* and restaging*
<b>Head &amp; Neck Cancers</b> (excluding CNS and thyroid)	Diagnosis*, staging* and restaging*
<b>Lung Cancer</b> (Non-Small Cell)	Diagnosis*, staging* and restaging*
<b>Lymphoma</b>	Diagnosis*, staging* and restaging*
<b>Melanoma</b> (Excludes evaluation of regional nodes)	Diagnosis*, staging* and restaging*
<b>Solitary Pulmonary Nodule</b>	Characterization of indeterminate single pulmonary nodule
<b>Thyroid Cancer*</b>	Restaging
<b>Cervical Cancer*</b>	Staging as an adjunct to conventional imaging

# Radionuclide Therapy

## Properties of the Ideal Therapeutic Radiopharmaceutical



1. Pure **beta minus emitter**
2. Medium/high **energy** (>1 meV).
3. **Effective half-life** = moderately long, e.g., days.
4. High **target:nontarget ratio**
5. Minimal **radiation dose** to patient and Nuclear Medicine personnel
6. Patient Safety
7. **Inexpensive, readily available** radiopharmaceutical.
8. Simple **preparation and quality control** if manufactured in house.

# Radionuclide Therapy



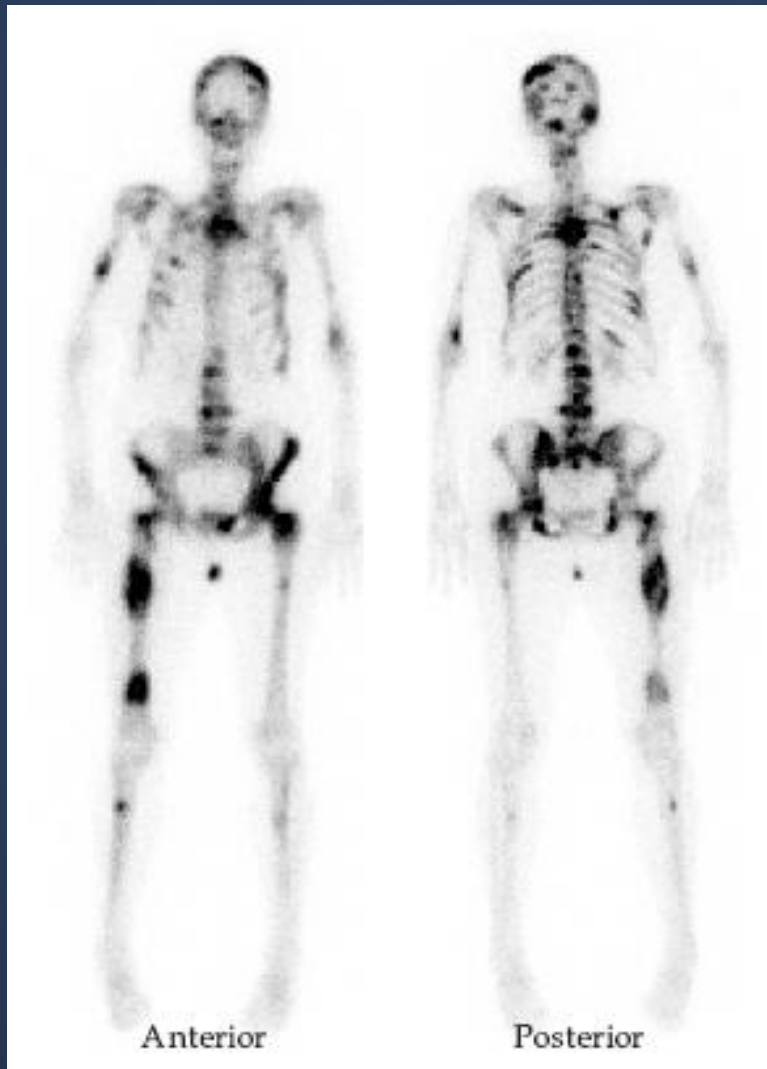
## Agent

## Indication

## Dose

- | <u>Agent</u>                                      | <u>Indication</u>  | <u>Dose</u>                   |
|---|--|-------------------------------|
| • <b>I131</b>                                     | • Thyroid cancer   | 100-200 mCi                   |
| • <b>131 MIBG</b>                                 | • Neuroblastoma  | 100-300 mCi                   |
| • <b>Strontium-89</b>                             | • Bone metastasis  | 40-60uCi/kg<br>1.0 mCi per kg |
| • <b>Sm-153-EDTMP</b>                             |  |                               |
| • <b>Phosphorus- 32</b>                           | • Polycythaemia  | 2.3mCi/m <sup>2</sup>         |
| • <b>Y-90-Ibritumomab<br/>Tiuxetan [Zevalin®]</b> | • B-Cell NHL Y-90-ibritumomab tiuxetan.<br>> Platelet count > 150,000 cells/mL: 0.4 mCi/kg<br>> Platelet count 100,000-150,000 cells/mL:<br>0.3 mCi/kg |                               |
- The dose should never exceed 32 mCi (1,184 MBq).

# Strontium-89 Therapy for Palliation of Bony Metastases



## History :

A 65 Ys ,M, with CA prostate and widespread bone metastases and severe bony pain.

Admitted for palliative Strontium-89 therapy.

## Procedure :

- Bone metastases was confirmed by bone scan.
- The patient was given 40 mCi of Strontium-89 I.V. according to body weight of the patient.
- The patient experienced one day of exacerbated pain which was controlled by opiates but the following day showed gradual pain relieve.

# Teaching Points



## NM tumor imaging

- Functional
- Sensitive
- Whole body evaluation
- Specific : Some tumors
- Targeted therapy

## Objectives of NM tumor imaging

- Diagnosis
- Staging
- Guiding biopsy
- Follow up and therapy monitoring
- Detection of recurrence.

# Reference book and the relevant page numbers..



- **Nuclear Medicine: The Requisites, Third Edition (Requisites in Radiology) [Hardcover]**

Harvey A. Ziessman MD, Janis P. O'Malley MD, James H. Thrall MD

## **Relevant Pages :**

**Oncology : 264-274 , 279 -283 ,302 -345 ,  
119-133 , 109 -112 ,296 -299**

