


# Esophageal Diseases



Surgery Team  
MED 433



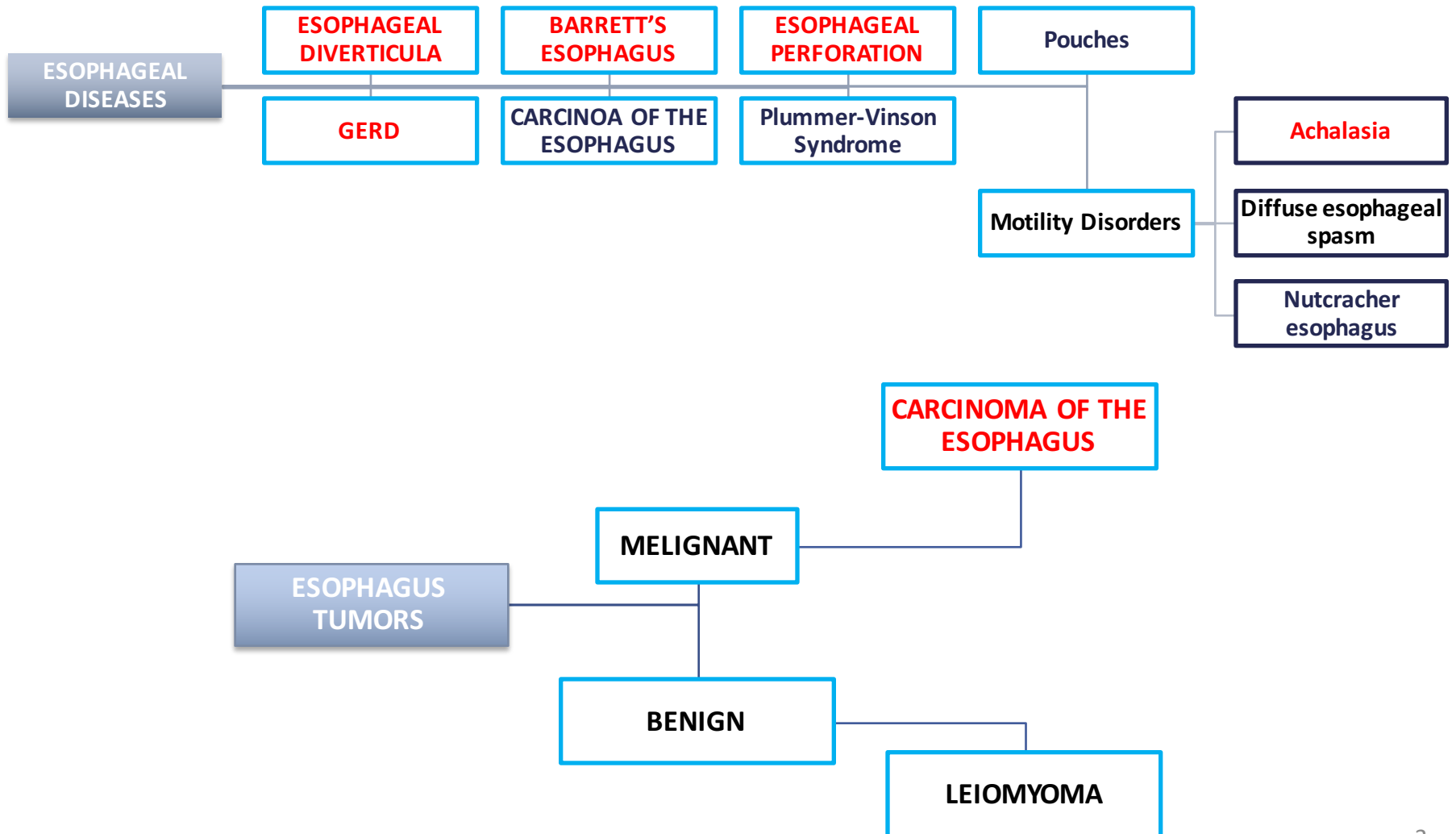
Starred topics are the  
topics which the  
doctor mentioned

# Objectives :

1. **Surgical Anatomy**
2. **Symptoms Of Esophageal Disorder** (Dysphagia, Pain, Regurgitation )
3. **Examination**
4. **Investigation** (Blood test, Radiology, Endoscopy, CT, Ultrasonography, Laparoscopy, Manometry and pH studies)
5. **Impacted Foreign Bodies**
6. **Corrosive Esophagitis**
7. **Perforation**
8. **Motility Disorders** (Achalasia, Diffuse esophageal spasm, Nutcracker esophagus)
9. **Plummer-Vinson Syndrome**
10. **Pouches**
11. **Gastro-Esophageal Reflux** (Hiatus hernia, Barrett's esophagus)
12. **Tumors Of The Esophagus** (Benign tumors, Carcinoma of the esophagus )

**Sources :** Slides, Raslan's Notebook, Principles & Practice of Surgery by: O. James Garden  
**Color Index:** Slides & Raslan's | Textbook | Doctor's Notes | Extra Explanation |  
**Important**

# Mind Map





# 1<sup>st</sup> : ACHALASIA



**Achalasia:** is an uncommon disease of esophageal motility disorder, it is characterized by degeneration of the myenteric neurons that innervate LES and esophageal body.

## 1.1 Symptoms

Common in ages of 25 and 60 years.

Equal male-to-female gender distribution.

1. **Dysphagia** to **solids and liquids** is the (most common; 90% of patients).
2. **Regurgitation** (2nd most common; 60% of patients).
3. **Night-time cough** and **aspiration** due to Nocturnal regurgitation of esophageal contents.
4. **Weight loss** occurs in end-stage disease.
5. **Chest pain** (20% to 60% of patients).
6. **Heartburn** (30% of achalasia patients). May be related to direct irritation of the esophageal lining by retained food, pills, or acidic by-products of bacterial metabolism of retained food.

## 1.2 Diagnosis

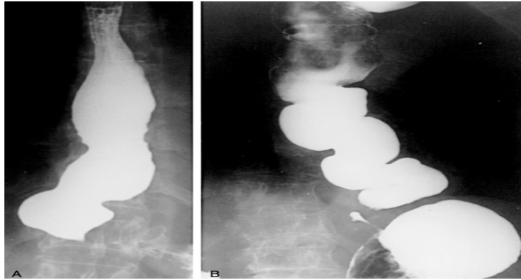
- 1) **CXR:** may show air-fluid level.
- 2) **Barium study:** quite dilated, and an air-fluid level may be secondary to retained secretions.
  - The classic finding is a gradual tapering at the end of the esophagus, similar to a bird's beak (rat tail).
- 3) **Upper endoscopy** is the next diagnostic test in a patient with dysphagia or suspected achalasia (**to rule out tumors**).
  - Findings can include:
    - Dilated esophagus with retained food or secretions.
    - Normal in as many as 44% of patients with achalasia.
  - Difficulty traversing the GEJ should raise suspicion for pseudoachalasia due to neoplastic infiltration of the distal esophagus.
- 4) **Esophageal manometry** (highest sensitivity for the diagnosis of achalasia): (**standard test**)
  - Aperistalsis of the distal esophageal body.
  - Incomplete or absent LES relaxation (Hypertensive LES).
  - Manometric variants of achalasia exist.
    - The best known is vigorous achalasia –may represent an early stage-, defined by the presence of normal to high amplitude esophageal body contractions in the presence of a non-relaxing LES.

### Criteria of achalasia:

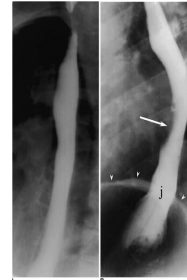
- 1) Aperistalsis of the distal esophageal body
- 2) Incomplete or absent LES relaxation
- 3) Hypertensive lower esophageal sphincter found in 20's (normal 5-10)



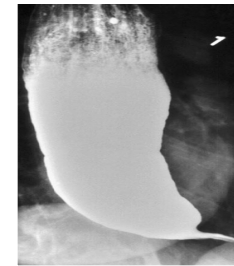
# 1<sup>st</sup> : ACHALASIA



Dilation and tapering on barium study



Barium study



"Bird's beak" or "rat's tail" on barium study

## 1.2.1 SECONDARY ACHALASIA:

- **Chagas' disease** is a parasitic infection caused by *Trypanosoma cruzi* which can cause secondary achalasia.
- The most concerning secondary etiology is **cancer**, which can present as achalasia through mechanical obstruction of the GEJ.
- Post fundoplication (surgery done for treatment of GERD patients): achalasia caused by mechanical obstruction of the GEJ by the fundoplication or diaphragmatic crural closure.
- Bariatric surgery using a gastric band device which constricts the proximal stomach a few centimeters below the LES.
- Some types of surgery could cause achalasia by reducing the LES diameter.

## NUTCRACKER OESOPHAGUS:

In this uncommon disorder, the symptoms are caused by repetitive forceful peristalsis. Manometry demonstrates normal peristalsis but with excessive amplitudes and pressures exceeding 150mmHg. Medical treatment is similar to that of diffuse oesophageal spasm, but the results are disappointing. Dilatation and surgical myotomy also have poor results.



# 1<sup>st</sup> : ACHALASIA



## Management

- The primary therapeutic goal in achalasia is to reduce the LES basal pressure.
- Treatment options include
  - Medical therapy: Nifedipine, Isosorbide dinitrate.
  - Botulinum toxin injection: block the release of acetylcholine; limited value.
  - Pneumatic dilation: blindly rupture the muscle fibers while leaving the mucosa intact.
  - Surgical myotomy (+ partial fundoplication).
- Symptomatic relief, particularly relief of dysphagia, is accepted as the primary desired outcome.

### Medical treatment

Inconvenient, only modestly effective, and frequently associated with side effects. It is reserved for patients who are awaiting or unable to tolerate more invasive treatment modalities. Pharmacologic therapies attempt to decrease the LES pressure by causing smooth muscle relaxation.

- Nitrates were first recognized as an effective treatment of achalasia.
  - Systemic vasodilatory effects and headaches limit their tolerability by patients.
- Calcium channel antagonists have a better side-effect profile when compared with nitrates.
  - 30% of patients report adverse side effects including peripheral edema, hypotension, and headache.

### Botulinum injection

- Injected into the LES targets the excitatory, acetylcholine-releasing neurons that generate LES basal muscle tone.

It is apparent that, with repeated injections, the response rates reported are similar or lower to that achieved with the initial injection; not very effective.

- Response rates at 1 month following administration average 78%, By 6 months, the clinical response rate drops to 58% and by 12 months to 49%.

Given the limitations of the efficacy and durability of response, botulinum toxin is generally reserved for use in patients who are not candidates for more invasive treatments.

### Pneumatic dilation

Pneumatic dilation remains one of the most effective first-line therapies for achalasia.

Long-term follow-up studies reported significant symptom relapse of 50% at 10 years.

Complications of pneumatic dilation:

- Gastroesophageal reflux 25-35%.
- Esophageal perforation 3 %.



# 1<sup>st</sup> : ACHALASIA



## Cont. Management

Surgery	<ul style="list-style-type: none"><li>• <b>Standard management</b></li><li>• Success rates &gt;90% - with hospital stays averaging only a few days.</li><li>• Acid exposure is a known complication of surgical intervention for achalasia (reflux esophagitis).</li><li>• Even with a successful myotomy, it is expected that patients will have some degree of dysphagia as a consequence of esophageal peristaltic dysfunction.</li><li>• Delayed recurrence of postoperative dysphagia is most commonly caused by development of a recurrent high pressure zone at the LES or a peptic stricture complicating acid reflux.</li><li>• Laparoscopic <b>Heller myotomy</b> demonstrated excellent results, with 98% of patients reporting symptomatic improvement at 5.3 years.</li><li>• Several retrospective and prospective studies have reported superior success rates for surgery when compared with pneumatic dilation.</li></ul>
Refractory achalasia	<ul style="list-style-type: none"><li>• In patients with achalasia that is refractory to therapy with Heller myotomy, options are limited.</li><li>• Although esophagectomy is considered in patients with marked dilation and sigmoid deformity, such patients may respond to Heller myotomy.</li></ul>

## Complications

- The primary complications of achalasia are related to the **functional obstruction** rendered by the non-relaxing LES and include progressive **malnutrition and aspiration**.
- Uncommon but important secondary complications of achalasia include the formation of **epiphrenic diverticula** and **esophageal cancer**.
- There is an established link between achalasia and esophageal cancer, most commonly **SQUAMOUS CELL CARCINOMA**.
  - The overall prevalence of esophageal cancer in achalasia is approximately 3% with an incidence of approximately 197 cases per 100,000 persons per year.



# 2<sup>nd</sup>: ESOPHAGEAL DIVERTICULA



## Causes

Most diverticula are a result of a primary motor disturbance or an abnormality of the UES (upper esophageal sphincter) or LES (lower esophageal sphincter).

## Site

Can occur in several places along the esophagus. The three most common sites of occurrence are:

- Pharyngoesophageal (Zenker's).
- Parabronchial (mid-esophageal) .
- Epiphrenic.

### True Diverticula

True diverticula involve **all layers** of the esophageal wall, including mucosa, submucosa, and muscularis.

Traction, or true, diverticula result from external inflammatory mediastinal lymph nodes adhering to the esophagus.

### False Diverticula

A false diverticulum consists **of mucosa and submucosa only**.

- Pulsion diverticula are false diverticula that occur because of elevated intraluminal pressures generated from abnormal motility disorders.
- **Zenker's diverticulum** and an epiphrenic diverticulum fall under the category of false, pulsion diverticula.

## PHARYNGOESOPHAGEAL (ZENKER'S) DIVERTICULUM

- Most common esophageal diverticulum found today.
- It usually presents in older patients in the 7th decade of life.
- Found herniating into Killian's triangle, between the oblique fibers of the thyropharyngeus muscle and the horizontal fibers of the cricopharyngeus muscle.





# 2<sup>nd</sup>: ESOPHAGEAL DIVERTICULA



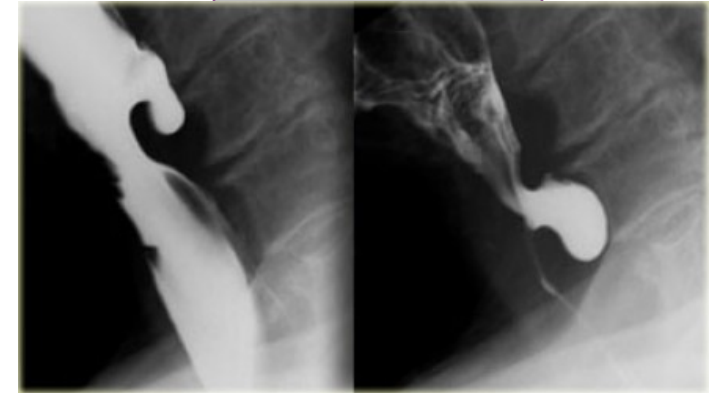## Symptoms:

- o Sticking in the throat (common).
- o Nagging cough .
- o Excessive salivation.
- o Intermittent dysphagia .
- o Regurgitation of foul-smelling, undigested material (common as the sac increases in size, because of fermentation of food).
- o Halitosis (bad mouth smell).
- o Voice changes.
- o Retrosternal pain.
- o Respiratory infections .

} Signs of progressive disease

} Especially common in elderly

Barium esophagram



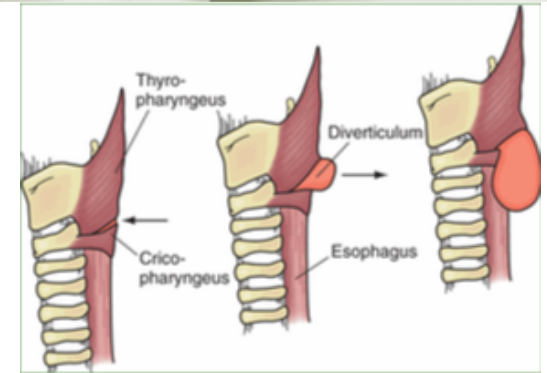
## Complications:

the most serious complication from an untreated Zenker's diverticulum is aspiration pneumonia or lung abscess.

## Diagnosis:

is made by **barium esophagram** ONLY

- o Neither esophageal manometry nor endoscopy is needed to make a diagnosis of Zenker's diverticulum.



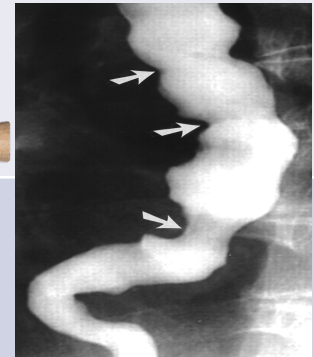## Treatment:

- o Surgical or endoscopic repair of a Zenker's diverticulum is the **gold standard** of treatment.
- o Open repair involve:
  - Myotomy of the **proximal and distal** thyropharyngeus and cricopharyngeus muscles.
  - Diverticulectomy or diverticulopexy are performed through an incision in the left neck.
- o An alternative to open surgical repair is the endoscopic Dohlman procedure.
- o Endoscopic division of the common wall between the esophagus and the diverticulum using a laser or stapler has also been successful.

# 3<sup>rd</sup>: DIFFUSE ESOPHAGEAL SPASM



<b>Pathology</b>	<ul style="list-style-type: none"><li>○ The esophageal contractions are repetitive, simultaneous, and of high amplitude.</li><li>○ DES is a hypermotility disorder of the esophagus (non-peristalsis disorder).</li><li>○ The basic pathology is related to a motor abnormality of the esophageal body that is most notable in the lower two thirds of the esophagus.</li></ul>
<b>Clinical presentation</b>	<ul style="list-style-type: none"><li>○ Is seen most often in women and is often found in patients with multiple complaints.</li><li>○ <b>Typically:</b> chest pain and dysphagia<ul style="list-style-type: none"><li>▪ Patients will complain of a squeezing pressure in the chest that may radiate to the jaw, arms, and upper back (could be misdiagnosed as <u>angina pectoris</u>).</li><li>▪ May be related to: eating or exertion.</li><li>▪ Aggravating: heightened emotional stress, acid reflux, cold liquids.</li></ul></li><li>○ <b>Regurgitation</b> of esophageal contents and saliva is common (but NOT acid reflux).</li><li>○ <b>Associated with:</b> Irritable bowel syndrome (IBS) and pyloric spasm.</li><li>○ Triggers: GI problems e.g. gallstones, peptic ulcer disease (PUD), and pancreatitis.</li></ul>
<b>Diagnosis</b>	Esophagram or manometry
<b>Treatment</b>	<ul style="list-style-type: none"><li>○ The mainstay of treatment for DES is <b>NON-SURGICAL</b>, and pharmacologic or endoscopic intervention is preferred.</li><li>○ Surgery is reserved for patients with recurrent incapacitating episodes of dysphagia and chest pain who do not respond to medical treatment.</li></ul>



Corkscrew appearance

# 4<sup>th</sup>: CAUSTIC INJURY



## The best cure for this condition is an ounce of prevention

- 🎬 In children: ingestion is accidental and in small quantities.
- 🎬 In teenagers and adults: ingestion usually is deliberate during suicide attempts, and in much larger quantities.
- 🎬 Alkali ingestion is more common than acid ingestion because of its lack of immediate symptoms.
- 🎬 Alkali ingestion is more devastating and almost always lead to significant destruction of the esophagus.

Three Phases Of Tissue Injury From Alkali Ingestion				
Phase Of Tissue Injury		Onset	Duration	Inflammatory Response
1	Acute necrosis	1-4 days	1-4 days	Coagulation of intracellular proteins
				Inflammation
2	Ulceration and granulation	3-5 days	3-12 days	Tissue sloughing
				Granulation of ulcerated tissue bed
3	Cicatrization and scarring	3 weeks	1-6 mo	Adhesion formation
				Scarring

# 4<sup>th</sup>: CAUSTIC INJURY



## Symptoms:

Phase I	Patients may complain of oral and substernal pain, hypersalivation, odynophagia and dysphagia, hematemesis, and vomiting.
Phase II	These symptoms may disappear.
Phase III	Dysphagia reappears as fibrosis and scarring begin to narrow the esophagus.

- Symptoms of respiratory distress, such as hoarseness, stridor, and dyspnea, suggest upper airway edema and are usually worse with acid ingestion.
- Pain in the back and chest may indicate a perforation of the mediastinal esophagus, whereas abdominal pain may indicate abdominal visceral perforation.

## Diagnosis:

### 1) Physical exam:

- a. Specifically evaluating the mouth, airway, chest, and abdomen.
- b. Careful inspection of the lips, palate, pharynx, and larynx is done.
- c. The abdomen is examined for signs of perforation.

### 2) Early endoscopy is recommended 12 to 24 hours after ingestion to identify the grade of the burn.

### 3) Serial chest and abdominal radiographs are indicated to follow patients with questionable chest and abdominal exams.

# 4<sup>th</sup>: CAUSTIC INJURY



## Management (of the acute phase):

- o Goal: limiting and identifying the extent of the injury.
- o It begins with neutralization of the ingested substance.
- o Alkalis (including lye) are neutralized with half-strength vinegar or citrus juice (we give them an acids to compensate alkaline solution)
- o Acids are neutralized with milk, egg whites, or antacids.
- o Emetics and sodium bicarbonate need to be avoided because they can increase the chance of perforation.

DEGREE OF BURN	ENDOSCOPIC EVALUATION	TREATMENT		
First degree	Mucosal hyperemia	48-hr observation	<b>First degree burns</b> <ul style="list-style-type: none"> <li>• 48 hours of observation is indicated.</li> <li>• Oral nutrition can be resumed when a patient can painlessly swallow saliva.</li> <li>• A repeat endoscopy and barium esophagram are done in follow-up at intervals of 1, 2, and 8 months.</li> </ul>	<b>Second and third degree burns</b> <ul style="list-style-type: none"> <li>• Resuscitation is aggressively pursued.</li> <li>• The patient is monitored in the intensive care unit.</li> <li>• Kept (NPO) with IV fluids. IV antibiotics and a proton pump inhibitor are started.</li> <li>• Fiberoptic intubation may be needed and must be available.</li> </ul>
	Edema	Acid suppression		
Second degree	Limited hemorrhage	Aggressive IV resuscitation		
	Exudates	IV antibiotics		
	Ulceration	Acid suppression		
	Pseudomembrane formation			
Third degree	Mucosal sloughing	Inhaled steroids		
	Deep ulcerations	Fiberoptic intubation (if needed)		
	Massive hemorrhage			
	Complete luminal obstruction			
	Charring			
	Perforation			



# 5<sup>th</sup>: ESOPHAGEAL PERFORATION



Perforation of the esophagus is a surgical emergency. Early detection and surgical repair within the first 24 hours results in 80% to 90% survival. After 24 hours, survival decreases to less than 50%.

## Causes:

- o Forceful vomiting “Boerhaave's syndrome” (15%) .
- o Foreign body ingestion (14%) .
- o Trauma (10%).
- o Endoscopic instrumentation for a diagnostic or therapeutic procedure (Majority).

## Signs and symptoms:

**1. fever & Severe dysphagia** (the patient is unable to swallow his saliva).

**2. Pain:** neck, substernal, or epigastric

+/- Vomiting or hematemesis.

### Cervical perforations

- May present with **neck ache** and **stiffness** due to contamination of the prevertebral space.
- Could cause subcutaneous emphysema .

### Thoracic perforations

Present with **shortness of breath and retrosternal chest pain** lateralizing to the side of perforation.  
Could cause **pneumothorax**.

### Abdominal perforations

present with **epigastric pain** that radiates to the back if the perforation is posterior .

### On examination:

- tachypnea, tachycardia, and a low-grade fever but have no other overt signs of perforation.
- Subcutaneous air in the neck or chest, shallow decreased breath sounds, or a tender abdomen are all suggestive of perforation.
  - With increased mediastinal and pleural contamination, patients progress toward hemodynamic instability (shock).

### History:

trauma, advanced esophageal cancer, violent writhing (as seen in Boerhaave's syndrome), swallowing of a foreign body, or recent instrumentation.

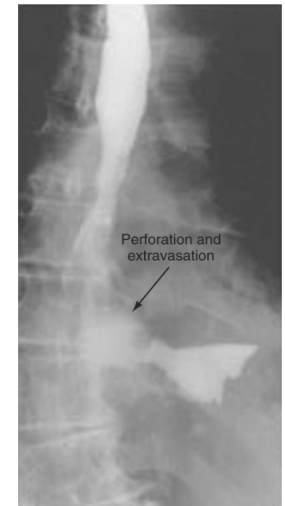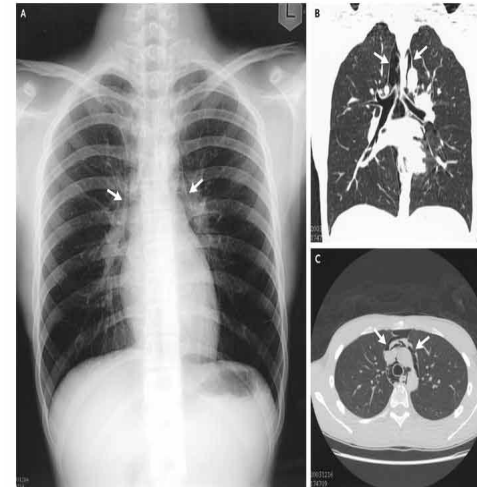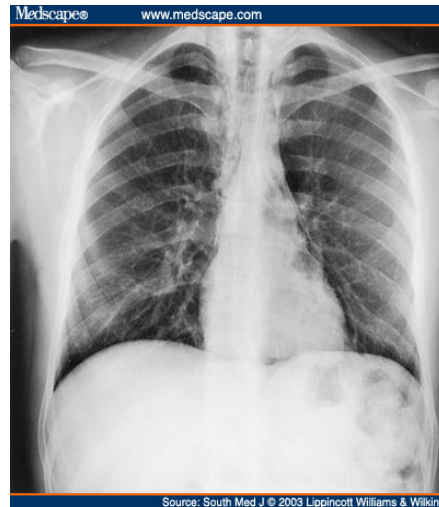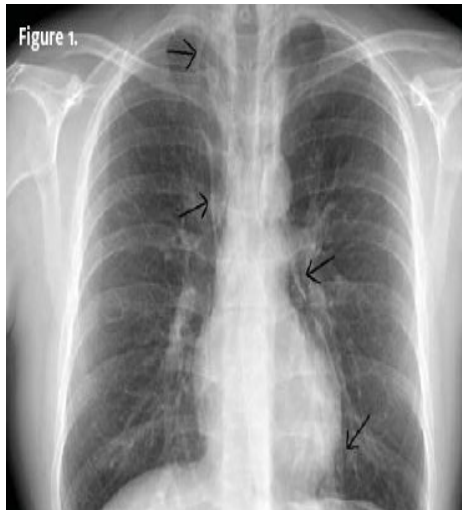


# 5<sup>th</sup>: ESOPHAGEAL PERFORATION



## Diagnosis:

- **Lab:** ↑WBC count and ↑salivary amylase in the blood or pleural fluid.
  - **Chest x-ray:** may demonstrate a hydropneumothorax.
  - **Contrast esophagram:** done using barium for a suspected thoracic perforation and Gastrografin is used for an abdominal perforation.
- Most perforations are found above the GEJ on the left lateral wall of the esophagus which results in a 10% false-negative rate in the contrast esophagram if the patient is not placed in the lateral decubitus position.
- **Chest CT:** shows mediastinal air and fluid at the site of perforation.





# 5<sup>th</sup>: ESOPHAGEAL PERFORATION



## TREATMENT:

- Patients with an esophageal perforation can progress rapidly to **hemodynamic instability** and **shock**.
- If perforation is suspected:
  - **Resuscitation** with placement of large-bore peripheral IV catheters, a urinary catheter, and a secure airway, before the patient is sent for diagnostic testing.
  - IV fluids and broad-spectrum antibiotics are started immediately, and the patient is monitored in an ICU.
  - NPO, and nutritional access needs are assessed.

A **surgical endoscopy** needs to be performed if the esophagram is negative or if operative intervention is planned. Mucosal injury is suggested if blood, mucosal hematoma, or a flap is seen or if the esophagus is difficult to insufflate.

## Surgery is not indicated for every patient with a perforation of the esophagus

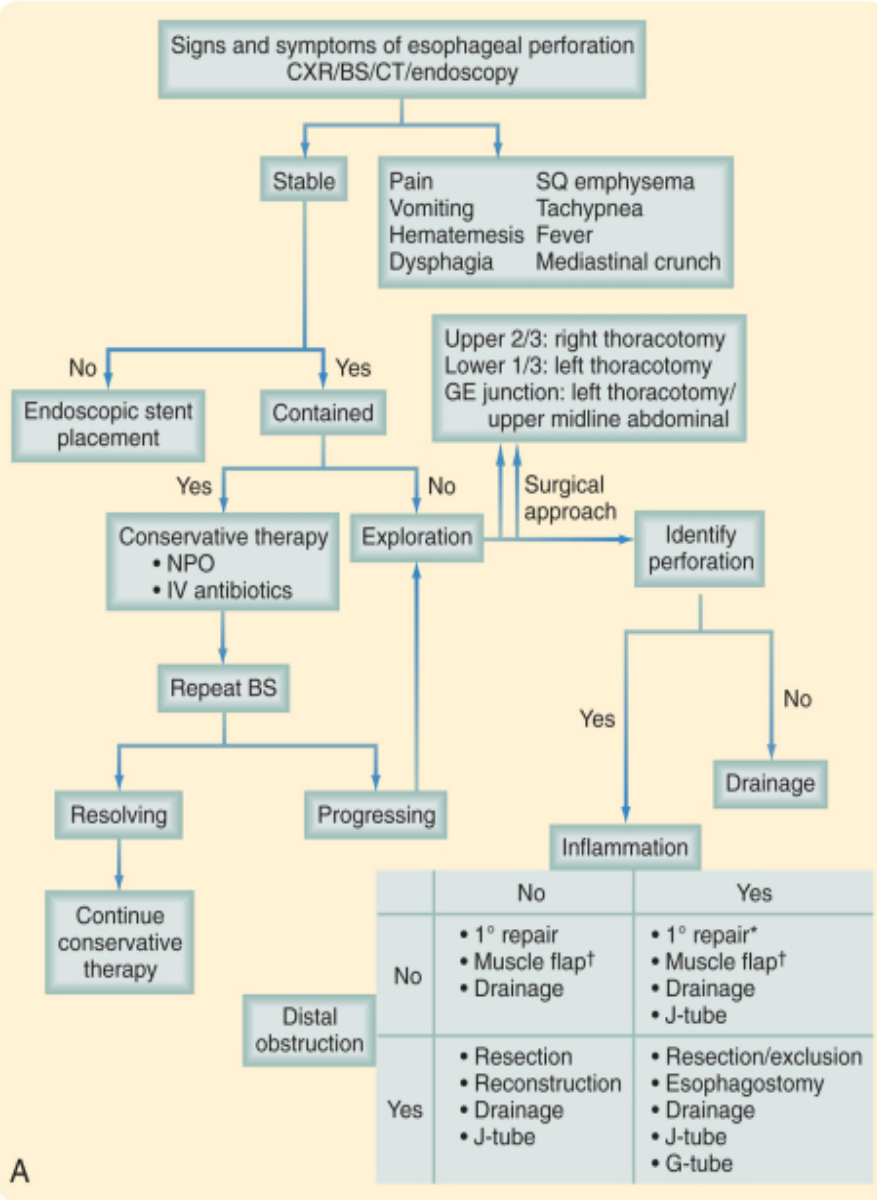
- Management is dependent on several variables: stability of the patient, extent of contamination, degree of inflammation, underlying esophageal disease, and location of perforation.
- **The most critical variable** that determines the surgical management of an esophageal perforation is the **degree of inflammation surrounding the perforation**.
  - When patients present within 24 hours of perforation, inflammation is generally minimal, and primary surgical repair is recommended.
  - With time, inflammation progresses, and tissues become friable and may not be amenable to primary repair.
- The **final variable** to consider in the **surgical management** of esophageal perforations is the location of the perforation.



# 5<sup>th</sup>: ESOPHAGEAL PERFORATION

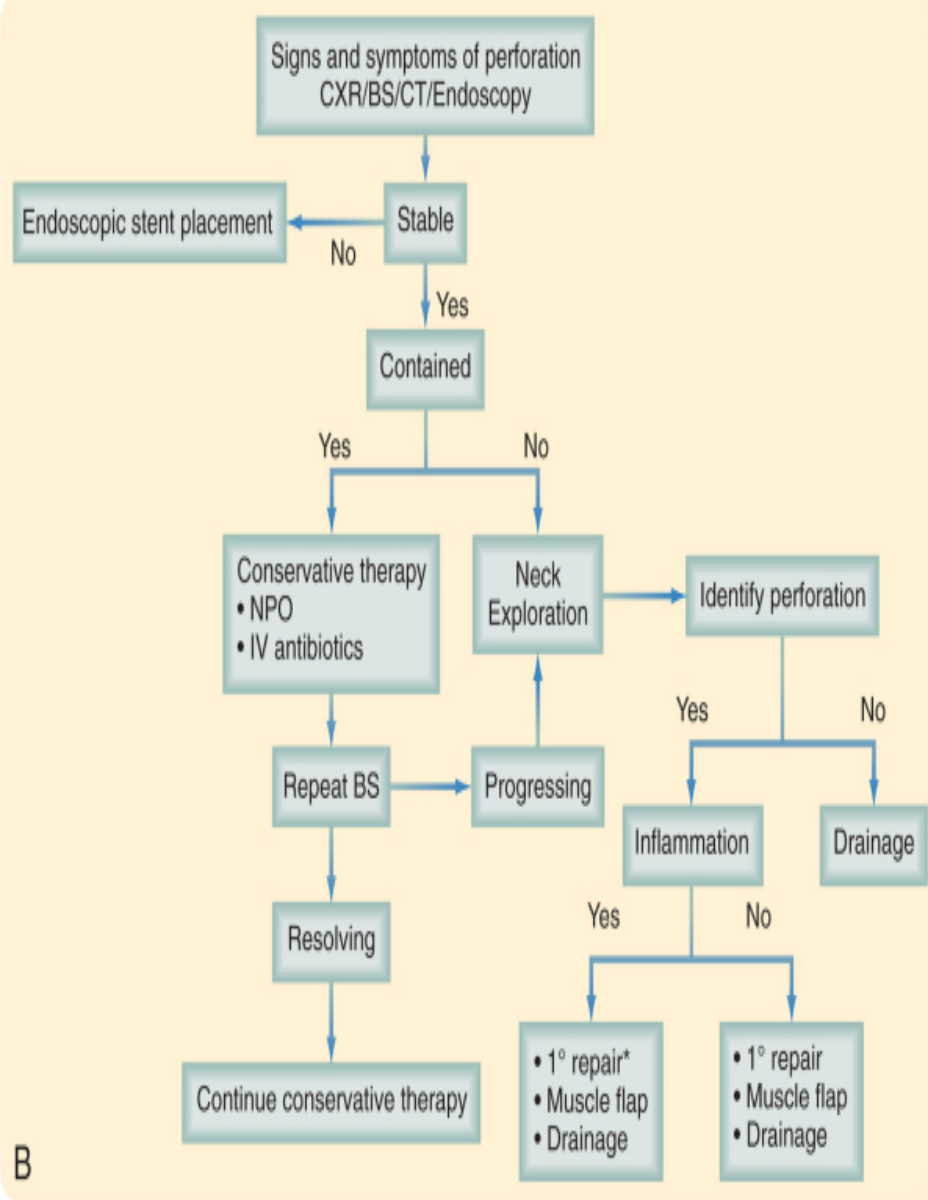


## MANAGEMENT OF THORACIC AND ABDOMINAL ESOPHAGEAL PERFORATIONS



A

## MANAGEMENT OF CERVICAL ESOPHAGEAL PERFORATIONS



B



# 6<sup>nd</sup> :GASTROESOPHAGEAL REFLUX DISEASE (GERD)



## • DEFINITION:

- Symptoms OR mucosal damage produced by the abnormal reflux of gastric contents into the esophagus. (it might be pathological or physiological GERD)

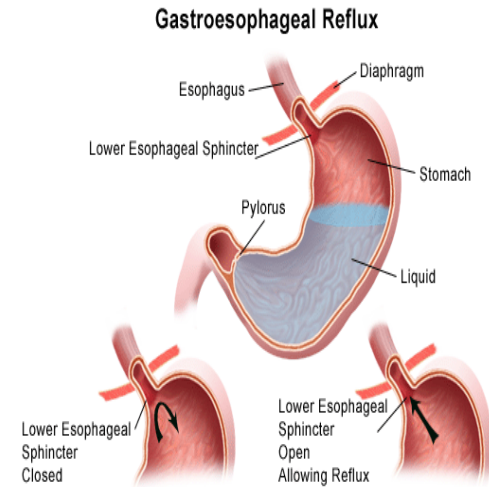
- Often chronic and relapsing.

May see complications of GERD in patients who lack typical symptoms.

## • PATHOLOGY:

LES has the primary role of preventing reflux of the gastric contents into the esophagus

- GERD may occur when the pressure of the high-pressure zone in the distal esophagus is too low to prevent gastric contents from entering the esophagus (when the LES is NOT contracting well).



**GERD is often associated with a hiatal hernia (imp.)** →

Epidemiology:

o About 44% of the US adult population have heartburn at least once a month.

o 14% of Americans have symptoms weekly. o 7% have symptoms daily.

### Hiatal Hernia types

TYPE I	The most common. Also called “sliding” hernia. Gastroesophageal junction is above the diaphragm
TYPE II	Referred to as paraesophageal hernias. May be associated with GERD. GE junction is normal in position BUT part of the stomach herniated above the diaphragm.
TYPE III	Referred to as paraesophageal hernias. May be associated with GERD. GE junction is above the diaphragm and part of stomach too.
TYPE IV	Another organ is herniated into the chest e.g. spleen, colon.



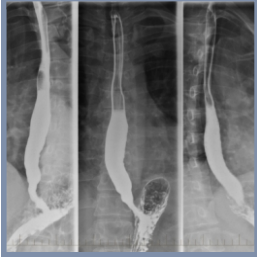## 6.1 SYMPTOMS:

Classic GERD (typical)	Complicated GERD
Substernal burning and or regurgitation	Dysphagia (difficulty in swallowing)
Postprandial	Odynophagia: Retrosternal pain w/swallowing
Aggravated by change of position	Bleeding
Prompt relief by antacid	
Extra-esophageal (atypical)	
Pulmonary	ENT
Asthma	Hoarseness (dysphonia)
Aspiration pneumonia	Laryngitis
Chronic bronchitis	Pharyngitis
Pulmonary fibrosis	Chronic cough (due to aspiration)
Other	
Chest pain	Sinusitis
Dental erosion	Subglottic stenosis
	Laryngeal cancer

**-Patients typically complain of Palpitations and hiccups ,heartburn, regurgitation of acid into the back of their throat, nausea, waterbrash (hypersalivation), epigastric pain and occasionally vomiting.**



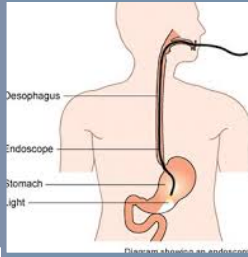
## 6.2.1 DIAGNOSIS:



### BARIUM SWALLOW

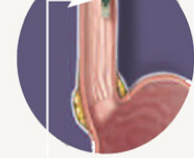(to confirm the diagnosis).

**Change in position**



### ENDOSCOPY

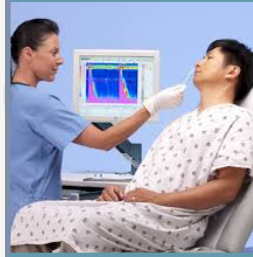(important to see the complication of GERD).



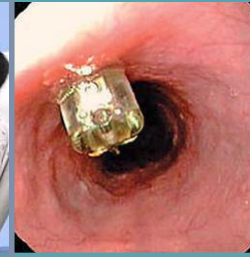
A small capsule that measures pH levels is attached to the esophagus wall.

### Ambulatory pH monitoring

**(the gold standard and most accurate).**



### Esophageal manometry.



### Bravo capsule

is a capsule that receive the PH massages for 24 hours.

- GERD is diagnosed by taking a good history, performing an endoscopy and sometimes a 24-hour oesophageal pH study

*Always start with less invasive procedures: CXR to exclude respiratory disease*

### Summary of GERD:

- It is due to low LES pressure that allows the reflux of gastric acids into the esophagus.
- **Symptoms of GERD:** (1) sore throat (2) epigastric pain (3) sub-sternal burning (4) hoarseness
  - o Mainly occur post-prandial and with change of position.
  - o Relieved by anti-acids.
- **Diagnosis:**
  - o Barium swallow to confirm the diagnosis.
  - o Endoscopy for complications.
  - o PH monitor is the most accurate.
- Chronic GERD mainly followed by Barrett's esophagus which is a pre-malignant sign

### **Barium study types:**

- Barium swallow
- Barium meal
- Barium follow through
- Small intestine enema
- Barium enema (small nasojejunal)



# 6<sup>th</sup> : GERD



## GERD treatment

<p><u>-Lifestyle Modifications</u> (most important)</p>	<p>Elevate head of bed 4-6 inches.</p> <ul style="list-style-type: none"> <li>• Avoid eating within 2-3 hours of bedtime. o Lose weight if overweight.</li> <li>• Stop smoking.</li> <li>• Modify diet: <ul style="list-style-type: none"> <li>☞ Eat more frequent but smaller meals.</li> <li>☞ Avoid fatty/fried food, peppermint, chocolate, alcohol, carbonated beverages, coffee and tea.</li> </ul> </li> <li>• OTC medications prn (as needed).</li> </ul>
<p><u>- Acid Suppression Therapy</u></p>	<ol style="list-style-type: none"> <li>1) <b>H2-Receptor Antagonists (H2RAs)</b> ☞ Cimetidine (Tagamet®), Ranitidine (Zantac®), Famotidine (Pepcid®), Nizatidine (Axid®).</li> <li>2) <b>Proton Pump Inhibitors (PPIs)</b> e.g. Omeprazole (Prilosec®), Lansoprazole (Prevacid®), Rabeprazole (Aciphex®), Pantoprazole (Protonix®), Esomeprazole (Nexium®)</li> </ol>
<p><u>- Anti-Reflux Surgery:</u>  Indications:</p>	<ol style="list-style-type: none"> <li>1) <b>Failed</b> medical management.</li> <li>2) Patient's <b>choice</b> (opt for surgery despite successful medical management, due to life style considerations including age, time or expense of medications, etc).</li> <li>3) <b>Complications</b> of GERD (e.g. Barrett's esophagus; grade III or IV esophagitis).</li> <li>4) <b>Medical complications</b> attributable to a large hiatal hernia (e.g. bleeding, dysphagia).</li> <li>5) <b>"Atypical"</b> symptoms (asthma, hoarseness, cough, chest pain, aspiration) and reflux documented on 24 hour pH monitoring.</li> </ol>
<p><u>- Endoscopic Antireflux Therapies:</u></p>	<ol style="list-style-type: none"> <li>1) Radiofrequency energy delivered to the LES (Stretta procedure).</li> <li>2) Suture ligation of the cardia (Endoscopic plication).</li> <li>3) Submucosal implantation of inert material in the region of the lower esophageal sphincter (Enteryx).</li> </ol>



# 7<sup>th</sup> : BARRETT'S ESOPHAGUS



## Barrett's esophagus

<b>Pathology</b>	Changing of a normal esophagus epithelium (squamous stratified) to <b>columnar epithelium with goblet</b> due to chronic irritation i.e. GERD to be more resistant to acid.
<b>Risk factors</b>	<b>Chronic GERD</b> (10% of GERD patient will develop Barrett's)
<b>Complications</b>	With continued exposure to the reflux disease, metaplastic cells undergo cellular transformation to low- and high-grade dysplasia: <ul style="list-style-type: none"><li>• <b>Low grade dysplasia</b> only affecting mucosa and has a risk of cancer.</li><li>• <b>High grade dysplasia</b> the patient for sure has carcinoma in situ.</li></ul> Barrett's is pre-malignant mass and it has 40-folds chance of developing Adenocarcinoma. (NOT SCC)
<b>Epidemiology</b>	Common in age of 55 to 63 years. Men have a 15-fold increased incidence over women of adenocarcinoma of the esophagus, but women with Barrett's esophagus are increasing in number
<b>Clinical presentation</b>	<ul style="list-style-type: none"><li><input type="checkbox"/> Many are <b><u>asymptomatic</u></b>.</li><li><input type="checkbox"/> Most patients present with symptoms of <b><u>GERD</u></b>: heartburn, regurgitation, acid or bitter taste in the mouth, excessive belching, and Indgestion.</li><li><input type="checkbox"/> <b>Recurrent <u>respiratory infections</u></b>, adult <b><u>asthma</u></b>, and infections in the head and neck also are common complaints.</li></ul>
<b>Diagnosis</b>	<ul style="list-style-type: none"><li><input type="checkbox"/> The diagnosis of BE is made by <b>endoscopy and pathology</b>. The presence of any endoscopically visible <b><u>segment of columnar mucosa</u></b> within the esophagus that on pathology identifies intestinal metaplasia defines BE.</li></ul>

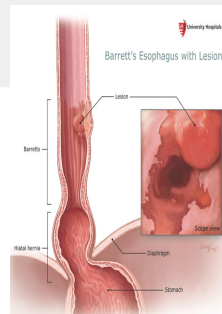
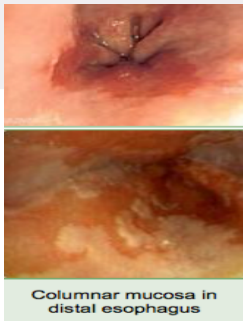


## Treatment of Barrett's

### Surveillance

**Yearly surveillance endoscopy** is recommended in all patients with a diagnosis of Barrett's esophagus.

- For patients with low-grade dysplasia, surveillance endoscopy is performed at 6-month intervals for the first year and then yearly thereafter if there has been no change.
- Patients undergoing surveillance are placed on acid suppression medication and monitored for changes in their reflux symptoms.



### Anti-reflux surgery (controversial)

- Those in favor of surgery argue that medical therapy and endoscopic surveillance may treat the symptoms but fail to address the problem.
- The problem is the functional impairment of the LES that leads to chronic reflux and metaplastic transformation of the lower esophageal mucosa.
- Surgery renders the LES competent and restores the barrier to reflux.
- Studies have demonstrated regression of metaplasia to normal mucosa up to 57% of the time in patients who have undergone anti-reflux surgery.
  - **Photodynamic therapy (PDT)** is the most common ablative method used to treat BE.
  - **Endoscopic mucosal resection (EMR)** is gaining favor for the treatment of Barrett's esophagus with low-grade dysplasia.
  - **Esophageal resection** for Barrett's esophagus is recommended only for patients in whom high-grade dysplasia is found.

# ★ 8<sup>th</sup> : CARCINOMA OF THE ESOPHAGUS

## Symptoms

- Early stages > asymptomatic or mimics GERD
- Most common symptom: **Dysphagia and weight loss.**
- Signs of advanced disease:
  - **tracheoesophageal fistula** causes Choking, coughing, and aspiration
  - **Direct invasion** into the recurrent laryngeal nerve causes Hoarseness and vocal cord paralysis
- Systemic metastases to liver, bone, and lung can present with jaundice, excessive pain, and respiratory symptoms.

## Types

	Adenocarcinoma	Squamous cell carcinomas
<b>Pathology</b>	the squamous-lined distal esophagus changes to columnar epithelium (Barrett's esophagus) then progresses to become Adenocarcinoma	Arises from the squamous mucosa that is native to the esophagus
<b>Site</b>	Lower third of esophagus	upper and middle third of the esophagus
<b>Risk factors</b>	<ul style="list-style-type: none"> <li>• GERD,</li> <li>• Western diet (Intake of caffeine, fats, and acidic and spicy foods all lead to decreased tone in the LES and an increase in reflux).</li> <li>• acid-suppression medications</li> </ul>	<ul style="list-style-type: none"> <li>• Smoking and alcohol</li> <li>• Food additives,</li> <li>• long-term ingestion of hot liquids</li> <li>• caustic ingestion,</li> <li>• Achalasia, bulimia, tylosis (an inherited autosomal dominant trait),</li> <li>• Plummer-Vinson syndrome, external-beam radiation,</li> <li>• and esophageal diverticula</li> </ul>



# ★ 8<sup>th</sup> : CARCINOMA OF THE ESOPHAGUS

## Diagnosis

### Esophagram

- A barium esophagram is recommended for any patient presenting with dysphagia.
- differentiates intraluminal from intramural lesions.
- discriminate between intrinsic (from a mass protruding into the lumen) and extrinsic (from compression of a structures outside the esophagus).
- The classic finding of an **apple-core lesion**.
- **Not specific** for cancer, but good first test to perform in patients presenting with dysphagia and a suspicion of esophageal cancer.

### Endoscope

- The diagnosis of esophageal cancer is made best from an **endoscopic biopsy**.
- Any patient undergoing surgery for esophageal cancer must have an endoscopy before entering the operating room for a definitive resection.

### CT scan

CT scan of the chest and abdomen is important to assess the length of the tumor, thickness of the esophagus and stomach, regional lymph node status and distant disease to the liver and lungs.

### PET scan

- Evaluates the **primary mass**, **regional lymph nodes**, and **distant** disease.
- Its sensitivity and specificity slightly exceed those of CT; however, they remain low for definitive staging.

### Endoscopic ultrasound

is the most critical component of **esophageal cancer staging**.

- The information obtained from EUS will help guide both medical and surgical therapy.
- Biopsy samples can be obtained of the mass and lymph nodes in the paratracheal, subcarinal, paraesophageal, celiac region.

## Treatment

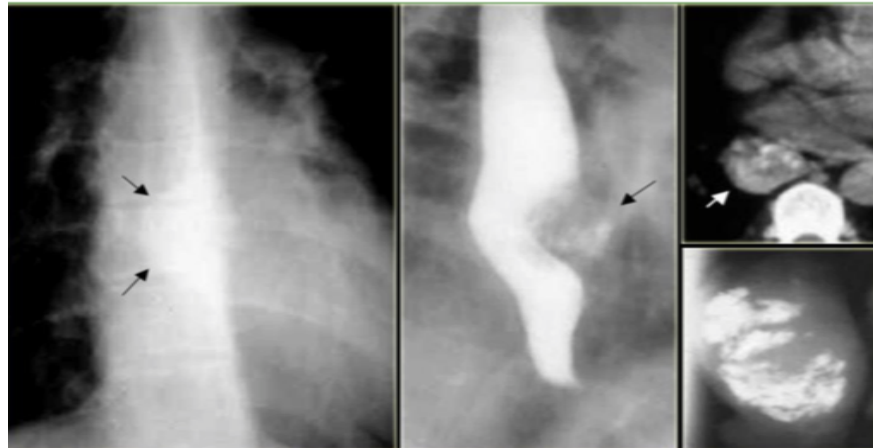
1. Chemotherapy
2. Radiation therapy.
3. Chemo-radiotherapy.
4. Surgical resection

# 9<sup>th</sup> :LEIOMYOMA



- ❑ Leiomyomas constitute 60% of all benign esophageal tumors.
- ❑ Found in men  $\geq$  women and tend to present in the 4th & 5th decades.
- ❑ 80% are found in the distal 2/3 of the esophagus.
- ❑ Usually solitary and remain intramural, causing symptoms as they enlarge
- ❑ Recently, they have been classified as a gastrointestinal stromal tumor (GIST).
  - **GIST tumors are the most common mesenchymal tumors of the gastrointestinal tract and can be benign or malignant.**
  - **Nearly all GIST tumors occur from mutations of the c-KIT oncogene, which codes for the expression of c-KIT (CD117).**
- ❑ All leiomyomas are benign. Malignant transformation is rare ⓘ.
- ❑ **Clinical presentation:**
  - Many leiomyomas are asymptomatic.
  - Dysphagia and pain are the most common symptoms and can result from even the smallest tumors.

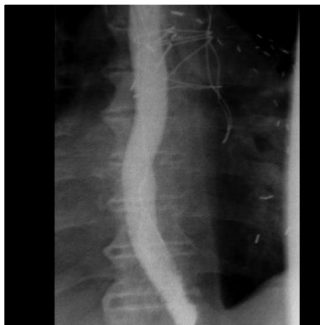**These account for less than 1% of oesophageal neoplasms. The most common is the benign leiomyoma which is often asymptomatic but may cause bleeding or dysphagia. It is best treated by local enucleation, with good results.**



# 9<sup>th</sup> :LEIOMYOMA



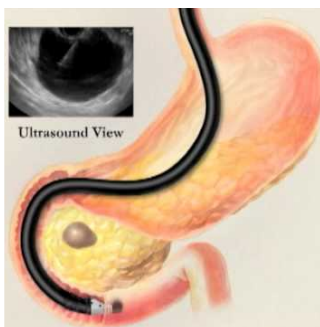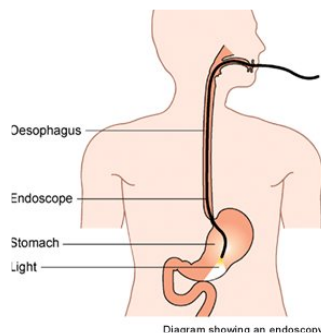
## ★ DIAGNOSIS:



Barium esophagram:  
leiomyoma has a characteristic appearance  
(smooth filling defect ☐).

### Endoscopy:

extrinsic compression is seen, and the  
overlying mucosa is  
noted to be intact.



Endoscopic ultrasound (EUS):  
hypoechoic mass in the submucosa  
or  
muscularis propria.

## TREATMENT:

- o Leiomyomas are slow-growing tumors with rare malignant potential that will continue to grow and become progressively symptomatic with time.
- o Although observation is acceptable in patients with small (<2 cm) asymptomatic tumors or other significant co-morbid conditions, in most patients, surgical resection is advocated.
- o Surgical enucleation of the tumor remains the standard of care (thoracotomy or with video or robotic assistance).
- o The mortality rate is less than 2%, and success in relieving dysphagia approaches 100%.

# Plummer–Vinson syndrome & Pouches:

## Plummer–Vinson syndrome:

It is characterized by a post-cricoid web that results in dysphagia. The web is related to iron deficiency anaemia, but may be congenital or traumatic in origin. The squamous epithelium becomes hyperplastic and there is hyperkeratosis and desquamation, which leads to web formation.

**Clinical features** :middle-aged women, dysphagia, signs of anaemia, including koilonychia, smooth tongue and angular stomatitis.

### **Investigations:**

**CBC:** hypochromic microcytic anaemia and serum ferritin levels will be low

**Barium swallow** demonstrates a narrowing of the upper oesophagus.

### **Management**

The web is dilated endoscopically and biopsies should also be taken, as there is an association with post-cricoid carcinoma. The iron deficiency status is corrected by oral iron therapy.

## Pouches:

Pouches are protrusions of mucosa through a weak area in the muscle wall. The best-known type of pouch lies in the pharynx and is associated with raised cricopharyngeal pressure, Incoordination of swallowing and failure of relaxation of the cricopharyngeus muscle cause the herniation.

### **Clinical features**

elderly and males aregurgitation of food, halitosis, dysphagia, gurgling in the throat, aspiration and a lump in the neck (pharyngeal pouch); alternatively, the patient may be asymptomatic.

### **Investigations**



Barium swallow demonstrates the pouch and the uncoordinated swallowing. Endoscopy also confirms the diagnosis but must be performed with care to avoid accidental perforation of the pouch.

### **Management**

Surgical myotomy of the cricopharyngeus and resection of the pouch.

# Summary

Disease	Symptoms	Diagnosis	Treatment	Notes
<b>GERD</b>	<p><b>Classic GERD:</b> burning,agrev. With position...</p> <p><b>Complicated GERD:</b> Odynophagia,dyspahagia</p> <p><b>Extraesophegeal GERD:</b> pulmonary, ENT, others.</p>	<p>-Ambulatory pH monitoring (gold standard)</p> <p>-Barium Swallow</p> <p>-Endoscopy</p> <p>-Esoph. Manometry</p> <p>-Bravo Capsule</p>	<p>-Lifestyle Modifications #1</p> <p>-Acid Suppression Therapy</p> <p>-Anti-Reflux Surgery</p> <p>-Endoscopic Antireflux Therapies</p>	<p>-due to ↓ LES pressure allows the reflux of gastric acids into esophagus</p> <p>-Chronic GERD mainly followed by BE</p>
<b>BARRETT'S ESOPHAGUS</b>	<p>-Asymptomatic</p> <p>-GERD symptoms-</p> <p>Respiratory infect.</p> <p>-Asthma</p>	<p>-endoscopy and pathology</p>	<p>-Yearly surveillance endoscopy</p> <p>-Anti-reflux surgery (controversial):PDT, EMR, Esophageal resection</p>	<p>segment of columnar mucosa within the esophagus that on pathology identifies intestinal metaplasia defines BE. (always follow-up)</p>
<b>CARCINOMA OF THE ESOPHAGUS</b>	<p>-Early stage: asymptomatic or mimic GERD</p> <p><u>-dysphagia and weight loss.</u></p>	<p>-Esophagram</p> <p>-Endoscopy</p> <p>-Scan</p> <p>-PET scan</p> <p>-Endoscopic ultrasound (EUS)</p>	<p>-Chemotherapy</p> <p>-Radiation therapy</p> <p>-Chemoradio-therapy</p> <p>-Surgical resection</p>	<p>Squamous cell carcinoma the most esophegeal cancer</p>
<b>LEIOMYOMA</b>	<p>-Asymptomatic</p> <p>-Dysphagia and pain</p>	<p>-Barium esophagram</p> <p>-Endoscopy</p> <p>-Endoscopic ultrasound (EUS):</p>	<p>-Observation in &lt;2cm</p> <p>-Surgical enucleation of the tumor remains the standard of care</p>	<p>-Solitary , Benign , - Stromal tumors</p> <p>-Rarely become Melignant</p>

Disease	Symptoms	Diagnosis	Treatment	Notes
<b>Achalasia</b>	<ol style="list-style-type: none"> <li>1. <b>Dysphagia to solids and liquids</b></li> <li>2. Regurgitation</li> <li>3. Weight loss</li> <li>4. Chest pain</li> <li>5. Heartburn</li> </ol>	<ol style="list-style-type: none"> <li>1. CXR</li> <li>2. <b>Barium study</b></li> <li>3. Upper endoscopy</li> <li>4. Esophageal manometry</li> </ol>	<ol style="list-style-type: none"> <li>1. Medical therapy.</li> <li>2. Botulinum toxin injection.</li> <li>3. Pneumatic dilation.</li> <li>4. Surgical myotomy.</li> </ol>	<b>Criteria of achalasia:</b> <ol style="list-style-type: none"> <li>1. Aperistalsis of the distal esophageal body</li> <li>2. Incomplete or absent LES relaxation</li> <li>3. Hypertensive LES.</li> </ol>
<b>ESOPHAGEAL DIVERTICULA</b>	<ol style="list-style-type: none"> <li>1. Sticking in the throat</li> <li>2. Halitosis (bad mouth smell).</li> <li>3. Voice changes.</li> <li>4. Regurgitation of undigested material.</li> </ol>	<ol style="list-style-type: none"> <li>1. barium esophagram ONLY o Neither esophageal manometry nor endoscopy is needed.</li> </ol>	Surgical or endoscopic repair ( <b>gold standard</b> ): <ol style="list-style-type: none"> <li>1. Myotomy of the <b>proximal and distal</b>.</li> <li>2. Diverticulectomy</li> </ol>	<b>*Common in elderly.</b> <b>*No medical treatment.</b>
<b>DIFFUSE ESOPHAGEAL SPASM</b>	<ol style="list-style-type: none"> <li>1. <b>Typically:</b> chest pain and dysphagia</li> <li>2. <b>Regurgitation</b></li> <li>3. <b>Associated with:</b> Irritable bowel syndrome (IBS) and pyloric spasm.</li> </ol>	<ol style="list-style-type: none"> <li>1. esophagram and manometric studies.</li> </ol>	NON-SURGICAL, and pharmacologic or endoscopic intervention is preferred. Surgery is reserved for patients with recurrent incapacitating episodes of dysphagia and chest pain who do not respond to medical treatment.	
<b>CAUSTIC INJURY</b>	<ol style="list-style-type: none"> <li>1. Respiratory distress, &gt;hoarseness, stridor, and dyspnea,</li> <li>2. Pain in the back and chest</li> <li>3. Abdominal pain</li> </ol>	<ol style="list-style-type: none"> <li>1. Physical exam.</li> <li>2. Early endoscopy .</li> <li>3. Serial chest and abdominal radiographs.</li> </ol>	<ol style="list-style-type: none"> <li>1. First degree: <ul style="list-style-type: none"> <li>• 48 hours of observation is indicated.</li> <li>• acid suppression.</li> </ul> </li> <li>2. Second and third degree burns: <ul style="list-style-type: none"> <li>• Resuscitation is aggressively pursued.</li> <li>• IV antibiotics</li> <li>• Inhaled steroids</li> <li>• Fiberoptic intubation</li> </ul> </li> </ol>	
<b>ESOPHAGEAL PERFORATION</b>	fever & dysphagia. +/- Vomiting or hematemesis. Pain: neck, substernal, or epigastric	<ul style="list-style-type: none"> <li>• lab:  <b>WBC</b>,  <b>salivary amylase</b></li> <li>• <i>Chest x-ray.</i></li> <li>• <i>Contrast esophagram.</i></li> <li>• <i>Chest CT.</i></li> </ul>	<ul style="list-style-type: none"> <li>• Surgical endoscopy needs to be performed if the esophagram is negative.</li> <li>• If perforation is suspected: <ol style="list-style-type: none"> <li>1. Resuscitation .</li> <li>2. IV fluids + antibiotics.</li> <li>3. The patient is kept NPO.</li> </ol> </li> </ul>	



# MCQs

## 1-The gold standard investigation for GERD is:

- A) Ambulatory pH monitoring
- B) Barium swallow
- C) Endoscopy
- D) Clinical picture

## 2-Hiatus hernia:

- A) Reflux is not seen in paraesophageal type
- B) Dysphagia is the commonest symptom of sliding type
- C) Paraesophageal type is treated medically
- D) The gastroesophageal junction is intraabdominal in sliding type

## 3-Achalasia's usual investigating tools & equipment ... all except:

- A) Radionuclide
- B) MRI
- C) Endoscopy
- D) Barium swallow

Answers:

1-A

2-A

3-B



# MCQs

4-Most common site for squamous cell carcinoma of the esophagus is:

- A) Upper 1/3
- B) Middle 1/3
- C) Lower 1/3
- D) Site of esophageal reflux

5-Transforms into adenocarcinoma in 10% of cases

What is not true about leiomyoma of the esophagus?

- A) 10% are multiple
- B) They are due to mutation in c kit oncogene
- C) They arise from the mucosa of esophagus
- D) Most common site of origin is the middle 1/3 of esophagus

6-Weight loss comes earlier with:

- A) Colon cancer
- B) Prostatic cancer
- C) Esophageal cancer
- D) Hepatoma

7- 70 year old male newly diagnosed with pharyngoesophageal (Zenker's) diverticulum, which one of the following most likely the presenting symptoms?

- A) Abdominal pain
- B) Haematemesis
- C) Halitosis
- D) Vomiting

8- 55 year old newly diagnosed with diffuse esophageal spasm, his presenting history may include one of the following?

- A) Abdominal pain
- B) Chest pain and dysphagia
- C) Haematemesis
- D) Recurrent vomiting

Answers:

4-A

5-A

6-D

7-C

8-C

9-B



# Thank You..

Done By :

Ghada Alalshaikh

Nouf Alhaamid

Revised By:

Omar Aldhasee

Ahmed Alhussien



[surgery433@gmail.com](mailto:surgery433@gmail.com)