

OSCE TEAM  
MED434



جامعة  
الملك سعود  
King Saud University



## how to approach flank pain

Color index :

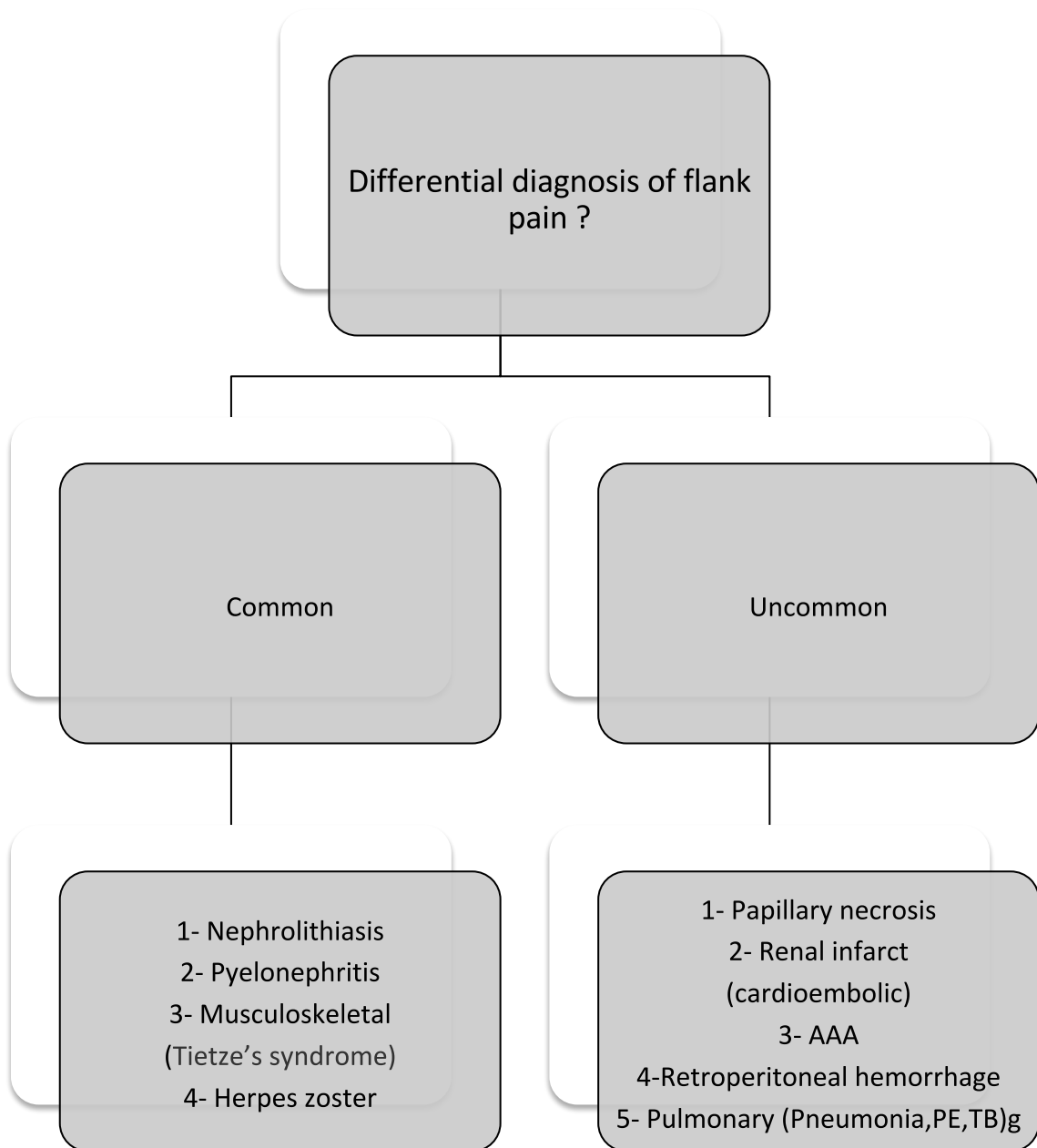
**Important**

Further explanation

[Editing link](#)

# Flank pain

- ◆ Refers to pain **occurring just below the ribs and above the pelvis.**
- ◆ Usually, the pain is worse on one side of your body



Personal data  
(Age -Sex)

Young female: UTI.  
Old male: suspect benign prostatic hyperplasia (BPH)

Chef complain (flank pain)

Question	Think about
1- Site	→ just below the ribs and above the pelvis
2- Onset (Tell me about how your symptoms started)	→ Sudden ? <b>Renal stone</b> → Associated with movement ? <b>Musculoskeletal</b>
3- Character (can you describe the pain ?)	→ Sharp & knife like or colicky ? <b>Renal stone</b> → Tingling? Numb sensation ? <b>Herpes zoster</b>
4- Reliving factor ?	→ Writting to find a comfortable position ? Renal stone
5- Associated symptoms ?	→ fever , vomiting and nausea? <b>Pyelonephritis</b> → Hematuria ? <b>Renal stone , pyelonephritis</b> → Other LUTS (dysuria, urgency , frequency) ? <b>Pyelonephritis / UTI</b> → Weight loss ? <b>Malignancy</b>
6- Duration ? How long have you been experiencing these symptoms ?	→ Hours to 1 week ? <b>pyelonephritis + renal stone</b> → Months ? <b>Malignancy , renal cyst</b>

Past medical & Surgical history

Similar symptoms ?  
Do you have any STD?  
Trauma ?  
Previous surgery ?  
Any chronic diseases ?  
Previous admission ?

## Medication history

Warfarin.  
Heparin  
AIDS drugs  
Rifampicin

## Social & systemic review

Smoking

Sexual contact.

Travel

→ The most important risk factor for transitional cell carcinoma (TCC) is smoking  
→ STD  
→ Endemic diseases

## Note :

- AAA : Sudden flank, orthostatic dizziness (hemorrhage)
- Use of anticoagulant ? Retroperitoneal hemorrhage
- Pleuritic chest pain ? PE, pneumonia
- Atrial fibrillation ? embolus → Renal infarction
- **Female + flank pain ? Always suspect pyelonephritis**

<b>Question</b>	<b>Stone</b>	<b>Acute Pyelonephritis</b>
<b>Site</b>	<ul style="list-style-type: none"> <li>→ Start at loin area and along with the line of the ureter could be in left</li> </ul>	<ul style="list-style-type: none"> <li>→ Sever pain in one or both lions</li> <li>→ Upper abdominal pain is unusual,</li> <li>→ most common in left flank pain</li> </ul>
<b>Onset Sudden or Gradual ?</b>	<ul style="list-style-type: none"> <li>→ Pain is sudden in onset, very and the patient is often writhing around</li> </ul>	<ul style="list-style-type: none"> <li>→ Sudden pain and increase with time</li> </ul>
<b>Character</b>	<ul style="list-style-type: none"> <li>→ Ureteric colic, it's gripping in nature</li> </ul>	<ul style="list-style-type: none"> <li>→ Pain is a dull ache heaviness and pressure</li> </ul>
<b>Radiating</b>	<ul style="list-style-type: none"> <li>→ Pain starts at lion and then radiates</li> <li>→ Downward, around the waist obliquely across the abdomen just above the inguinal ligament to the penis, the scrotum and labia</li> </ul>	<ul style="list-style-type: none"> <li>→ Pain radiation to groin area .</li> </ul>
<b>Relieving &amp; aggravating</b>	<ul style="list-style-type: none"> <li>→ The patient tries to relieve the pain by rolling around the bed</li> </ul>	
<b>Severity</b>		
<b>Associated Symptoms:</b>	<ul style="list-style-type: none"> <li>→ Sweating</li> <li>→ Hematuria</li> </ul>	<ul style="list-style-type: none"> <li>→ Headache</li> <li>→ Fever malaise</li> <li>→ Nausea vomiting</li> <li>→ Sweating .</li> <li>→ Micturition become frequent and painful(burring sensation)</li> </ul>

Done by :  
 Abdulrahman almizel  
 ahmad aldawalibi  
 Nada Alamri