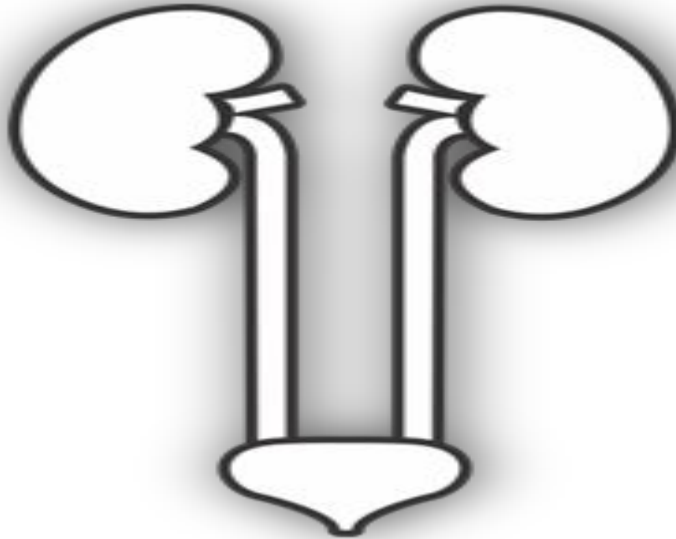

Traumatic-Emergency in Urology

Done By:

Abdallah AlBasha

Abdulaziz Alsaud

Reviewed by:

Malak Al-Khathlan,

Abdulrahman AlKaff

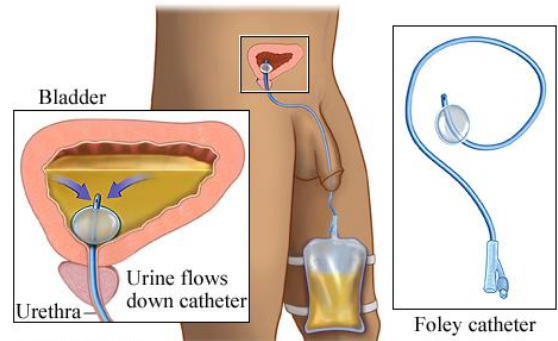
Color Index:

-Doctor's Notes -Surgery Recall -Doctor's Slides -Important -Extra

Catheters

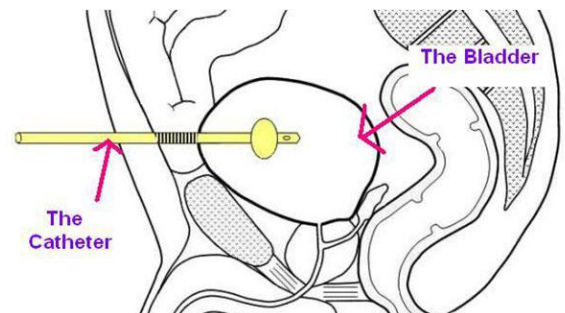
Indwelling Catheters (Foley catheter)

The catheter is held in the bladder by a water-filled balloon, which prevents it from falling out. It is suitable to remain in place for three months then it needs to be changed.




Suprapubic catheters:

Type of indwelling catheters but it will be inserted through a hole in the abdominal wall then into the bladder. Usually changed every 6-8 weeks. Of course, a problem with the urethra.



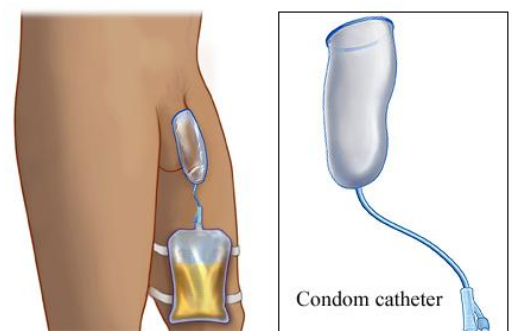
Intermittent urinary catheters (short catheter) :

These catheters are inserted several times a day, for just long enough to drain your bladder, and are then removed. When the flow of urine stops, the catheter can be removed. A new catheter is used each time.




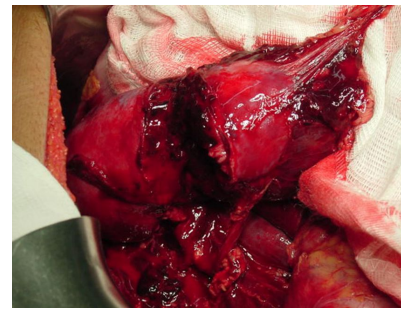
External Catheters (Condom Catheters) :

This type of catheter is typically necessary for men who don't have urinary retention problems but have serious functional or mental disabilities, such as dementia. Condom catheters need to be changed daily.



1) Renal injury:

Note :Usually renal injury lead retroperitoneal hematoma 



The kidneys, liver ,heart and lungs are by protected by thoracic cage, therefore kidneys are relatively protected from traumatic injuries. Considerable degree of force is usually required to injure a kidney.

● **Mechanism and causes:**

- A) Blunt trauma: direct blow or acceleration/ deceleration (road traffic accidents, falls from a height, fall onto flank)
- B) Penetrating: knives, gunshots, iatrogenic, e.g., percutaneous nephrolithotomy (PCNL). **The most cases of penetrating mechanism in saudi arabia due surgery.**

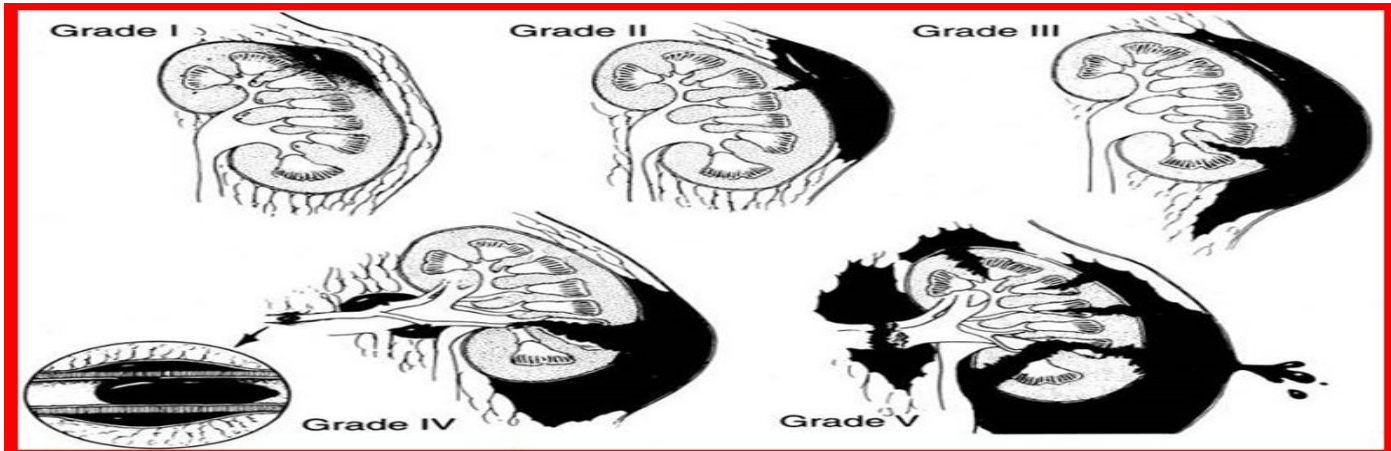
● **Indications for renal imaging:**

- A. Macroscopic haematuria (is an indication of immediate imaging process).
- B. Penetrating chest, flank, and abdominal wounds (any injury close to the kidney).
- C. Microscopic [>5 red blood cells (RBCs) per high powered field] or dipstick.
- D. Hypotensive patient (SBP <90 mmHg). (you give him a lot of fluid and no response)
- E. A history of a rapid acceleration or deceleration.
- F. Any child with microscopic or dipstick haematuria who has sustained trauma.

Modalities available

<p>1-IVU</p>	<ul style="list-style-type: none"> A. replaced by the contrast enhanced CT. B. On-table IVU if patient is transferred immediately to the operating theatre without having had a CT scan and a retroperitoneal hematoma is found (means the only indication of IVU is intraoperative in case of retroperitoneal hematoma to look for renal injury) C. Done to see if other kidney is functioning and/or exists because the injured kidney might have to be removed.
<p>2-CT scan</p>	<ul style="list-style-type: none"> • Without contrast: does not allow accurate staging. • With contrast (CT angiogram): the imaging study of choice: accurate, rapid, images other intra-abdominal structures
<p>3-Renal US</p>	<ul style="list-style-type: none"> A) <u>Advantages: (mainly to follow up after CT)</u> <ul style="list-style-type: none"> -can certainly establish the presence of two kidneys -the presence of a retroperitoneal hematoma -power Doppler can identify the presence of blood flow in the renal vessels B) <u>Disadvantages:</u> <ul style="list-style-type: none"> -cannot accurately identify parenchymal tears, collecting system injuries, or extravasations of urine until a later stage when a urine collection has had time to accumulate.

Staging of kidney injury:



Grades or stages of kidney injury

Grade I	Flank pain + Hematuria with or without pericapsular Hematoma, but no evident kidney damage.
Grade II	Injury to the cortex with hematoma only of 1cm or less.
Grade III	Injury to the cortex and medulla without reaching the collecting system with hematoma more than 1cm.
Grade IV	Injury reaching the collecting system OR thrombosis to the renal vessels. On IVU there will be extravasations of contrast and decreased filling.
Grade V	Shattered kidney completely.

Management:

A-Conservative:

Over 95% of blunt injuries

50% of renal stab injuries and 25% of renal gunshot wounds (specialized center).

• Include:

1. Wide Bore IV line. (to be ready if they need transfusion)
2. IV antibiotics. (to avoid infection)
3. Bed rest (because if there is clot and patient still move that will increase bleeding)
4. Vital signs monitoring.
5. serial CBC (HCT) (to see if there is bleeding or not)
6. Follow up US &/or CT.

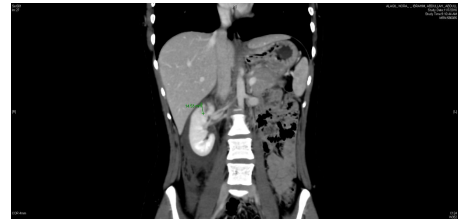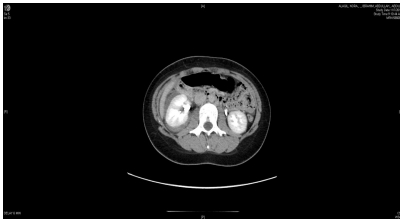Note : Most of cases of massive renal injury leads to remove of othe kidney



B-Surgical exploration:

- Persistent bleeding (persistent tachycardia and/or hypotension failing to respond to appropriate fluid and blood replacement).
- Expanding peri-renal hematoma (again the patient will show signs of continued bleeding).
- Pulsatile peri-renal hematoma.

Note : Expanding hematoma quickly and pulseatile hematoma indicate large blood vessels injury which require surgical intervention



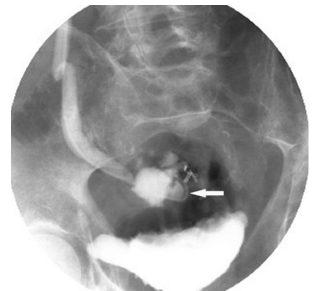2- Ureteral injury:

The ureters are protected from external trauma by surrounding bony structures (vertebral column), muscles and other organs

Causes and Mechanisms:

-External Trauma : Rare) because is very well protected

-Internal Trauma



External trauma (rare)

- Severe force is required
- Blunt or penetrating:
 1. Blunt external trauma severe enough to injure the ureters will usually be associated with multiple other injuries
 2. Knife or bullet wound to the abdomen or chest may damage the ureter, as well as other organs.

Internal trauma

- Uncommon, but is more common than external trauma
- Surgery:
 1. Hysterectomy, oophorectomy, and sigmoidcolectomy
 2. Caesarean section
 3. Ureteroscopy
 4. Aortoiliac vascular graft replacement
 5. Laparoscopic
 6. Orthopedic operations

Diagnosis: Requires a high index of suspicion, usually diagnosed **Intra-operatively** (by drainage).

Late: (suggestive of ureter injury)

1. An ileus: the presence of urine within the peritoneal cavity
2. Prolonged postoperative fever or overt urinary sepsis
3. Persistent drainage of fluid from abdominal or pelvic drains, from the *abdominal* wound, or from the vagina.
4. Flank pain if the ureter has been ligated
5. An abdominal mass (ascites), representing a urinoma
6. Vague abdominal pain

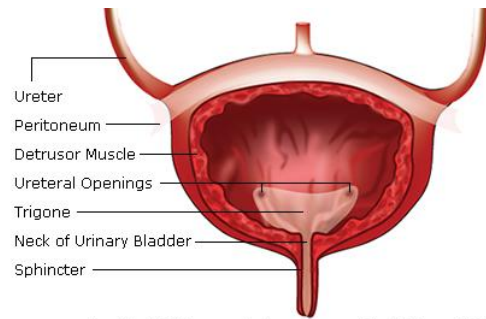
Treatment options:

- JJ stenting (putting a stent and leaving it to heal itself).
- Primary closure of partial transection of the ureter.
- Direct ureter to ureter anastomosis.
- Re-implantation of the ureter into the bladder using a psoas hitch or a Boari flap. (**The most used**) . if it is long -> directly ,but if it is short -> posts hitch
- Trans uretero-ureterostomy.
- Auto-transplantation of the kidney into the pelvis.
- Replacement of the ureter with ileum.
- Permanent cutaneous ureterostomy.
- Nephrectomy.

3- bladder injury

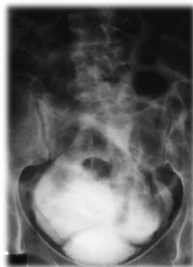Iatrogenic causes

- Transurethral resection of bladder tumor (TURBT).
- Cystoscopic bladder biopsy.
- Transurethral resection of prostate (TURP).
- Cystolitholapaxy.
- Caesarean section, especially as an emergency.
- Total hip replacement (very rare).
- Penetrating trauma to the lower abdomen or back.
- Blunt pelvic trauma associated with pelvic fracture or 'minor' trauma in a drunkard patient
- Rapid deceleration injury **seat belt injury** with full bladder in the absence of a pelvic fracture **(when the bladder is full then fasten the passenger seat belt it will cause pressure on the bladder) Mostly in female**
- Spontaneous rupture after bladder augmentation*. **(suddenly)**

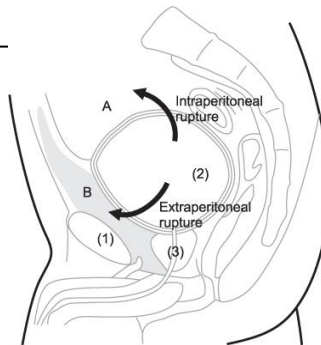


* Bladder augmentation :- Bladder augmentation is an operation to make the bladder larger. It can also lower the pressure in the bladder and make it more elastic.

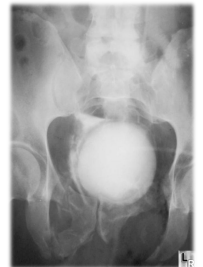Types



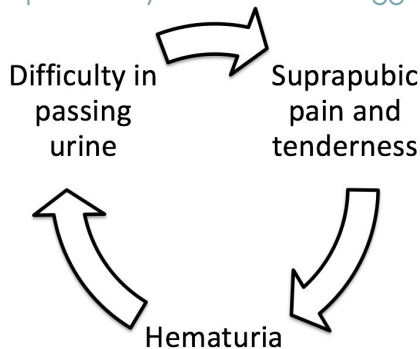
Intra-peritoneal perforation
The peritoneum has been breached, allowing urine to escape into the **peritoneal cavity**.



Extra-peritoneal perforation
The peritoneum is intact and urine escapes into the space **around the Bladder**. More common



Presentation : Recognized intraoperatively or from triad suggestive bladder injury



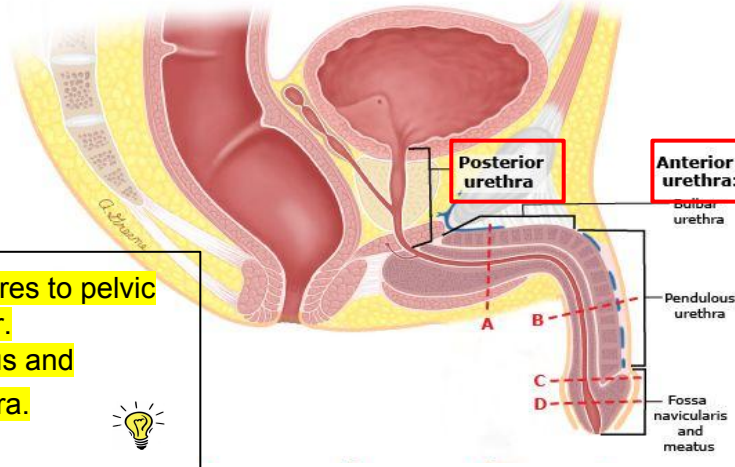
Treatment (by open repair)Why ?

- Unlikely to heal itself.
- Usually large in size
- Causes peritonitis b/c of the leakage
- Associated other organ injury. If it with trauma.

Treatment

- **Bladder drainage. (by foley catheter)**
- Open repair (surgery) is rare. If the injury persistence

4- urethral injury



Note : 1-Anterior urethra is from external structures to pelvic brim while the rest parts of urethra are posterior.
 2-In male posterior urethra involves membranous and prostatic urethra while anterior only penile urethra.



Anterior injury (rare)	Posterior injury
<ul style="list-style-type: none"> - Straddle injury in boys or men. مغامرین - Direct injuries to the penis. - Penile fractures. - Inflating a catheter balloon in the anterior urethra (before enter the bladder). - Penetrating injuries by gunshot wounds. 	<ul style="list-style-type: none"> - Mostly are associated with pelvic fractures. (because the pelvic fractures affect the membranous urethra) - 10% to 20% have an association with bladder rupture.
<ul style="list-style-type: none"> - Meatal Bleeding. - Difficulty in passing urine. - Frank haematuria. - Hematoma may accumulate around the site of the rupture. - Penile swelling. 	<ul style="list-style-type: none"> - Blood at the meatus, gross hematuria, and perineal or scrotal bruising. - High-riding prostate (which mean can't feel the prostate when doing rectal examination).
<p>Diagnostic tool Retrograde Urethrography (ascending urethrogram)</p>	

4- urethral injury cont.

Treatment

- **Contusion** → The contrast will reach to the bladder.
- (no extravasation of the contrast)

Tx :-

- Small-gauge urethra catheter for week.

- **Partial Rupture** → Extravasation of the contrast also reach to the bladder.

Tx :-

- **No blind insertion of urethral catheterization.** (may be by using cystoscopy and guide wire) **(now we use Portable Flexible Scopes in ER).**
- Use suprapubic urinary diversion for week.
- If there **penetrating parietal disruption** → **immediate repair.**



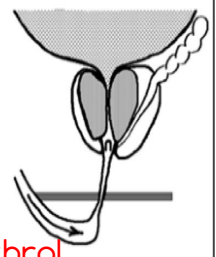
Portable flexible scopes

- **Complete rupture** → No filling of posterior or bladder.

Tx :-

- Unstable → suprapubic catheter.
- Stable → immediately repair or suprapubic catheter.
- If there **Penetrating injury**, managed by surgical debridement & repair.

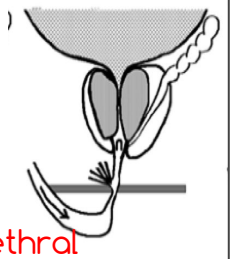
- **Type I (Rare)** → Stretch injury with intact urethra.
- (no extravasation of the contrast)



Type I

Tx :-

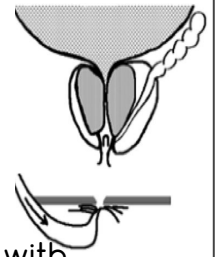
- Stenting with a **urethral catheter.** دعمات
- **Type II (25%)** → Partial tear but some continuity remains.



Type II

Tx :-

- Stenting with a **urethral catheter.** دعمات
- **Type III (75%)** → Complete tear with no evidence of continuity.
- **Risk of urethral stricture, urinary incontinence, and erectile dysfunction (ED).**



Type III

Tx :-

- Initial management with **suprapubic cystostomy** and attempting primary repair at 7 to 10 days after injury.

5- External genitalia injuries

Penile fracture

Is tear in corpora cavernosa. Eggplant deformity (مثل البطجان), during sexual intercourse or trauma.

Scrotal

Mostly in machinery workers which is rarely and easily to repair b/c of the skin surround it.

Glans injury

When doing circumcision.

Penile amputation

Need to protect yourself b/c most cases **psychotic** or crime.

Female External genitalia

Injuries Managed by Gynecologists unless the urethra is involve

Thank you

