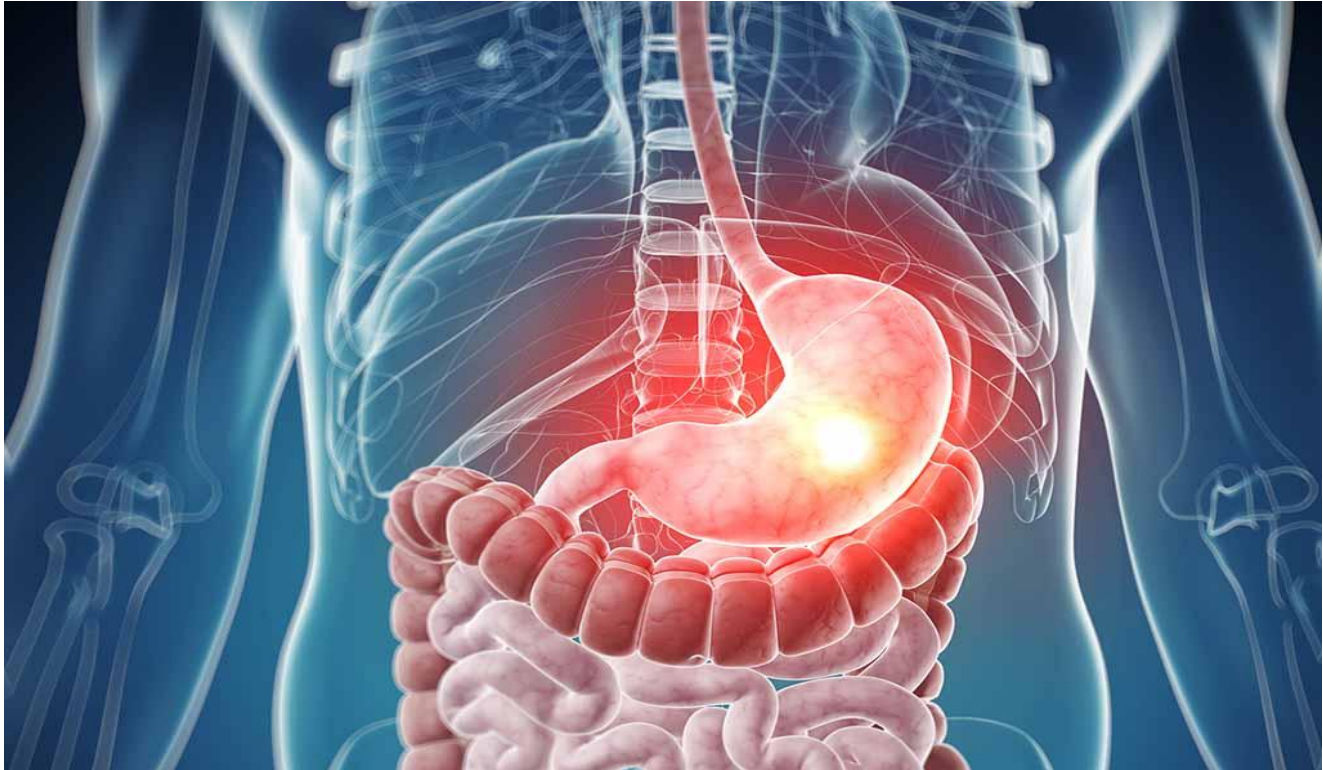



Stomach and duodenum

Done By:

Sara Julidan
Ahlam Salam

Kholud AlEnzy
Sara N.AlJasser

Reviewed by:

Omar AlRahbeeni
Reema AlRasheed

Obj:

- Definition
- Presentation
- Diagnosis
- treatment

Color Index:

-Doctor's Notes -Surgery Recall -Doctor's Slides+433 team -Important
-Extra (Davidson's notes are included)

Important notice:

- dr.Fahad said: Stomach & Duodenum anatomy and physiology are included in the examination and you need to cover it, I am not going to cover it in this presentation

	Stomach	Duodenum
Relation	<p>Partly covered by the left costal margin Anteriorly⇒ the diaphragm and left lobe of the liver. Posteriorly⇒ the stomach bed is formed by: the diaphragm, spleen, left adrenal, upper part of the left kidney, splenic artery and pancreas. The greater and lesser curvatures correspond to the long and short borders of the stomach respectively</p>	<p>The is divided into four parts, which are closely applied to the head of the pancreas...</p>
Parts	<p><u>5 parts:</u> antrum. Limited at its proximal end by the oesophagogastric junction situated just below the lower oesophageal sphincter, a <u>physiological</u> sphincter that prevents stomach contents from regurgitating into the oesophagus. a physiological sphincter, since there is no obvious thickening of muscle. The muscle in this region normally remains contracted except when swallowing Distally, the stomach is limited by the pylorus, a true <u>anatomical</u> sphincter. It is composed of greatly thickened inner circular muscle that helps to regulate the emptying of stomach contents into the duodenum. (Disruption in this sphincter could weaken this sphincter and results in Dumping)</p> <div style="border: 1px solid black; padding: 5px; margin-top: 10px;"> <p style="text-align: center;">stomach bed</p> <p style="text-align: center;">Dr. Satyen Sen Kills Patients Cruelly and Mercilessly: Dr.=left crus of Diaphragm Satyen=Splenic artery Sen=left Suprarenal gland Kills=left Kidney Patients=body of Pancreas Cruelly=left Colic flexure Mercilessly=transverse Mesocolon</p> </div>	<p>1st part⇒ is approximately 5 cm in length; its importance lies in the fact that it is the most common site for peptic ulceration to occur. 2nd part⇒ on its medial wall the ampulla of Vater, where the conjoined pancreatic duct and common bile duct deliver their contents to the gastrointestinal tract (the second most common part of the duodenum for diverticulum formation. It's the most common part of diverticulation in the whole duodenum). * 3rd and 4th parts⇒ pass behind the transverse mesocolon** into the infrasonic compartment. (the superior mesenteric artery passes in front of the third part of the duodenum, separated from it by only fat, whenever trauma occurs, this fat necrotizes, and the SMA and Abdominal Aorta squeeze the 3rd part of the duodenum, resulting in symptoms!)</p>
Blood supply	<p>The stomach has an extensive blood supply derived from the coeliac axis. When the stomach is used as a conduit in the chest, as in an oesophagectomy, the left gastric, left gastroepiploic and short gastric vessels are divided, and the stomach then relies on the right gastric and right gastroepiploic vessels for viability. Ischaemia does not usually result because of the free communication between the vessels supplying the stomach.</p>	<p>The superior and inferior pancreaticoduodenal arteries (from the gastroduodenal artery and SMA respectively</p> <p>*The most common site for diverticula is the sigmoid colon) **the peritoneal process attaching the colon to the posterior abdominal wall</p>

There are 5 parts of the stomach:

1-cardia (even though it distal esophagus, we consider it a part of stomach too) the first part of the stomach ⇒ when this part due to GERD or any other cause undergoes metaplasia ⇒ we call it Barret's esophagus.

2-fundus

(a non-secretory function)

it's important for its physiological function. If it's distended with gas, we will feel hunger

(a secretory function) ⇒ parietal cell= HCL and intrinsic factor secretion

3-body storage + acid production + digest food.

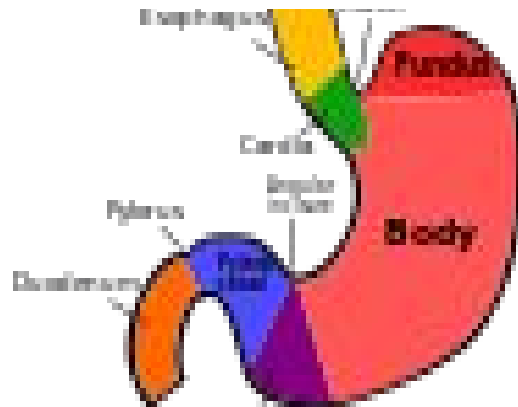
4-antrum it has two functions:

a-Contractility of the muscles

b- G-cells secrete gastrin hormone into the blood

(how do you surgical treat an ulcer related to high acid production? **Antrectomy** (Removal of stomach antrum) or **vagotomy** by removing the nerve supplies of the cells)

5-pylorus(door or gate) if we lose pylorus → dumping syndrome



We need to know that any part of the stomach has:

1-Secretory function (such as secreting of intrinsic factor)

2-Non-secretory function (we feel hungry after the fundus is filled with air)

-Parietal (oxyntic) cells secrete:

1-HCL 2-intrinsic factor.

We can find these cells in the lining of fundus and body.

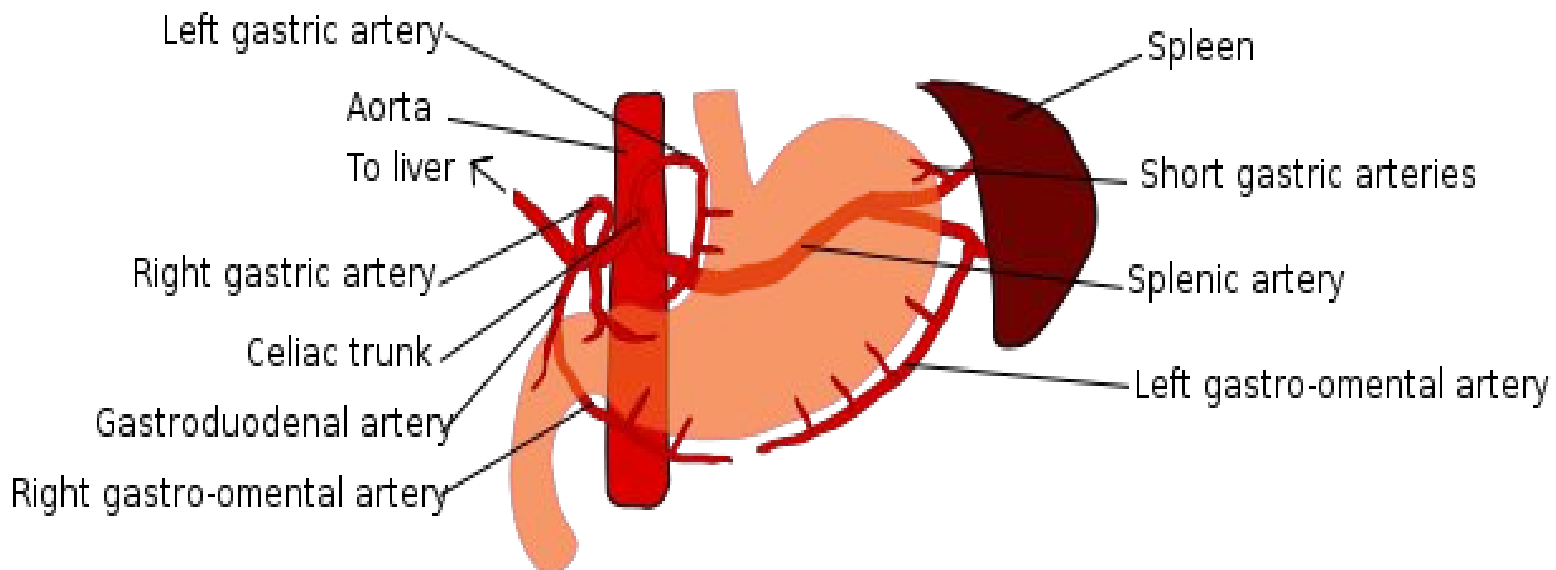
-Parietal cells produce acids by 3 mechanisms (the parietal cells is stimulated by):

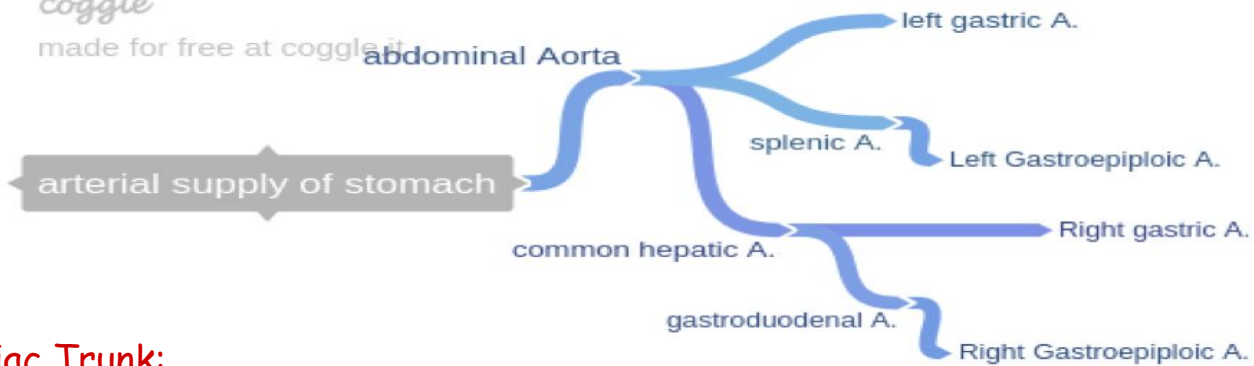
1-Hormonal (gastrin from g-cells in the antrum)

2-Neurogenic (Vagus nerve)

3-Direct

It is important to know the blood supplies





Celiac Trunk:

1) Common Hepatic Artery

- Right gastric artery
- Gastroduodenal artery → Right gastroepiploic , Superior Pancreaticoduodenal.

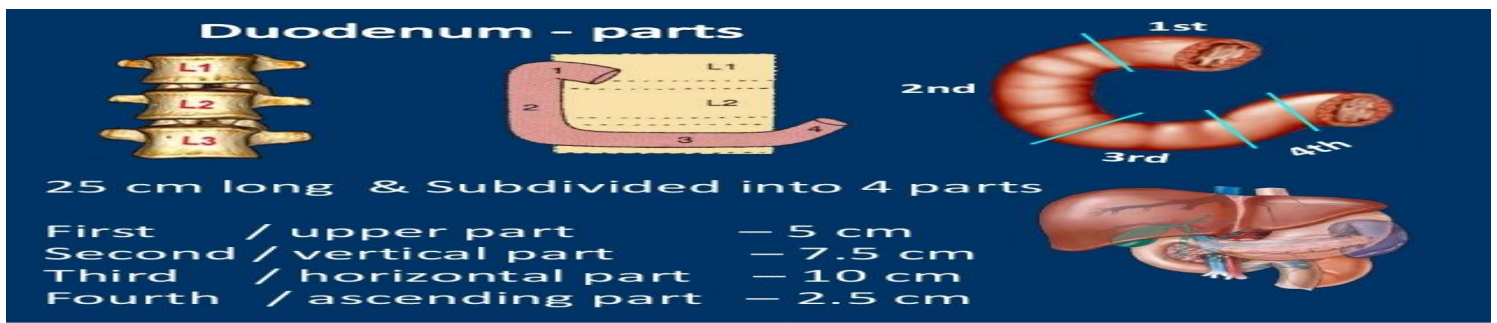
2) Left Gastric Artery

3) Splenic Artery

- Short Gastric Arteries (passing in the gastrosplenic ligament)
- Left gastroepiploic artery
- Pancreatic Branches

**So, now that you've recapped the arterial branches
let's know what each branch supplies**

Artery	Branch	Supply
Celiac Trunk	Left Gastric	Esophageal branches
Splenic Artery	Left Gastroepiploic	Supplies the greater curvature of the stomach. Anastomoses with the right gastroepiploic artery.
Splenic Artery	Short Gastric Arteries	5-7 small branches supplying the fundus of the stomach.
Splenic Artery	Pancreatic Branches	supply the body and tail of the pancreas.
Proper Hepatic	Right Gastric	supplies the pylorus and lesser curvature of the stomach.
Gastrododenal Artery	Right Gastroepiploic	supplies the greater curvature of the stomach. Found between the layers of the greater omentum, which it also supplies.
Gastrododenal Artery	Superior Pancreaticoduodenal	divides into an anterior and posterior branch, which supplies the head of the pancreas.



25 cm long & Subdivided into 4 parts

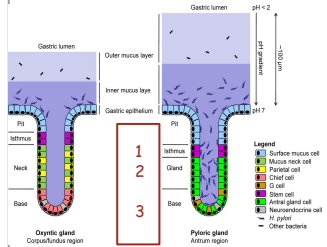
- First / upper part — 5 cm
- Second / vertical part — 7.5 cm
- Third / horizontal part — 10 cm
- Fourth / ascending part — 2.5 cm

We have to know the anterior vessels of the 3rd part of duodenum.

Why? Superior mesenteric artery syndrome → the duodenum get compressed by two arteries aorta (posteriorly) and superior mesenteric artery (anteriorly)

Types of Glands in the stomach ⇒ the dr did not mention but it's better to go through it

Layar of glands	Name	Secretion	Region	Stain
1. Isthmus of gland	Foveolar cells	Mucus gel layer	Fundic, cardiac, pyloric	Clear
2. Body of gland	Parietal (oxyntic) cells	Gastric acid and intrinsic factor	Fundic only	Acidophilic
3. Base of gland	Chief (zymogenic) cells	Pepsinogen and gastric lipase	Fundic only	Basophilic
	Enteroendocrine (APUD) cells	Hormones gastrin, histamine, endorphins, serotonin, cholecystokinin and somatostatin	Fundic, cardiac, pyloric	—



-Mucus is produced by all regions of the stomach. It is composed mainly of glycoproteins, water and electrolytes, and serves two important functions. It acts as a lubricant, and it protects the surface of the stomach against the powerful digestive properties of acid and pepsin. Bicarbonate ions are secreted into the mucus gel layer and this creates a protective buffer zone against the effects of the low pH secretions. Alkaline mucus is produced in the duodenum and small intestine, where it has a similar function of mucosal protection.

-The parietal cells in the stomach are responsible for the production of acid. Acid secretion by these cells is stimulated by two main factors: acetylcholine, released by the vagus nerve, and gastrin from the antrum. Acetylcholine and gastrin act on neuroendocrine cells located close to the parietal cells. On stimulation, these cells release histamine, which has a paracrine action on the parietal cell, stimulating acid production and secretion. Parietal cells secrete acid via an active transport mechanism, the proton pump. Somatostatin, gastric inhibitory peptide and vasoactive intestinal peptide inhibit acid secretion.

-Pepsin is a proteolytic enzyme produced in its precursor form, pepsinogen, by the peptic cells (chief cells) found in the body and fundus of the stomach. Pepsinogen production is stimulated by acetylcholine from the vagus nerve. The precursor is then converted to its active form, pepsin, by the acid contents of the stomach.

-Intrinsic factor is also produced by the parietal cells. It is a glycoprotein that binds to vitamin B present in the diet and carries it to the terminal ileum. Here specific receptors for intrinsic factor exist and the complex is taken up by the mucosa. Intrinsic factor is broken down and vitamin B is then absorbed into the bloodstream.

Common Presentation

- **Pain:** site (**epigastric**) one of the differential diagnosis is stomach and duodenum (could be liver, gall bladder, heart, pneumonia, skin and could be related to retroperitoneal structure aneurysm)

1- ULCER DISEASE

2- PERFORATION

Very common presentation of epigastric pain is ulcer, could be pancreatitis, acute cholecystitis and ischemic heart disease.

- **Bleeding:**
(FIVE CAUSES)

Table 13.2 Causes of upper gastrointestinal bleeding.

● Peptic ulceration	50%
● Mucosal lesions including gastritis, duodenitis and erosions	30%
● Mallory-Weiss tear	5–10%
● Varices	5–10%
● Reflux oesophagitis	5%


- **Vomiting:**
OBSTRUCTION

Atypical presentation

- palpable mass
- coughing

Peptic Ulcer 'Old definition'. Peptic=acid

- ❖ Esophagus
- ❖ Duodenum
- ❖ Stomach
- ❖ Jejunum after surgical construction of a gastrojejunostomy → **Anastomosis created between stomach and upper loop of jejunum**
- ❖ Ileum in relation to ectopic gastric mucosa in Meckles diverticulum



Peptic Ulcer, Cont.

- Men are affected three times as often as women
- Duodenal ulcers are ten times more common than gastric ulcers in young patients
- In the older age groups the frequency is about equal



there are other questions to be sure if it's duodenal or gastric ulcer:

Related to food:	If there is a pain → gastric (produce more acid)	If the pain relieved → duodenal ulcer
Related to weight:	Increased weight → duodenal.	Decreased weight → gastric

Why are we worried more about gastric ulcer?

Because there is more chances of developing a cancer than in duodenal ulcer.

- ❖ We have to do something before scope? X-ray (eric X-ray).

If we suspecting a perforation → never do a scope

If no free air under the diaphragm shown in the x-ray → we can do scope

- ❖ When we do scope and we find gastric ulcer we need a biopsy to rule out cancer.
- ❖ If we found a duodenal ulcer there is no need of a biopsy (most likely a H.pylori)
- ❖ What are the possible consequences of PUD? Pain, hemorrhage, perforation, obstruction



DUODENAL ULCER

- ❖ Epigastric area, mid-day, noon, night
- ❖ Relieved by food
- ❖ Normal or increased acid secretion
- ❖ Common in young - middle age male
- ❖ smoking, NSAIDs, uremia, Z-E syndrome, trauma, burn injury
- ❖ 95% in duodenal bulb (2cm)
- ❖ 90% principle cause is *H pylori* (GNCB aeroph)

★ We need to understand that duodenal ulcer is not always related to high secretion of acid it could be normal and we have ulcer (*H.pylori*)

★ common is common

-1ST part of duodenum is common for ulcer

-2nd part of duodenum is common for obstructive jaundice

-3rd part of duodenum is common for superior mesenteric artery syndrome (SMAS)


GASTRIC ULCER

- ❖ Epigastric area pain
- ❖ Increase by food
- ❖ Common in 40-60 years male
- ❖ 95% along lesser curve, (where is the Incisura)
- ❖ Types :
 - Type 1 : in incisura angularis & normal acid
 - Type 2: prepyloric and DU 'Duodenal ulcer' & high acid Angularis duodenal
 - Type 3: antrum duo to NSAID
 - Type 4: at GEJ Gastroesophageal junction

3 criteria of *H. pylori*:

- 1-gram -ve
- 2-coccobacillus
- 3-aerophilic (in stomach)

MEET A SECRET
BACTERIA TERRORIST:
H. pylori



Diagnosis

Clinical → history and physical examination

- Epigastric area pain and tenderness

Investigation:

1. Non-specific -	(CBC : anemia, liver function, platelets count, etc...)
2. Specific for stomach and duodenum 'gastroscopy':	EGD Upper endoscopy (EsophagoGastroDuodenoscopy) → modality for finding an ulcer: <u>1-treatment:</u> if there is a complication. <u>2-diagnosis.</u> <u>*contraindications of Endoscopy:</u> Anyone came with acute abdomen, trauma, bleeding or comatose. How to manage the patient? ABC, next I will take a brief history. Then I'll do an endoscopy "When I'm sure there is no acute abdomen (tender or rigid)"
3. Ultrasound and CT scan	are used later and for specific disease.
Gastric analysis (basal vs maximal)	measuring acid by using a nasogastric tube and we aspirate the secretion from the stomach to know the concentration of the stomach contain (we don't need to have a high acid secretion to get ulcer). Do we need for every case? (No) any case of ulcer diagnosis is clinical 'like hernia', if I'm doubting I may use scope.
4. Gastrin serum level (severe or refractory)	
5. Contrast meal (show complication)	*typical symptoms clinical exam → start treatment -doubting or persistent symptoms → scope abnormality → gastrin level -sometimes we need contrast (barium): -Contrast Swallow (esophagus) -Contrast meal (to show esophagus and stomach) -Follow through contrast (to show the small bowel)

Treatment

1-modification of lifestyle (such as: quitting smoke or stop drinking tea and coffee)

2-start to reduce the acid, and there is hormonal part, neurogenic part and direct part

3-Medical Treatment (80% in 6 weeks)

-H2 antagonists (zantac.....) (inhibiting the vagal nerve) but still the hormonal & the direct part are working. "partial treatment"

-H1 (throat=respiratory tract, and brain) if someone come with congested throat and we give him an antihistamine he can't drive.

-H2 can't affect the brain so the patient can drive

- Proton pump inhibitors (omeprazole.....) the best treatment

PPI→block the **ACTIVE** secretion of hydrogen ions into the stomach so it can't combine with chloride ions in the stomach lumen to form gastric acid.

- H.pylori eradication (amoxicillin , clarithro..) When there is duodenal ulcer add H.pylori treatment **MOC** or **ACO** 2-week antibiotic regimens:

MOC: Metronidazole, Omeprazole, Clarithromycin (think: **MOCK**) or **ACO: Ampicillin, Clarithromycin, Omeprazole**

4-Surgical Treatment

1. Vagotomy (block the neural stimulation)
2. Antrectomy and vagotomy
3. Subtotal gastrectomy=**75% of stomach removed**

We need to do surgery? (No!!) except if there is a complication (it will lead into complication, so having the pain is much better)

Complications of surgery for peptic ulcer

- Early Complications (leakage, bleeding, retention)

- Late Complications

1. Recurrent ulcer (marginal ulcer, stomal ulcer ,anastomotic ulcer).
2. Gastrojejunocolic and gastrocolic fistula.
3. **Dumping syndrome**, If I lose my pylorus the food will go immediately to the small bowel without digestion and it will be in high concentration.
4. Alkaline gastritis it occurs most often after gastric surgery in which function of the pyloric and lower esophageal sphincter is compromised. Reflux of bile in these patients can then lead to severe inflammation of the gastric and lower esophageal mucosa.
5. **Anemia** (Iron defi and vitB12).
6. Postvagotomy diarrhea, it is Diarrhea after a truncal vagotomy.
7. Chronic gastroparesis is a condition in which the spontaneous movement of the muscles (motility) in your stomach does not function normally.

Two types of dumping:

1-Early(rapid) dumping:

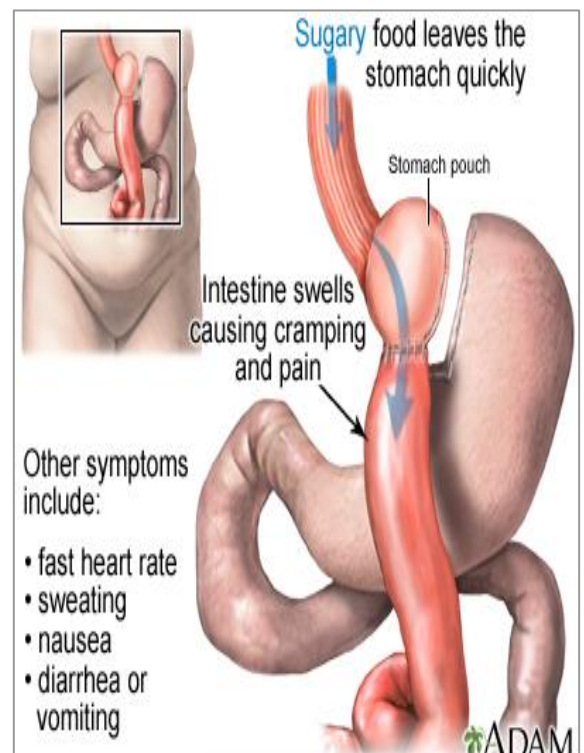
(hypovolemia) high concentration →
absorb water →hypovolemic →
what will happened to the patient?

He will feel lightheadedness and

laziness

2-late dumping:

(due to hypoglycemia) when the food arrives
at the duodenum the pancreas secretes
a large amount of insulin (because the
pancreas was surprised and doesn't
know about the amount of the food).



- You will give an anti-acid treatment (iron becomes active in acidic media) ferric Fe^{3+} → ferrous Fe^{2+} . So if the acid becomes in low concentration, the iron will not be reduced and it will not be absorbed → it will pass out in the stool → iron deficiency anemia
- A special protein, called intrinsic factor (IF), helps your intestines absorb vitamin B12. This protein is released by cells in the stomach. When the stomach does not make enough intrinsic factor, the intestine cannot properly absorb vitamin B12
- How to differentiate between iron deficiency anemia & B12 deficiency anemia? By CBC

Normal MCV is around 80 → if it is below (micro) → iron deficiency anemia

More than 100 (macro) → B12 deficiency anemia

Zollinger-Ellison Syndrome (Gastrinoma → G-cell tumor).

-Gastrin is in the antrum of stomach, first part of duodenum and head of pancreas
 -Atypical presentation of an ulcer

- Peptic ulcer disease (often severe) in 95%.
- Gastric hypersecretion.
- Elevated serum gastrin.
- Single one is malignant.
- Multiple is benign (MEN 1).
- GASTRIN LEVEL IS MORE THAN 500 pg/ml.
- CT Scan, somatostatin scan.
- Portal vein blood sample.
- severe pain
- treatment for 6 weeks with no response
- by scope we will find massive ulceration.
- Next I have to do gastrin level → high → immediate CT scan.
- Second I have to be sure that it isn't part of any other syndrome (MEN 1) it's affecting pancreas, parathyroid and thyroid (benign)
- If it was a single gastrinoma and it wasn't a part of a syndrome → malignant

Diagnosis	Treatment
<ul style="list-style-type: none"> • Epigastric tenderness • EGD • Contrast swallow 	<ul style="list-style-type: none"> • Medical Treatment • Surgical Treatment gastrectomy

Ulcer complication (Perforation):

1. Perforated peptic ulcer

- Sudden, Severe, Steroid-related diffuse abdominal pain.
 - Patient can't breath(or shallow breathing), talk (and this the first attack) but he was known of having an ulcer before this attack.
 - Pulse is high and pressure is low →this calls a shock
 - Presents as Acute Abdomen clinical Syndrome (Rigidity VS Guarding).
 - Mangement is ABC, then, NPO Nil per os/ nothing by mouth , IVF IV fluid , NGTNasogastric tube , FC, and **erect** abdominal X-ray (**NEVER DO EGD**)
 - Definitive one is surgical repair (Graham patch) **Piece of omentum incorporated into the suture closure of perforation.**
 - I will do abdominal x-ray (never scope or CT if there free air)
 - Treatment OR (any air under the diaphragm is OR)
 - Locate **anteriorly** (Usually perforated) in the duodenum.
 - **Where is the part which usually bleed?** Posteriorly. **Why?** Because there is the gastroduodenal artery behind the 1st part of the duodenum
 - **How is a bleeding duodenal ulcer surgically corrected?** Opening of the duodenum through the pylorus Oversewing of the bleeding vessel.
 - High risk : female, old age, gastric one.
 - Acute presentation:
- X-ray:** Free air (85%) & fill 400 cc air by NGT
- Treatment: NGT, ABS(antibiotic), Surgery

2. Ulcer complication (Obstruction):

- Symptoms are Vomiting, +/- weight loss, **not bilious**-color.
- *Vomiting → one of the diagnosis is **obstruction** but we don't know where it is? How I will differentiate?

By knowing the associated symptoms

- Is he started by vomiting or not?
Obstipation "severe constipation" then it developed into distension with colicky pain after that vomiting.
- Do you think it is the colon or the stomach and duodenum? Colon (obstipation or constipation)
- Clinically: no abdominal distension if it was stomach and duodenum "not colon", **gastric splash**.
- **Diagnosis** : ch. History, non-cooperative pt, smoker.
- **Investigation**: abdominal X-ray, EGD **where is the obstruction** → to take a biopsy or to dilate it, **contrast swallow**.

It is only obstruction when you do x-ray and you will not find fluid level

Fluid level is that you do an x-ray while standing and because of the gravity the fluid will pull down and distend the stomach while the gas will be shown up ⇒ > more than 4 fluid levels indicates obstruction.

What x-ray will you do? Abdominal x-ray. **Which type?** Erect

If the patient is intubated? We will stand the bed or the patient will take an x-ray on the lateral position

What is the color of the vomit? White colorless(stomach) or green (duodenum and could be from the small bowel)

Fermented food vomiting → large bowel

- **Treatment**: R/O malignancy, possible resection vs bypass

3. Upper GI Hemorrhage (Bleeding)

what is it? Bleeding into the lumen of the proximal GI tract, proximal to the ligament of Treitz

- **Hematemesis** "coffee-ground emesis".
- **Melena** Melenic stool (melanotic is incorrect) 'Black, tarry feces'
we need > 50 cc of blood to have melena
- **hematochezia** 'Passage of fresh blood through anus'.
 - ↳ First diagnosis is upper GI bleeding
- syncope, shock, fatigue, coffee-ground emesis, epigastric discomfort, epigastric tenderness, signs of hypovolemia, guaiac-positive stools

-If someone came with hematemesis and after the ABC we insert NGT and the blood appeared (from the stomach) → upper GI bleeding.

-If we insert NGT and it shows gastric juice and bile → a lower GI bleeding.

Causes of massive upper gastrointestinal hemorrhage

Causes	Relative Incidence	
<ul style="list-style-type: none"> Common causes: <ul style="list-style-type: none"> peptic ulcer most common Duodenal ulcer Gastric ulcer Esophageal varices Due to portal hypertension Gastritis Mallory-Weiss syndrome Uncommon causes: <ul style="list-style-type: none"> Gastric carcinoma Esophagitis Pancreatitis Hemophilia Duodenal diverticulum 	45% 25% 20%	20% 20% 10% 5%

Causes of massive upper GI hemorrhage "as the doctor said"

1-peptic ulcer

2-esophageal varices

3-mallory-weiss syndrome

4-gastric carcinoma

5-Dieulafoy lesion (is a medical condition characterized by a large tortuous arteriole most commonly in the stomach wall (submucosal) that erodes and bleeds)

- If a Bleeder came:

1-ABC 2-brief history ulcer+NSAIDs/Liver disease → esophageal varices

3-gastroscope (diagnostic & treatment), Hemoglobin and coagulation profile

- How can I control a bleeder by gastroscopy? **5 maneuver**

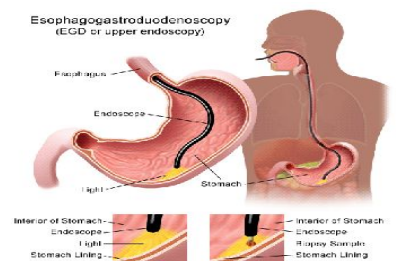
1-catheterization 2-ligation (banding) 3-clipping 4-inject scleroting agent

These are **4** inside by endoscopy

If we fail endoscopy we can use it by angio and do 5-embolization (Entering the vessel not the lumen of the GI)

The only maneuver we don't use it in portal HTN is catheterization. **Why?** Because the portal is a vein

It's already dilated because of the pressure so why we trying to add more pressure?



Mallory-Weiss Syndrome.

- 10% of UGIB
- *most common site :1-4cm longitudinal tear in gastric mucosa at EGJ (* 1-4cm longitudinal tear in lower esophagus or proximal cardia injury or in gastric mucosa at EGJ most common → due to Forceful vomiting.)
- Forceful vomiting
- EGD
- 90% bleeding stops spontaneously by cold gastric wash(vasospasm),
- EGD- cautery, surgery

Manage: stabilize the patient state with ABC and brief history then scope (EGD) 90%bleeding stops spontaneously by cold gastric wash, some times you can EGD- cautery if it small , but if it is continue to bleed taking to OR for surgery (open the stomach and suturing).

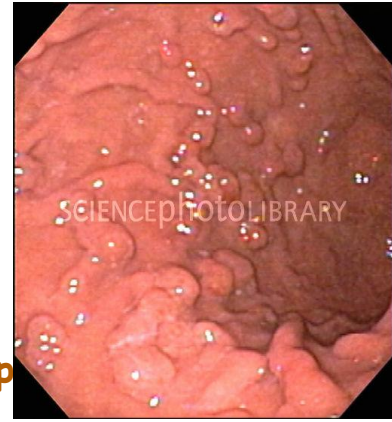
- Scenario : young patient arrive to ER with first forceful vomiting with retching 3rd time vomiting blood happen when he start to drink → typical MALLORY-WEISS SYNDROME

Stress Gastroduodenitis, Stress Ulcer & Acute Hemorrhage Gastritis:

- Stress Ulcer -----shock &sepsis
- Curling's ulcers-----burns
- Cushing's Ulcer ----CNS tumor, injury (more to perforates, high acid production
- Acute Hemorrhagic Gastritis

Gastric Polyps.

- Affecting distal stomach
- 95% Presentation is mainly incidental finding , rarely by **anemia**, 99% asymptomatic which is common and 1% symptomatic.
- EGD: diagnosed by **endoscopy (EGD)** → **remove the polyp and do biopsy to see the type of polyps pathology.**

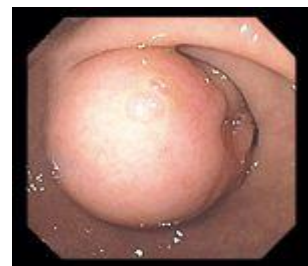

types:

- Hype- plastic.
- Adenomatous (Premalignant) - it is the most serious so need follow up.
- Inflammatory.
- Hamartomatus .
- R/O malignancy → if the the patient symptomatic like bleeding or present by malignant → you need resect it .

Gastric Leiomyomas.

- Common submucosal growth
- Incidental finding, 90% Asymptomatic & less than 1% massive bleeding
- EGD & C T Scan
- Do not biopsy
- Surgical wide excision

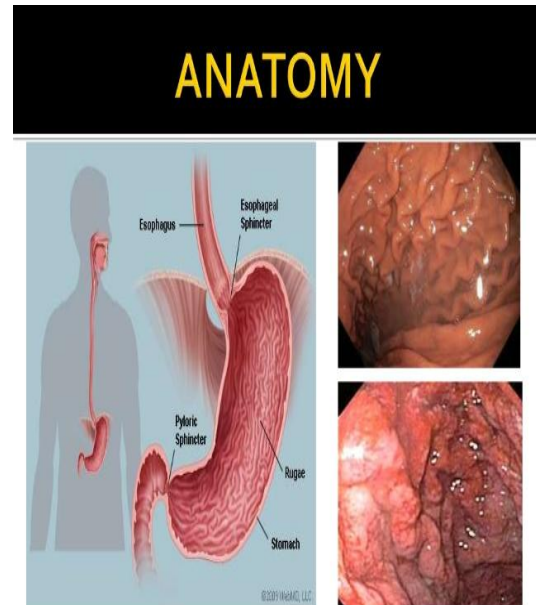


- Scenario :Patient come to you with mild epigastric pain you give him medication of ulcer and the pain still and he feel unwell you do the scope the mucosal normal but there something push it from behind most likely→ **GASTRIC LEIOMYOMAS** is benign tumor of smooth muscle of the stomach (extra info the benign tumor of the skeletal muscle rhabdomyoma) → Do not take biopsy (the capsule will break) leave it capsulated → do Surgical wide excision

Menetrier's Disease.

due malnourishment ** (sometimes we think of small and large bowel and forget the stomach in malnourishment) so after investigation we will see normal bowel so we will do further scope to stomach and we find it indirectly .

- Giant hypertrophy of the gastric rugae (4-6 mm), the antrum is usually spared.
- Present with hypoproteinemia (hypoalbuminemia)
- Edema, diarrhea, weight loss, K^+ loss .
- Treatment : atropine (to reduce the secretion) , omeprazole, H.pylori eradicationrarely is gastrectomy (If the patient still has symptoms)



Prolapse of Gastric Mucosa.

- Occasionally accompanies small gastric ulcer
- Vomiting and abdominal pain
- X-ray : antral folds into duodenum
- Antrectomy with Billroth 1

Incidental finding when you are doing scope and you go to ampulla because the obstructive jaundice and you see the antrum mucosa prolapse to duodenum like hemorrhoid treatment resect if there is obstruction if not otherwise leave it because the variation

Gastric Volvulus. emergency

Benign disease, but lethal (can lead to death)

1-(organo-axial volvulus):

patient can not vomit, (□ 360 degree rotation of stomach (you need to reversed immediately by take him to the OR)

- More common and sever it can perforate and lead to ischemia in the stomach)

- Its longitudinal axis
- More common
- Associated with HH

2-(mesenterioaxial volvulus):

- Transverse axis
- Line drawn from the mid lesser curvature to the mid greater curvature - Associated with vomiting (obstruction)

*Present with : Severe abdominal pain and

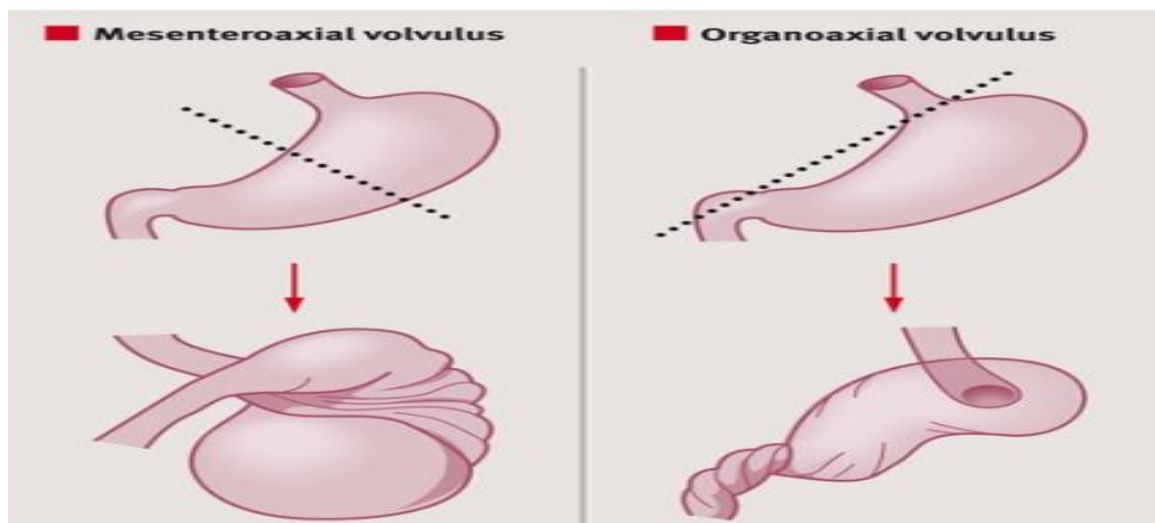
*Brochardt"s triad: (Vomiting followed by retching and then inability to vomit ,Epigastric distention ,Inability to pass a nasogastric tube).

How to differentiate between the *GASTRIC VOLVULUS* and Perforation ??

by history high index of suspicions come with severe epigastric pain → ask the patient did you vomit he said I try but I cannot that → so you notice severe retching with Epigastric distention and Inability to pass a nasogastric tube → this is called Brochardt"s triad of *GASTRIC VOLVULUS*

**Diagnosis: Confirmed by a Ground Glass appearance on X-Ray

**Management : If diagnosed, we should immediately take him to the OR

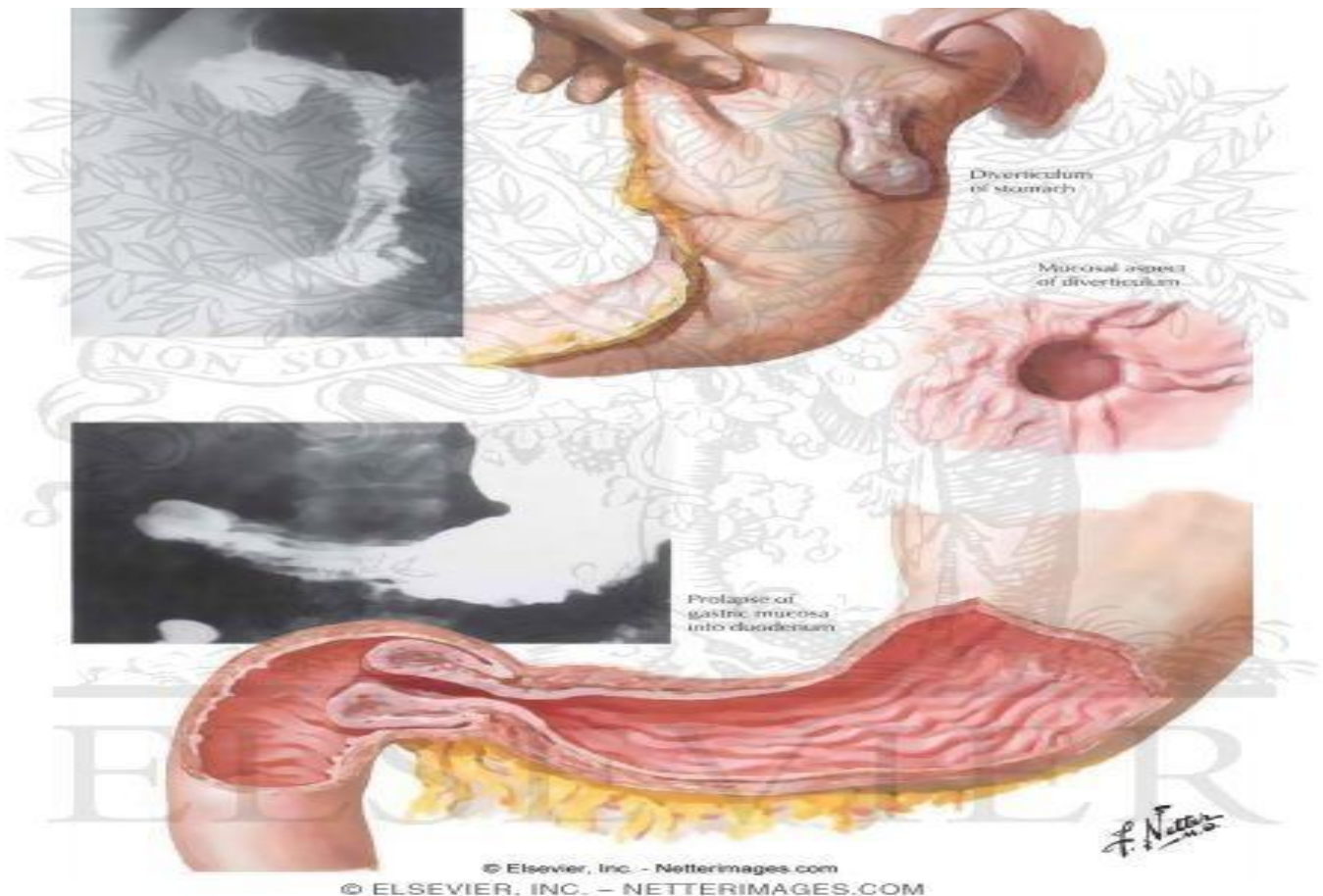


Gastric Diverticula.

- Uncommon
- Asymptomatic (Incidental finding) malnourishment due to bacterial in gut
- Weight loss, diarrhea
- EGD, X-ray (barium meal examination,)
- surgery?? (next page)

DIVERTICULA: any organ have lumen cover from in to out side(mucosa-muscle -serosa) flat normal if the pulging out or swelling from all the layers (called true diverticula) if it only mucosa (called false diverticula)

** stomach and duodenum diverticula most likely true diverticula .



For further understanding in Diverticula:

Soft diet:

There is no specific treatment plan for an asymptomatic diverticulum. The appropriate management for a symptomatic GD depends mainly on the severity of the presenting complaints.[1]. Soft diet, antacids, antispasmodics, and proton pump inhibitors have all been reported to relieve symptoms.[2].

Proton pump inhibitors (PPI):

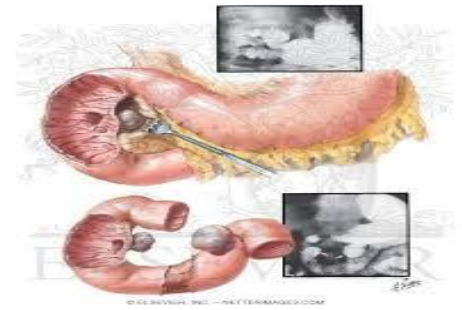
Medical treatment with thorough evaluation for other gastrointestinal pathology should be the first line of therapy for suspected symptomatic gastric diverticula.[2]. Proton pump inhibitors therapy for few weeks is reported to resolve the symptoms in proven cases of GD. However it is important to note that this does not resolve the underlying pathology. Some studies report that patients presented again with refractory symptoms of dyspepsia and worsening epigastric pain that did not settle with either proton pump inhibitors or histamine receptor blockers .[1].

Surgical resection:

is recommended when the diverticulum is large, symptomatic or complicated by bleeding, perforation or malignancy. Both open and laparoscopic resection yield good results. The laparoscopic approach has been described by different authors. The most favourable approach that provides the necessary exposure is by placing the ports in a similar fashion to laparoscopic Nissen fundoplication. This includes a midline port, right upper quadrant, and 2 left upper quadrant ports. The laparoscopic dissection has been performed by either releasing the gastrocolic/gastrosplenic ligament or by mobilizing the short gastric vessels, thus gaining exposure of the superior posterior wall of the stomach. The latter is the most frequently used approach. Because all diverticula were true and located in the gastric fundus, the most direct approach was by taking down of the short gastric vessels. Simple resection of the diverticulum with a laparoscopic cutting stapler was reported to be successful

Duodenal Diverticula.

- 20% OF POPULATION
- Asymptomatic → (incidental finding)
- 90% medial aspect of the duodenum (2nd part of the duodenum is the most common site in the GI tract)
- Rare before 40 years of age
- Most are solitary and 2.5 cm peri-ampullary of vater (It can cause obstruction, bleeding and inflammation)

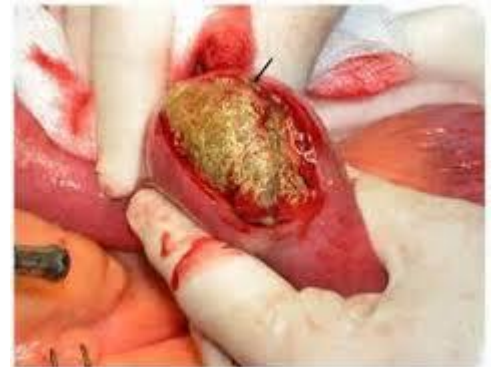

**If it's asymptomatic, we leave it.

**If there is superficial cancer (overgrowth, we excise it.

Bezoar.

- Concretions formed in the stomach → (Retained concretions of indigestible foreign material like food particle in the stomach or foreign Body in the stomach)
- Types:
 - Trichobezoars: hair (like in psychic patient)
 - Phytobezoars: vegtab
- Presentation by obstruction → vomiting
- EGD, X-RAY (Barium examination)
- Surgical Removal



**what is the cause of the obstruction(foreign Body, tumor and fibrosis) or by scientific word (intra-luminal,through the wall and external)

Superior Mesenteric artery obstruction of the duodenum.

- Obstruction of the third portion of the duodenum
--compression SMA and Aorta
- Appears after rapid weight loss following injury
- Distance between two vessels is 10-20 mm
- Proximal bowel obstruction symptoms and signs
- CT Scan
- bypass

**3rd part of Duodenum between SMA anteriorly and Aorta posteriorly .

HOW the SUPERIOR MESENTERIC ARTERY OBSTRUCTION happen??:

Fat is the only thing that lies between the duodenum and the SMA.

So when a person is cachexic and chronically ill, the fat will diminish and this will bring the duodenum and SMA closer to each other, leading to the obstruction.

** how are the presentation will be → someone with RTA after ABC admitted in ICU the second month in ICU the patient start sudden lose of weight he was 100 kg and now he 60 kg and the nurse tell you when she start to feeding him the patient start to vomit → hat mean SUPERIOR MESENTERIC ARTERY OBSTRUCTION.

Benign Duodenal Tumors.

- Brunner's gland adenomas
- Carcinoid tumors
- Heterotopic gastric mucosa
- Villous adenomas

Regional Enteritis Of The Stomach & Duodenum.

- Food poisoning
- Pain and diarrhea
- Clinical DX
- observation

Peptic Ulcer.

From Davidson (180-191)

- Peptic ulceration affects areas of mucosa exposed to acidic gastric contents. The main pathology is an imbalance between the acid-pepsin system and the mucosal ability to resist digestion.
- Duodenal ulcers may be acute (Fig. 13.17) or chronic. Ulcers with a history of less than 3 months' duration and with no evidence of fibrosis are considered to be acute. Gastric ulcers generally run a chronic course.

In gastric ulcer, it seems that the key factor is decreased mucosal resistance, with excess acid having less of a role. Indeed, most patients with gastric ulceration have a normal or decreased secretory capacity.

- **Aetiology:**

- 1-Helicobacter pylori:**

It infects the mucosa of the antrum of the stomach, where it causes an inflammatory response. This gastritis stimulates the gastrin-producing (G) cells of the antrum to increase gastrin production. The subsequent hypersecretion of acid provides an ideal environment for gastric metaplasia of the duodenal mucosa to occur. The colonization of the metaplastic areas by *H. pylori* further damages the mucosa, and ultimately duodenal ulceration occurs.

- 2-Nonsteroidal anti-inflammatory drugs (NSAIDs):**

Their role as anti-inflammatory agents centres on their inhibition of prostaglandin synthesis by inhibiting the action of cyclo-oxygenase. In the stomach, prostaglandins are responsible for the production of mucus and bicarbonate. These both help to protect the stomach mucosa from acid by maintaining an alkaline buffer zone. By inhibiting prostaglandin synthesis, NSAIDs damage the gastric mucosa and are implicated in 30% of gastric ulcers. They may also be responsible for the small number of *H. pylori*-negative duodenal ulcers.

Other factors

Other patients at risk of peptic ulceration include those with blood group O and those with hyperparathyroidism. Hyperparathyroidism causes elevated calcium levels, thus stimulating acid secretion. With treatment of the underlying condition, spontaneous ulcer healing usually occurs.

- In stress ulcers: Hypersecretion of acid is not always essential for stress ulceration to occur, but does appear to be important in both of these conditions. In neurosurgical injury, raised intracranial pressure may be responsible for an increase in vagal activity and hence the increase in gastric secretion. The ulcers resulting from hypersecretion are usually single and, in common with other forms of peptic ulceration, may be complicated by perforation and bleeding.
- Where persistent vomiting is troublesome, the possibility of gastric outlet obstruction should be considered. Such vomiting tends to be projectile and may contain recognizable food eaten many hours previously.
- Diagnosis: As already described, endoscopy and biopsy is essential in the diagnosis of peptic ulceration. In addition *H. pylori* can be diagnosed using the CLO test; a biopsy specimen taken from the antrum is placed in a gel containing urea. Ammonia released by the action of the *H. pylori*-derived urease is detected and causes a colour change – in most kits, from yellow to pink/red. Biopsy of gastric ulcers is particularly important, as malignancy needs to be excluded.
- Treatment: If NSAIDs cannot be avoided in patients with a history of peptic ulceration PPIs should be prescribed (e.g. omeprazole or lansoprazole). These agents act by irreversibly inhibiting H⁺/K⁺ ATPase and thus are powerful inhibitors of acid secretion.

1-In duodenal ulcer:

Eradication of the *H. pylori* has become the mainstay of management in patients with a duodenal ulcer. Eradication therapies comprise an antisecretory agent, typically a PPI, together with one or more antibiotics. This ‘triple therapy’ is usually given for 7 days followed by a healing dose of PPI for 4–6 weeks.

2-In Gastric ulcers:

Malignancy should be excluded by endoscopic biopsy before a diagnosis of benign gastric ulcer is made. Where a patient is found to be *H. pylori*-positive at endoscopy, eradication therapy should be instituted. Without eradication, the relapse rate is in the region of 50% .

- Failure of conservative therapy to heal a gastric ulcer is an indication for surgical intervention. Where malignancy cannot be excluded or is suspected, resection of the ulcer is the treatment of choice. The extent and type of resection will be determined by the position of the ulcer within the stomach and its suspected malignant potential.

Davidson (189-191)

I highly suggest that you read Davidson's related chapters. It's beautifully written

Complications:

A) Perforation

- **Duodenal ulcers:** perforation usually occurs in acute ulcers on the anterior wall of the duodenum.
- **Gastric ulcers:** less common and strongly associated with NSAIDs.

Clinical Features: Acute onset of severe unremitting epigastric pain. Patient may be pale, shocked. Patient may have **shoulder-tip pain**.

Diagnosis: always x-ray; an erect chest x-ray will show free air under the diaphragm.

Management: initial management consists of resuscitation, oxygen therapy, IV fluids and broad spectrum antibiotics, and nasogastric tube. IV opiates for analgesia and PPI should be given as necessary.

Surgical management:

Duodenal ulcers: simple closure where the ulcer is plugged with an omental patch (or the round ligament of the liver) coupled with peritoneal lavage (PLUG & CLEAN). IV PPI'S and eradication h.pylori is of high importance post-op.

Gastric Ulcers: 15% are malignant; however, the safest procedure is a biopsy of the ulcer wall followed by simple closure or local excision of the ulcer. Large pre-pyloric ulcers or those close to the lesser curvature are a hard due to their size and location so distal gastrectomy is needed. if the ulcer turns out to be malignant, a formal gastric resection should be performed following tumor staging.

B) Acute Hemorrhage:

- There are causes of upper GI bleeding (peptic ulcer, gastritis, duodenitis, and erosions)
- Upper GI bleeding: presents with **hematemesis and melena** (which results from digestion of blood by enzymes and bacteria.)

Diagnosis:

History and Examination:

- past medical history (peptic ulcer, liver disease)
- past drug history (NSAIDs and anticoagulants)
- social history (alcohol abuse)

Blood tests:

Management:

Resuscitation: high flow oxygen, IV fluids, nasogastric tube to prevent aspiration, and urinary catheter.

Endoscopy: is mainly used for detection of the site of bleeding and then bleeding is controlled via clipping or adrenaline injection. If endoscopy fails to detect the site angiography can be used.

Surgical management: ER surgery is required if endoscopy reveals bleeding from a major artery.

C) Obstruction:

- Benign gastric obstruction is commonly a sequela of peptic ulcer disease and presents with vomiting that is characteristically non-bile-stained.
- Clinical features are palpable distended stomach and the presence of gastric peristalsis with a direction from left to right in the upper abdomen.
- Management: resuscitation and correction of acid-base abnormalities, a nasogastric suction and washout. A subsequent OGD is mandatory to rule out carcinoma.

Surgical Recall

Upper GI bleed:

- Which diagnostic tests are useful?
History, NGT aspirate, abdominal x-ray, endoscopy (EGD)
- What is the diagnostic test of choice with UGI bleeding?
EGD (95% diagnosis rate)
- What are the treatment options with the endoscope during an EGD?
Coagulation, injection of epinephrine (for vasoconstriction), injection of sclerosing agents (varices), variceal ligation (banding)
- Which lab tests should be performed?
Chem-7, bilirubin, LFTs, CBC, type & cross, PT/PTT, amylase
- What is the initial treatment?
 1. IVFs (16 G or larger peripheral IVS 2), Foley catheter (monitor fluid status)
 2. NGT suction (determine rate and amount of blood)
 3. Water lavage (use warm H₂O—will remove clots)
 4. EGD: endoscopy (determine etiology/ location of bleeding and possible treatment—coagulate bleeders)
- Why irrigate in an upper GI bleed?
To remove the blood clot so you can see the mucosa
- What test may help identify the site of MASSIVE UGI bleeding when EGD fails to diagnose cause and blood continues per NGT?
Selective mesenteric angiography
- What are the indications for surgical intervention in UGI bleeding?
Refractory or recurrent bleeding and site known, >3 u PRBCs to stabilize or >6 u PRBCs overall
- What is the mortality of acute UGI bleeding?
Overall 10%, 60-80 years of age 15%, older than 80 years of age 25%
- What are the risk factors for death following UGI bleed?
Age older than 60 years Shock > 5 units of PRBC transfusion Concomitant health problems