

Chronic Diarrhea

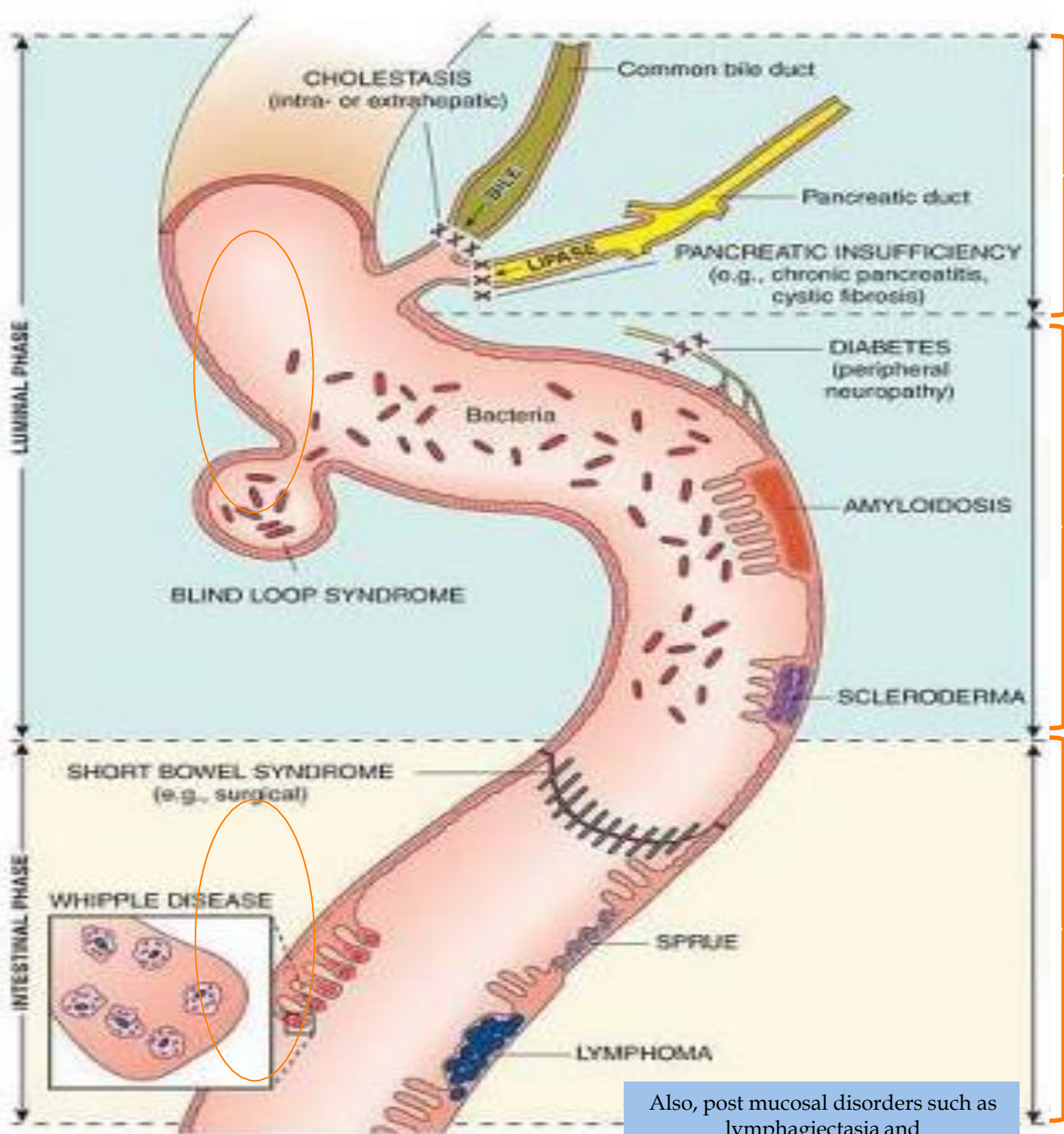
Suliman Alshankiti

Objectives

- To have an overview regarding chronic diarrhea:
 - ✓ Definition
 - ✓ Pathophysiology
 - ✓ Classification
 - ✓ Approach
- To discuss common causes of chronic diarrhea:
 - ✓ Celiac Disease
 - ✓ Whipple Disease
 - ✓ Tropical Sprue
 - ✓ Small Bowel Bacterial Overgrowth
 - ✓ Exocrine Pancreatic Insufficiency
 - ✓ Bile Salt-Induced Diarrhea

Definition

- Diarrhea
- Chronic Diarrhea
- Maldigestion
- Malabsorption



SECRETORY INSUFFICIENCY

maldigestion

IMPAIRED MOTILITY WITH BACTERIAL OVERGROWTH AND BILE SALT INACTIVATION

Why make the distinction?

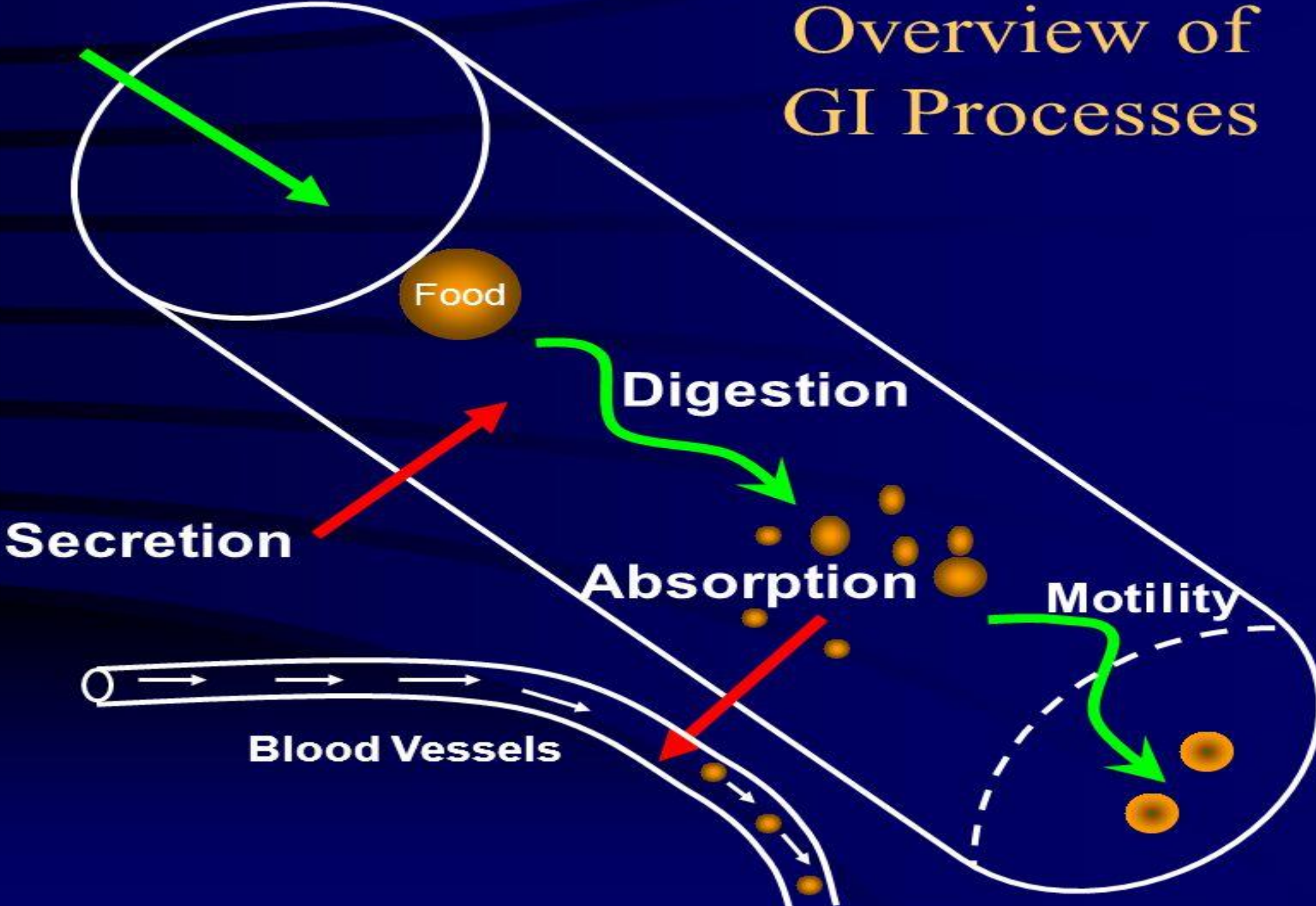
..to provide a framework for remembering/classifying the responsible physiological mechanisms

IMPAIRED MUCOSAL FUNCTION

malabsorption

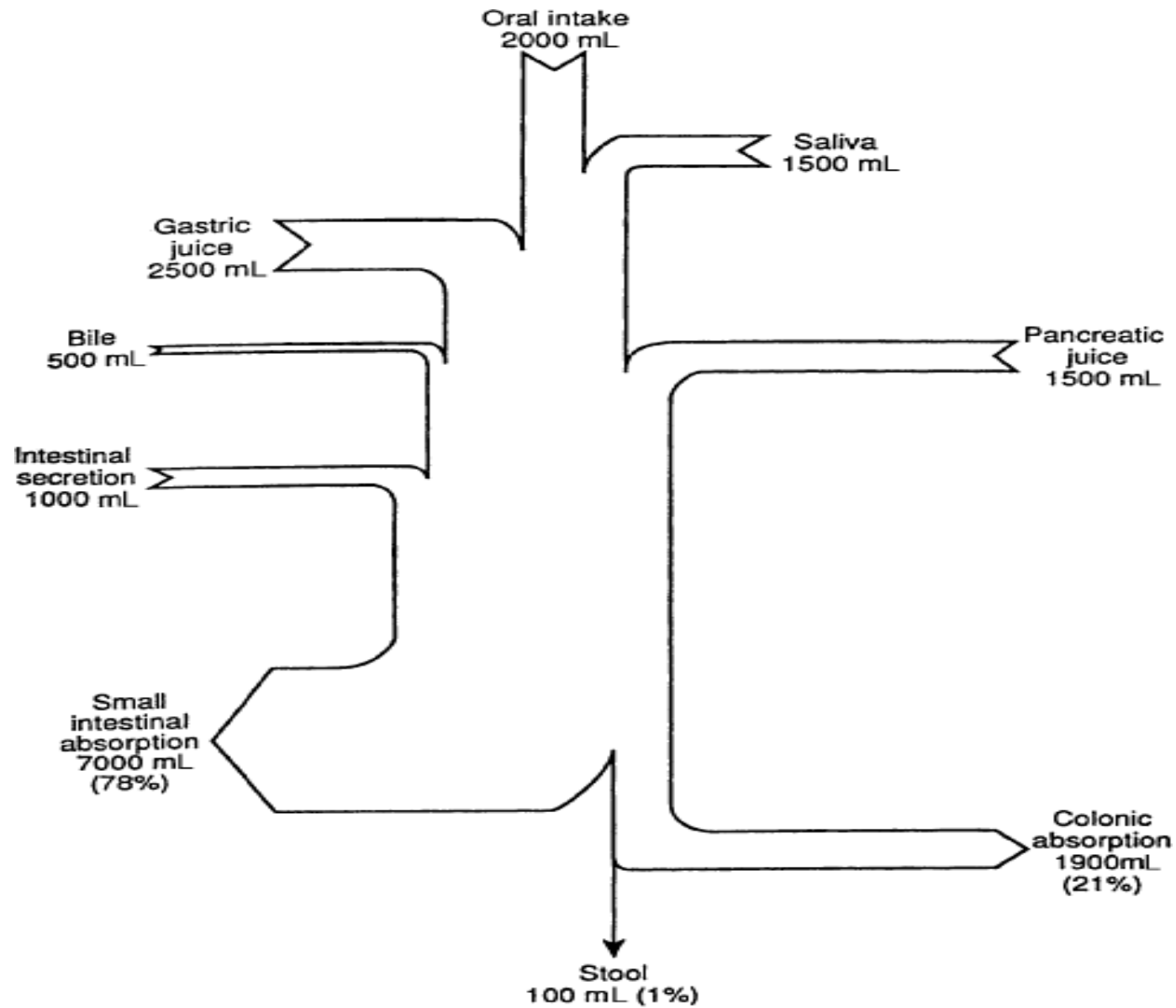
Also, post mucosal disorders such as lymphangiectasia and abetalipoproteinemia

Overview of GI Processes



Pathophysiology

- Each day, 9–10 L of fluid enter the jejunum.
- Small intestine absorbs 90% of this fluid load
- The colon absorbs 90% of the remaining load (about 900 ml/24 hours); leaving approximately 80–100 ml excreted each day in feces.
- A normal colon can compensate by absorbing up to 3000–4000 ml/24 hours



Source: Barrett KE: *Gastrointestinal Physiology*:
<http://www.accessmedicine.com>

Copyright © The McGraw-Hill Companies, Inc. All rights reserved.

Osmotic Diarrhea

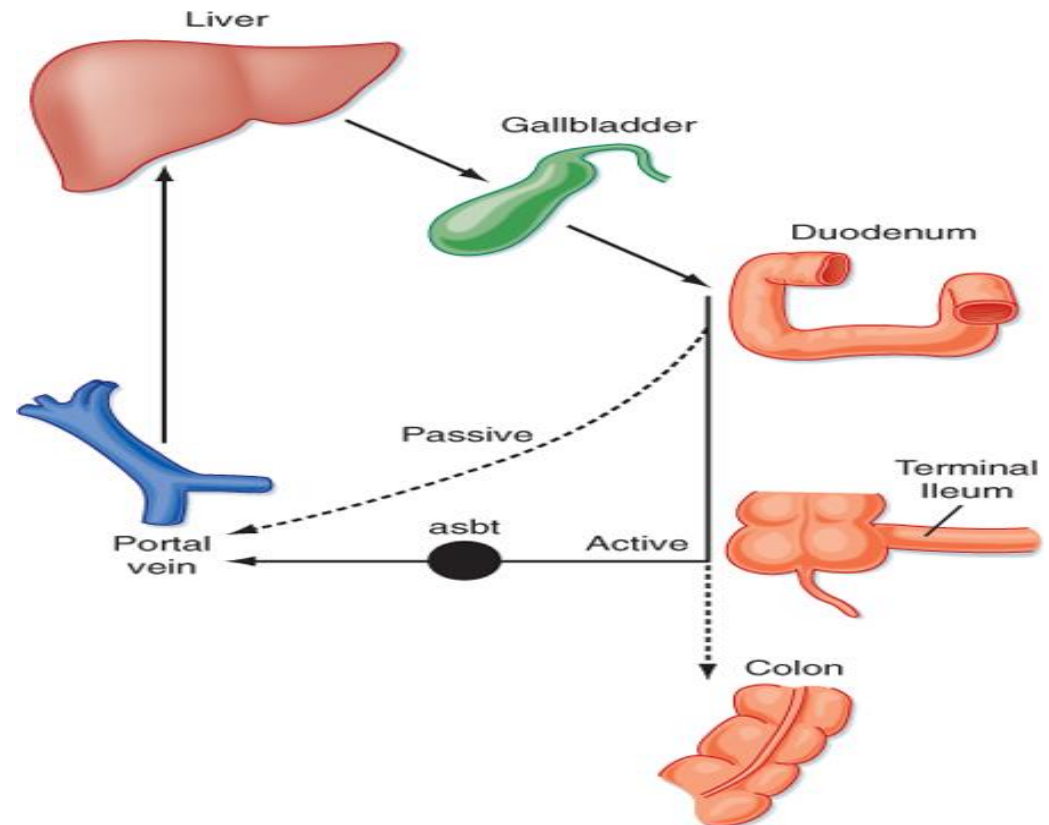
- Poorly absorbed substances that remain in the lumen of the intestine and obligate retention of water within the lumen by virtue of their osmotic effects
- ✓ Ingestion of poorly absorbed agent (eg, magnesium)
- ✓ Loss of nutrient transporter (eg, lactase deficiency)

- ✓ *Lactose (in individuals with lactase deficiency)*
- ✓ *Fructose*
- ✓ *Mannitol*
- ✓ *Sorbitol*
- ✓ *Lactulose*
- ✓ *Magnesium*
- ✓ *Phosphate*
- ✓ *Sulfate*

Secretory Diarrhea

- Infections
- Reduction of mucosal surface area by surgery or disease
- Absence of an ion-transport mechanism
- Inflammation
- Dysregulation
- Circulating secretagogues (endocrine)

- Pancreatic Insufficiency
- Bile Acid-Induced Diarrhea



Fecal Osmotic Gap (FOG)

- $FOG = 290 - 2 \times (\text{stool Na} + \text{stool K})$
- FOG of >50 mosm/kg is suggestive of an osmotic diarrhea and a gap of >100 mosm/kg is more specific.

Clinical Classification

➤ Fatty

- Bloating, flatulence, greasy malodorous stools that can be difficult to flush, weight loss, s/s of vitamin deficiencies (peripheral neuropathy, easy bruising)
- Anemia, coagulopathy, hypoalbuminemia, osteopenia

➤ Watery

- Large volume, variable presentation

➤ Inflammatory

- Blood, mucus, pus, abd pain, fever, small volume
- Positive fecal leukocytes, gross or occult blood, ESR/CRP, leukocytosis

Fatty Diarrhea

Maldigestion = inadequate breakdown of triglycerides

- Pancreatic exocrine insufficiency (eg, chronic pancreatitis)
- Inadequate luminal bile acid concentration (eg, advanced primary biliary cirrhosis)

Malabsorption = inadequate mucosal transport of digestion products

- Mucosal diseases (eg, Celiac sprue, Whipple's disease)
- Mesenteric ischemia
- Structural disease (eg, short bowel syndrome)
- Small intestinal bacterial overgrowth (bile salt deconjugation)

Chronic Inflammatory Diarrhea

Inflammatory diarrhea

Inflammatory bowel disease

Ulcerative colitis

Crohn's disease

Diverticulitis

Ulcerative jejunoileitis

Infectious diseases

Pseudomembranous colitis

Invasive bacterial infections (e.g., tuberculosis, yersiniosis)

Ulcerating viral infections (e.g., cytomegalovirus, *Herpes simplex*)

Invasive parasitic infections (e.g., amebiasis, *strongyloides*)

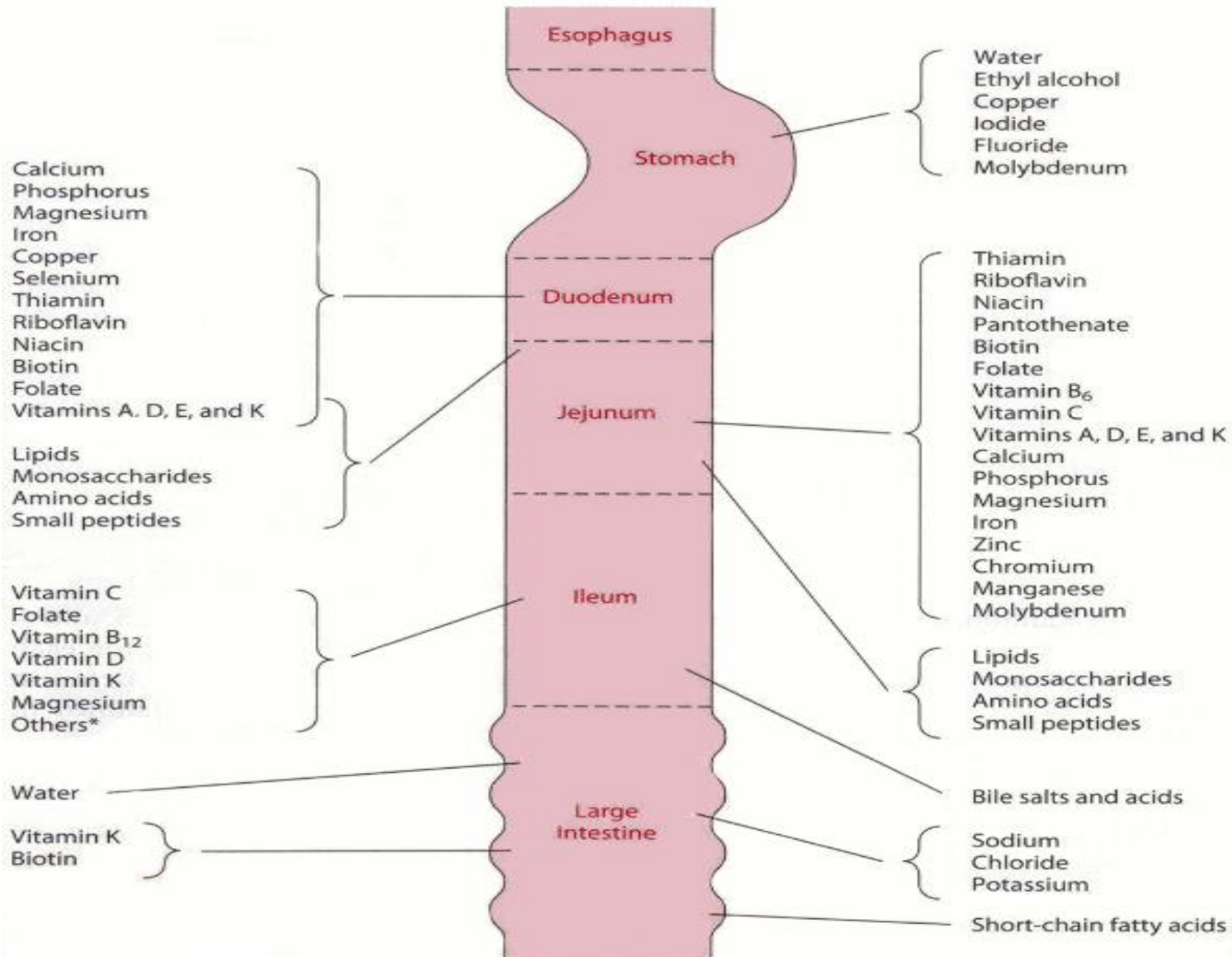
Ischemic colitis

Radiation colitis

Neoplasia

Colon cancer

Lymphoma

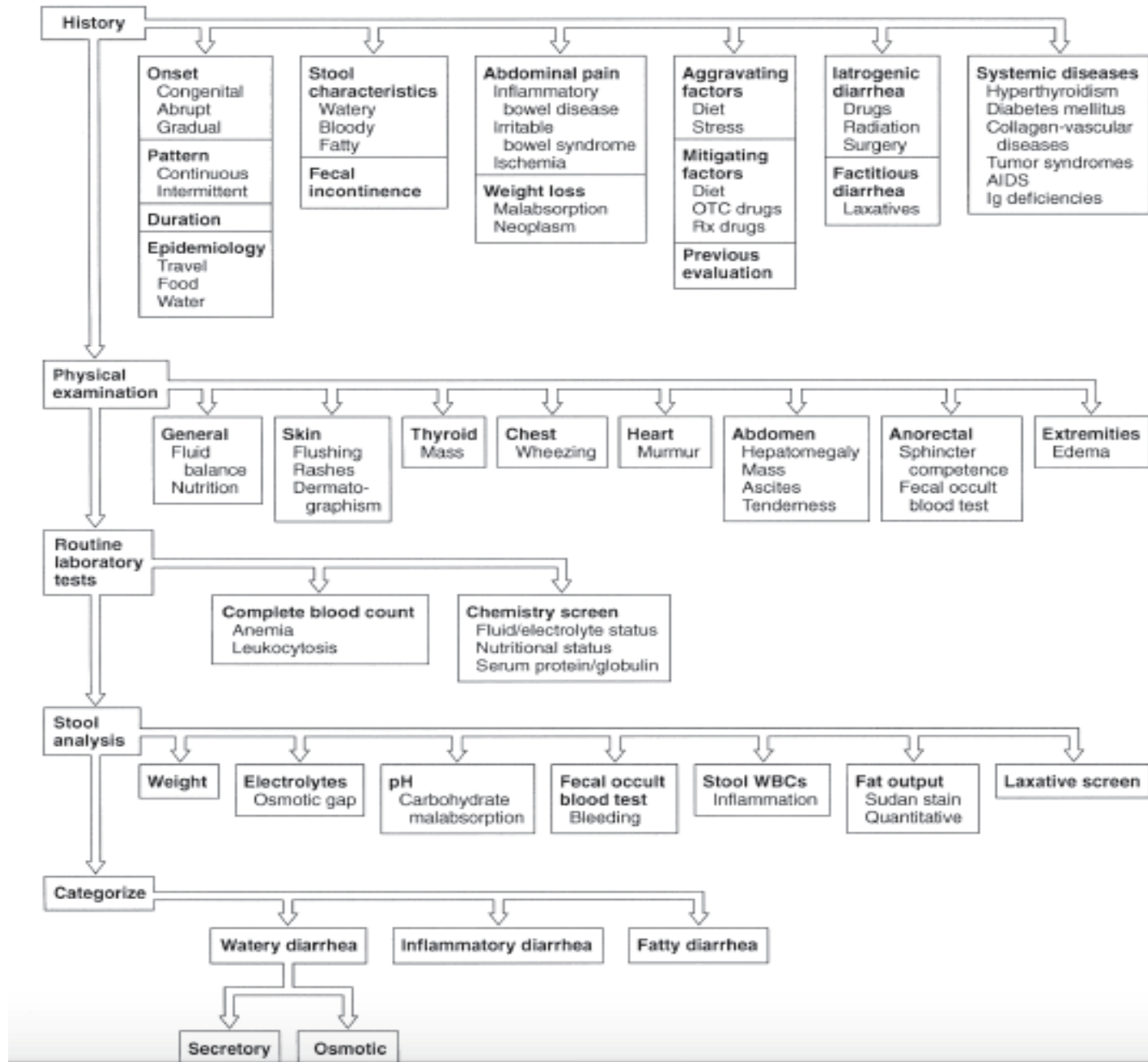


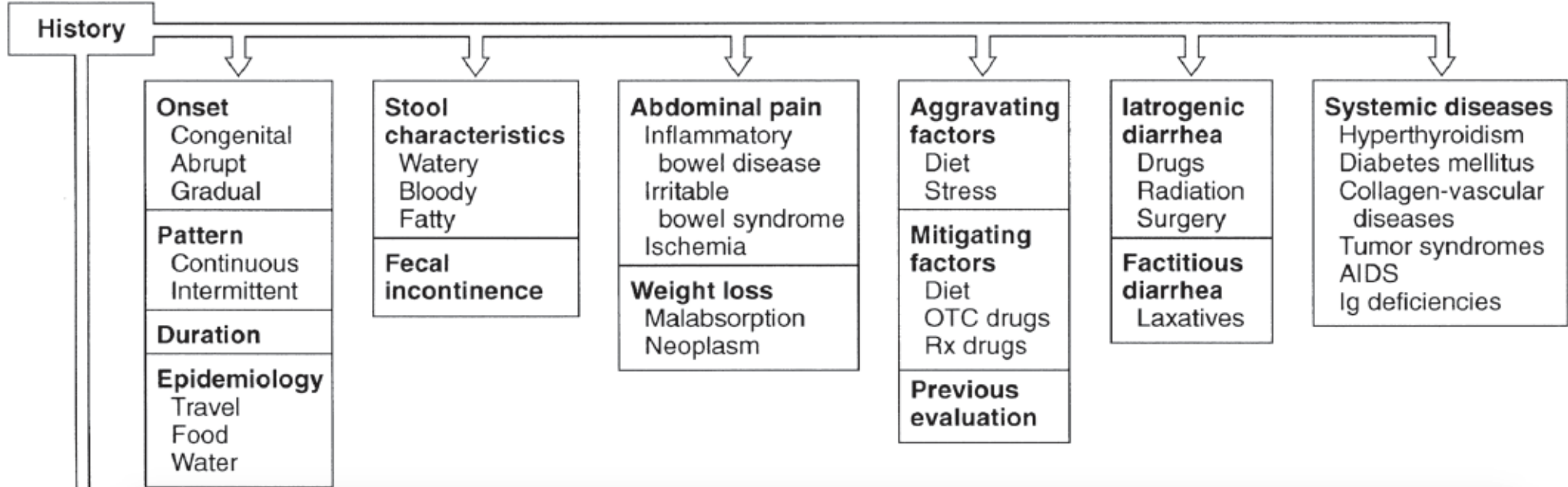
*Many additional nutrients may be absorbed from the ileum depending on transit time.

Review of Nutrient/Vitamin Absorption

Duodenum/Jejunum	Ileum	Colon
Carbohydrates / simple sugars	Vitamin B12	Short-chain fatty acids
Fats	Bile salts	Vitamin K**
Amino acids	Magnesium	Biotin**
Iron		
Fat-soluble vitamins (A, D, E, K)		
Calcium		
Magnesium		
Other Vitamins		
Minerals		

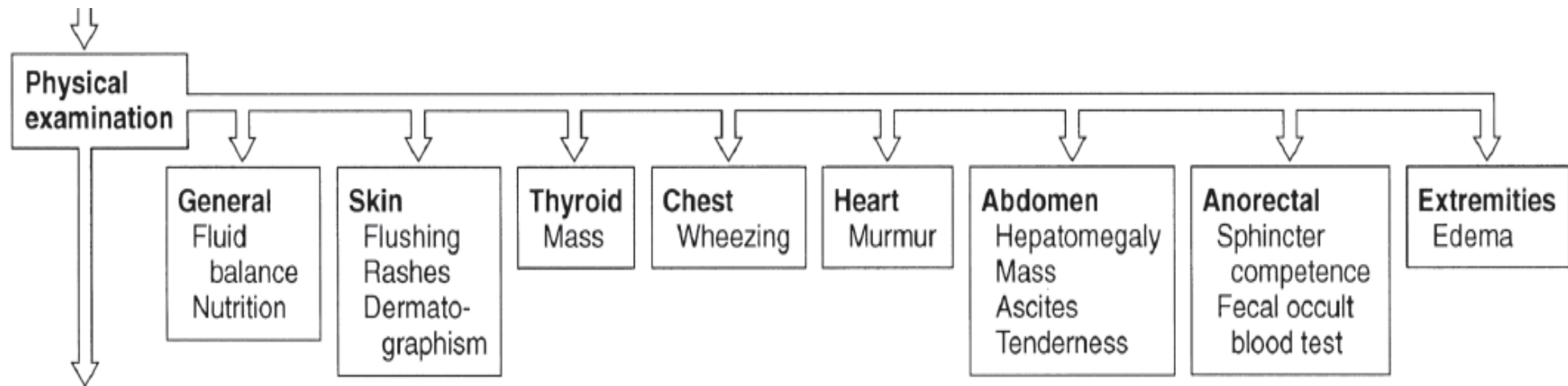
** In part produced by bacterial gut flora

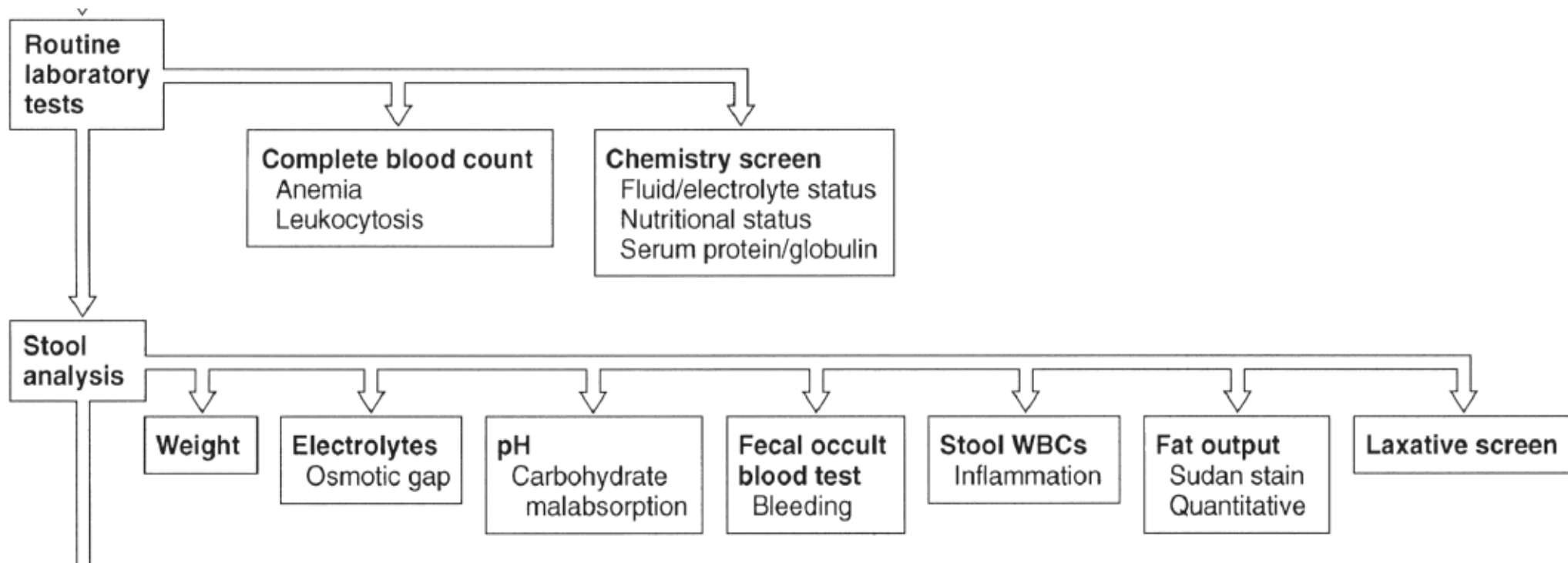




Common Medications and Toxins Associated with Diarrhea

- Acid-reducing agents (H2 blockers, PPIs)
- Magnesium-containing antacids
- Anti-arrhythmics (eg, digitalis, quinidine)
- Antibiotics
- Anti-neoplastic agents
- Antiretrovirals
- Beta blockers
- Colchicine
- Levothyroxine
- SSRIs
- Furosemide
- Metformin
- NSAIDs, ASA
- Prostaglandin analogs (ie, misoprostil)
- Theophylline
- Amphetamines
- Caffeine
- Alcohol
- Narcotic/opioid withdrawal

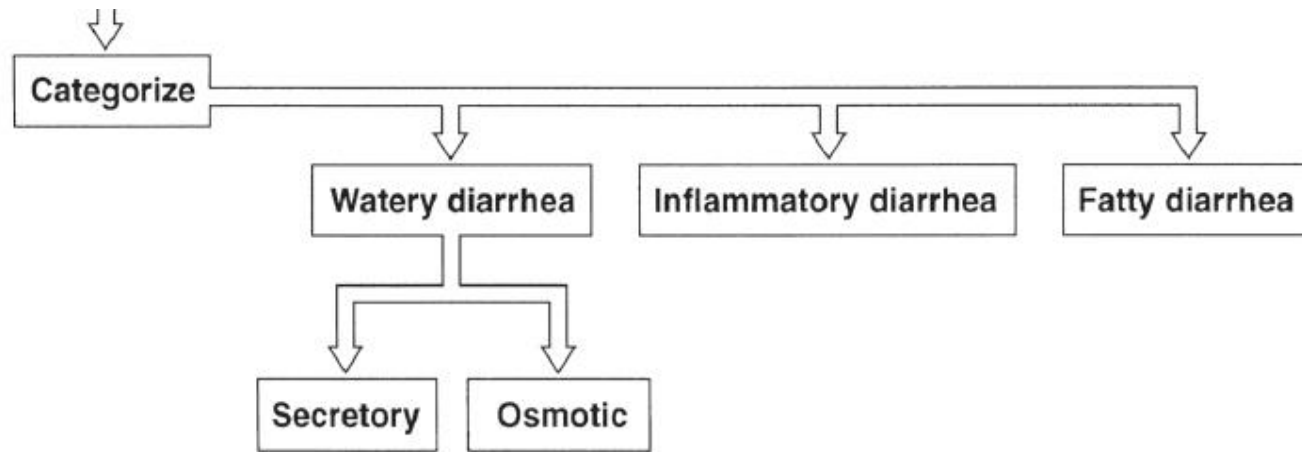




- Culture (more useful only for acute), O&P, Giardia Ag, C diff, Coccidia, Microsporidia, Cryptosporidiosis
- Fecal leukocytes (or marker for neutrophils: lactoferrin or calprotectin)
- Fecal occult blood
- Stool electrolytes for osmolar gap = $290 - 2[\text{Na} + \text{K}]$
- Stool pH (<6 suggests CHO malabsorption due to colonic bacterial fermentation to CO₂, H₂, and short chain FA)
- Fat content (48h or 72h quantitative or Sudan stain)
- Laxative screen (if positive, repeat before approaching pt)

Additional Studies

- Imaging
 - Small bowel series
 - CT/MRI or CT/MR enterography
- Endoscopy with small bowel biopsy and aspirate for quantitative culture
- Colonoscopy, including random biopsies



Differential Diagnosis: Watery Diarrhea

Osmotic (poorly absorbable substance in lumen)

- Carbohydrate malabsorption (eg, lactase deficiency, diet high in fructose or sugar alcohols)
- Osmotic laxatives (Mg, PO₄, SO₄)

Secretory (malabsorption or secretion of electrolytes, H₂O)

- Very broad differential – see next slide

Differential Diagnosis: Watery (Secretory) Diarrhea

- Bacterial toxins
- Abnormal motility
 - DM-related dysfunction
 - IBS
 - Post-vagotomy diarrhea
- Diverticulitis
- Ileal bile acid malabsorption
- Malignancy
 - Colon CA
 - Lymphoma
 - Rectal villous adenoma
- Vasculitis
- Congenital chloridorrhea
- Inflammatory
 - Microscopic colitis
- Endocrinopathies
 - Hyperthyroidism
 - Adrenal insufficiency
 - Carcinoid syndrome
 - Gastrinoma, VIPoma, Somatostatinoma
 - Pheochromocytoma
- Idiopathic
 - Epidemic (Brainerd)
 - Sporadic
- Medications, stimulant laxative abuse, toxins

Differential Diagnosis: Inflammatory Diarrhea

- IBD (Crohn's, UC)
 - Ischemic colitis
 - Malignancy
 - Colon CA
 - Lymphoma
 - Diverticulitis
 - Radiation colitis
- Infectious
 - Invasive bacterial (*Yersinia*, TB)
 - Invasive parasitic (Amebiasis, strongyloides)
 - Pseudomembranous colitis (*C diff* infection)
 - Ulcerating viral infections (CMV, HSV)

Fatty Diarrhea

Maldigestion = inadequate breakdown of triglycerides

- Pancreatic exocrine insufficiency (eg, chronic pancreatitis)
- Inadequate luminal bile acid concentration (eg, advanced primary biliary cirrhosis)

Malabsorption = inadequate mucosal transport of digestion products

- Mucosal diseases (eg, Celiac sprue, Whipple's disease)
- Mesenteric ischemia
- Structural disease (eg, short bowel syndrome)
- Small intestinal bacterial overgrowth (bile salt deconjugation)

Signs and Symptoms of Malabsorption

Malabsorption of	Clinical features	Lab findings
Calories	Wt loss w/ normal appetite	
Fat	Pale voluminous stool, steatorrhea	Stool fat >6 g daily
Protein	Edema, muscle atrophy, amenorrhea	Low albumin, low protein
Carbohydrates	Watery diarrhea, flatulence, milk intolerance	Stool pH < 6; stool osmotic gap >100; increased breath hydrogen
Vitamin B12	Anemia, subacute combined degeneration of spinal cord (paresthesias, ataxia, loss of position/vibratory sense)	Macrocytic anemia; low B12 level; increased MMA and homocysteine levels; abnormal Schilling test
Folic acid	Anemia	Macrocytic anemia; decreased serum/RBC folate; increased homocysteine level

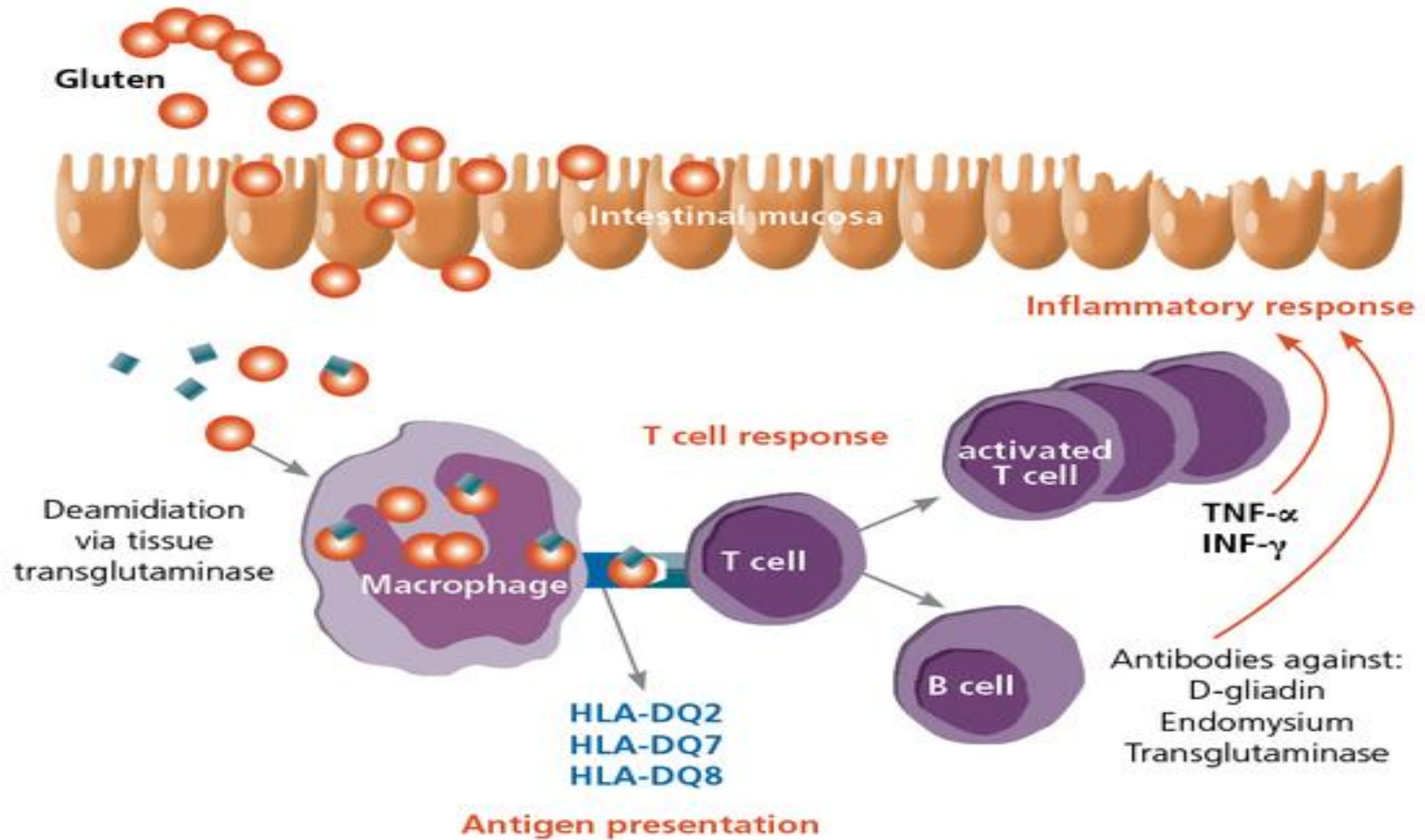
Signs and Symptoms of Malabsorption

Malabsorption of	Clinical features	Lab findings
Iron	Anemia, glossitis, pagophagia	Microcytic anemia; decreased serum iron and ferritin levels; increased TIBC
Calcium and Vitamin D	Paresthesia, tetany, pathologic fractures, positive Chvostek and Trusseau signs	Low serum calcium; abnormal DEXA; elevated Alk Phos
Vitamin A	Follicular hyperkeratosis, night blindness	Decreased serum carotene
Vitamin K	Easy bruising, bleeding disorders	Elevated INR; decreased Vitamin K-dependent coagulation factors (2, 7, 9, 10)
Vitamin B (general)	Cheilosis, painless glossitis, angular stomatitis, acrodermatitis	

Celiac Disease

Introduction

- Small intestinal malabsorption of nutrients following the ingestion of wheat gluten or related proteins from rye and barley.
- A characteristic, though not specific, villous atrophy of the small intestinal mucosa.
- Prompt clinical and histologic improvement following strict adherence to a gluten free diet.
- Clinical and histologic relapse when gluten is reintroduced



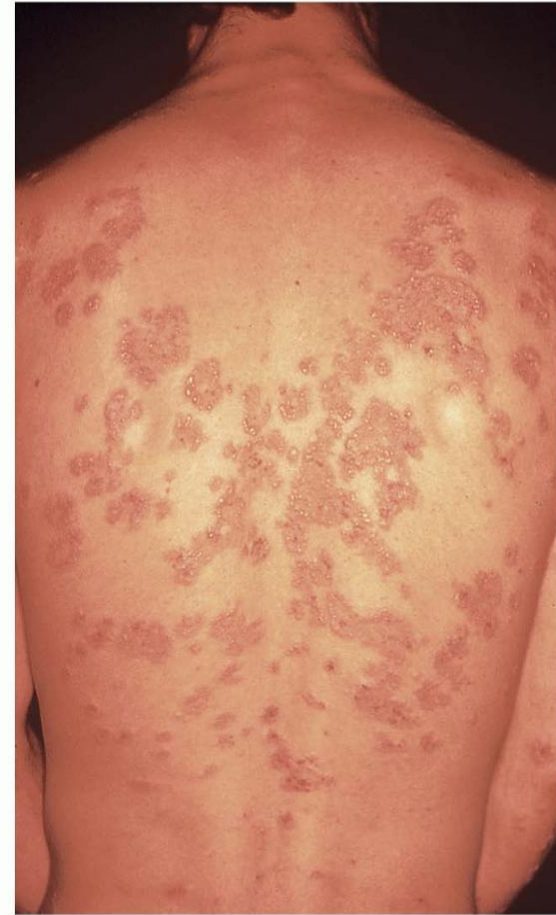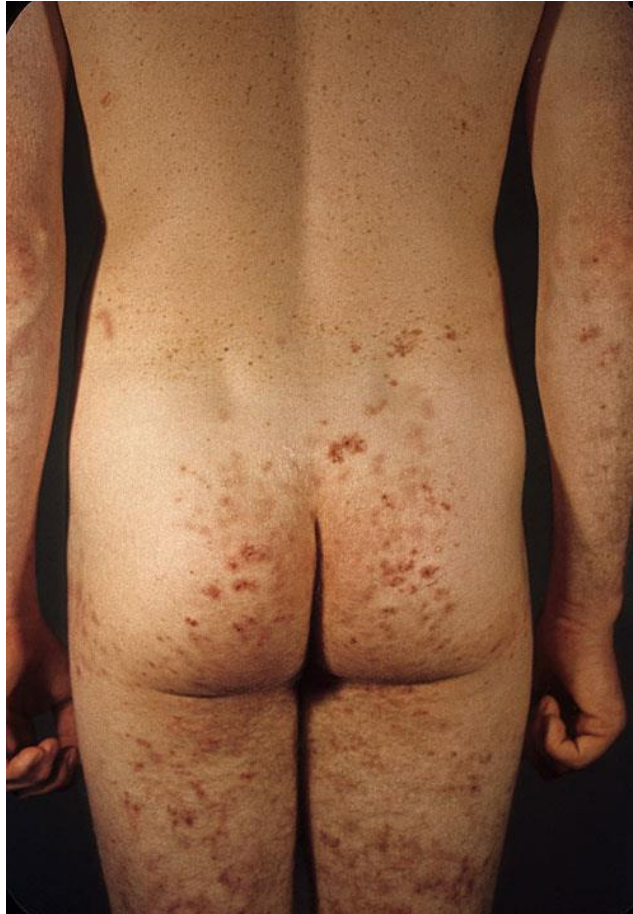Pathophysiology

- The disease affect the mucosa with marked variation
- Loss of normal villous structure - flattening
- Intestinal crypts are elongated and open onto a flat absorptive surface
- Leaky mucosa with increased permeability due to structural changes of the tight junctions between damaged absorptive cells
- Marked increase in cellularity of the lamina propria – plasma cells and lymphocytes

Presentation

- Asymptomatic
- Non-specific GI symptoms
 - Diarrhea
 - Bloating
 - Dyspepsia
- Nutritional deficiency:
 - Anemia (Iron & folate)
 - Osteoporosis
- Fat soluble vitamin deficiencies:
 - Vit A: poor night vision, follicular hyperkeratosis
 - Vit D: hypocalcemia, osteoporosis
 - Vit K: easy bruising & bleeding, elevated INR
- Dermatitis herpatiformis
- Elevated ALT & AST
- Malignancy
 - T-cell lymphoma
 - Small bowel adenoCa

Dermatitis Herpatiformis



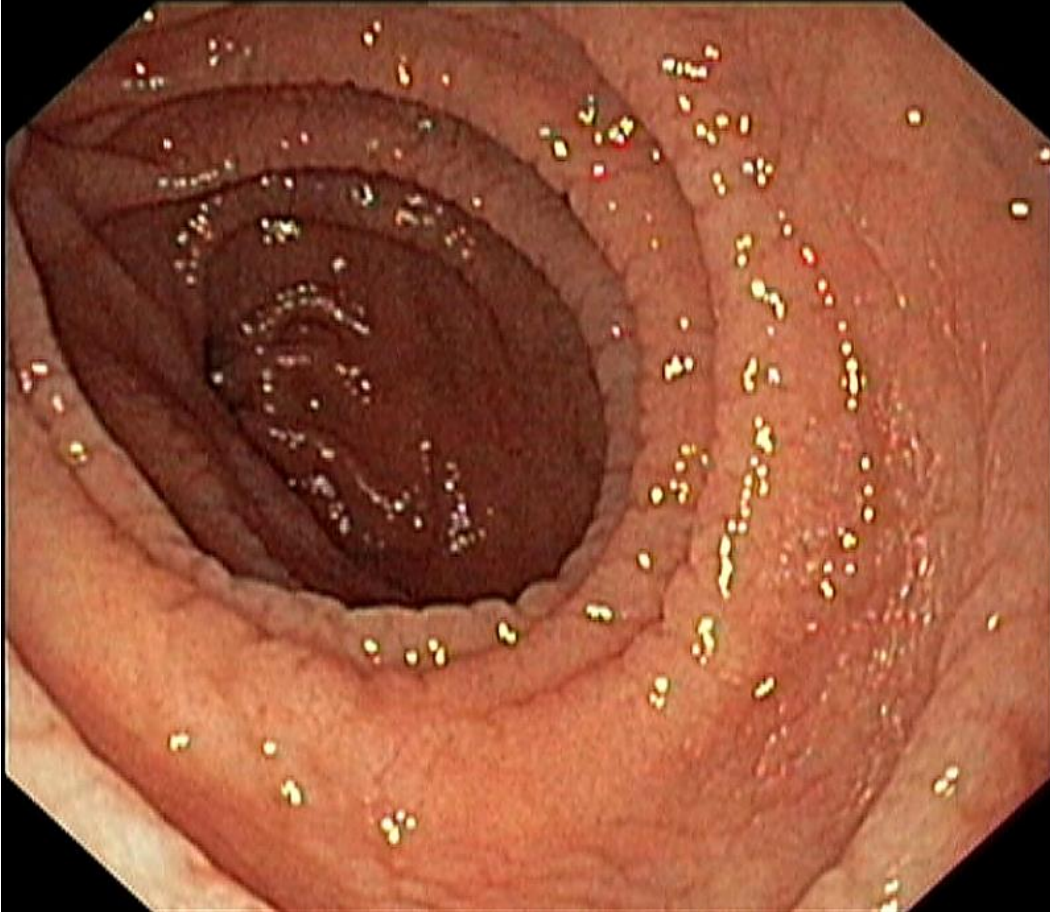
At Risk

- Type 1 DM (3-6%)
- Autoimmune thyroid disease (6-8%)
- Down's syndrome
- Connective tissue disease
- IgA deficiency (2-3%)

Serology

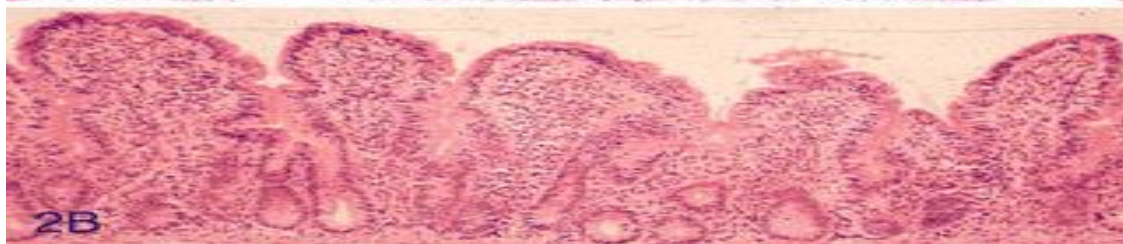
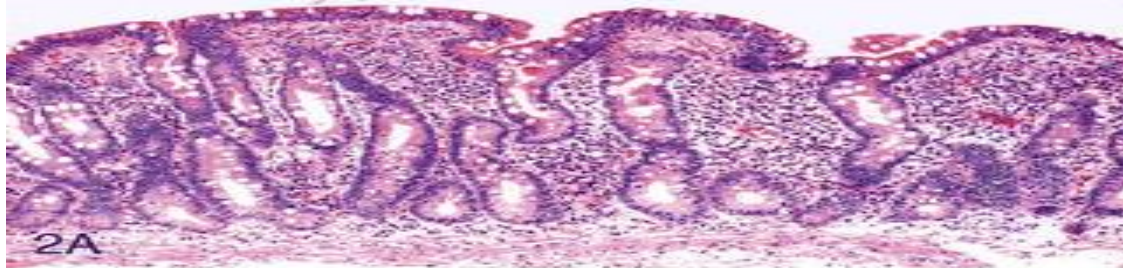
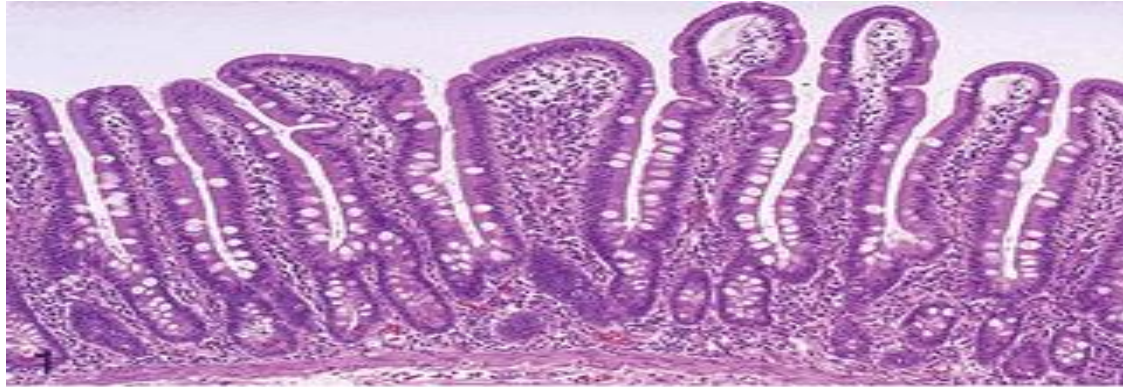- **Anti-tissue transglutaminase antibody (IgA)**
 - Sensitivity 95%; specificity 97.5%
- Endomysial antibody (IgA)
 - Sensitivity 85-98% (~93) Specificity 97-100% (~99)
- IgA anti-gliadin antibodies
 - Sensitivity 75-90% (~80) Specificity 82-95% (~85)
- IgG anti-gliadin antibodies
 - Sensitivity 69-85% (~75) Spec 73-90% (~80)
 - Can be used in IgA deficient patients

Endoscopy

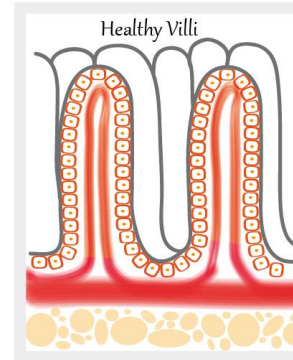


- Normal
- Loss of mucosal folds
- Flattening of mucosa
- Scalloping of mucosa
- Ulcerations

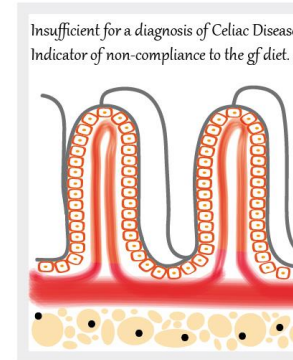
Histology



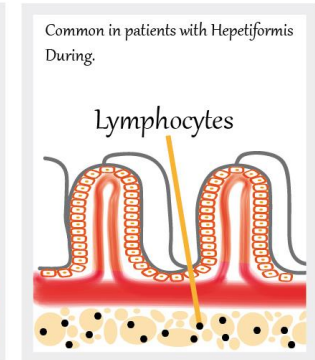
MARSH 0



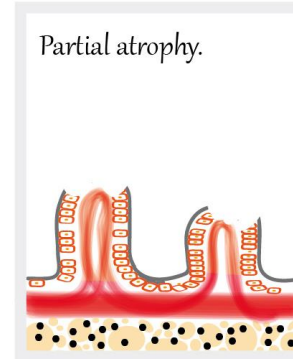
MARSH 1



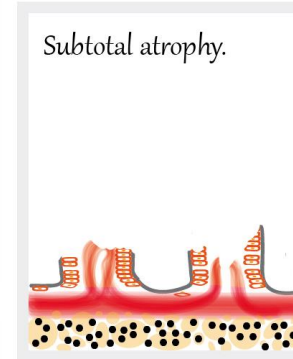
MARSH 2




MARSH 3A



MARSH 3B



MARSH 3B



Management

- Education
- Gluten-free diet: avoid wheat, barley, rye & oat
- Correct nutritional deficiencies (Iron, Ca, Vit D)
- Anticipate complications

Whipple Disease

- Chronic systemic infection by *Tropheryma whipplei*
- Has GI, CNS, CVS, MSK & skin manifestations
- Malabsorption – weight loss, diarrhea (watery or fatty) and abdominal pain
 - Caused by bacterial and macrophage-predominant inflammatory cell infiltration of the small intestinal mucosa and obstruction of mesenteric lymph nodes

Whipple Disease

➤ CNS

- Progressive dementia
- Supranuclear ophthalmoplegia
- Altered LOC
- Oculo-masticatory & oculo-facial skeletal dysfunction

➤ CVS

- Endocarditis – MV most common
- Myocarditis
- Pericarditis

➤ MSK

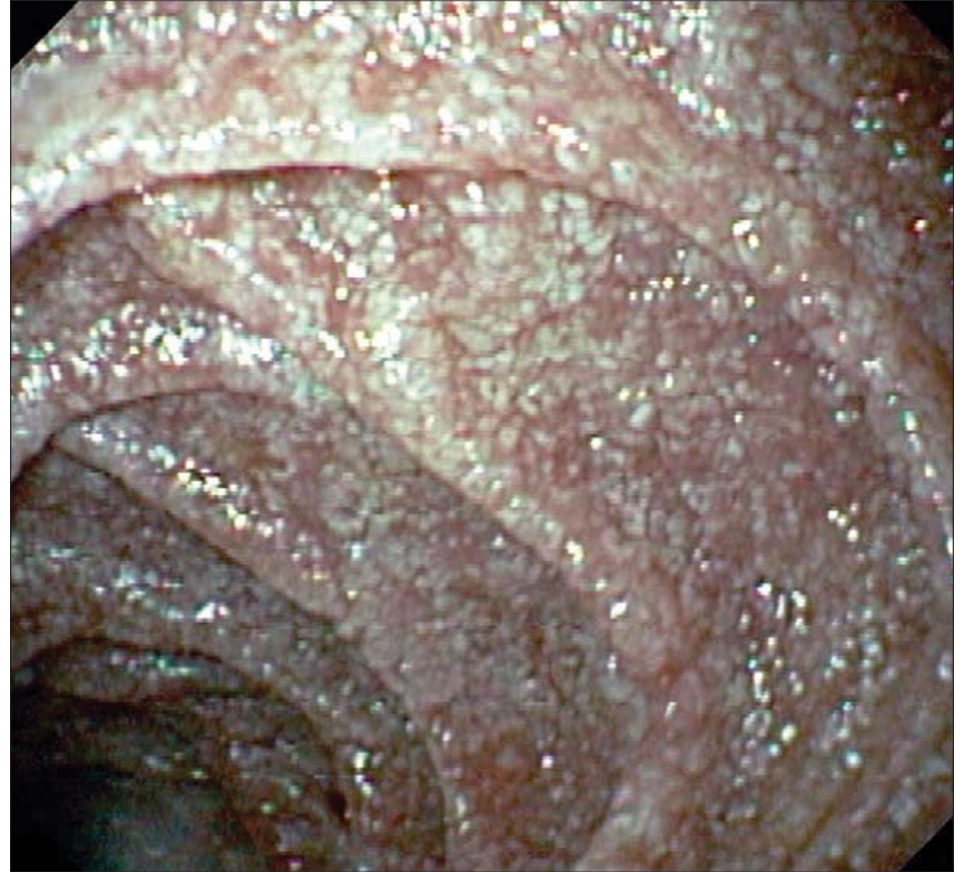- Oligo or polyarthralgias

➤ Skin (common)

- Hyperpigmentation

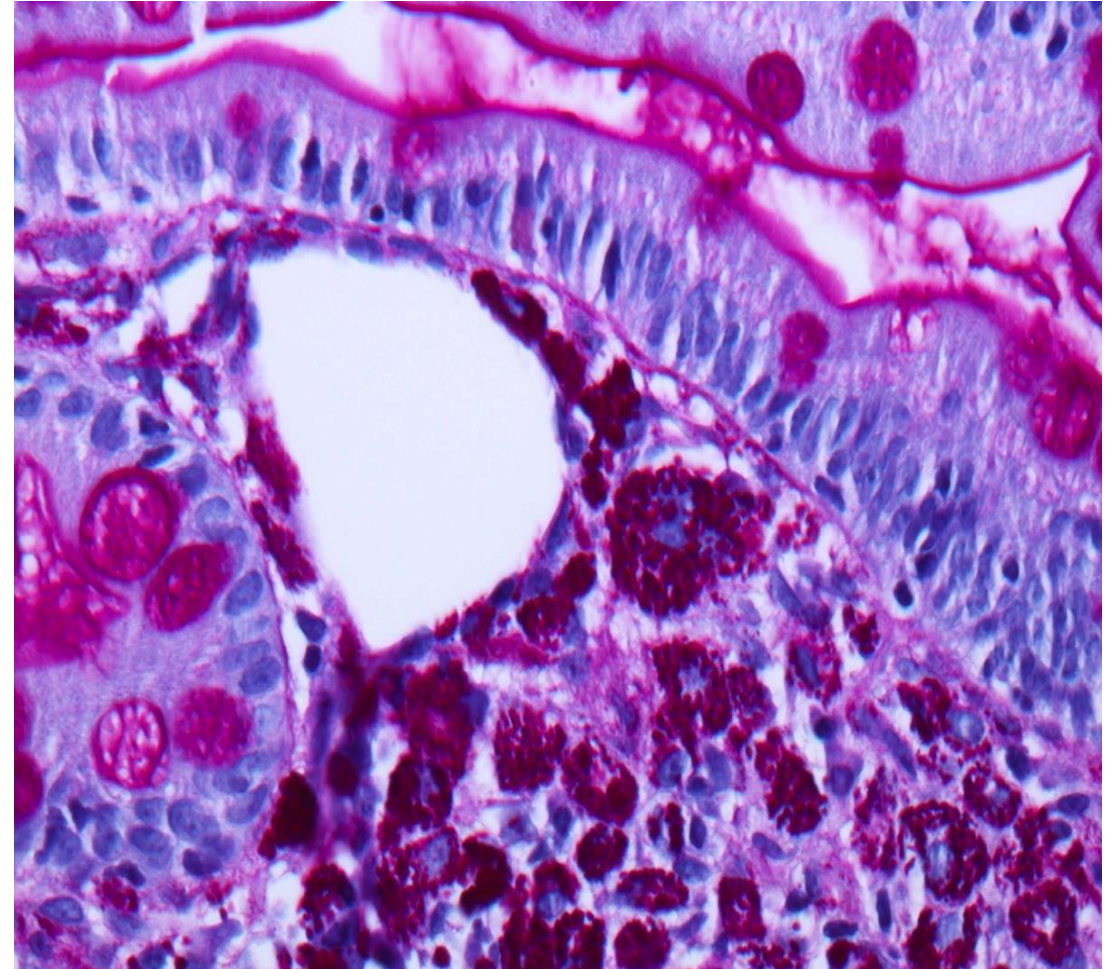
Whipple Disease

- Whitish to yellow plaque-like patches in 75% of patients (*representing lipid droplets and/or lymphangiectasia*)



Whipple Disease

- Foamy macrophages on routine H&E
- Numerous PAS-positive granular particles (pink/purple appearing)
 - Lysosomes filled with *T. whipplei*



Whipple Disease

- 2 weeks with Abx to cross BBB: Ceftriaxone 2g IV daily monotherapy or Pen G (2 MU IV q4h) PLUS streptomycin...

THEN...

- Septra DS tab BID x 1 year.

Small Bowel Bacterial Overgrowth (SBBO)

➤ Normal Microbiom:

- Stomach $0-10^3$ CFU/ml
- Jejunum $0-10^4$
 - ✓ Gram + aerobes (oral streptococci, lactobacillus); no gram –ve aerobes
- Ileum 10^5-10^9
- Colon $10^{10}-10^{12}$
 - ✓ Anaerobes: bacteroides, peptostreptococcus, lactobacillus, bifidobacterium, clostridium
 - ✓ Facultative aerobes: e. coli, enterococcus, staphylococcus

Small Bowel Bacterial Overgrowth

- Normal barriers that prevent SBBO:
 - ✓ Gastric acid & pancreatic enzymes (*chronic pancreatitis, low HCl from surgery, diseases or PPI*)
 - ✓ Intact bowel structure (*Surgery, diverticulum*)
 - ✓ Cleansing effect of bowel motility – inter-digestive migrating motor complex (*dysmotility*)
 - ✓ Gut immunity – intraluminal secretory IgA (*immunodeficiency*)
 - ✓ Competent ileocecal valve (*scarring from inflammation, surgery*)
 - ✓ Competition by other bacteria (*antibiotics*)

Small Bowel Bacterial Overgrowth

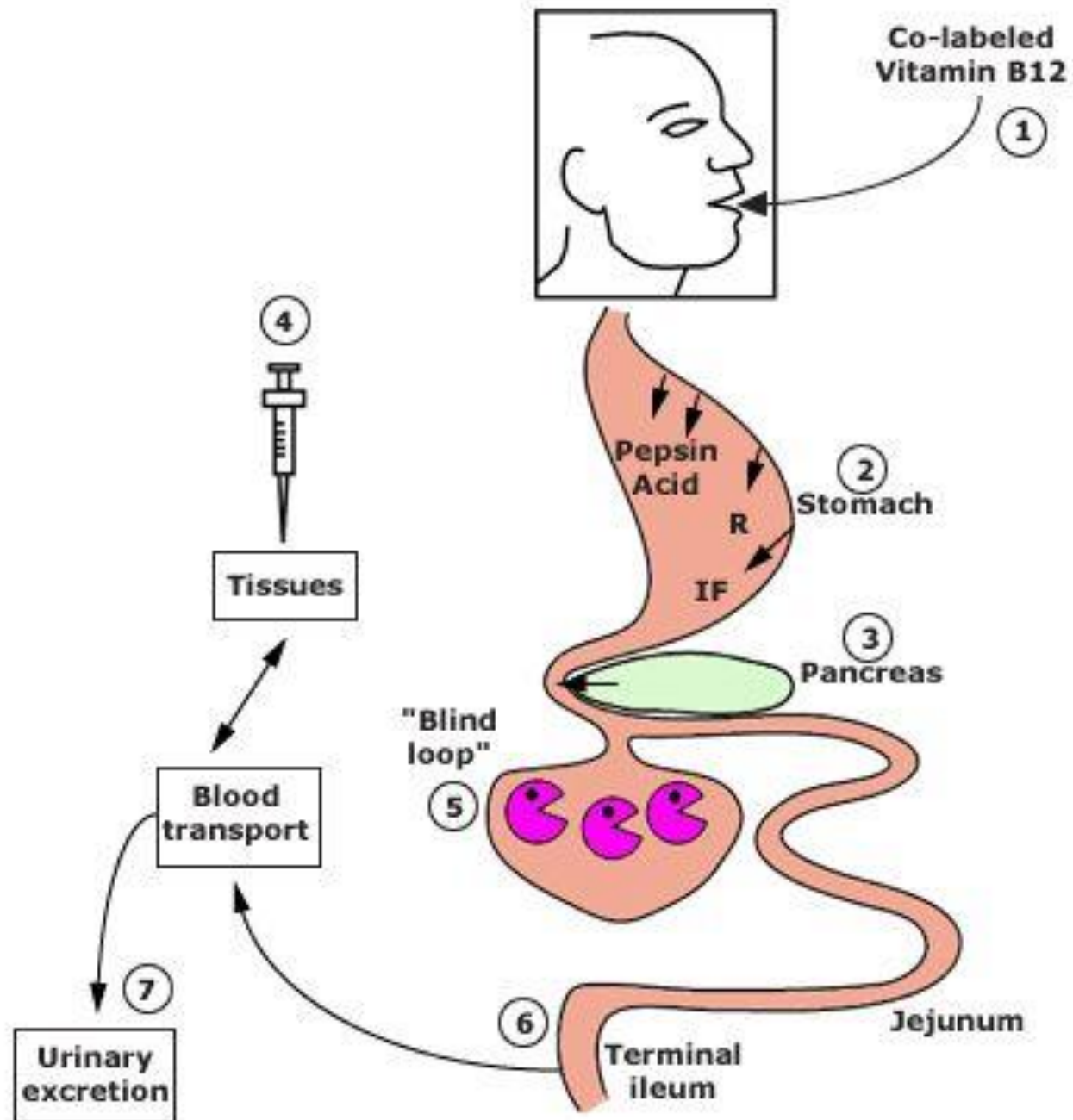
- Effect of SBBO:
 - ✓ Bile acids metabolism – deconjugated bile acids
 - ✓ Bilirubin metabolism – deconjugated bilirubin
 - ✓ CHO metabolism – CO₂, H₂, D-lactic acid, organic acids (short chain fatty acids)
 - ✓ Lipid metabolism – short chain fatty acids
 - ✓ Protein metabolism – amines, ammonia

Small Bowel Bacterial Overgrowth

- Bloating, diarrhea, abdominal pain, weight loss, neuropathy
- B12 deficiency – utilized for nutrition
- Elevated folate level - produced by bacteria
- Vitamin A,D,E,K deficiency – therefore bruising, night blindness, bone diseases
- Iron deficiency
- Hypoproteinemia, hypoalbuminemia
- Fat and CHO malabsorption

Small Bowel Bacterial Overgrowth

- Jejunal culture – gold standard;
- C¹⁴-labeled bile acid breath test
- C¹⁴-xylose breath test
- H breath test
- Schilling's test



Small Bowel Bacterial Overgrowth- Schilling's test

TABLE 350e-1

DIFFERENTIAL RESULTS OF THE SCHILLING TEST IN SEVERAL DISEASES ASSOCIATED WITH COBALAMIN MALABSORPTION

	⁵⁸ Co-Labeled Cobalamin	With Intrinsic Factor	With Pancreatic Enzymes	After 5 Days of Antibiotics
Pernicious anemia	Reduced	Normal	Reduced	Reduced
Chronic pancreatitis	Reduced	Reduced	Normal	Reduced
Bacterial overgrowth	Reduced	Reduced	Reduced	Normal
Ileal disease	Reduced	Reduced	Reduced	Reduced

Small Bowel Bacterial Overgrowth

- Treat underlying cause
 - e.g. discontinue acid suppressive meds, treat inflammatory Crohn's disease, remove strictures, etc...
- Nutrition – replace fat soluble vitamins, B12
 - Low CHO diet to limit bacteria substrate
- 7 – 10 days of antibiotics
 - Metronidazole, Amox/Clav, Tetracycline, Doxycycline, Amoxicillin
 - May need to cycle Abx to avoid resistance
- Bowel cleanse with PEG
- Prokinetic
- Octreotide – at low dose, has a promotility effect;
 - causes hypomotility at higher doses
- Probiotics – minimal evidence

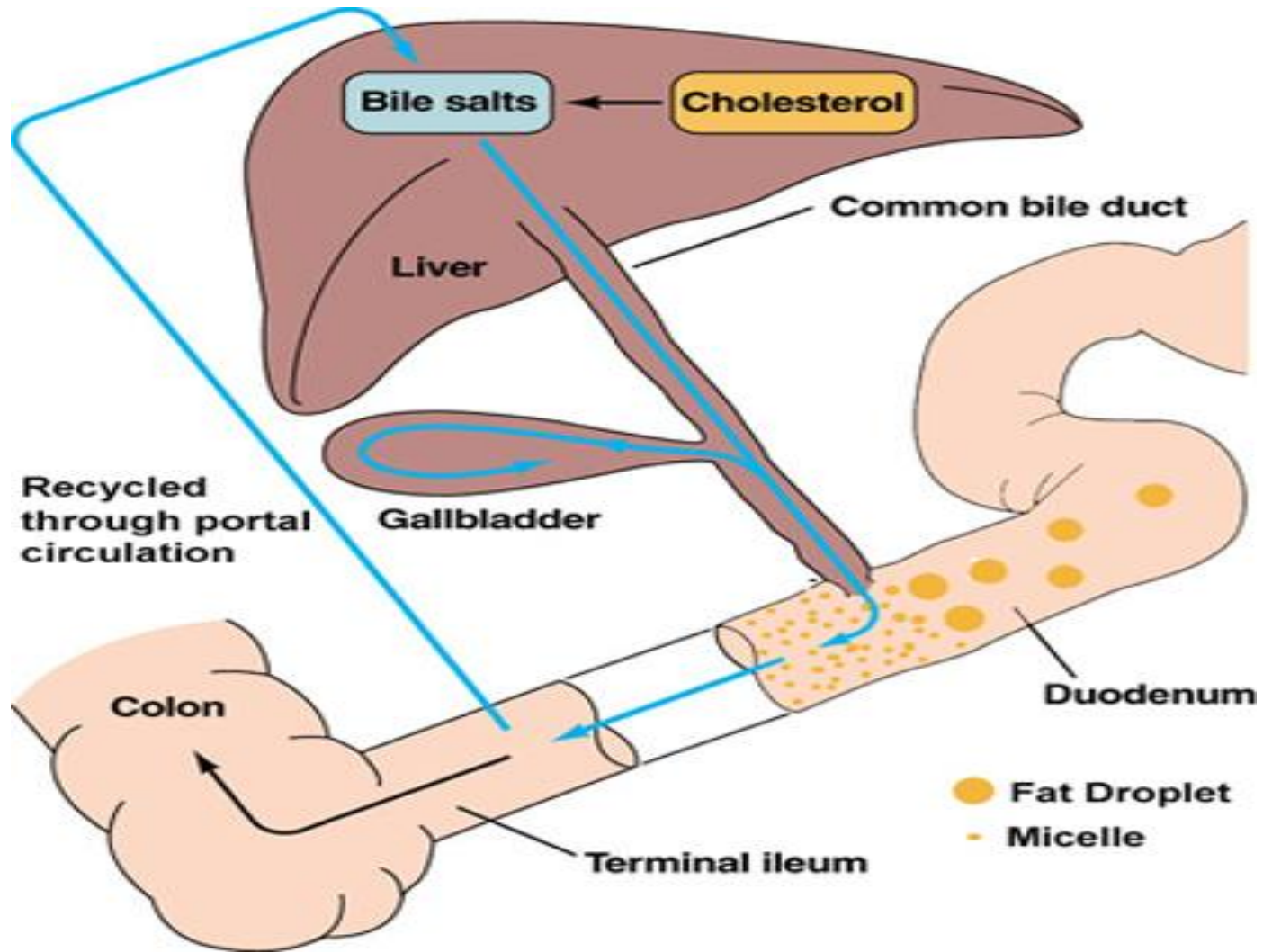
Tropical Sprue

- Is characterized by villous atrophy and crypt hyperplasia
- Most tropical regions of Asia, Africa, the Middle East, the Caribbean and Central and South America
 - It is an acquired defect – not present in newborns. Travelers from the industrialized world may develop it.
- Cause
 - Not known, but seems to be due to continuous bacterial contamination of the upper small bowel and nutritional deficiency

Tropical Sprue

- Chronic diarrhea often with steatorrhea, anorexia, abdominal cramps, bloating
 - B12 and folate deficiency
- If suspicion is high – jejunal aspirate and biopsy
- Management:
 - Folate & B12 Supplement
 - tetracycline for 3-6 months

Bile Acid-Induced Diarrhea



Exocrine Pancreatic Insufficiency

Enzyme secretion of pancreas and role in digestion

Secretion	Site of action	Active enzyme	Substrate and products
Pancreatic juice	duodenum	pancreatic amylase	starch → maltose
		trypsin	protein → peptides
		chymotrypsin	protein → peptides
		pancreatic lipase	fats → fatty acid + glycerol

Exocrine Pancreatic Insufficiency

Diseases and Mechanisms Associated With Exocrine Pancreatic Insufficiency

Disease or Condition	Pathologic Mechanism
Chronic pancreatitis, CF, diabetes, sequelae of acute necrotizing pancreatitis, hereditary pancreatitis	Loss of pancreatic parenchyma (responsible for most cases of EPI)
Periampullary tumors, IPMN, pancreatic head carcinoma, benign pancreatic tumors	Obstruction of main pancreatic duct
Celiac disease, Crohn disease, Schwachman-Diamond syndrome	Decreased pancreatic stimulation
Zollinger-Ellison syndrome	Acid-mediated inactivation of pancreas enzymes
Gastrectomy, gastric bypass, extensive small bowel surgery	Gastrointestinal/pancreatic surgery

Take Home Messages

- Chronic diarrhea (>4 weeks) can be osmotic, secretory, inflammatory or fatty diarrhea.
- Fecal osmotic gap is helpful to point toward osmotic diarrhea
- Iron, Ca & folate are absorbed in proximal bowel; while B12 is absorbed in ileum.

Take Home Messages

- Celiac disease:
 - ✓ Should always be suspected in patients with iron-def anemia, diarrhea or dyspepsia.
 - ✓ Anti-TTG is most helpful.
 - ✓ Biopsy shows villus atrophy.
 - ✓ Gluten-free diet
 - ✓ Watch for complications: nutritional & malignancy

Take Home Messages

- Whipple Disease:
 - ✓ Chronic systemic infection by *Tropheryma whipplei*
 - ✓ Has GI, CNS, CVS, MSK & skin manifestations
 - ✓ Biopsy: Foamy macrophages & PAS-positive granular particles
- SBBO:
 - ✓ Look for & treat underlying causes
 - ✓ B12 def
 - ✓ Schilling's test
- Tropical Sprue:
 - ✓ Hx of travel to tropical area for long period

Take Home Messages

- Exocrine pancreatic insufficiency:
 - ✓ Mainly in patients with chronic pancreatitis
 - ✓ Steatorrhea
 - ✓ Improves with pancreatic enzymes replacement therapy
- Bile acid-induced diarrhea:
 - ✓ Watery diarrhea
 - ✓ Improves with cholestyramine