


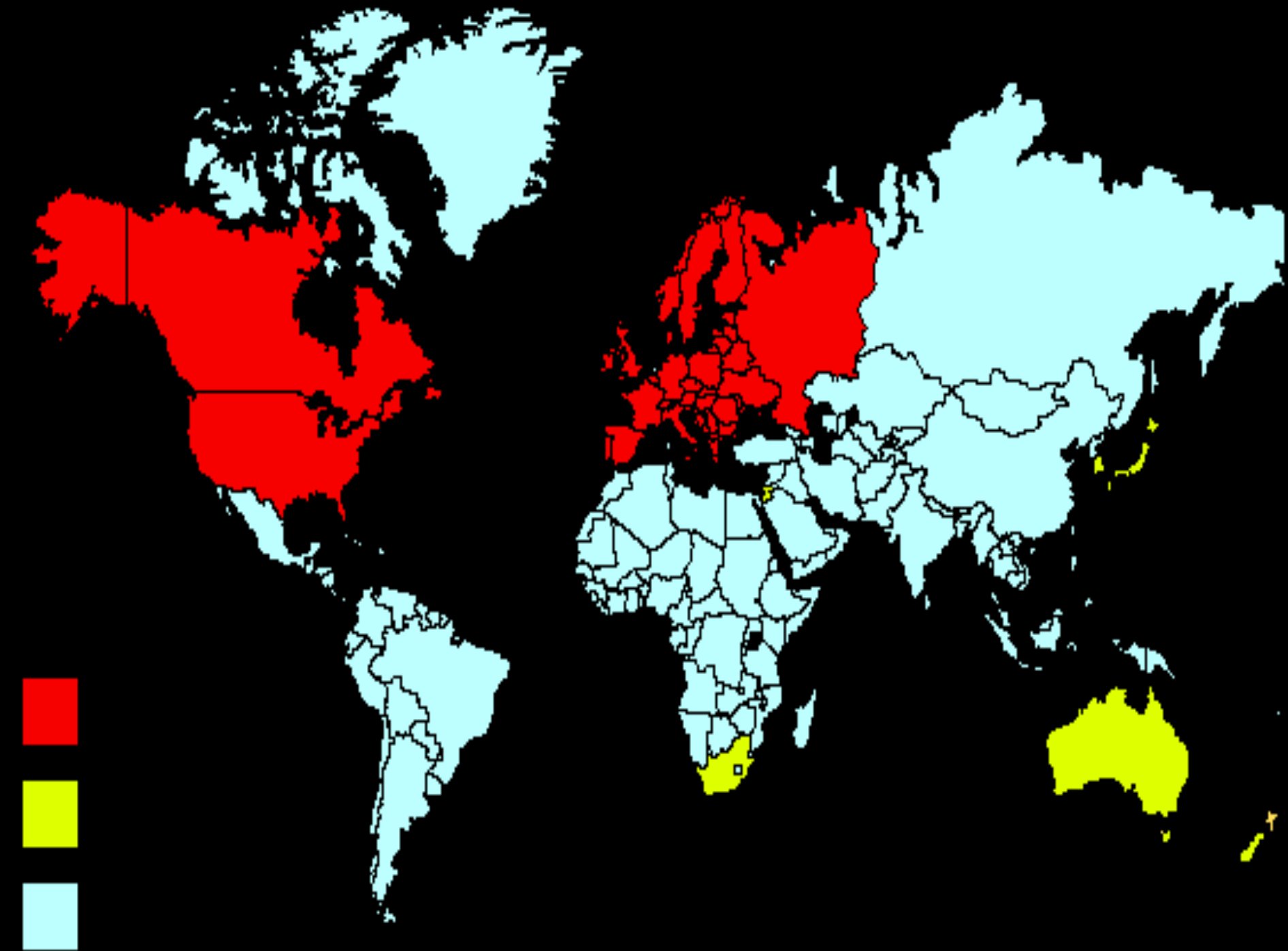
Inflammatory Bowel Disease

Othman alharbi, FRCPC

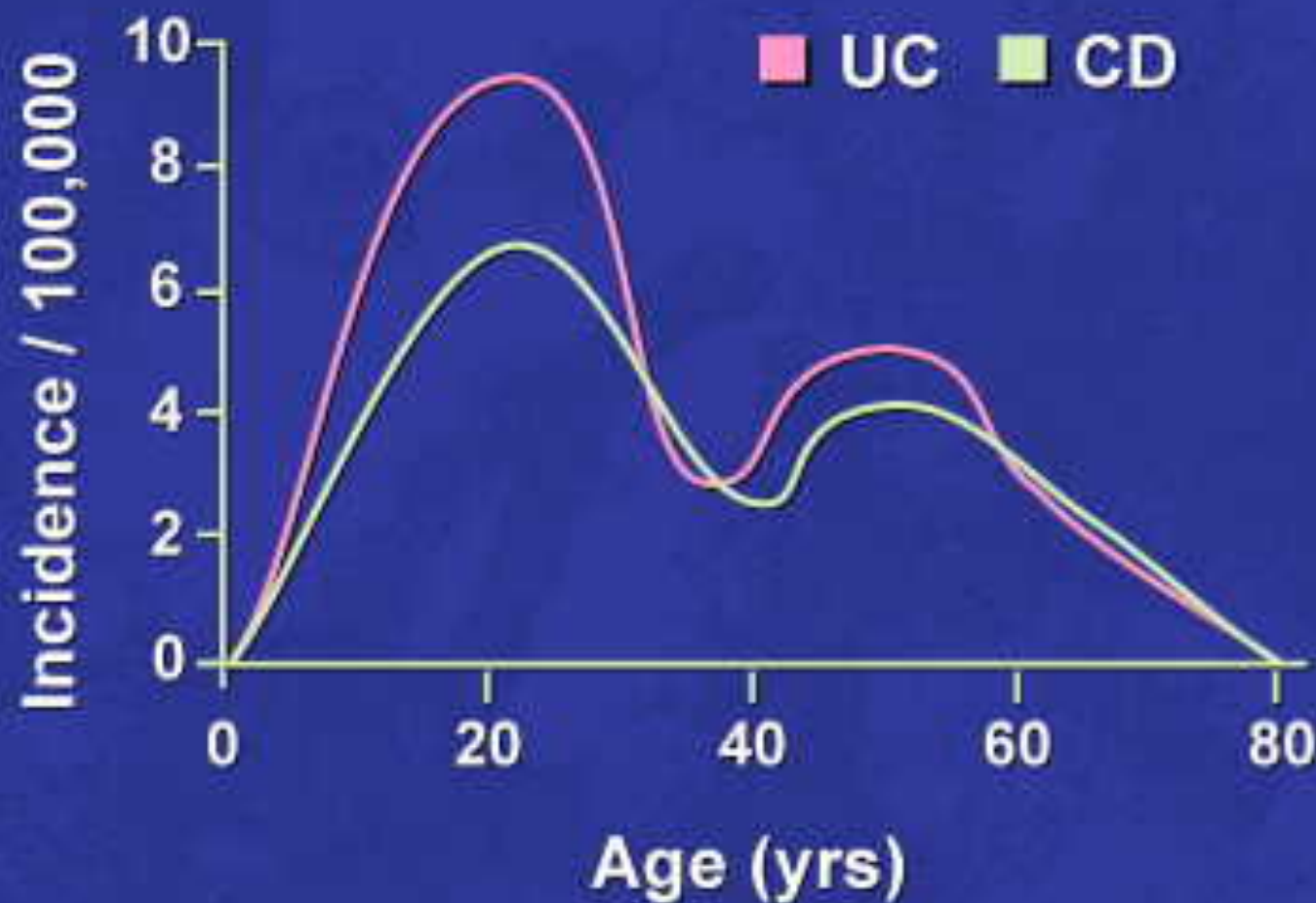
- 
- Inflammatory bowel disease (IBD) is comprised of two major disorders:
 - Ulcerative colitis (UC).
 - Crohn's disease (CD).
 - These disorders have both distinct and overlapping pathologic and clinical characteristics.

Epidemiology

- IBD is more common in the West, but the incidence is increasing in the developing countries including Saudi Arabia.
- IBD can present at any age:
 - The peak :15 - 30 years.
 - A second peak 50



Age-Specific Incidence of IBD



Lashner BA. In: Stein SH, *Inflammatory Bowel Disease: A Guide for Patients and Their Families*, 1999



- HOST FACTORS

- Genetic factors: NOD2 / CARD15

- ENVIRONMENTAL FACTORS

- Smoking:
- Appendectomy: protect UC

- Diet

Etiologic Hypotheses

Persistent infection

- Mycobacteria
- *Helicobacter* sp.
- Measles-mumps
- Listeria
- Toxigenic *E. coli*

Defective mucosal integrity

- Altered mucus
- Increased permeability
- Cellular starvation
- Impaired restitution



IBD

Dysbiosis

- ↓ protective bacteria
- ↑ aggressive commensals

Dysregulated immune response

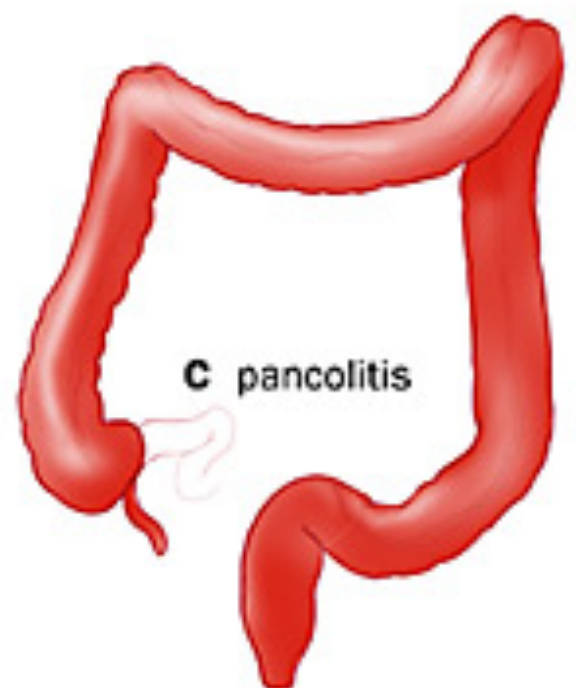
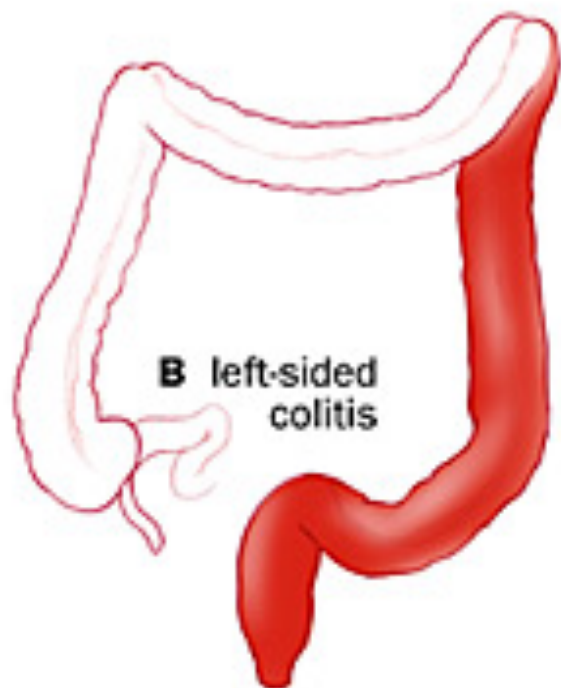
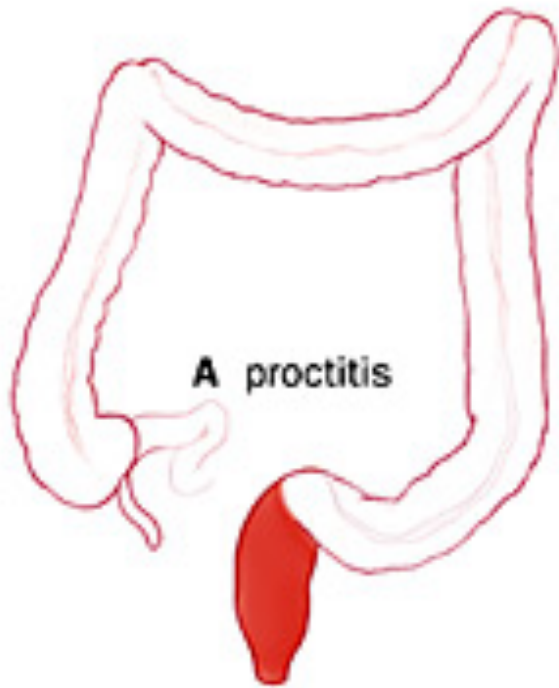
- Loss of tolerance
- Aggressive cellular activation
- Defective apoptosis





Ulcerative colitis


- Ulcerative colitis is characterized by recurring episodes of inflammation limited to the mucosal layer of the colon.
- Start rectum then extend proximally.

- Ulcerative proctitis :rectum.
- Ulcerative proctosigmoiditis :rectum and sigmoid colon.
- Left-sided colitis: disease that extends beyond the rectum and as far proximally as the splenic flexure.
- Extensive colitis :beyond the splenic flexure.
- Pancolitis: whole colon



- 
- 40-50% of patients have disease limited to the rectum and rectosigmoid
 - 30-40% of patients have disease extending beyond the sigmoid
 - 20% of patients have pancolitis

- 
- The major symptoms of UC are:
 - diarrhea
 - rectal bleeding
 - tenesmus
 - passage of mucus
 - crampy abdominal pain

- 
- Patients with proctitis usually pass **fresh blood or blood-stained mucus either mixed with stool or streaked onto the surface** of normal or hard stool
 - When the disease extends beyond the rectum, blood is usually mixed with stool or grossly bloody diarrhea may be noted
 - When the disease is severe, patients pass a liquid stool containing blood, pus, fecal matter
 - Other symptoms in moderate to severe disease include: anorexia, nausea, vomiting, fever, weight loss



- **DIAGNOSIS —**

- No single modalities is enough for Diagnosis.
- Combination of Clinical picture, laboratory, Endoscopy, pathology.

Colonoscopy

- The vascular markings are lost, petechiae, exudates, touch friability, and frank hemorrhage may be present.
- Colonic involvement is continuous in ulcerative colitis, in contrast to the patchy nature of Crohn's disease.

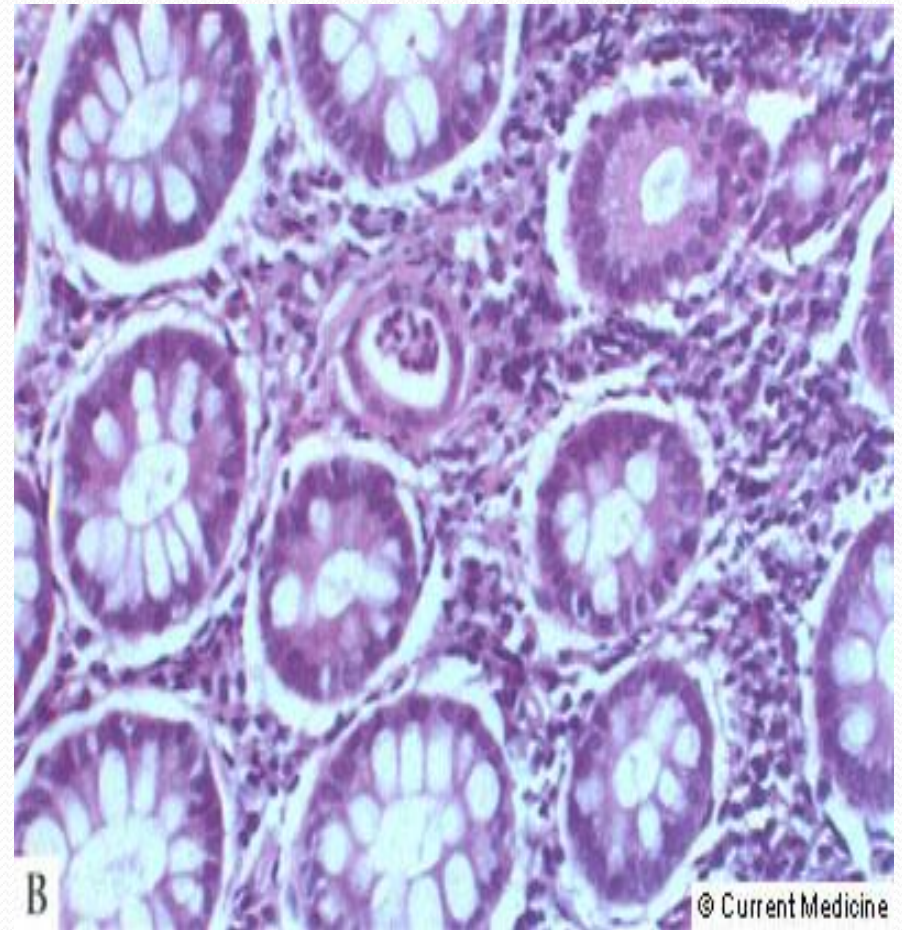
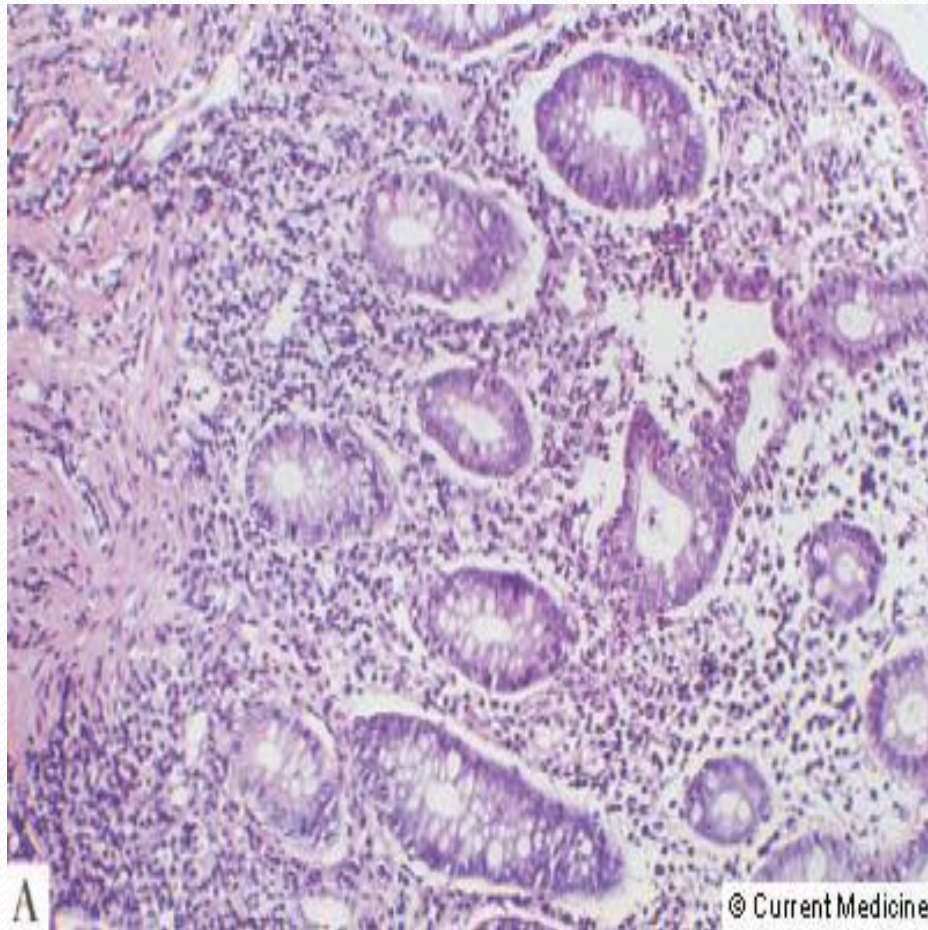


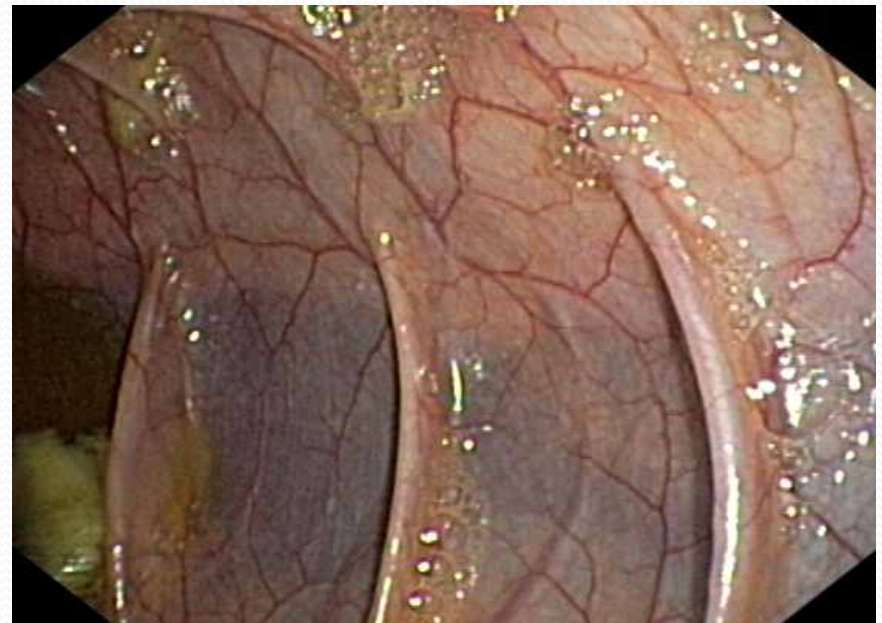
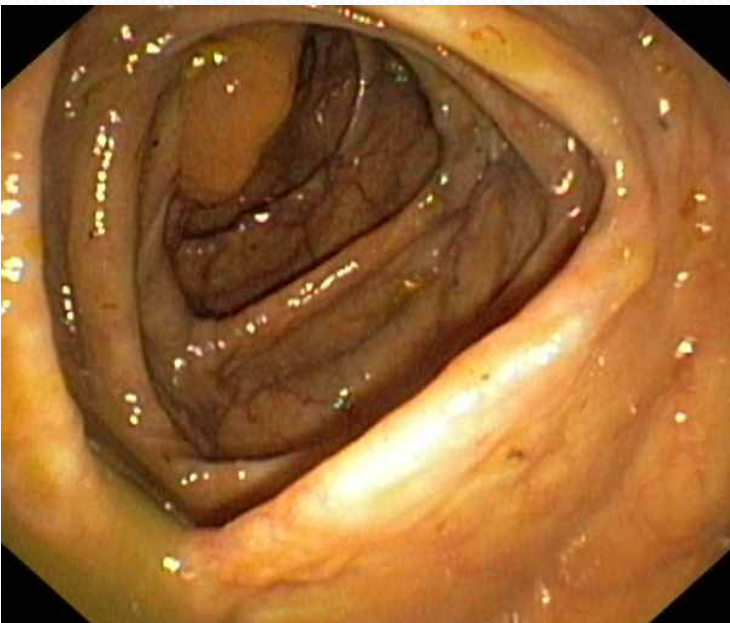
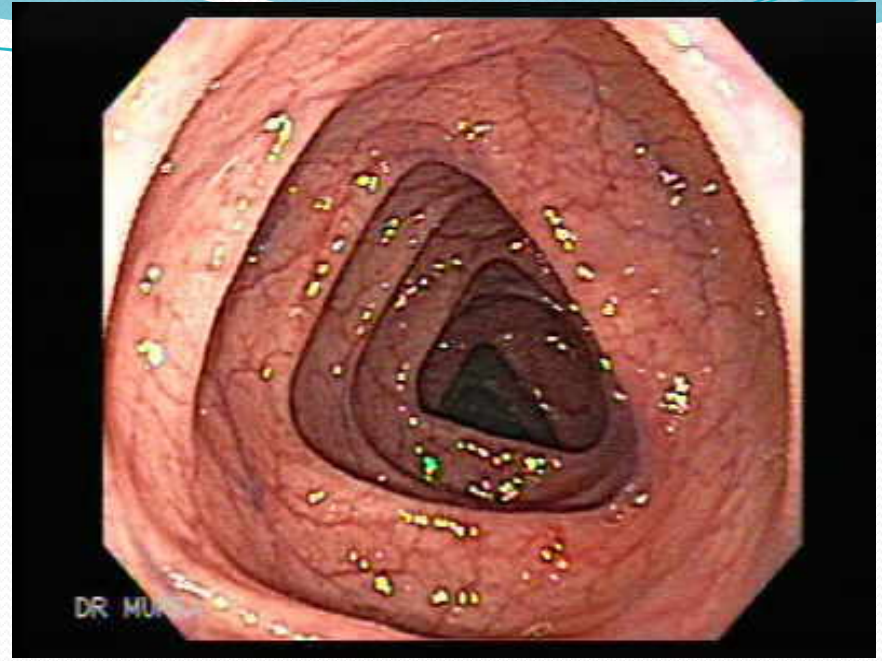
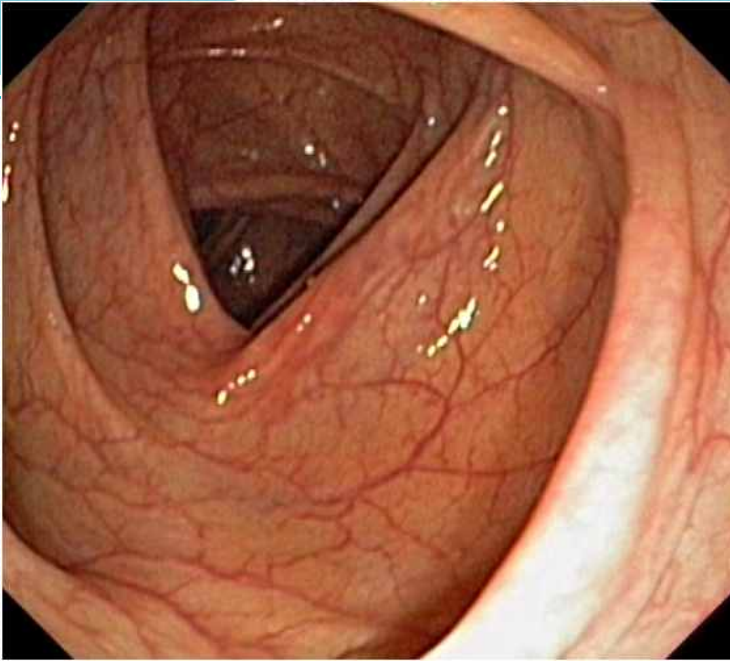
- Pathology:

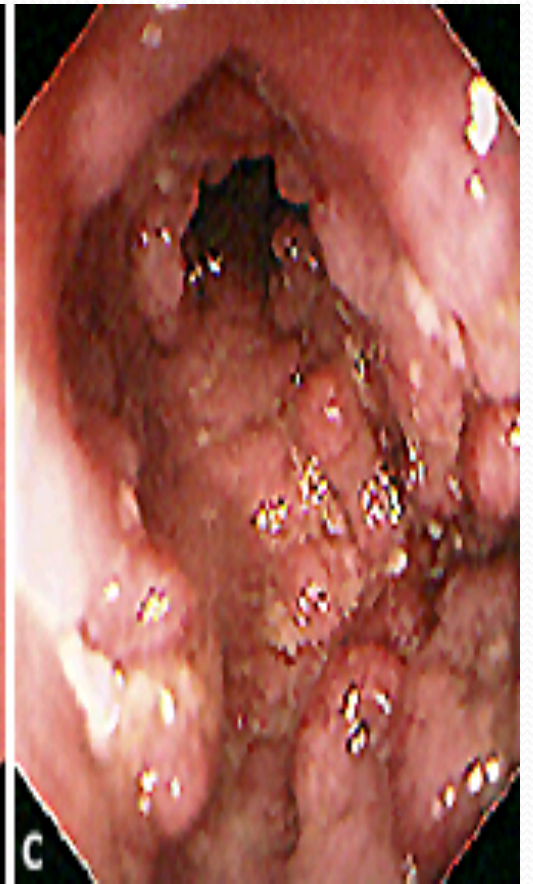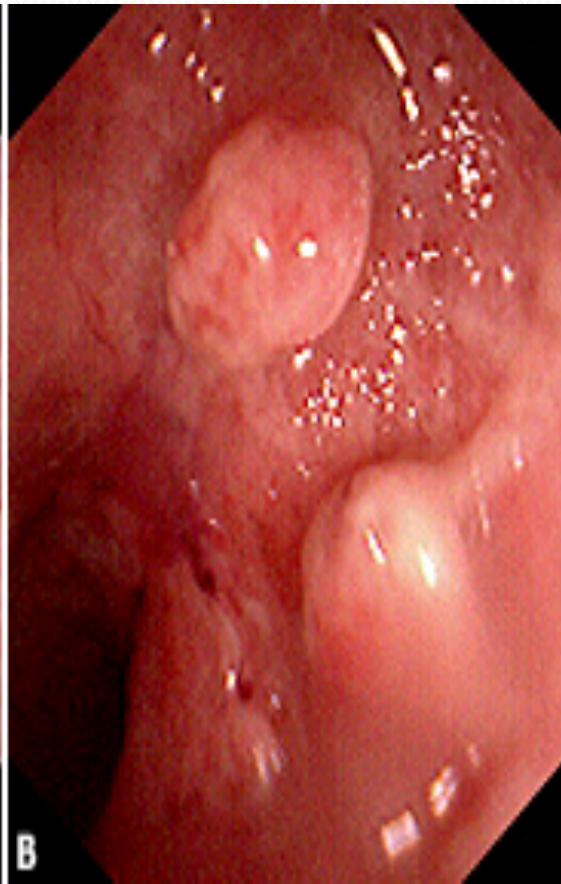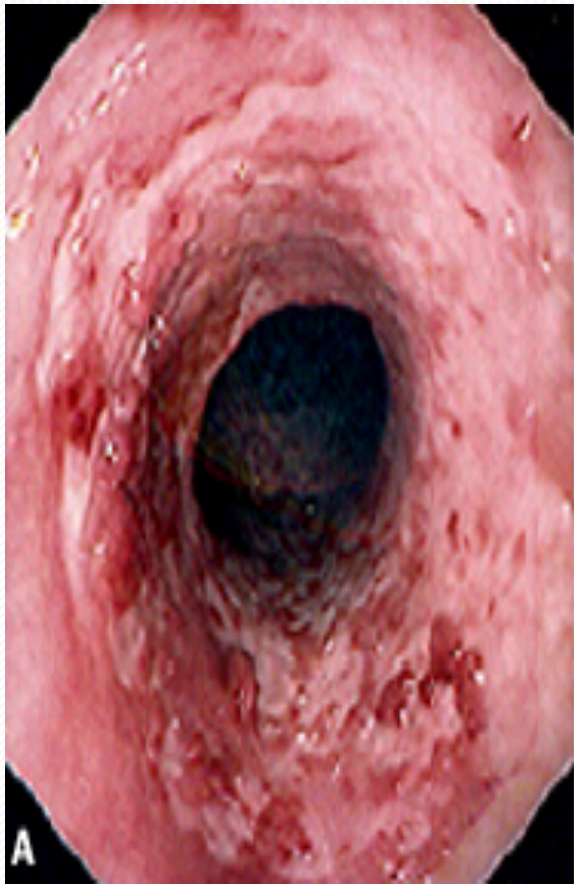- crypt abscesses.

- chronic changes including branching of crypts, atrophy of glands, and loss of mucin in goblet cells

UC







Ulcerative colitis - complication

- Hemorrhage
- Perforation
- Toxic megacolon (transverse colon with a diameter of more than 5,0 cm to 6,0 cm with loss of haustration)
- Colon cancer

managements

- Goals of therapy
 - Induce and maintain remission.
 - Ameliorate symptoms
 - Improve pts quality of life
 - Adequate nutrition
 - Prevent complication of both the disease and medications

managements

- Role out infection
- 5 ASA therapy:
 - Oral
 - Rectal
- Corticosteroids:
 - Systemic: Prednisolone
 - Local acting: enema.
- Immunomodulators :
 - Azithyoprine
 - Methotrexate
- Anti TNF therapy


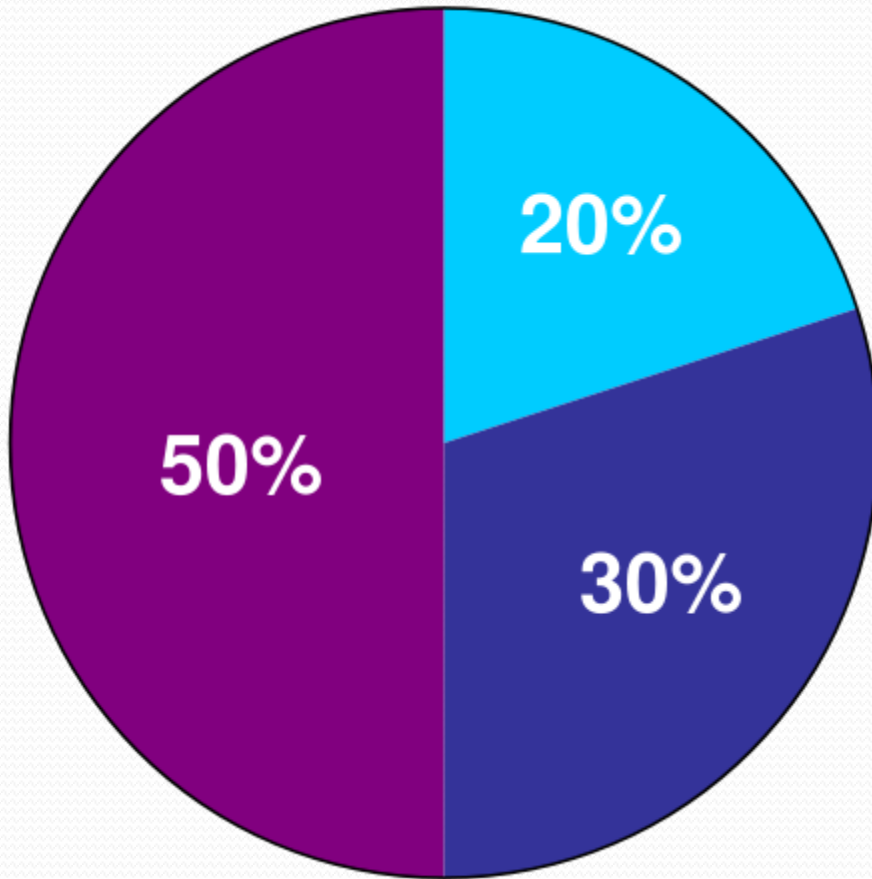


- Surgery:

- Severe attacks that fail to respond to medical therapy.
- Complications of a severe attack (e.g., perforation, acute dilatation).
- Chronic continuous disease with an impaired quality of life.
- Dysplasia or carcinoma.

CD

- Crohn's disease (CD) is a disorder of uncertain etiology that is characterized by transmural inflammation of the gastrointestinal tract.
- CD may involve the entire gastrointestinal tract from mouth to the perianal area.
 - 80% Small bowel.
 - 50 % ileocolitis.
 - 20 % colon.
 - 30% perianal disease.
 - UGI < 5 %



CLINICAL MANIFESTATIONS

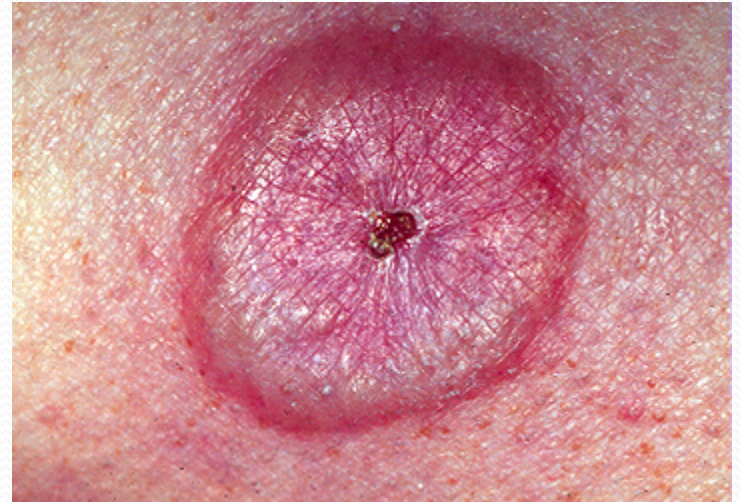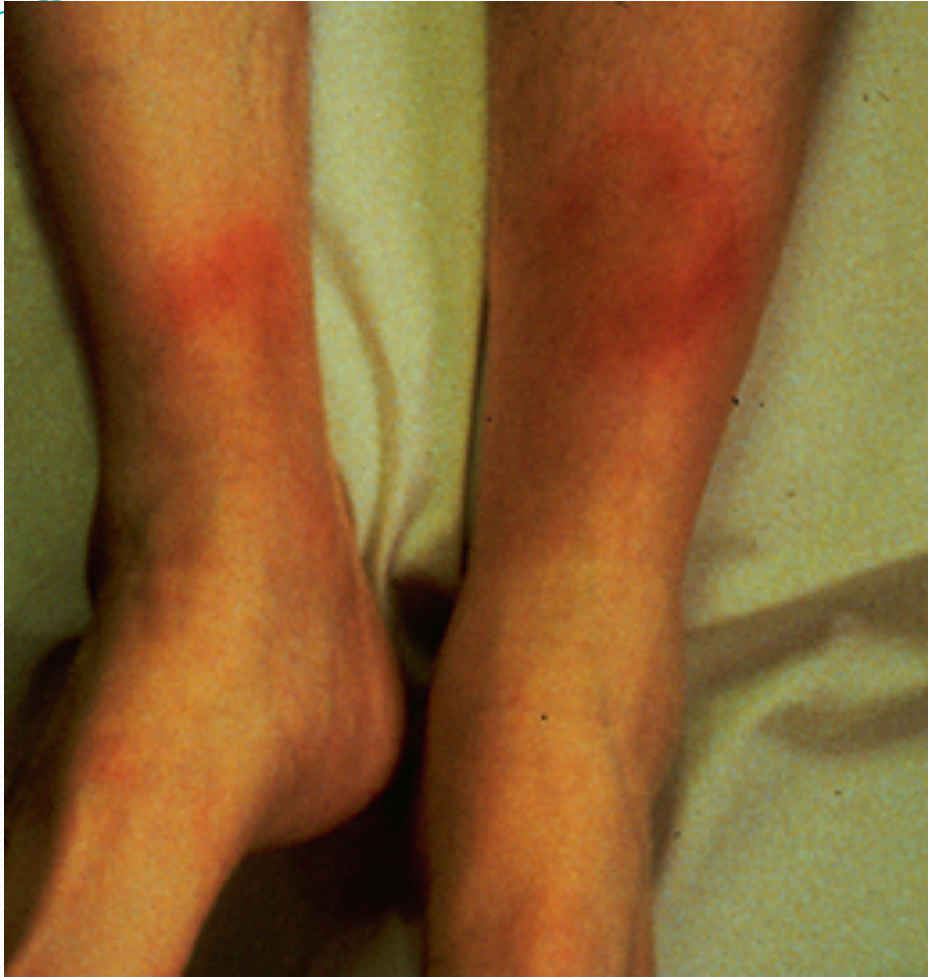- Fatigue.
- Diarrhea.
- Abdominal pain.
- Weight loss.
- Fever.

- **Phlegmon/abscess :**
 - walled off inflammatory mass without bacterial infection
- **Fistulas :**
 - Fistulas are tracts or communications that connect two epithelial-lined organs.
 - Enterovesical
 - Enterocutaneous
 - Enteroenteric
 - enterovaginal
- **Perianal disease**

- Severe oral involvement
 - aphthous ulcers.
- Esophageal involvement
 - odynophagia and dysphagia.
- Gastroduodenal CD
 - upper abdominal pain and symptoms of gastric outlet obstruction.
- Gallstones

Extraintestinal manifestations

- CD and ulcerative colitis share a number of extraintestinal manifestations
- **Arthritis**
- **Eye involvement** –uveitis, iritis, and episcleritis
- **Skin disorders.**
- **Others:**
 - **Primary sclerosing cholangitis, Venous and arterial thromboembolism ,Renal stones ,Bone loss and osteoporosis ,Vitamin B12 deficiency**



DIAGNOSIS

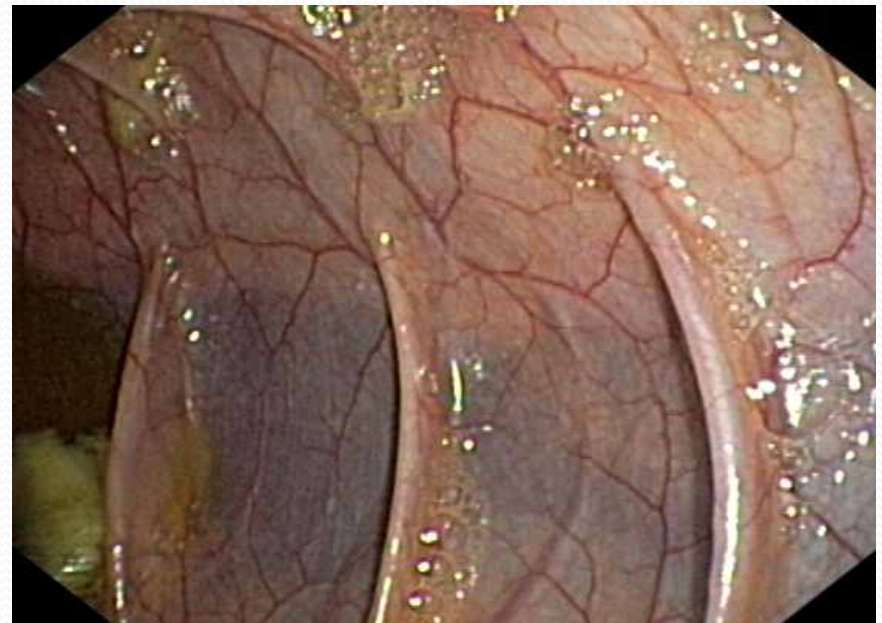
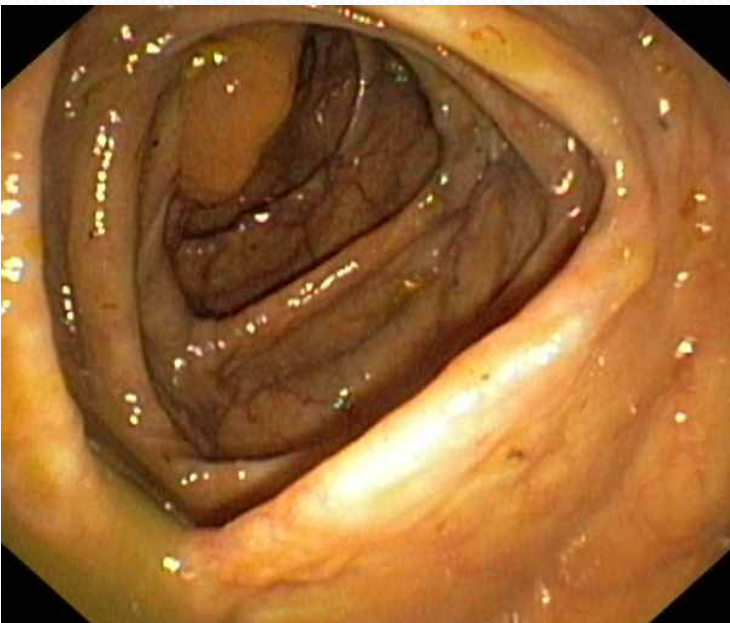
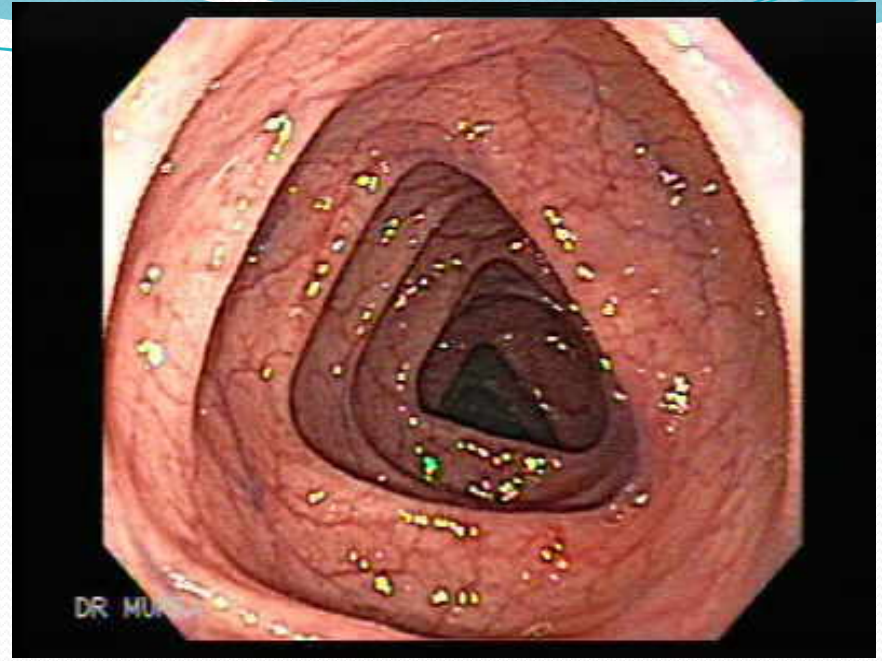
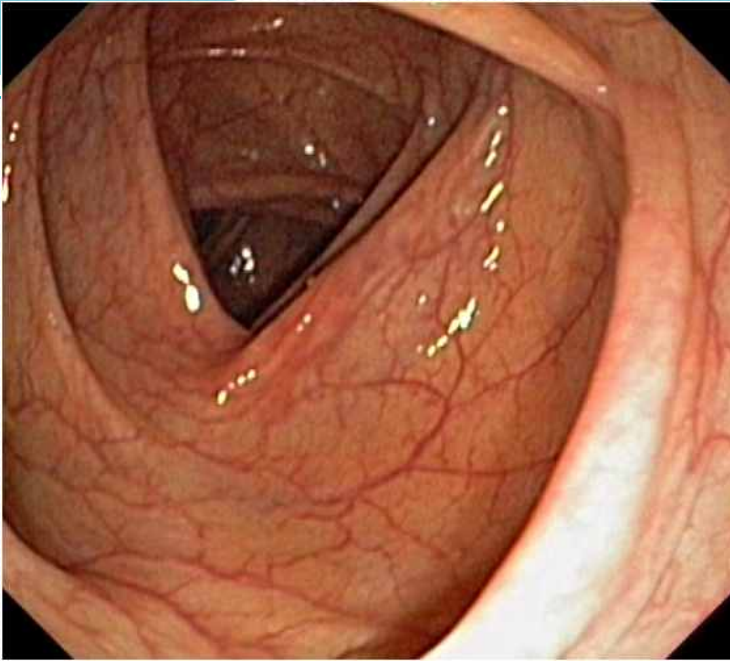
- The diagnosis of CD is usually established with endoscopic findings or imaging studies in a patient with a compatible clinical history.

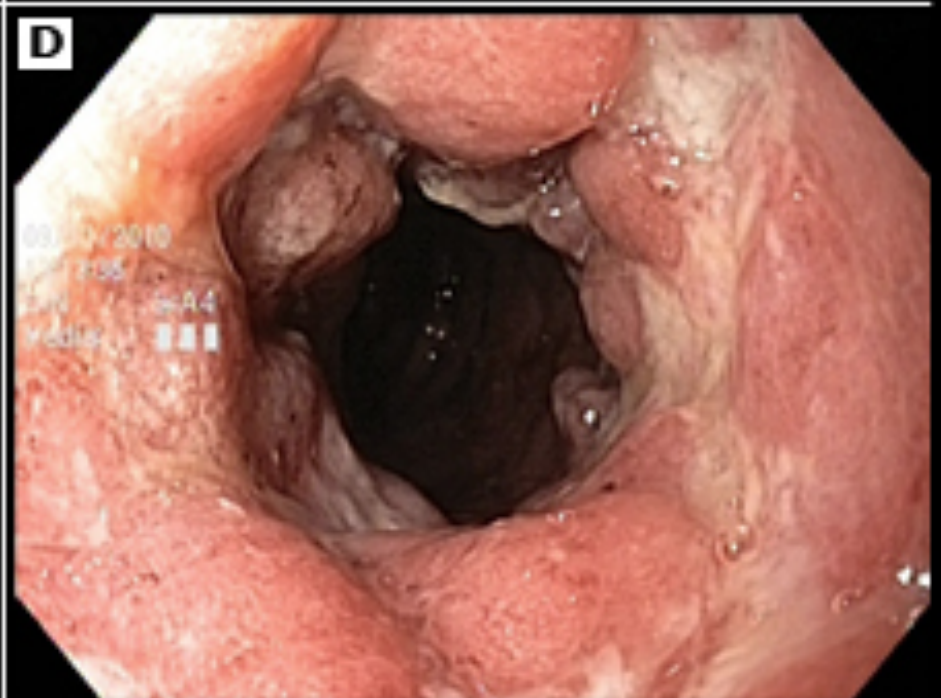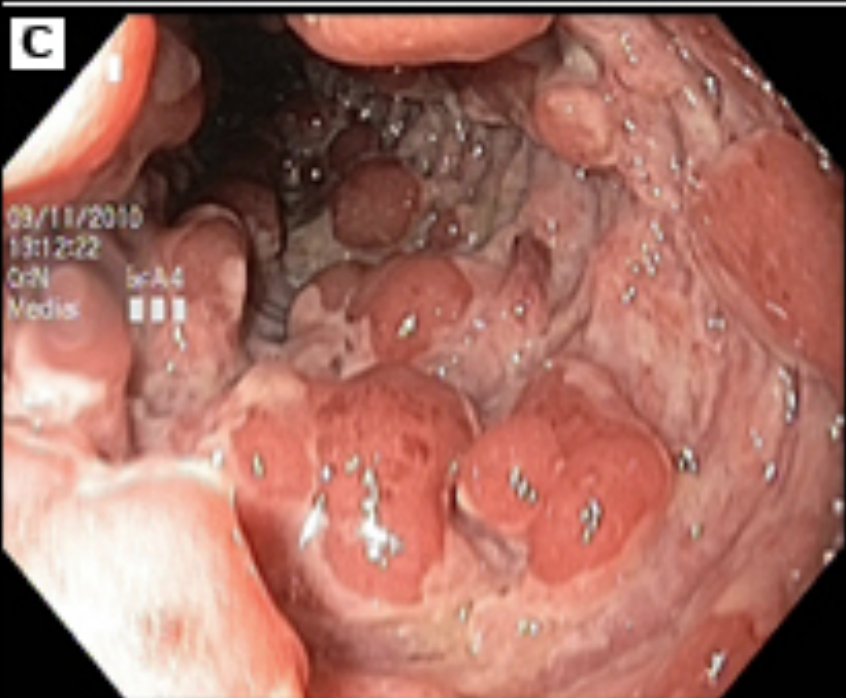
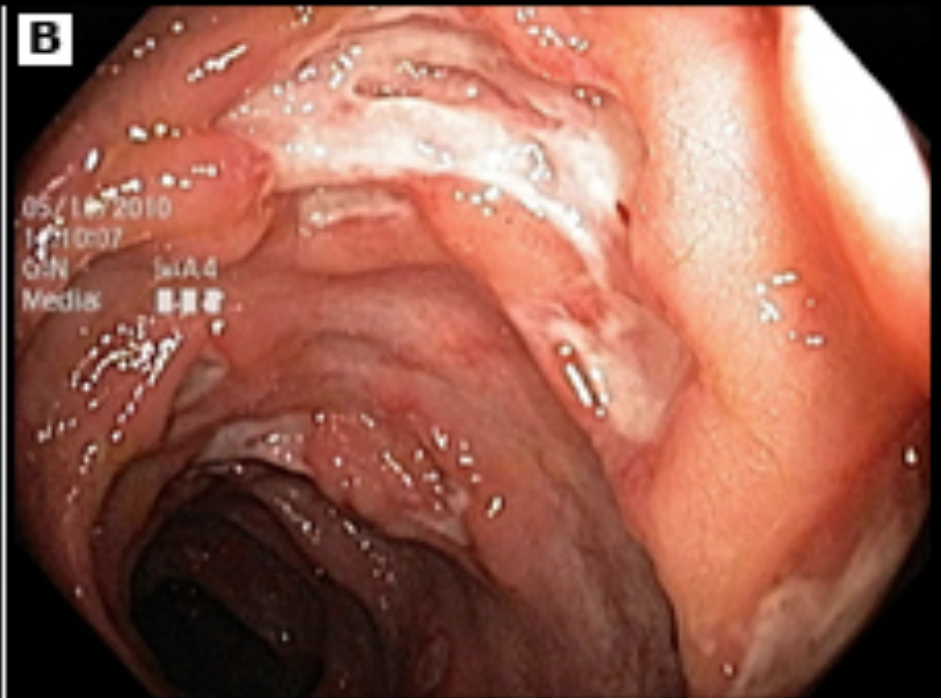

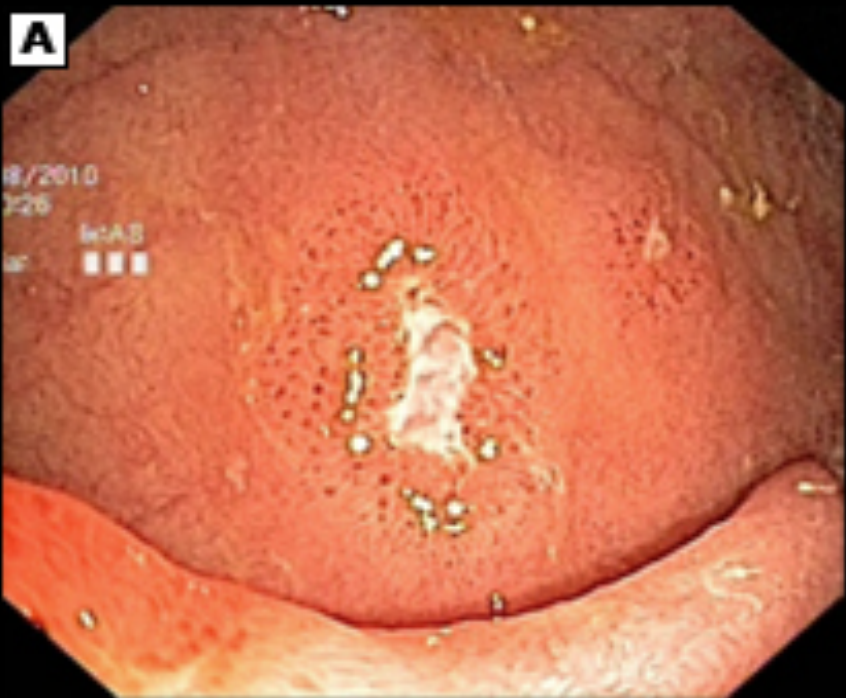
- **Colonoscopy:**

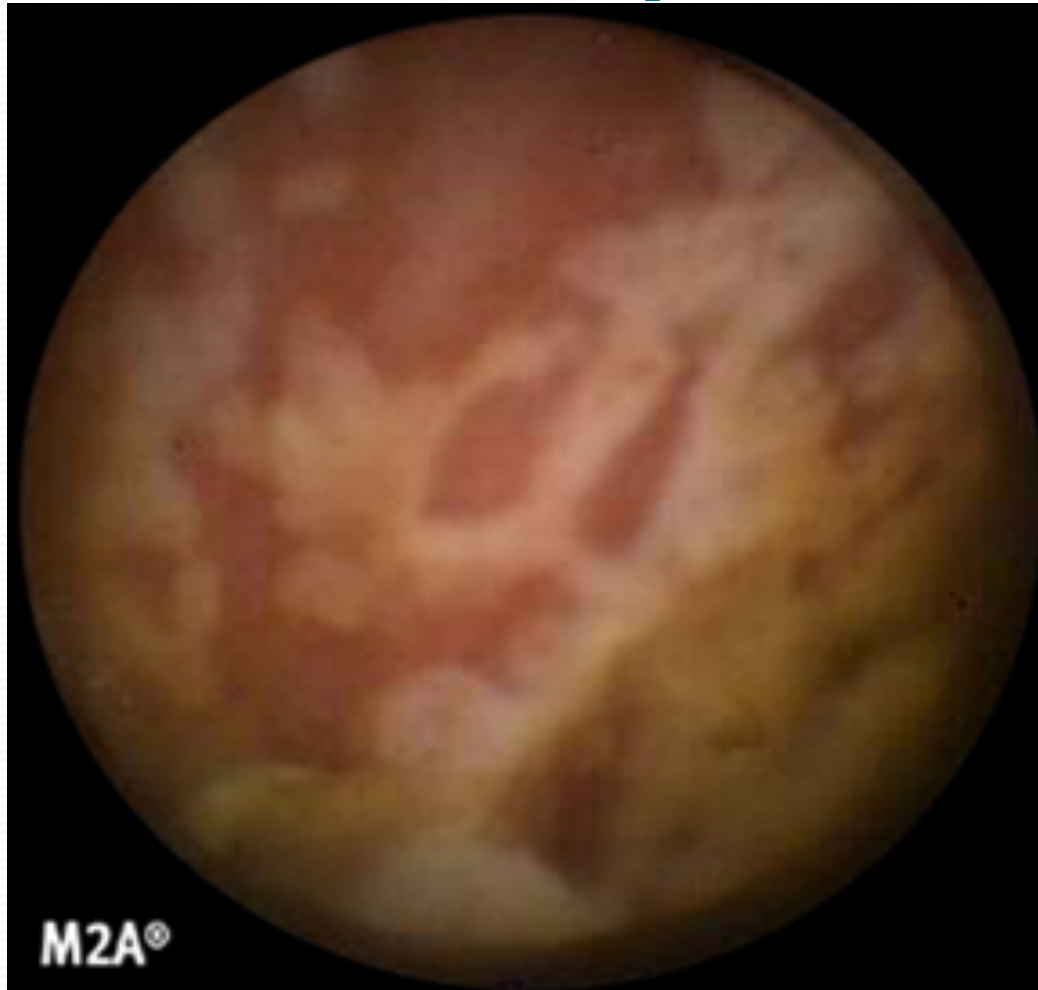- Endoscopic features include focal ulcerations adjacent to areas of normal appearing mucosa along with polypoid mucosal changes that give a cobblestone

- **Wireless capsule endoscopy**





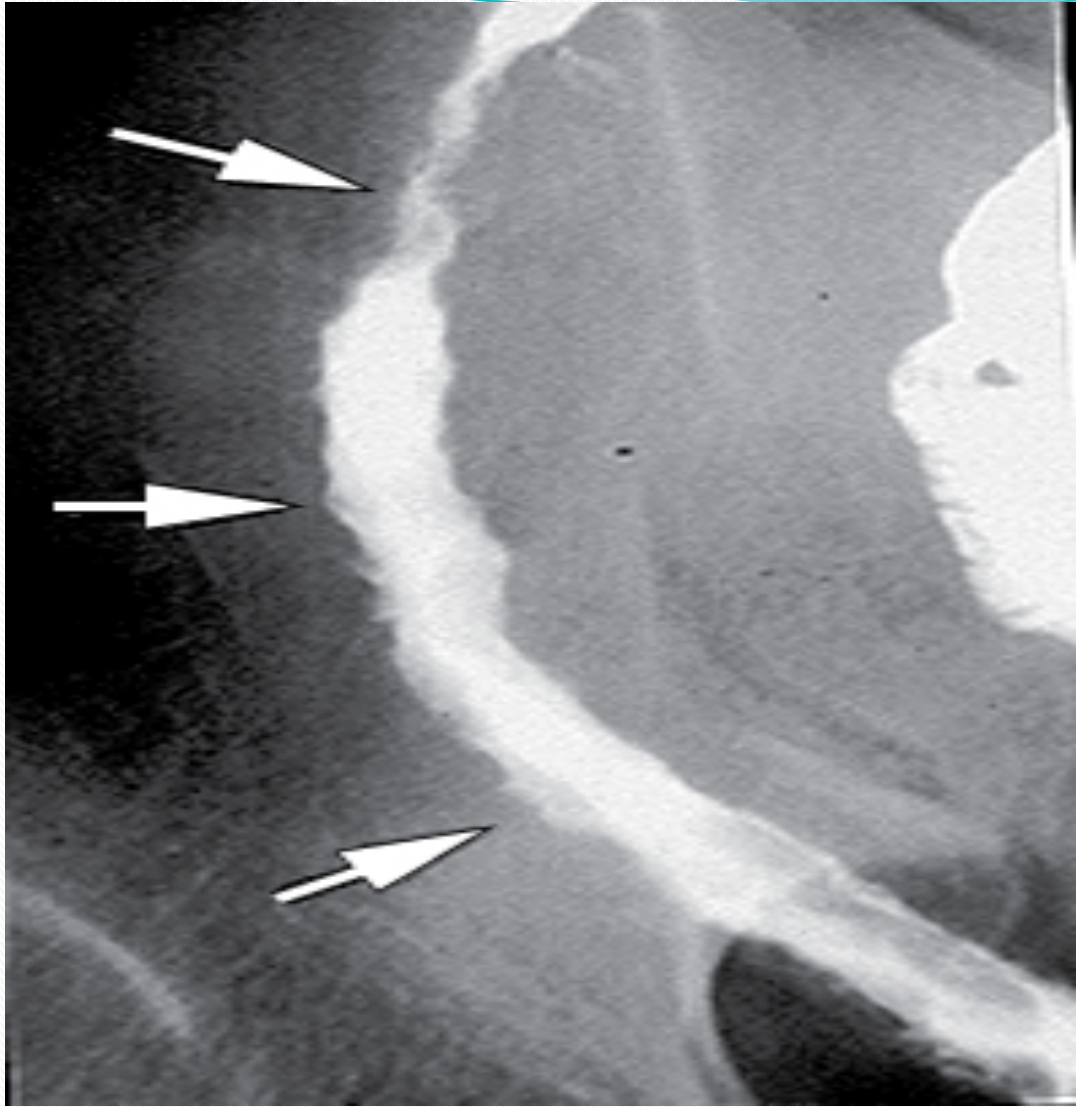
Wireless capsule endoscopy





- **Imaging studies**

- small bowel follow through (SBFT)
- computed tomography: CTS or CT enterography
- Magnetic resonance imaging (MRI) or MR enterography





- **Serologic markers**


- Inflammatory marker : ERS, CRP

- **Antibody tests :**

- Antineutrophil cytoplasmic antibodies (pANCA)


- Anti-Saccharomyces cerevisiae antibodies (ASCA)

- **Stool markers** — fecal calprotectin

- 
- Goals of therapy
 - Induce and maintain remission.
 - Ameliorate symptoms
 - Improve pts quality of life
 - Adequate nutrition
 - Prevent complication of both the disease and medications

Management

- Role out infection
- Corticosteroids:
 - Systemic: Prednisolone
 - Local acting: Budosonide.
- Immunomodulators :
 - azithyoprine
 - Methotrexate

- 
- Anti TNF therapy
 - Surgery
 - Obstruction, severe perianal disease unresponsive to medical therapy, difficult fistulas, major bleeding, severe disability

Distinguishing characteristics of CD and UC

Feature	CD	UC
Location	SB or colon	colon
Anatomic distribution	Skip lesions	Continuous
Rectal involvement	Rectal spare	Involved in >90%
Gross bleeding	Only 25%	Universal
Peri-anal disease	1/3	Rare
Fistulization	Yes	No
Granulomas	30%	No

Endoscopic features of CD and UC

Feature	CD	UC
Mucosal involvement	Discontinuous	Continuous
Aphthous ulcers	Common	Rare
Surrounding mucosa	Relatively normal	Abnormal
Longitudinal ulcer	Common	Rare
Cobble stoning	In severe cases	No
Mucosal friability	Uncommon	Common
Vascular pattern	Normal	distorted

Pathologic features of CD and UC

Feature	CD	UC
Transmural inflammation	Yes	Uncommon
Granulomas	30%	No
Fissures	Common	Rare
Fibrosis	Common	No
Submucosal inflammation	Common	Uncommon



Thank You