

# Interactive lecture

Dr. Abdulrahman Alhawas, MBBS

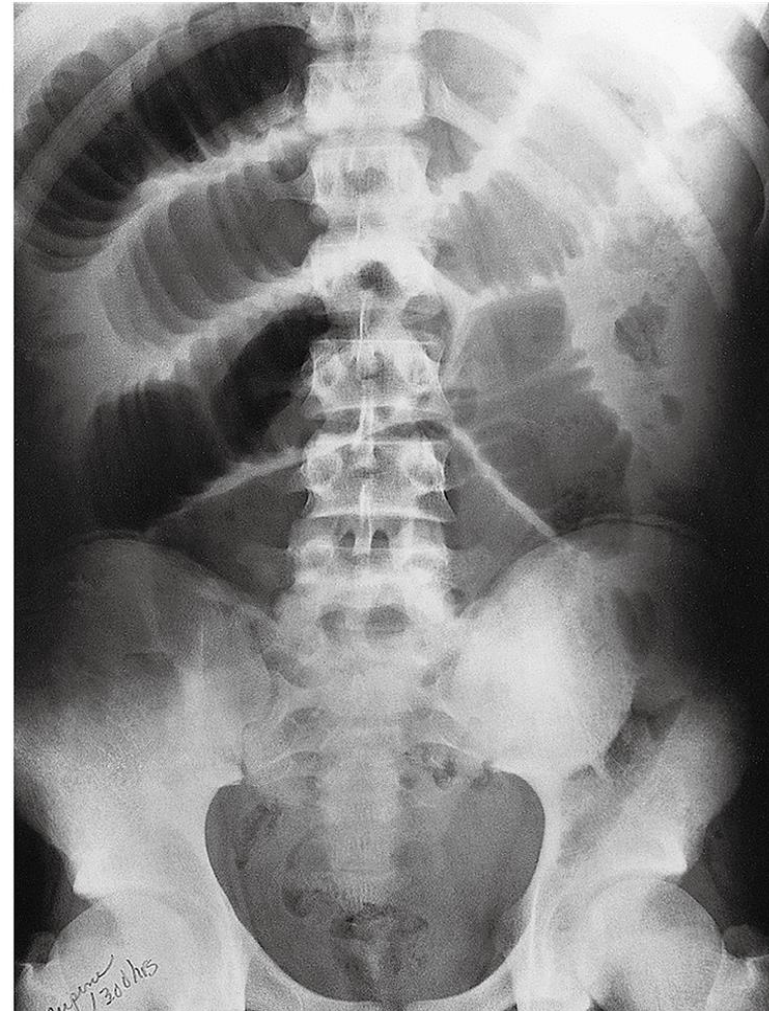
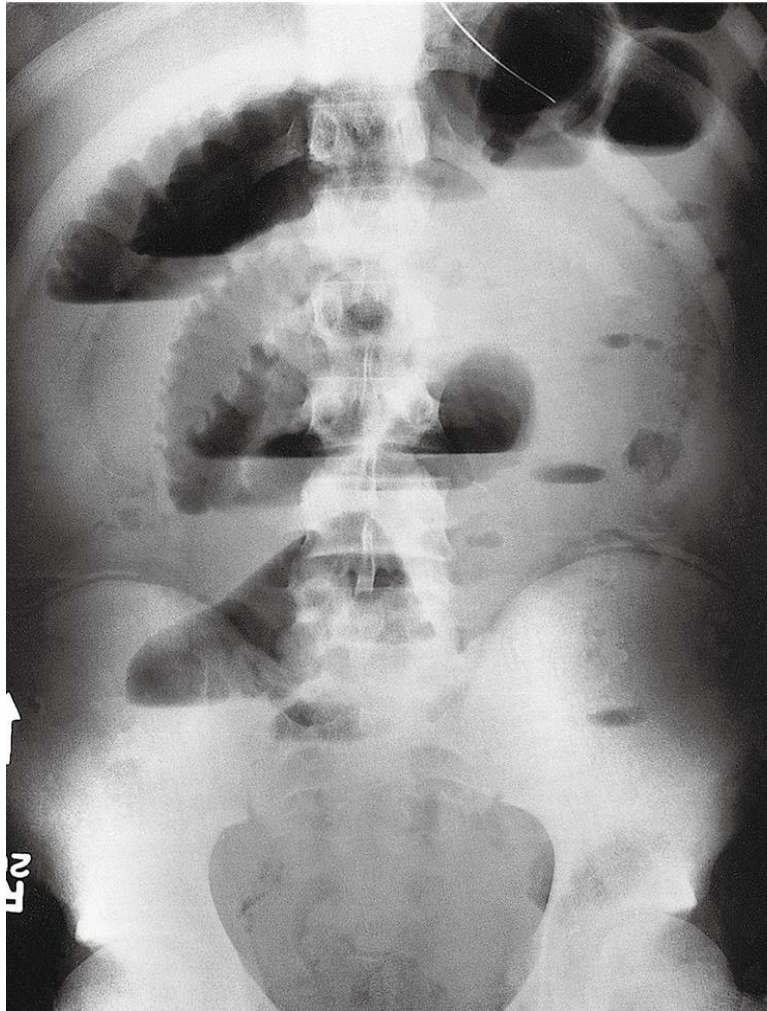Chairman and Assistant Professor

Radiology and Medical Imaging Department

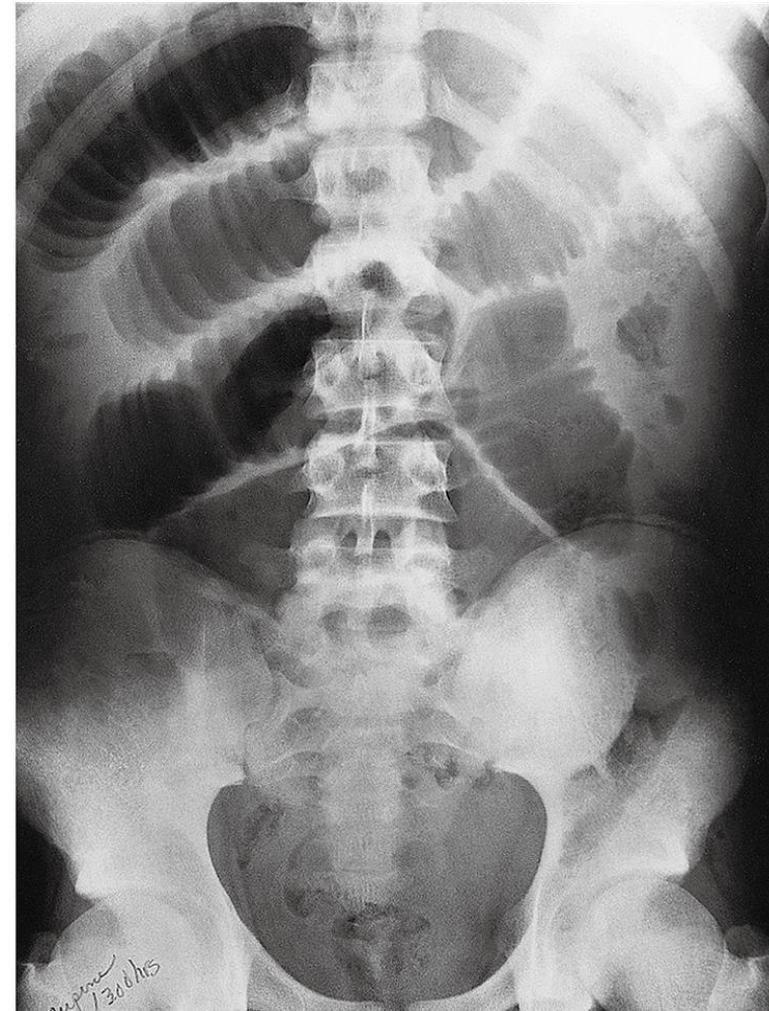
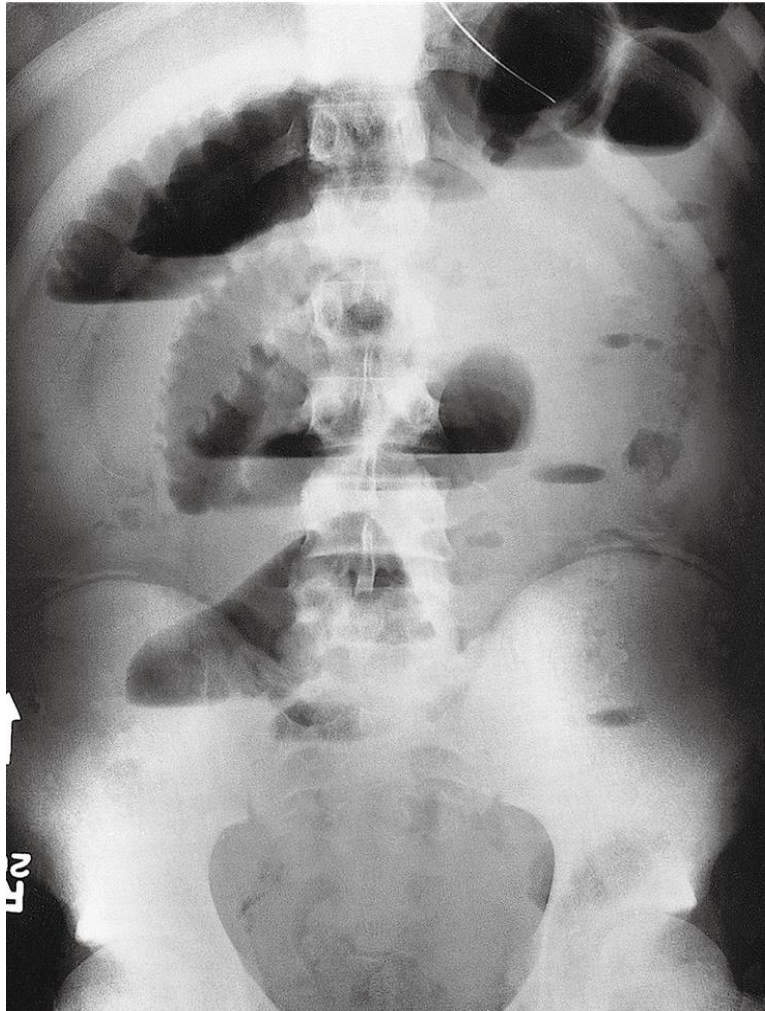
Name 5 radiological modalities

# Name 5 radiological modalities

- X-RAY
- Flouroscopy
- U/S
- MRI
- CT scan
- Nuclear Medicine
- Angiography



What is the modality?  
Mention 2 abnormalities?



What is the modality? **Plain X-RAYS**

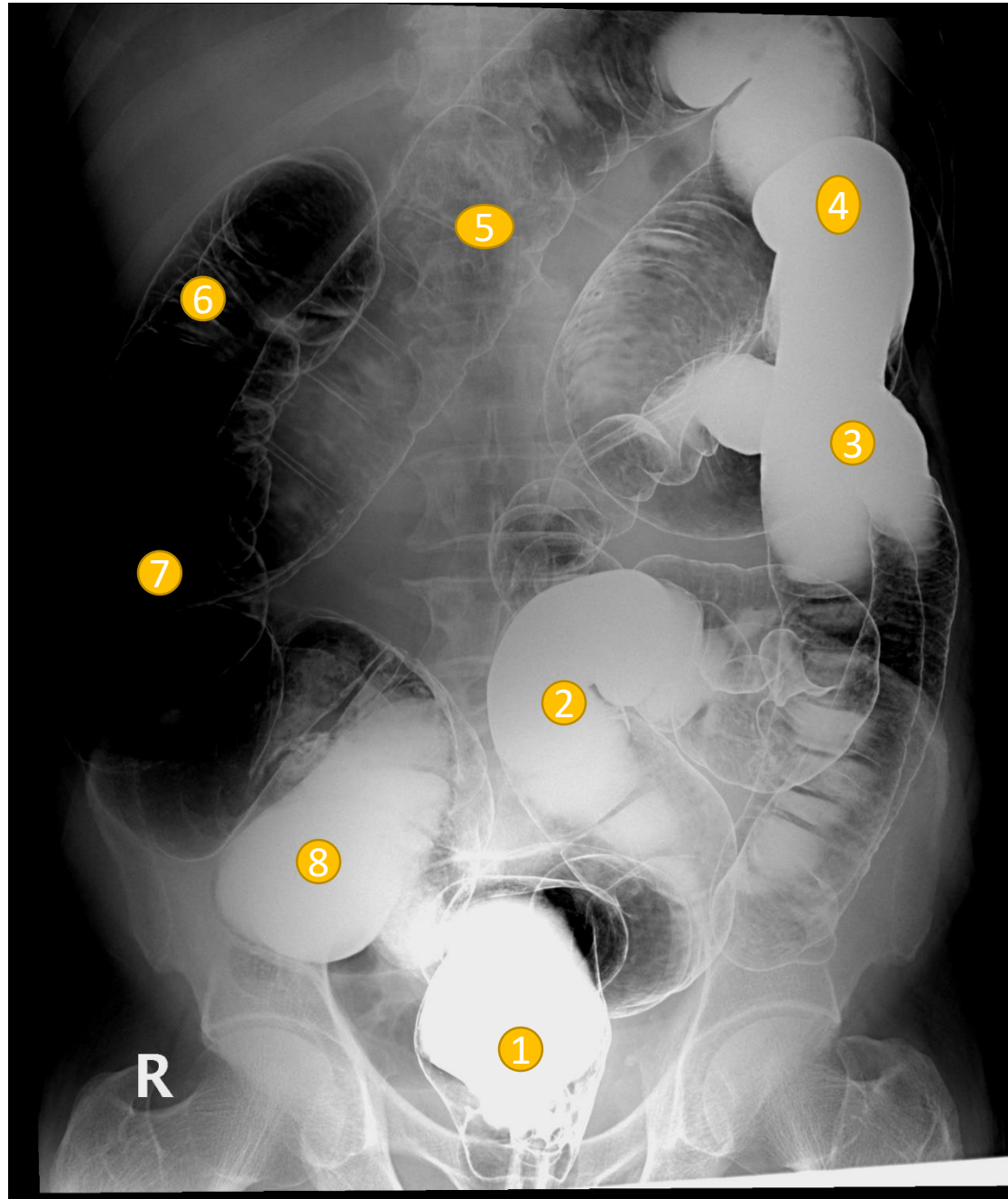
Mention 2 abnormalities? **Multiple air-Fluid levels** and **Stack of coins** signs



# Stack of Coins

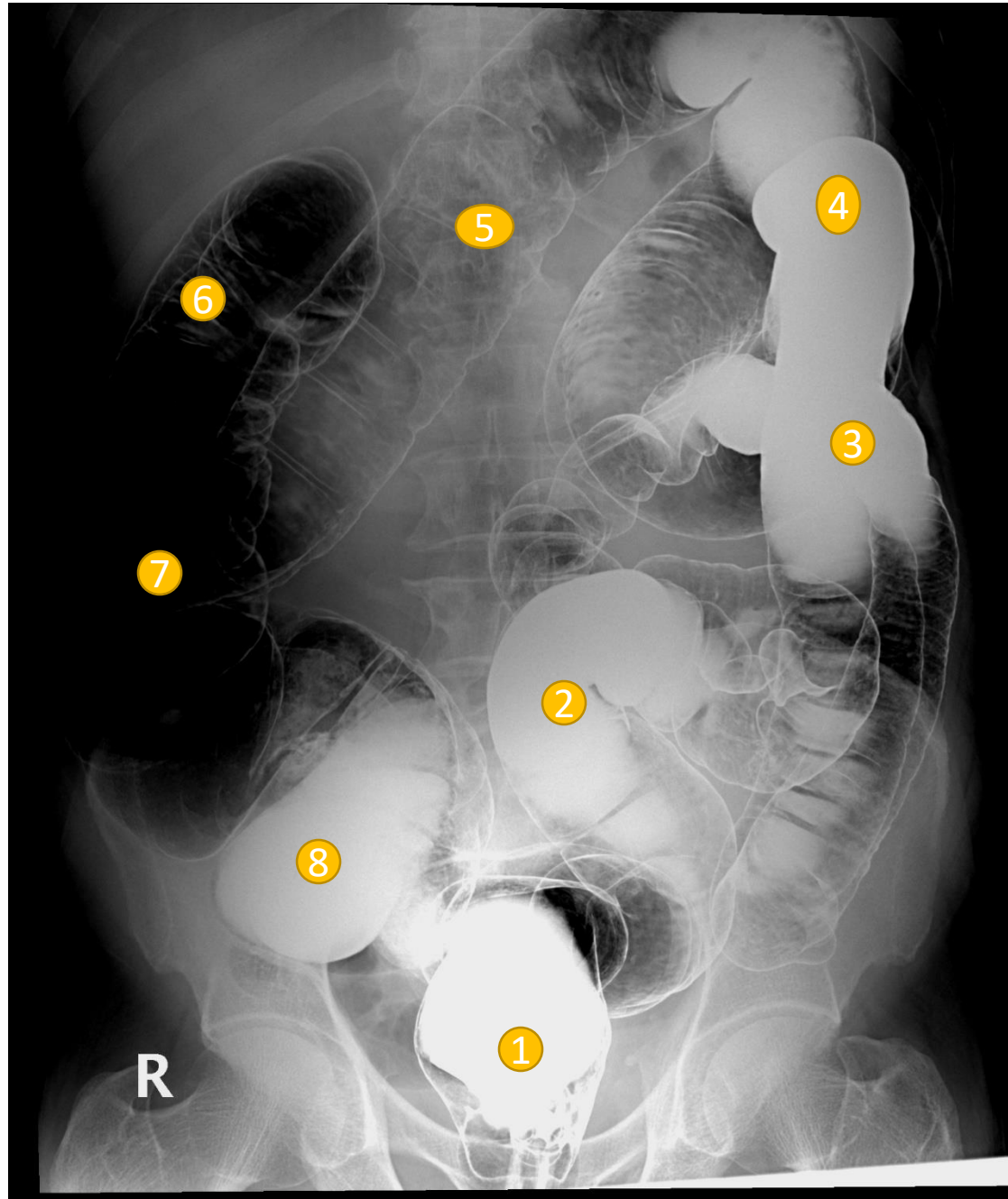


What is the name of the study?  
Name the labelled structures?

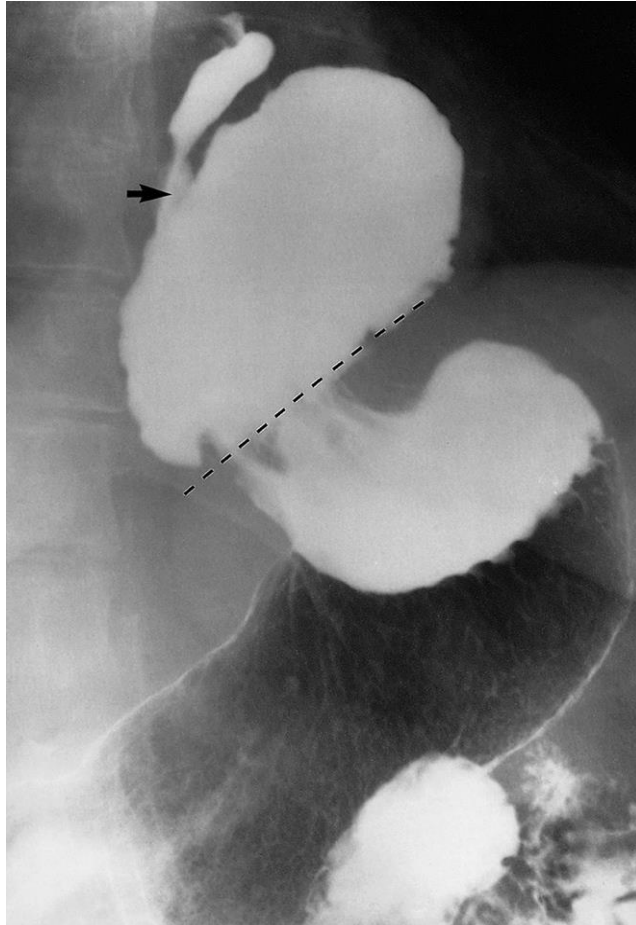


## Double barium enema

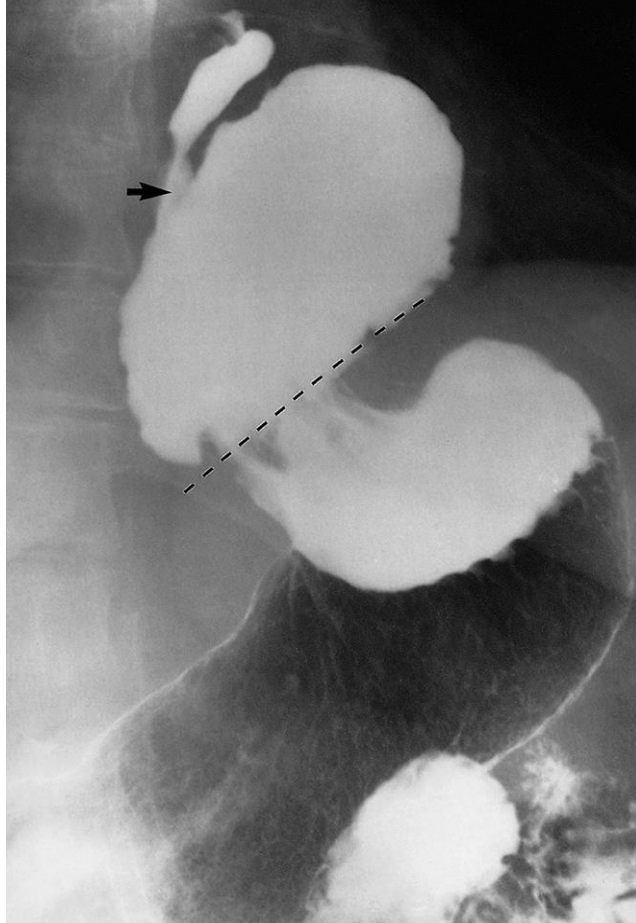
1. Rectum
2. Sigmoid colon
3. Descending colon
4. Splenic flexure
5. Transverse colon
6. Hepatic flexure
7. Ascending colon
8. cecum







What is the modality?  
What is the diagnosis?



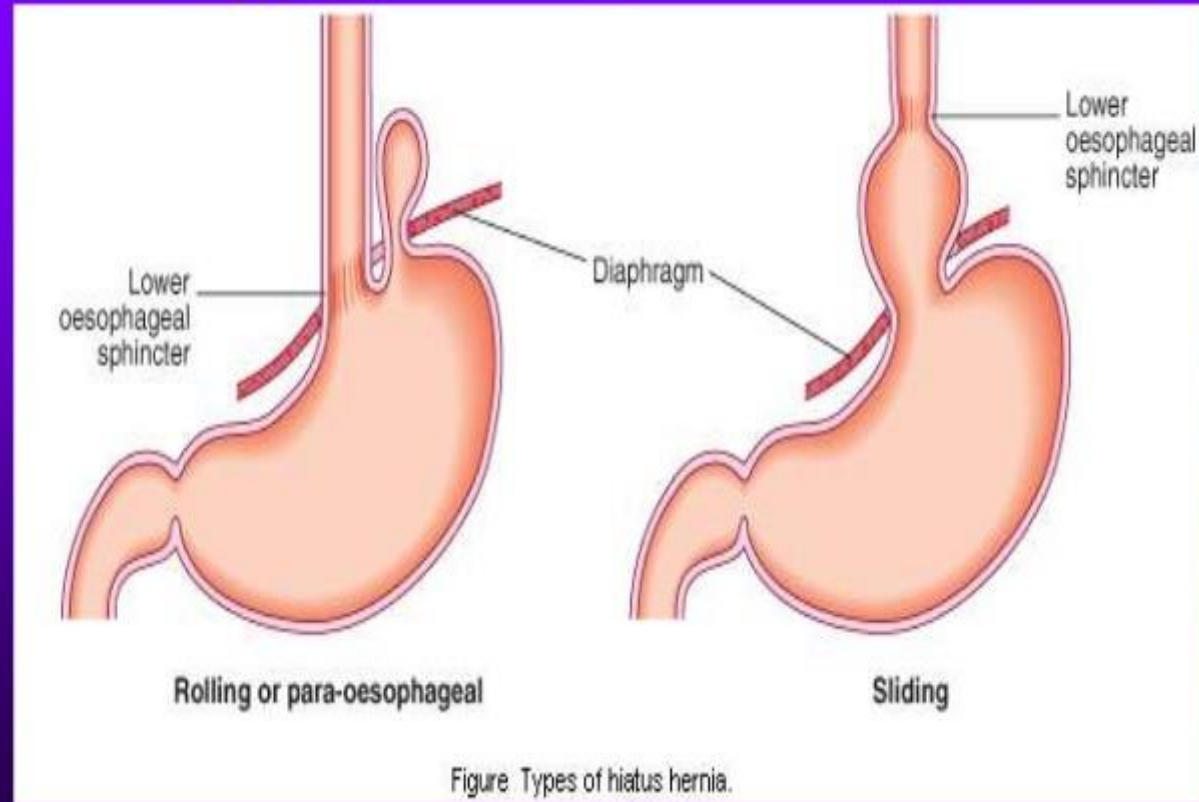
What is the modality?

Barium meal - fluoroscopy

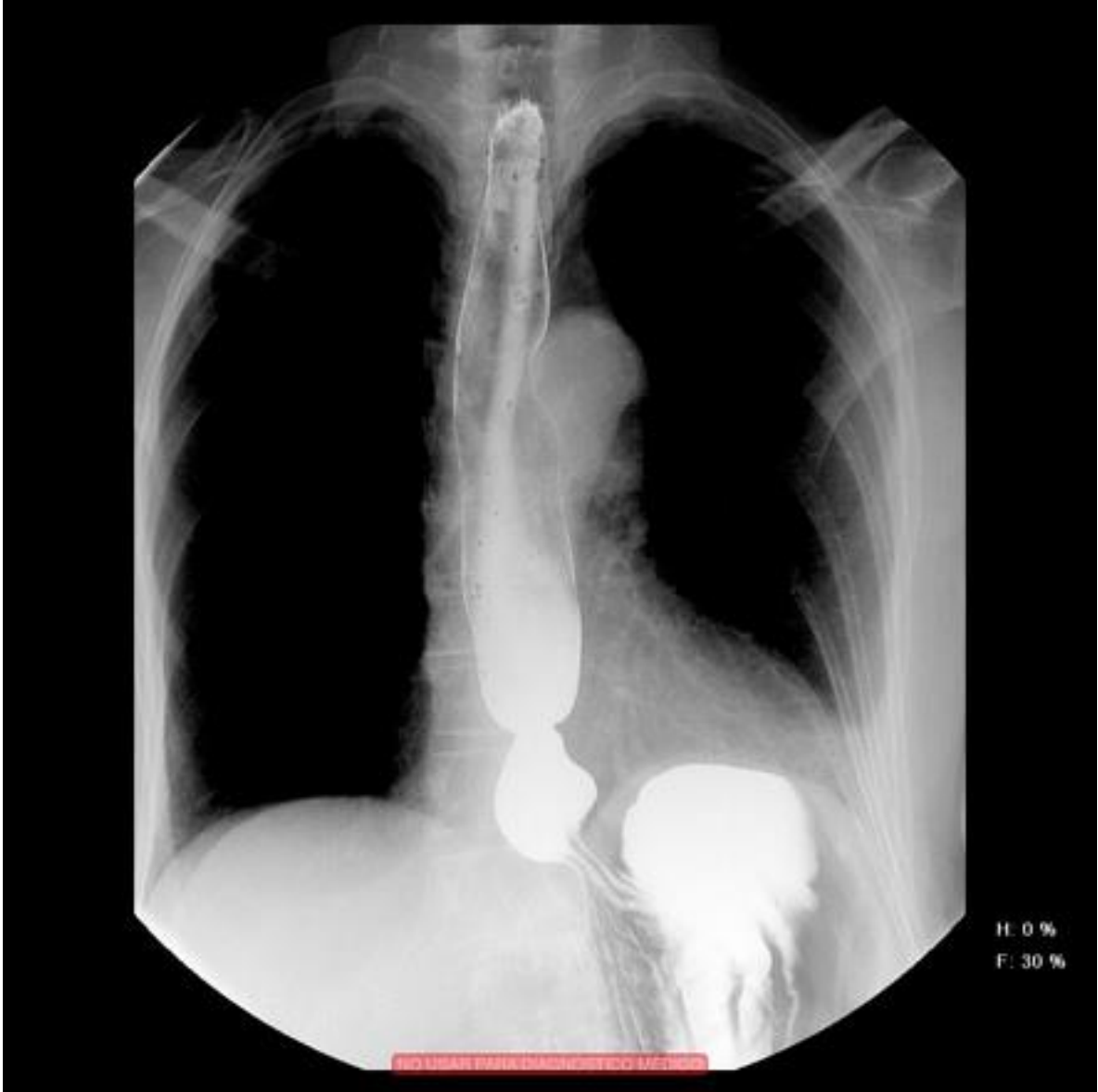
What is the diagnosis?

Hiatus hernia

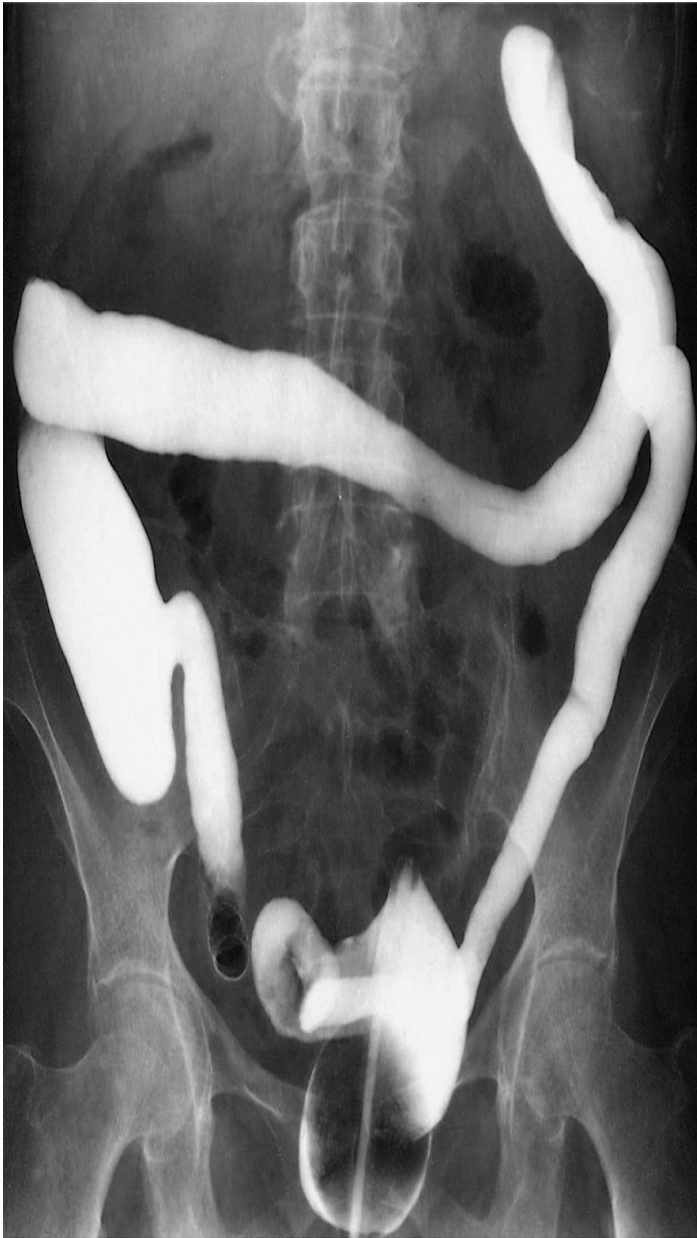# Types of Hiatus Hernia



Another example of hiatus hernia



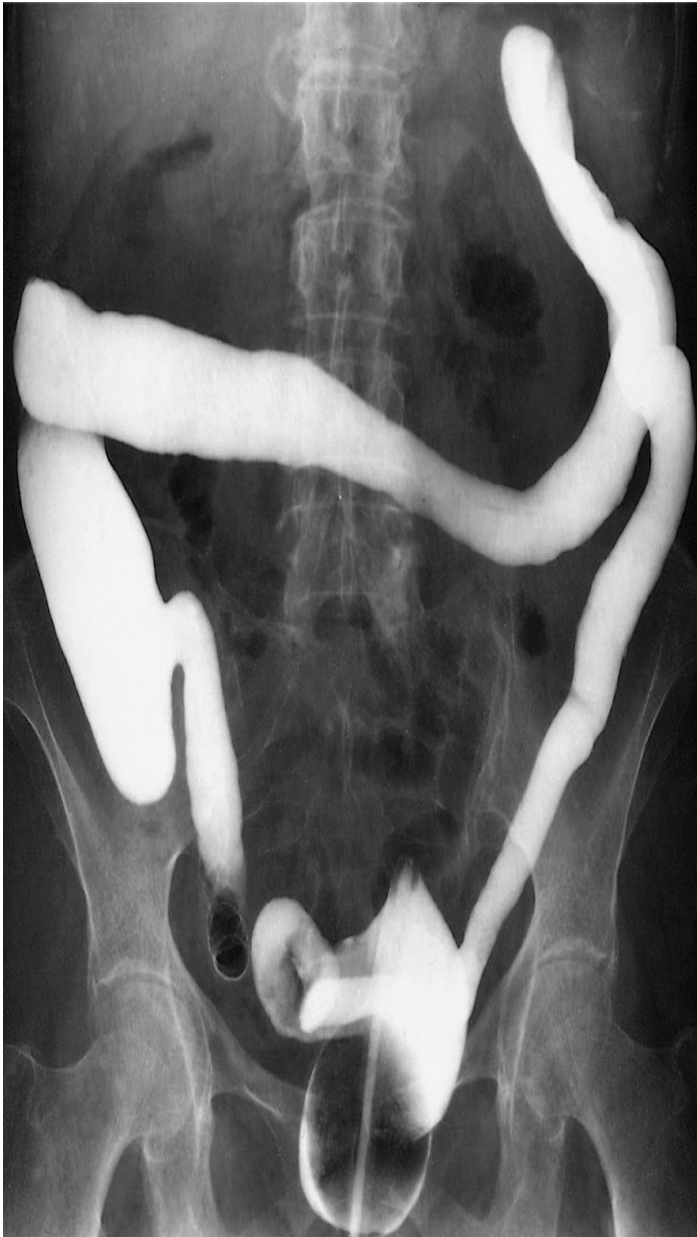



What is the modality?

What is the name of the sign?

What is the diagnosis?



What is the modality?

**Barium enema – fluoroscopy**

What is the name of the sign?

**Lead pipe sign**

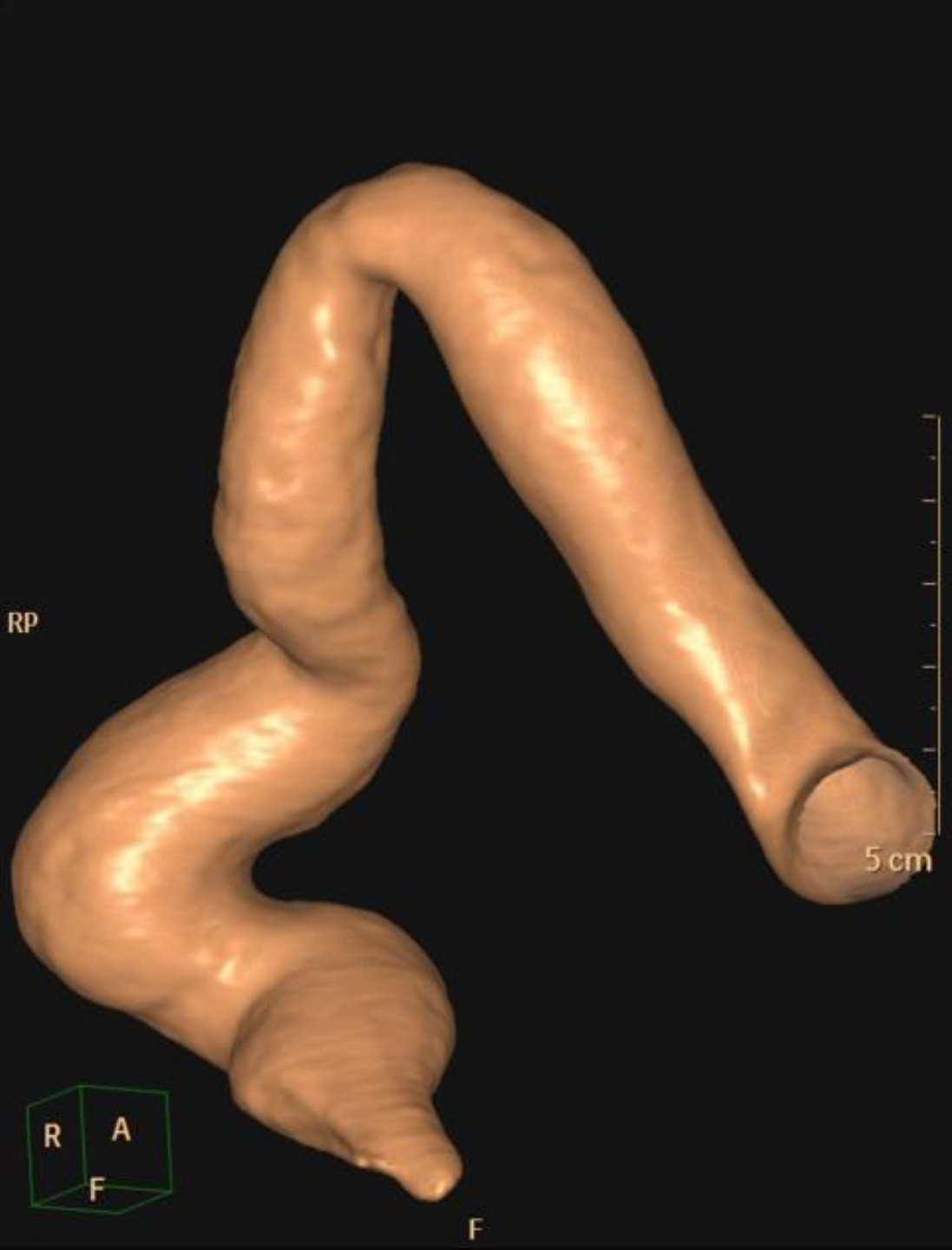What is the diagnosis?

**IBD – Ulcerative colitis**

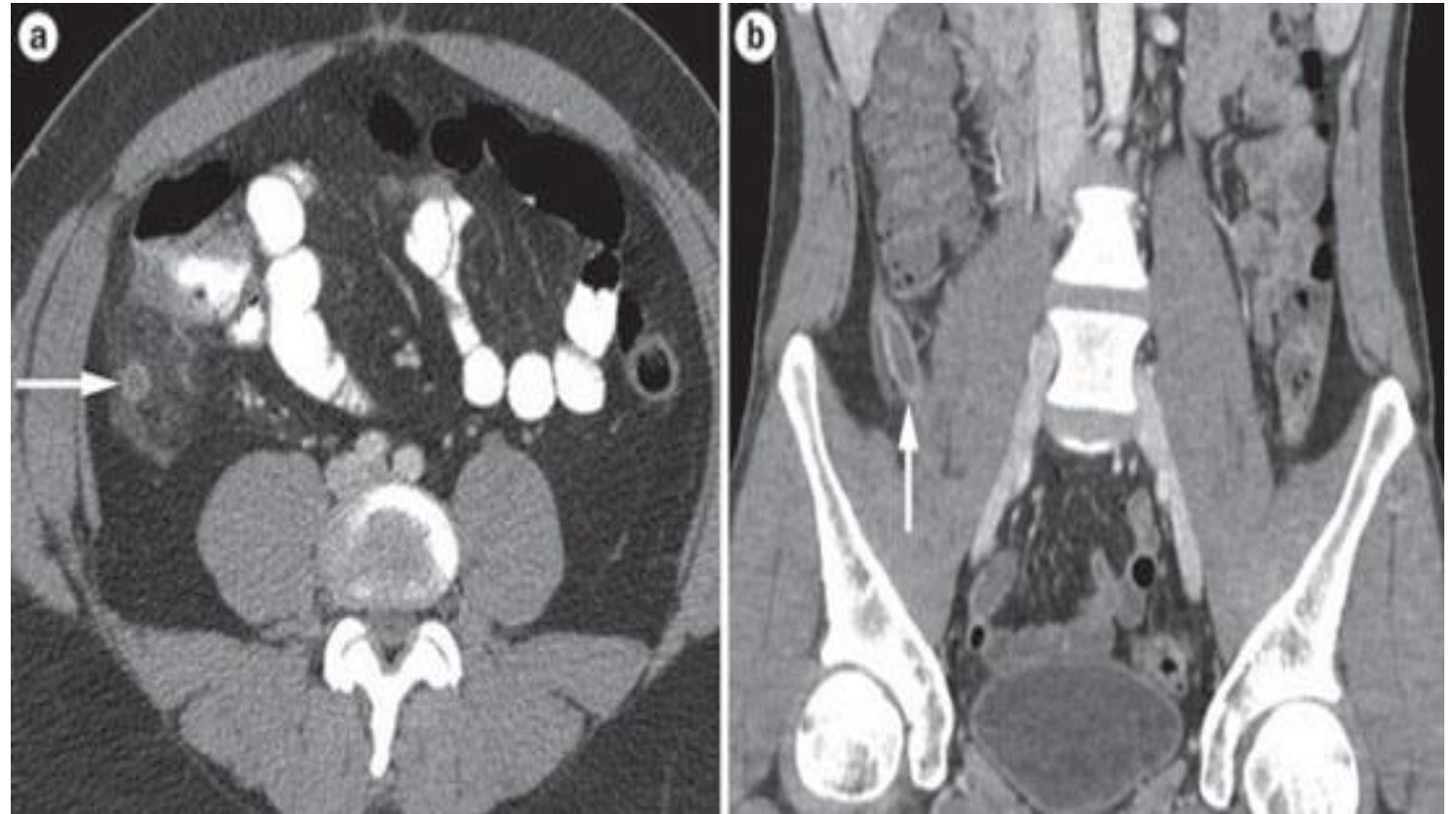
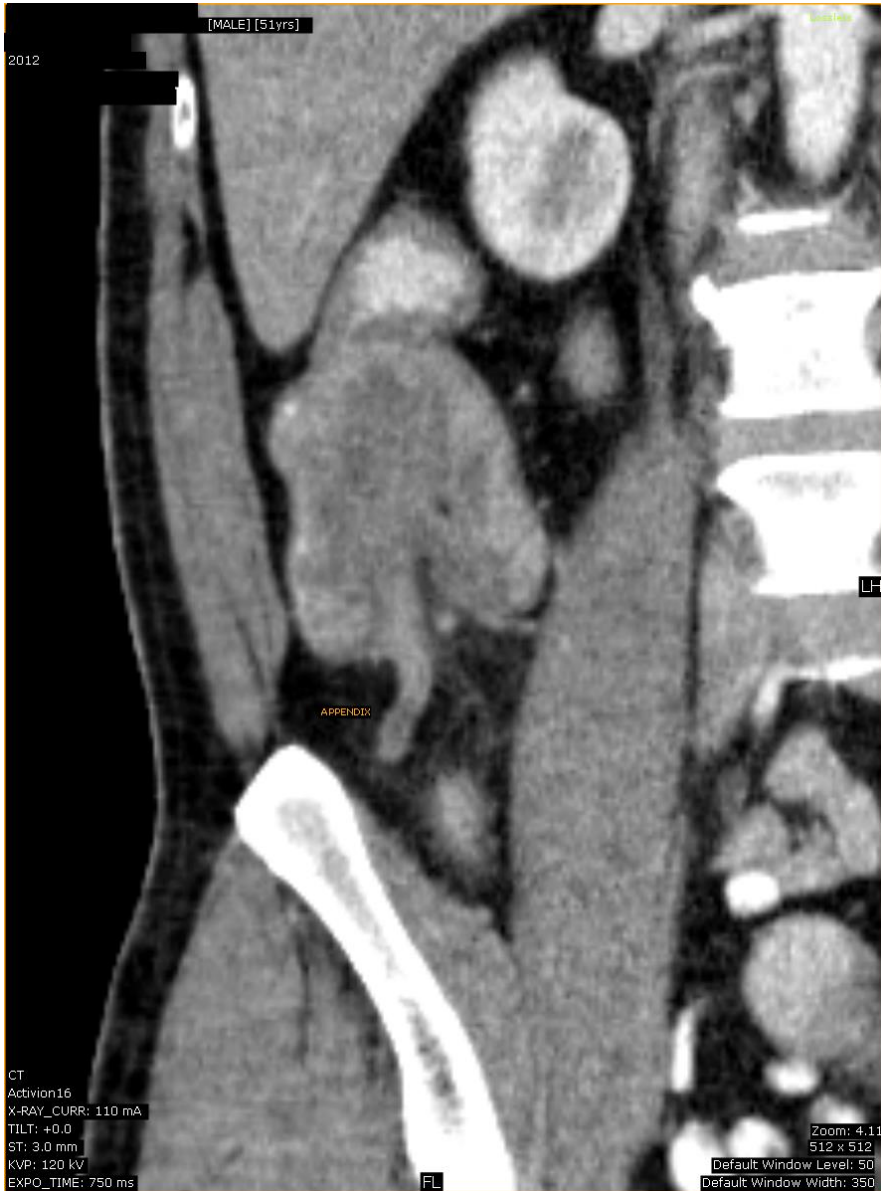Lead pipe



Another example of lead pipe colon  
(featureless colon)





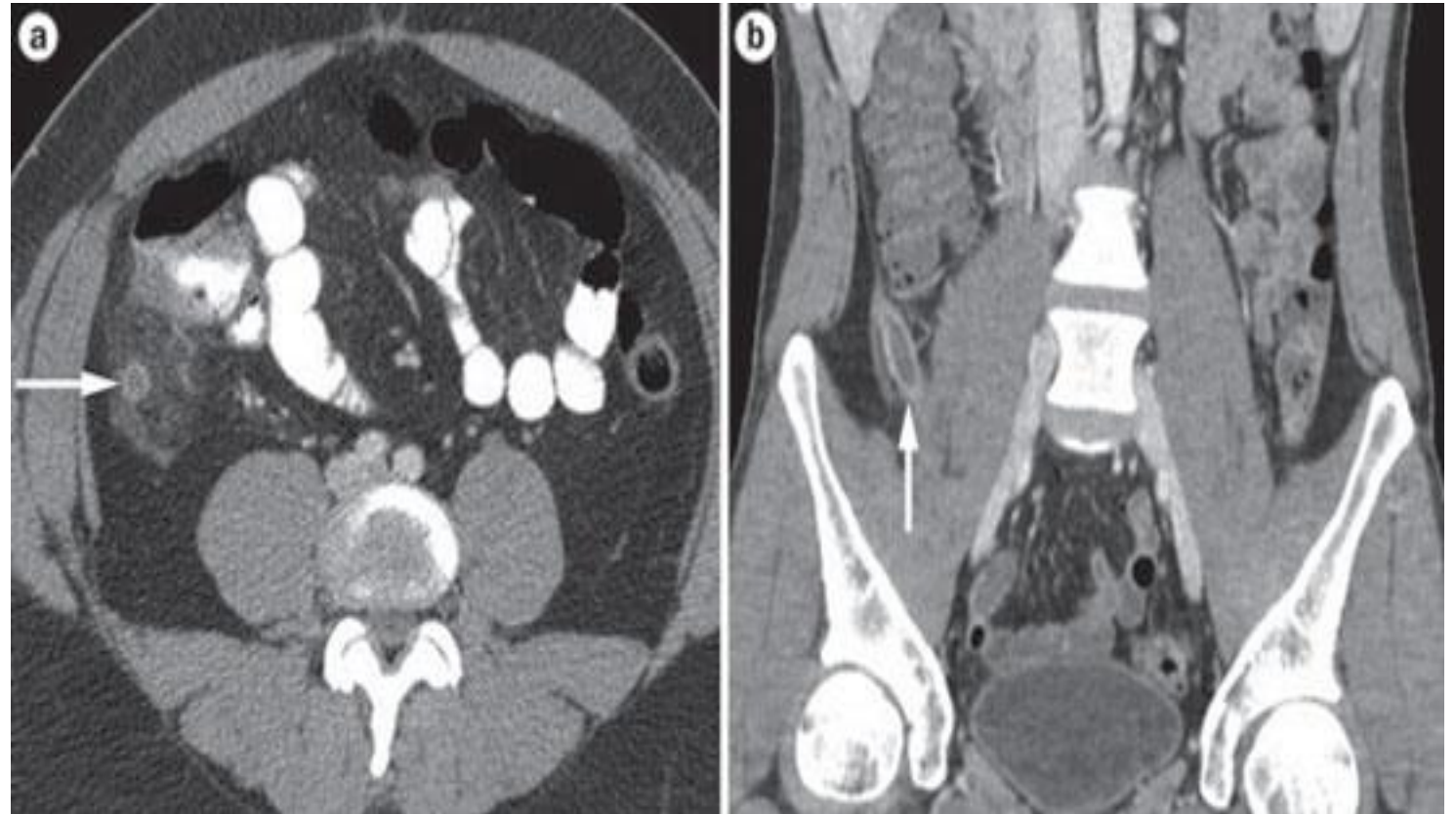


What is the name of the study?

What is structure labeled on the left image?

What is the diagnosis of the patient on right image?

What is the gold standard image modality for such diagnosis? What is the alternative image modality in pregnant/pediatric patients?



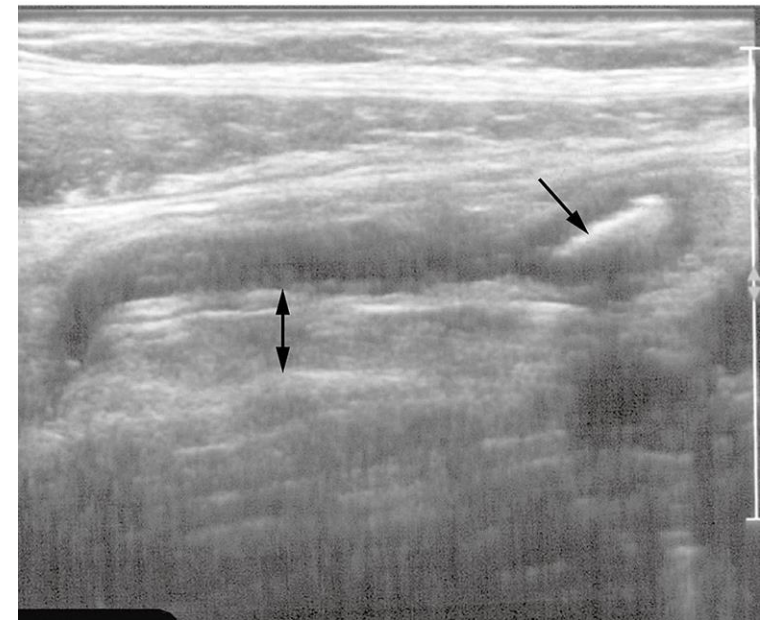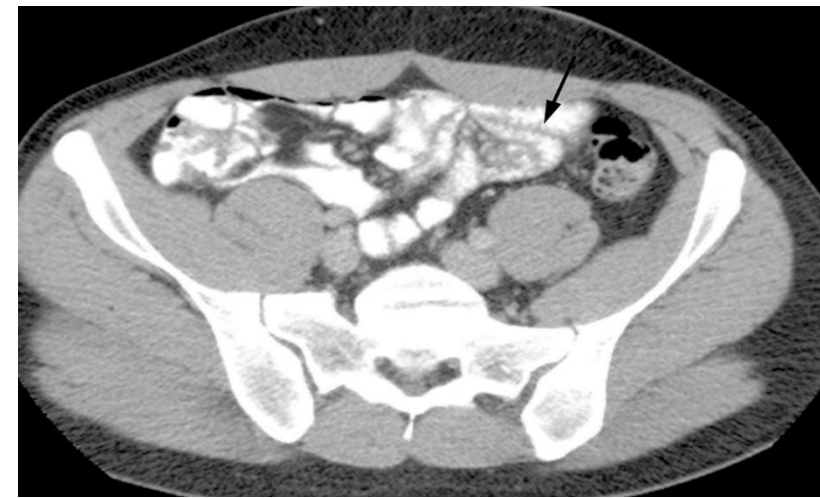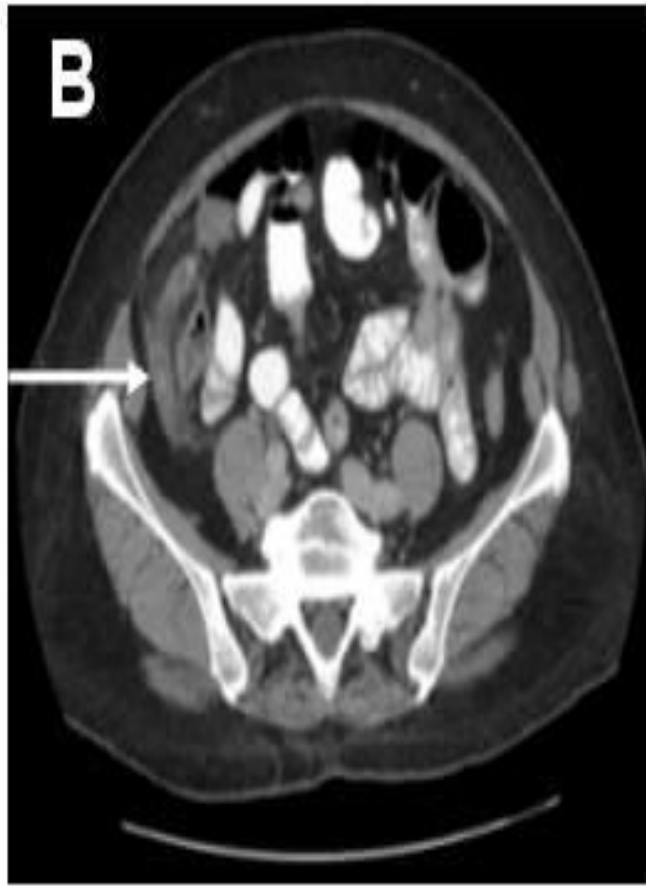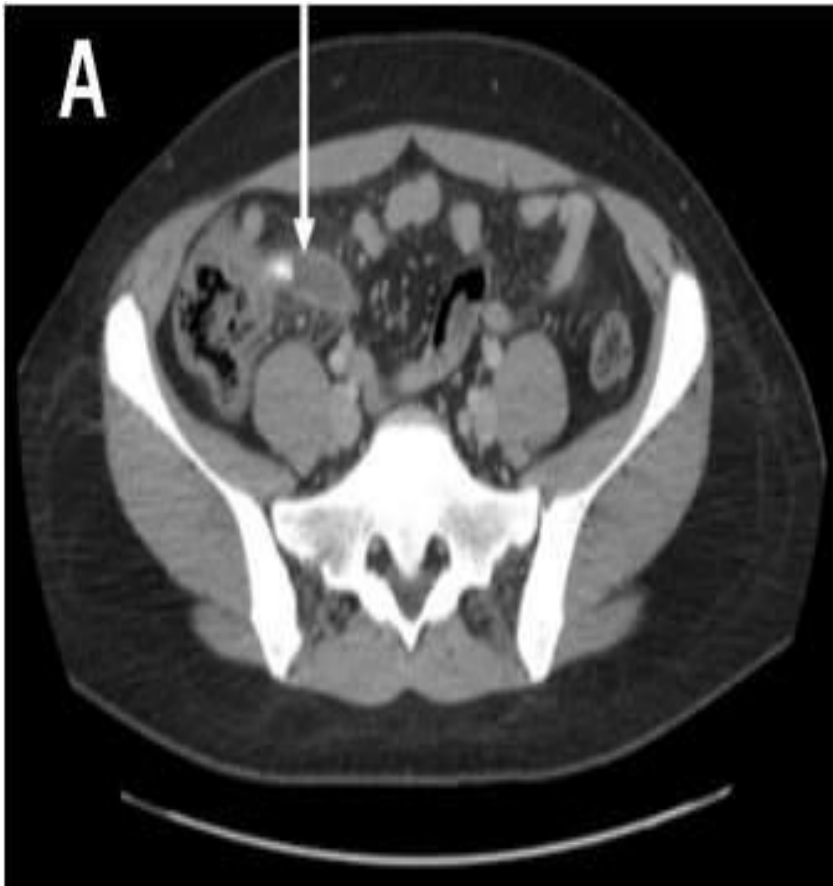
What is the name of the study? **CT scan**

What is structure labeled on the left image? **appendix**

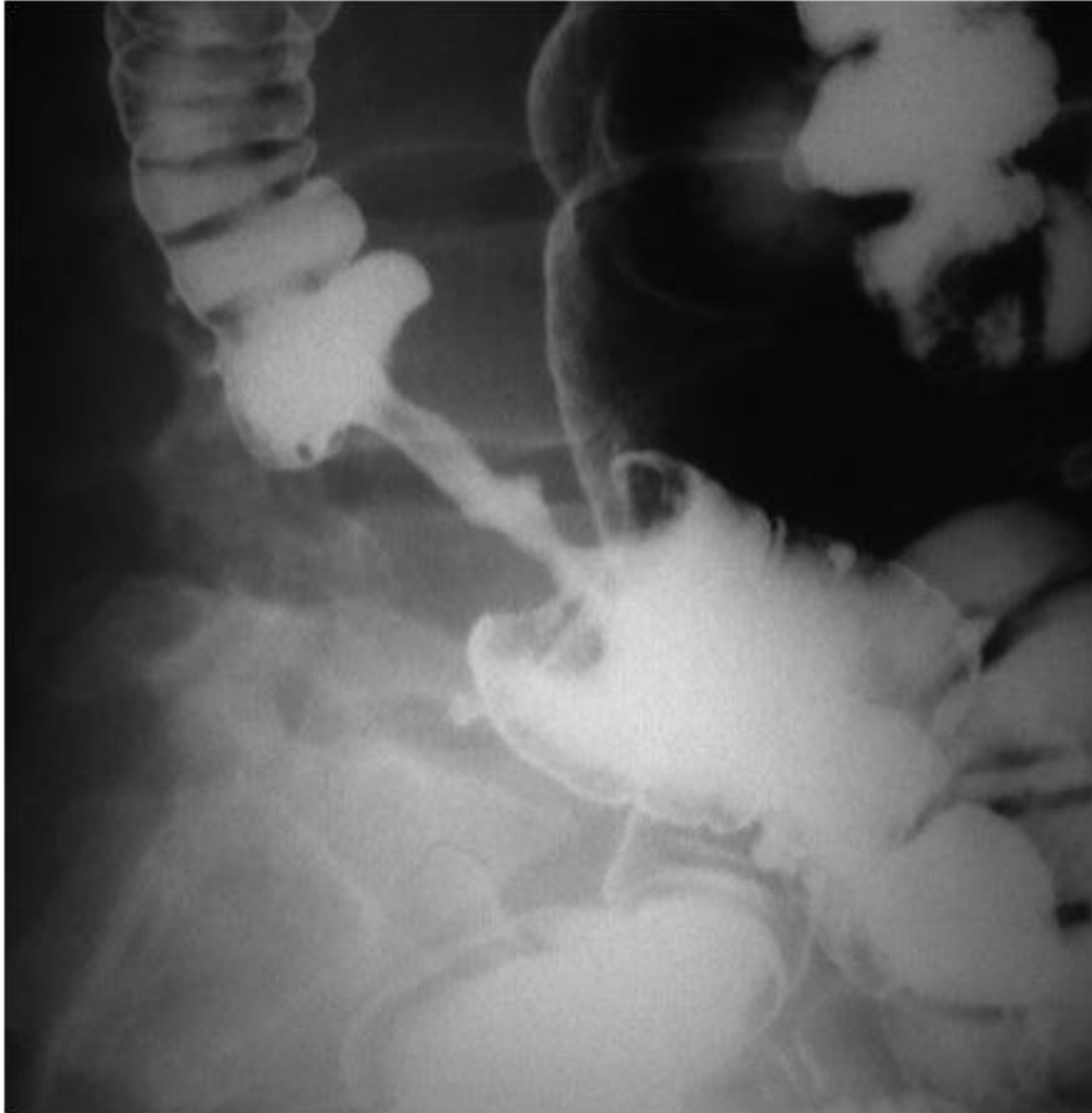What is the diagnosis of the patient on right image? **appendicitis**

What is the gold standard image modality for such diagnosis? What is the alternative image modality in pregnant/pediatric patients? **CT scan is the gold standard, U/S is the alternative.**





Appendix should not exceed **6 mm** in diameter.  
The surrounding fat should be **clear**.  
Appendix normally is **compressible** by U/S probe.  
Normally, there will be no **appendicolith**.



What is the name of the study?

What is the pertinent sign?

What is the diagnosis?





What is the name of the study?

**Barium enema**

What is the pertinent sign?

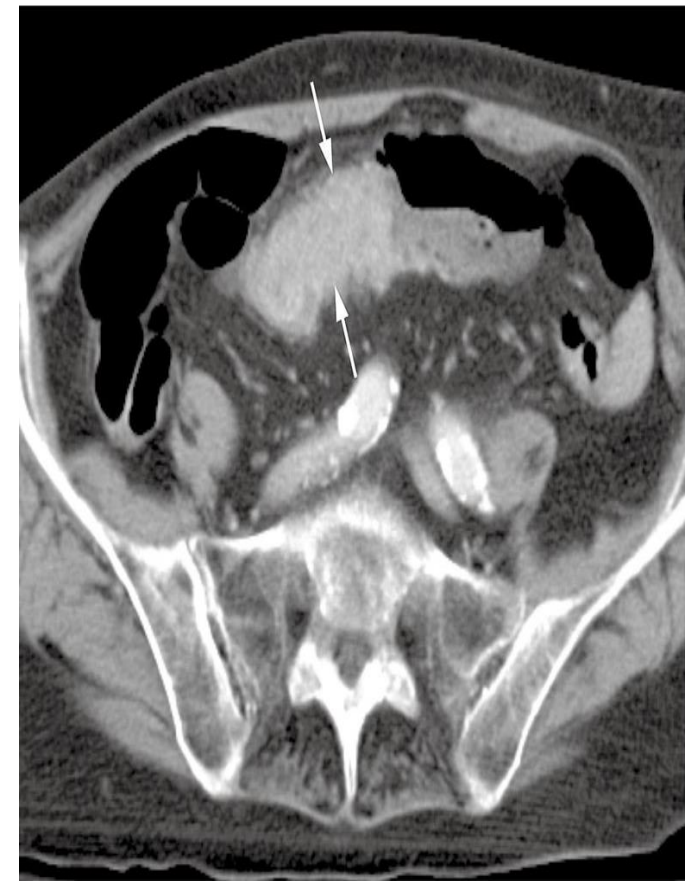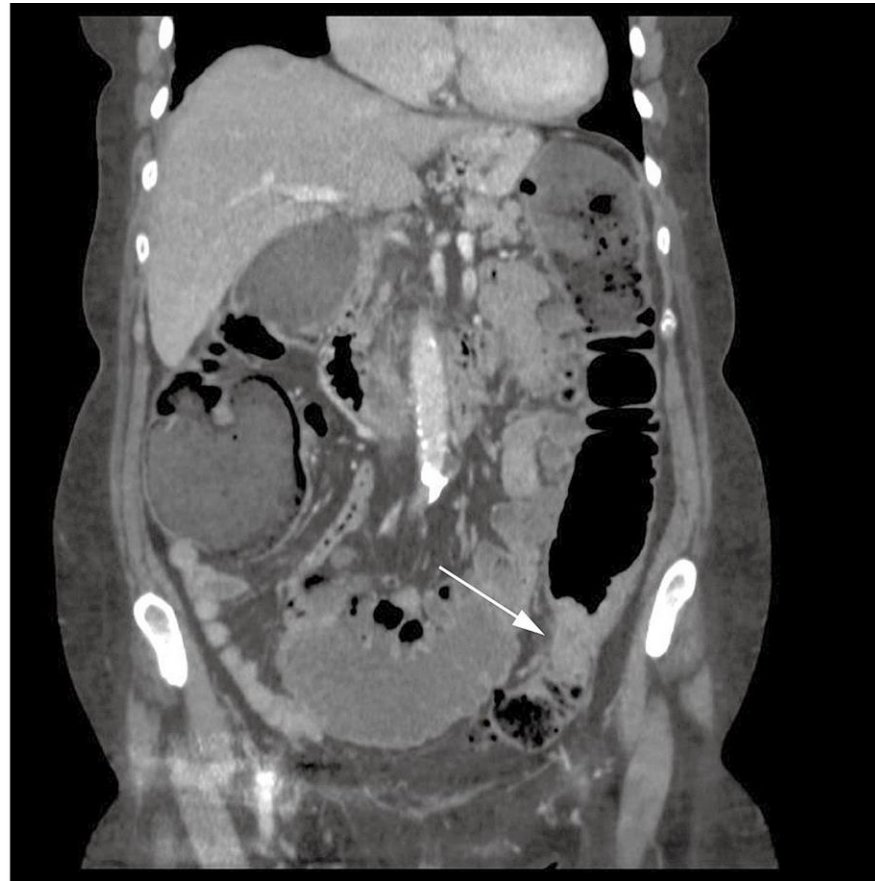
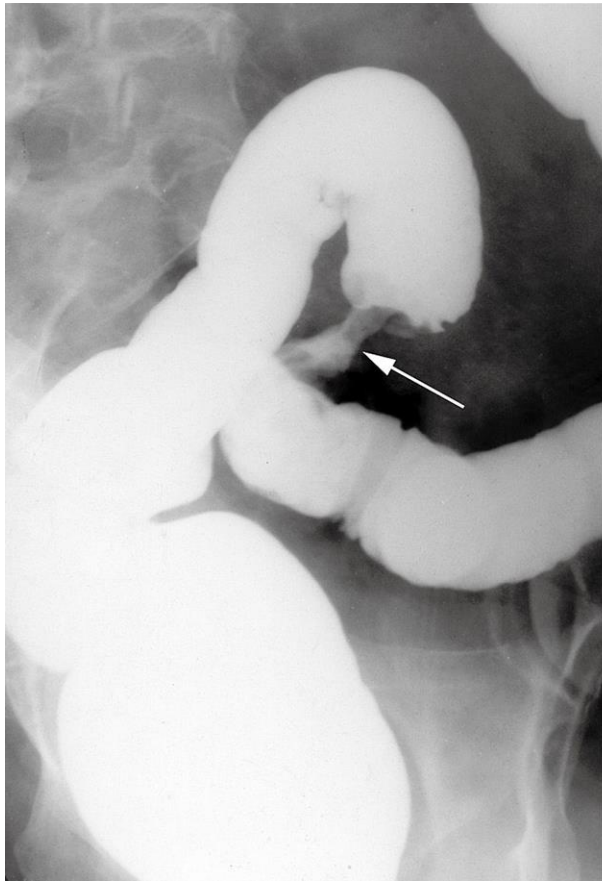
**Apple-core sign**

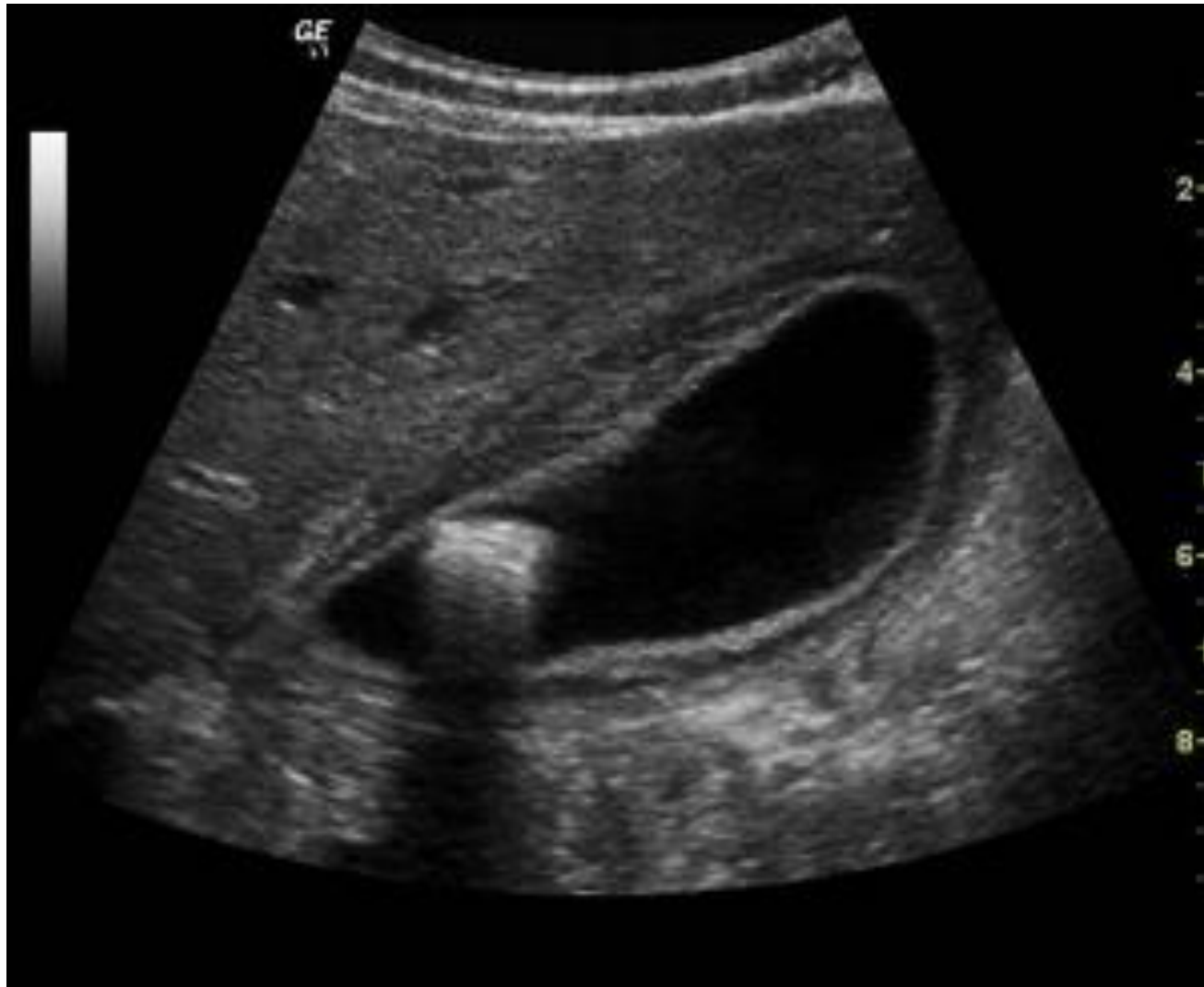What is the diagnosis?

**Colon cancer**



# Examples of colon cancer in barium enema and CT scan

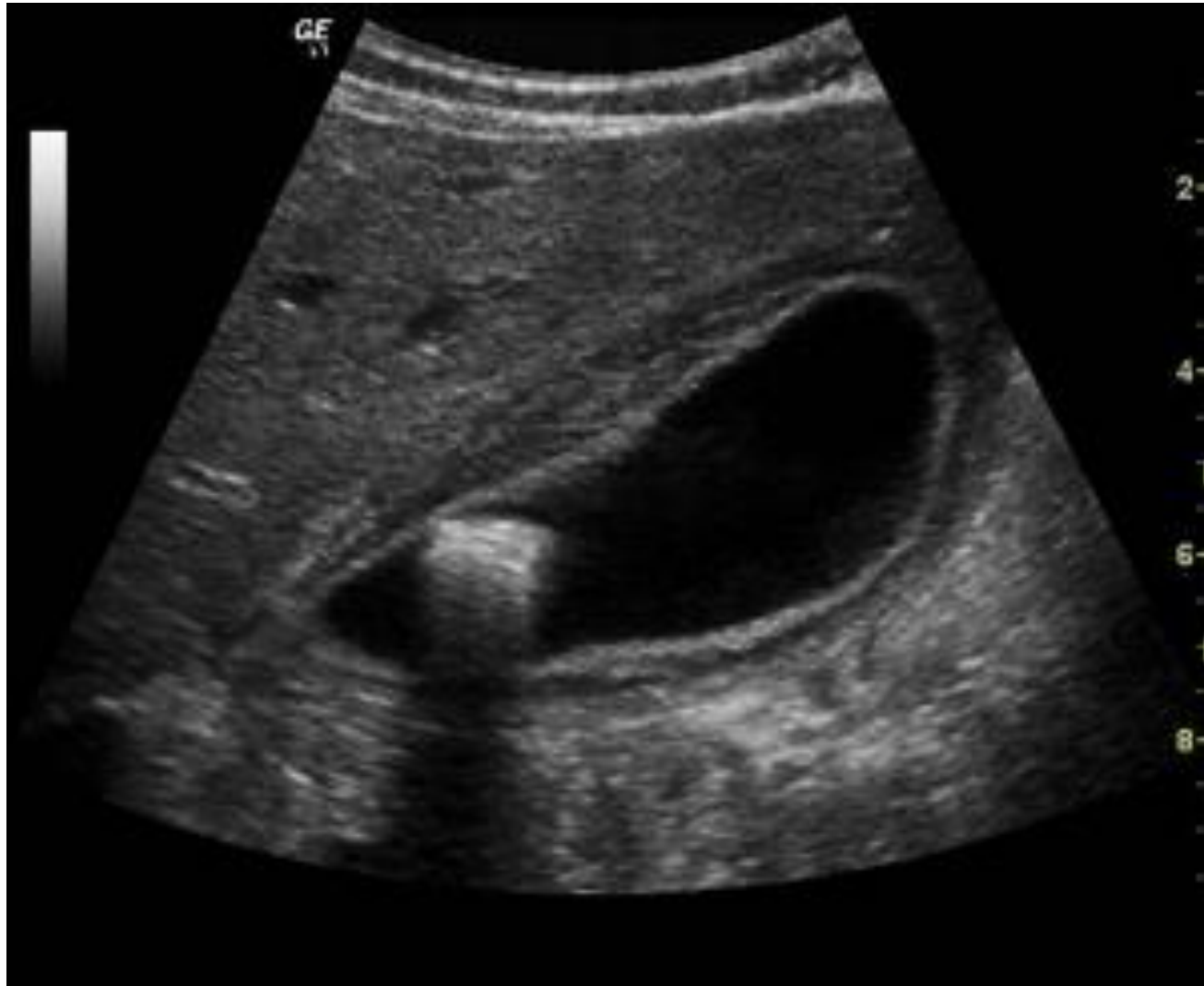



What is the name of the modality?

What is the diagnosis?

What are the expected symptoms the patient has?



What is the name of the modality?

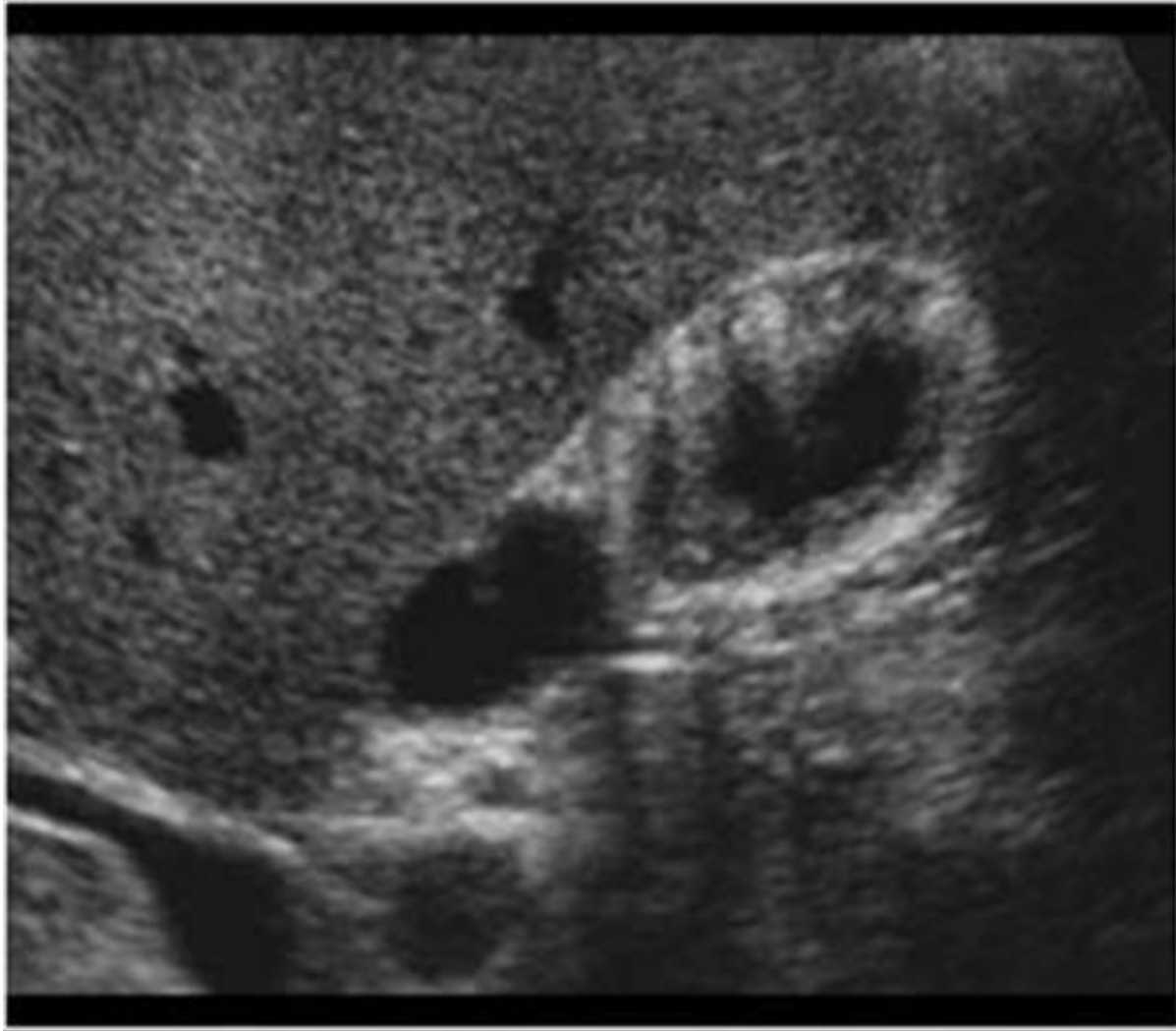
UltraSound

What is the diagnosis?

Gallstone with cholecystitis

What are the expected symptoms the patient has?

RUQ pain radiating to right shoulder aggravating by fatty meal



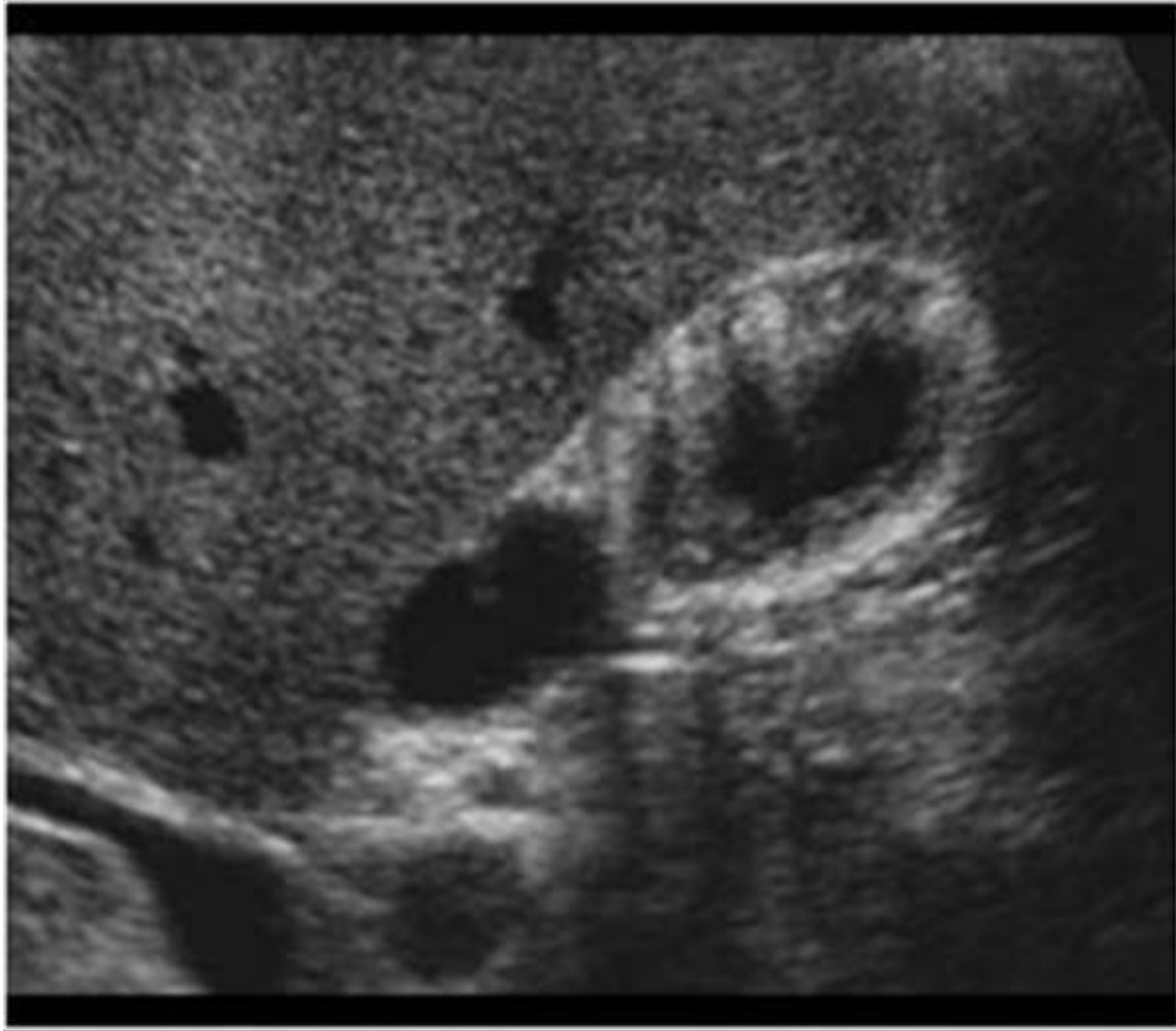
What is the name of the modality?

What is the findings?

What is the diagnosis?

What is the important of this disease?





What is the name of the modality?

**UltraSound**

What is the findings?

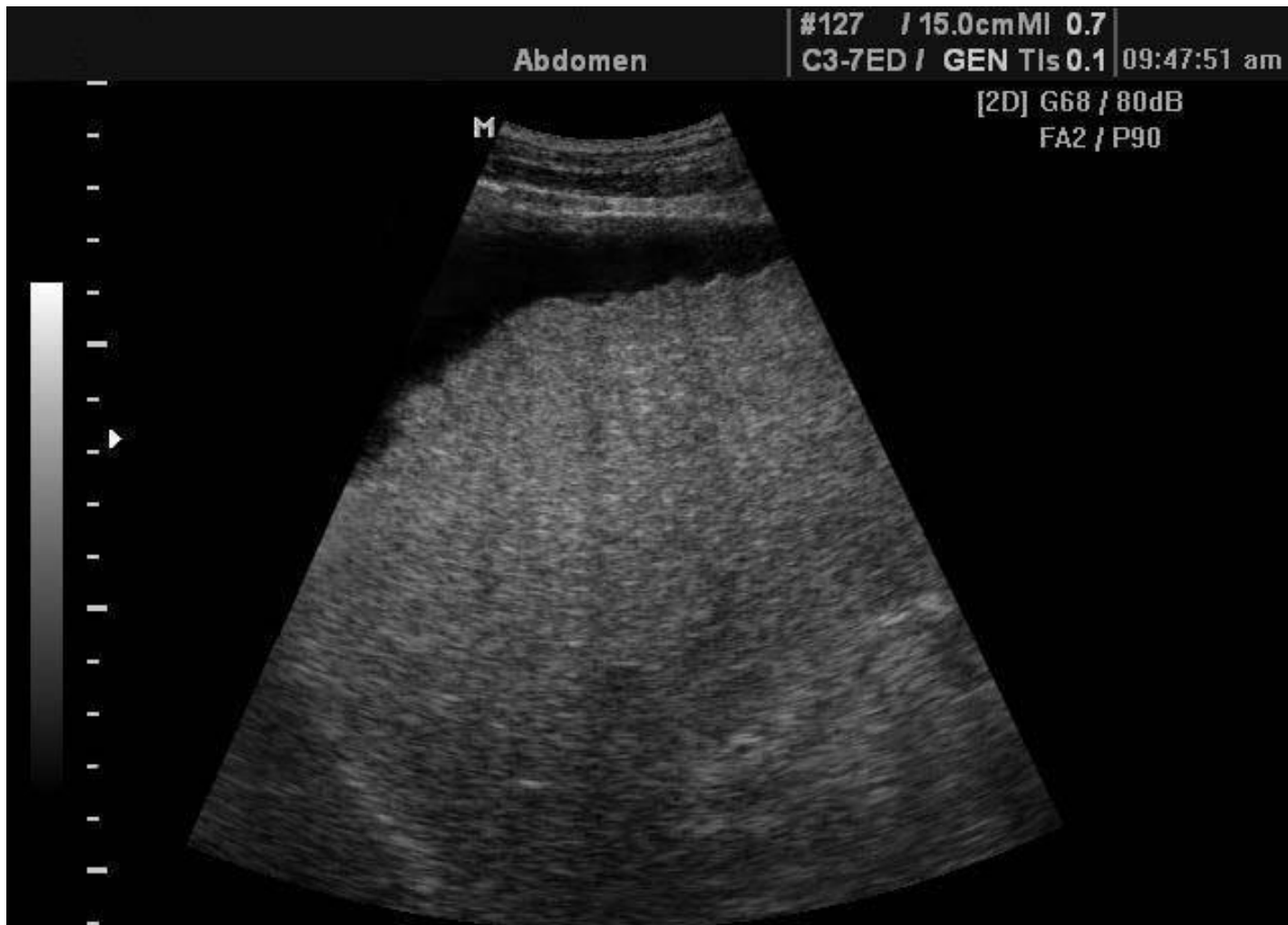**Hyperechoic lesions within the wall**

What is the diagnosis?

**Gallbladder adenomyomatosis**

What is the important of this disease?

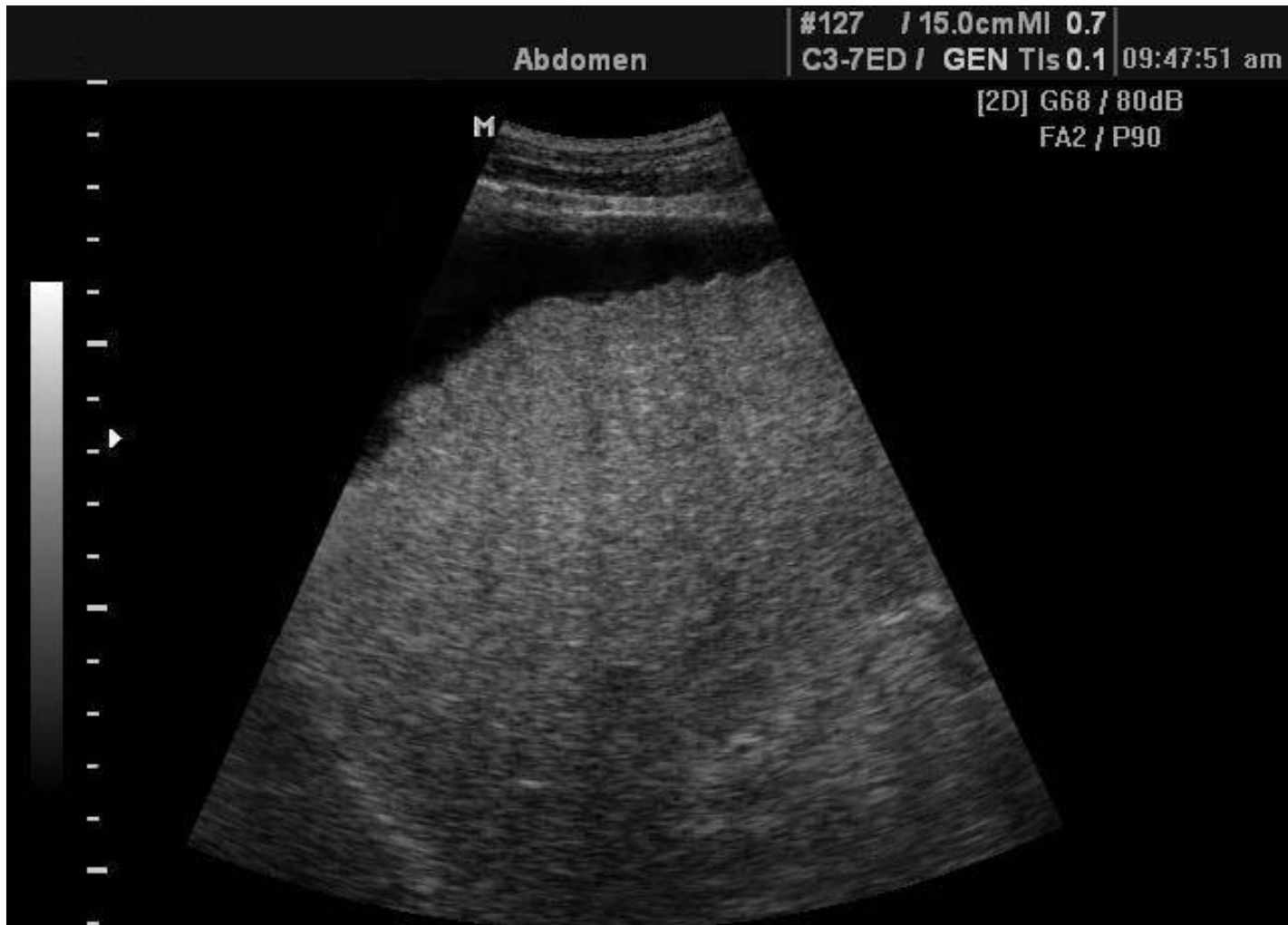**Misdiagnose with stone, benign lesion and can convert to malignant lesions, F/U is needed.**



What is the modality?

What is the findings?

What is the diagnosis?



What is the modality?

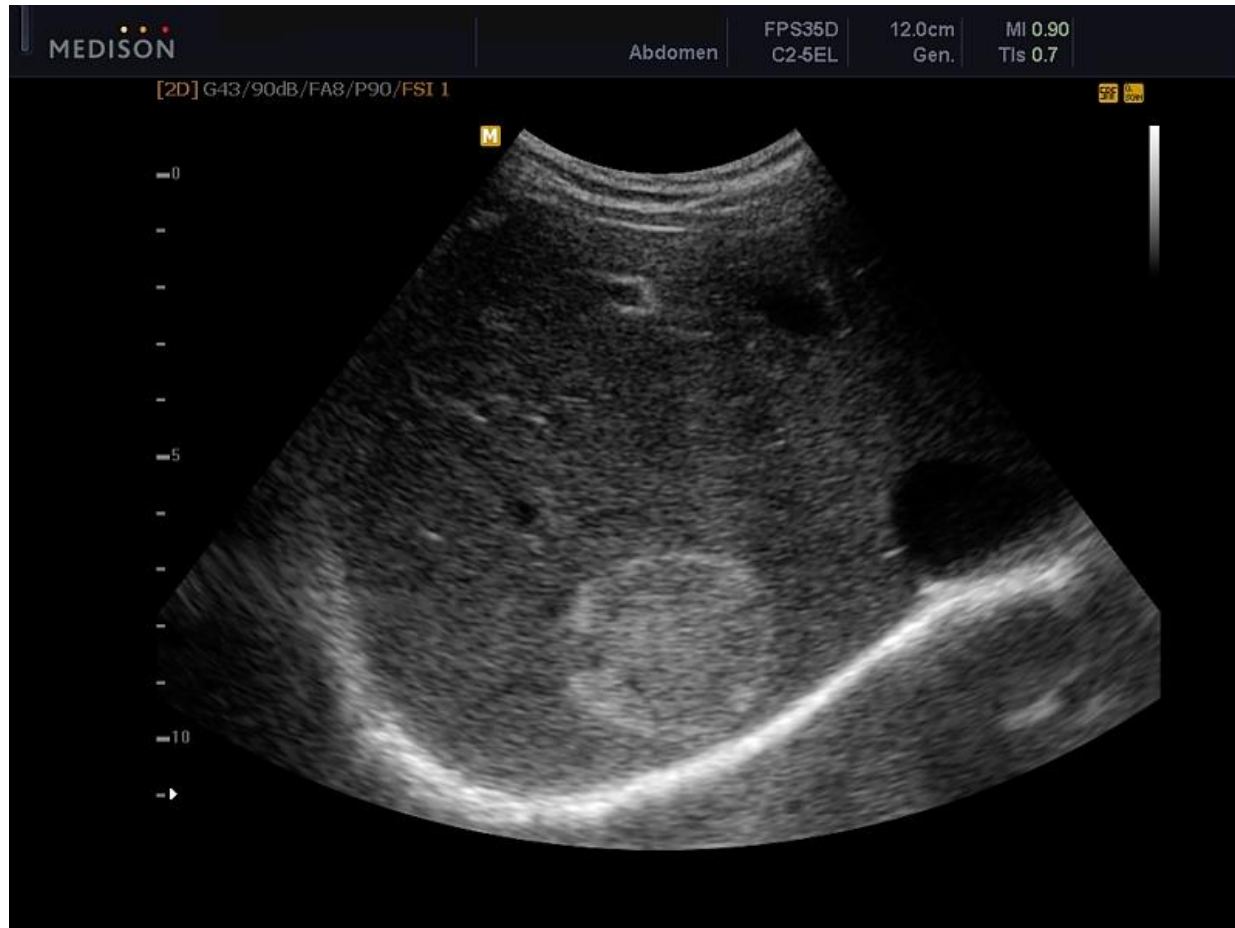Ultrasound

What is the findings?

Shrink, nodular surface, hyperechoic texture, ascites.

What is the diagnosis?

Liver cirrhosis

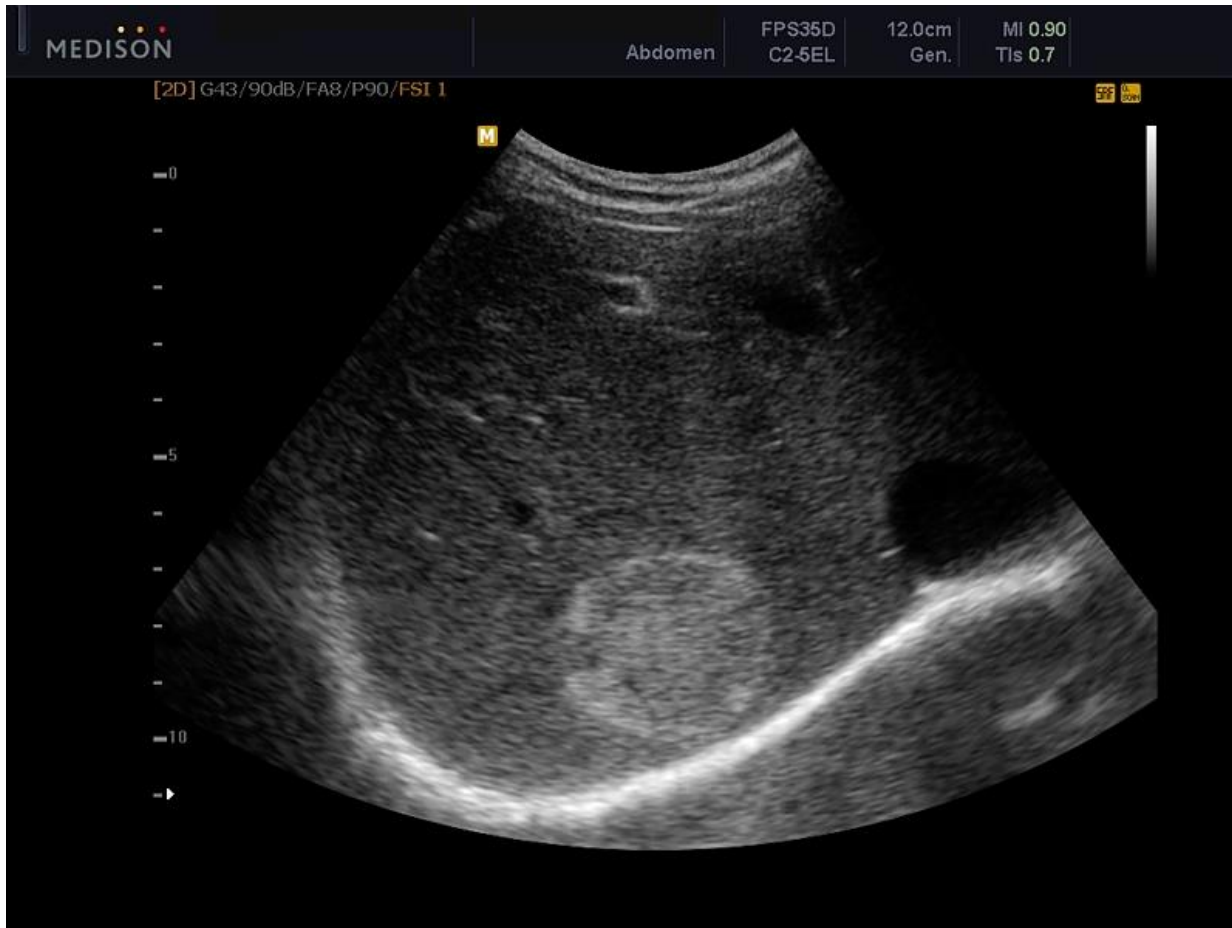

What is the modality?

What is the findings?

What is the diagnosis?

What is other imaging modality to confirm the diagnosis?



What is the modality?

U/S

What is the findings?

Hyper-echoic focal hepatic nodule

What is the diagnosis?

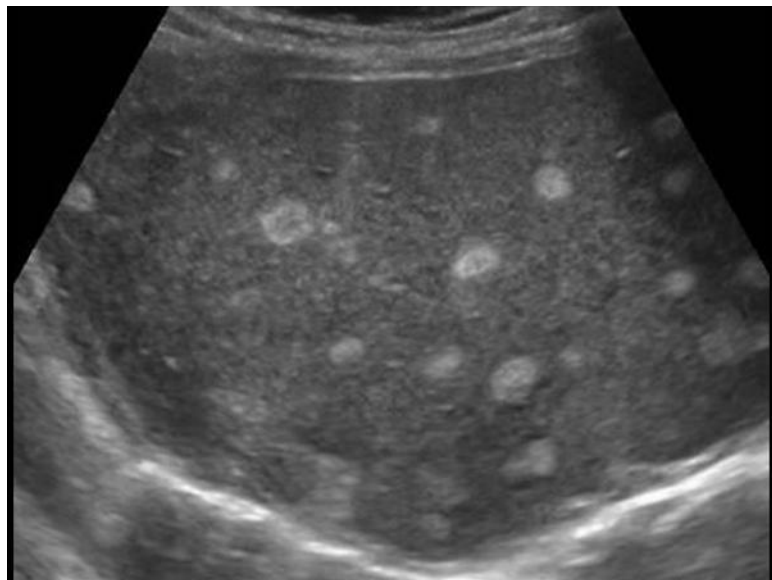
hemangioma

What is other imaging modality to confirm the diagnosis?

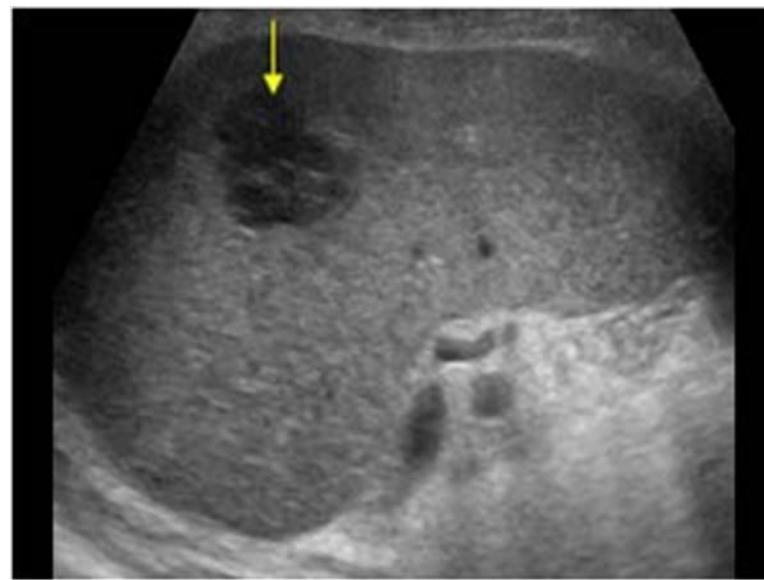
Triphasic liver CT scan

MRI



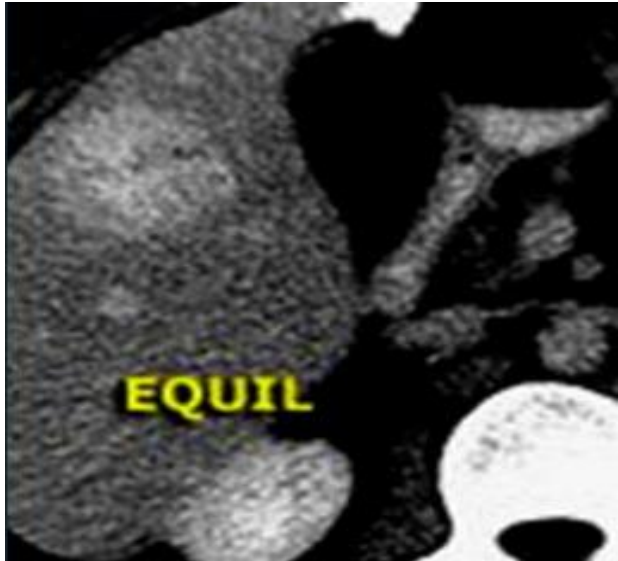
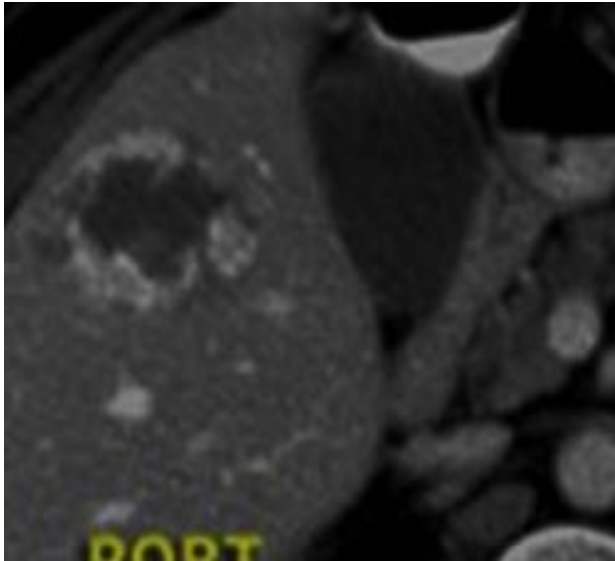
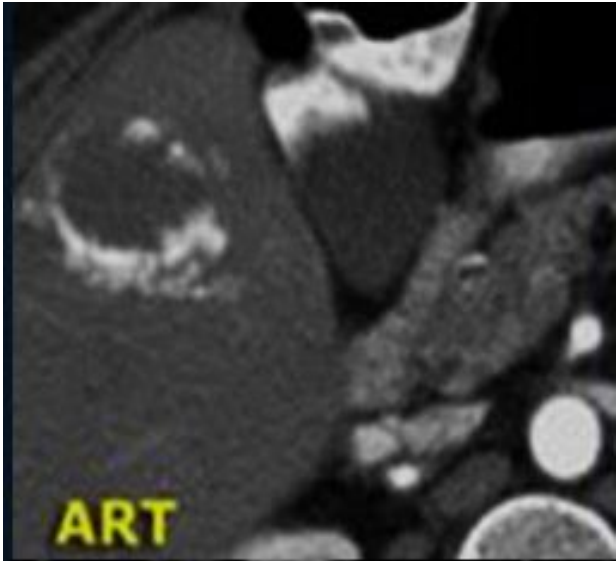


Hyper echoic lesions



Hypo echoic lesions

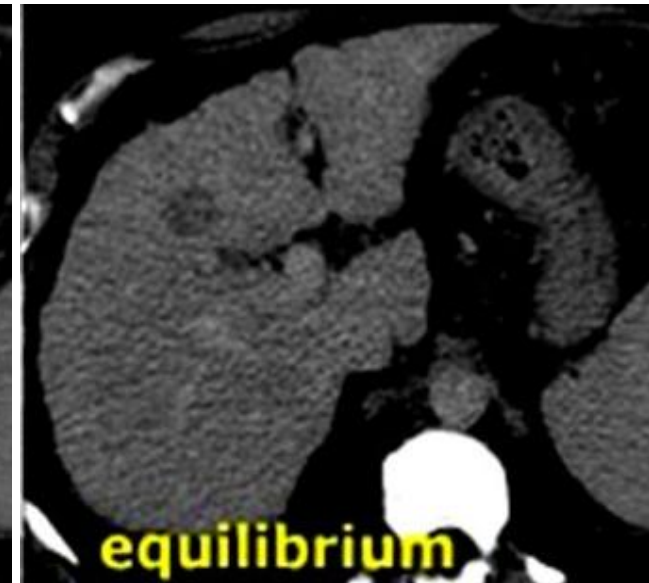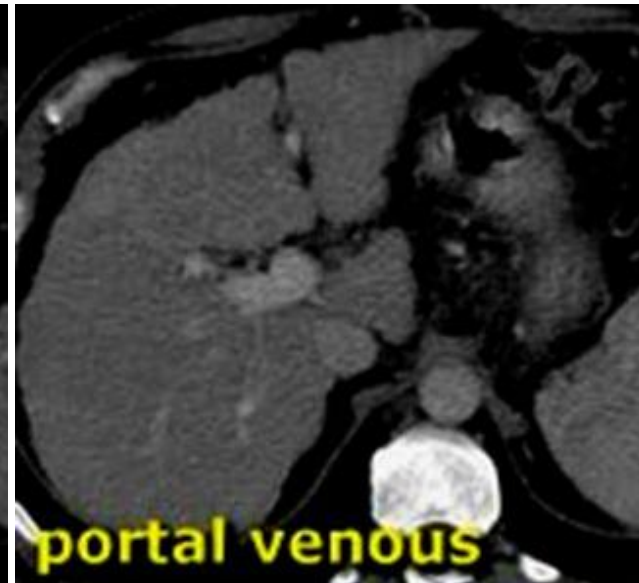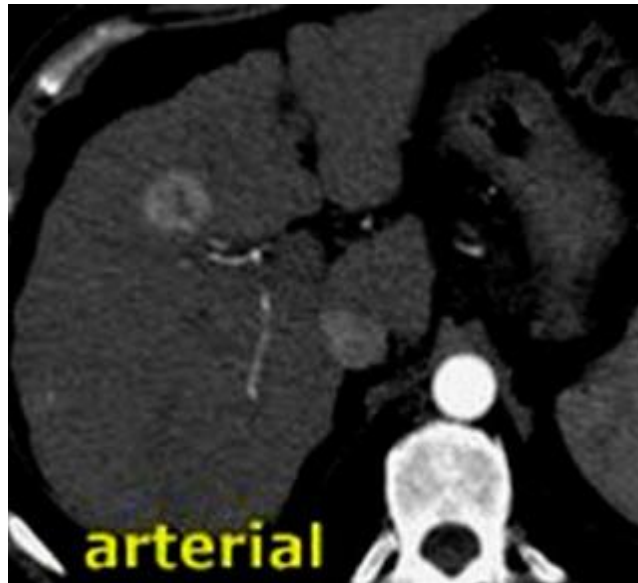
# Triphasic liver CT scan of the same patient



What is the modality?

What are the findings?

What is the diagnosis?



What is the modality?

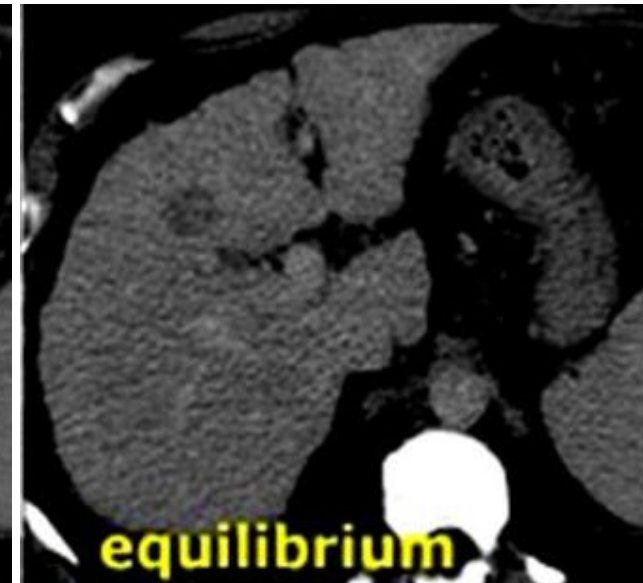Triphasic liver CT scan

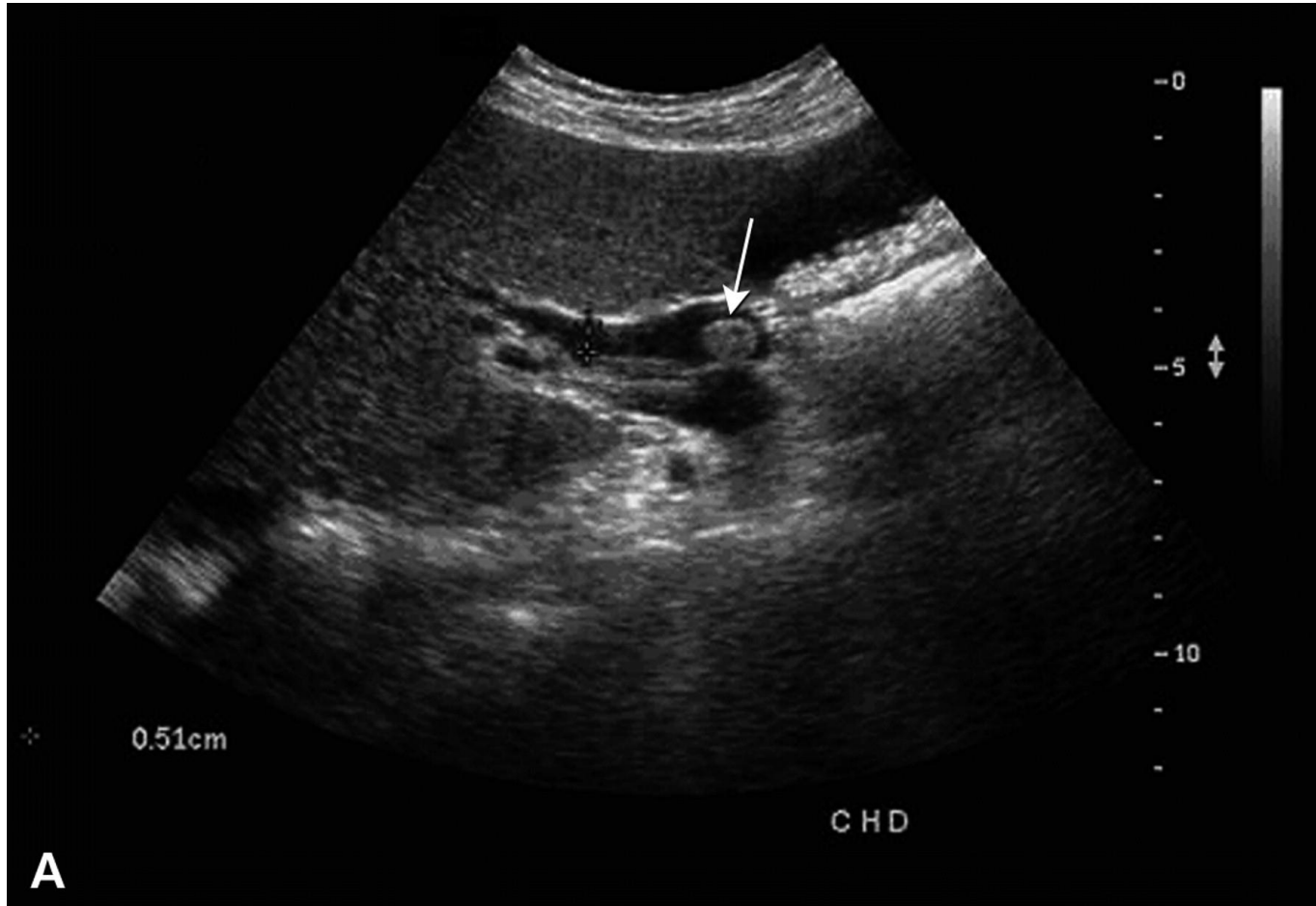
What are the findings?

Focal hepatic lesion with fill-in enhancement

What is the diagnosis?

HCC





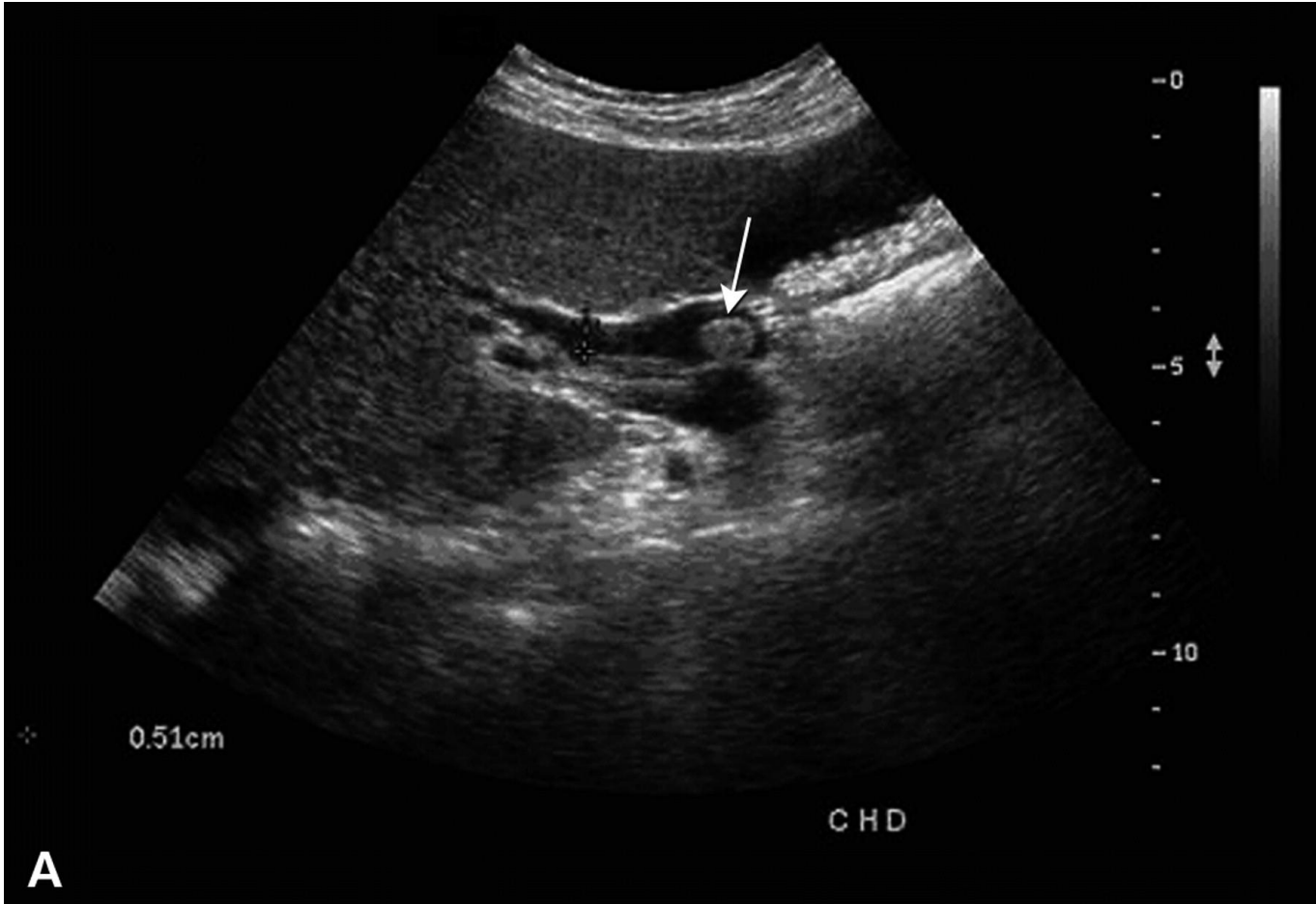
What is the modality?

What is the findings?

What is the diagnosis?

What is the expected symptoms and signs the patient has?





What is the modality?

U/S

What is the findings?

Hyperechoic lesion in CBD

What is the diagnosis?

CBD stone

What is the expected symptoms and signs the patient has?

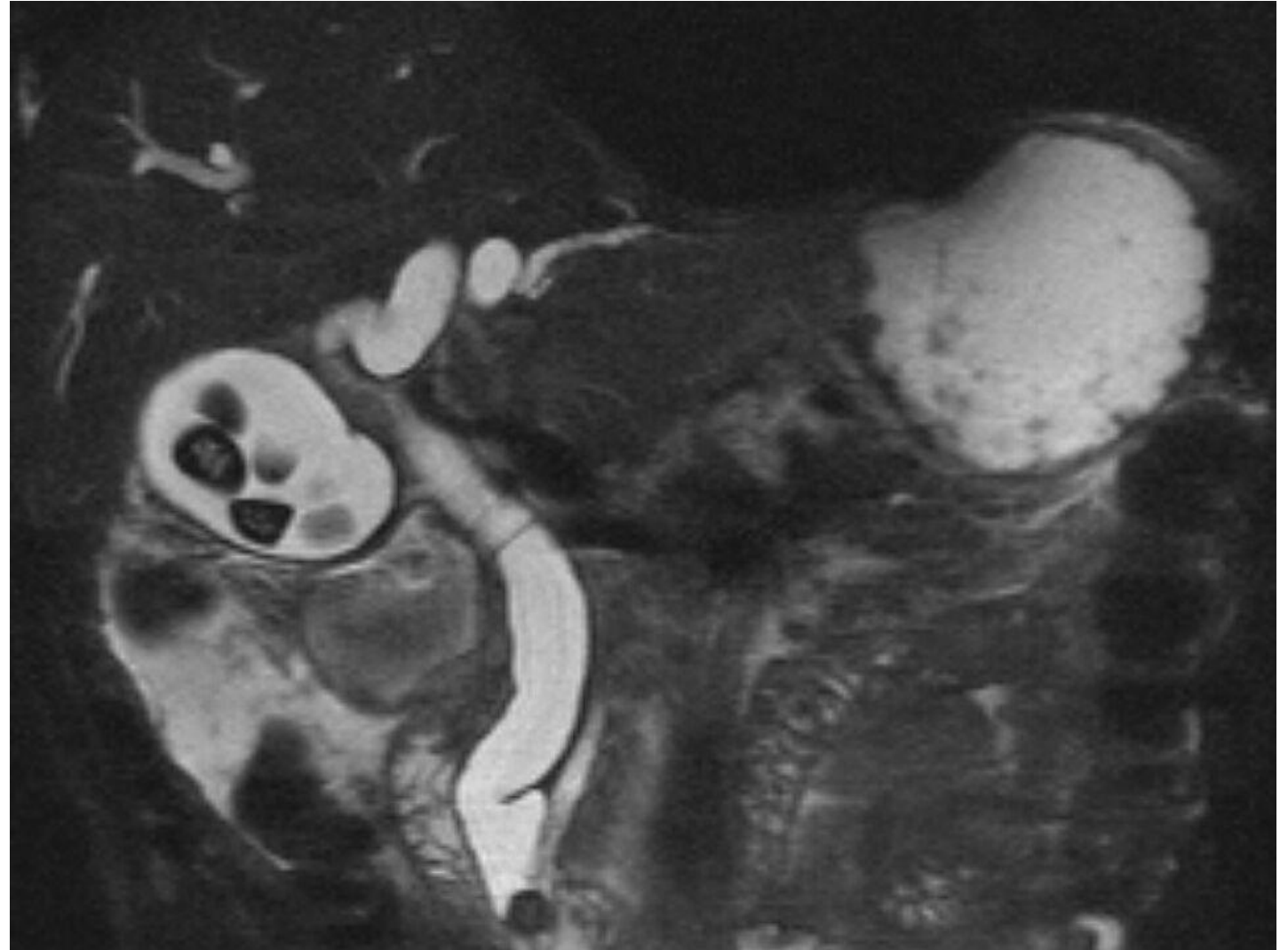
Yellow discoloration. RUQ pain.

Hyper-bilirubinemia.

MRCP = **MRI** Cholangio-**P**ancreatico-graphy

The dark signals in the gallbladder = stones

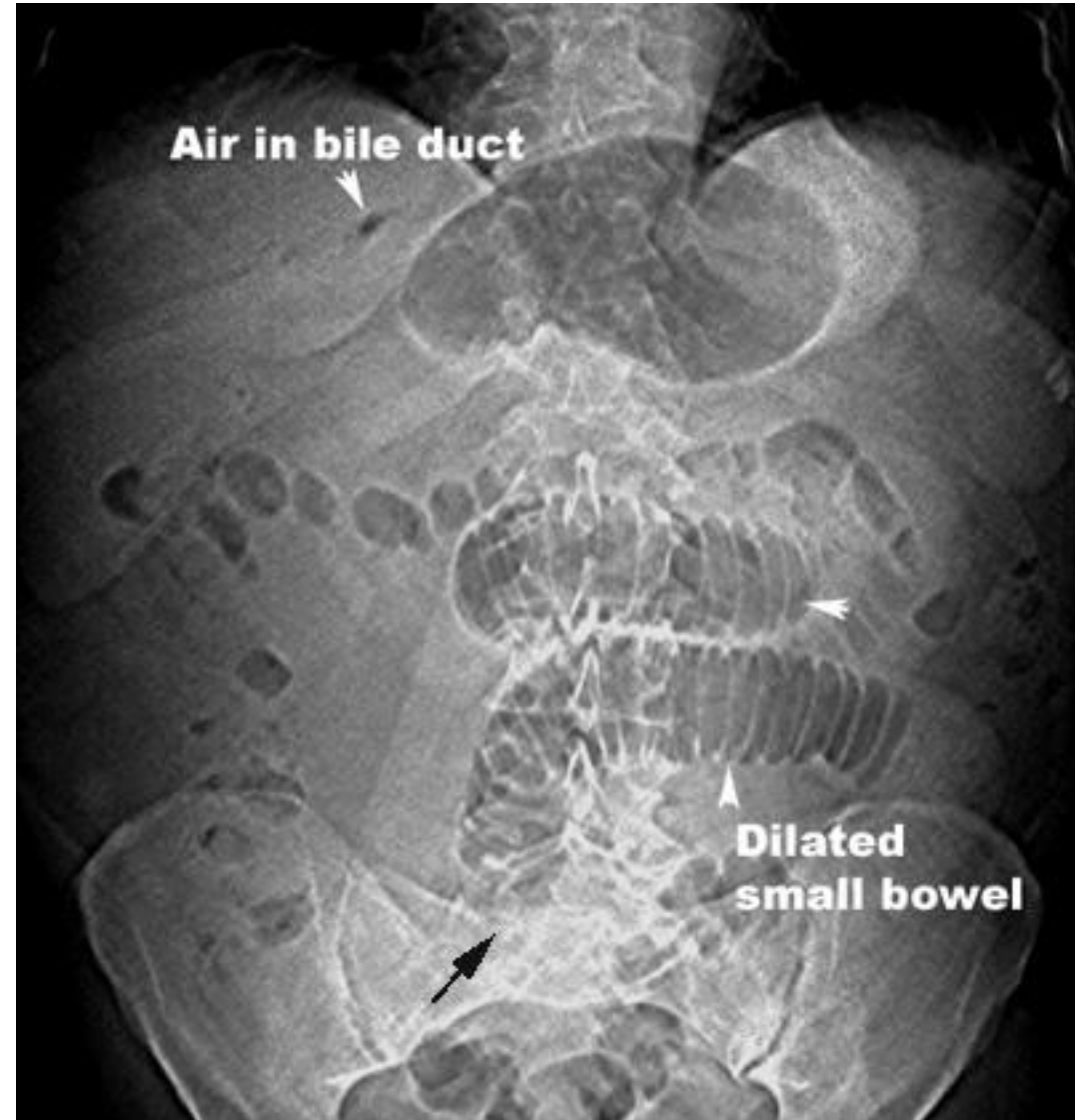
The dark signal in the distal CBD is stone



Triad:

1. Air in the bile ducts, **Pneumobilia**.
2. **Dilatation** of the small bowel.
3. Calcified **stone** in the distal bowel.

Triad of ? diagnosis



Gallstone Ileus

Diagnosis by **Radiology**

Treatment by **Surgery**

