

**Interactive
CHEST IMAGING
lecture**

366 COURSE

October 2017

Anatomy and Radiologic investigation of Chest and CVS

By

Dr Mohamed Sherif El-Sharkawy

ASSOCIATE PROF. and Consultant Radiologist

KKUH

KING SAUD UNIVERSITY

Objectives

1. To understand the basic radiologic anatomy of the chest and CVS.
- 2. To recognize the basic radiological examinations applied in chest and CVS diseases.**
- 3. To understand the radiological appearances of common chest and CVS diseases.**

Anatomy and Radiologic investigation of cardiovascular system

By

Dr Mohamed Sherif El-Sharkawy

ASSOCIATE PROF. and Consultant Radiologist

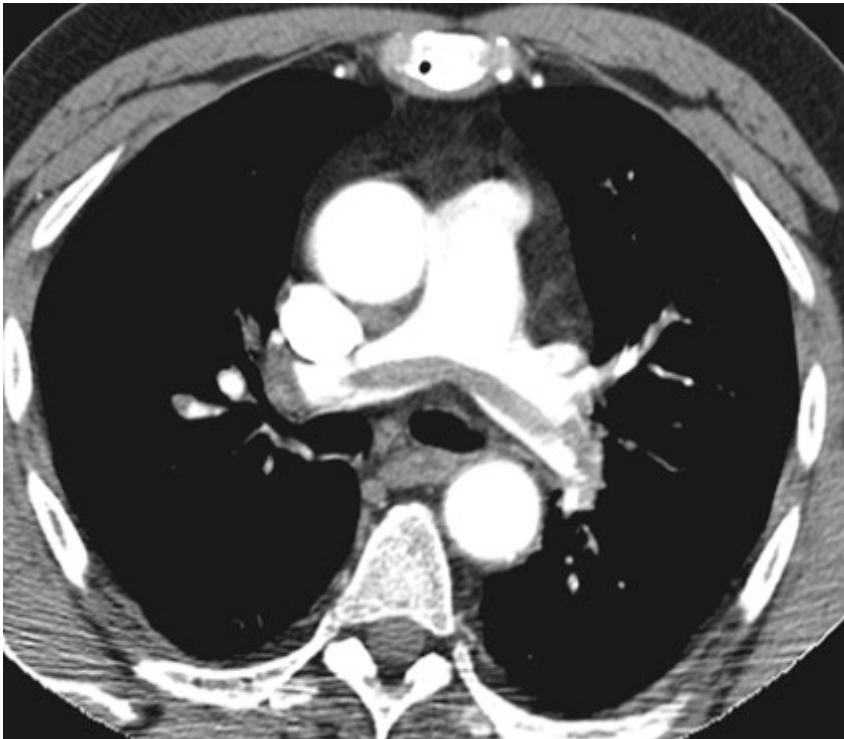
KKUH

KING SAUD UNIVERSITY

Objectives

1. To understand the basic radiologic anatomy of the cardiovascular system.
2. To recognize the basic radiological examinations applied in cardiovascular system diseases.
3. To understand the radiological appearances of common cardiovascular system diseases.

Question ?



- Patient presented to ER with acute chest pain and SOB
- Past history of pelvic fracture with hospital admission for 5 weeks.
- **Answer the following question by selecting the SINGLE BEST ANSWER**

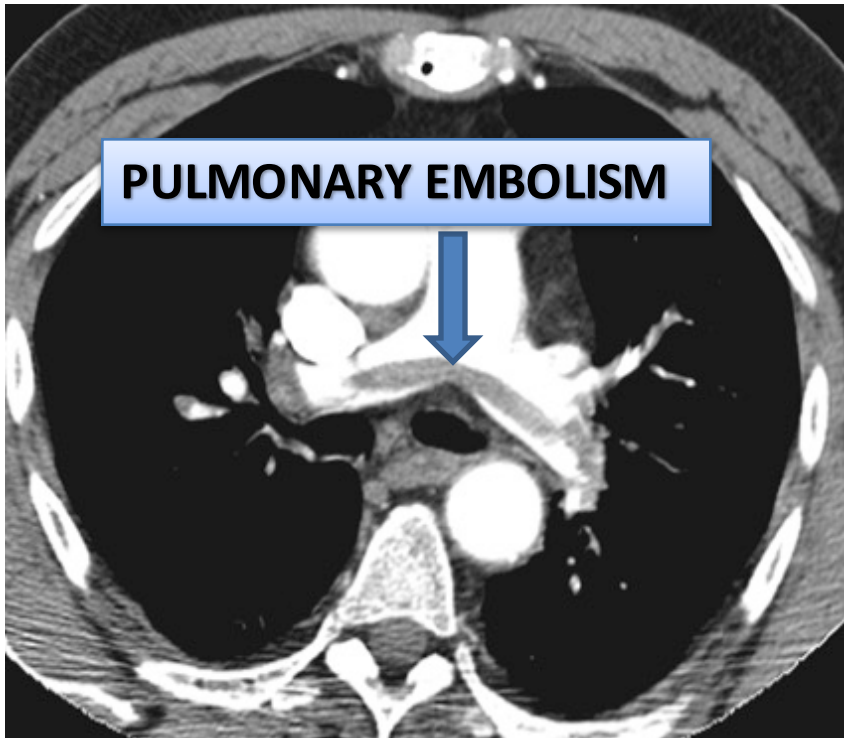
1. -----

2. ----- **X**

3. -----

4. -----

Answer ?

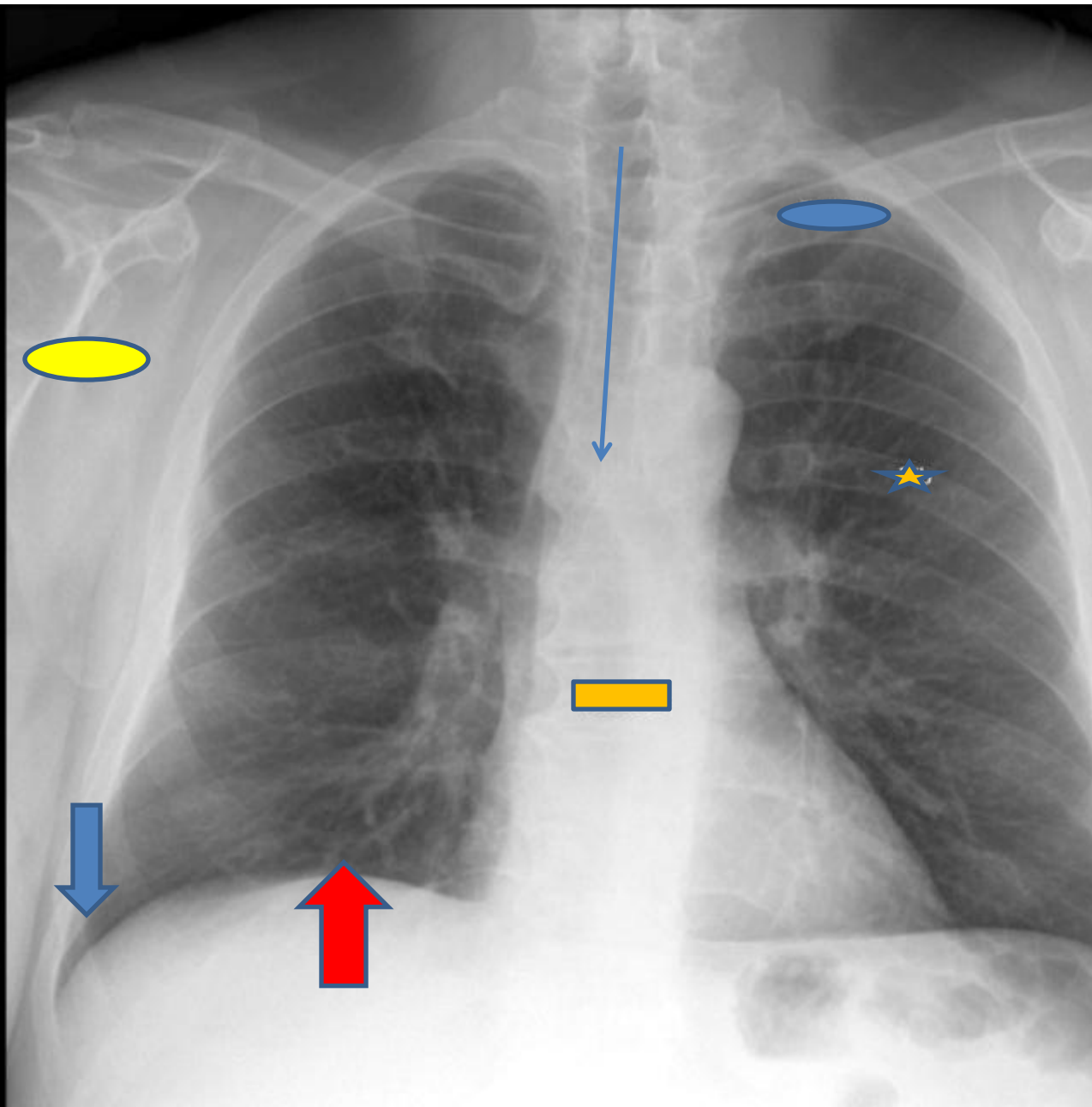


- Patient presented to ER with acute chest pain and SOB
- Past history of pelvic fracture with hospital admission for 5 weeks.

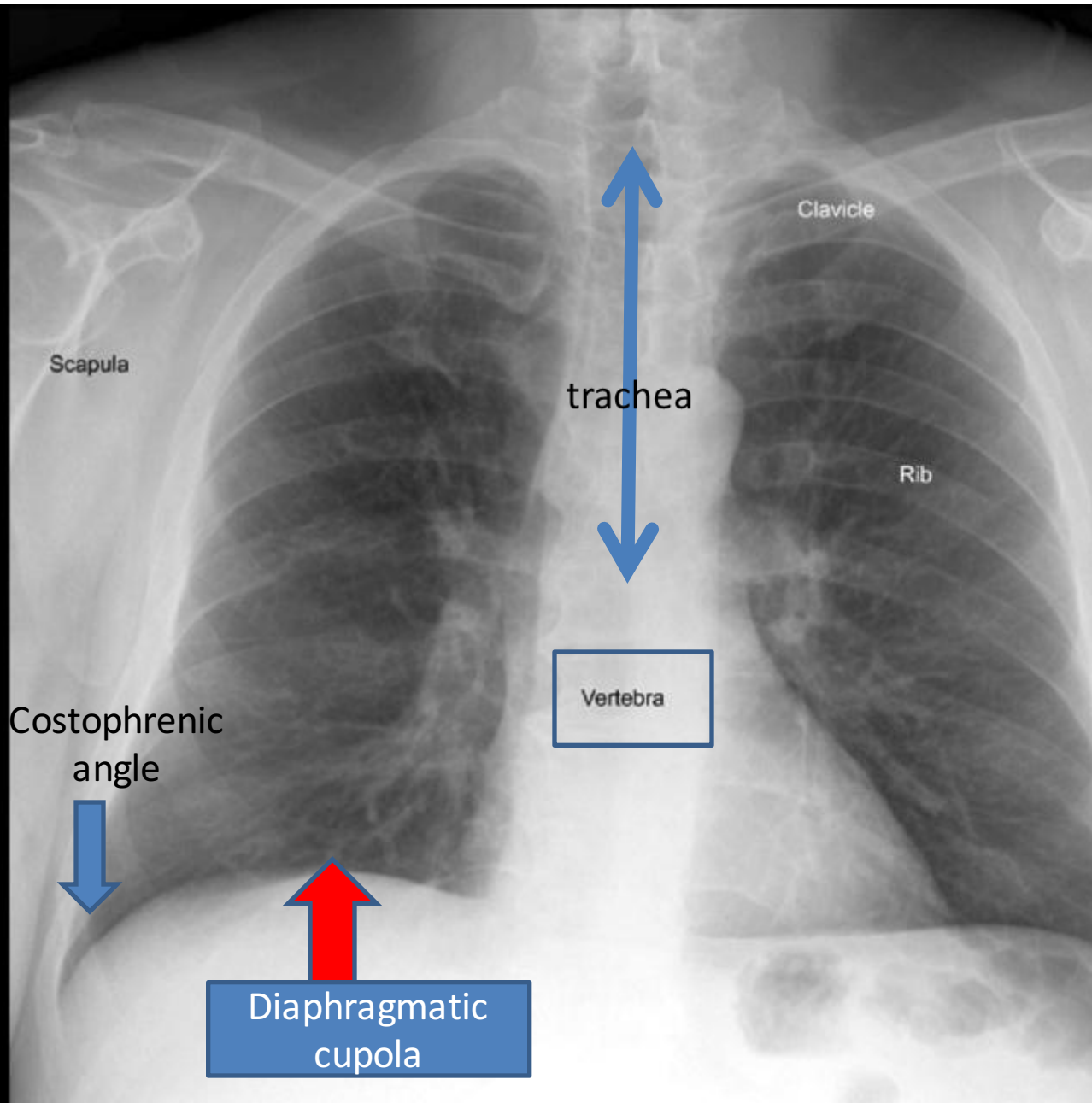
Q-SINGLE BEST ANSWER

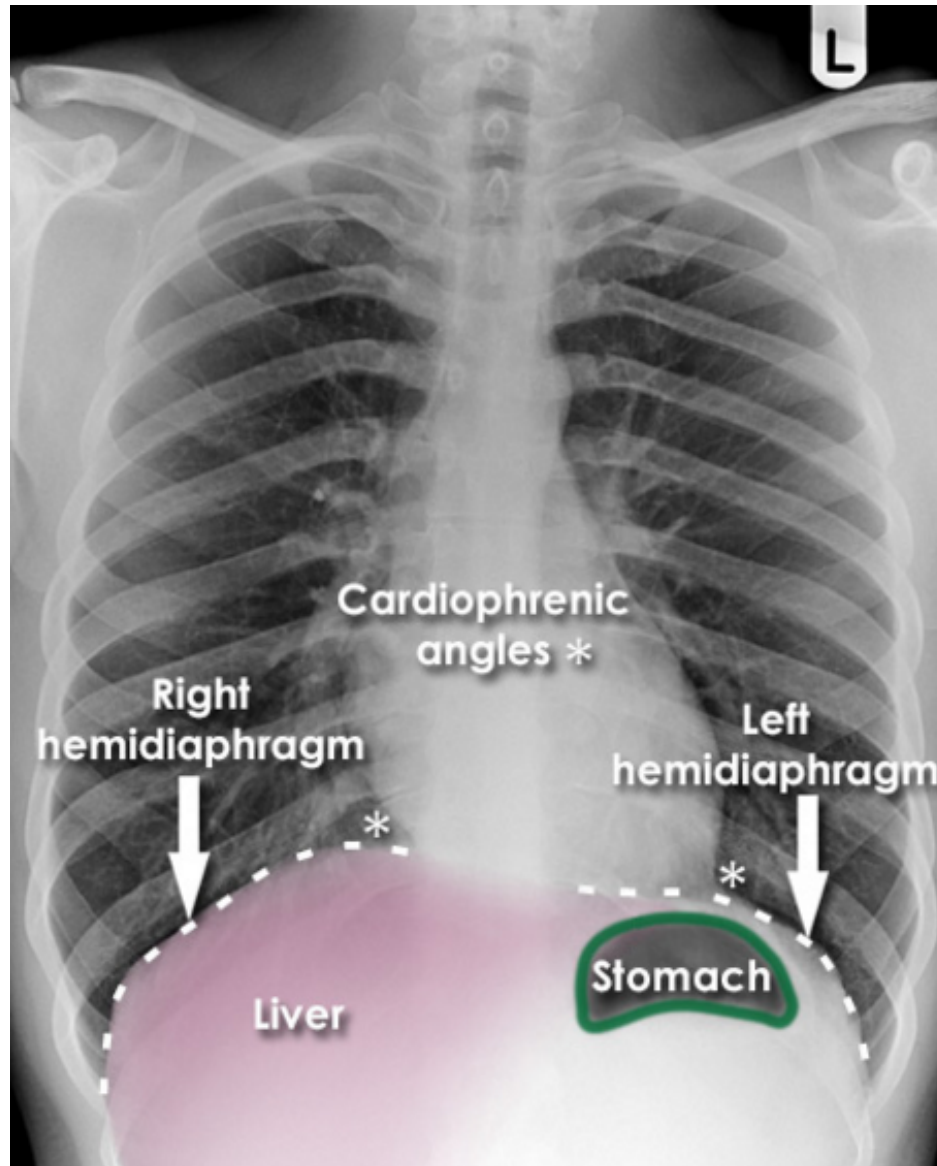
1. -----
2. CTA showing PULMONARY EMBOLISM **X**
3. -----
4. -----

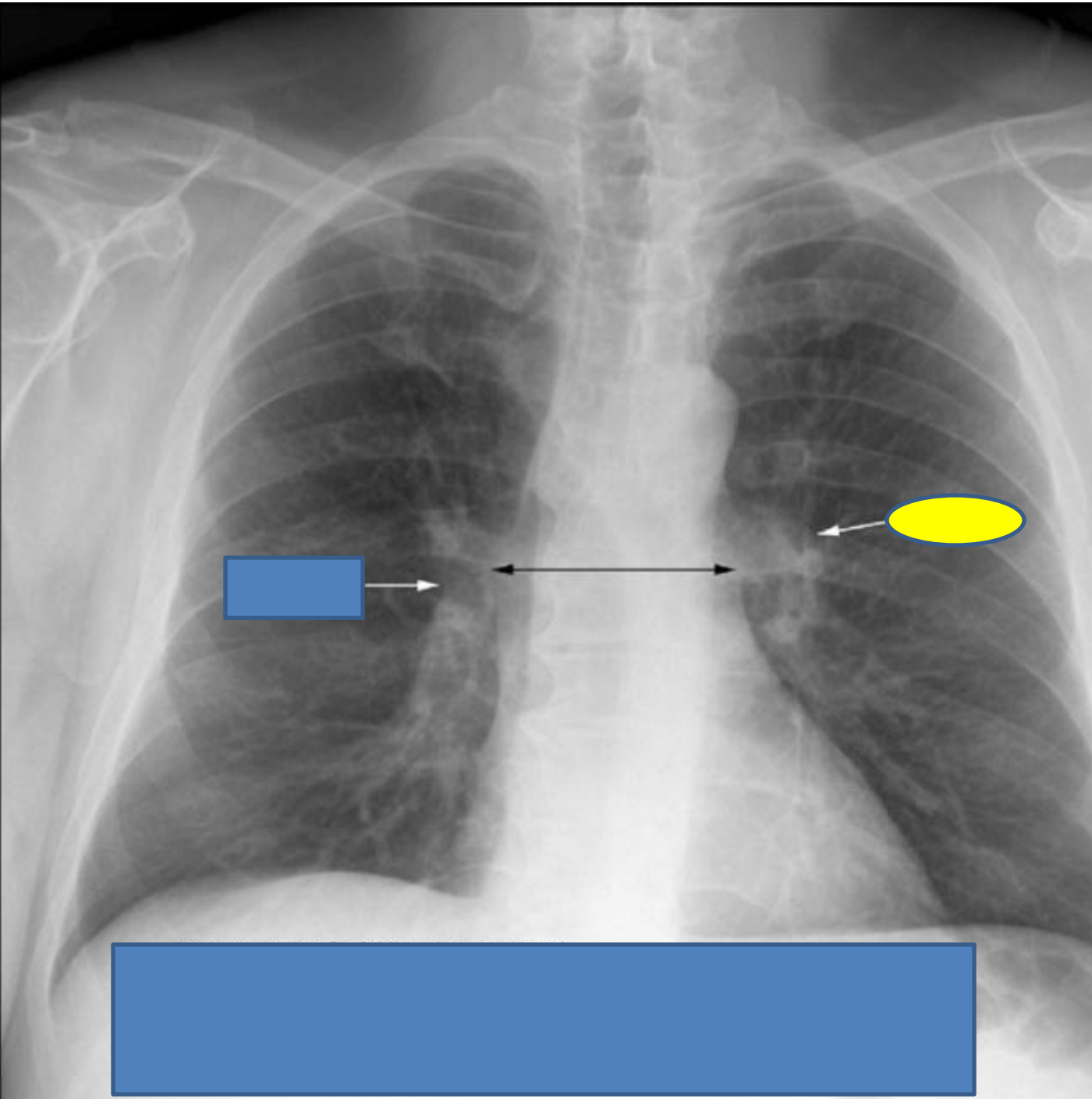
Anatomy



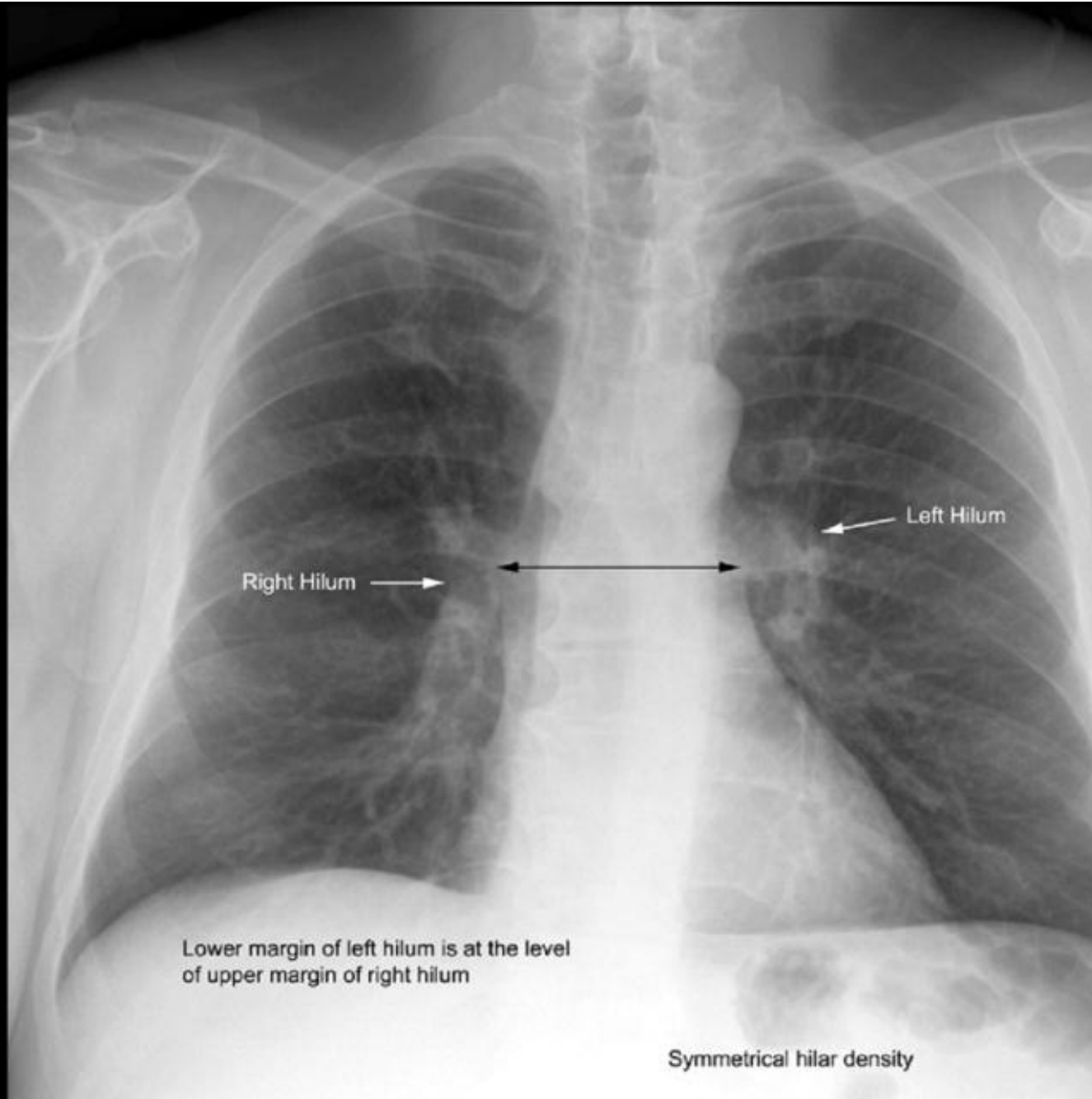
Anatomy



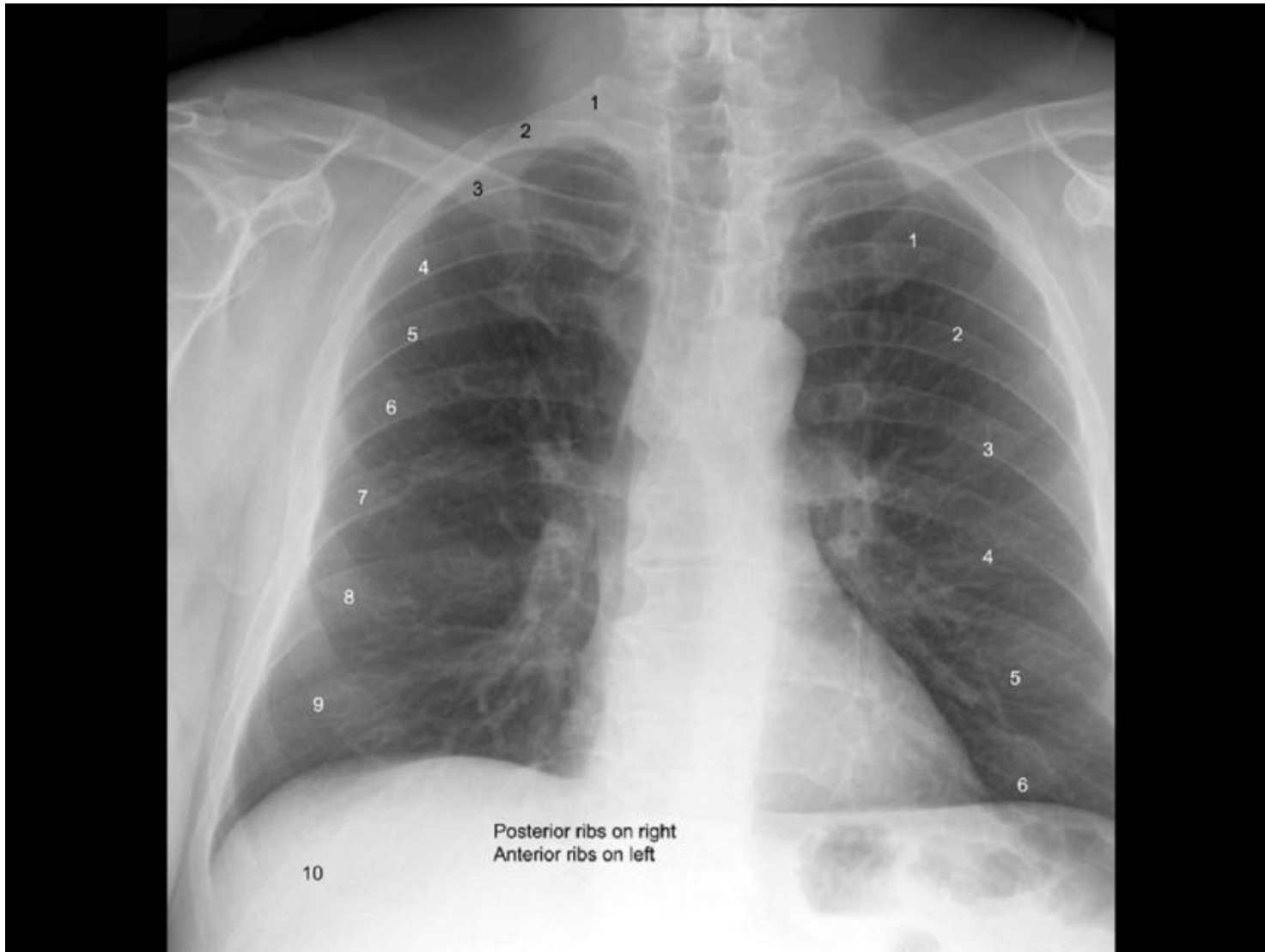




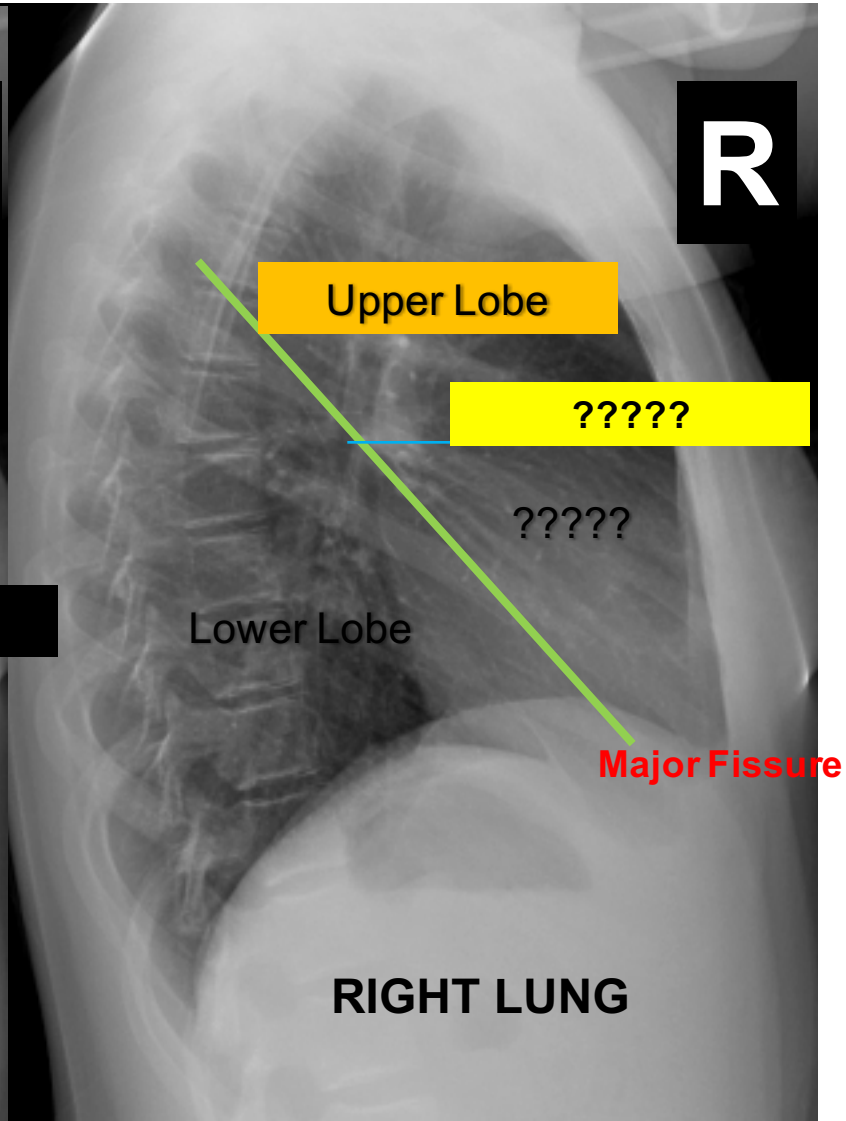
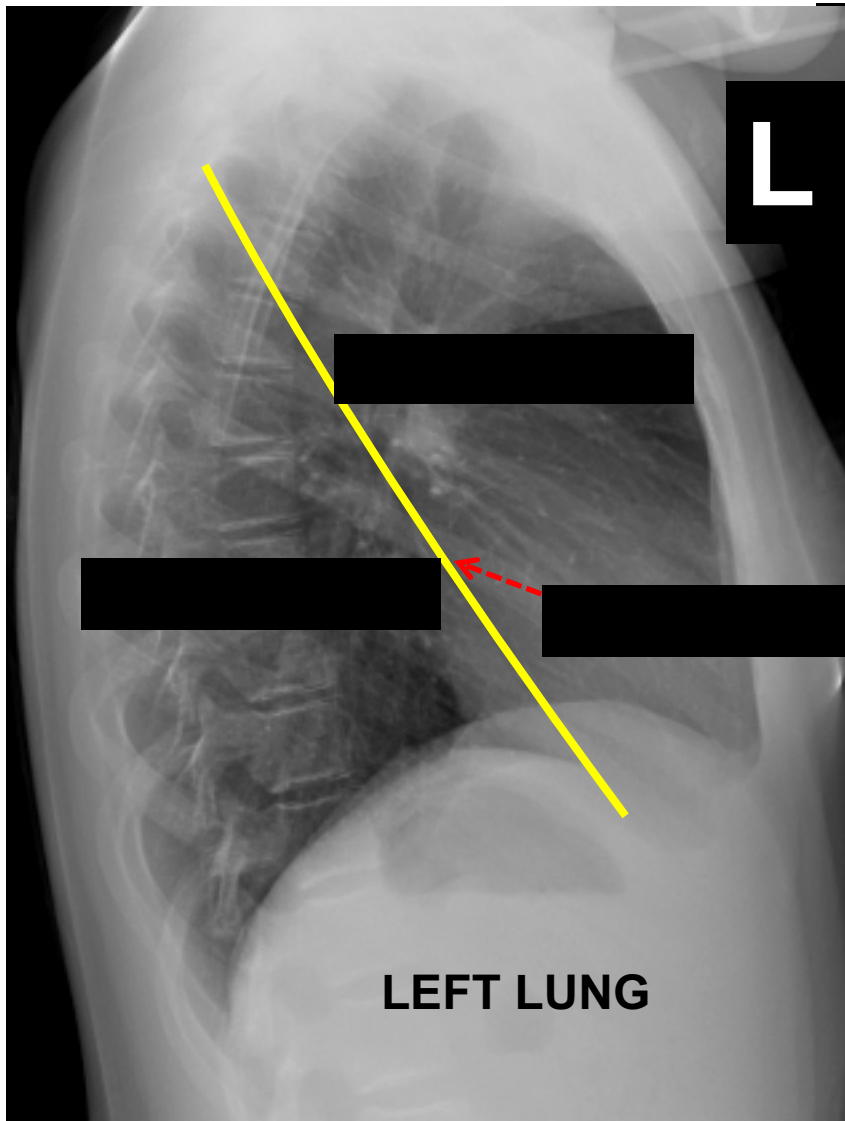
Hilum



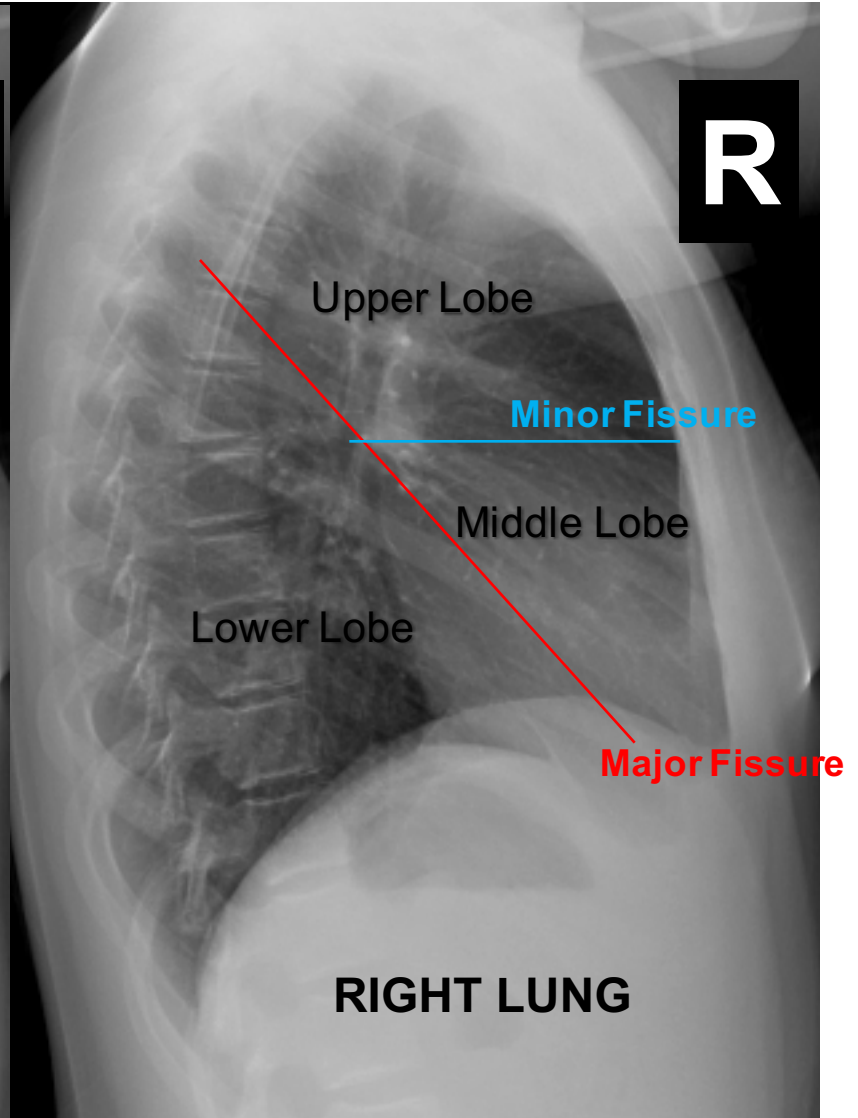
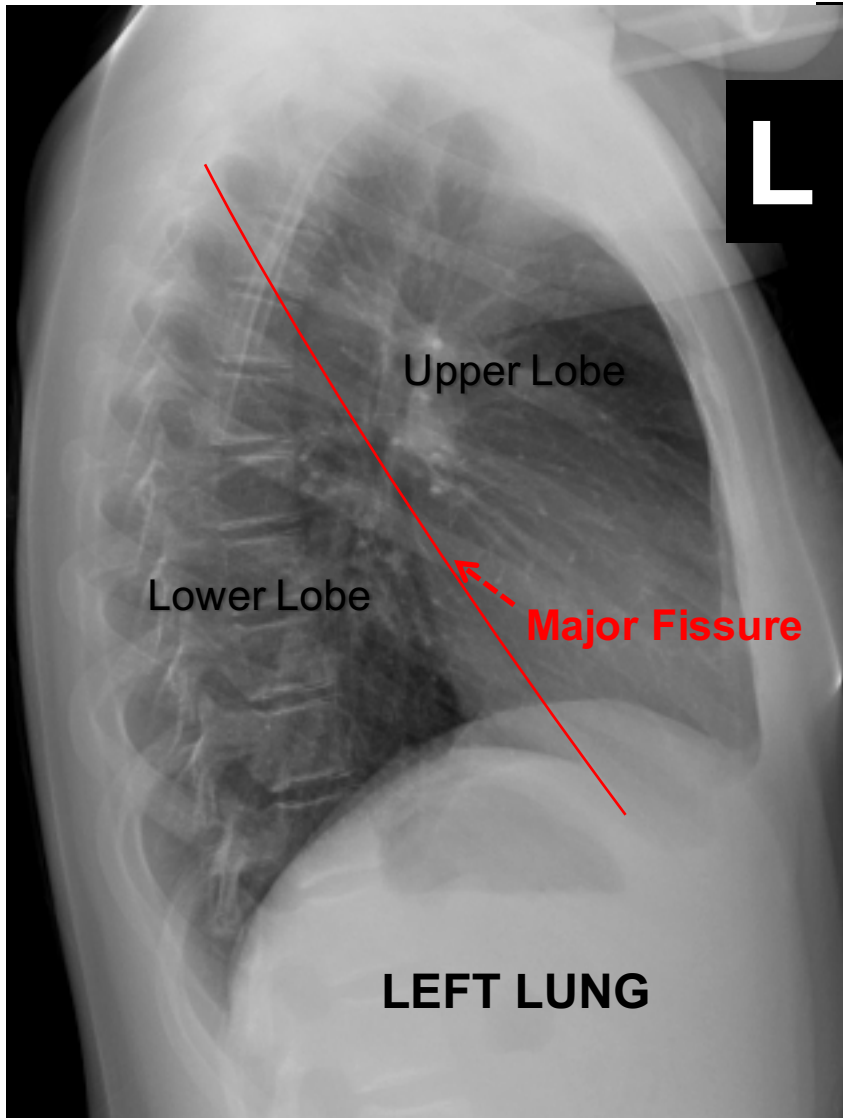
COUNTING RIBS



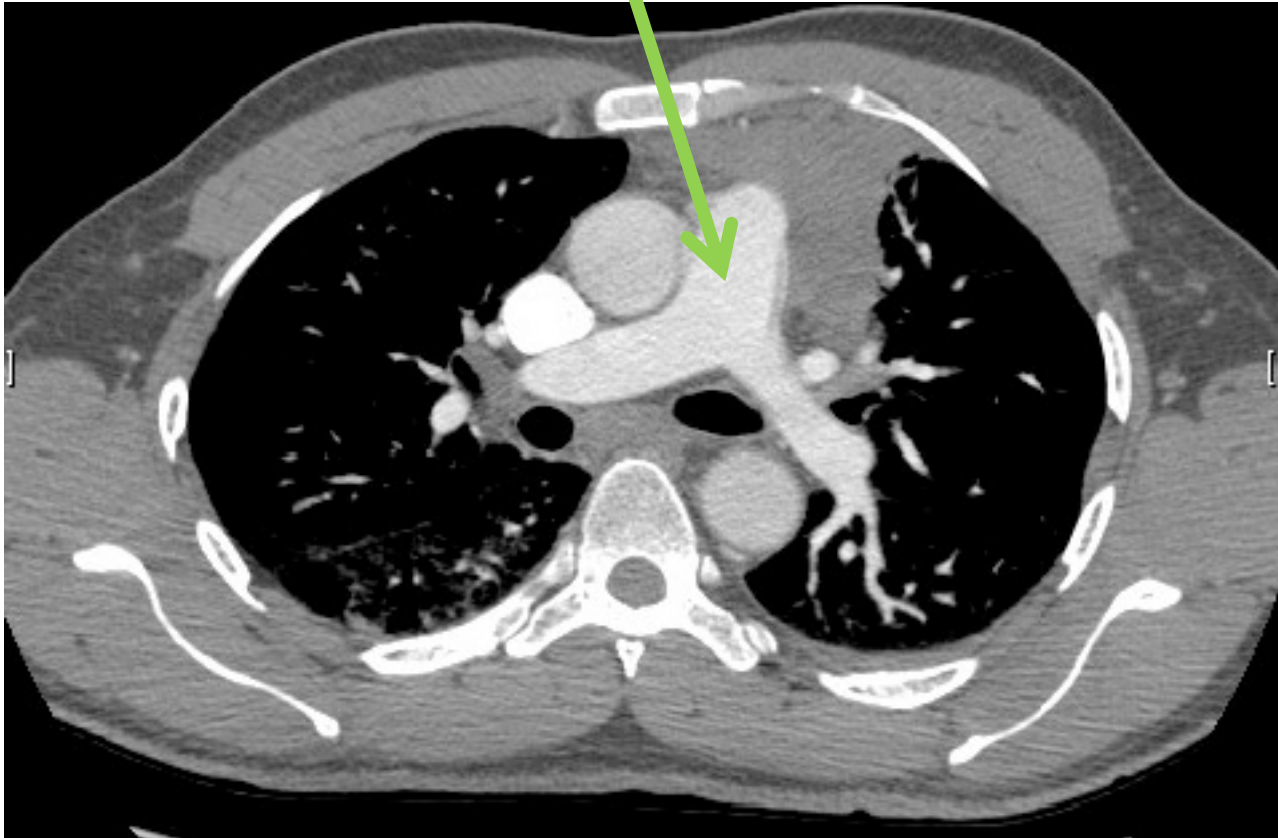
Radiological Anatomy of the Chest



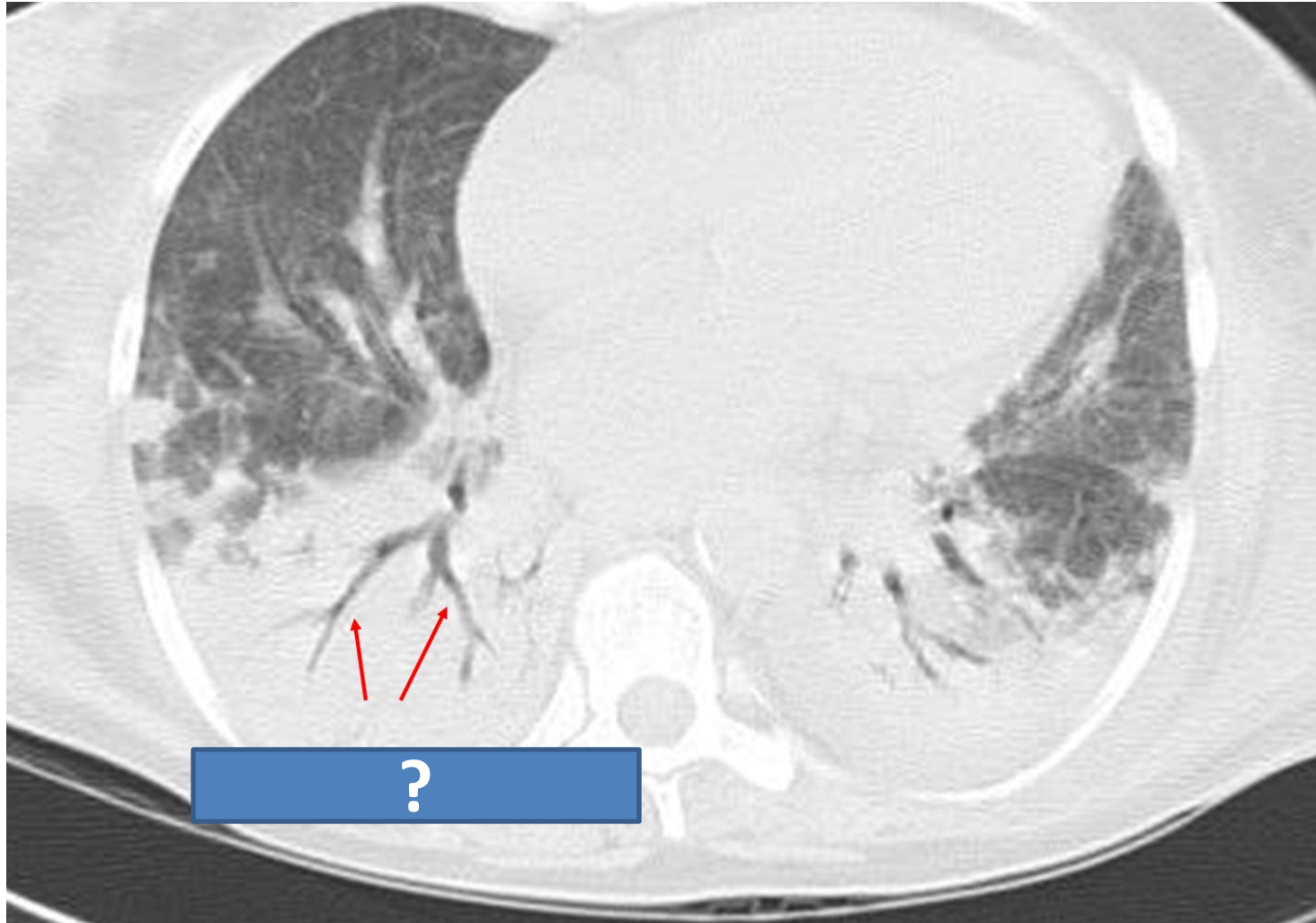
Radiological Anatomy of the Chest

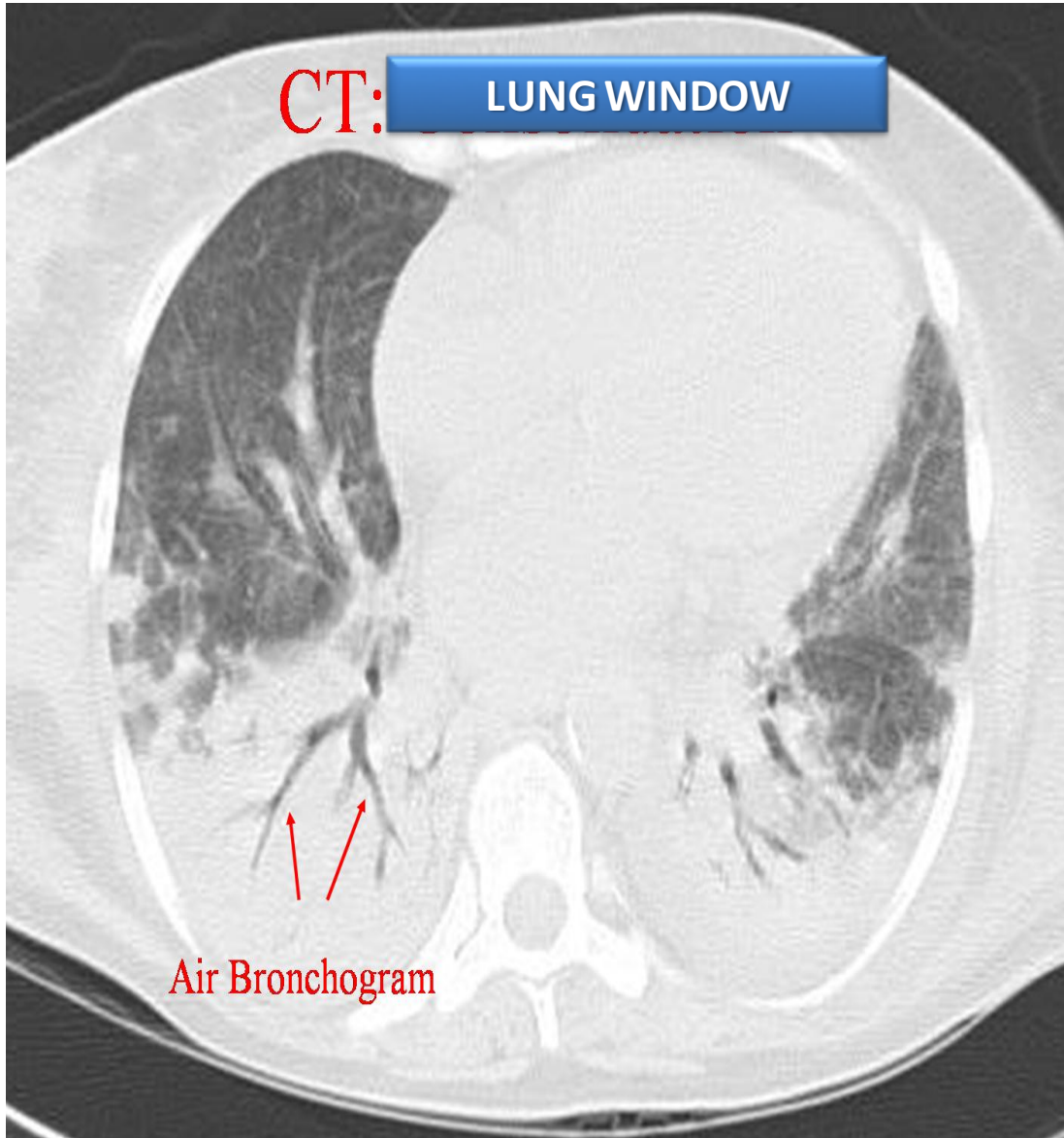


EXAM?
NORMAL/ABNORMAL?

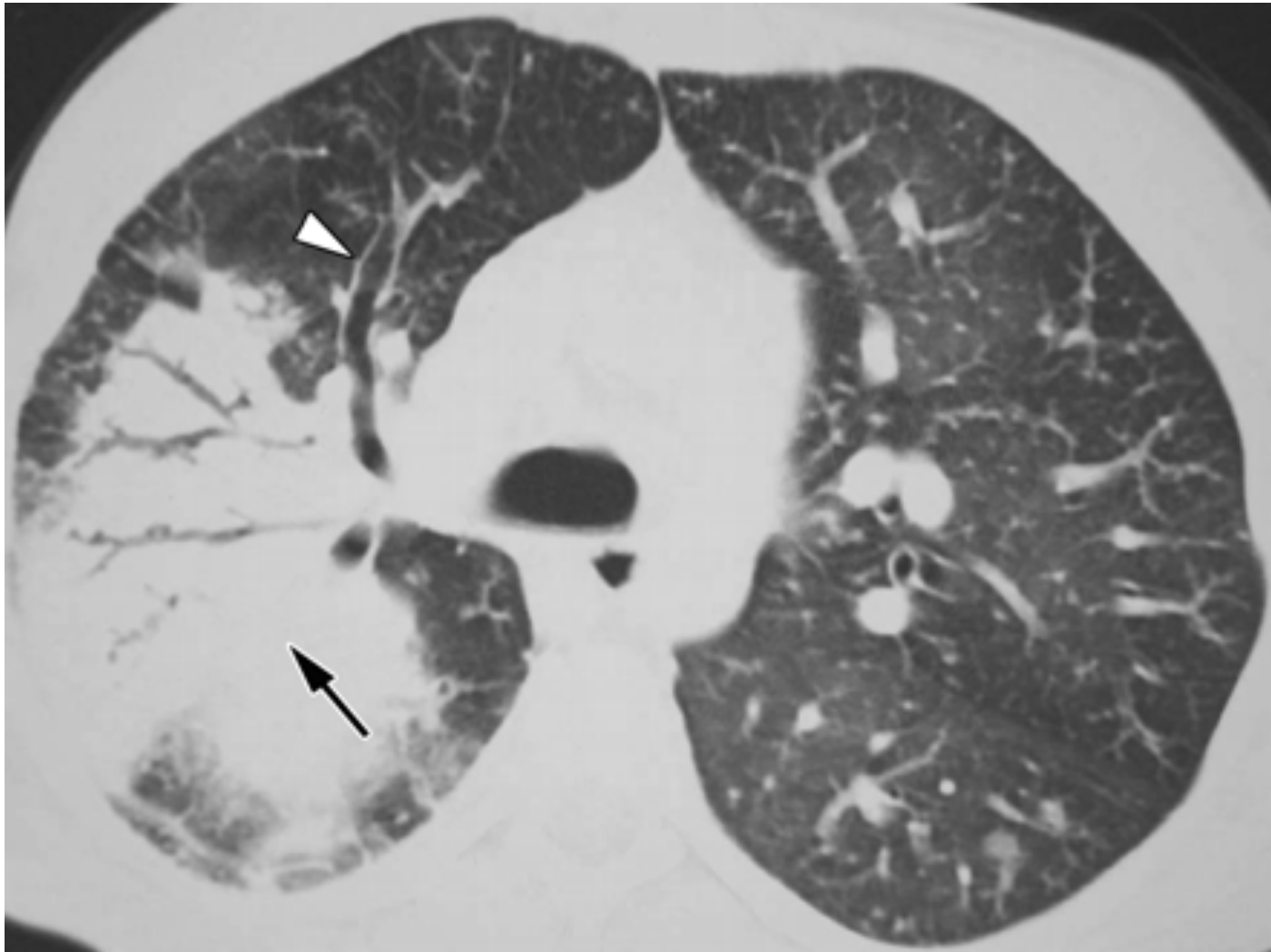


1-EXAM
2-SIGN?
3-DIAGNOSIS?



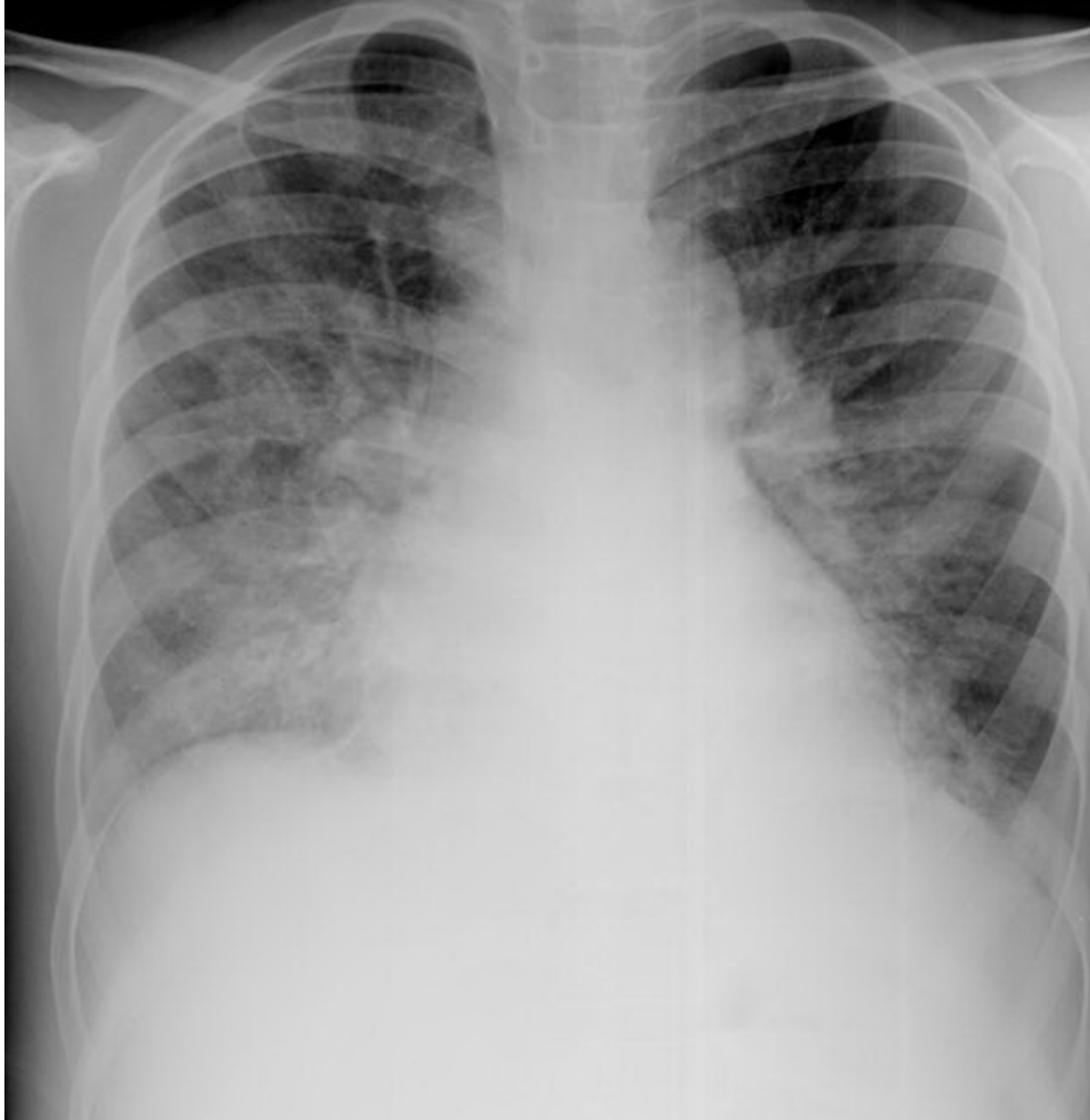

Consolidation

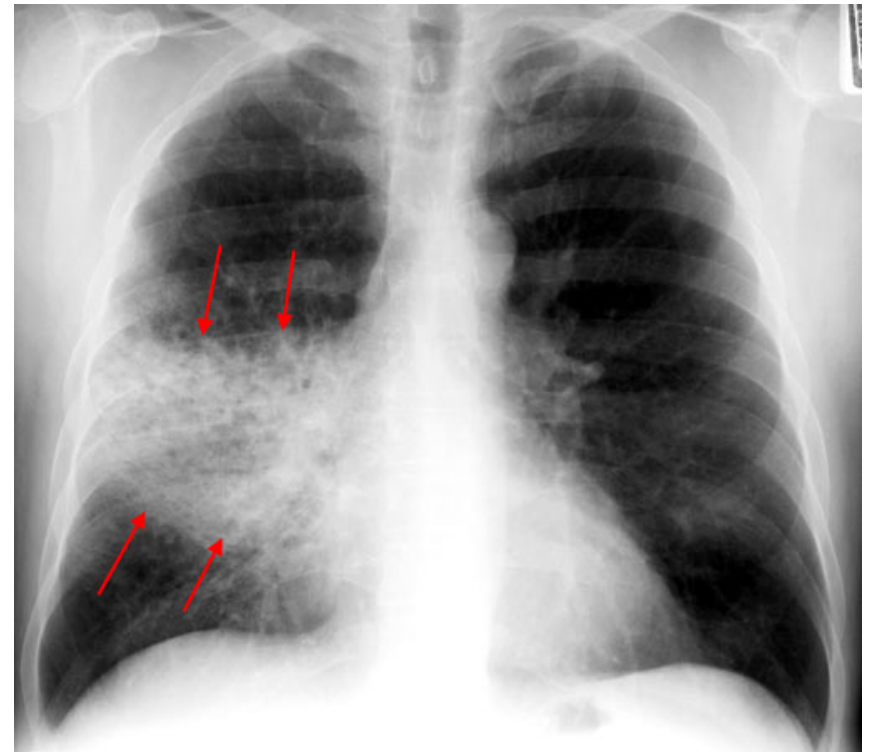
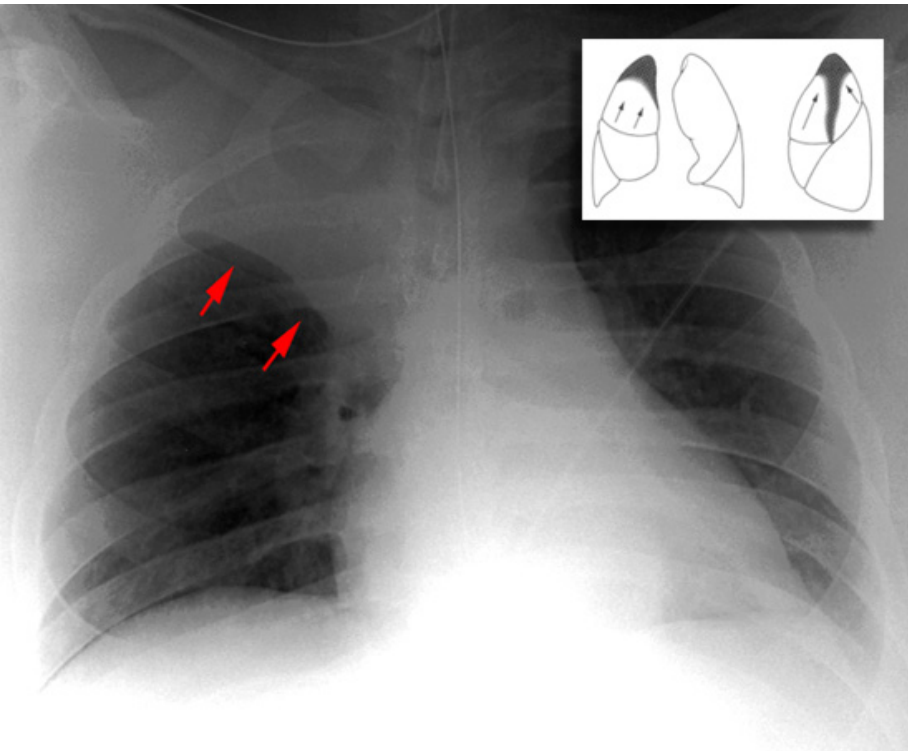


1-EXAM
2-SIGN?
3-DIAGNOSIS?

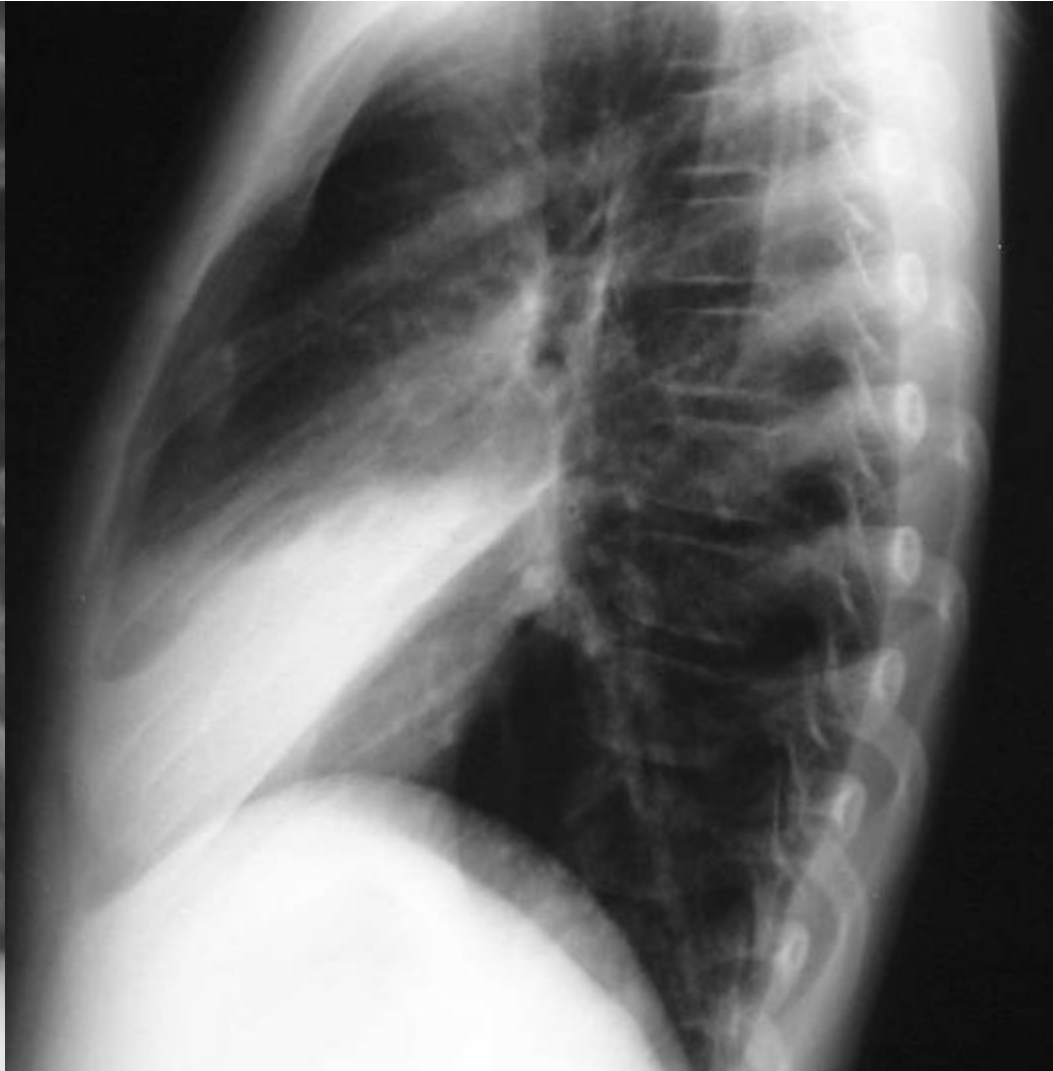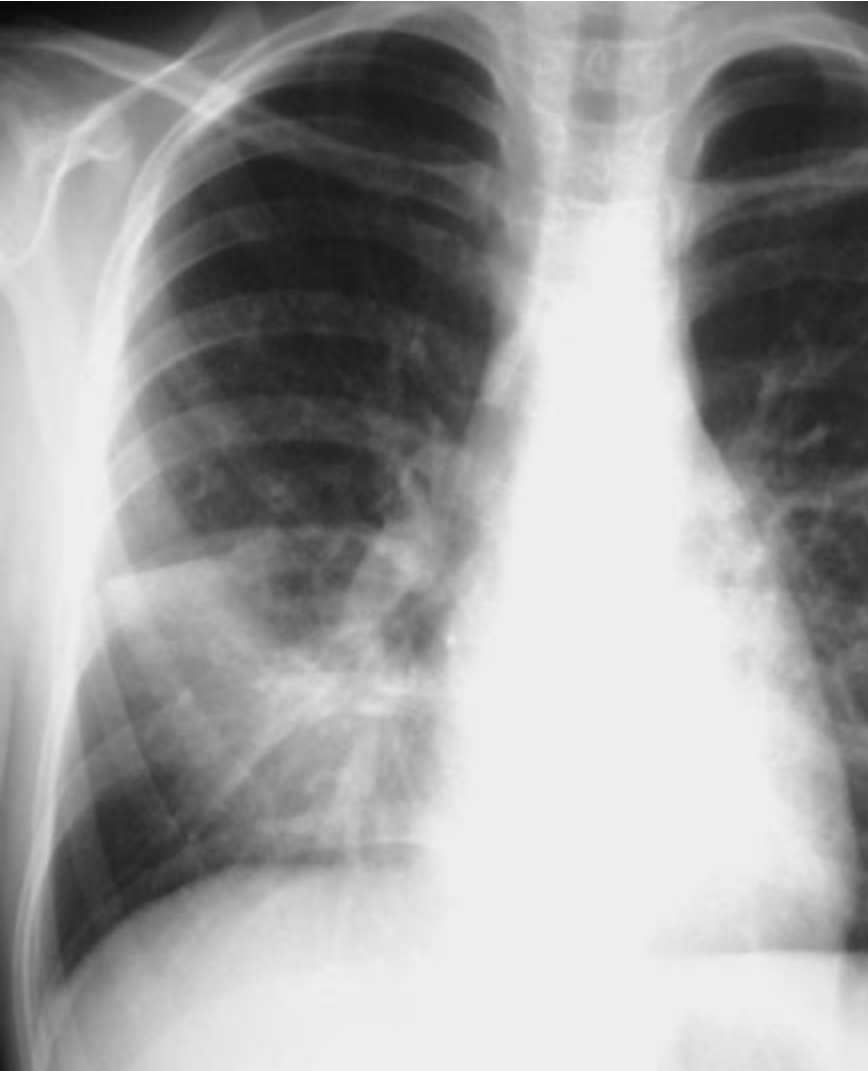MASS OR INFILTRATION



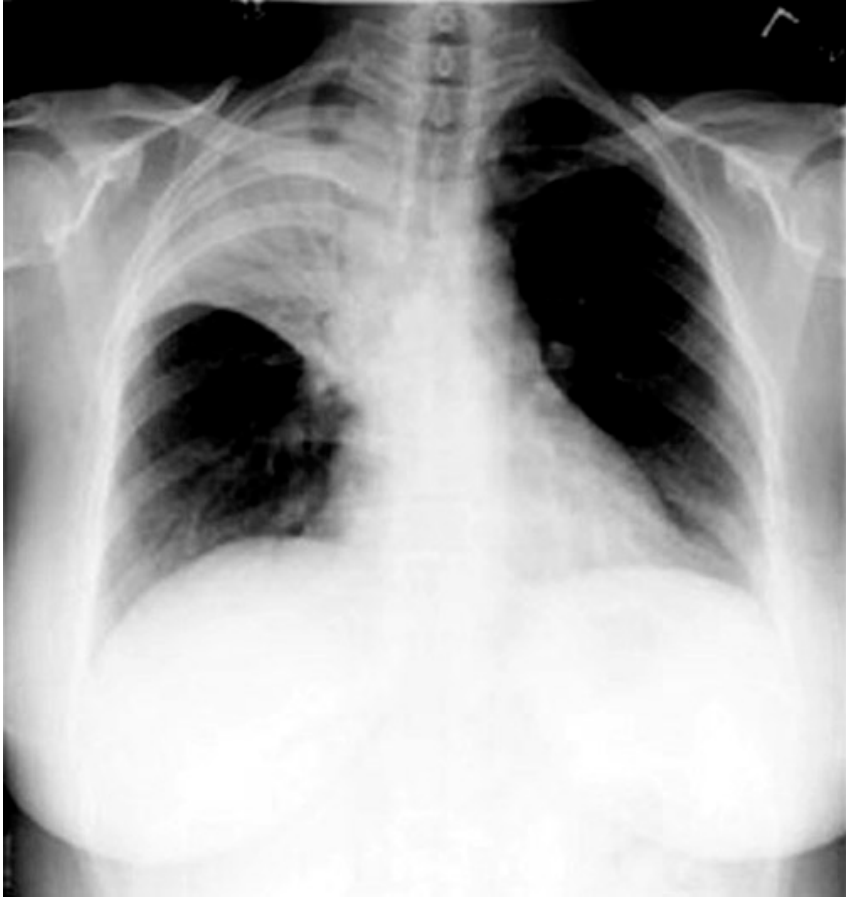ATELECTASIS Vs PNEUMONIA



Right ????? lobe ??????

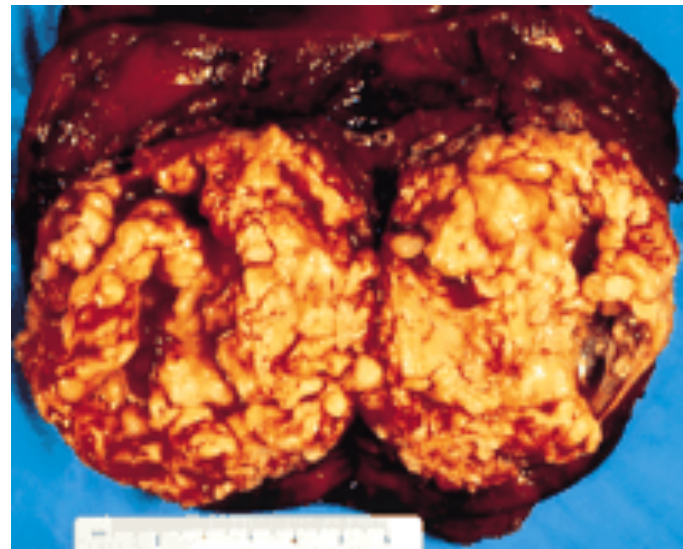
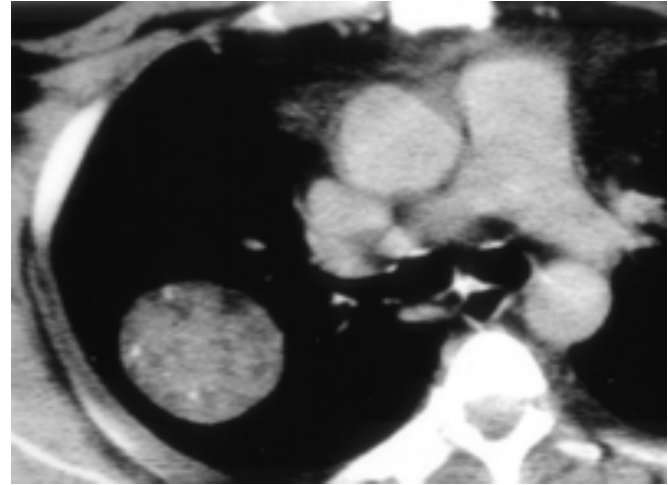
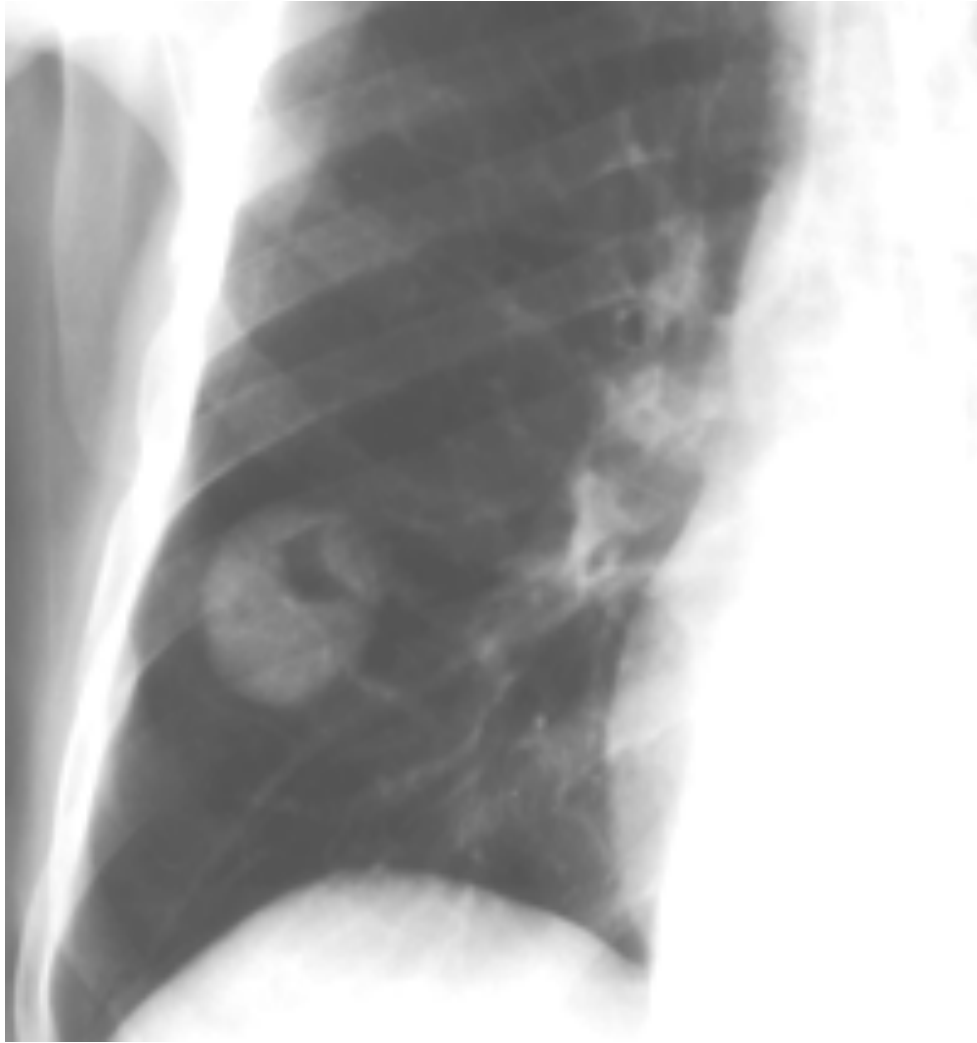

DIAGNOSIS

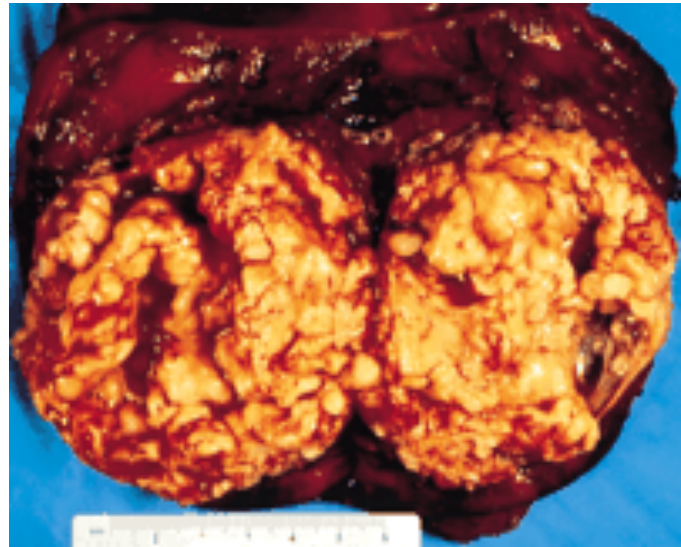
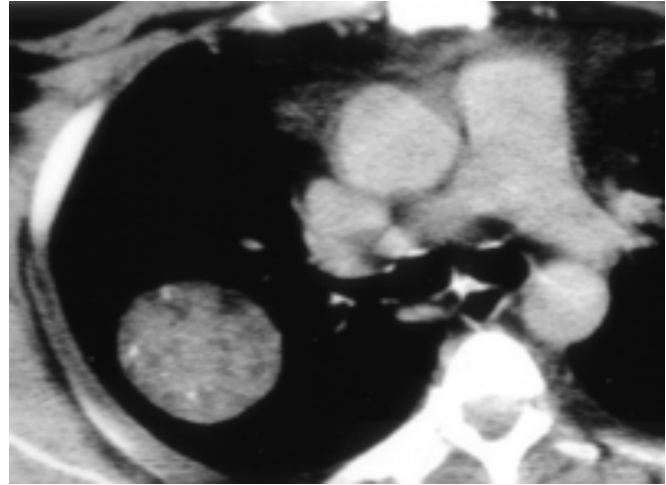
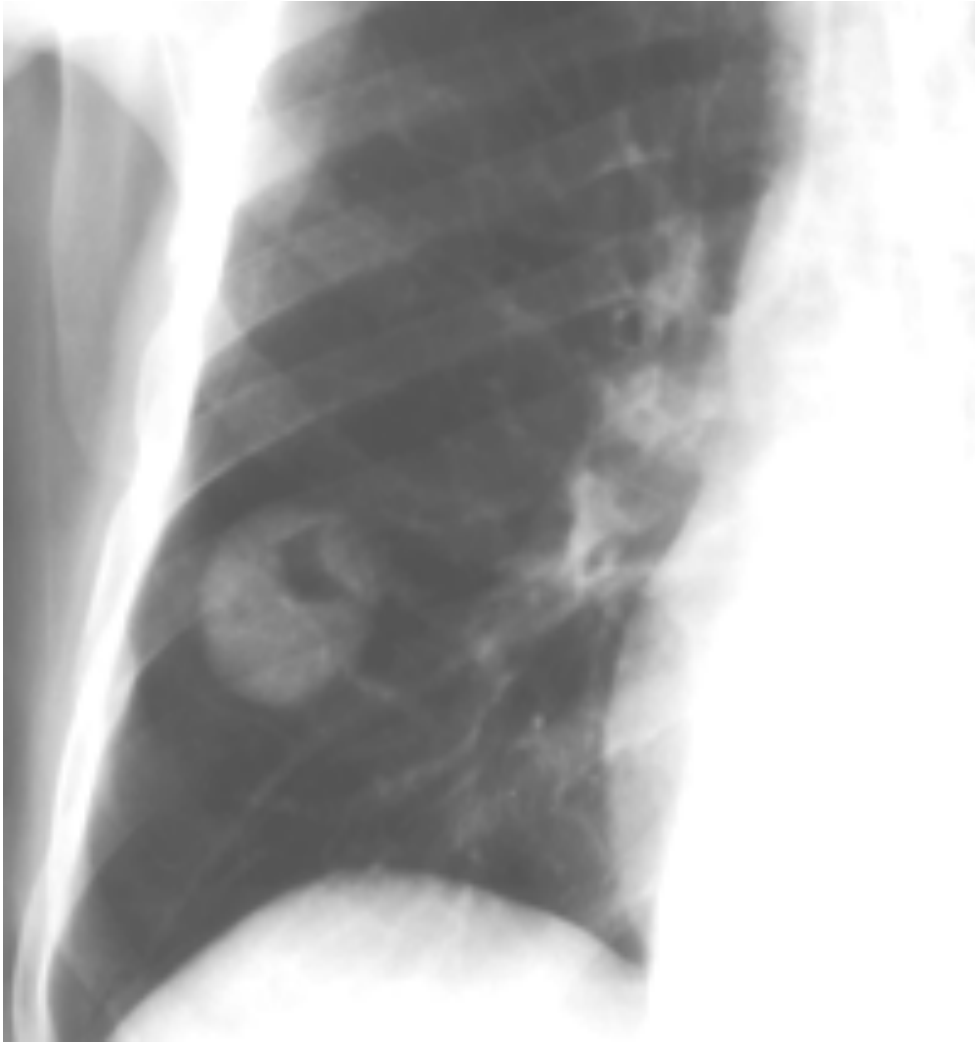

- 37 YEARS OLD PATIENT WITH SOB AND FEVER.

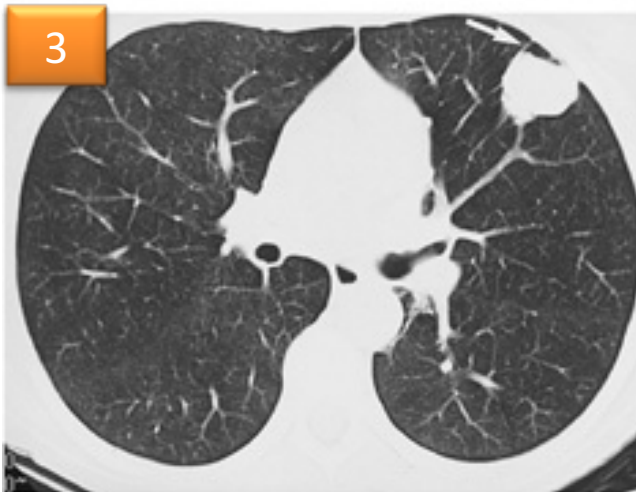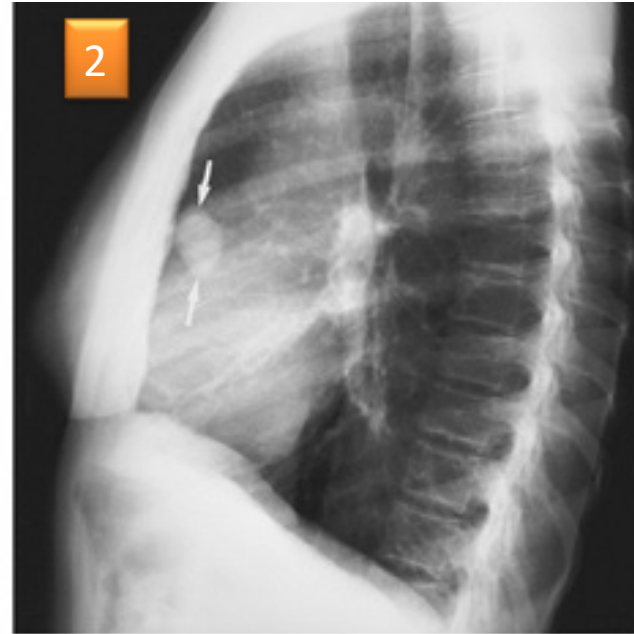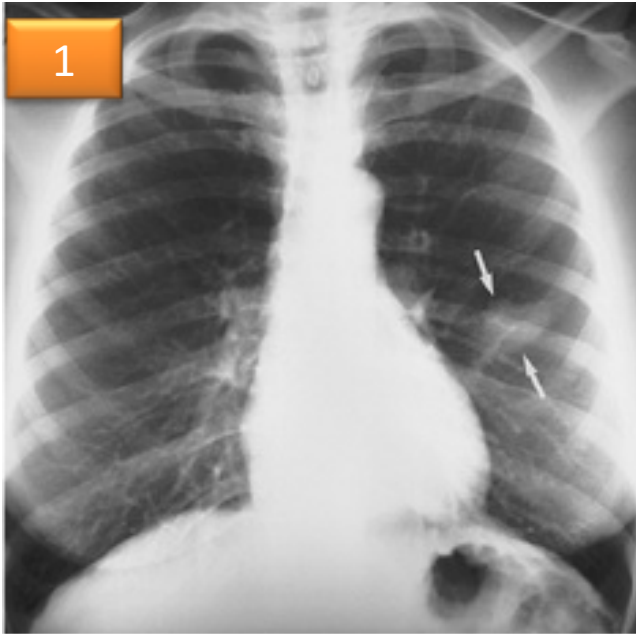
MASS OR INFILTRATION ?



Neoplastic: MASS

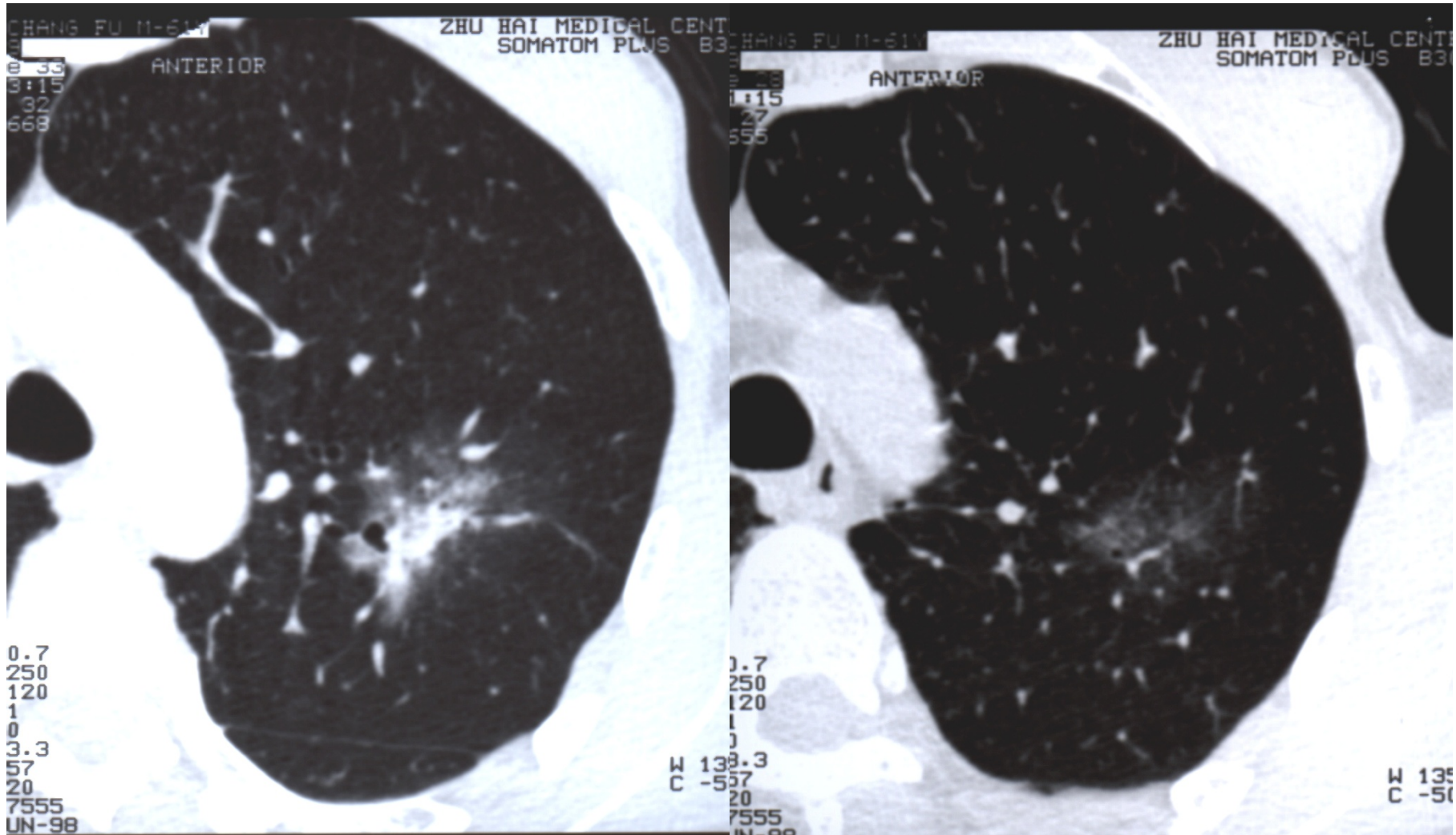


MASS OR INFILTRATION ? STEPS

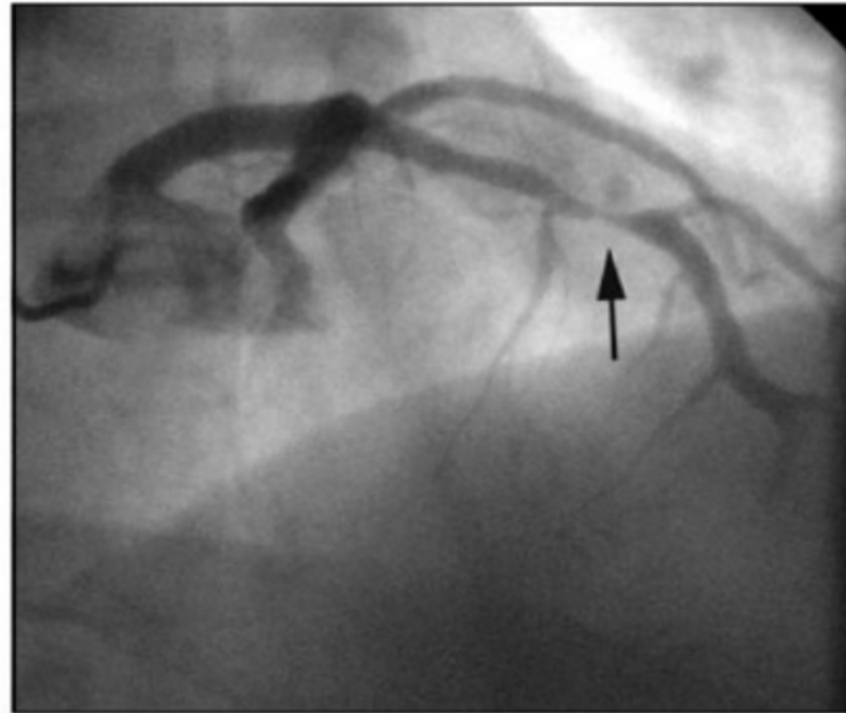
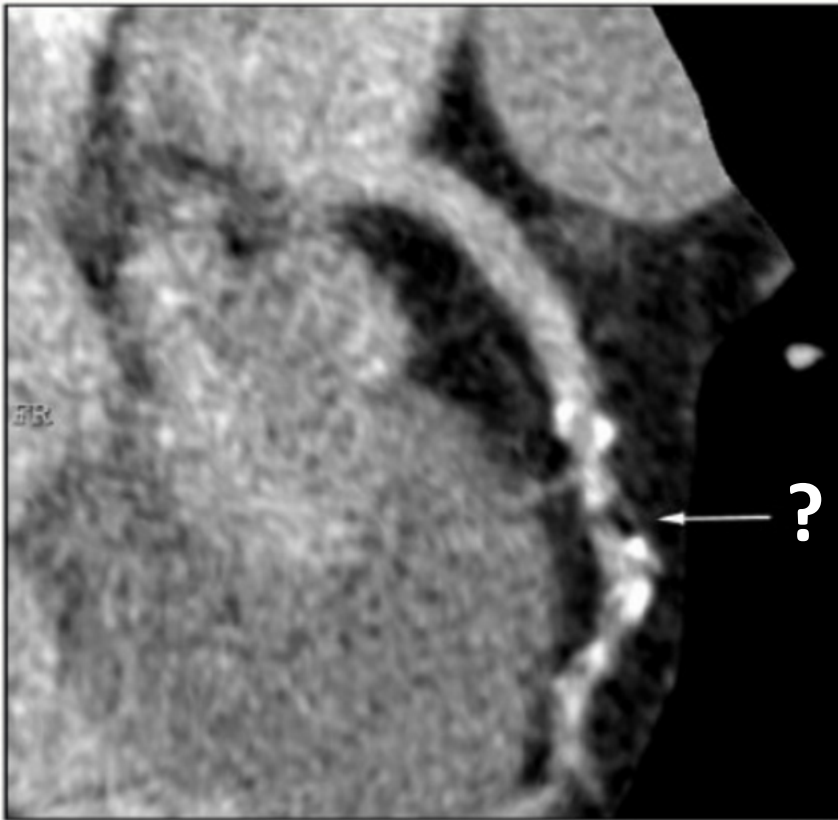


← ---?--- WINDOW

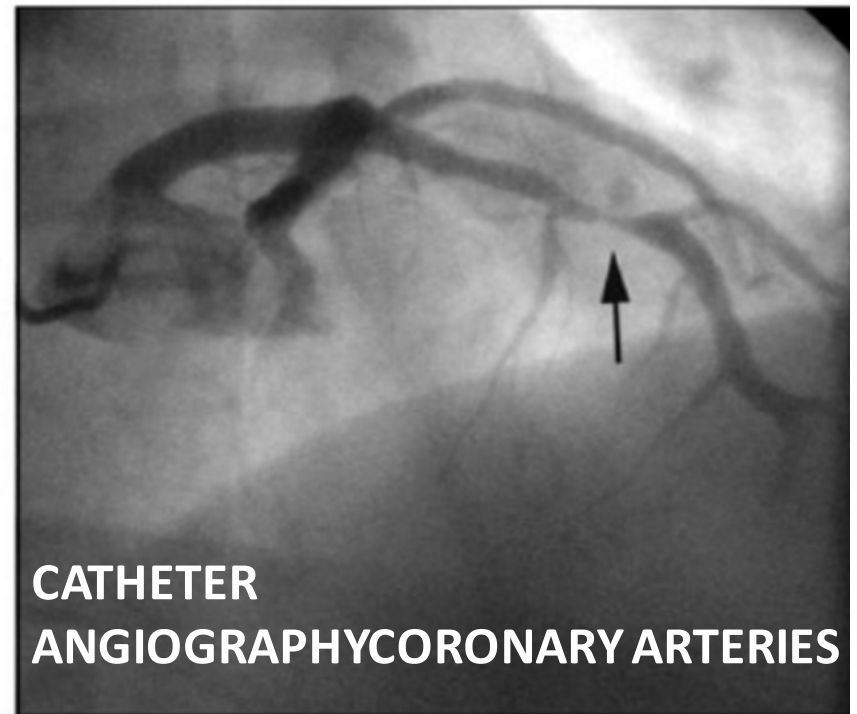
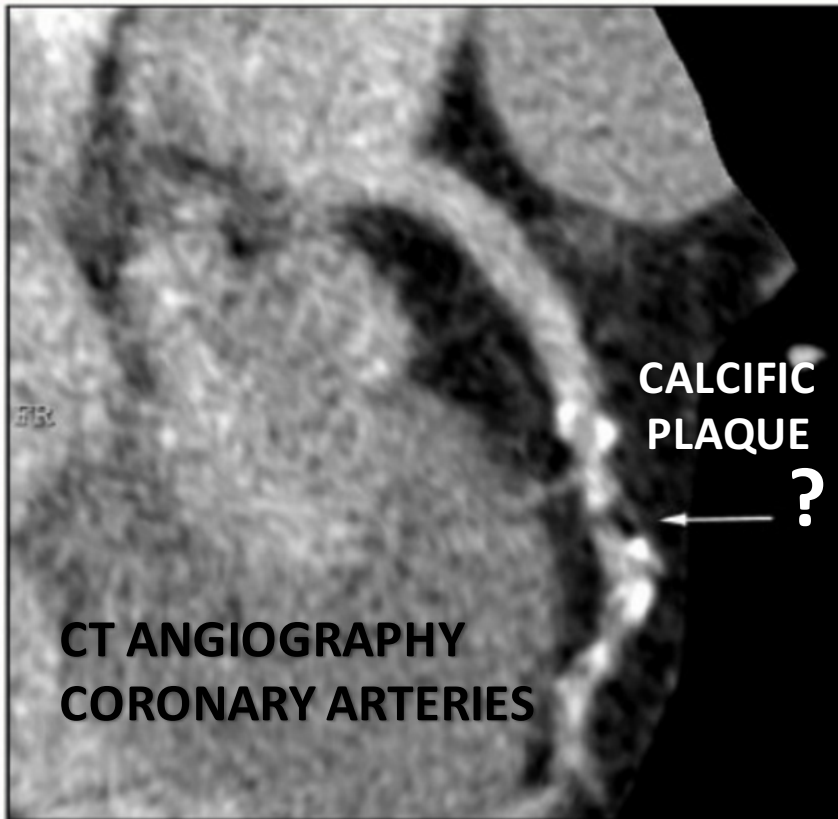
MASS OR INFILTRATION?

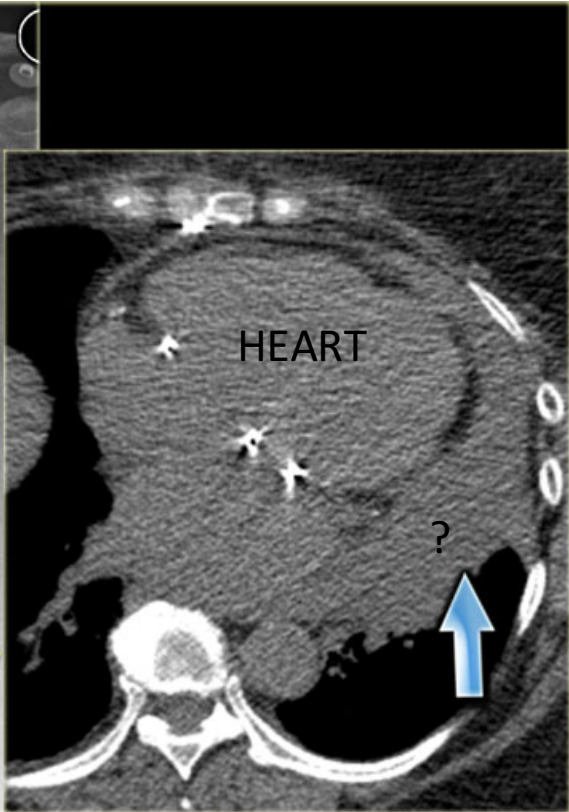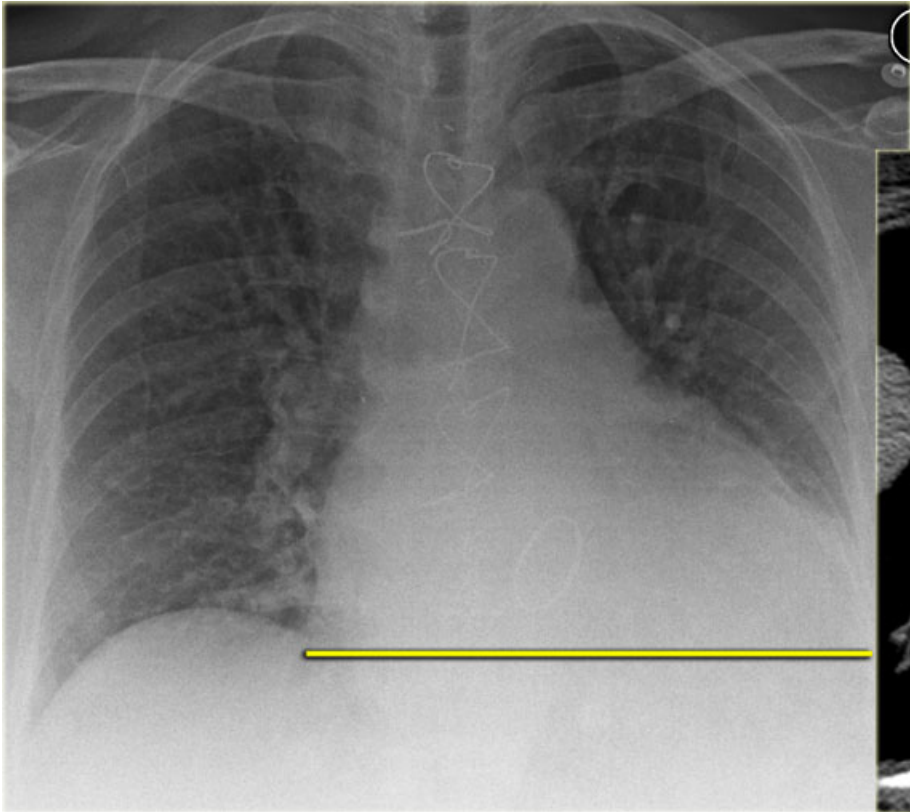


EXAM?

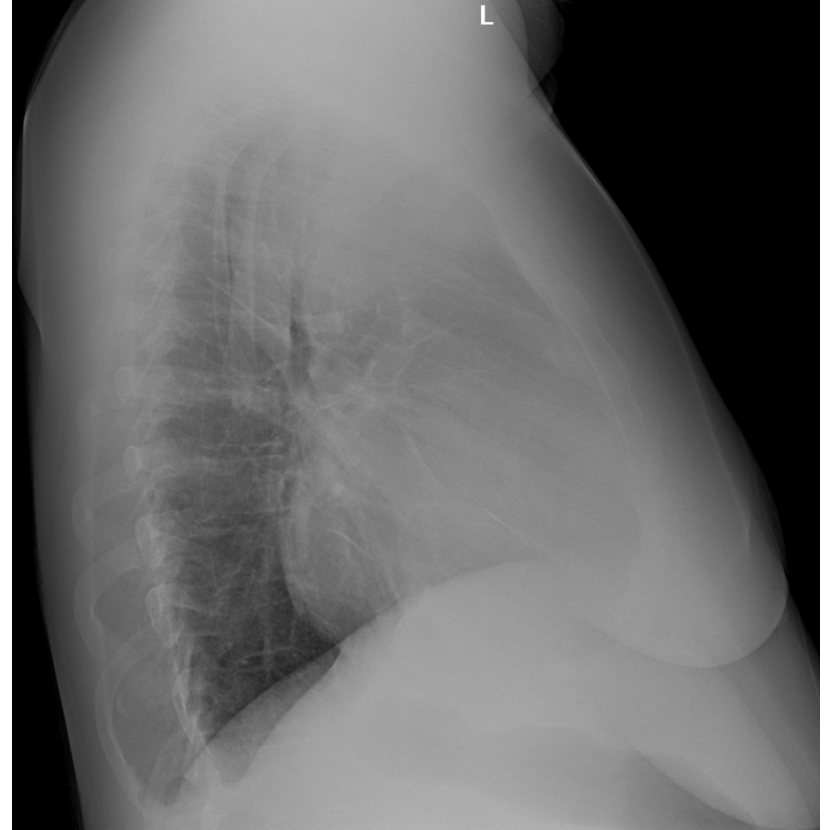
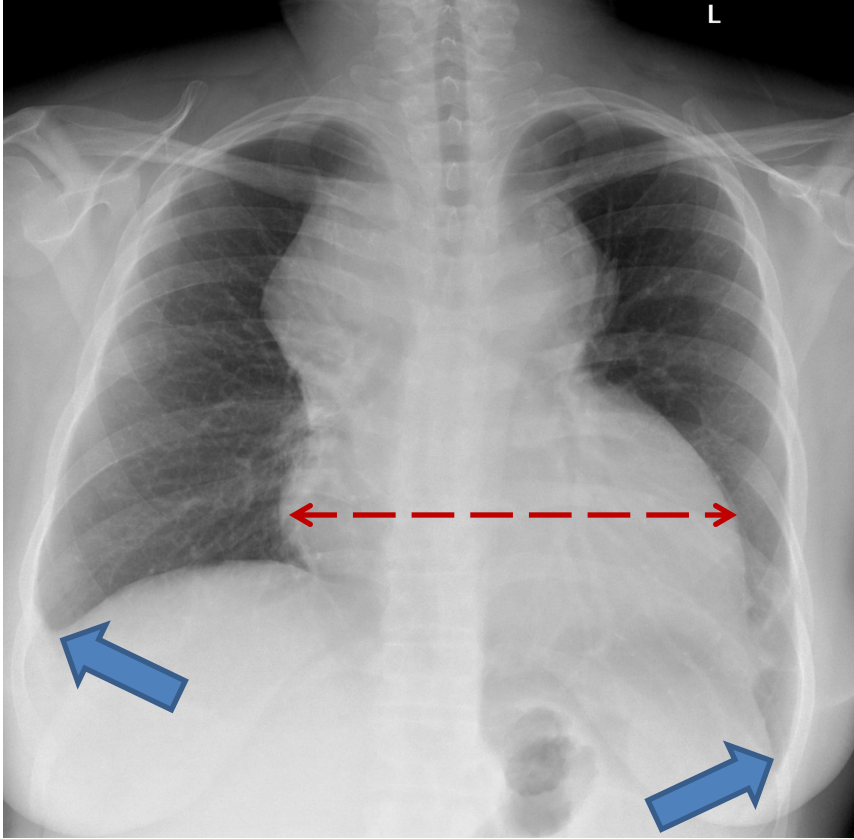


EXAM?

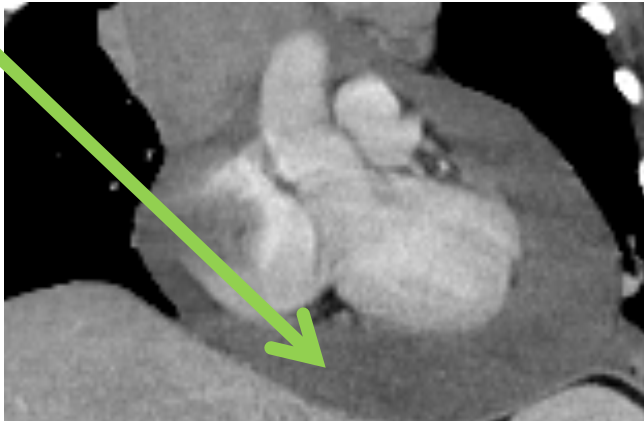
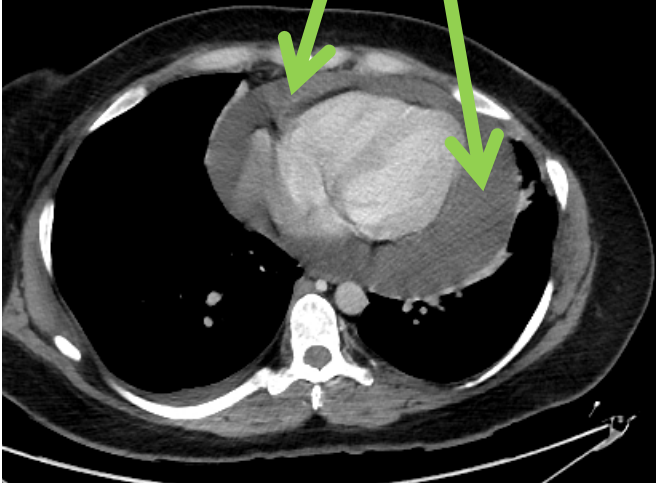
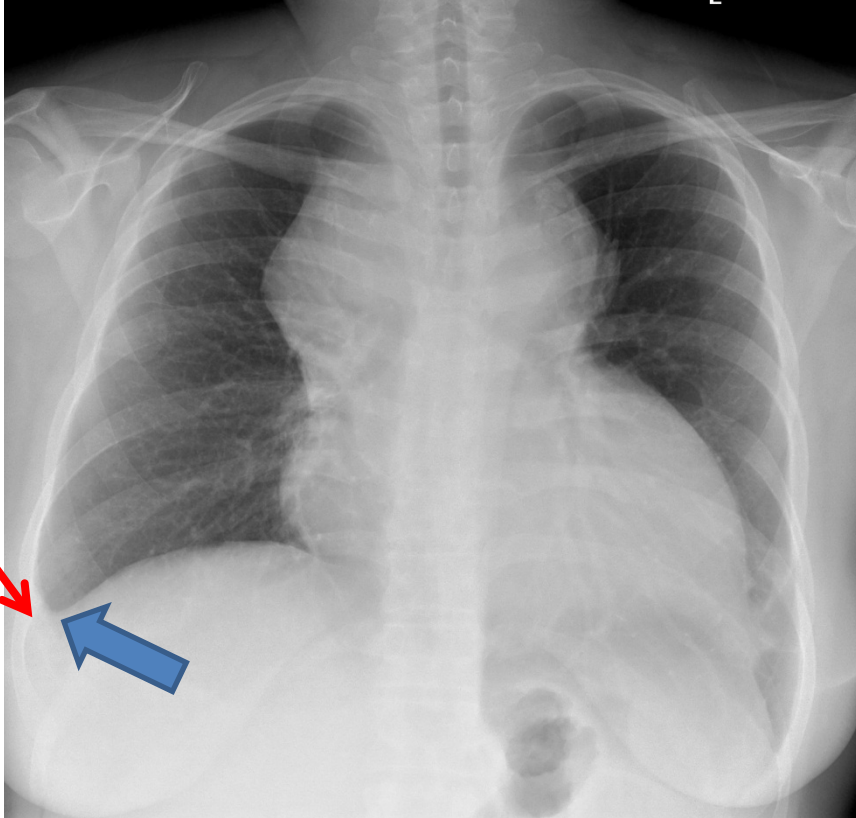




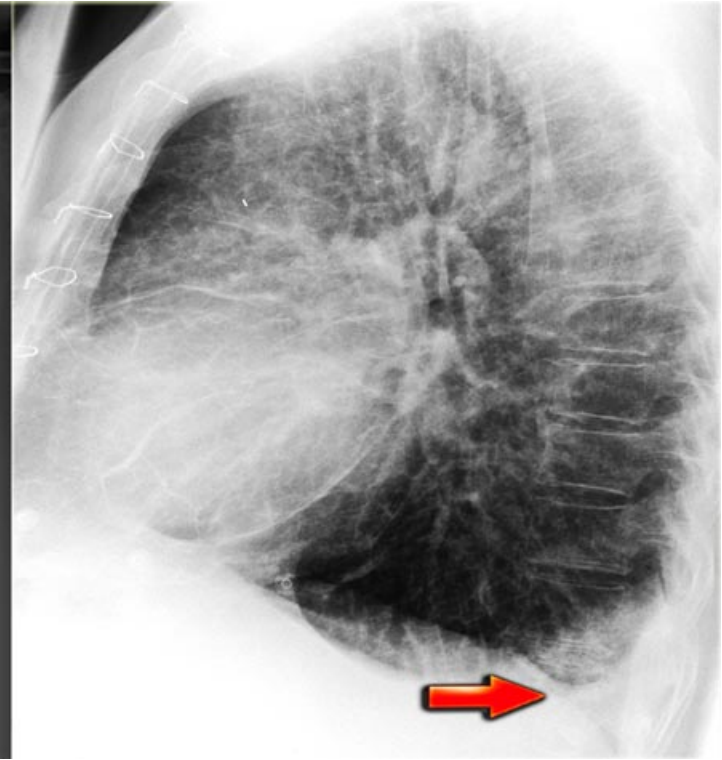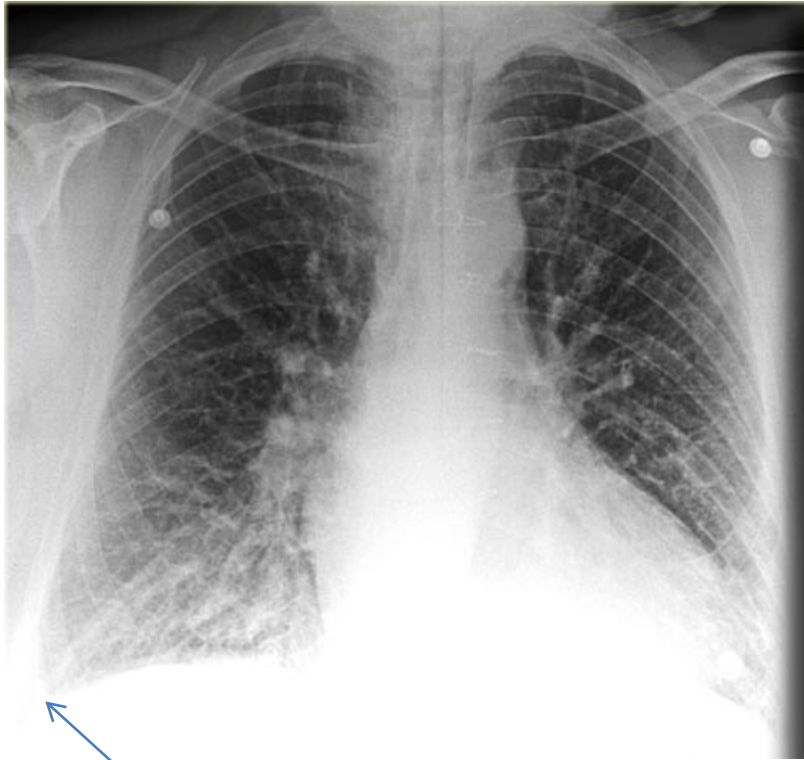
Heart ?



Pleural effusion and pericardial effusion

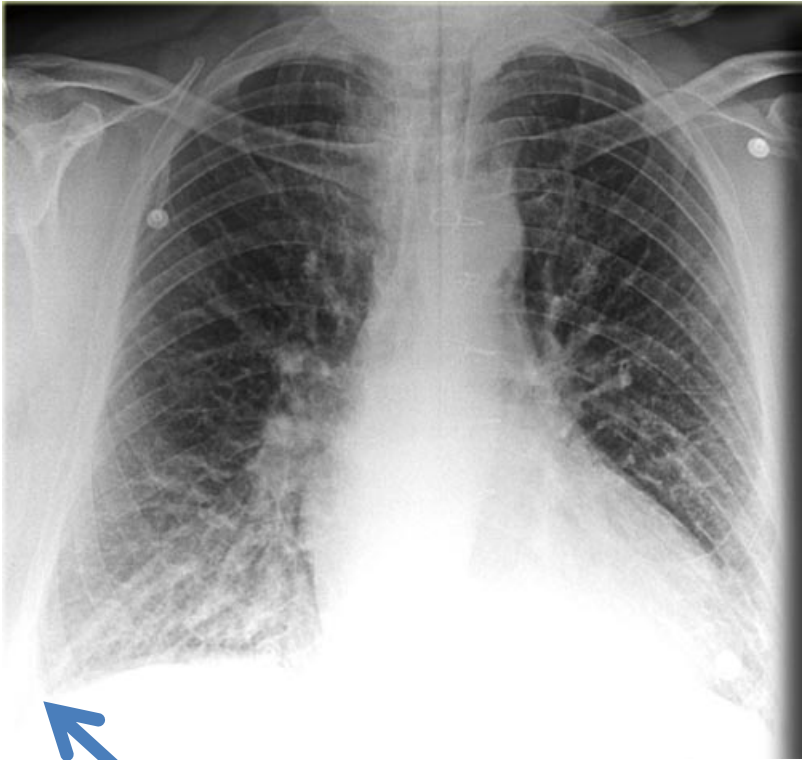


ABNORMAL? DIAGNOSIS?

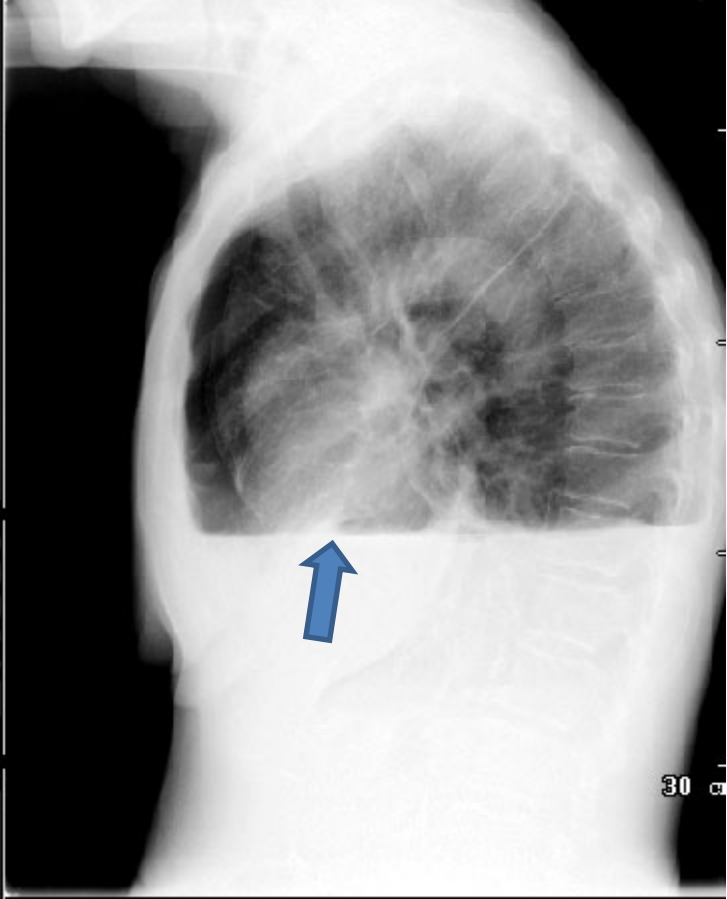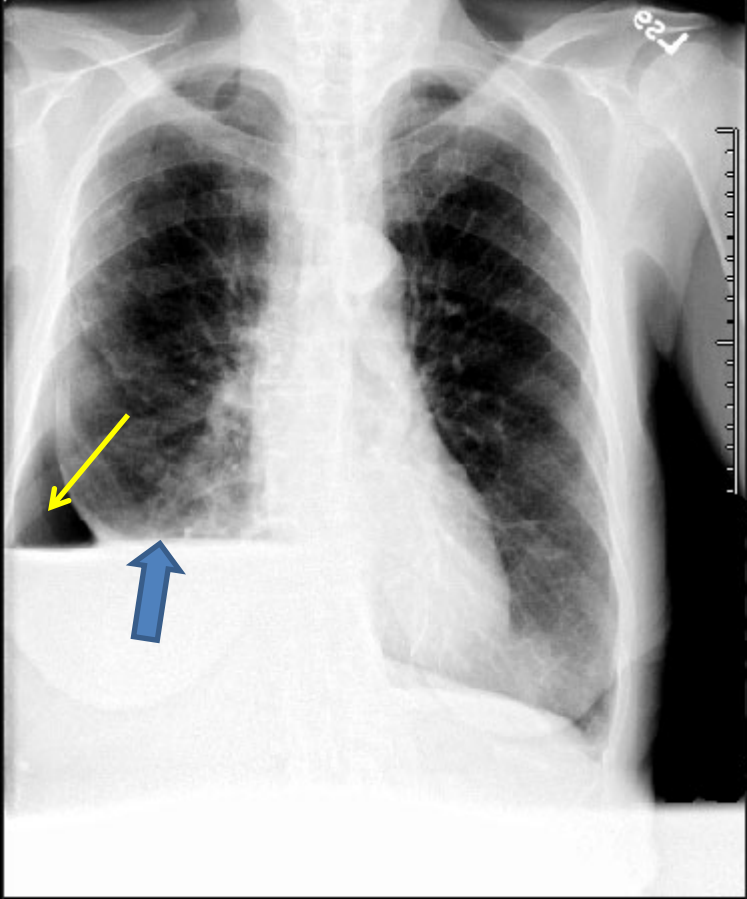


BLUNTED RIGHTCOSTOPHRENIC ANGLE

DIAGNOSIS: PLEURAL EFFUSION.



?????



HYDRO-PNEUMOTHORAX

