

Benign Esophageal Diseases

Dr.Sami Alnassar MD, FRCSC

Head, Division of Thoracic Surgery

Achalasia

- Achalasia is an uncommon disease of esophageal motility disorder
- It is characterized by degeneration of the myenteric neurons that innervate LES and esophageal body
- the pathogenesis :
 - autoimmune ?
 - Viral ?
 - Familial ?

Clinical features

- **most commonly presents in patients between the ages of 25 and 60 years**
- **an equal male-to-female gender distribution**
- **Dysphagia to solids and liquids is the most common presenting symptom, experienced by greater than 90% of patients**

Clinical features

- **Regurgitation is the second most common symptom, occurring in approximately 60% of patients**
- **Nocturnal regurgitation of esophageal contents can lead to nighttime cough and aspiration**
- **Weight loss occurs in end-stage disease**

Clinical features

- Chest pain is reported in 20% to 60% of patients
- Heartburn is reported in a large number of patients with achalasia (30% of achalasia patients)
- may be related to direct irritation of the esophageal lining by retained food, pills, or acidic byproducts of bacterial metabolism of retained food

Diagnosis

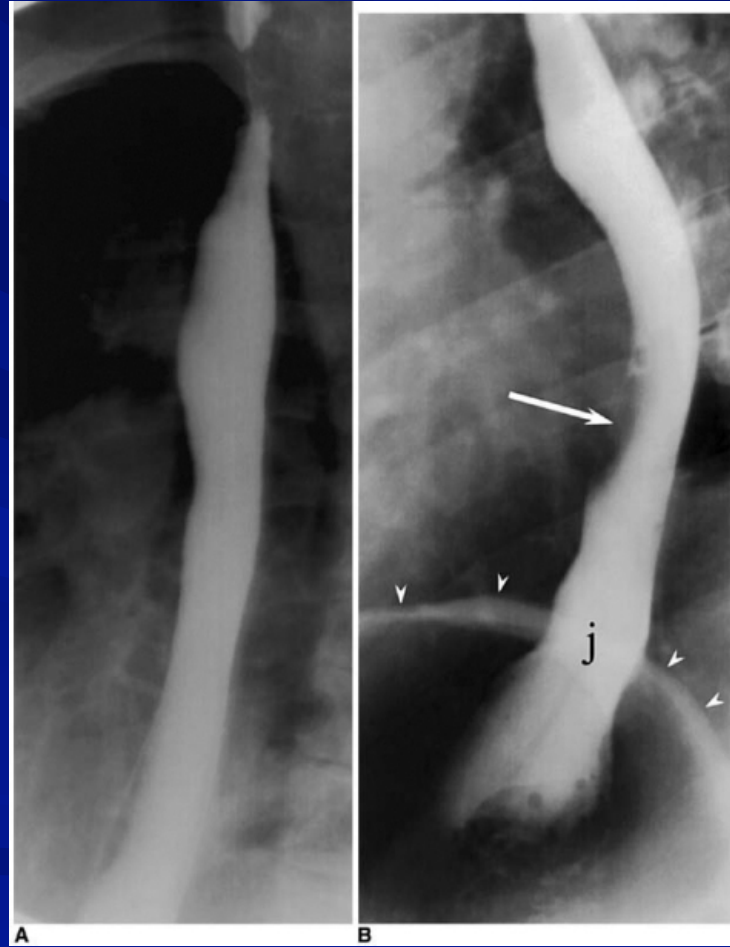
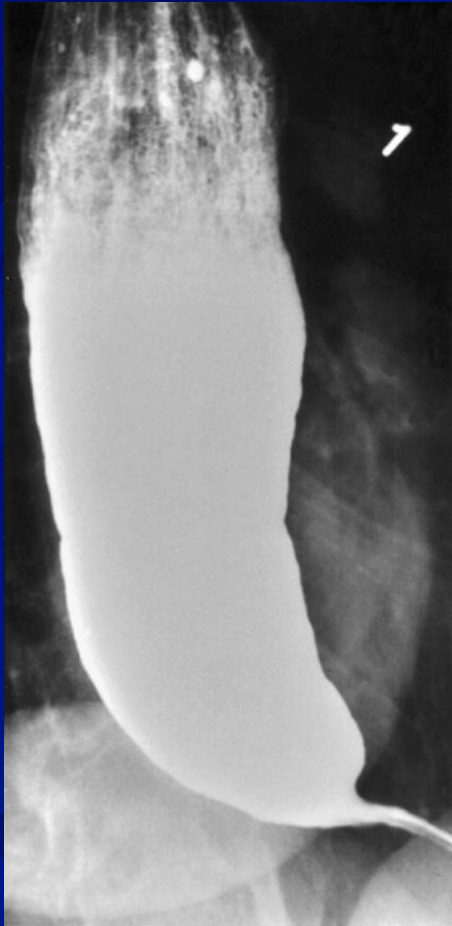
- **CXR may show air-fluid level**
- **Barium study quite dilated, and an air-fluid level may be secondary to retained secretions. The classic finding is a gradual tapering at the end of the esophagus, similar to a bird's beak**
- **Upper endoscopy is the next diagnostic test in a patient with dysphagia or suspected achalasia**

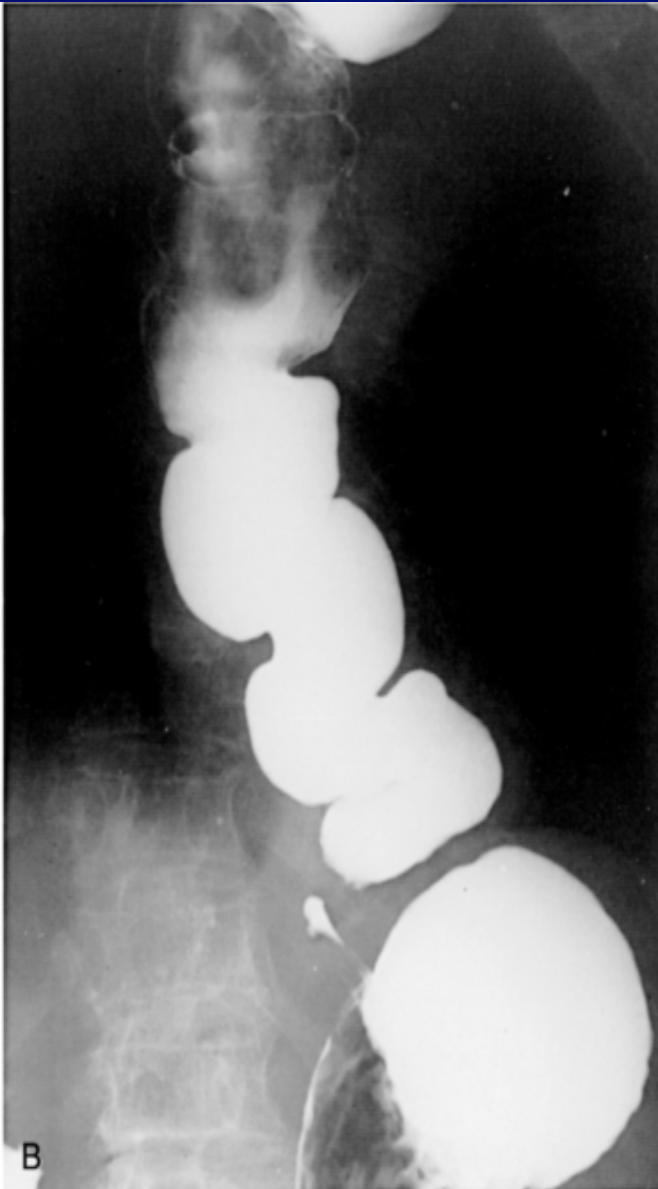
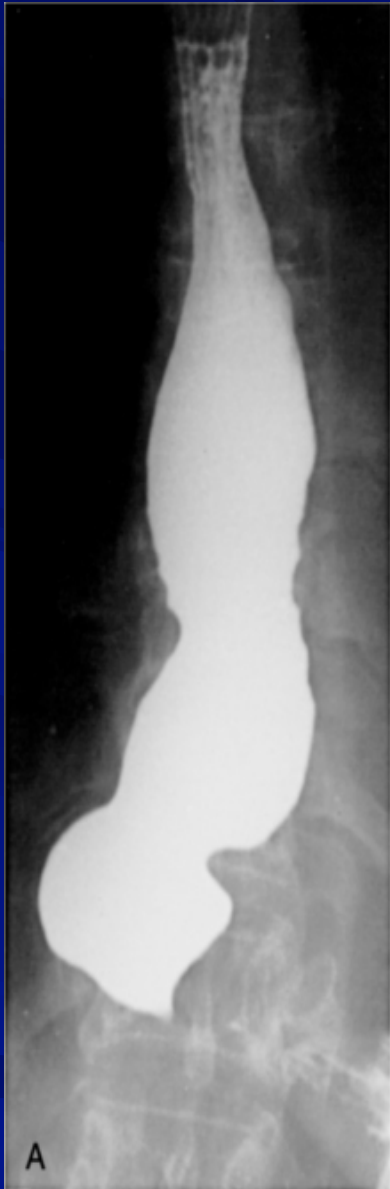Diagnosis

■ Findings can include :

- dilated esophagus with retained food or secretions
- normal in as many as 44% of patients with achalasia

■ Difficulty traversing the GEJ should raise suspicion for pseudoachalasia due to neoplastic infiltration of the distal esophagus





Diagnosis

■ **Esophageal manometry has the highest sensitivity for the diagnosis of achalasia :**

- aperistalsis of the distal esophageal body
- incomplete or absent LES relaxation
- hypertensive LES

■ **Manometric variants of achalasia exist**

- The best known is vigorous achalasia
- defined by the presence of normal to high amplitude esophageal body contractions in the presence of a nonrelaxing LES

Diagnosis

- **Manometric variants of achalasia exist**
 - vigorous achalasia may represent an early stage of achalasia
- **Chagas' disease is a parasitic infection caused by *Trypanosoma cruzi* which can cause secondary achalasia**
- **The most concerning secondary etiology is cancer, which can present as achalasia through mechanical obstruction of the GEJ**

Diagnosis

- **Additional secondary forms of achalasia exist**
 - **An increasingly recognized etiology is post fundoplication achalasia caused by mechanical obstruction of the GEJ by the fundoplication or diaphragmatic crural closure**
 - **Similar cases have been described following bariatric surgery using a gastric band device which constricts the proximal stomach a few centimeters below the LES**

Treatment

- **The primary therapeutic goal in achalasia is to reduce the LES basal pressure**
- **Treatment options include medical therapy, botulinum toxin injection, pneumatic dilation, and surgical myotomy**
- **Symptom relief, particularly relief of dysphagia, is accepted as the primary desired outcome**

Medical Therapy

- is inconvenient, only modestly effective, and frequently associated with side effects
- it is reserved for patients who are awaiting or unable to tolerate more invasive treatment modalities
- Pharmacologic therapies attempt to decrease the LES pressure by causing smooth muscle relaxation

Medical Therapy

- **Nitrates were first recognized as an effective treatment of achalasia**
 - their systemic vasodilatory effects and headaches limit their tolerability by patients
- **Calcium channel antagonists have a better side-effect profile when compared with nitrates**
 - 30% of patients report adverse side effects including peripheral edema, hypotension, and headache

Botulinum Toxin

- injected into the LES targets the excitatory, acetylcholine-releasing neurons that generate LES basal muscle tone
- is easy to administer and associated with relatively few side effects
- It is apparent that, with repeated injections, the response rates reported are similar or lower to that achieved with the initial injection

Botulinum Toxin

- **Response rates at 1 month following administration average 78% , By 6 months, the clinical response rate drops to 58% and by 12 months to 49%**
- **Given the limitations of the efficacy and durability of response, botulinum toxin is generally reserved for use in patients who are not candidates for more invasive treatments**

Pneumatic Dilation

- pneumatic dilation remains one of the most effective first-line therapies for achalasia
- Long-term follow-up studies reported significant symptom relapse of 50% at 10 years
- Complications of pneumatic dilation exist :
 - Gastroesophageal reflux 25-35%
 - Esophageal perforation 3 %

Surgical Therapy

- has success rates in excess of 90% with hospital stays averaging only a few days
- acid exposure is a known complication of surgical intervention for achalasia
- Even with a successful myotomy, it is expected that patients will have some degree of dysphagia as a consequence of esophageal peristaltic dysfunction

Surgical Therapy

- Delayed recurrence of postoperative dysphagia is most commonly caused by development of a recurrent high pressure zone at the LES or a peptic stricture complicating acid reflux
- laparoscopic Heller myotomy demonstrated excellent results, with 98% of patients reporting symptomatic improvement at 5.3 years

Surgery Versus Pneumatic Dilation

- Several retrospective and prospective studies have reported superior success rates for surgery when compared with pneumatic dilation
- a study of outcomes of 1181 patients treated with pneumatic dilation with that of 280 patients treated with Heller myotomy as initial therapy showed that the risk of subsequent therapeutic intervention at 10 years was significantly higher with dilation (64%) when compared with surgery (38%)

Refractory Achalasia

- In patients with achalasia that is refractory to therapy with Heller myotomy, options are limited
- Although esophagectomy is considered in patients with marked dilation and sigmoid deformity, such patients may respond to Heller myotomy

Complications

- The primary complications of achalasia are related to the functional obstruction rendered by the nonrelaxing LES and include progressive malnutrition and aspiration.
- Uncommon but important secondary complications of achalasia include the formation of epiphrenic diverticula and esophageal cancer.

Complications

- There is an established link between achalasia and esophageal cancer, most commonly squamous cell carcinoma
- The overall prevalence of esophageal cancer in achalasia is approximately 3% with an incidence of approximately 197 cases per 100,000 persons per year

Esophageal Diverticula

- most diverticula are a result of a primary motor disturbance or an abnormality of the UES or LES
- can occur in several places along the esophagus
- The three most common sites of occurrence are pharyngoesophageal (Zenker's), parabronchial (midesophageal), and epiphrenic

Esophageal Diverticula

- True diverticula involve all layers of the esophageal wall, including mucosa, submucosa, and muscularis
- A false diverticulum consists of mucosa and submucosa only
- Pulsion diverticula are false diverticula that occur because of elevated intraluminal pressures generated from abnormal motility disorders

Esophageal Diverticula

- **Zenker's diverticulum and an epiphrenic diverticulum fall under the category of false, pulsion diverticula.**
- **Traction, or true, diverticula result from external inflammatory mediastinal lymph nodes adhering to the esophagus**

Pharyngoesophageal (Zenker's) Diverticulum

- **is the most common esophageal diverticulum found today**
- **It usually presents in older patients in the 7th decade of life**
- **found herniating into Killian's triangle, between the oblique fibers of the thyropharyngeus muscle and the horizontal fibers of the cricopharyngeus muscle**

Symptoms and Diagnosis

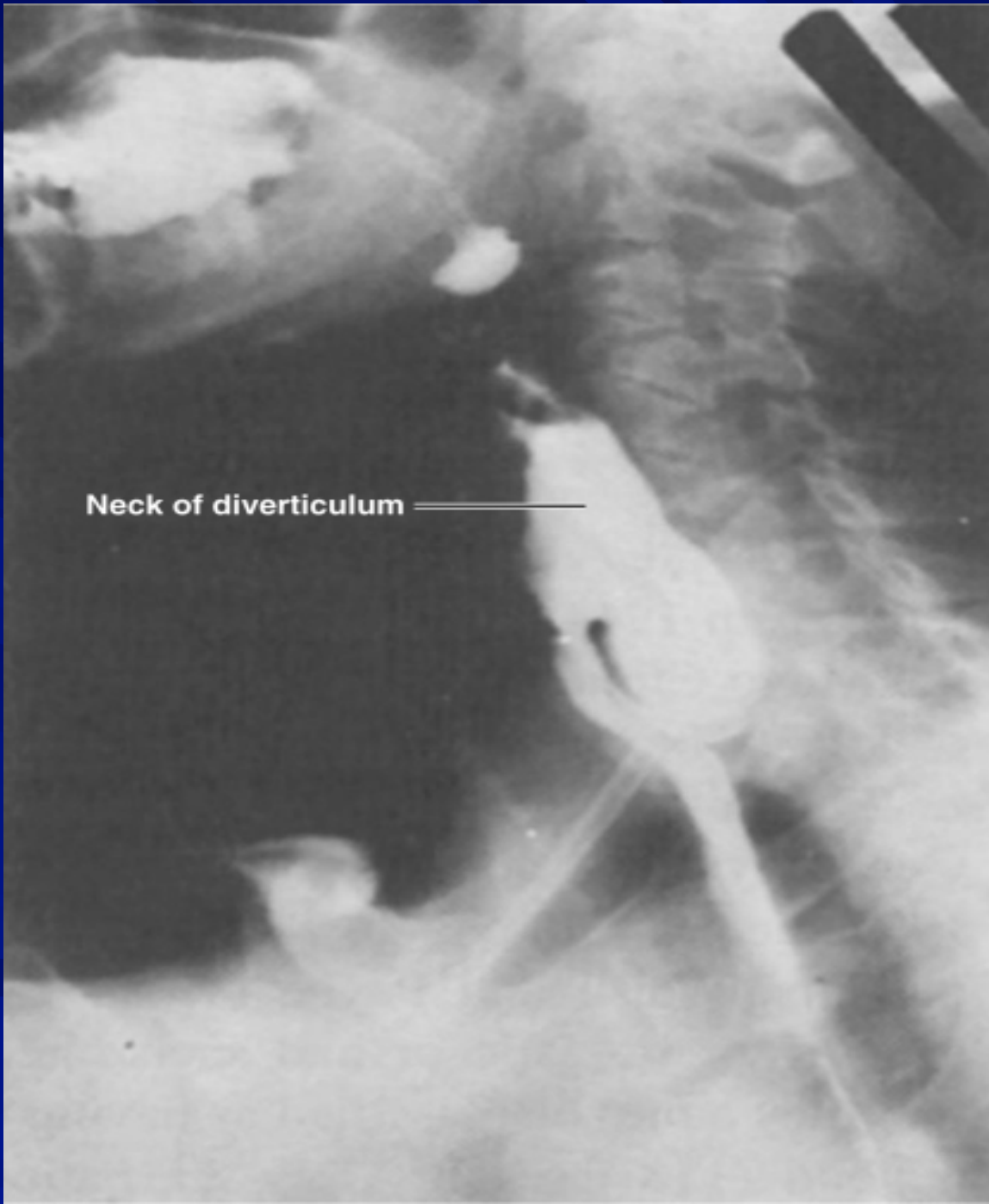- **Commonly, patients complain of a sticking in the throat.**
- **nagging cough, excessive salivation, and intermittent dysphagia often are signs of progressive disease**
- **As the sac increases in size, regurgitation of foul-smelling, undigested material is common**

Symptoms and Diagnosis

- Halitosis, voice changes, retrosternal pain, and respiratory infections are especially common in the elderly population
- The most serious complication from an untreated Zenker's diverticulum is aspiration pneumonia or lung abscess

Symptoms and Diagnosis

- **Diagnosis is made by barium esophagram**
- **Neither esophageal manometry nor endoscopy is needed to make a diagnosis of Zenker's diverticulum.**



Neck of diverticulum

Treatment

- **Surgical or endoscopic repair of a Zenker's diverticulum is the gold standard of treatment**
- **Open repair involve :**
 - **myotomy of the proximal and distal thyropharyngeus and cricopharyngeus muscles**
 - **diverticulectomy or diverticulopexy are performed through an incision in the left neck**

Treatment

- An alternative to open surgical repair is the endoscopic Dohlman procedure
- Endoscopic division of the common wall between the esophagus and the diverticulum using a laser or stapler has also been successful

Diffuse Esophageal Spasm

- DES is a hypermotility disorder of the esophagus
- is seen most often in women and is often found in patients with multiple complaints
- The basic pathology is related to a motor abnormality of the esophageal body that is most notable in the lower two thirds of the esophagus

Diffuse Esophageal Spasm

- the esophageal contractions are repetitive, simultaneous, and of high amplitude

Symptoms and Diagnosis

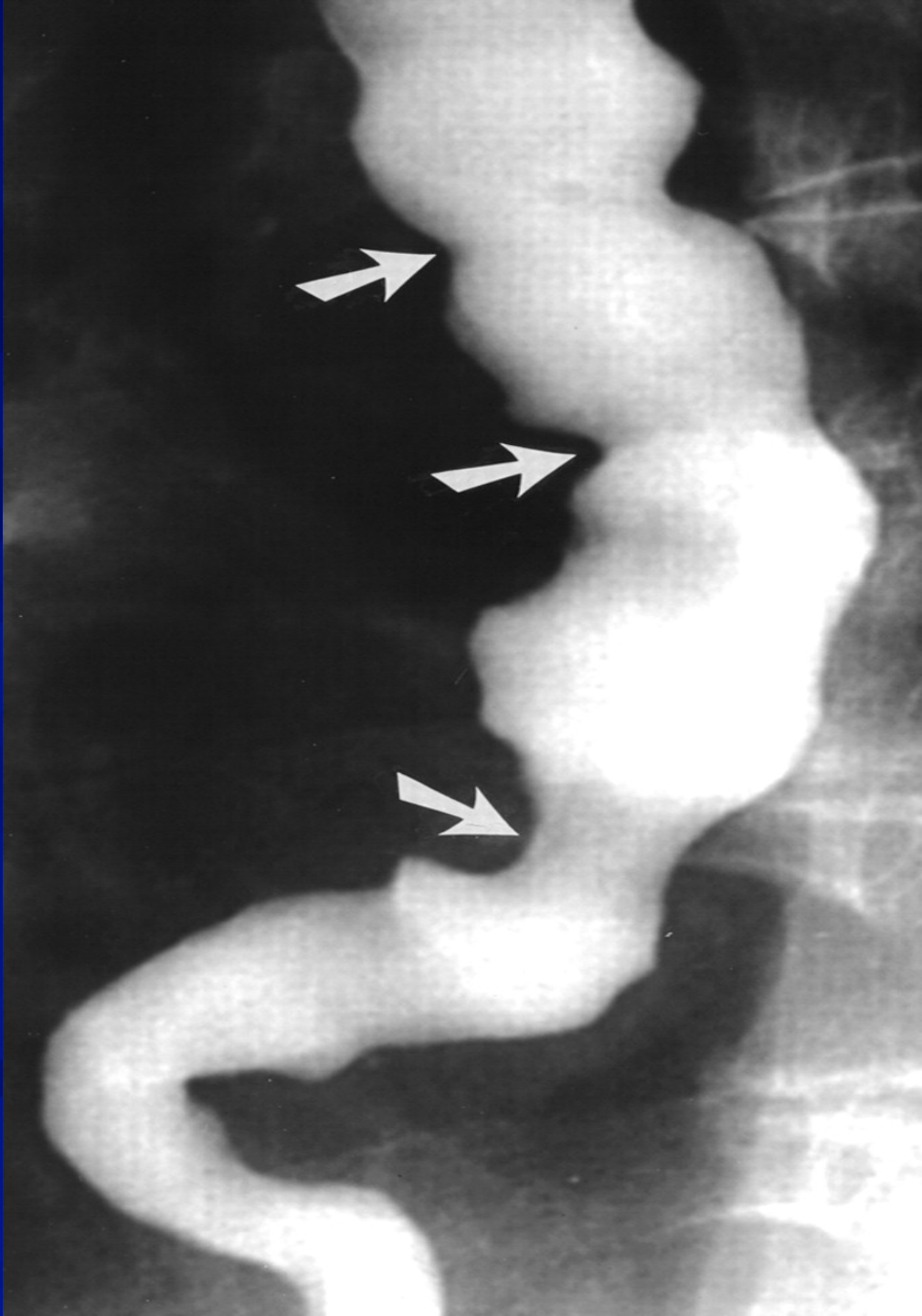
- **The clinical presentation of DES is typically that of chest pain and dysphagia**
- **These symptoms may be related to eating or exertion and may mimic angina**
- **Patients will complain of a squeezing pressure in the chest that may radiate to the jaw, arms, and upper back**

Symptoms and Diagnosis

- **The symptoms are often pronounced during times of heightened emotional stress**
- **Regurgitation of esophageal contents and saliva is common, but acid reflux is not**
- **acid reflux can aggravate the symptoms, as can cold liquids**

Symptoms and Diagnosis

- **irritable bowel syndrome and pyloric spasm, may accompany DES, whereas other gastrointestinal problems, such as gallstones, peptic ulcer disease, and pancreatitis, all trigger DES**
- **The diagnosis of DES is made by an esophagram and manometric studies**



Treatment

- **the mainstay of treatment for DES is nonsurgical, and pharmacologic or endoscopic intervention is preferred**
- **Surgery is reserved for patients with recurrent incapacitating episodes of dysphagia and chest pain who do not respond to medical treatment**

Barrett's Esophagus

- **Barrett's esophagus is a condition whereby an intestinal, columnar epithelium replaces the stratified squamous epithelium that normally lines the distal esophagus**
- **Chronic gastroesophageal reflux is the factor that both injures the squamous epithelium and promotes repair through columnar metaplasia**

Barrett's Esophagus

- Although these metaplastic cells may be more resistant to injury from reflux, they also are more prone to malignancy
- Ten percent of patients with GERD develop Barrett's esophagus
- the 40-fold increase in risk for developing esophageal carcinoma in patients with Barrett's esophagus

Barrett's Esophagus

- With continued exposure to the reflux disease, metaplastic cells undergo cellular transformation to low- and high-grade dysplasia
- these dysplastic cells may evolve to cancer

Barrett's Esophagus

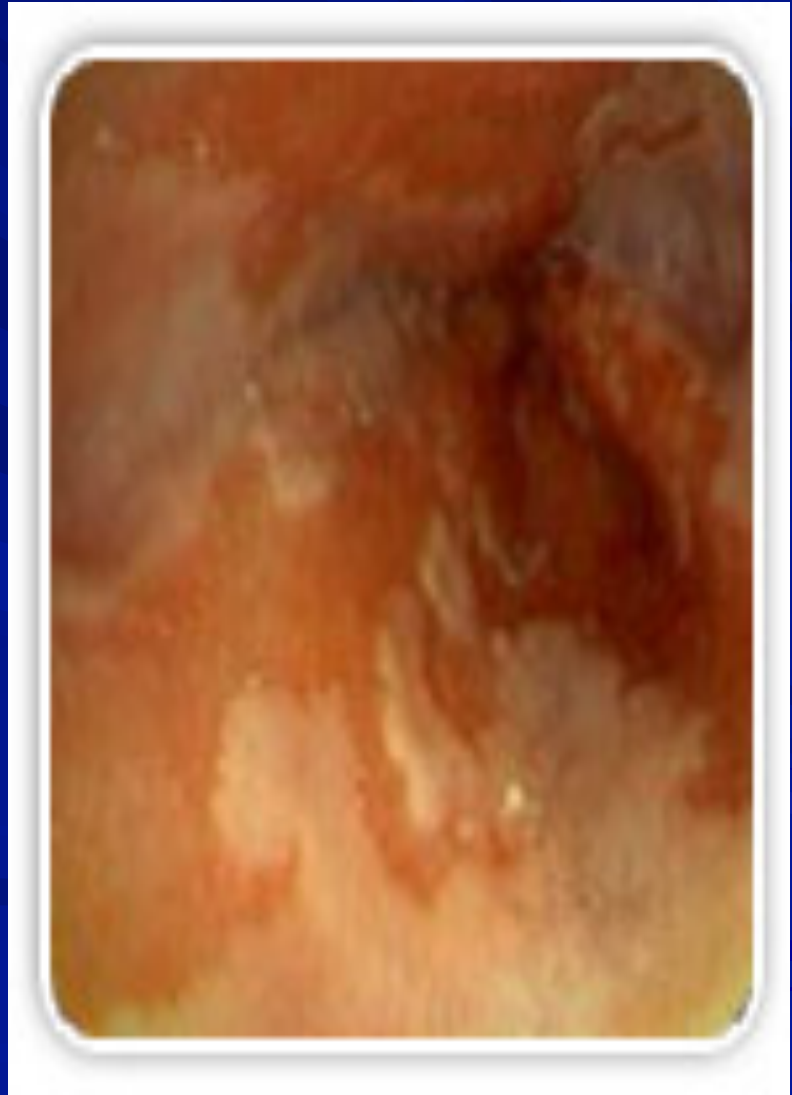
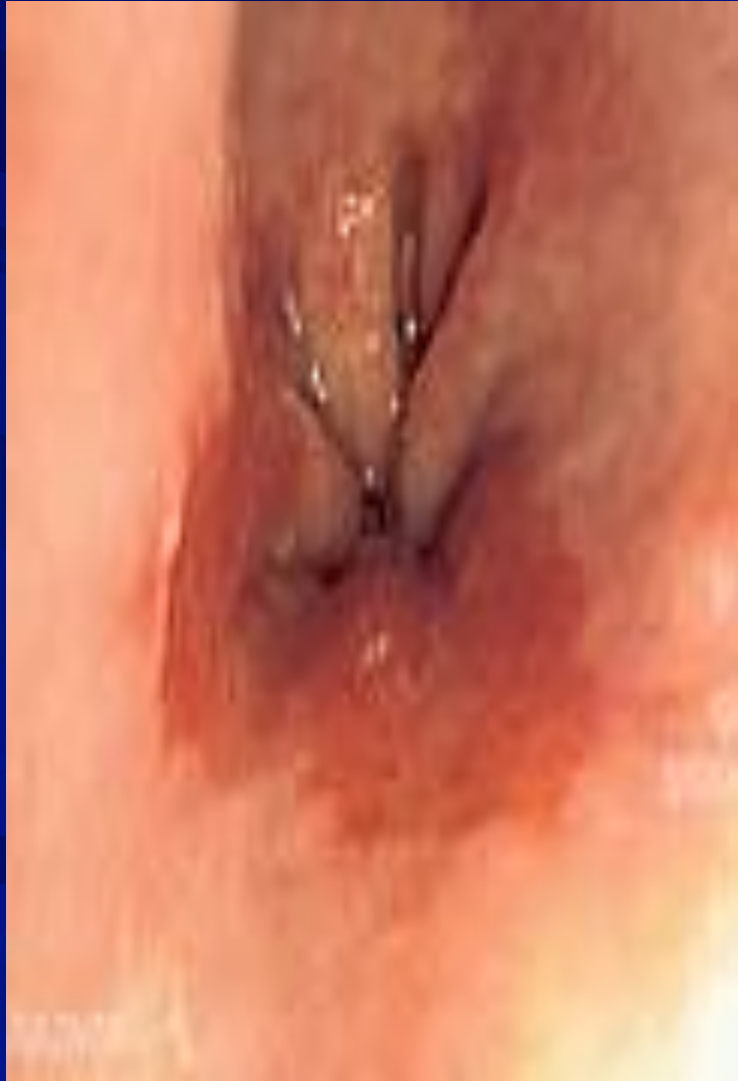- **70% of patients are men aged 55 to 63 years**
- **Men have a 15-fold increased incidence over women of adenocarcinoma of the esophagus, but women with Barrett's esophagus are increasing in number as the differences in the Western lifestyle between men and women diminish**

Symptoms and Diagnosis

- **Many patients harboring intestinal metaplasia in their distal esophagus are asymptomatic**
- **Most patients present with symptoms of GERD. Heartburn, regurgitation, acid or bitter taste in the mouth, excessive belching, and indigestion are some of the common symptoms associated with GERD**

Symptoms and Diagnosis

- **Recurrent respiratory infections, adult asthma, and infections in the head and neck also are common complaints.**
- **The diagnosis of BE is made by endoscopy and pathology**
- **The presence of any endoscopically visible segment of columnar mucosa within the esophagus that on pathology identifies intestinal metaplasia defines BE**



Treatment

- **Yearly surveillance endoscopy is recommended in all patients with a diagnosis of Barrett's esophagus**
- **For patients with low-grade dysplasia, surveillance endoscopy is performed at 6-month intervals for the first year and then yearly thereafter if there has been no change**

Treatment

- **Patients undergoing surveillance are placed on acid suppression medication and monitored for changes in their reflux symptoms.**
- **Controversy surrounds the benefits of antireflux surgery in patients with Barrett's esophagus**

Treatment

- **Those in favour of surgery argue that medical therapy and endoscopic surveillance may treat the symptoms but fail to address the problem**
- **The problem is the functional impairment of the LES that leads to chronic reflux and metaplastic transformation of the lower esophageal mucosa**

Treatment

- **Surgery renders the LES competent and restores the barrier to reflux**
- **Studies have demonstrated regression of metaplasia to normal mucosa up to 57% of the time in patients who have undergone antireflux surgery**

Treatment

- **Photodynamic therapy (PDT) is the most common ablative method used to treat BE**
- **Endoscopic mucosal resection (EMR) is gaining favor for the treatment of Barrett's esophagus with low-grade dysplasia.**

Treatment

- **Esophageal resection for Barrett's esophagus is recommended only for patients in whom high-grade dysplasia is found**
- **Pathologic data on surgical specimens demonstrate a 40% risk for adenocarcinoma within a focus of high-grade dysplasia**

Caustic Injury

- **the best cure for this condition is an ounce of prevention**
- **In children, ingestion of caustic materials is accidental and tends to be in small quantities**
- **In teenagers and adults, however, ingestion usually is deliberate during suicide attempts, and much larger quantities of caustic liquids are consumed**

Caustic Injury

- **Alkali ingestion is more common than acid ingestion because of its lack of immediate symptoms**
- **alkali ingestion are much more devastating and almost always lead to significant de-struction of the esophagus**

Caustic Injury

Table 41-3 -- Three Phases of Tissue Injury From Alkali Ingestion

PHASE	TISSUE INJURY	ONSET	DURATION	INFLAMMATORY RESPONSE
1	Acute necrosis	1-4 days	1-4 days	Coagulation of intracellular proteins Inflammation
2	Ulceration and granulation	3-5 days	3-12 days	Tissue sloughing Granulation of ulcerated tissue bed
3	Cicatrization and scarring	3 weeks	1-6 months	Adhesion formation Scarring

Symptoms and Diagnosis

- **During phase one, patients may complain of oral and substernal pain, hypersalivation, odynophagia and dysphagia, hematemesis, and vomiting**
- **During stage two, these symptoms may disappear only to see dysphagia reappear as fibrosis and scarring begin to narrow the esophagus throughout stage three**

Symptoms and Diagnosis

- **Symptoms of respiratory distress, such as hoarseness, stridor, and dyspnea, suggest upper airway edema and are usually worse with acid ingestion**
- **Pain in the back and chest may indicate a perforation of the mediastinal esophagus, whereas abdominal pain may indicate abdominal visceral perforation**

Symptoms and Diagnosis

- **Diagnosis is initiated with a physical exam specifically evaluating the mouth, airway, chest, and abdomen**
- **Careful inspection of the lips, palate, pharynx, and larynx is done**
- **The abdomen is examined for signs of perforation**

Symptoms and Diagnosis

- **Early endoscopy is recommended 12 to 24 hours after ingestion to identify the grade of the burn**
- **Serial chest and abdominal radiographs are indicated to follow patients with questionable chest and abdominal exams**

Table 41.4 -- Endoscopic Grading and Treatment of Corrosive Esophageal and Gastric Injuries

DEGREE OF BURN	ENDOSCOPIC EVALUATION	TREATMENT
First degree	Mucosal hyperemia	48-hr observation
	Edema	Acid suppression
Second degree	Limited hemorrhage	Aggressive IV resuscitation
	Exudates	IV antibiotics
	Ulceration	Acid suppression
	Pseudomembrane formation	
Third degree	Mucosal sloughing	Inhaled steroids
	Deep ulcerations	Fiberoptic intubation (if needed)
	Massive hemorrhage	
	Complete luminal obstruction	
	Charring	
	Perforation	

Treatment

- **Management of the acute phase is aimed at limiting and identifying the extent of the injury**
- **It begins with neutralization of the ingested substance**
- **Alkalis (including lye) are neutralized with half-strength vinegar or citrus juice**

Treatment

- **Acids are neutralized with milk, egg whites, or antacids**
- **Emetics and sodium bicarbonate need to be avoided because they can increase the chance of perforation**

Treatment

■ First-Degree Burn :

- 48 hours of observation is indicated
- Oral nutrition can be resumed when a patient can painlessly swallow saliva
- A repeat endoscopy and barium esophagram are done in follow-up at intervals of 1, 2, and 8 months

Treatment

- **Second- and Third-Degree Burns :**
 - **Resuscitation is aggressively pursued**
 - **The patient is monitored in the intensive care unit**
 - **kept (NPO) with IV fluids. IV antibiotics and a proton pump inhibitor are started**
 - **Fiberoptic intubation may be needed and must be available**

Esophageal Perforation

- Perforation of the esophagus is a surgical emergency
- Early detection and surgical repair within the first 24 hours results in 80% to 90% survival
- after 24 hours, survival decreases to less than 50%

Esophageal Perforation

- Perforation from forceful vomiting (Boerhaave's syndrome), foreign body ingestion, or trauma accounts for 15%, 14%, and 10% of cases, respectively
- Most esophageal perforations occur after endoscopic instrumentation for a diagnostic or therapeutic procedure,

Symptoms and Diagnosis

- Symptoms of neck, substernal, or epigastric pain are consistently associated with esophageal perforation
- Vomiting, hematemesis, or dysphagia also may accompany them
- history of trauma, advanced esophageal cancer, violent wretching as seen in Boerhaave's syndrome, swallowing of a foreign body, or recent instrumentation must raise the question of esophageal perforation

Symptoms and Diagnosis

- **Cervical perforations may present with neck ache and stiffness due to contamination of the prevertebral space**
- **Thoracic perforations present with shortness of breath and retrosternal chest pain lateralizing to the side of perforation**

Symptoms and Diagnosis

- **Abdominal perforations present with epigastric pain that radiates to the back if the perforation is posterior**
- **On examination , patient may present with tachypnea, tachycardia, and a low-grade fever but have no other overt signs of perforation**

Symptoms and Diagnosis

- With increased mediastinal and pleural contamination, patients progress toward hemodynamic instability
- On exam, subcutaneous air in the neck or chest, shallow decreased breath sounds, or a tender abdomen are all suggestive of perforation
- Laboratory values of significance are an elevated white blood cell count and an elevated salivary amylase in the blood or pleural fluid.

Symptoms and Diagnosis

- **Diagnosis of an esophageal perforation may be made radiographically**
- **A chest roentgenogram may demonstrate a hydropneumothorax**
- **A contrast esophagram is done using barium for a suspected thoracic perforation and Gastrografin for an abdominal perforation.**

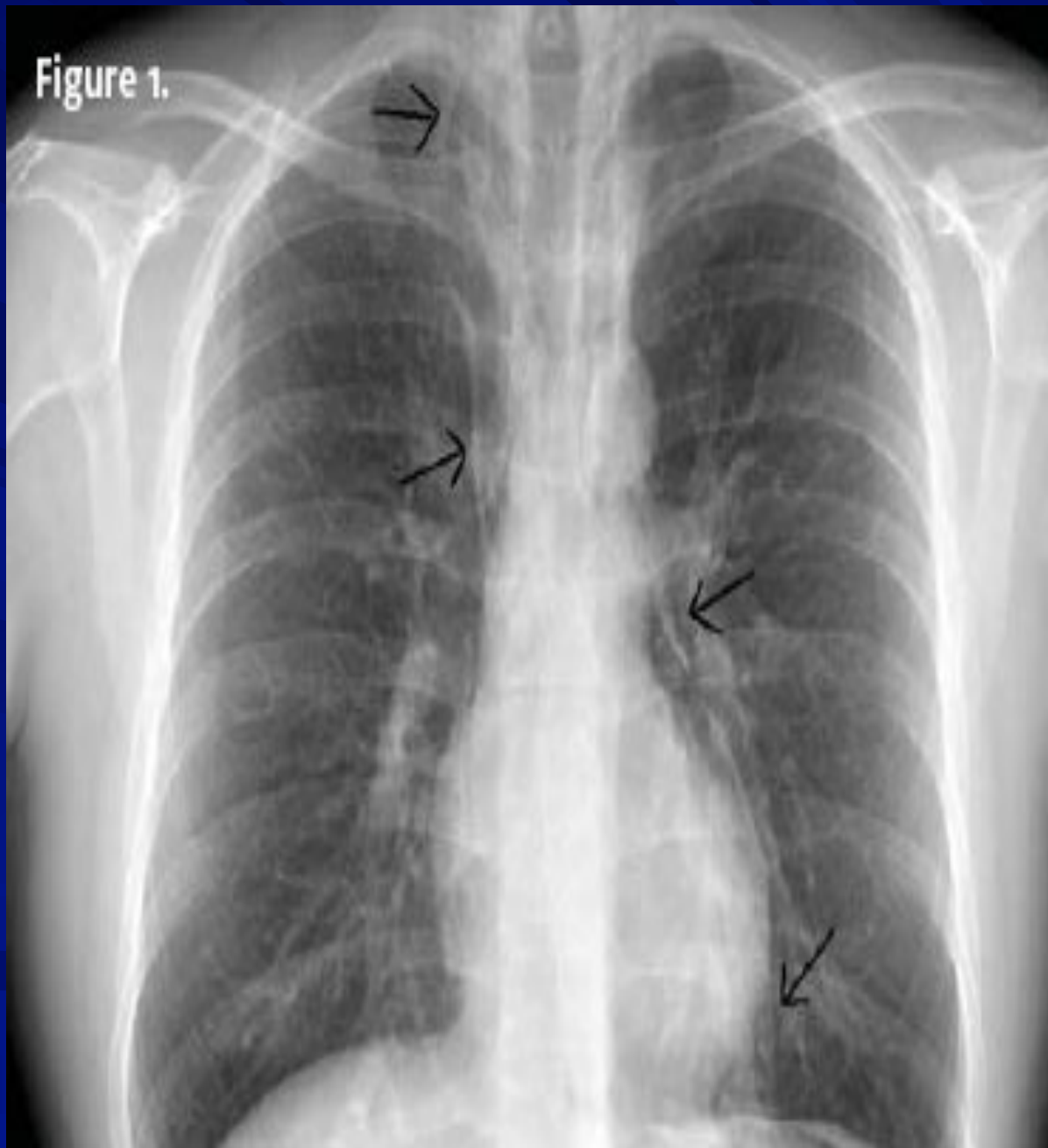Symptoms and Diagnosis

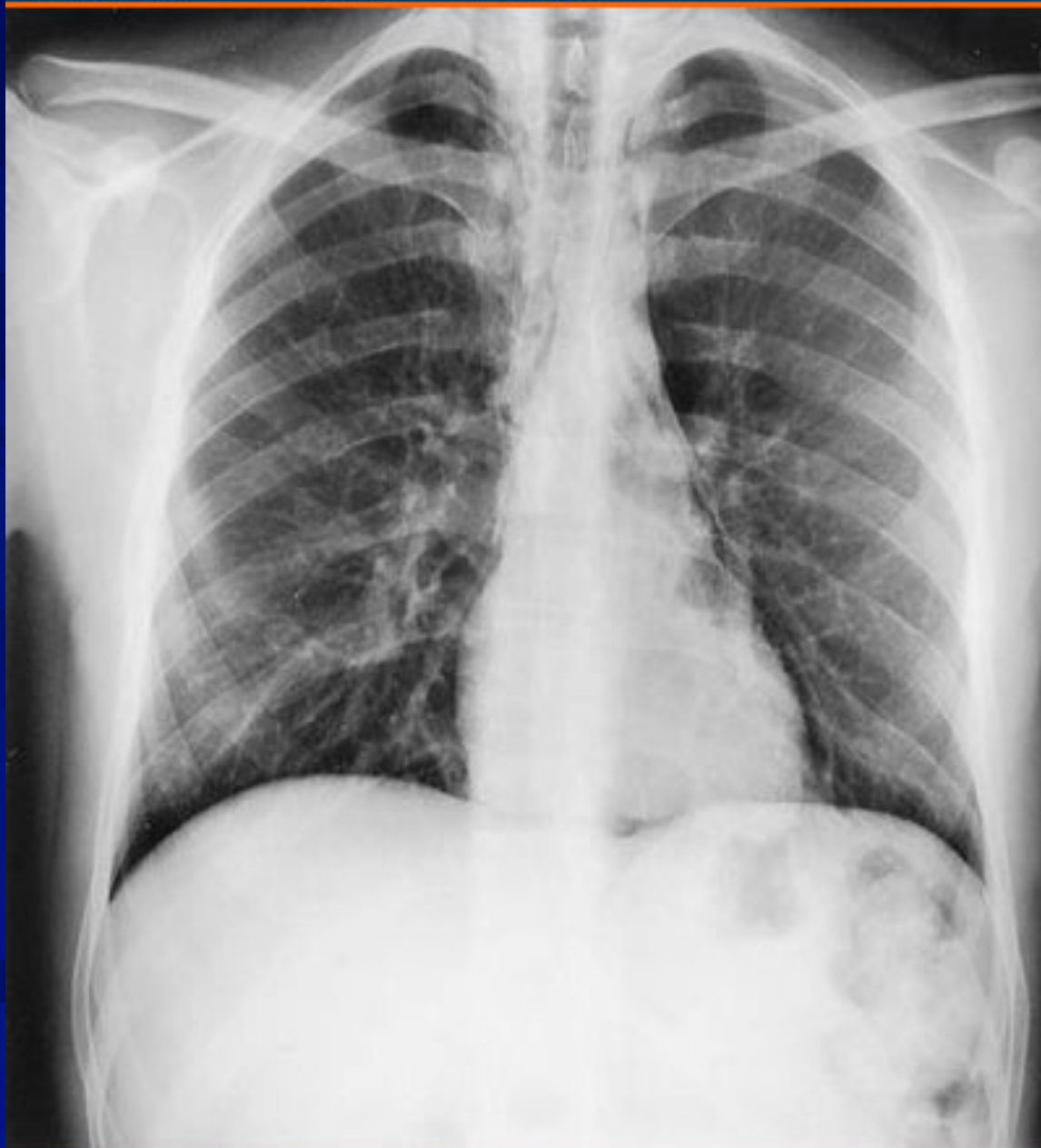- **Most perforations are found above the GEJ on the left lateral wall of the esophagus which results in a 10% false-negative rate in the contrast esophagram if the patient is not placed in the lateral decubitus position**
- **Chest CT shows mediastinal air and fluid at the site of perforation**

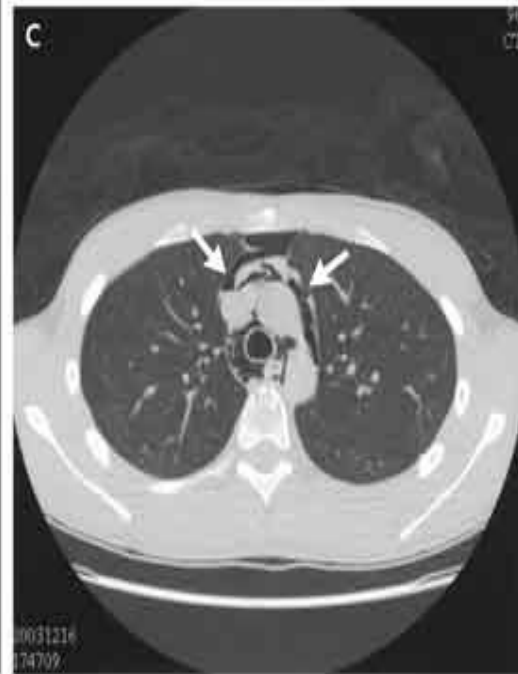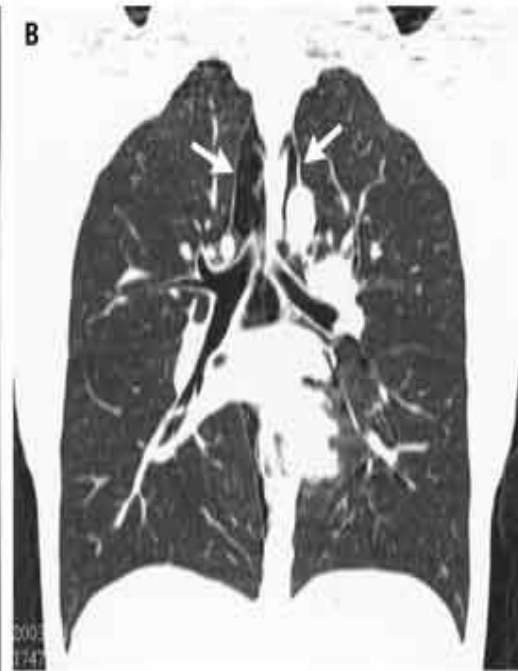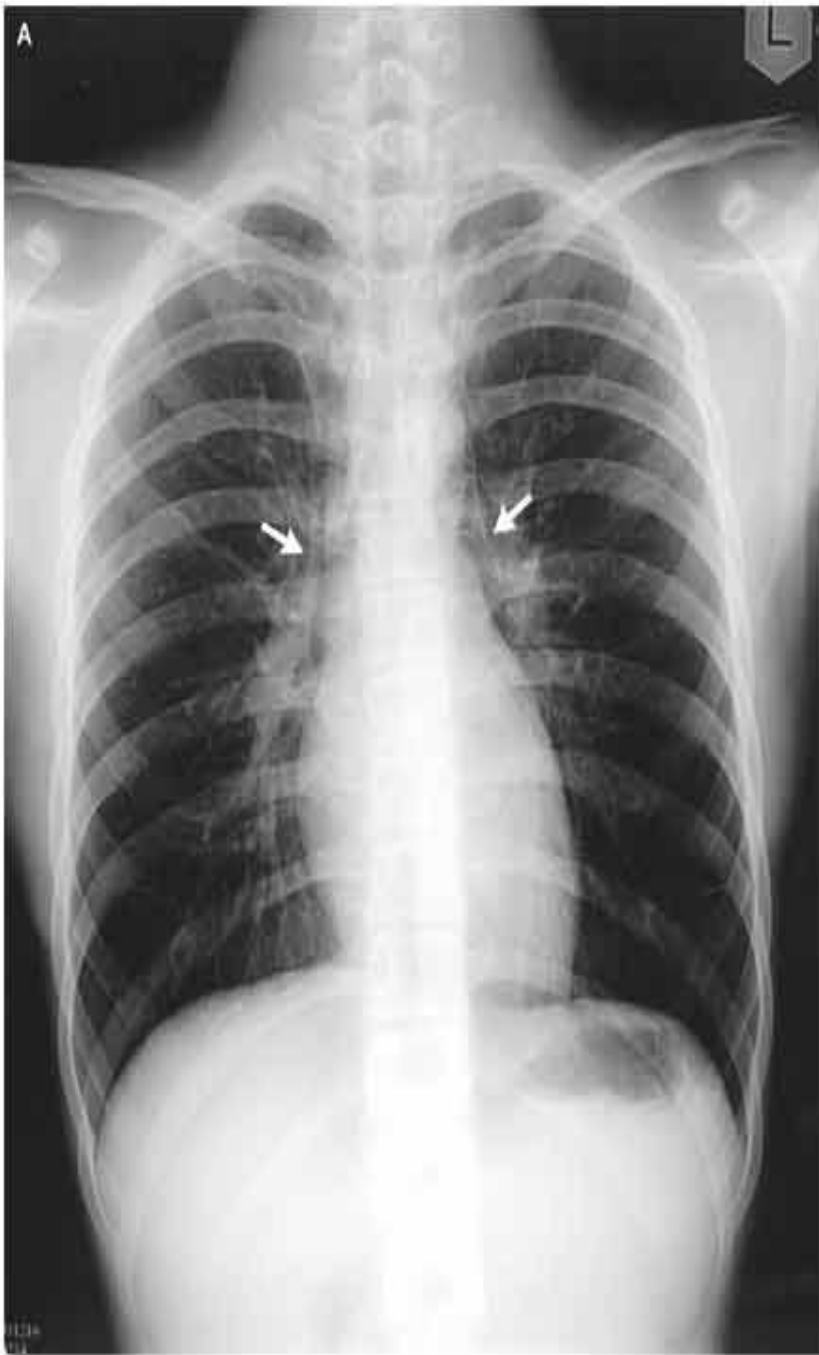
Symptoms and Diagnosis

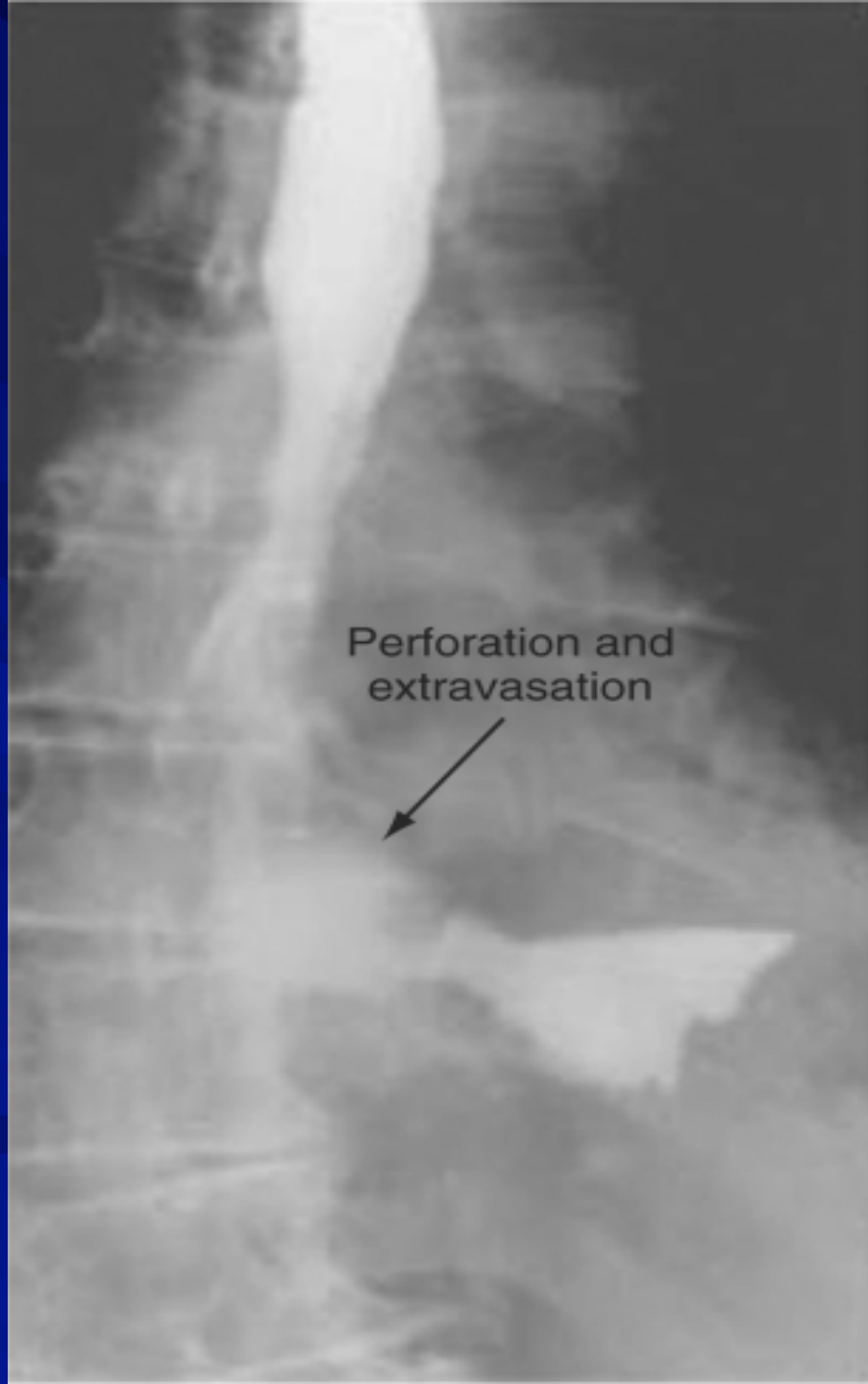- **A surgical endoscopy needs to be performed if the esophagram is negative or if operative intervention is planned.**
- **Mucosal injury is suggested if blood, mucosal hematoma, or a flap is seen or if the esophagus is difficult to insufflate.**

Figure 1.









Perforation and
extravasation



Treatment

- **Patients with an esophageal perforation can progress rapidly to hemodynamic instability and shock**
- **perforation is suspected, appropriate resuscitation measures with the placement of large-bore peripheral IV catheters, a urinary catheter, and a secured airway are undertaken before the patient is sent for diagnostic testing**

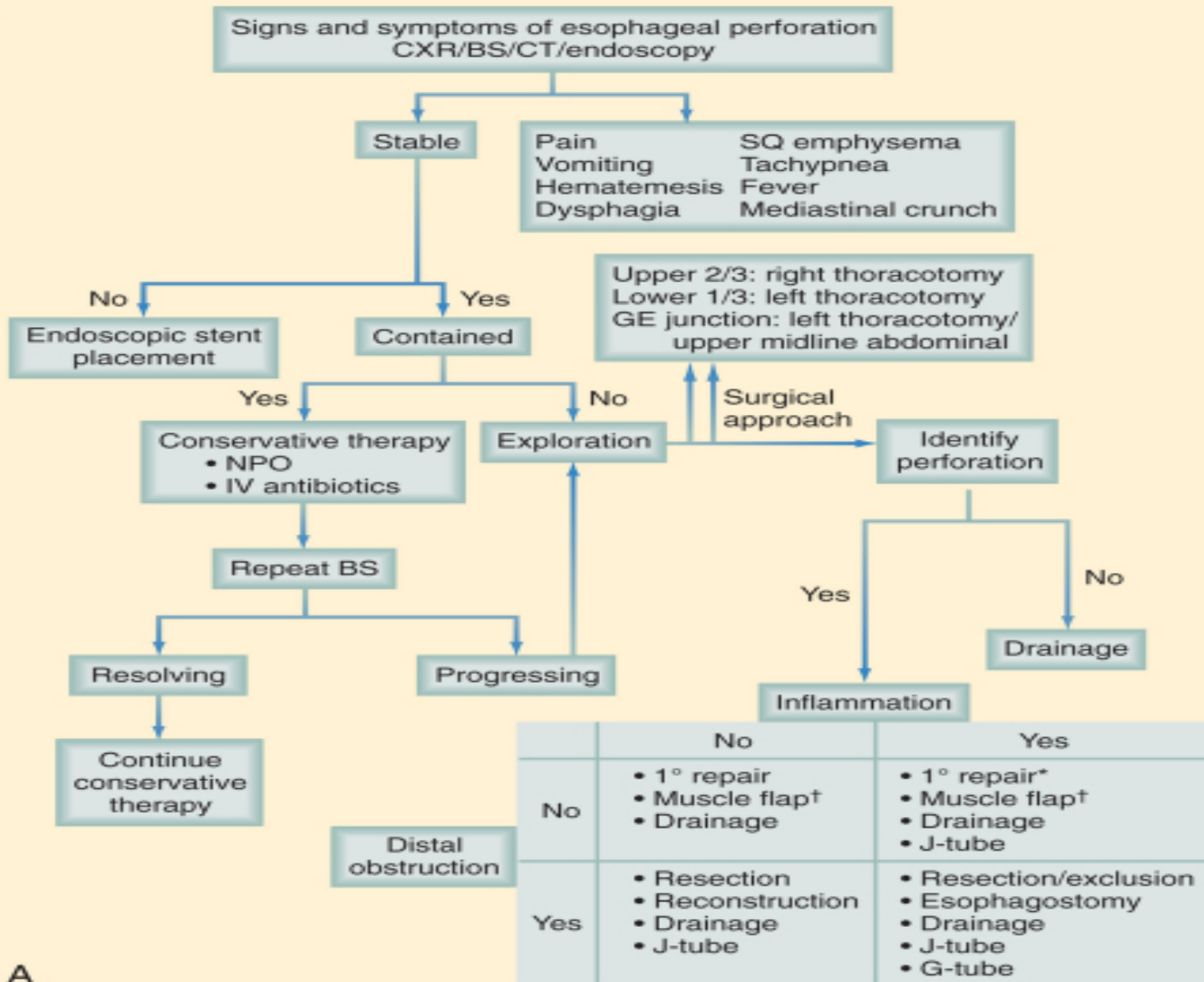
Treatment

- **IV fluids and broad-spectrum antibiotics are started immediately, and the patient is monitored in an ICU**
- **The patient is kept NPO, and nutritional access needs are assessed**

Treatment

- **Surgery is not indicated for every patient with a perforation of the esophagus**
- **management is dependent on several variables: stability of the patient, extent of contamination, degree of inflammation, underlying esophageal disease, and location of perforation**

MANAGEMENT OF THORACIC AND ABDOMINAL ESOPHAGEAL PERFORATIONS



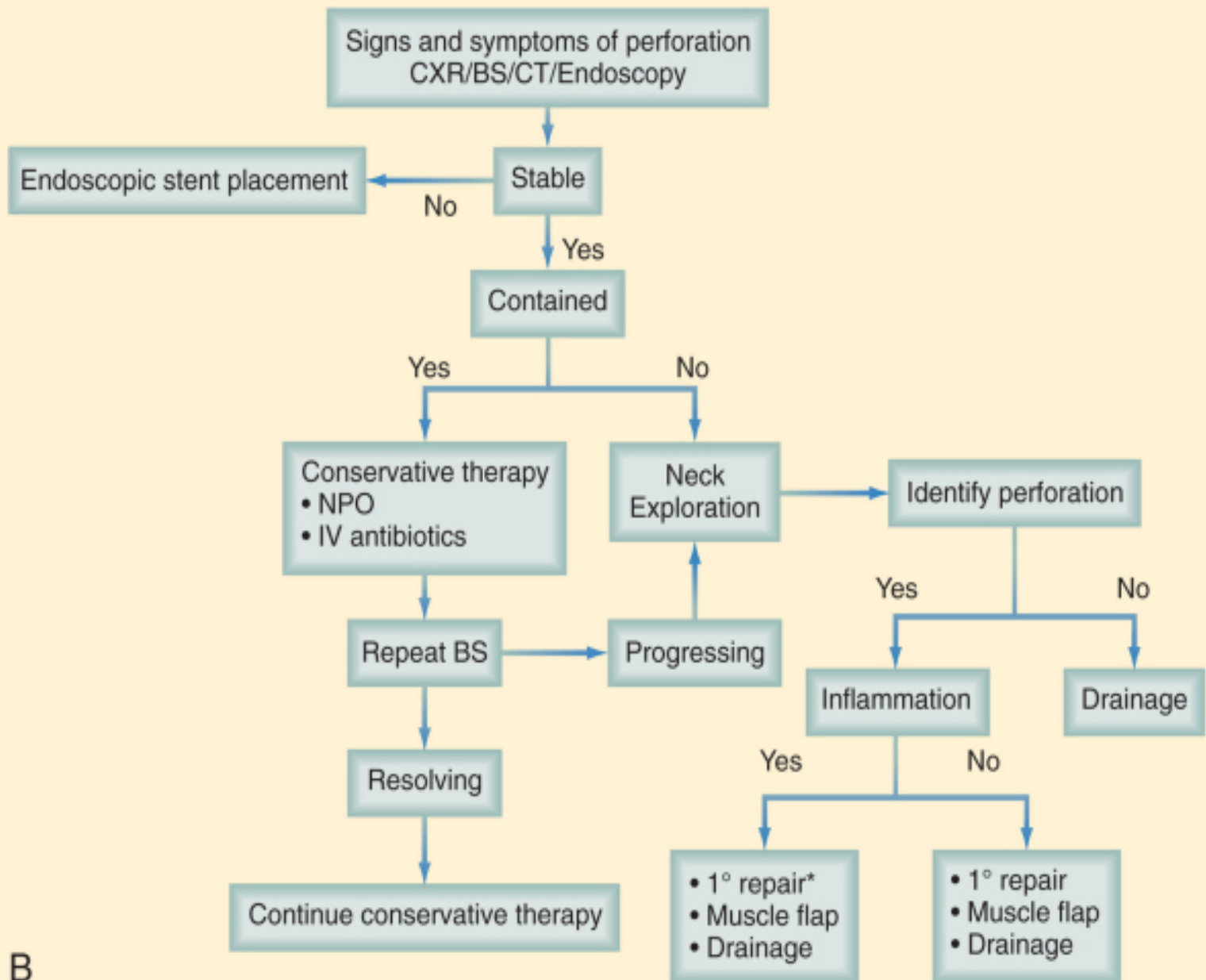
Treatment

- **The most critical variable that determines the surgical management of an esophageal perforation is the degree of inflammation surrounding the perforation.**
- **When patients present within 24 hours of perforation, inflammation is generally minimal, and primary surgical repair is recommended**

Treatment

- **With time, inflammation progresses, and tissues become friable and may not be amenable to primary repair.**
- **The final variable to consider in the surgical management of esophageal perforations is the location of the perforation**

MANAGEMENT OF CERVICAL ESOPHAGEAL PERFORATIONS



Leiomyoma

- **Leiomyomas constitute 60% of all benign esophageal tumors**
- **They are found in men slightly more often than women and tend to present in the 4th and 5th decades**
- **They are found in the distal two thirds of the esophagus more than 80% of the time**

Leiomyoma

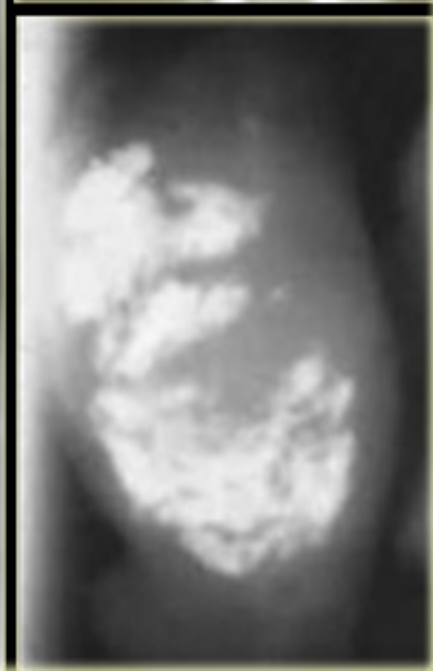
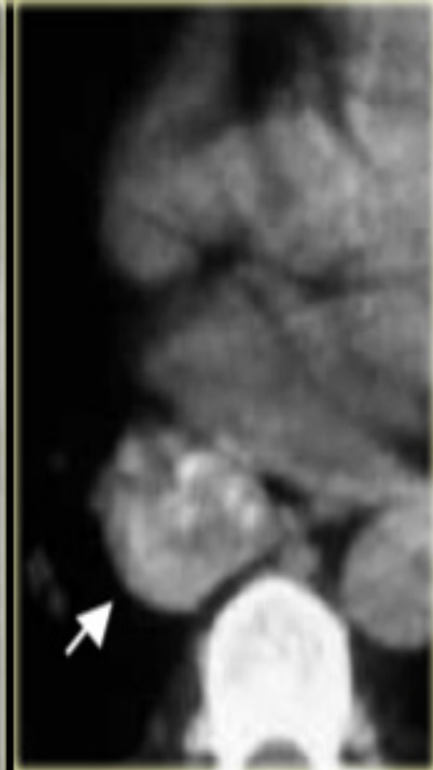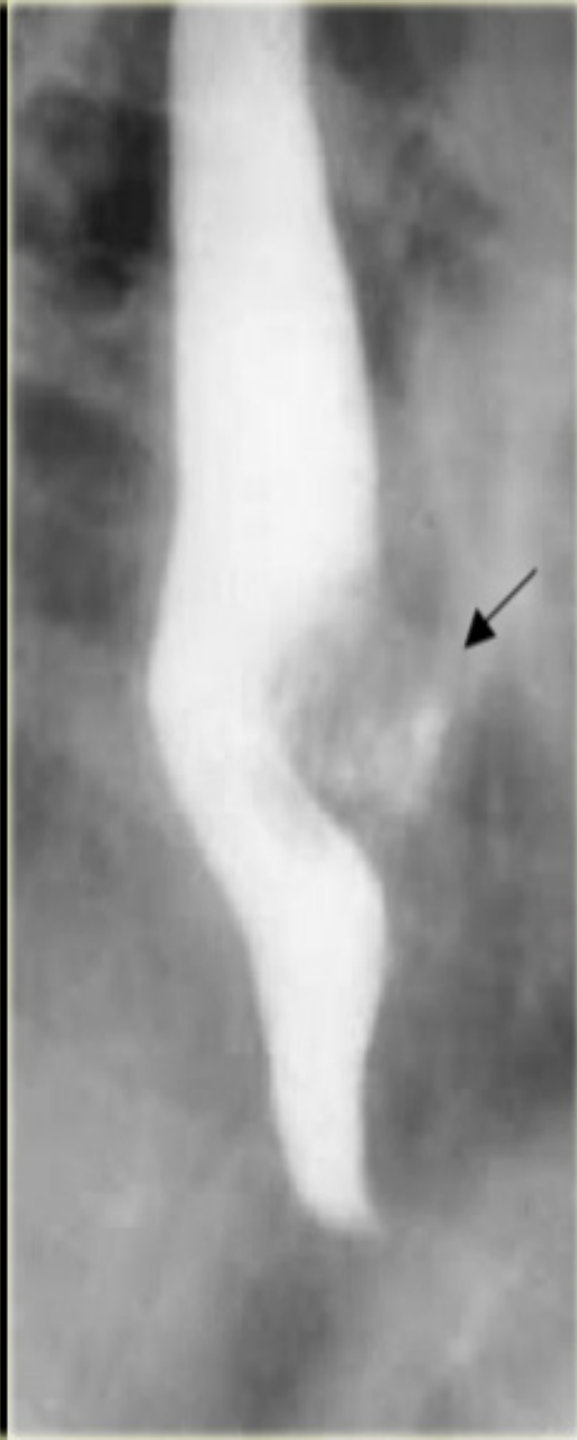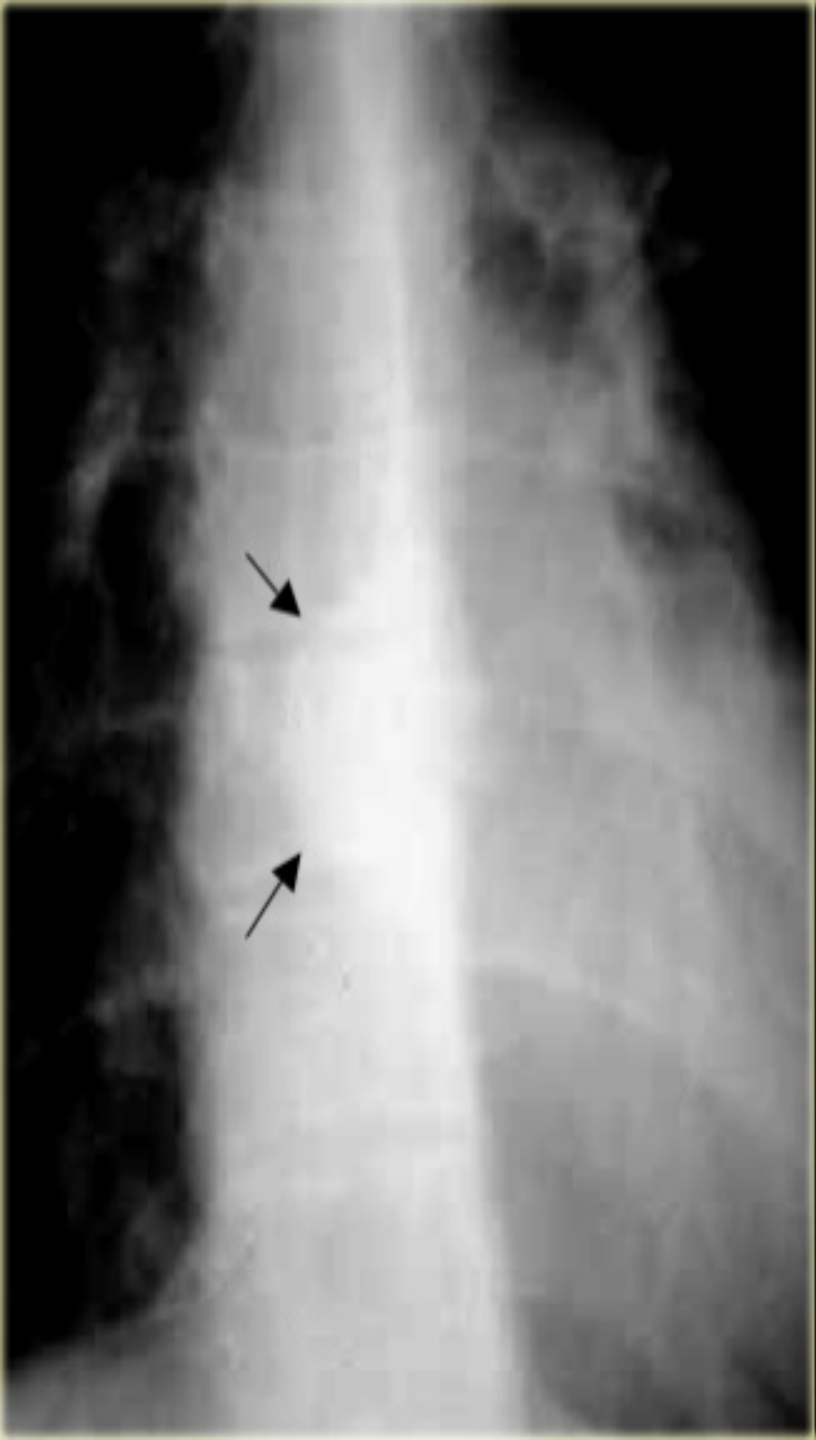
- They are usually solitary and remain intramural, causing symptoms as they enlarge.
- Recently, they have been classified as a gastrointestinal stromal tumor (GIST)
- GIST tumors are the most common mesenchymal tumors of the gastrointestinal tract and can be benign or malignant

Leiomyoma

- Nearly all GIST tumors occur from mutations of the *c-KIT* oncogene, which codes for the expression of *c-KIT* (CD117).
- All leiomyomas are benign with malignant transformation being ra

Symptoms and Diagnosis

- **Many leiomyomas are asymptomatic**
- **Dysphagia and pain are the most common symptoms and can result from even the smallest tumors**
- **A chest radiograph is not usually helpful to diagnose a leiomyoma, but on barium esophagram, a leiomyoma has a characteristic appearance.**



Leiomyoma

- During endoscopy, extrinsic compression is seen, and the overlying mucosa is noted to be intact
- Diagnosis also can be made by an endoscopic ultrasound (EUS), which will demonstrate a hypoechoic mass in the submucosa or muscularis propria

Treatment

- **Leiomyomas are slow-growing tumors with rare malignant potential that will continue to grow and become progressively symptomatic with time**
- **Although observation is acceptable in patients with small (<2 cm) asymptomatic tumors or other significant comorbid conditions, in most patients, surgical resection is advocated**

Treatment

- **Surgical enucleation of the tumor remains the standard of care and is performed through a thoracotomy or with video or robotic assistance**
- **The mortality rate is less than 2%, and success in relieving dysphagia approaches 100%**

CARCINOMA OF THE ESOPHAGUS

- **Esophageal cancer is the fastest growing cancer in the western countries**
- **Squamous cell carcinoma still accounts for most esophageal cancers diagnosed**
- **However, in the US, esophageal adenocarcinoma is noted in up to 70% of patients presenting with esophageal cancer**

CARCINOMA OF THE ESOPHAGUS

- **Squamous cell carcinomas arise from the squamous mucosa that is native to the esophagus and is found in the upper and middle third of the esophagus 70% of the time**
- **Smoking and alcohol both increase the risk for foregut cancers by 5-fold.
Combined**

CARCINOMA OF THE ESOPHAGUS

- **Food additives, including nitrosamines found in pickled and smoked foods, long-term ingestion of hot liquids**
- **caustic ingestion, achalasia, bulimia, tylosis (an inherited autosomal dominant trait), Plummer-Vinson syndrome, external-beam radiation, and esophageal diverticula all have known associations with squamous cell cancer.**

CARCINOMA OF THE ESOPHAGUS

- **The 5-year survival rate varies but can be as good as 70% with polypoid lesions and as poor as 15% with advanced tumors.**
- **esophageal adenocarcinoma now accounts for nearly 70% of all esophageal carcinomas diagnosed in Western countries**

CARCINOMA OF THE ESOPHAGUS

- **There are a number of factors that are responsible for this shift in cell type:**
 - Increasing incidence of GERD
 - Western diet
 - Increased use of acid-suppression medications
- **Intake of caffeine, fats, and acidic and spicy foods all lead to decreased tone in the LES and an increase in reflux**

CARCINOMA OF THE ESOPHAGUS

- **As an adaptive measure, the squamous-lined distal esophagus changes to become lined with metaplastic columnar epithelium (Barrett's esophagus)**
- **Progressive changes from metaplastic (Barrett's esophagus) to dysplastic cells may lead to the development of esophageal adenocarcinoma**

Symptoms

- **Early-stage cancers may be asymptomatic or mimic symptoms of GERD**
- **Most patients with esophageal cancer present with dysphagia and weight loss**
- **Because of the distensibility of the esophagus, a mass can obstruct two thirds of the lumen before symptoms of dysphagia are noted**

Symptoms

- Choking, coughing, and aspiration from a tracheoesophageal fistula, as well as hoarseness and vocal cord paralysis from direct invasion into the recurrent laryngeal nerve, are ominous signs of advanced disease
- Systemic metastases to liver, bone, and lung can present with jaundice, excessive pain, and respiratory symptoms.

Diagnosis

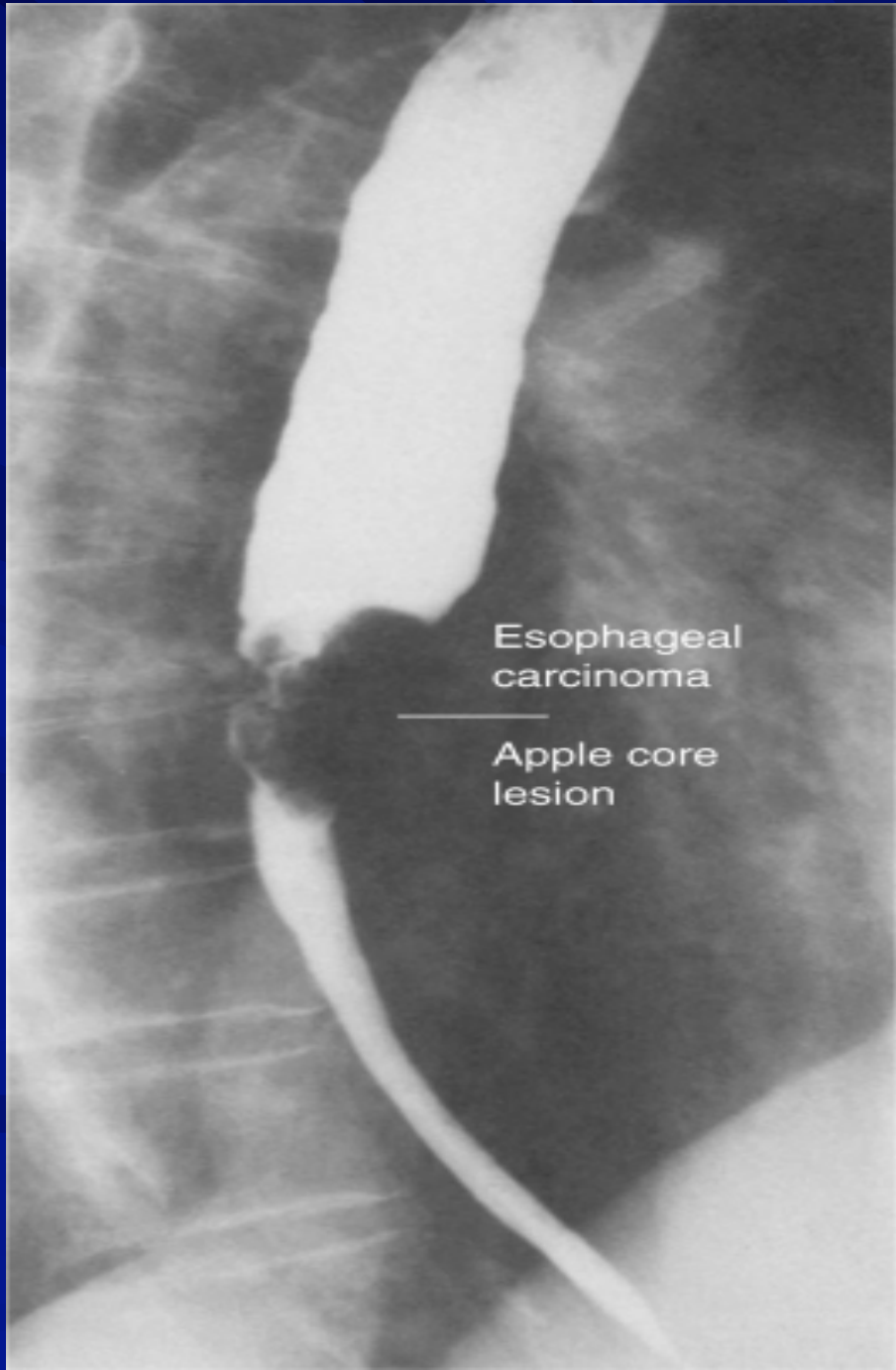
- **There are a plethora of modalities available to diagnose and stage esophageal cancer**
- **Radiologic tests, endoscopic procedures, and minimally invasive surgical techniques all add value to a solid staging workup in a patient with esophageal cancer.**

Esophagram

- **A barium esophagram is recommended for any patient presenting with dysphagia**
- **is able to differentiate intraluminal from intramural lesions and to discriminate between intrinsic (from a mass protruding into the lumen) and extrinsic (from compression of a structures outside the esophagus) compression**

Esophagram

- **The classic finding of an apple-core lesion in patients with esophageal cancer is recognized easily**
- **Although the esophagram will not be specific for cancer, it is a good first test to perform in patients presenting with dysphagia and a suspicion of esophageal cancer**



Esophageal carcinoma

Apple core lesion

Endoscopy

- **The diagnosis of esophageal cancer is made best from an endoscopic biopsy**
- **any patient undergoing surgery for esophageal cancer must have an endoscopy performed by the operating surgeon before entering the operating room for a definitive resection**

Computed Tomography

- **CT scan of the chest and abdomen is important to assess the length of the tumor, thickness of the esophagus and stomach, regional lymph node status and distant disease to the liver and lungs**

Positron Emission Tomography

- **PET scan evaluates the primary mass, regional lymph nodes, and distant disease**
- **Its sensitivity and specificity slightly exceed those of CT; however, they remain low for definitive staging**

Endoscopic Ultrasound

- **EUS is the most critical component of esophageal cancer staging.**
- **The information obtained from EUS will help guide both medical and surgical therapy**
- **biopsy samples can be obtained of the mass and lymph nodes in the paratracheal, subcarinal, paraesophageal, celiac region**

Treatment

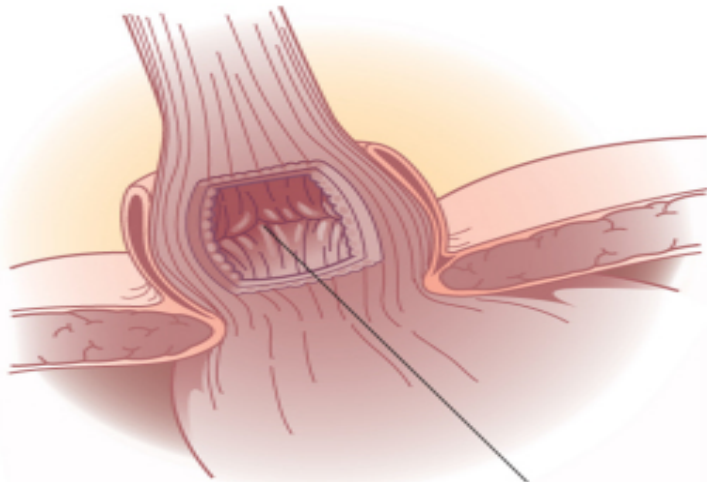
- Chemotherpay
- Radiation therap
- Chemo-radiotherap
- Surgical resection

GASTROESOPHAGEAL REFLUX DISEASE

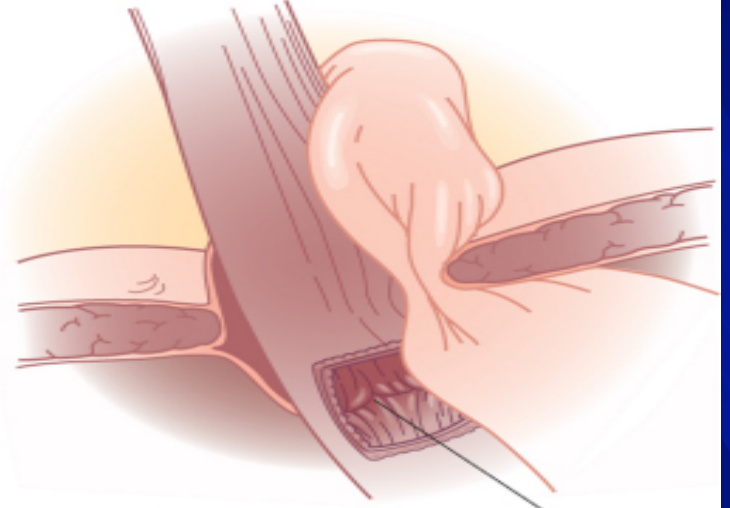
- LES has the primary role of preventing reflux of the gastric contents into the esophagus
- GERD may occur when the pressure of the high-pressure zone in the distal esophagus is too low to prevent gastric contents from entering the esophagus

GASTROESOPHAGEAL REFLUX DISEASE

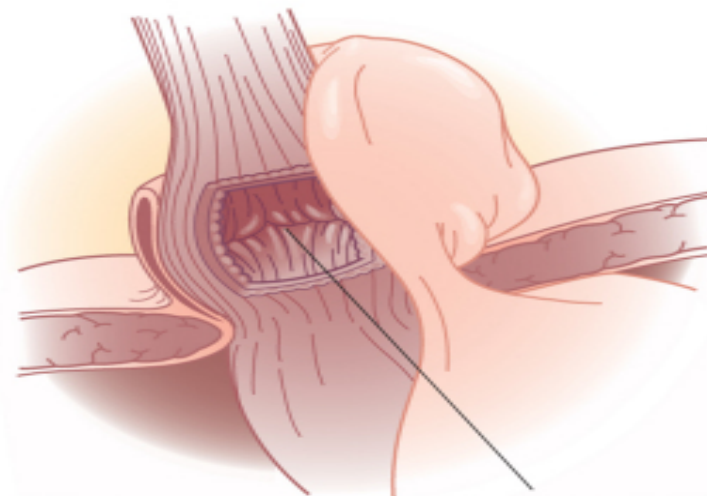
- GERD is often associated with a hiatal hernia
- the most common is the type I hernia, also called a *sliding hiatal hernia*
- Type II and III hiatal hernias are often referred to as *paraesophageal hernias* and they may be associated with GERD
- Type IV when there is other organ herniated into the chest (Spleen ,Colon)



A GE junction



B GE junction



C GE junction

GASTROESOPHAGEAL REFLUX DISEASE

■ Defintion :

- Symptoms OR mucosal damage produced by the abnormal reflux of gastric contents into the esophagus
- Often chronic and relapsing
- May see complications of GERD in patients who lack typical symptoms

GASTROESOPHAGEAL REFLUX DISEASE

■ Epidemiology :

- About 44% of the US adult population have heartburn at least once a month
- 14% of Americans have symptoms weekly
- 7% have symptoms daily

Clinical Presentations of GERD

- Classic GERD
- Extraesophageal/Atypical GERD
- Complicated GERD

Clinical Presentations of GERD

■ Classic GERD :

- Substernal burning and or regurgitation
- Postprandial
- Aggravated by change of position
- Prompt relief by antacid

Extraesophageal Manifestations of GERD

Pulmonary

Asthma

Aspiration pneumonia

Chronic bronchitis

Pulmonary fibrosis

Other

Chest pain

Dental erosion

ENT

Hoarseness

Laryngitis

Pharyngitis

Chronic cough

Globus sensation

Dysphonia

Sinusitis

Subglottic stenosis

Laryngeal cancer

Clinical Presentations of GERD

■ Symptoms of Complicated GERD :

■ Dysphagia

- Difficulty swallowing: food sticks or hangs up

■ Odynophagia

- Retrosternal pain with swallowing

■ Bleeding

Diagnostic Tests for GERD

- Barium swallow
- Endoscopy
- Ambulatory pH monitoring
- Esophageal manometry

Treatment

- Lifestyle Modifications
- Acid Suppression Therapy
- Anti-Reflux Surgery
- Endoscopic GERD Therapy

Treatment

■ Lifestyle Modifications

- Elevate head of bed 4-6 inches
- Avoid eating within 2-3 hours of bedtime
- Lose weight if overweight
- Stop smoking
- Modify diet
 - Eat more frequent but smaller meals
 - Avoid fatty/fried food, peppermint, chocolate, alcohol, carbonated beverages, coffee and tea
- OTC medications prn

Acid Suppression Therapy for GERD

H₂-Receptor Antagonists (H₂RAs)

Cimetidine (Tagamet®)
Ranitidine (Zantac®)
Famotidine (Pepcid®)
Nizatidine (Axid®)

Proton Pump Inhibitors (PPIs)

Omeprazole (Prilosec®)
Lansoprazole
(Prevacid®)
Rabeprazole (Aciphex®)
Pantoprazole (Protonix®)
Esomeprazole (Nexium
®)

Anti-Reflux Surgery

■ Indication for Surgery :

- have failed medical management
- opt for surgery despite successful medical management (due to life style considerations including age, time or expense of medications, etc)
- have complications of GERD (e.g. Barrett's esophagus; grade III or IV esophagitis)
- have medical complications attributable to a large hiatal hernia. (e.g. bleeding, dysphagia)
- have "atypical" symptoms (asthma, hoarseness, cough, chest pain, aspiration) and reflux documented on 24 hour pH monitoring

Endoscopic GERD Therapy

- Endoscopic antireflux therapies
 - Radiofrequency energy delivered to the LES
 - Stretta procedure
 - Suture ligation of the cardia
 - Endoscopic plication
 - Submucosal implantation of inert material in the region of the lower esophageal sphincter
 - Enteryx