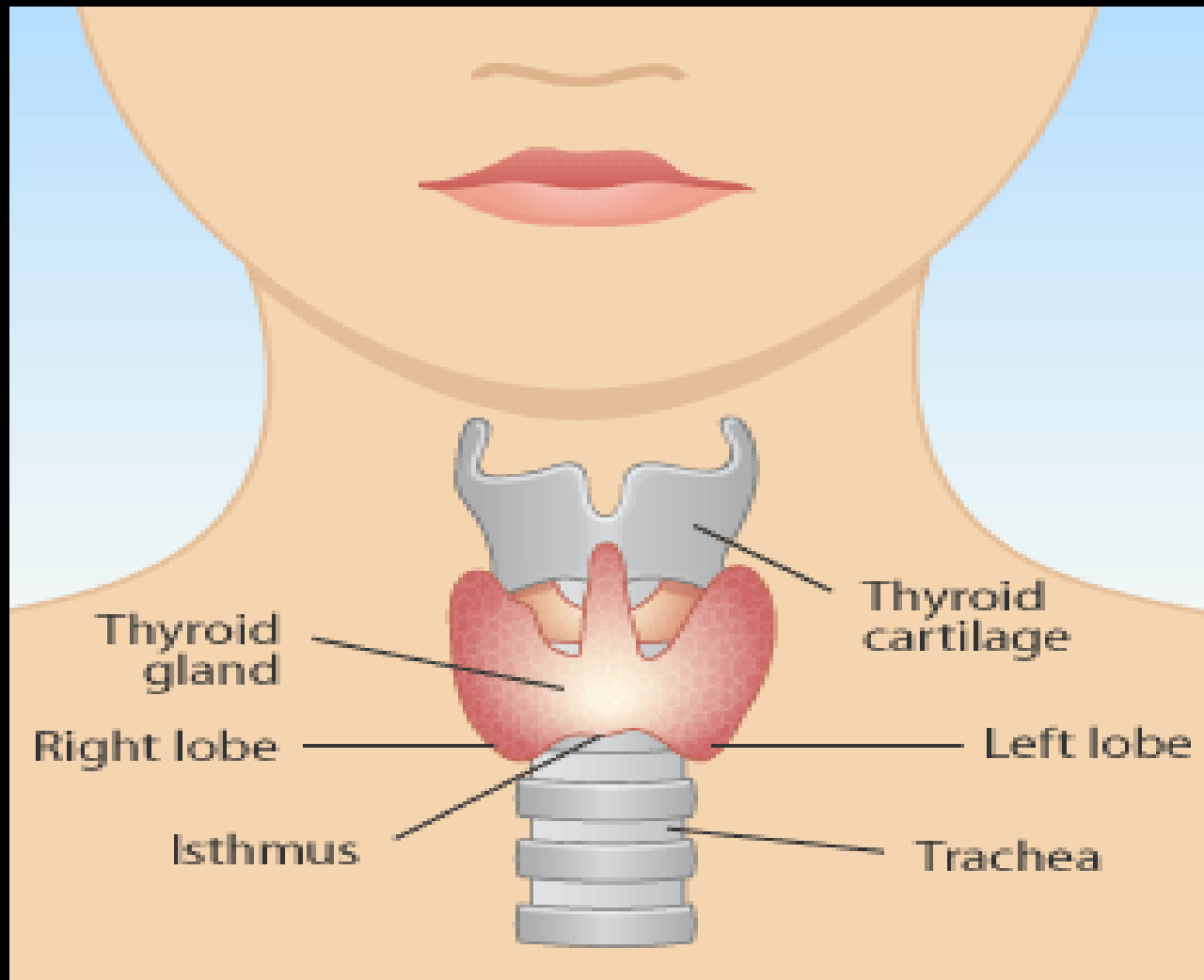
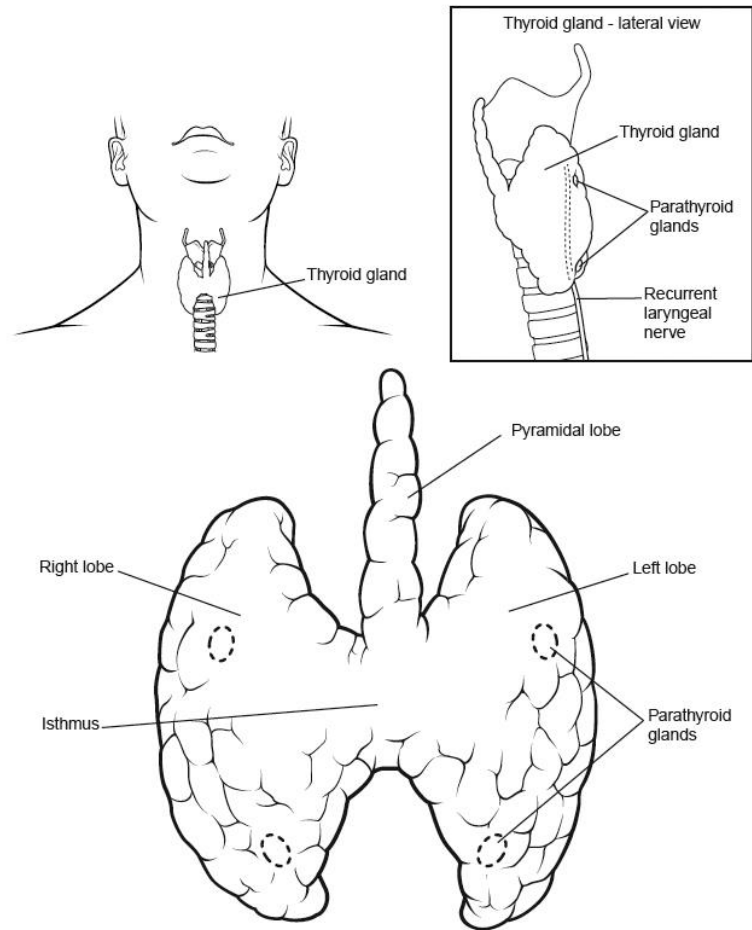


Imaging of Thyroid  
& Parathyroid  
Disease

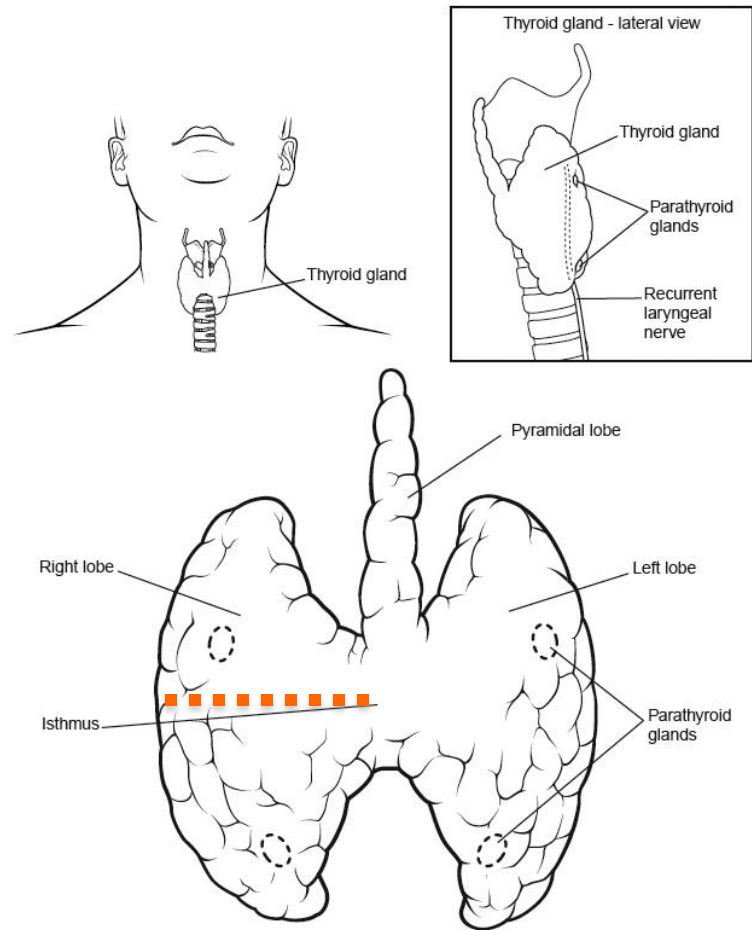
# Anatomy of the Thyroid Gland



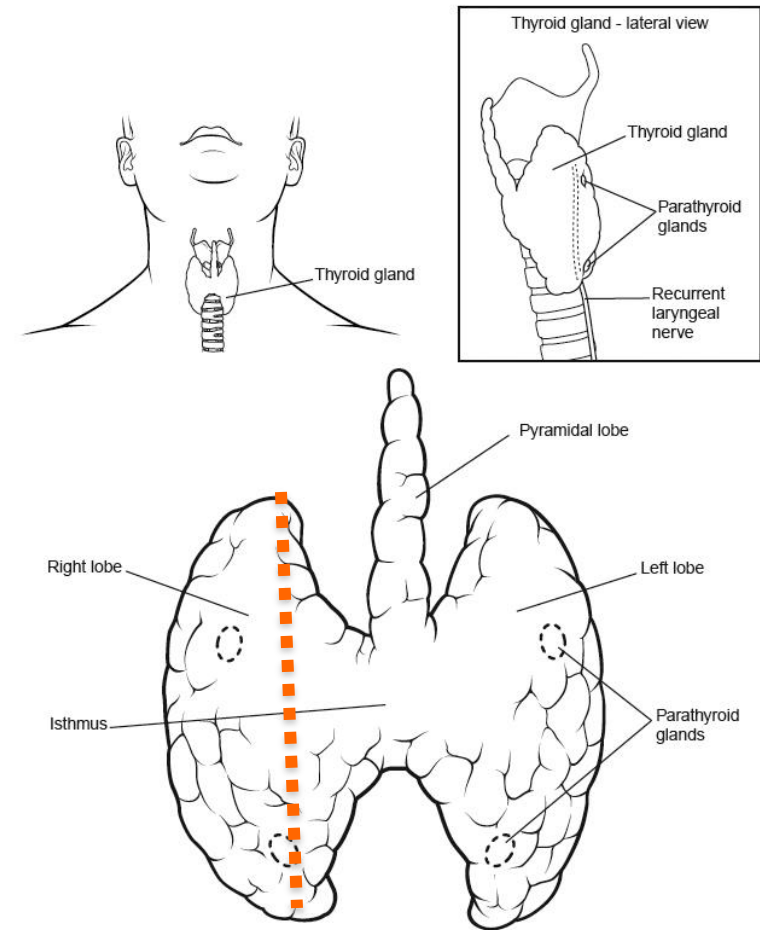
- Anterior neck
- Extending from the level of **C5 - T1**
- Overlays **2<sup>nd</sup> – 4<sup>th</sup>** tracheal rings



- Average width: 12-15 mm (each lobe)



- Average height: 50-60 mm long



# Thyroid disease

# Thyroid Diseases

<b>Thyrotoxicosis</b>	<b>Hypothyroidism</b>	<b>Thyroid nodules</b>

# Thyroid Diseases

Thyrotoxicosis	Hypothyroidism	Thyroid nodules



# Thyrotoxicosis versus Hyperthyroidism

A group of symptoms and signs due to  production of thyroid hormones

Hyperthyroidism

Thyrotoxicosis

Hyper functioning thyroid gland.

Any cause.

# Thyroid Diseases

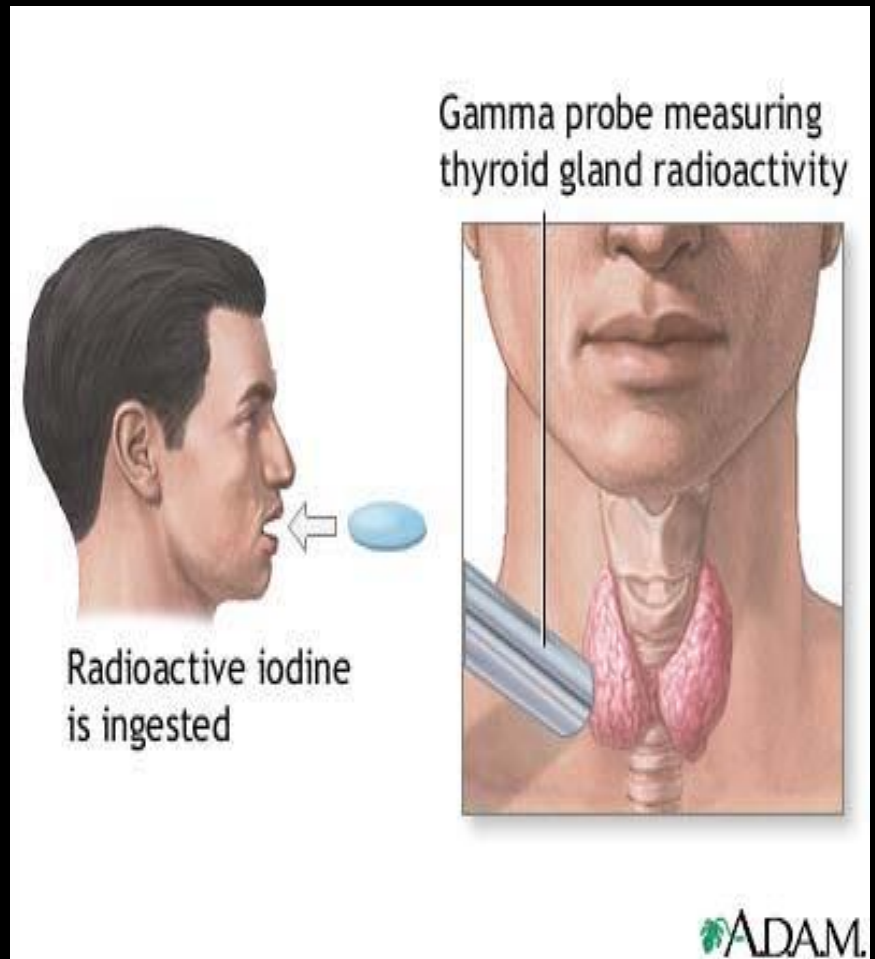
Thyrotoxicosis	Hypothyroidism	Thyroid nodules
<u>Hyperthyroidism</u> 1- Diffuse toxic goiter (Graves' disease). 2- Single toxic nodule. 3- Multi-nodular toxic goiter.		
<u>Early phase sub-acute thyroiditis.</u>		
<u>Exogenous thyroid hormone intake.</u>		

# TFT and Thyroid scan

- Thyrotoxicosis = suppressed TSH and elevated T3/T4.
- Based on TFT, the exact cause of thyrotoxicosis can not be determined.
- **Thyroid scan** is a very helpful tool in differentiating between various causes of thyrotoxicosis.

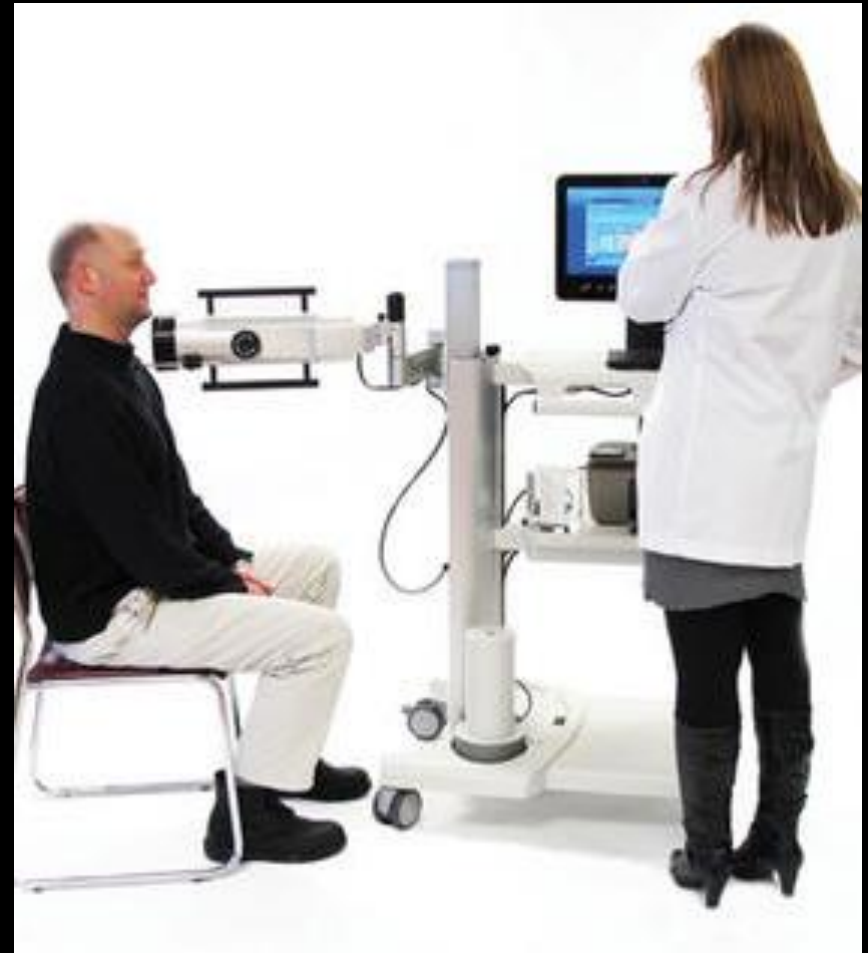# Thyroid scan and uptake

- **Radioactive Iodine (RAI)** is used for thyroid scan and uptake.
- RAI is given **orally**.



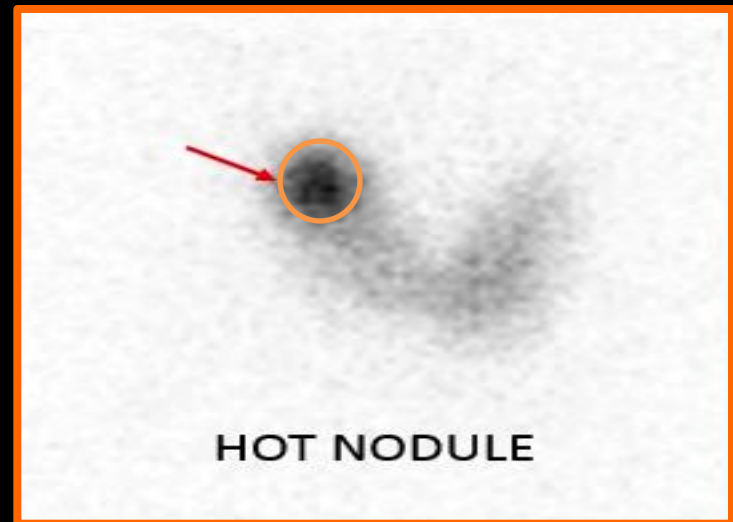
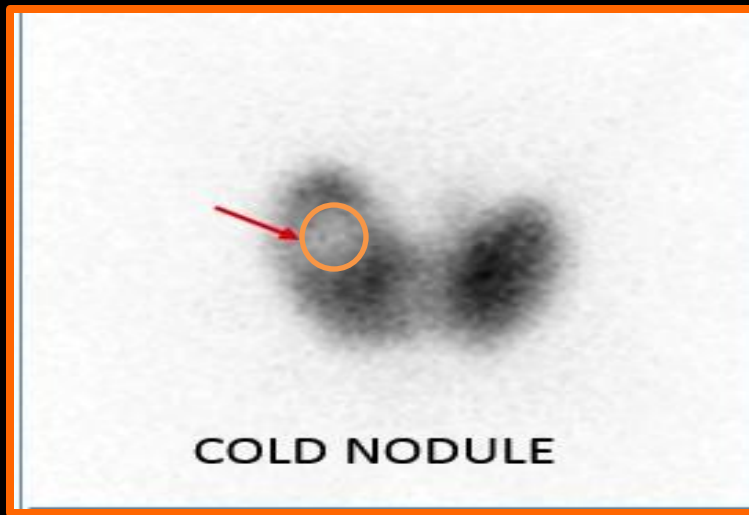
# Thyroid scan and uptake

- Image and uptake are obtained **after 24 hours**
- This test determines how much of orally ingested iodine accumulated in the thyroid at 24 hours



# Imaging Findings???

- Symmetric or asymmetric uptake.
- Homogeneous or inhomogeneous uptake.
- Nodules: Cold or Hot



# Thyroid Diseases

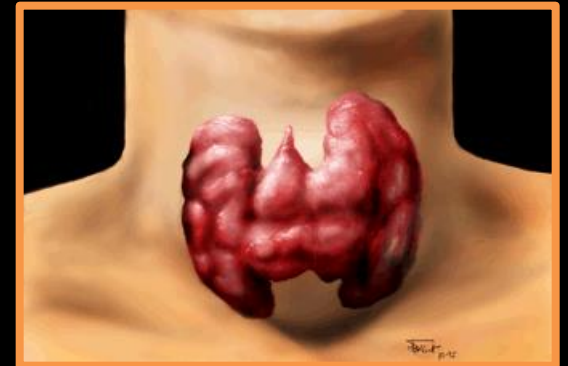
Thyrotoxicosis	Hypothyroidism	Thyroid nodules
<u>Hyperthyroidism</u> 1- Diffuse toxic goiter (Graves' disease). 2- Single toxic nodule. 3- Multi-nodular toxic goiter.		
<u>Early phase sub-acute thyroiditis.</u>		
<u>Exogenous thyroid hormone intake.</u>		

# 1) Diffuse Toxic goiter (Graves' Disease)

- Diffuse **enlargement** of thyroid gland.
- **Homogeneous** uptake.
- No significant focal abnormalities (nodules).
- 24-hour RAI uptake is **elevated**, usually  $> 35\%$



# Graves' Disease



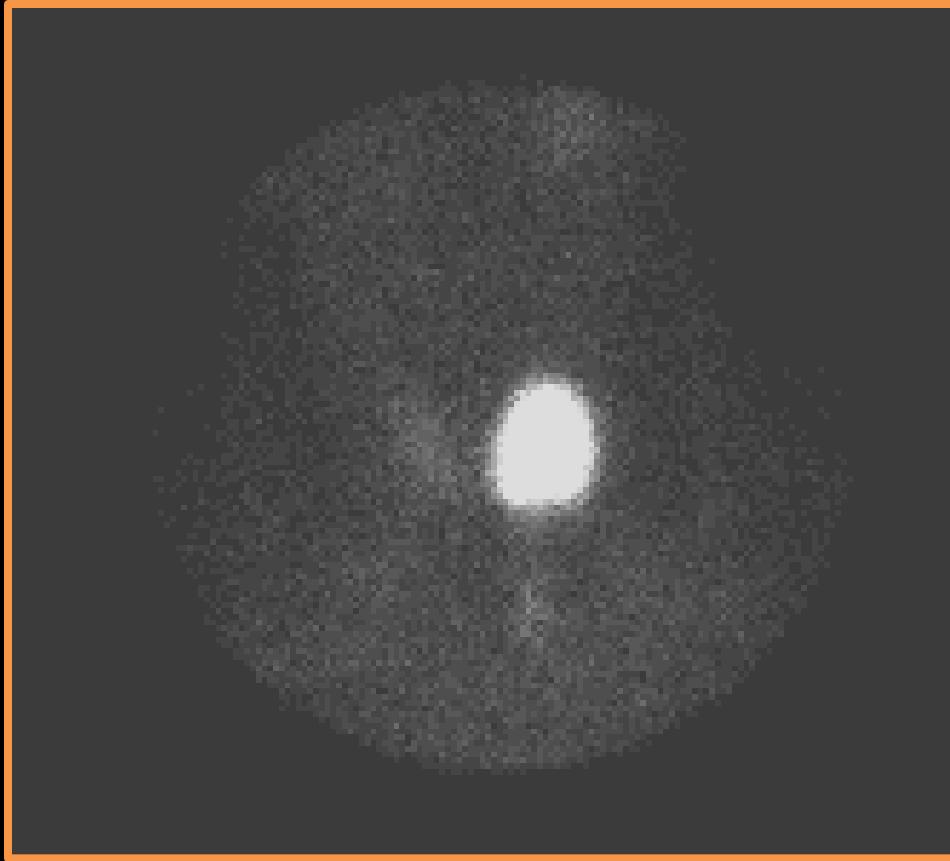
# Thyroid Diseases

Thyrotoxicosis	Hypothyroidism	Thyroid nodules
<u>Hyperthyroidism</u> 1- Diffuse toxic goiter (Graves' disease). <b>2- Single toxic nodule.</b> 3- Multi-nodular toxic goiter.		
<u>Early phase sub-acute thyroiditis.</u>		
<u>Exogenous thyroid hormone intake.</u>		

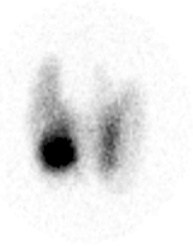## 2) Single Toxic Nodule

- Single hot nodule (independent of TSH or autonomous).
- Rest of thyroid gland is **poorly visualized** due to low TSH level (TSH dependent).
- 24-hour RAI uptake is **slightly elevated**, usually around 20%.

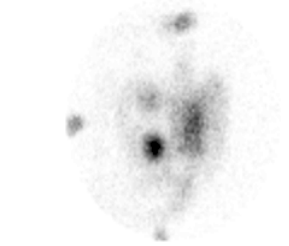
# Toxic ( Hot) Nodule



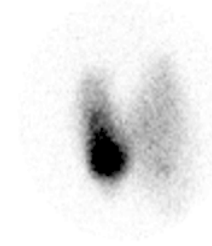
# Hot Nodule



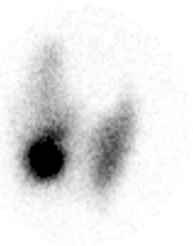
Anterior



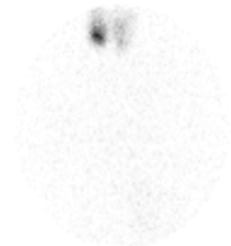Anterior w/marker



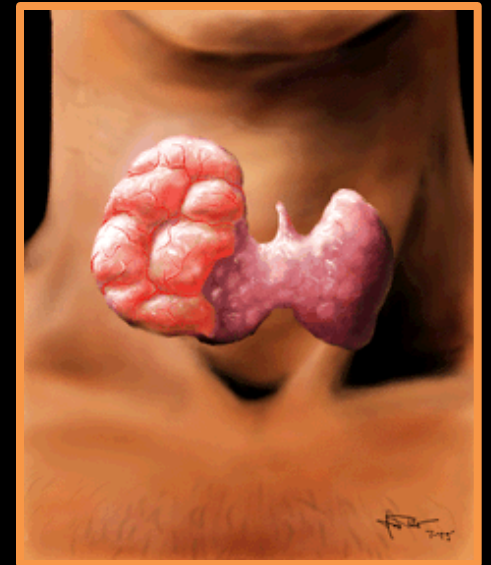LPO



RPO



Anterior chest



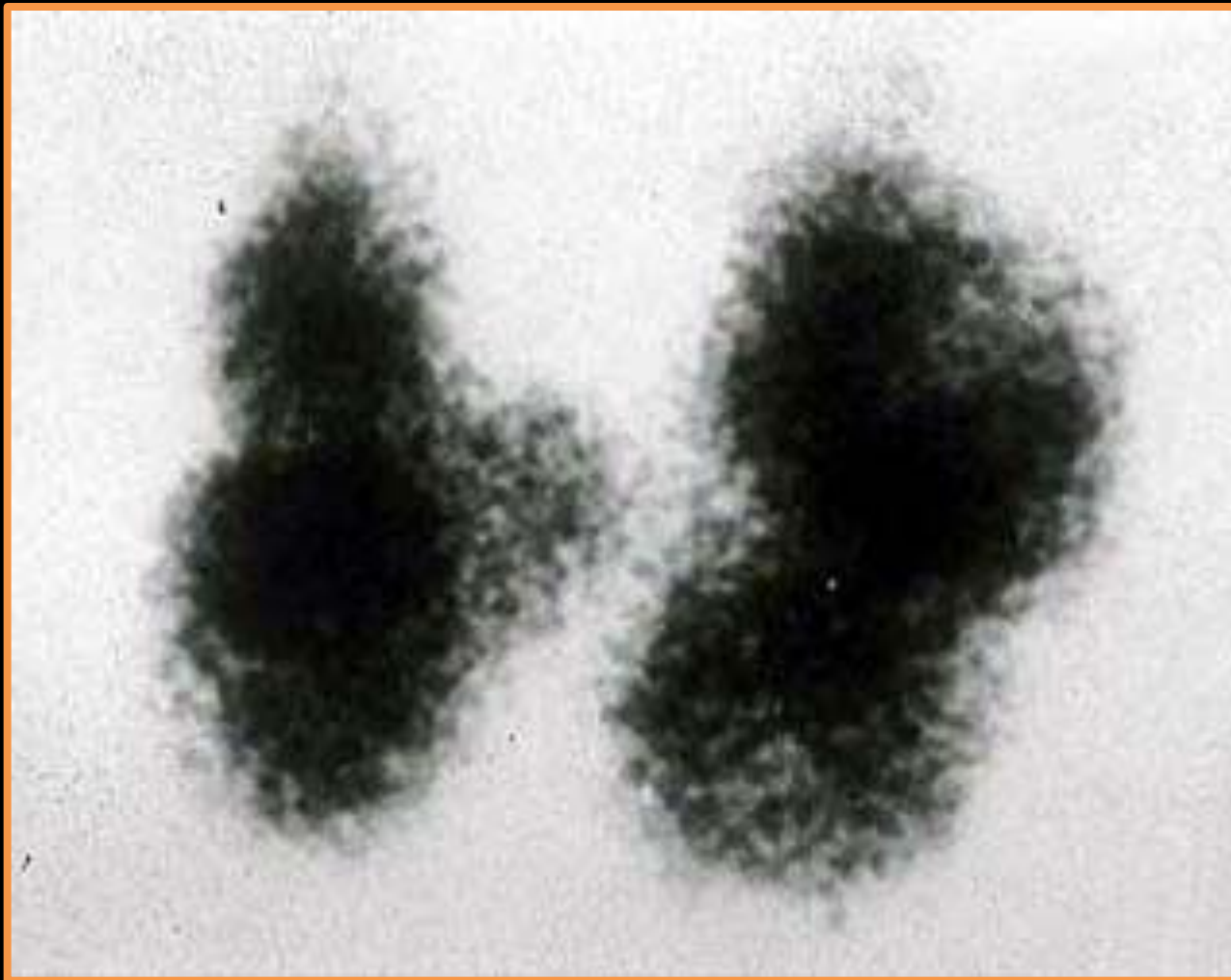
# Thyroid Diseases

Thyrotoxicosis	Hypothyroidism	Thyroid nodules
<u>Hyperthyroidism</u> 1- Diffuse toxic goiter (Graves' disease). 2- Single toxic nodule. <b>3- Multi-nodular toxic goiter.</b>		
<u>Early phase sub-acute thyroiditis.</u>		
<u>Exogenous thyroid hormone intake.</u>		

### 3) Toxic Multi-Nodular Goiter

- **Mild inhomogeneous** uptake in thyroid gland.
- Multiple **cold and hot nodules** in both thyroid lobes.
- 24-hour uptake is **mildly elevated**, usually between 20%-30%.

# Multi-nodular Goiter





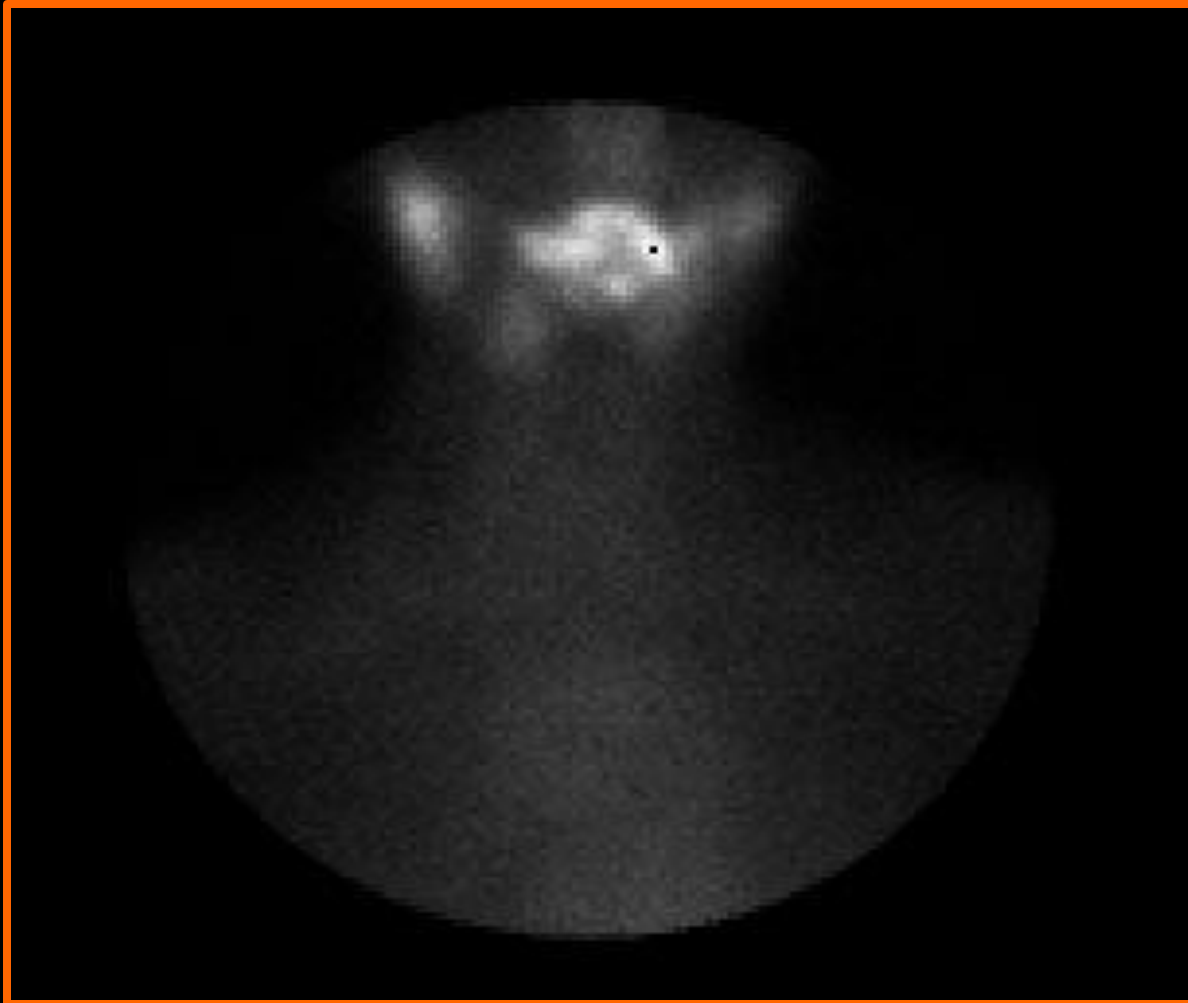
# Thyroid Diseases

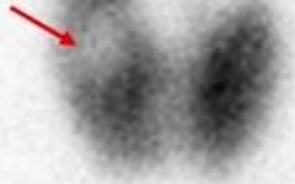
Thyrotoxicosis	Hypothyroidism	Thyroid nodules
<u>Hyperthyroidism</u> 1- Diffuse toxic goiter (Graves' disease). 2- Single toxic nodule. 3- Multi-nodular toxic goiter.		
<u>Early phase sub-acute thyroiditis.</u>		
<u>Exogenous thyroid hormone intake.</u>		

# Early Phase Sub-acute Thyroiditis

- **Inhomogeneous uptake** could be mild or severe. In some cases thyroid gland is not visualized.
- No significant focal abnormalities (nodules).
- 24-hour RAI uptake is **low**, usually  $< 5\%$ .

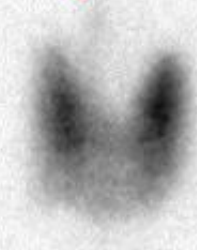# Early Subacute Thyroiditis





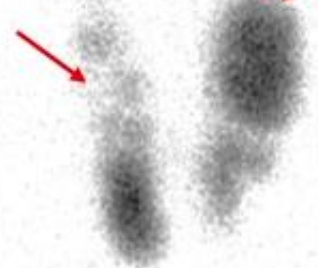
COLD NODULE

pyramidal lobe

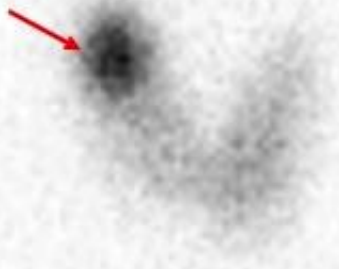


GRAVE DISEASE

hot and cold nodules




TOXIC MULTINODULAR



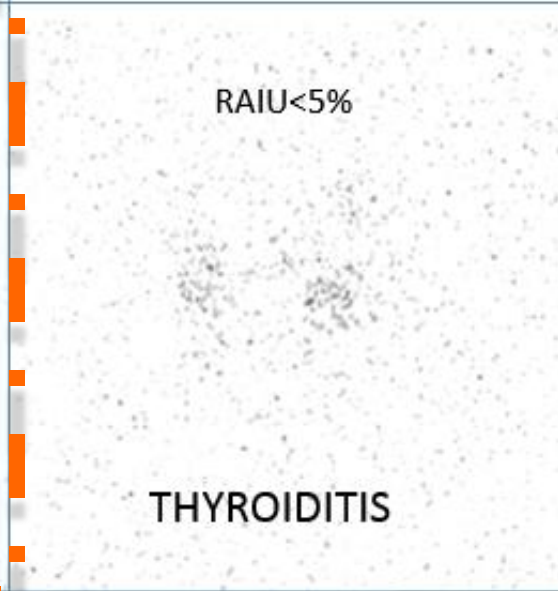
HOT NODULE

suppression of remainder of gland



AUTONOMOUS NODULE

RAIU < 5%



THYROIDITIS

# Thyroid Diseases

Thyrotoxicosis	Hypothyroidism	Thyroid nodules

# Hypothyroidism

- The main cause **is chronic thyroiditis** (Hashimoto's thyroiditis).
- TSH is elevated.
- Thyroid scan **does not** have significant diagnostic value in this entity. Unless, there is nodule, thyroid scan may be helpful.

# Thyroid Diseases

<b>Thyrotoxicosis</b>	<b>Hypothyroidism</b>	<b>Thyroid nodules</b>

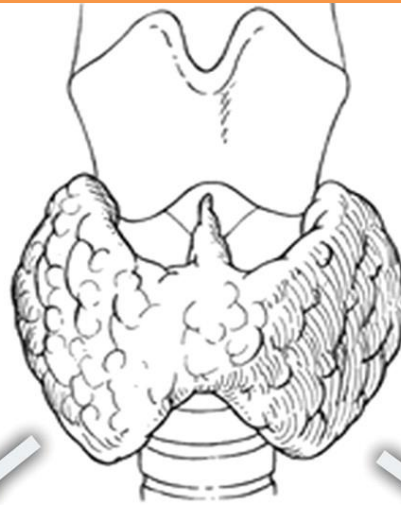# Thyroid Nodules

- Common, almost existing in half of the population.
- Usually found by physical examination or by ultrasound.
- **US is the first modality** used to investigate a palpable thyroid nodule.
- Scintigraphy is reserved for **characterizing functioning nodules** and for **staging follicular and papillary carcinomas**.



- The patient is usually **euthyroid**.
- If the patient is **hyperthyroid** do nuclear scan otherwise do FNA.
- **FNA** is the most accurate and cost-effective method for diagnostic evaluation of thyroid nodules.
- FNA have a **sensitivity of 76%–98%**, **specificity of 71%–100%**

# Frequency of Occurrence of Thyroid Malignancies



**CARCINOMA**  
Papillary 75%  
Follicular 10%  
Medullary 5%  
Anaplastic <5%

**Lymphoma <5%**  
**Metastases**  
lung, breast, renal

**Sarcoma**  
rare

# Risk Factors for Thyroid Cancer

1. Family history of thyroid cancer.
2. History of head and neck irradiation.
3. Female Gender.
4. Age of less than 30 years or more than 60 years.
5. Previous diagnosis of type 2 Multiple Endocrine Neoplasia

# US features of thyroid nodules

Certain US features are helpful in differentiating between the two. **The malignant features are includes:**

1. Micro-calcifications.
2. Local invasion.
3. A nodule that is taller than it is wider.
4. Markedly reduced echogenicity.
5. Lymph node metastases.

# US features of thyroid nodules

Other **less specific** features of malignant nodules which may be useful, such as:

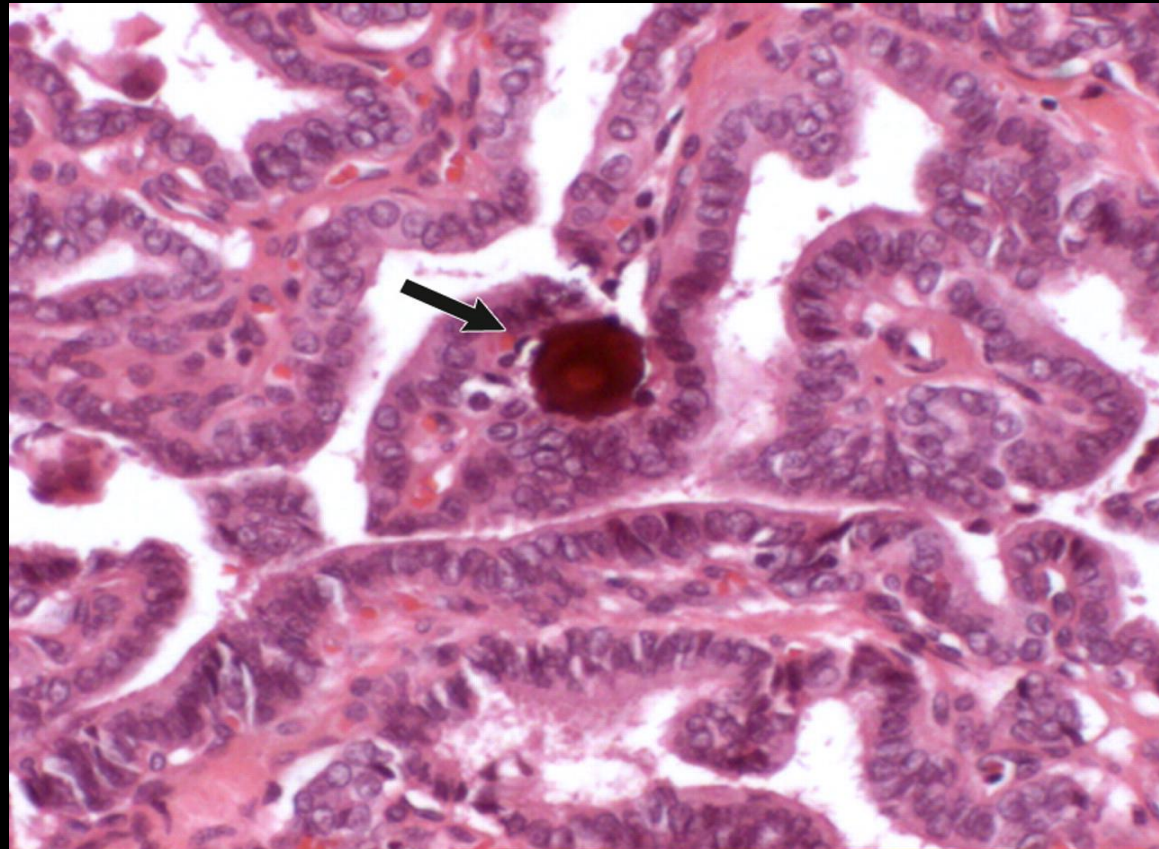
1. Absence of a halo.
2. Ill-defined irregular margins.
3. Solid composition.
4. Vascularity.

# US Features Associated with Thyroid Cancer

US Feature*	Sensitivity (%)	Specificity (%)	Positive Predictive Value (%)	Negative Predictive Value (%)
Microcalcifications (1–5)	26.1–59.1	85.8–95.0	24.3–70.7	41.8–94.2
Hypoechoogenicity (2–5)	26.5–87.1	43.4–94.3	11.4–68.4	73.5–93.8
Irregular margins or no halo (2–5)	17.4–77.5	38.9–85.0	9.3–60.0	38.9–97.8
Solid (4–6)	69.0–75.0	52.5–55.9	15.6–27.0	88.0–92.1
Intranodule vascularity (3, 6)	54.3–74.2	78.6–80.8	24.0–41.9	85.7–97.4
More tall than wide (2)	32.7	92.5	66.7	74.8

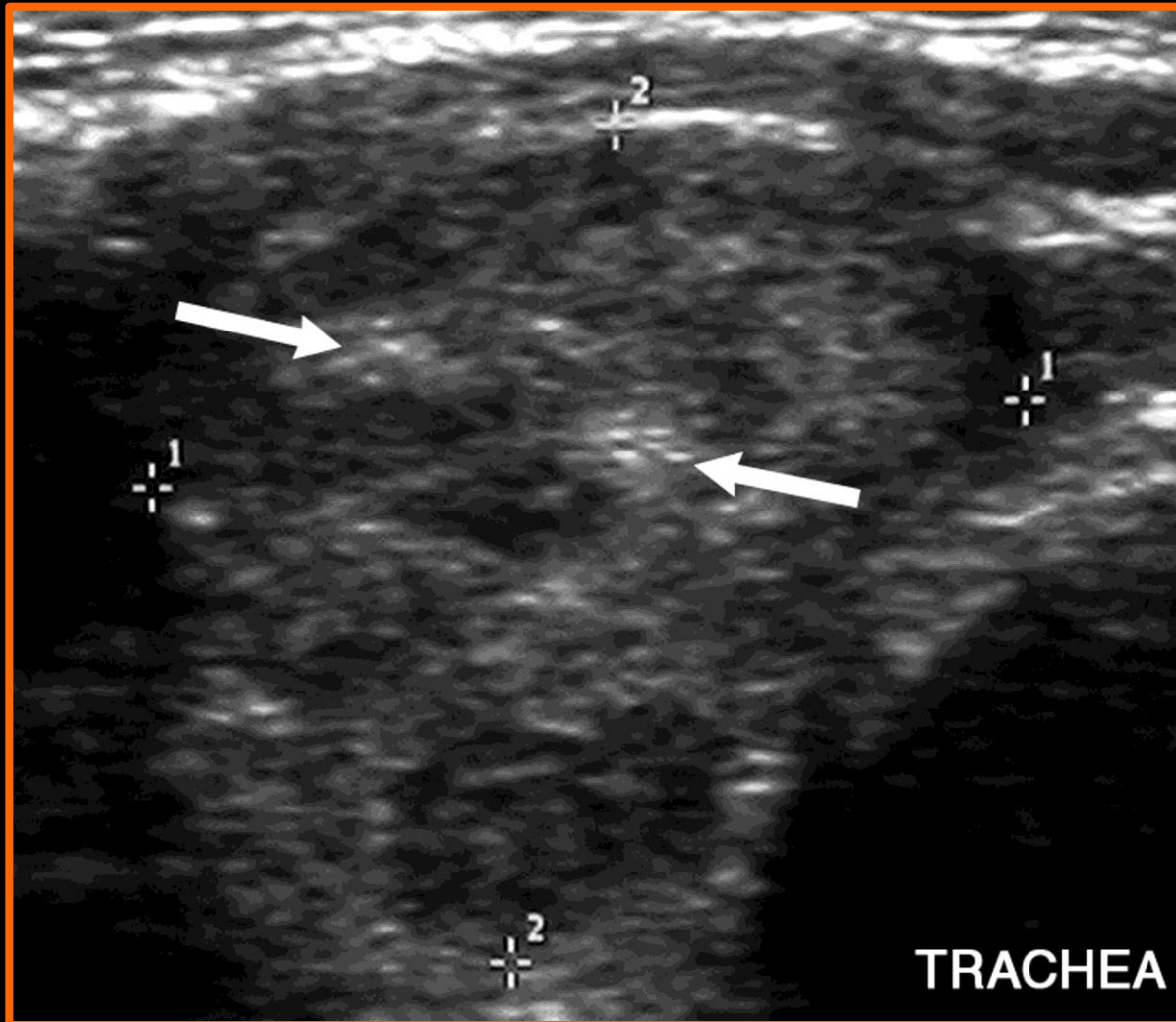
# Thyroid microcalcifications

- They are psammoma bodies, which are 10–100- $\mu\text{m}$



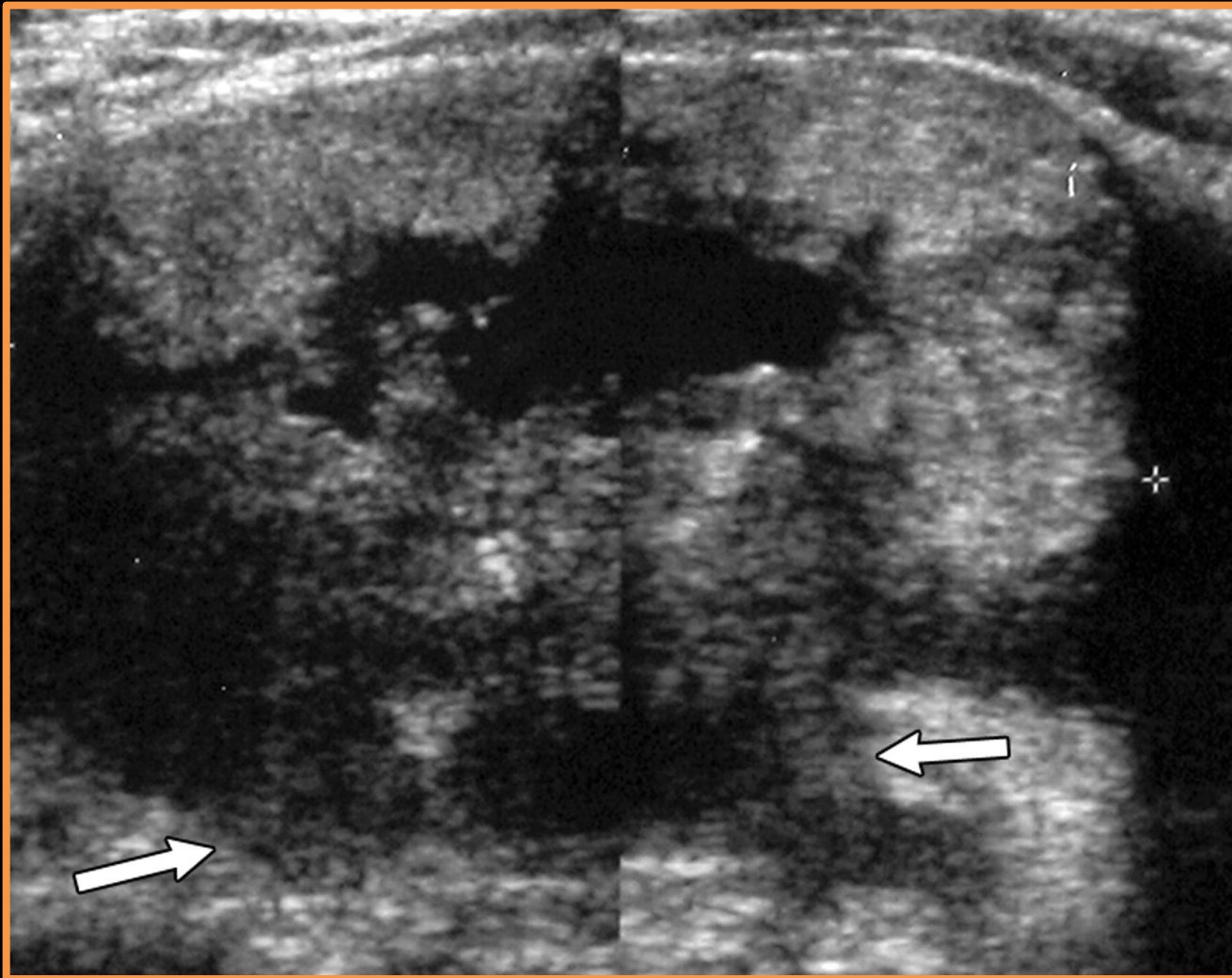


**Papillary thyroid carcinoma in a 42-year-old man.**

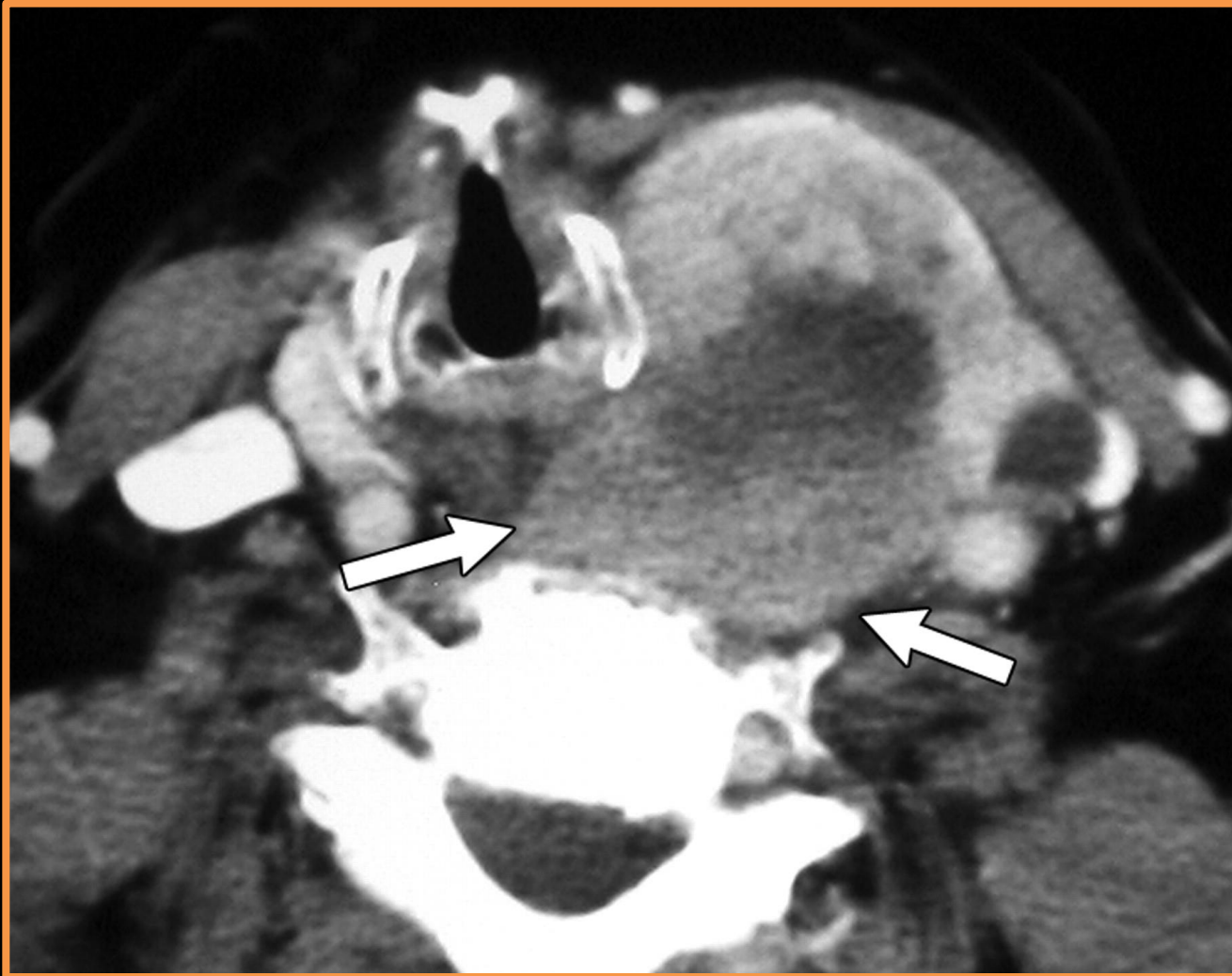




**Anaplastic thyroid carcinoma in an 84-year-old woman.**



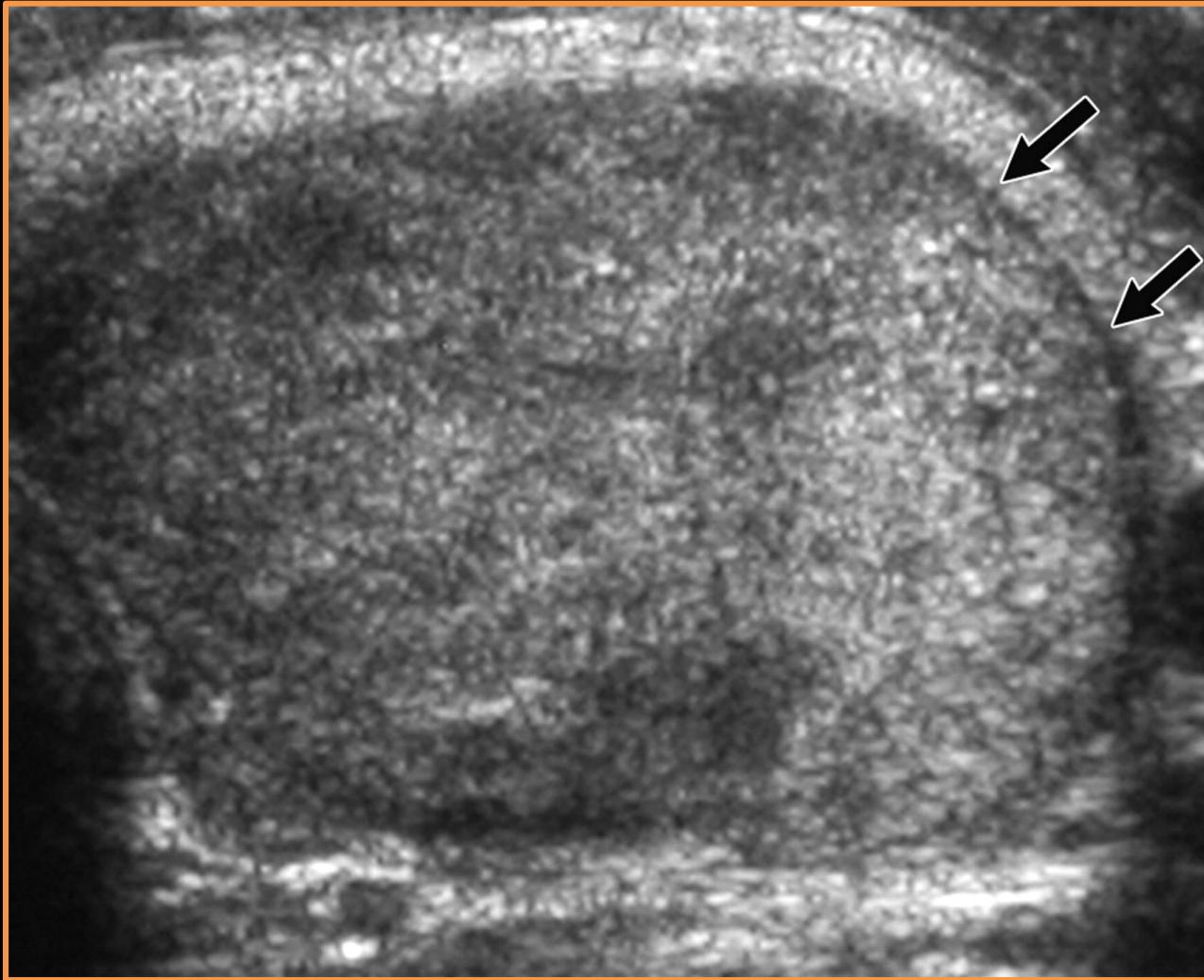
**Anaplastic thyroid carcinoma in an 84-year-old woman.**



# Margins, Contour, and Shape

- A **completely uniform halo** around a nodule is highly suggestive of **benignity**, with a specificity of 95%

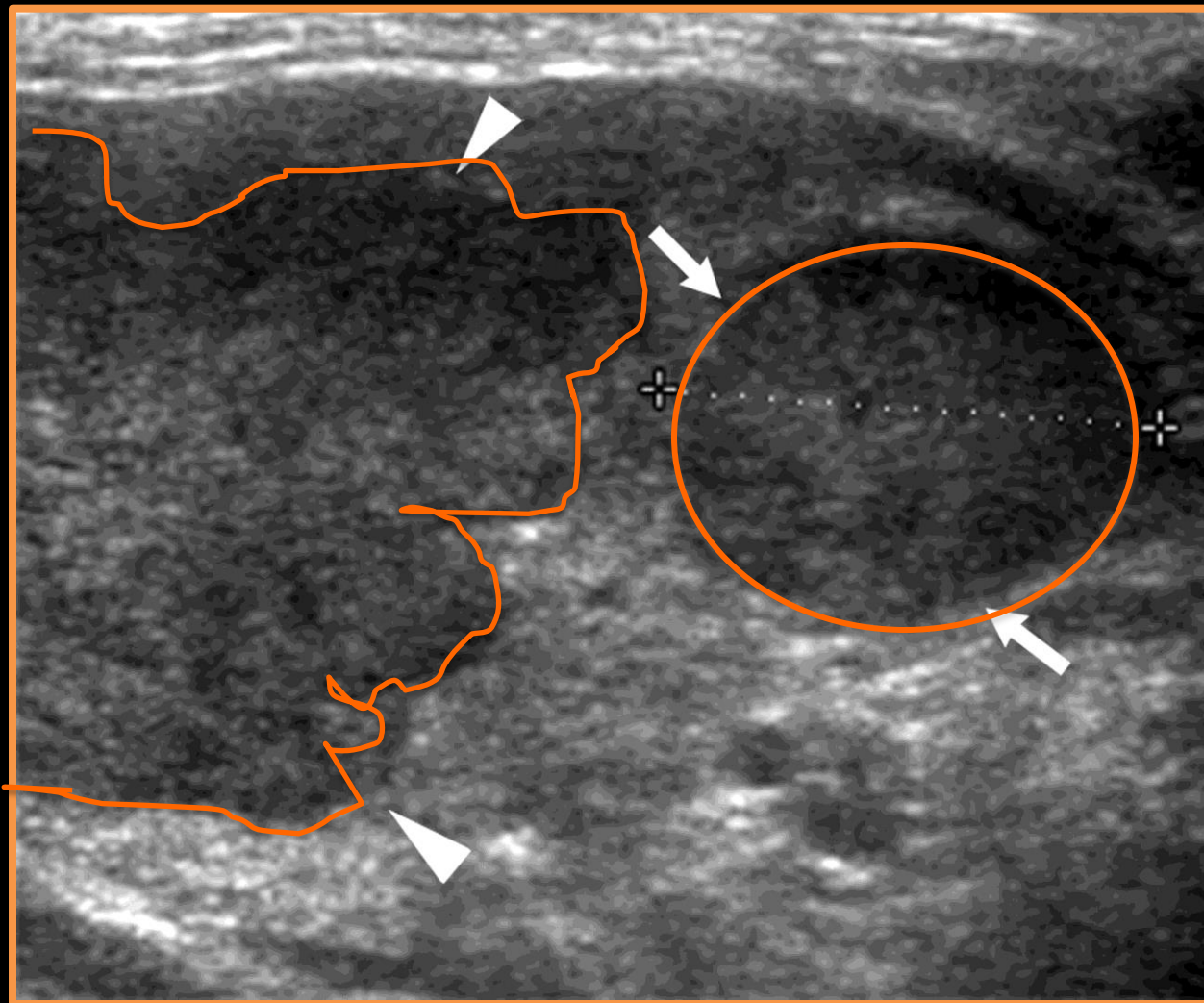
**Follicular adenoma in a 30-year-old woman.**



# Vascularity

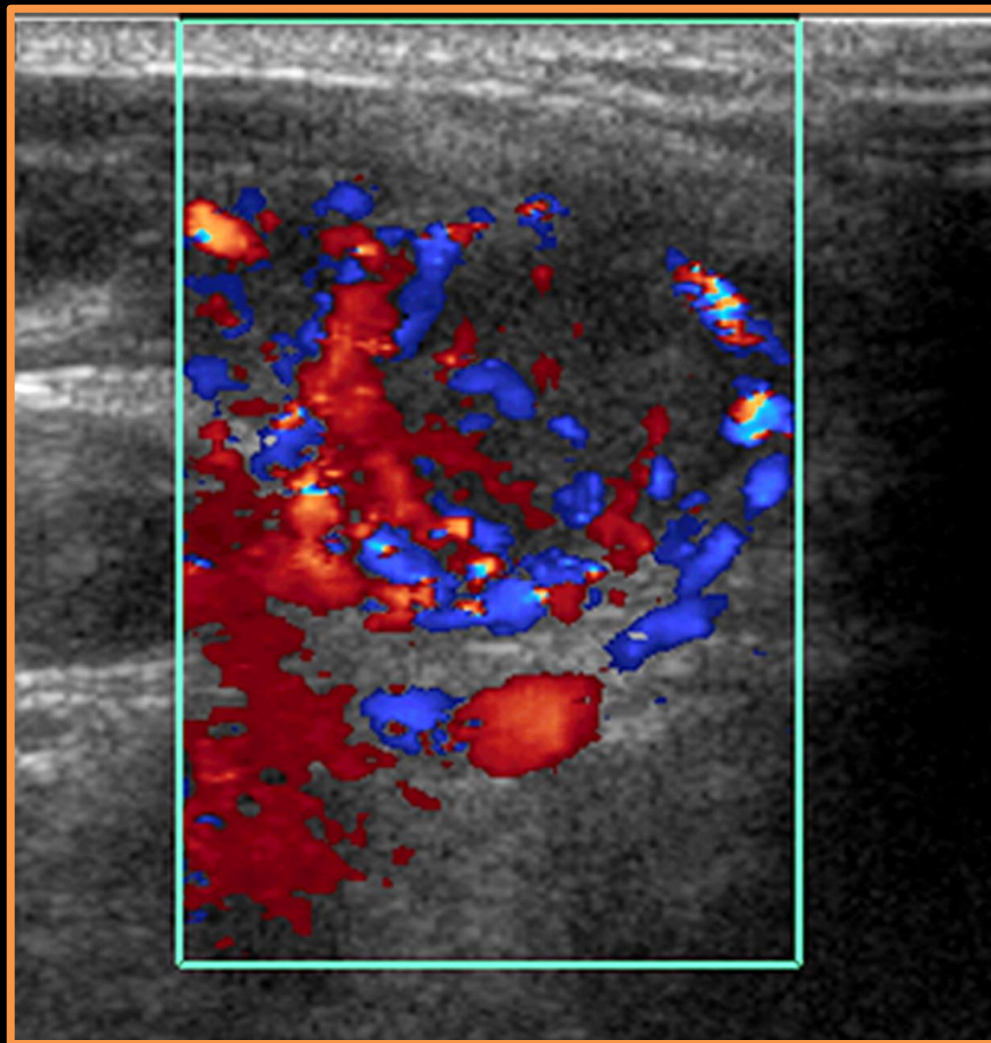
- Papillary thyroid carcinomas had some intrinsic blood flow
- Avascular nodule is very unlikely to be malignant.

**Renal cell carcinoma metastases to the thyroid in a 69-year-old woman.**

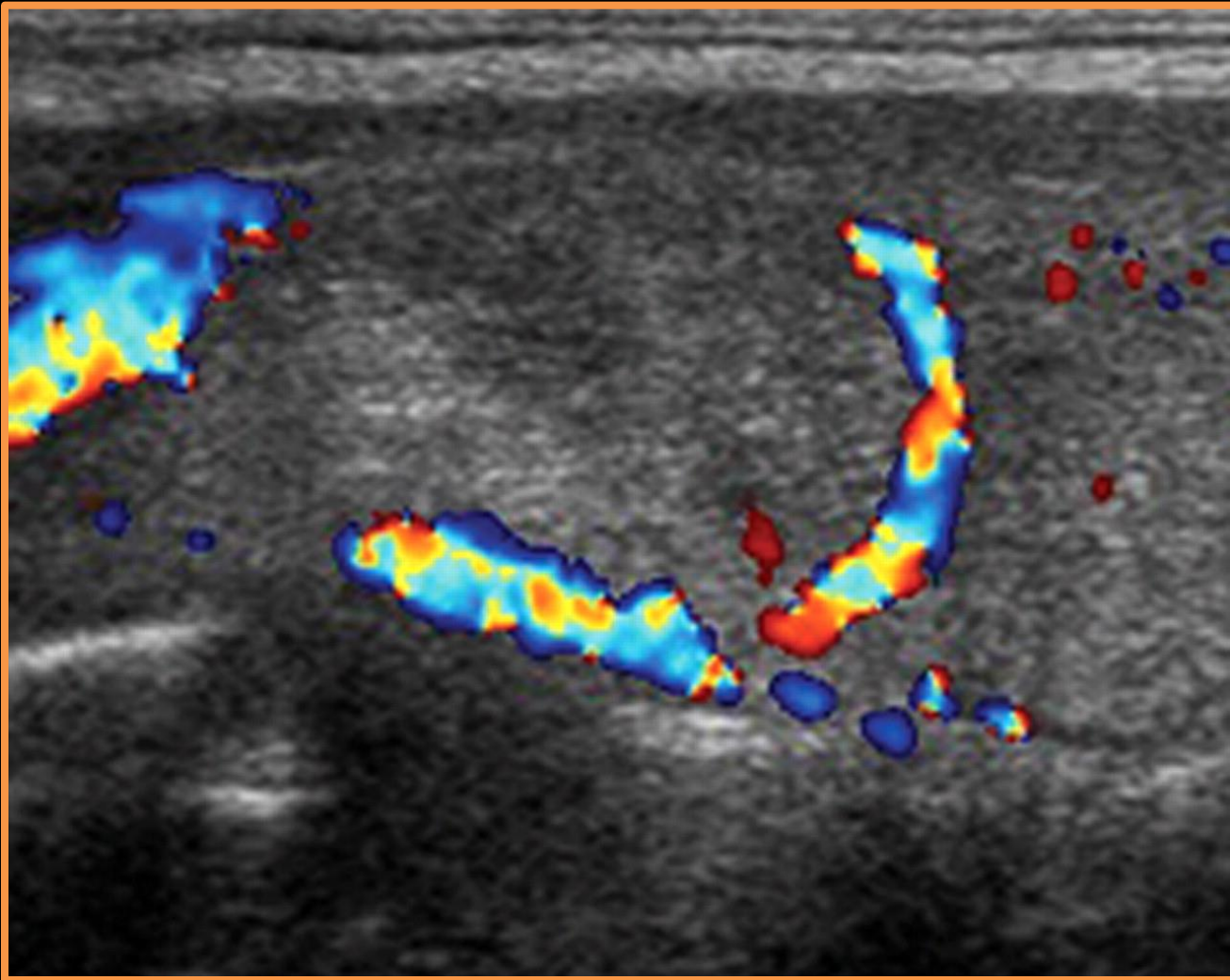




**Renal cell carcinoma metastases to the thyroid in a 69-year-old woman.**



**Follicular adenoma in a 36-year-old woman.**

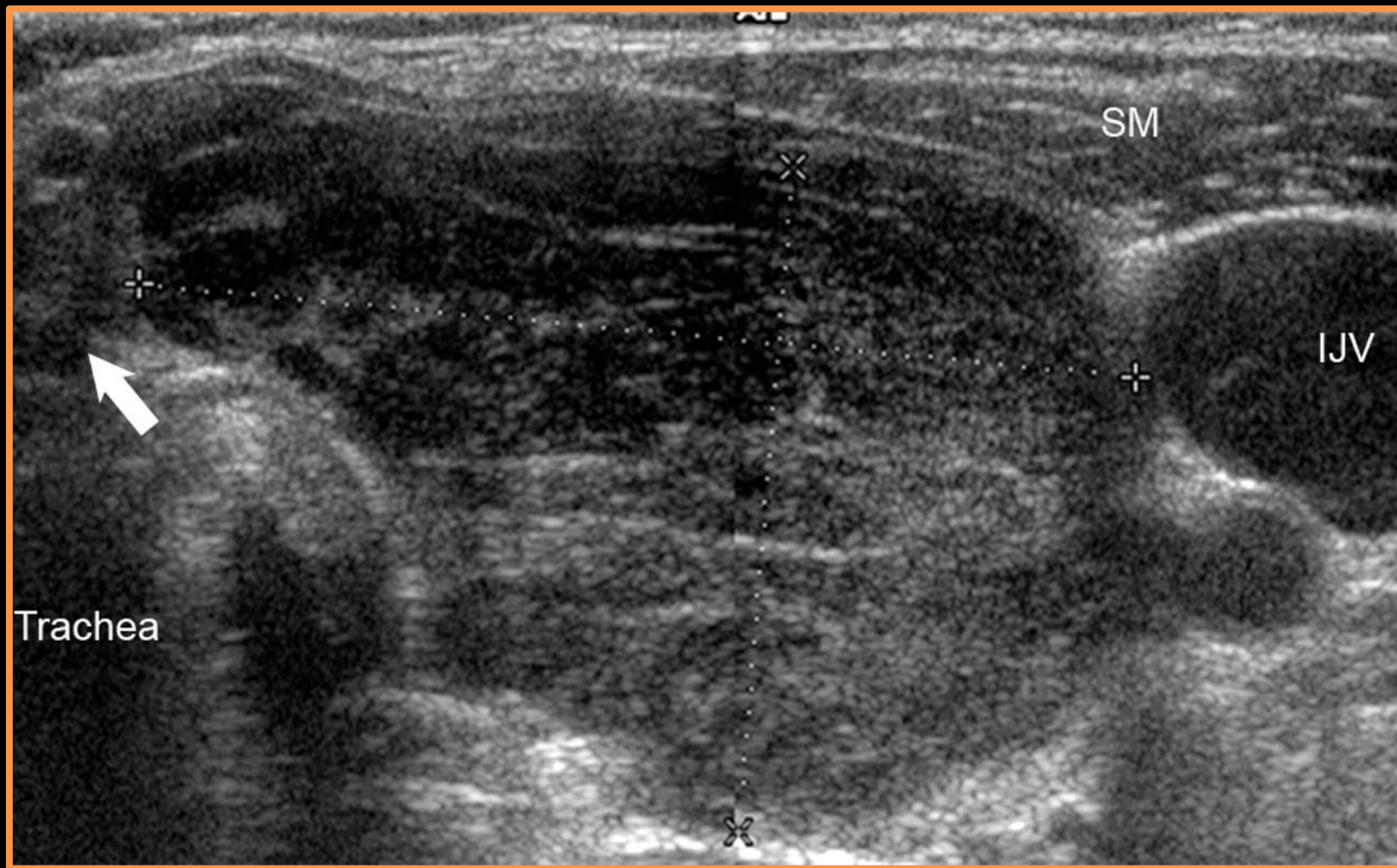



# Hypoechoic Solid Nodule

- Marked hypoechogenicity is very suggestive of malignancy.

**B cell lymphoma of the thyroid in a 73-year-old woman with Hashimoto thyroiditis.**



# Nonspecific US Features

- The size of a nodule is not helpful for predicting or excluding malignancy.
- There is a common but mistaken practice of selecting the largest nodule in a multinodular thyroid for FNA.

# Interval Growth of a Nodule

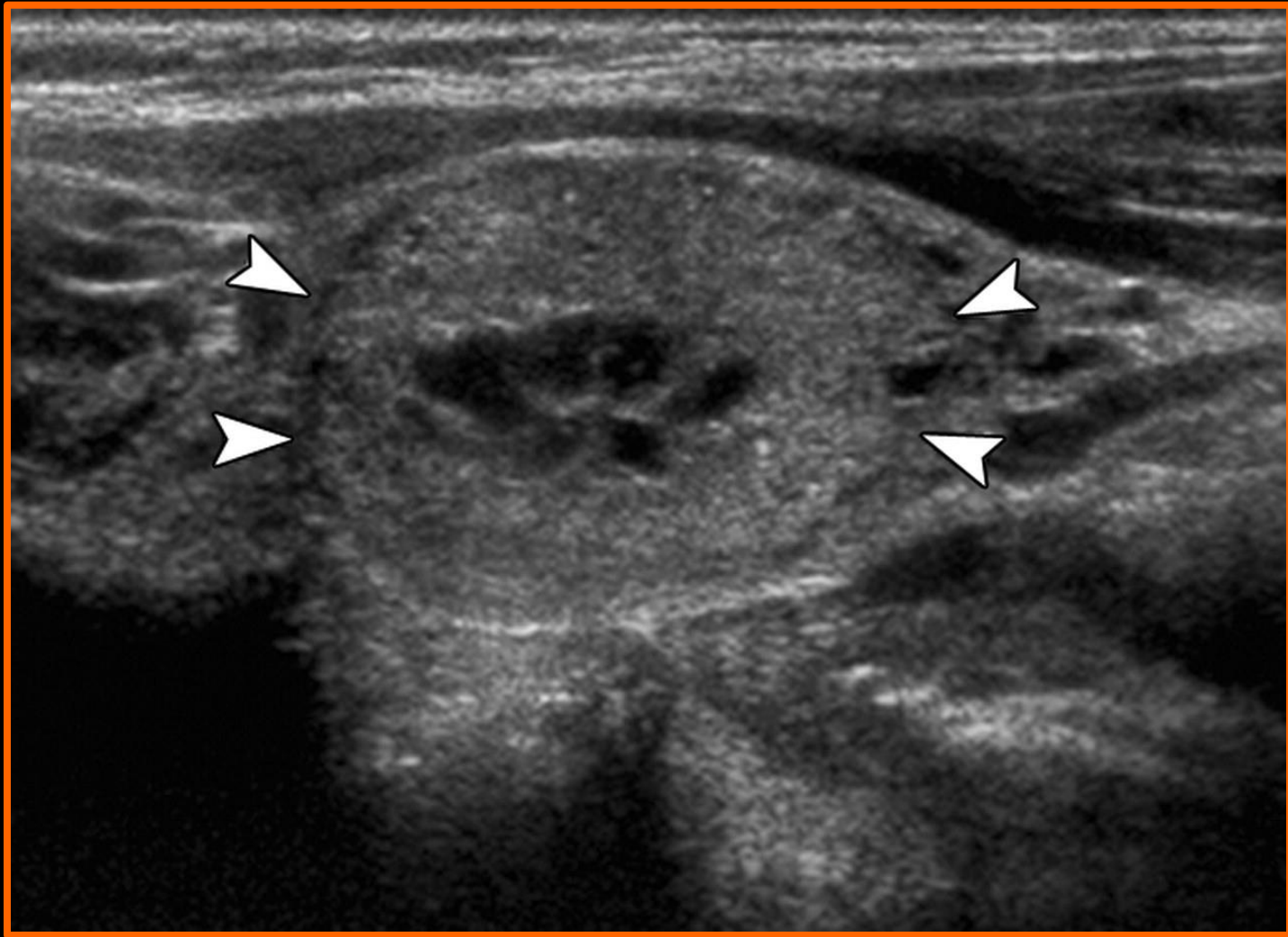
- In general, interval growth of a thyroid nodule is a **poor indicator of malignancy**. Benign thyroid nodules may change in size and appearance over time.
- The exception is clinically detectable **rapid interval growth**, which most commonly occurs in anaplastic thyroid carcinoma but also may occur in lymphoma, sarcoma, and, occasionally, high-grade carcinoma.

# Recommendations for Thyroid Nodules 1 cm or Larger in Maximum Diameter

US Feature	Recommendation
Solitary nodule	
Microcalcifications	Strongly consider US-guided FNA if $\geq 1$ cm
Solid (or almost entirely solid) or coarse calcifications	Strongly consider US-guided FNA if $\geq 1.5$ cm
Mixed solid and cystic or almost entirely cystic with solid mural component	Consider US-guided FNA if $\geq 2$ cm
None of the above but substantial growth since prior US examination	Consider US-guided FNA
Almost entirely cystic and none of the above and no substantial growth (or no prior US)	US-guided FNA probably unnecessary
Multiple nodules	Consider US-guided FNA of one or more nodules, with selection prioritized on basis of criteria (in order listed) for solitary nodule*

**Society of Radiologists in Ultrasound Consensus  
Conference Statement**

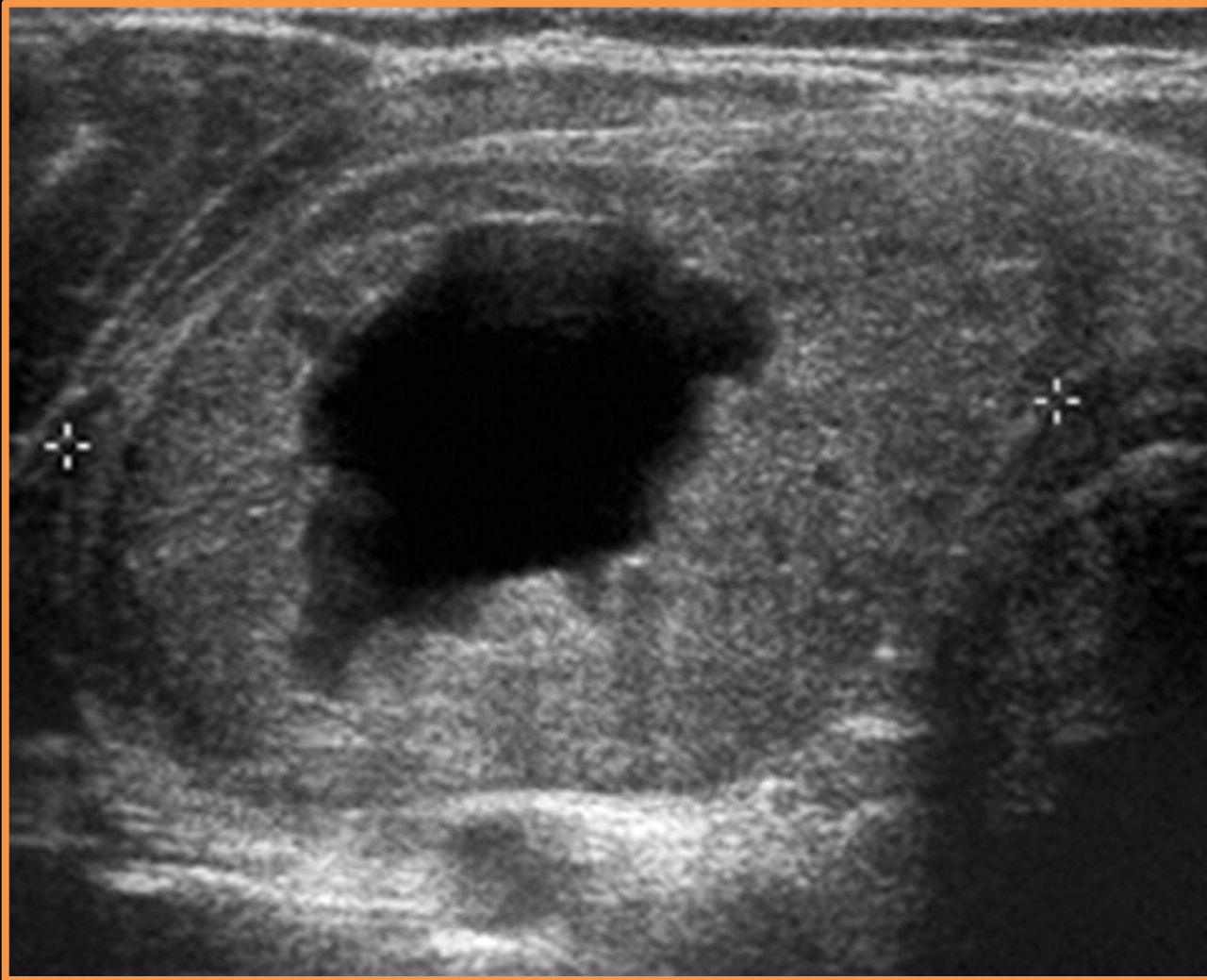
**US images of thyroid nodules of varying parenchymal composition (solid to cystic).**



Proved to be benign at cytologic examination



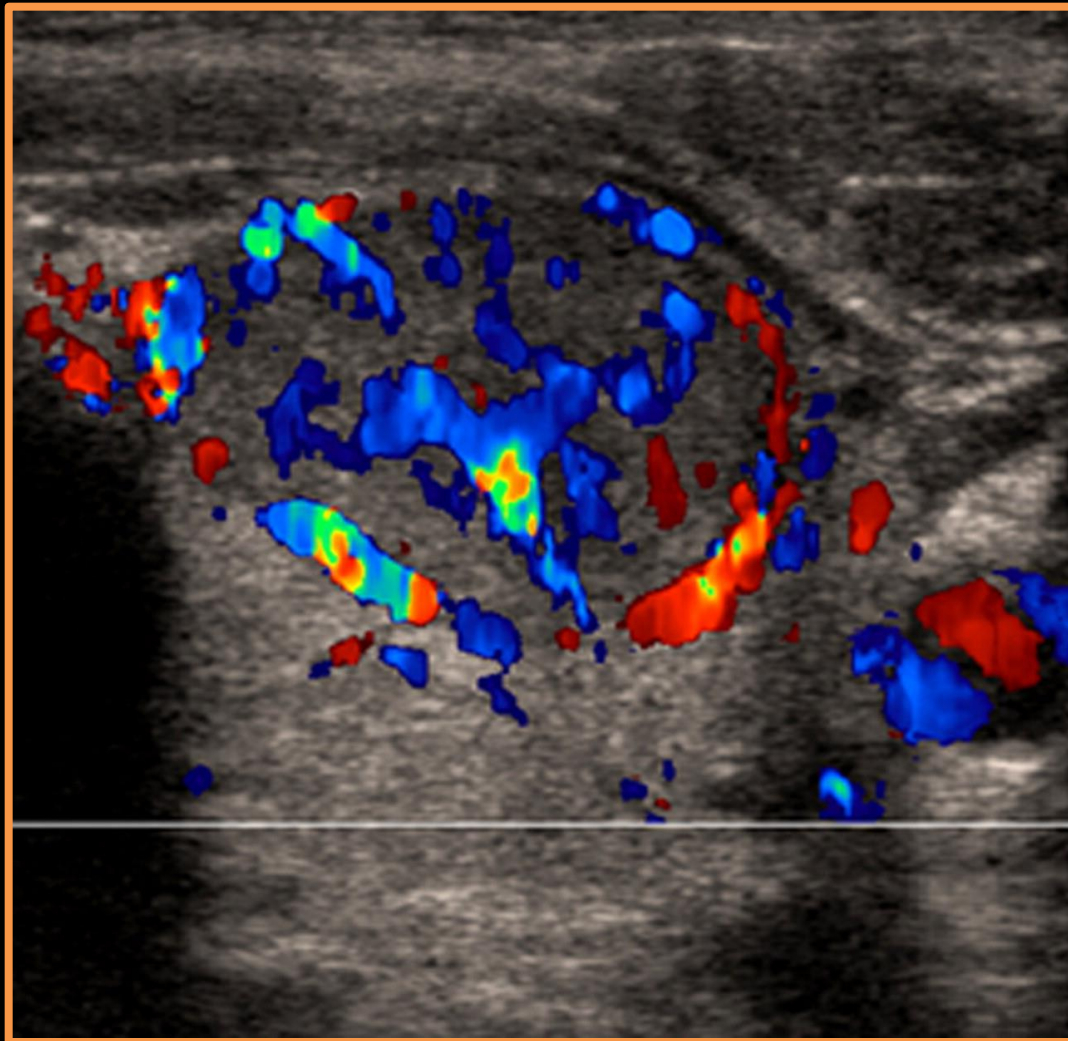
US images of thyroid nodules of varying parenchymal composition (solid to cystic).



Proved to be benign at cytologic examination

Radiology

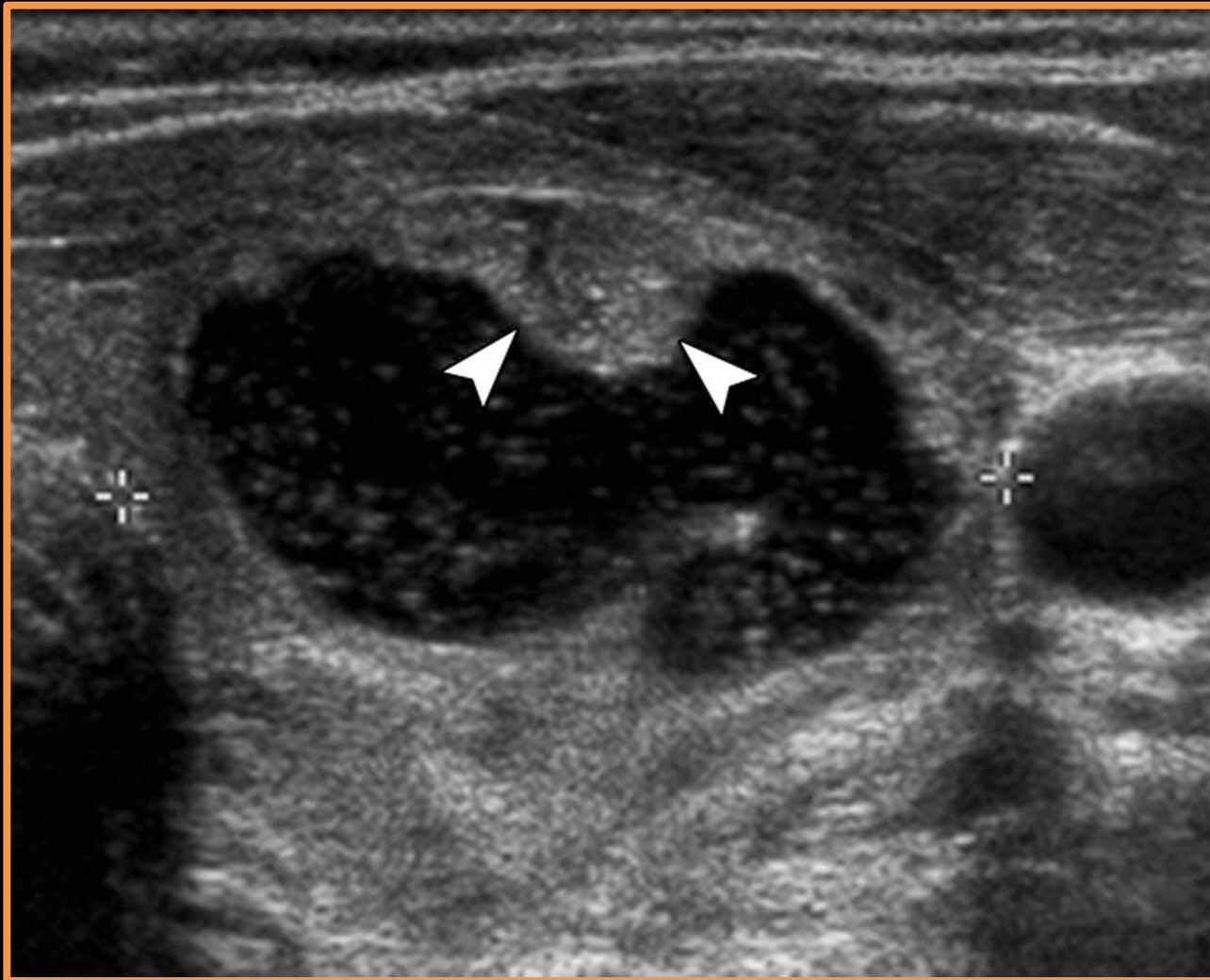
**Predominantly solid thyroid nodule.**



Papillary carcinoma



Predominantly cystic nodule with small solid-appearing mural component



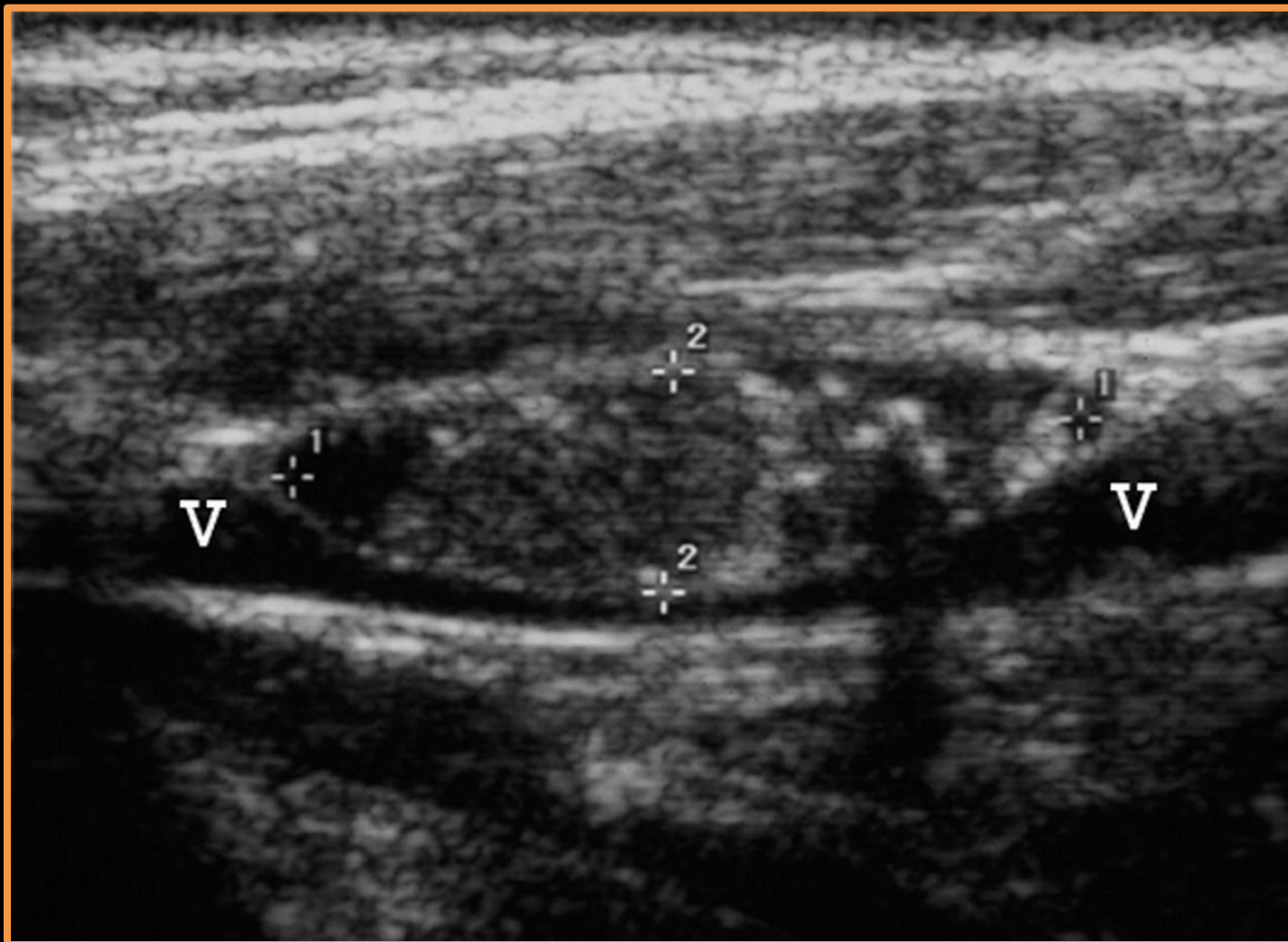
The lesion was benign at cytologic examination

Radiology

# US features of Malignant lymph nodes

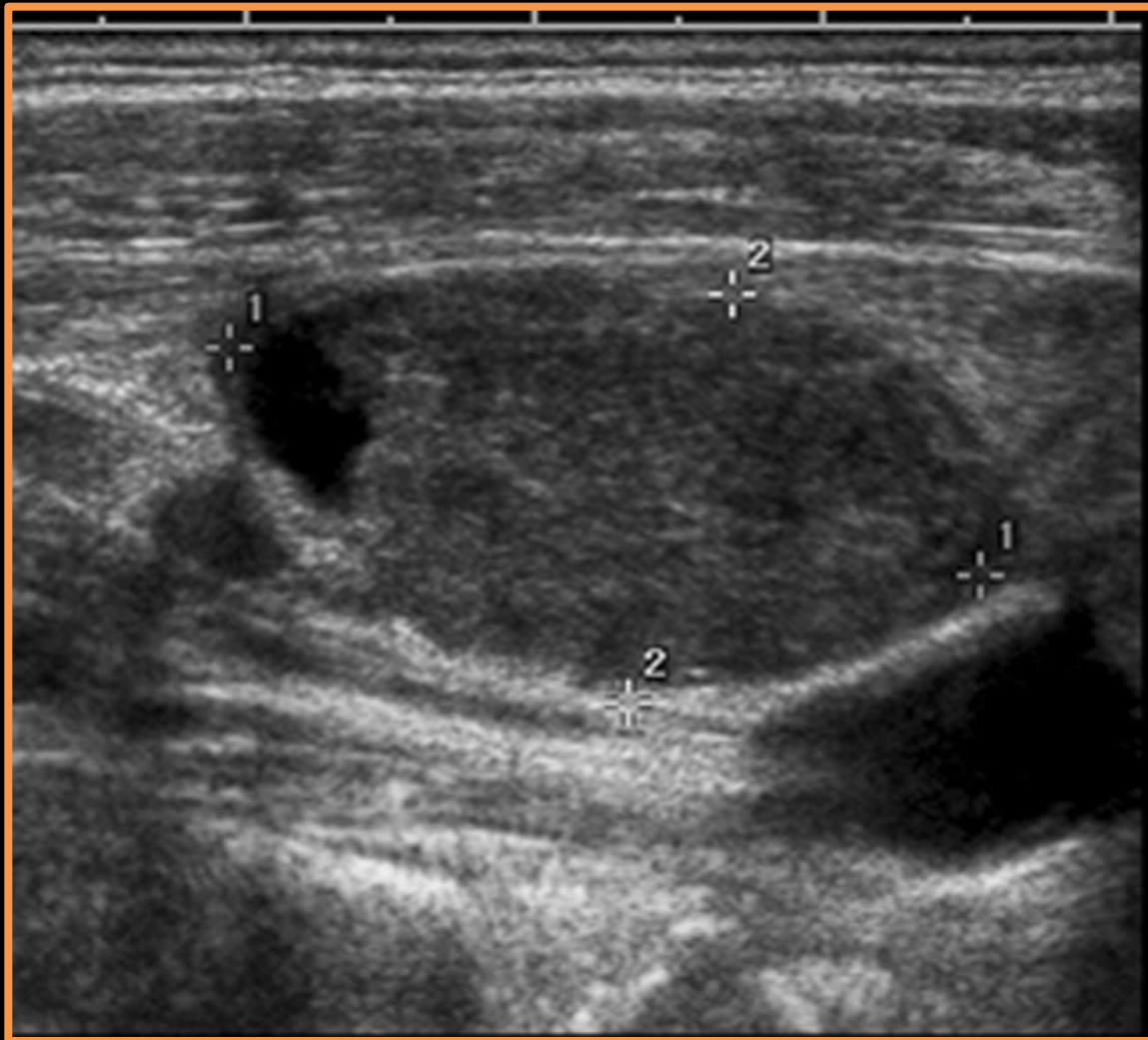- Rounded bulging shape.
- Increased size.
- Replaced fatty hilum .
- Irregular margins.
- Heterogeneous echotexture.
- Calcifications.
- Cystic areas.
- Vascularity throughout the lymph node instead of normal central hilar vessels at Doppler imaging.

## Abnormal cervical lymph nodes.



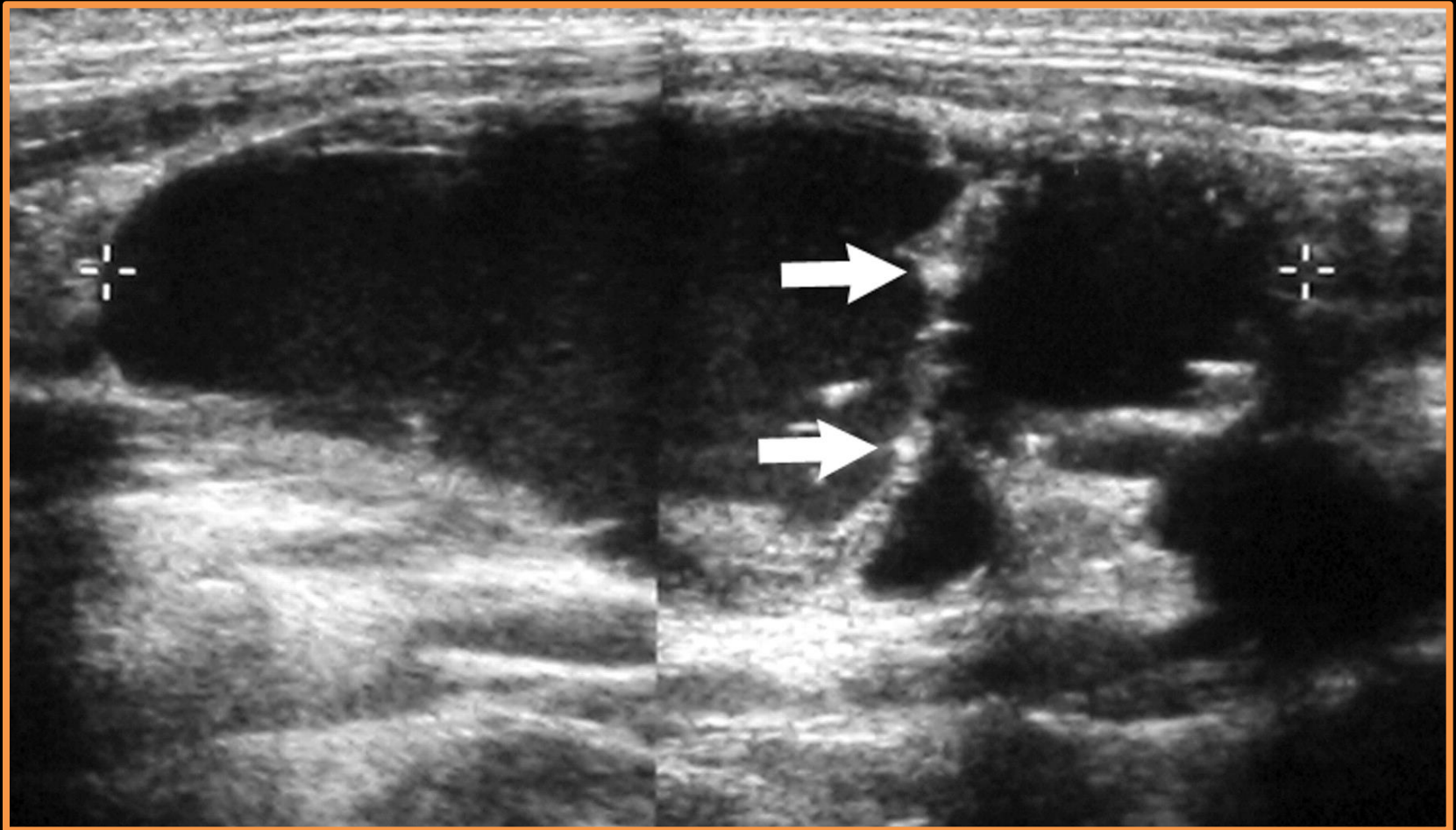
Metastatic papillary carcinoma

# Abnormal cervical lymph nodes.



Mtastatic papillary carcinoma.

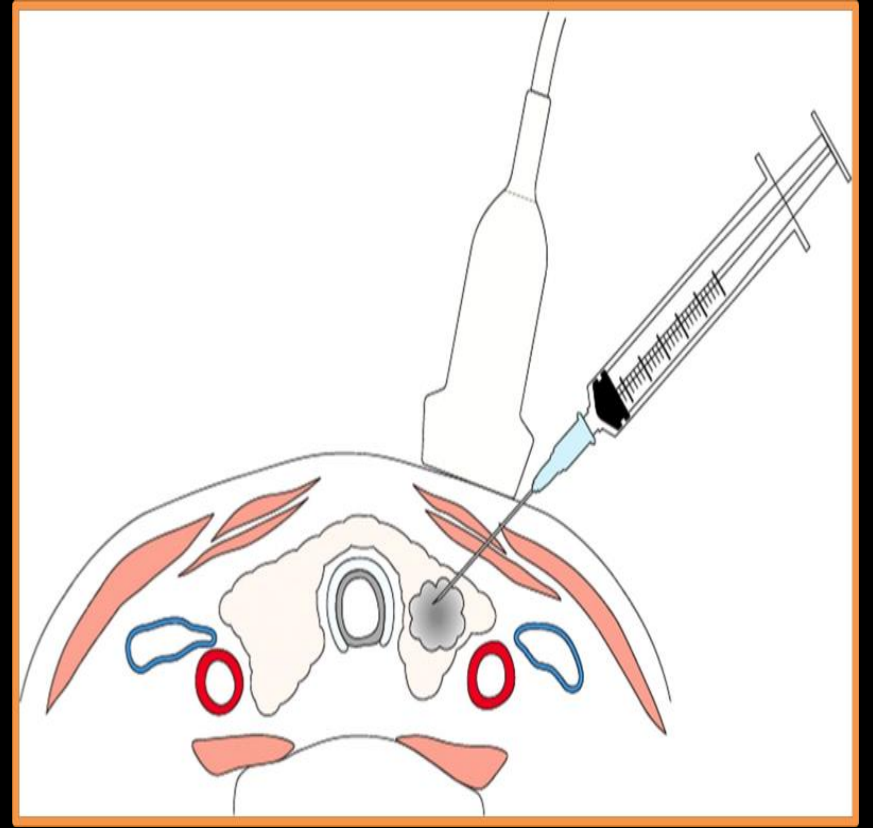
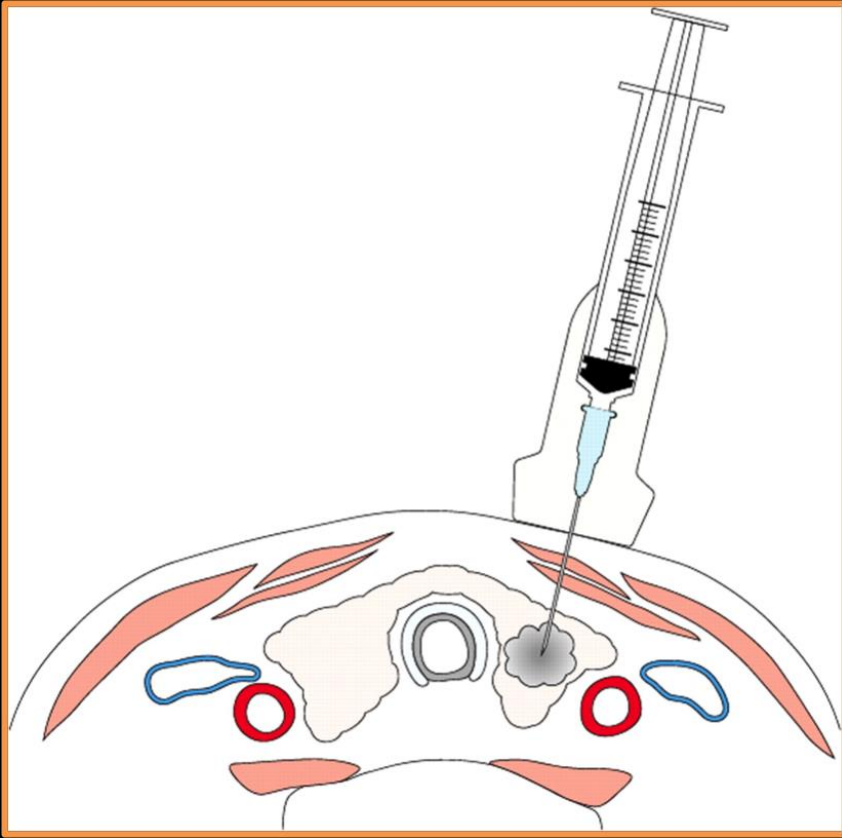
**Papillary carcinoma and cystic lymph node metastasis in a 28-year-old woman.**



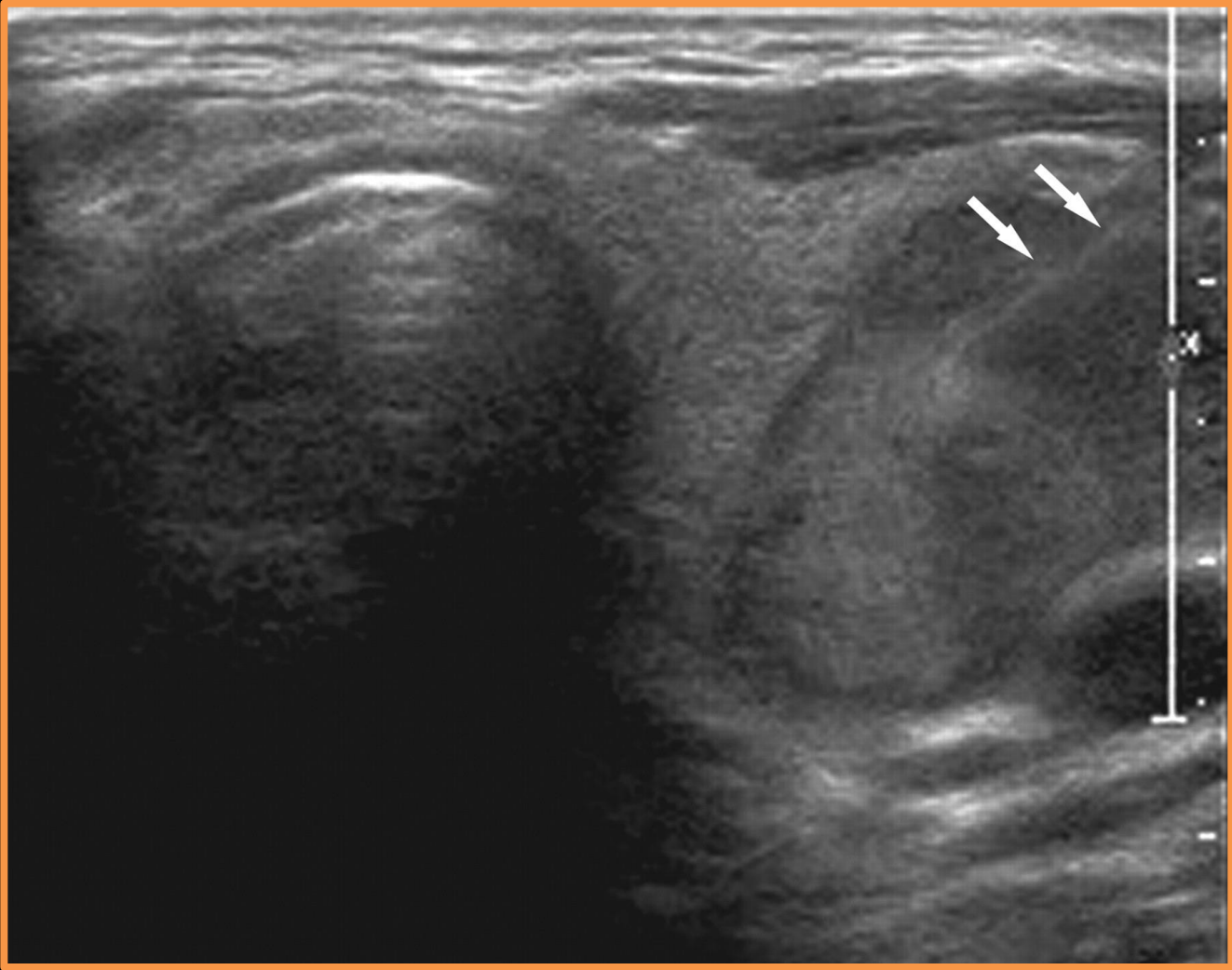
# US-guided FNA Technique

- The needle may be introduced parallel or perpendicular to the transducer, and the needle tip should be carefully monitored during the procedure.





**Parallel positioning of the fine-gauge needle for thyroid nodule biopsy.**





# Thyroid Ophthalmopathy (Graves' Disease)

## Clinical history:

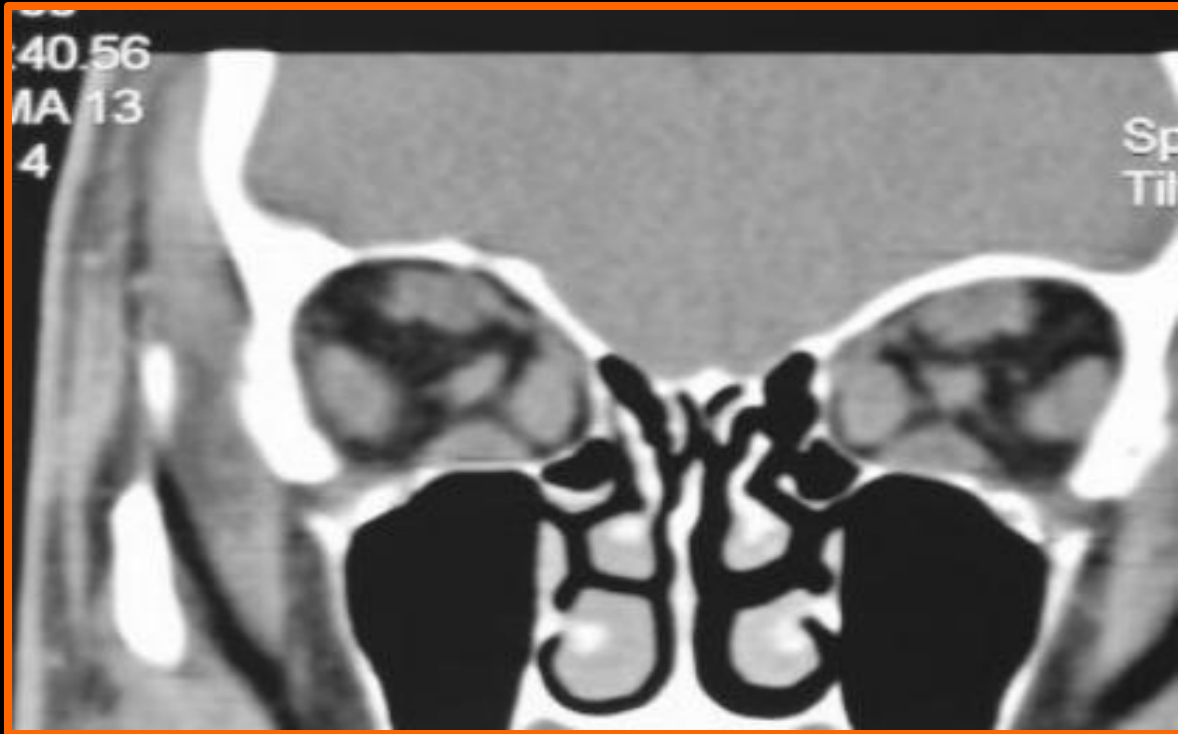
Slow onset (months), painless exophthalmos.

## Patterns of muscle involvement in thyroid ophthalmopathy:

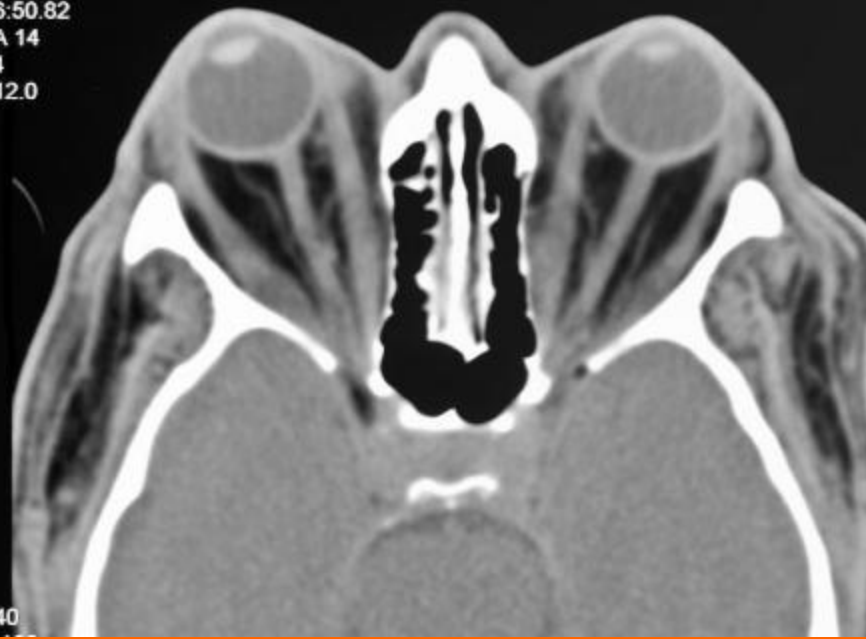1. Bilateral (85%)
2. Unilateral (5%)
3. Normal muscles (10%)

- ALL muscles involved is most common scenario of extraocular muscle enlargement.
- If only individual muscles involved, commonly **Inferior** then **Medial recti muscles**
- **Lateral rectus muscle**: last to become involved; rarely/never the only muscle involved
- **! I'M SLOW** ( **I**nferior, **M**edial, **S**uperior , **L**ateral)
- Muscle enlargement characteristically involves the body of the muscle, sparing the tendinous attachment to the globe.

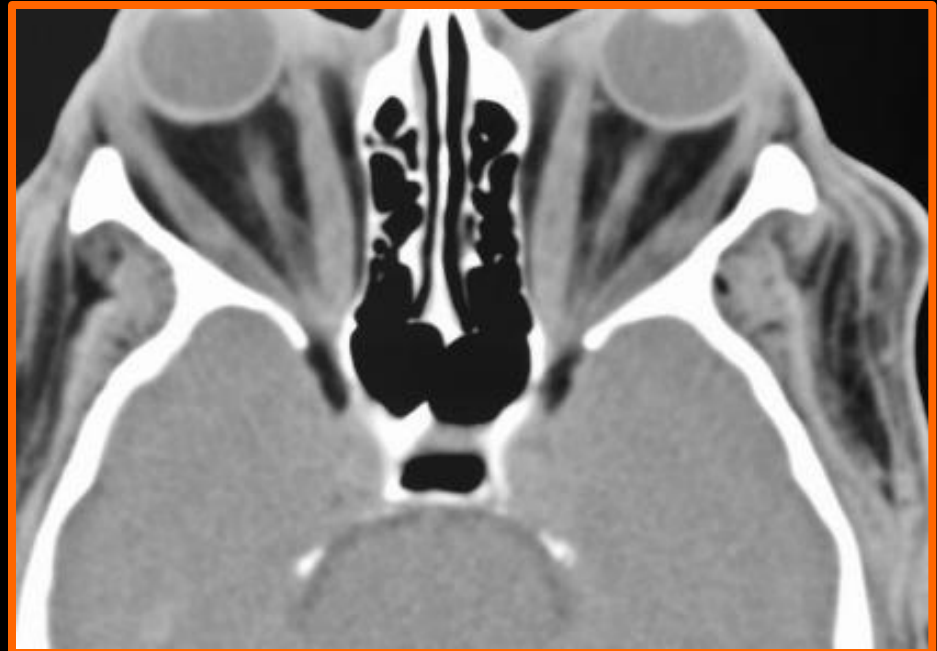- Patients need not be hyperthyroid (some are euthyroid).
- **Coronal imaging** is the method of choice for assessing muscle thickness



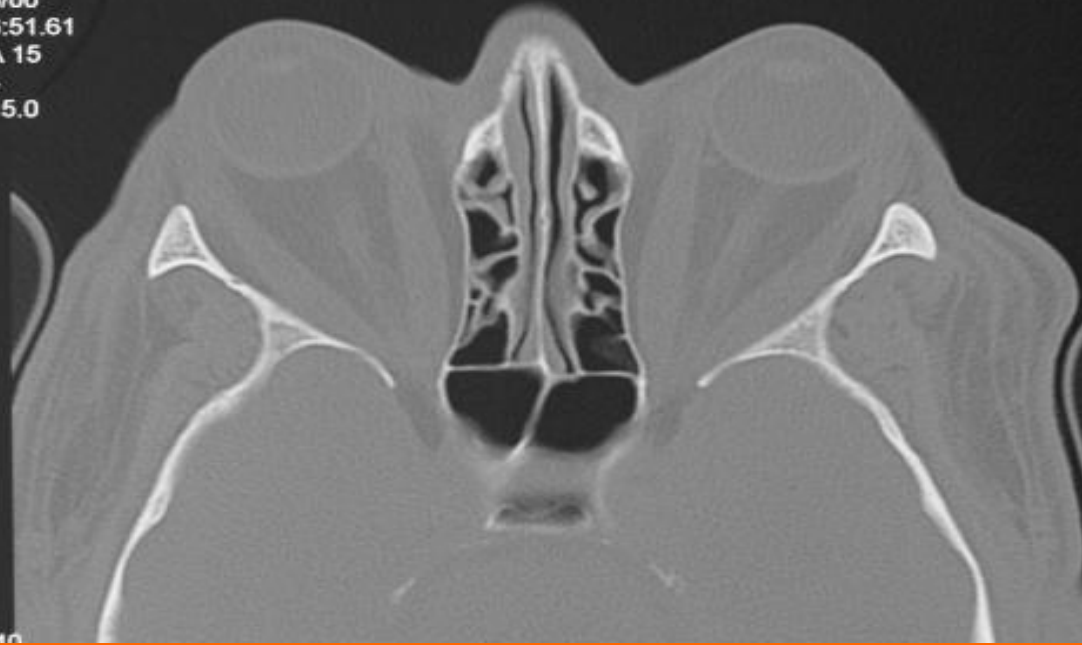:56:50.82  
MA 14  
PI 4  
P -12.0



140



V00  
:51.61  
15  
5.0

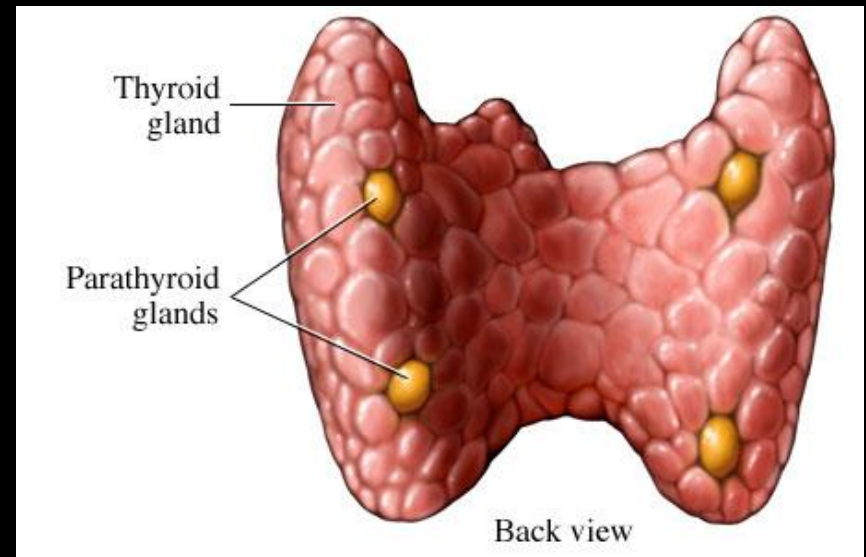


140

# Parathyroid Gland

# Anatomy of the Parathyroid Gland

- Two pairs of glands usually positioned behind the left and right lobes of the thyroid.
- Typically 4 parathyroid glands (Superior and Inferior ) parathyroid glands.



# Renal Osteodystrophy

- Seen in setting of chronic, end-stage renal disease.
- Related to combination of :
  1. **Osteomalacia.**
  2. **Secondary hyperparathyroidism**

Bone resorption mainly (Sub-periosteal)

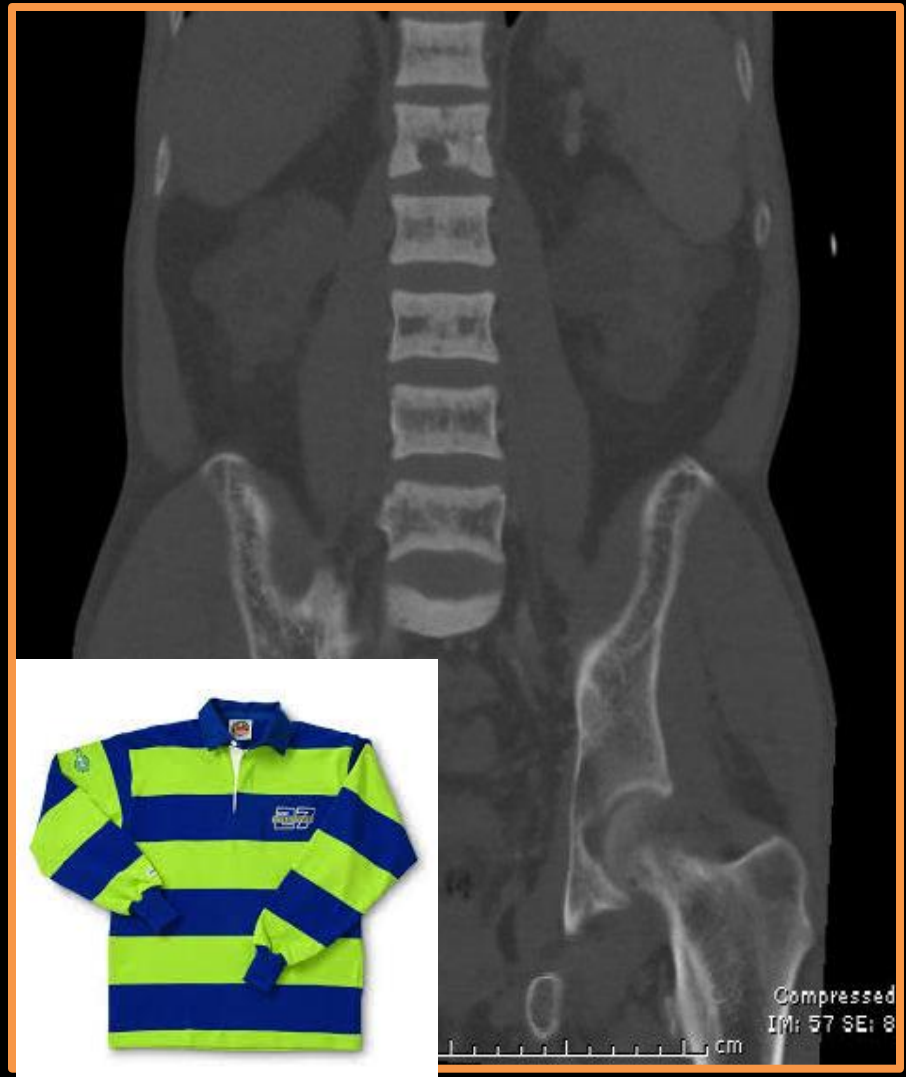
Cortical thinning.

Soft tissue and vascular calcifications

Osteosclerosis

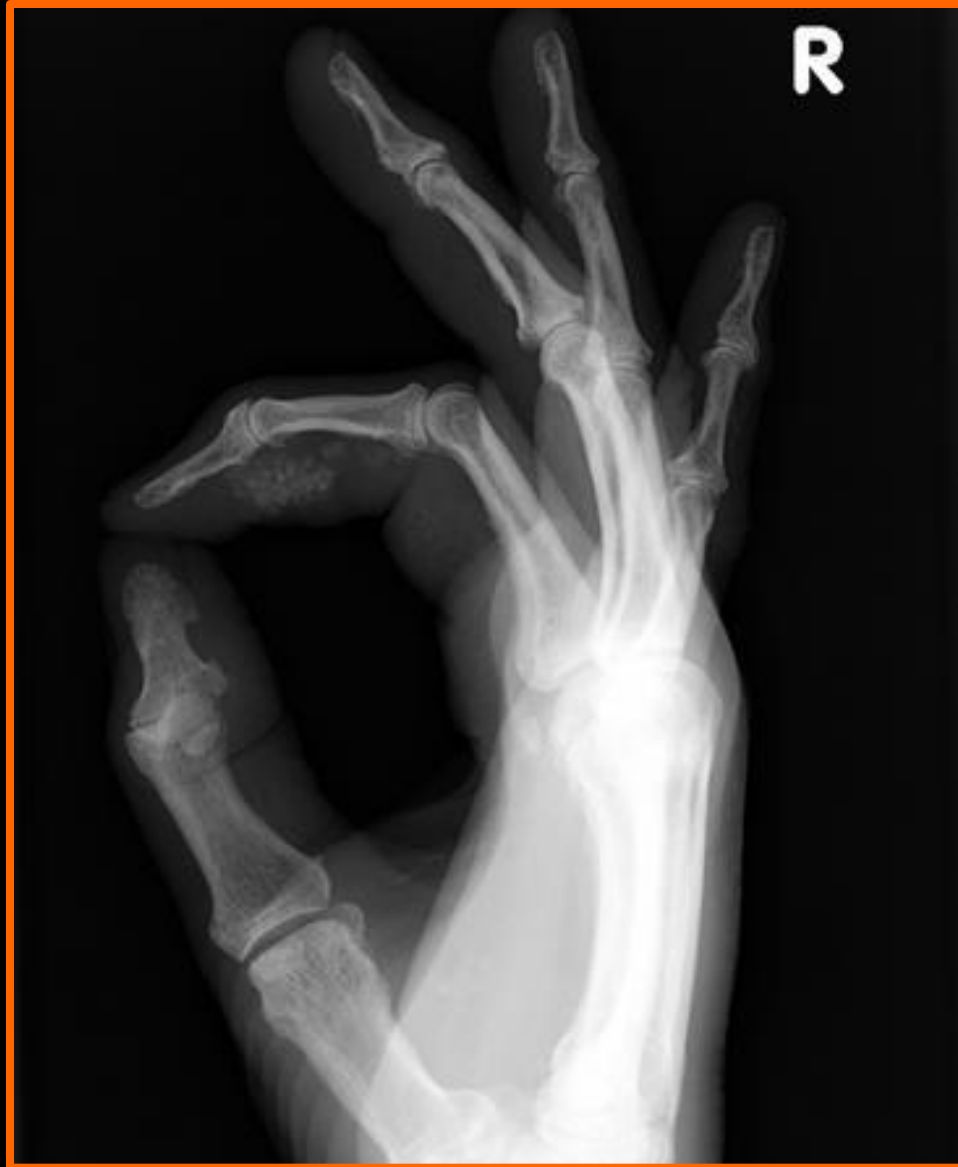Brown tumors.

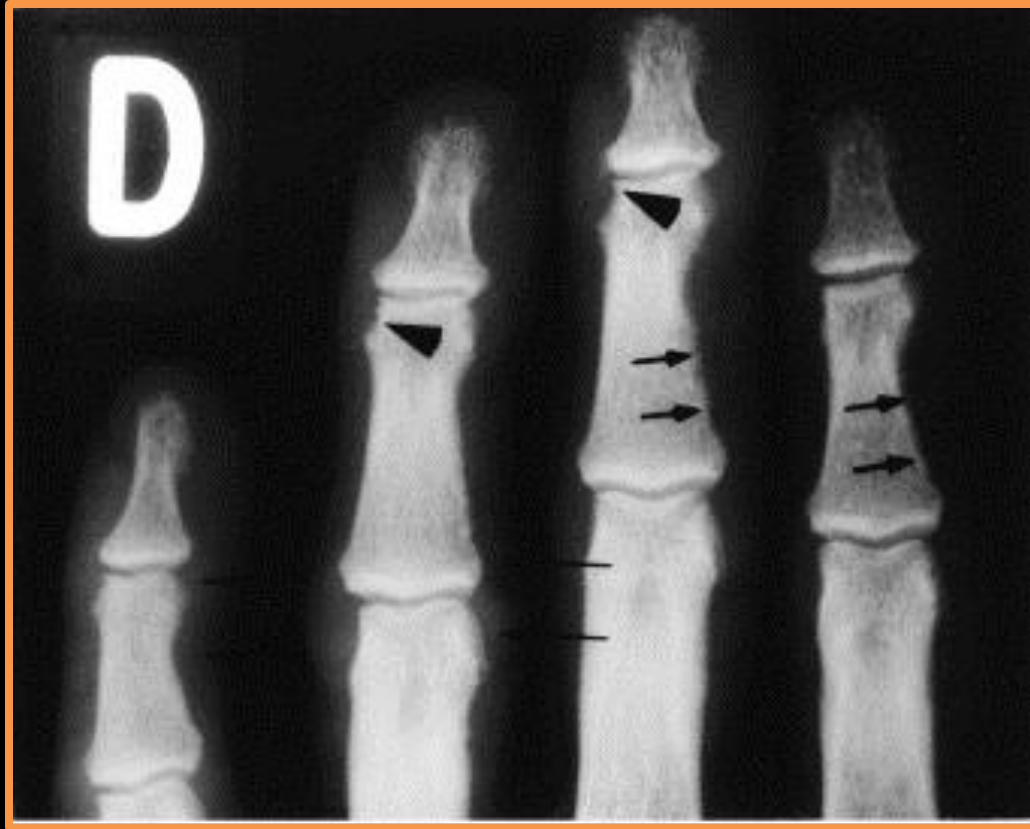- **Osteopenia** is most common finding; however, 10-20% of patients also exhibit osteosclerosis.
- Characteristic finding of osteosclerosis is **"Rugger jersey spine"**  
Bands of hazy sclerosis that parallels the vertebral body endplates



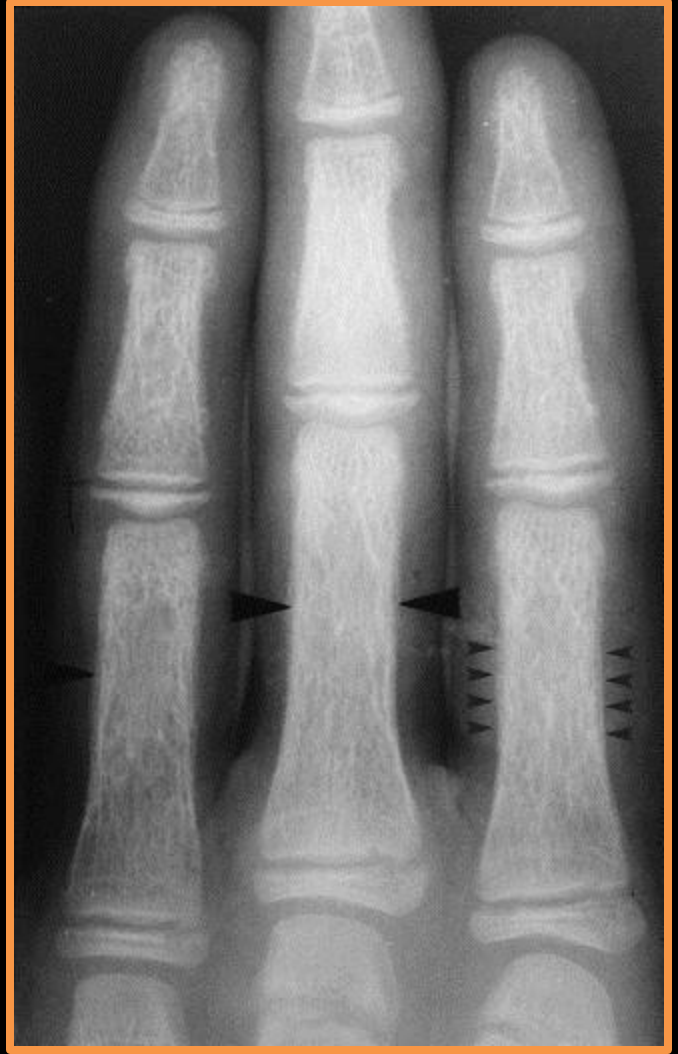
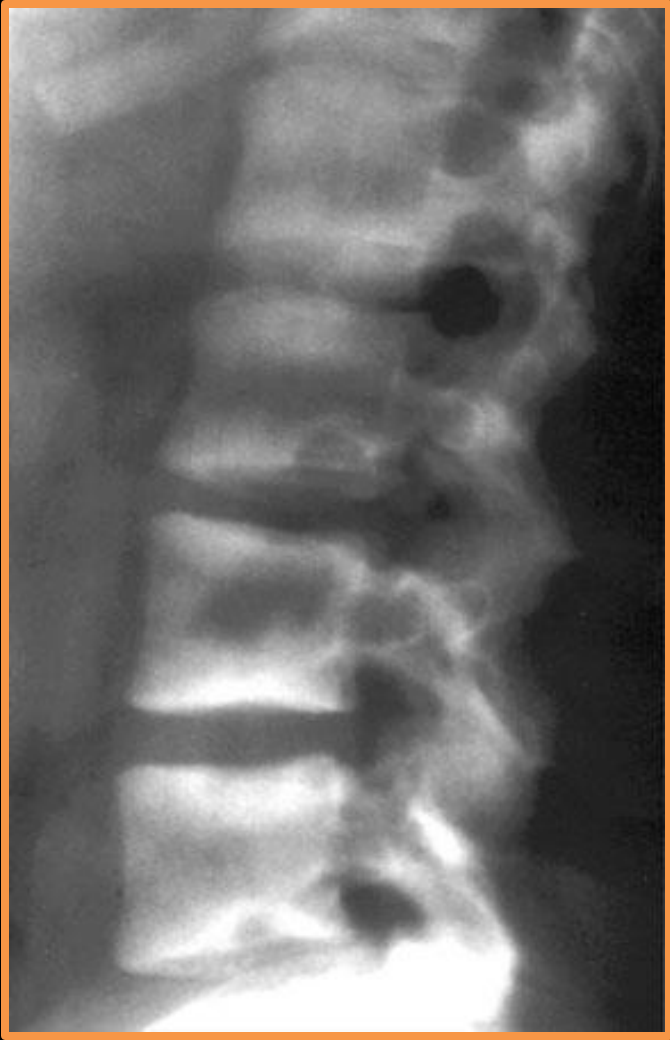
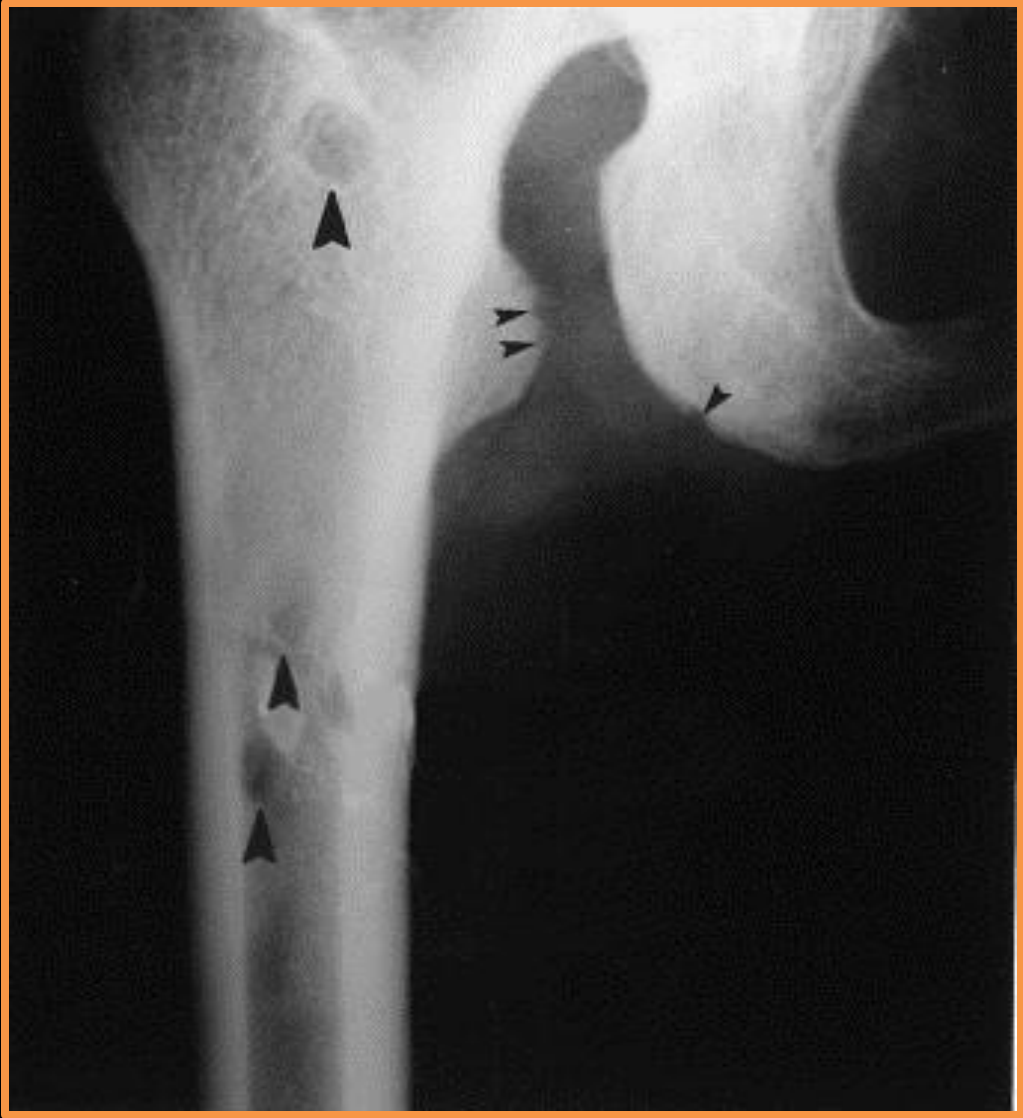- Both axial and appendicular skeleton involved.
- Increased risk for pathologic fracture.





Typical subperiosteal bone resorption at the radial aspects of the middle phalanges with bone resorption at the margins of the distal interphalangeal joints.





Question?