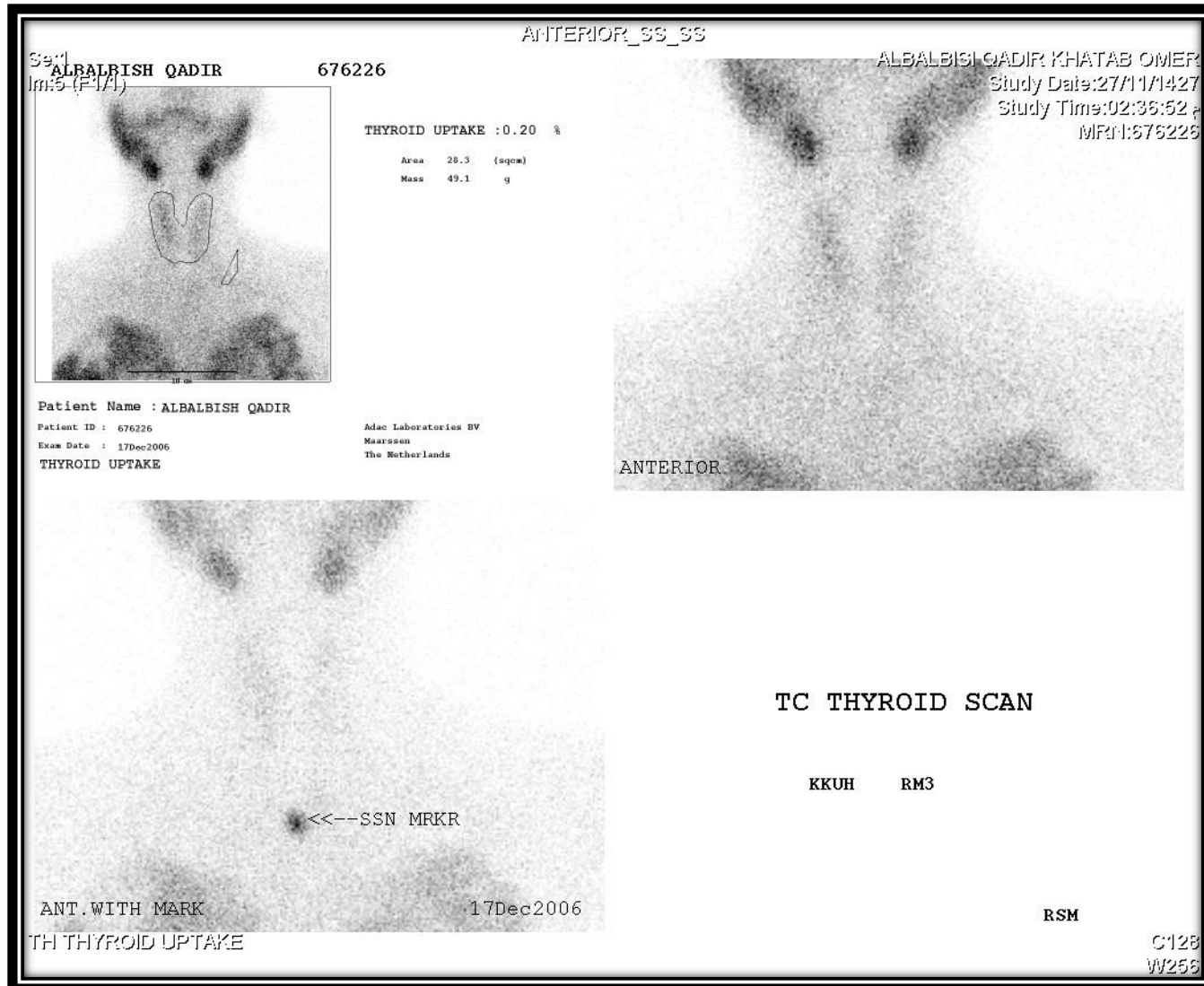


RAD 366

NUCLEAR MEDICINE

2018

Elevated T4 and suppressed TSH



Elevated T4 and suppressed TSH



Se:1
Im:9 (F1/1)
SALHA ALSHAHRANI

ALSHAHRANI SALHA SAAD ABDULLAH
Study Date: 09/08/1426
Study Time: 09:57
MFI: 793268

793268

THYROID UPTAKE : 24.13 %

Area	0.0	(sqcm)
Mass	0.0	g




10 cm

10 cm

Thyroid

Patient Name : SALHA ALSHAHRANI
Patient ID : 793268
Exam Date : 12Sep2005
THYROID UPTAKE

Adac Laboratories BV
Maarsse
The Netherlands



<-MARKER

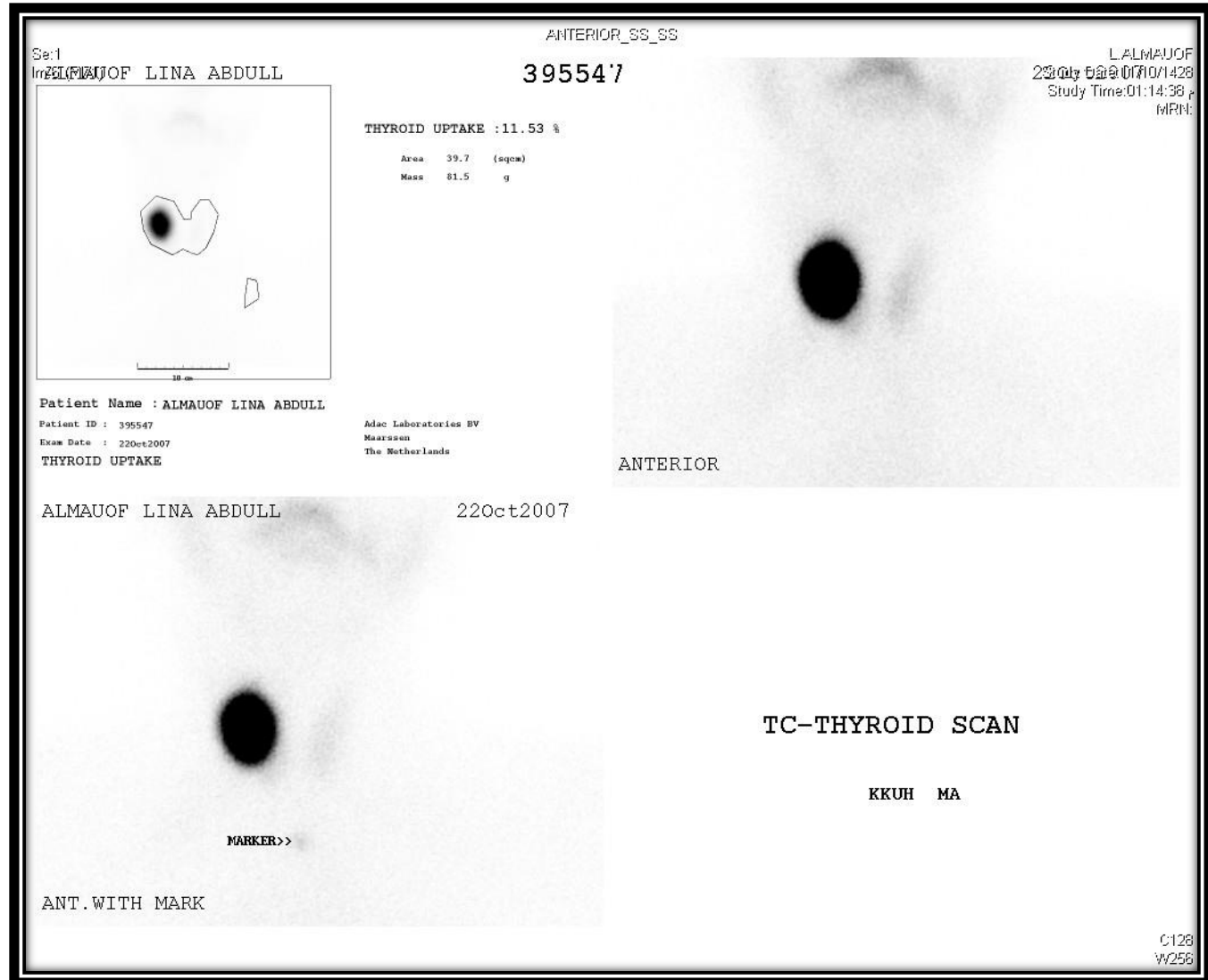
TC THYROID UPTAKE

KKUH HS

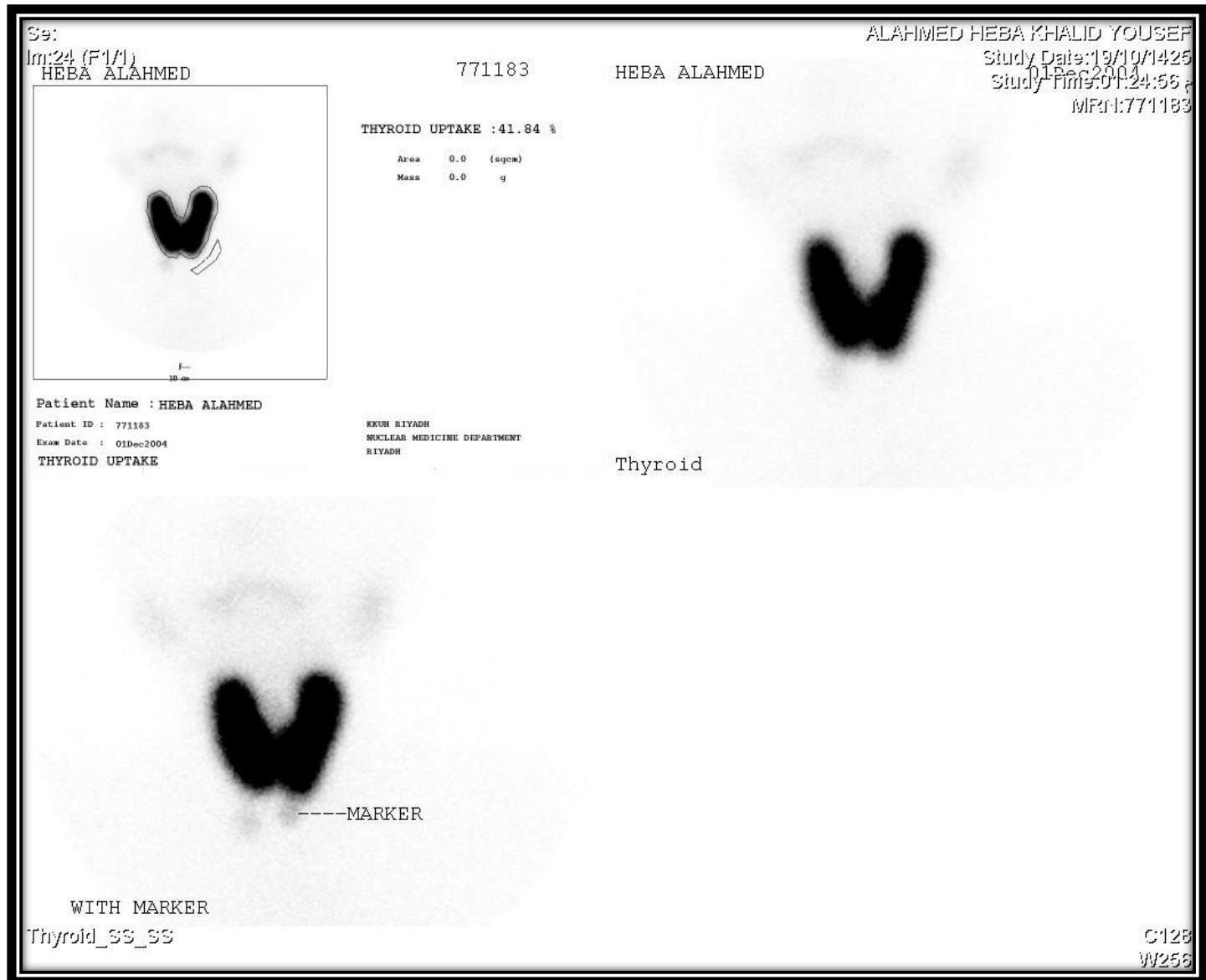
ANT THYROID
Thyroid_SS_SS

C128
W256

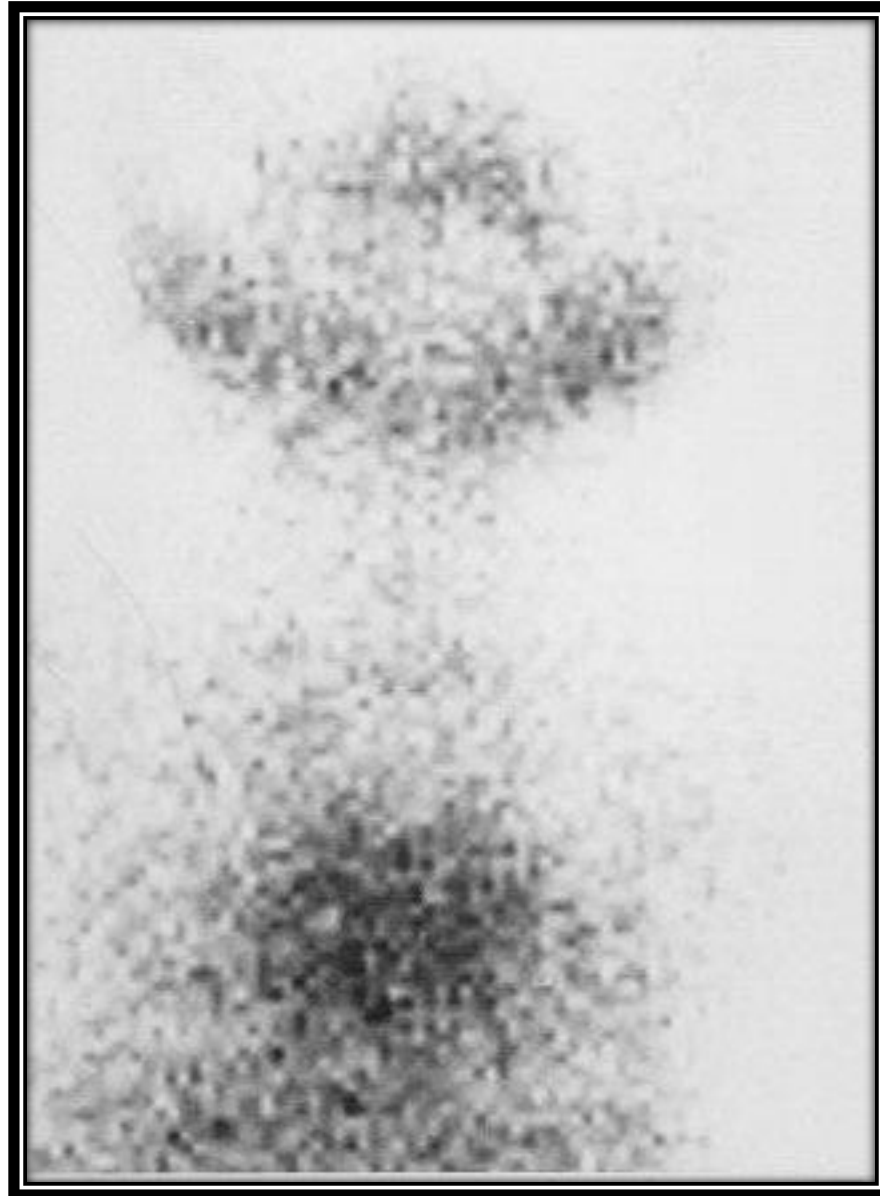
Elevated T4 and suppressed TSH



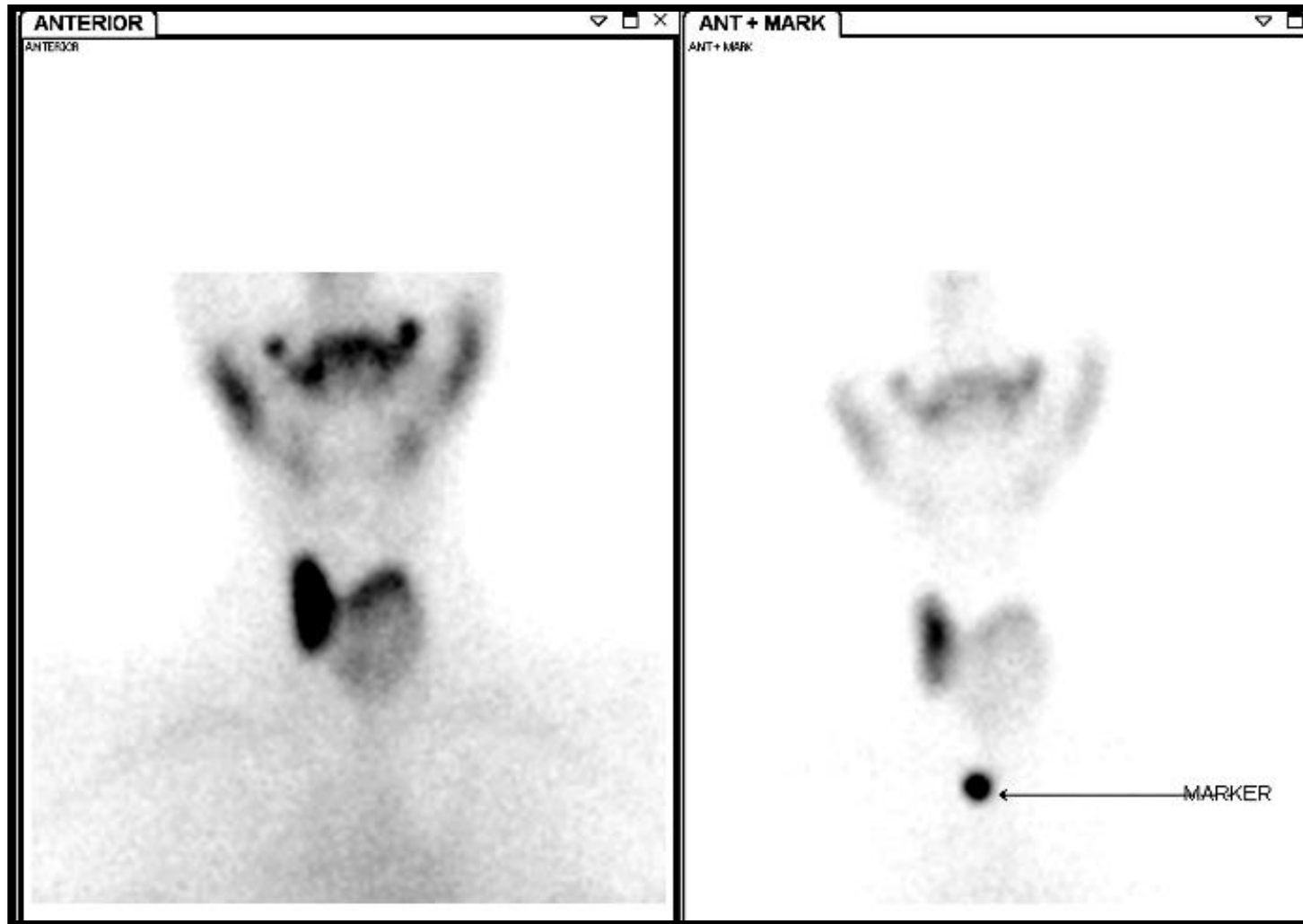
Elevated TSH and low T4 (2 YEARS OLD)



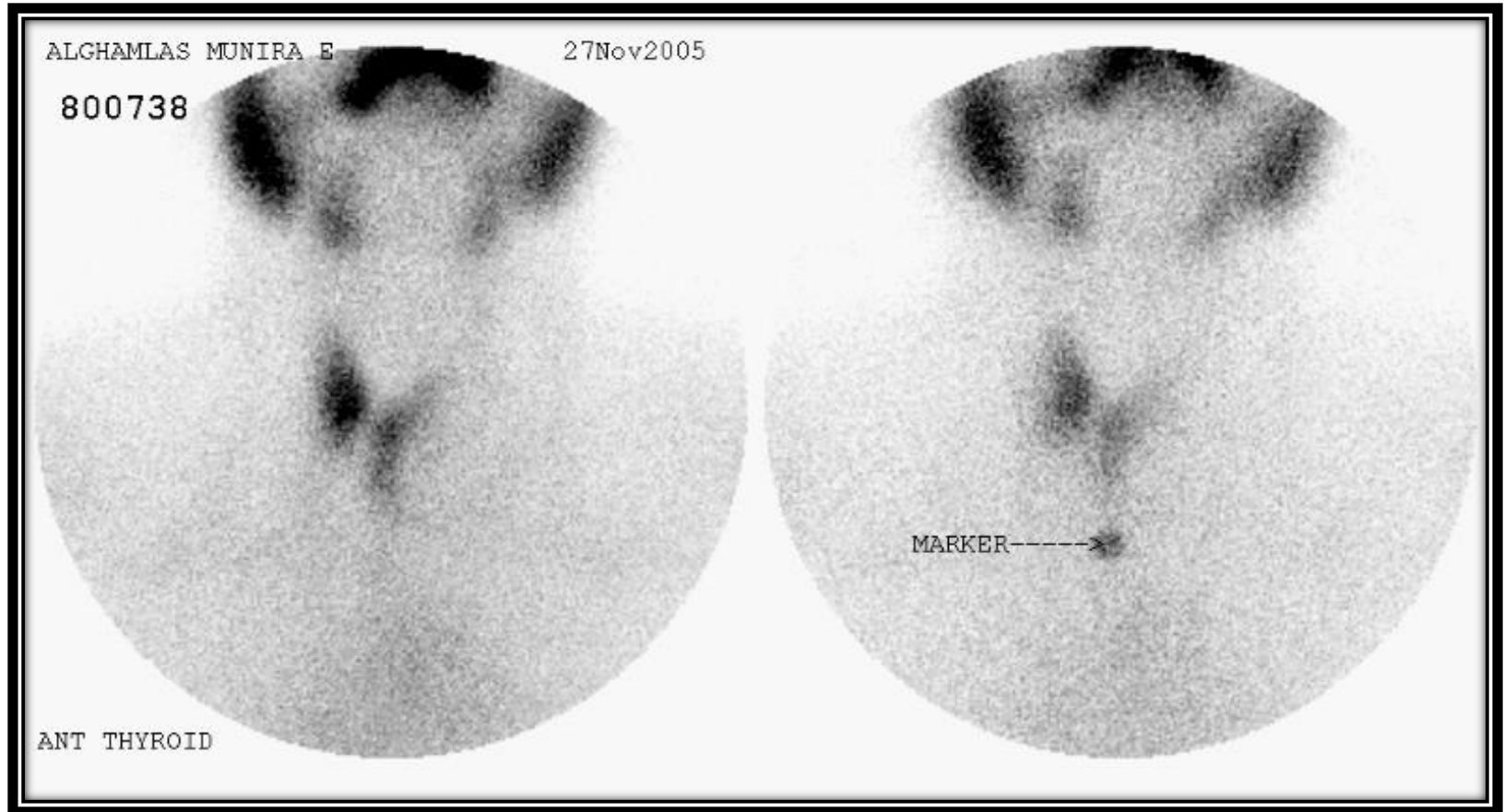
Elevated TSH and low T4



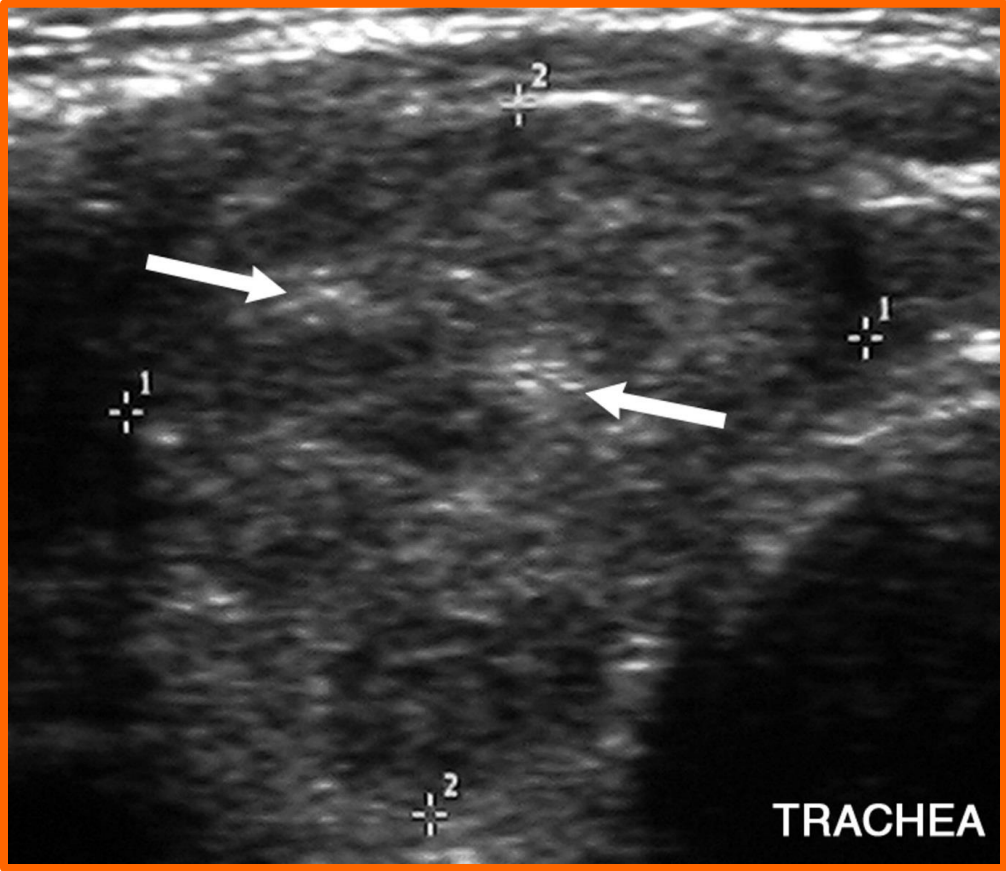
Palpable Neck Mass



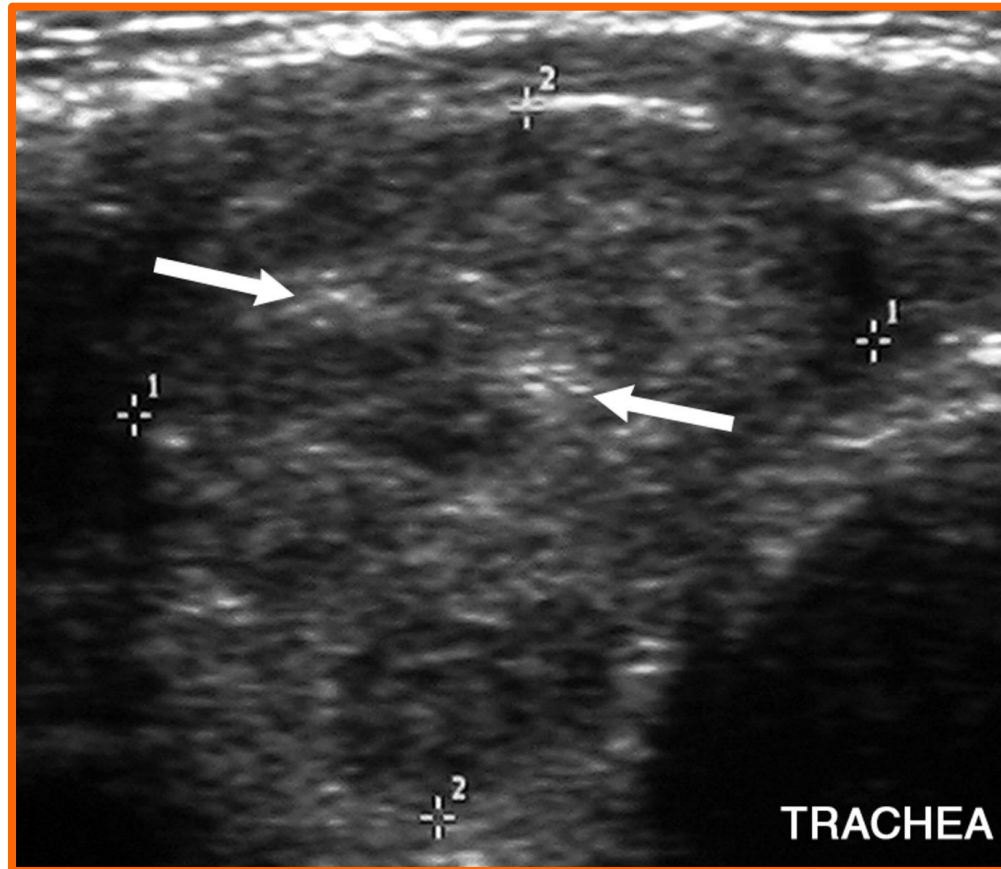
Palpable Neck Mass



Right Thyroid lobe : Papillary thyroid carcinoma in a 42-year-old man.



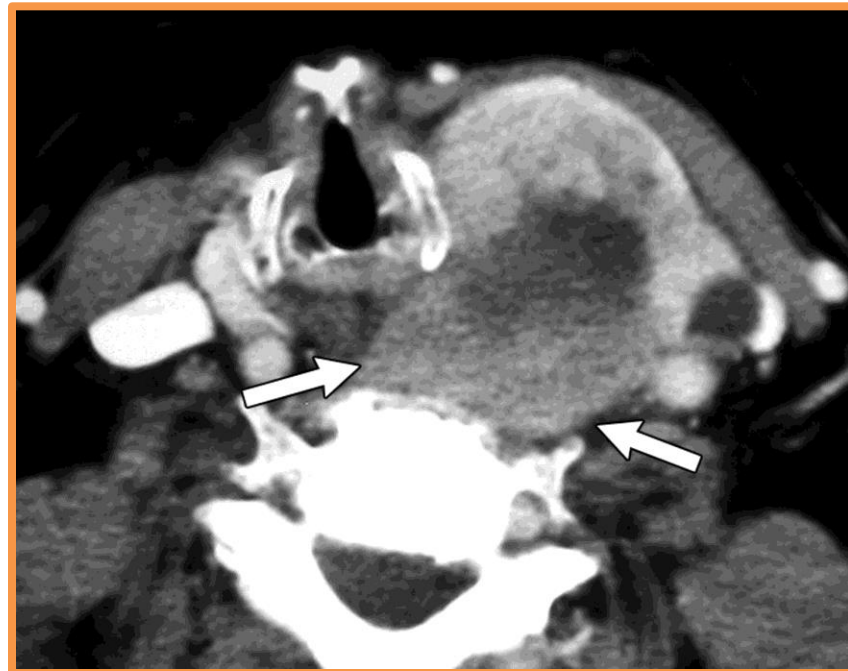
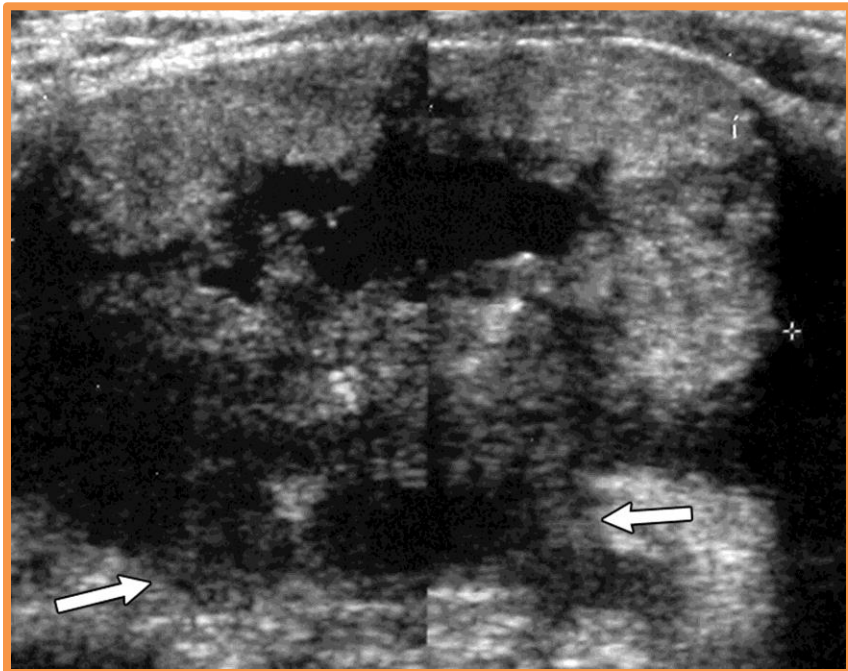
Right Thyroid lobe : Papillary thyroid carcinoma in a 42-year-old man.



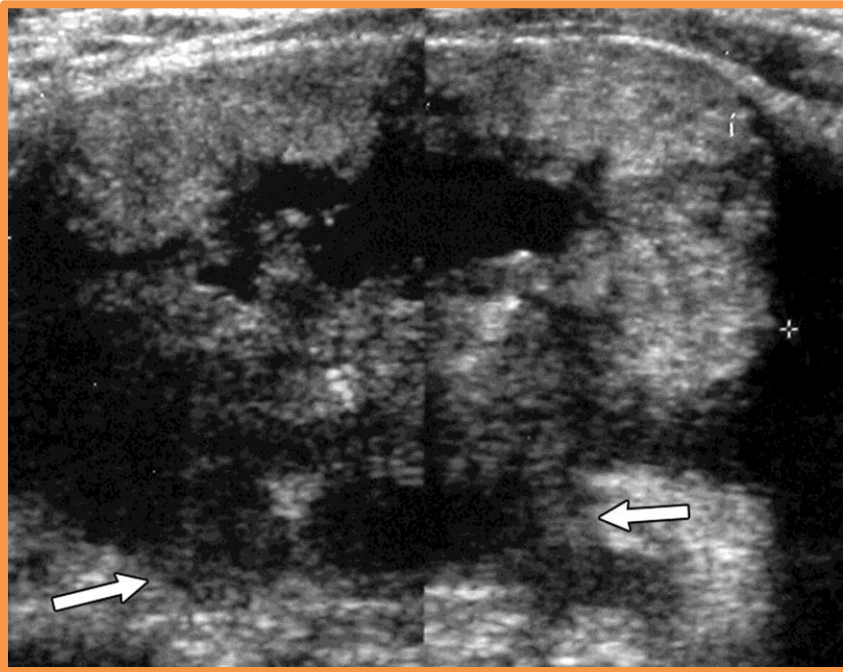
Transverse sonogram of the right lobe of the thyroid demonstrates:

Punctate echogenic foci without posterior acoustic shadowing, findings indicative of **microcalcifications** (arrows).

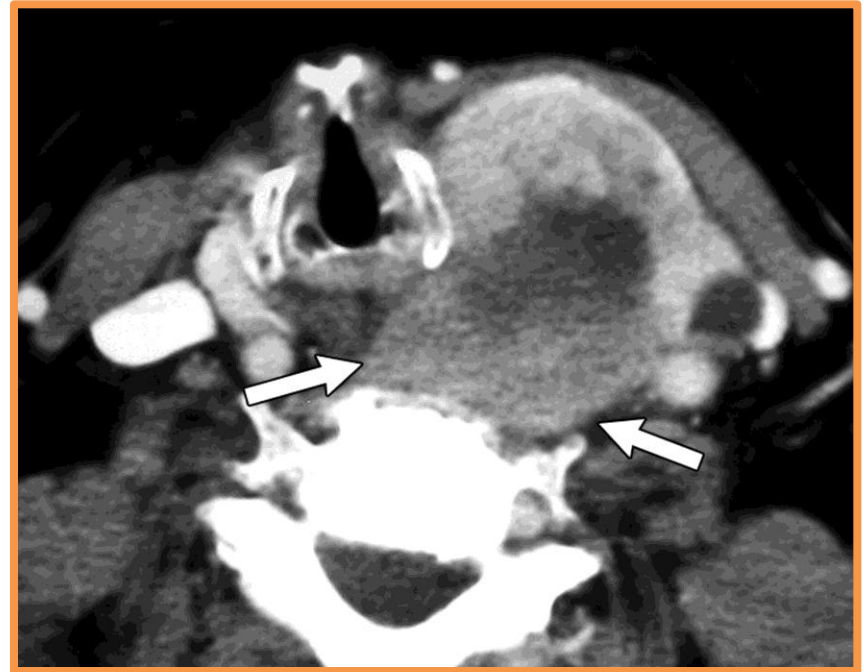
Anaplastic thyroid carcinoma in an 84-year-old woman



Anaplastic thyroid carcinoma in an 84-year-old woman

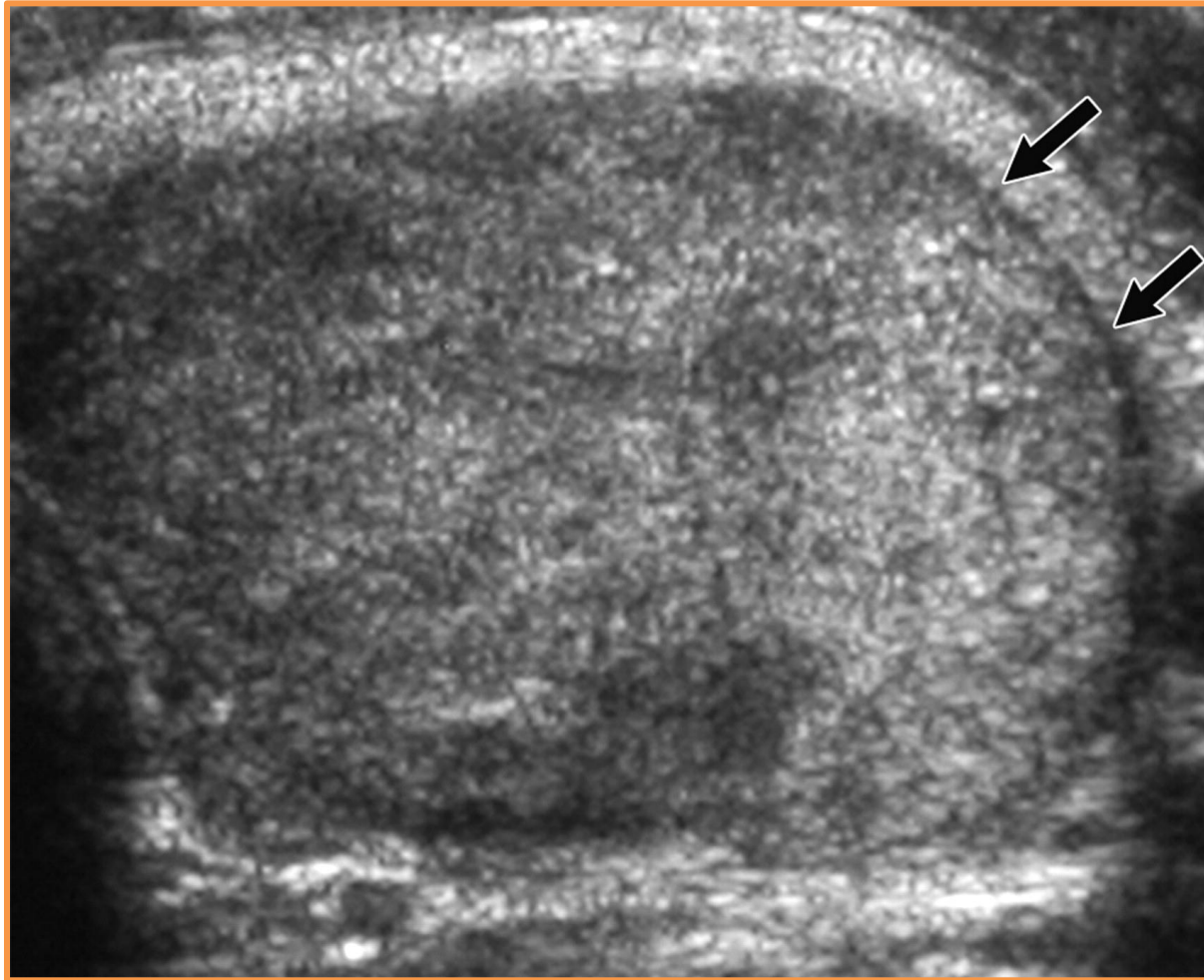


Transverse sonogram of the left lobe of the thyroid shows an advanced tumor with infiltrative posterior margins (arrows) and invasion of prevertebral muscle.

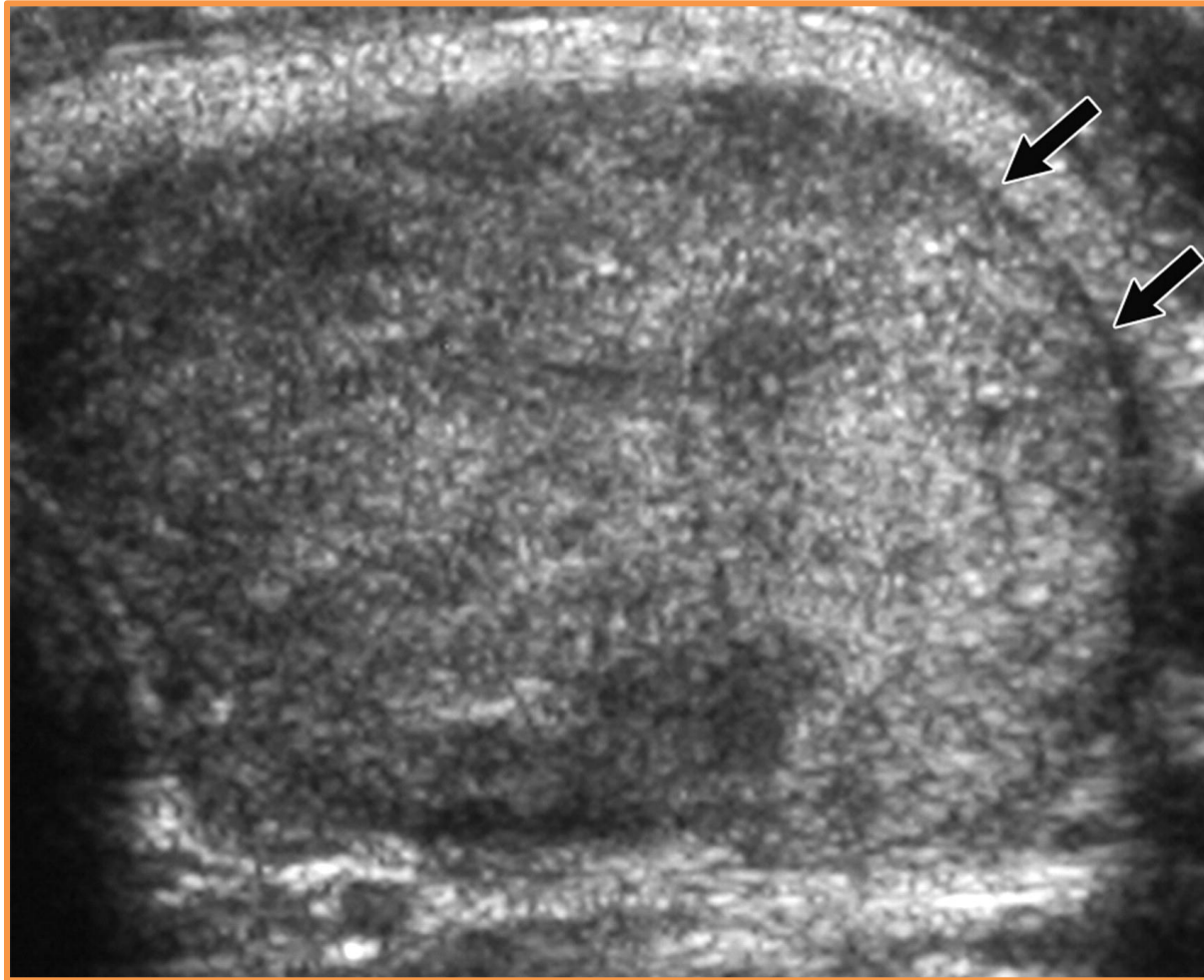


Axial contrast-enhanced CT image shows a large tumor that has invaded the prevertebral muscle (arrows).

Follicular adenoma in a 30-year-old woman

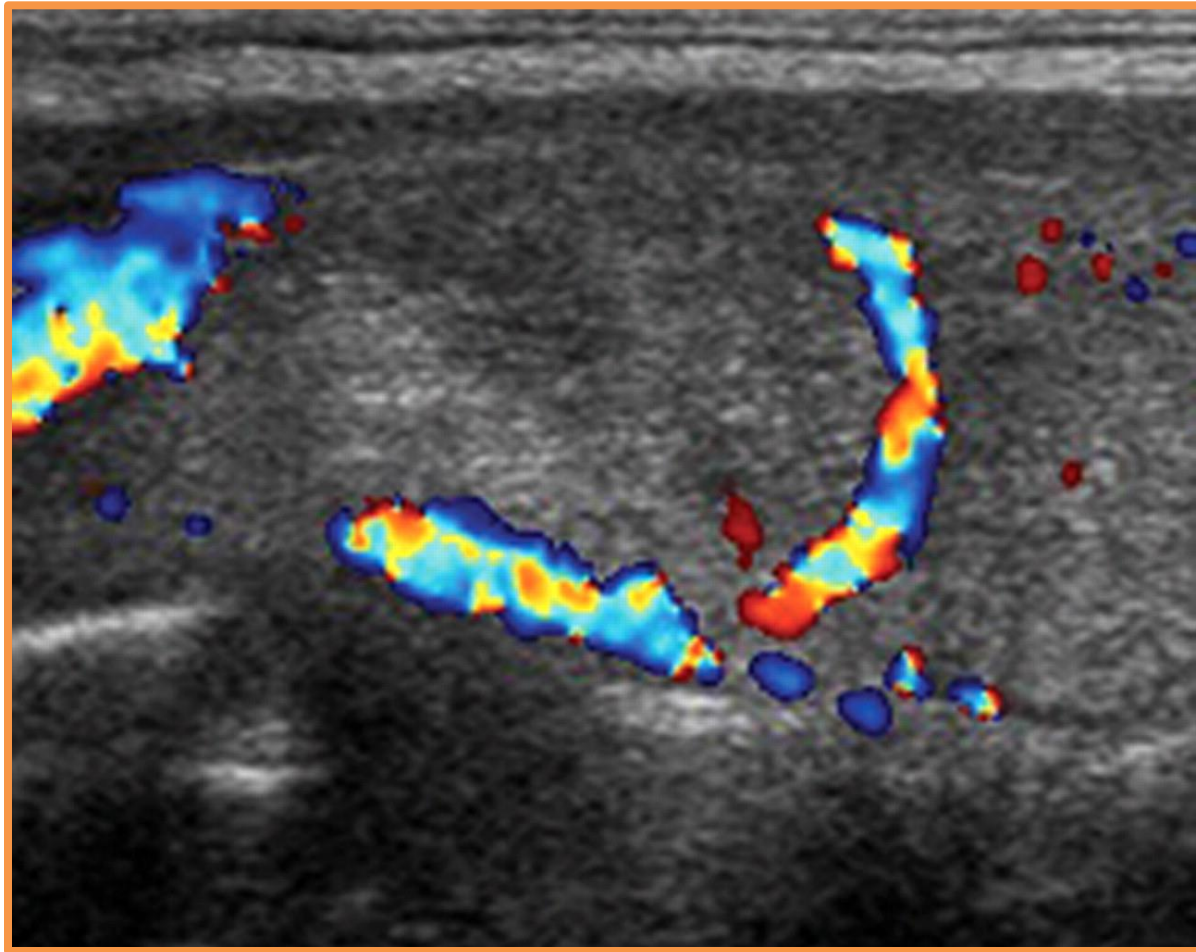


Follicular adenoma in a 30-year-old woman

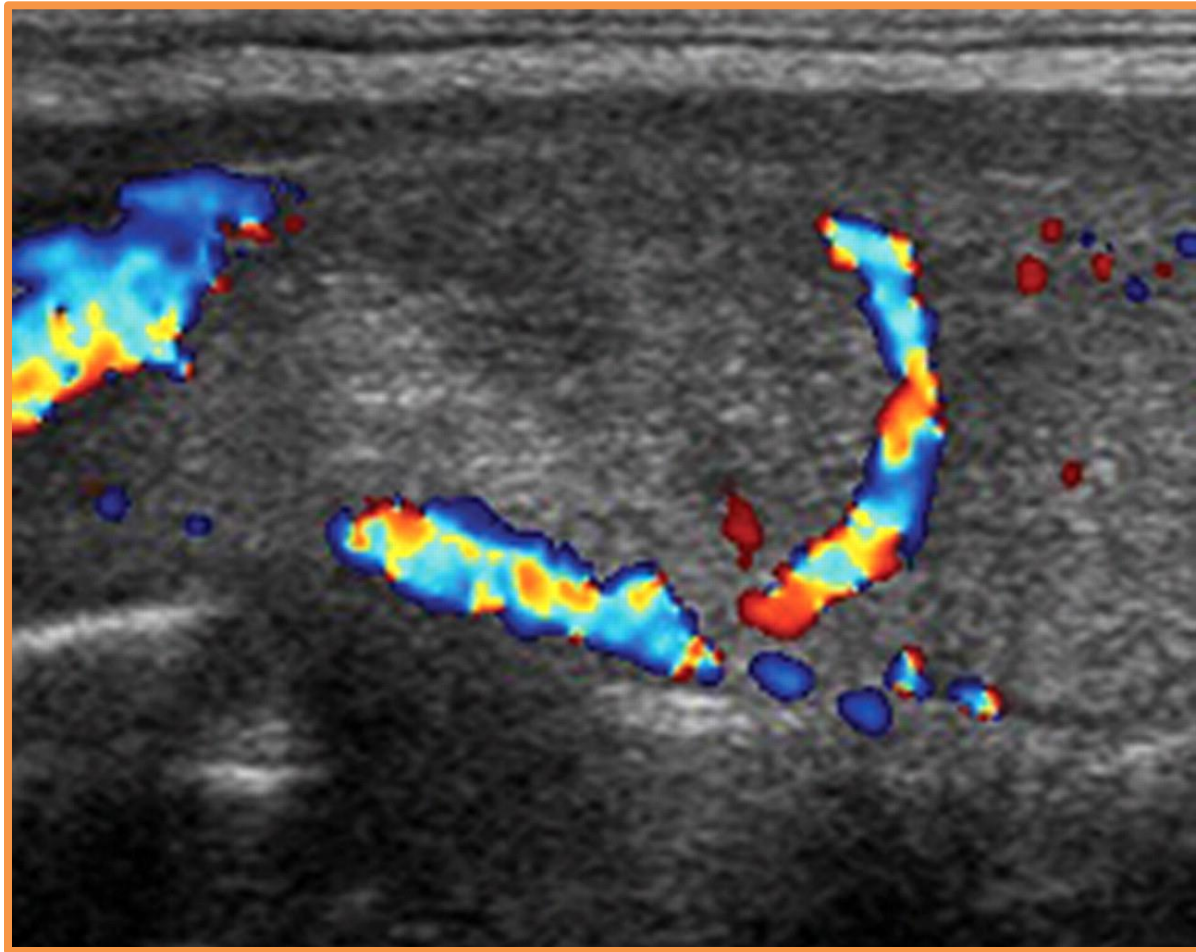


Transverse sonogram of the left lobe of the thyroid shows a follicular adenoma with a hypoechoic halo (arrows).

Follicular adenoma in a 36-year-old woman

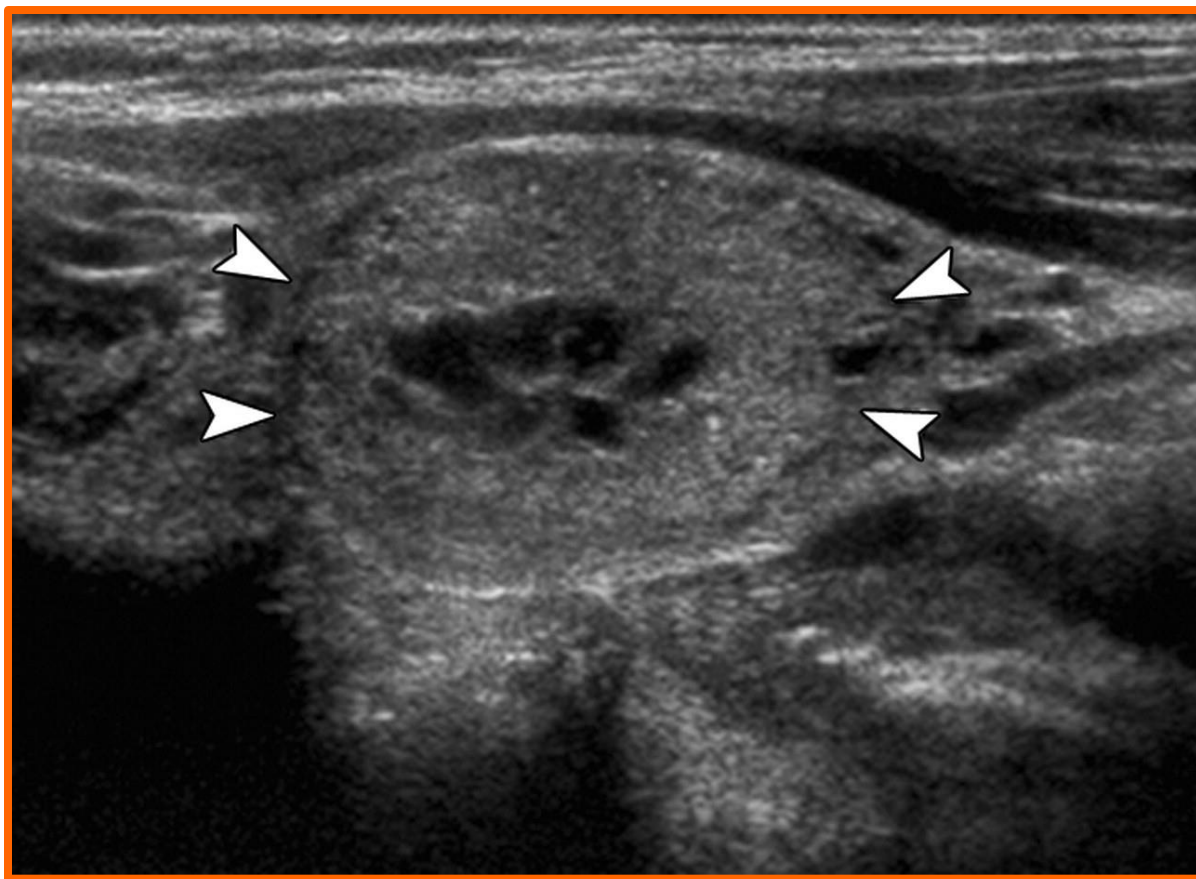


Follicular adenoma in a 36-year-old woman

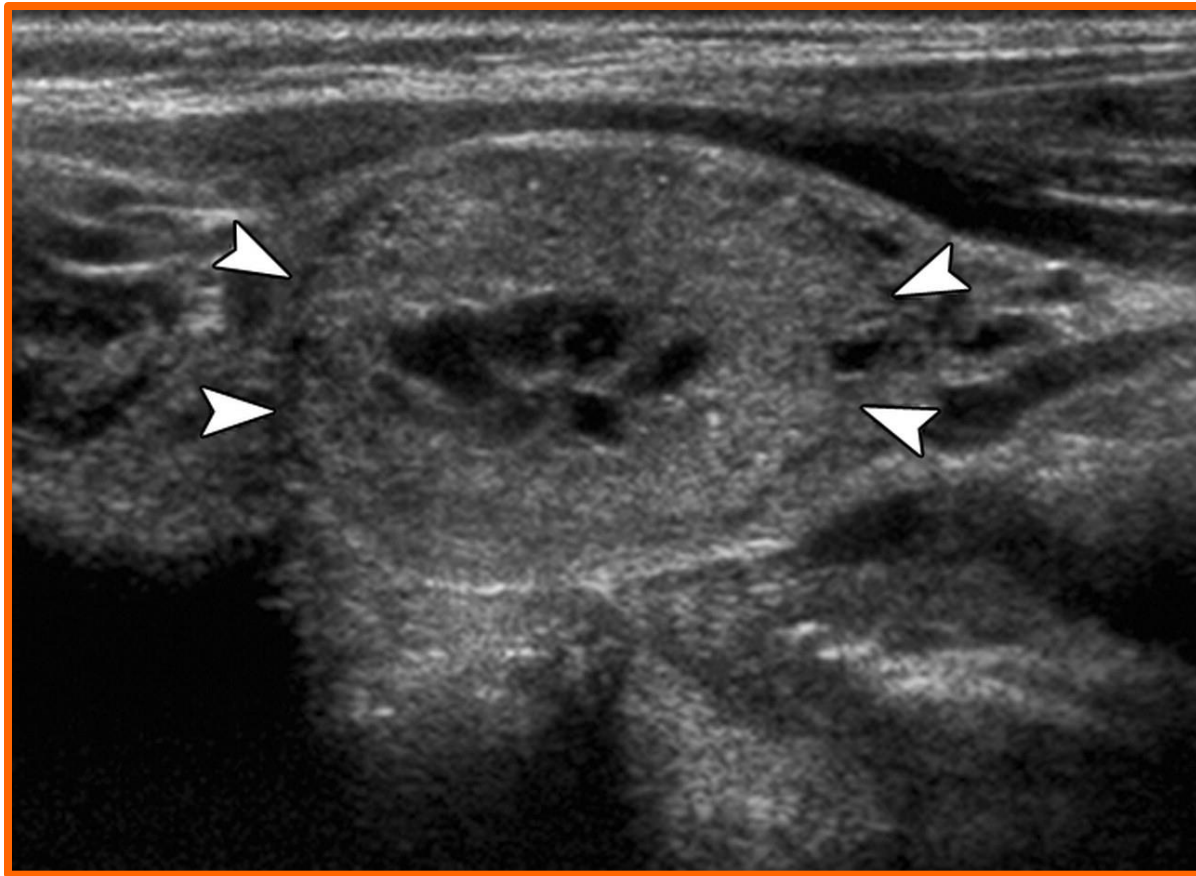


Longitudinal color Doppler sonogram of the right lobe of the thyroid shows perinodular flow around a follicular adenoma.

US images of thyroid nodules

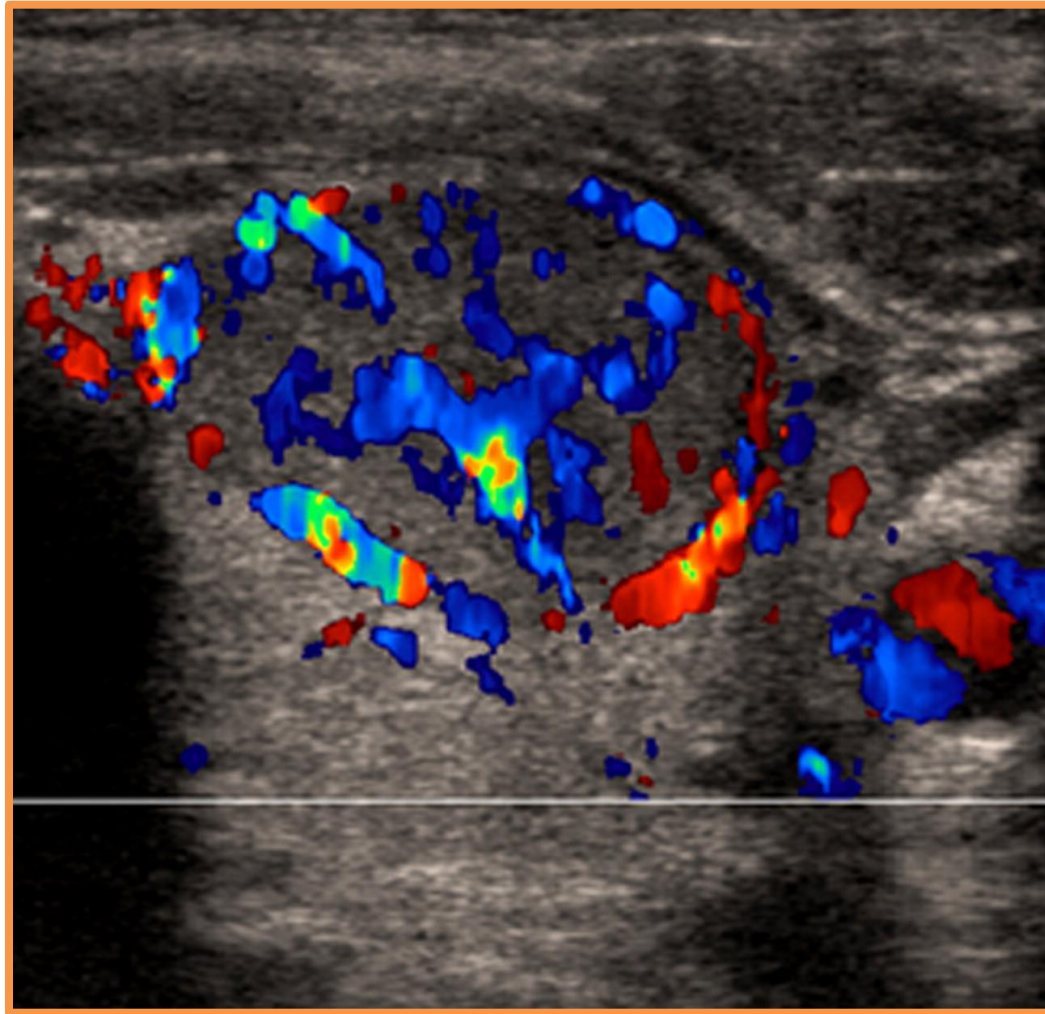


US images of thyroid nodules of varying parenchymal composition (solid to cystic).

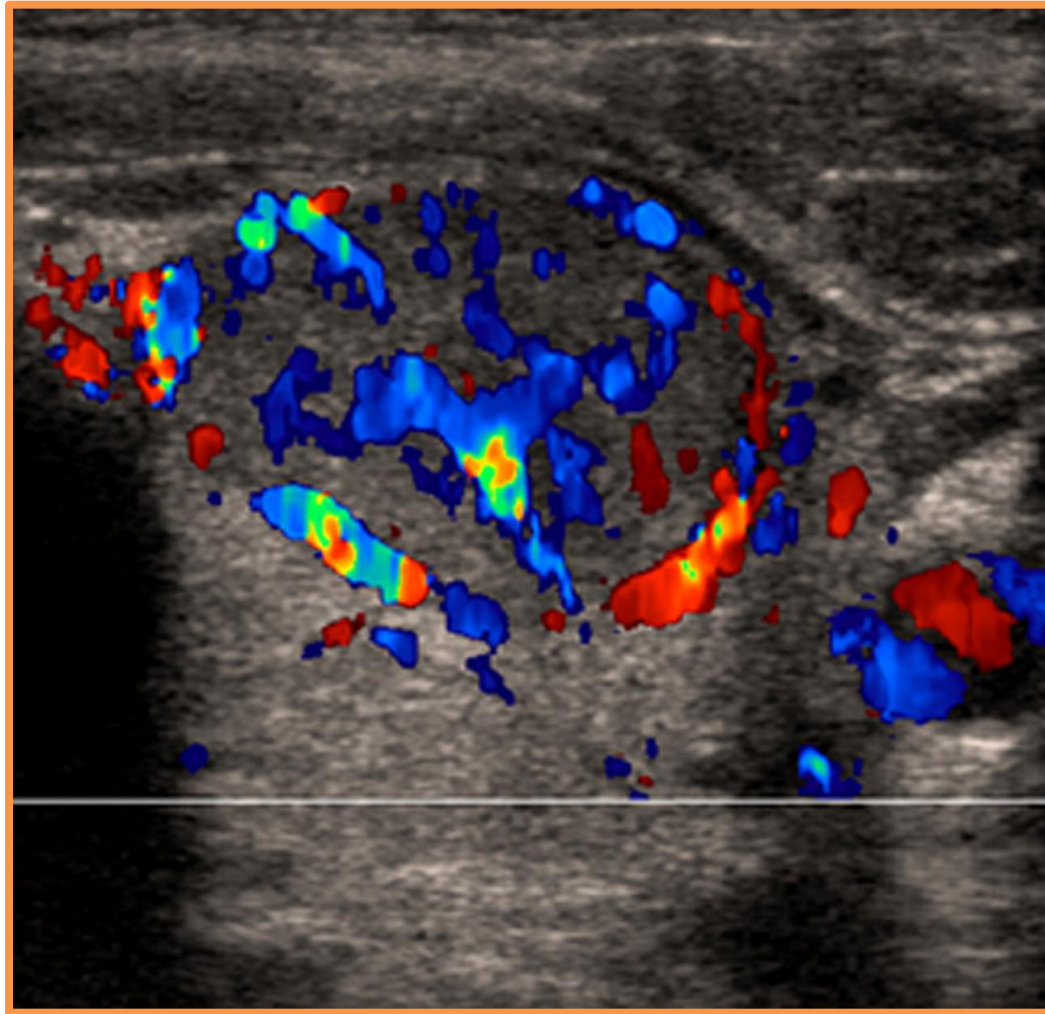


Proved to be benign at cytologic examination

Papillary carcinoma: Predominantly solid thyroid nodule



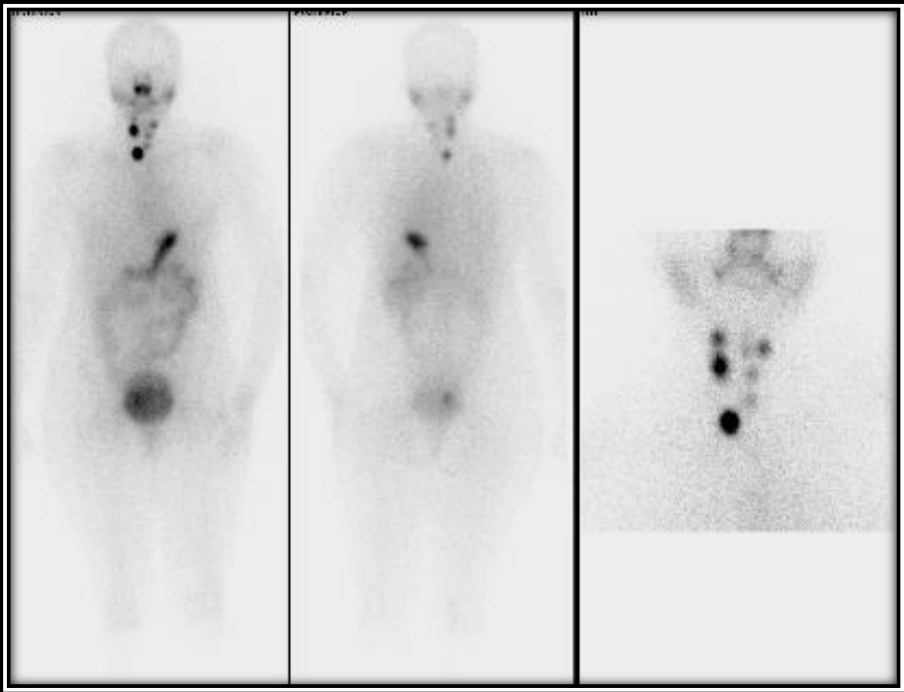

Papillary carcinoma: Predominantly solid thyroid nodule



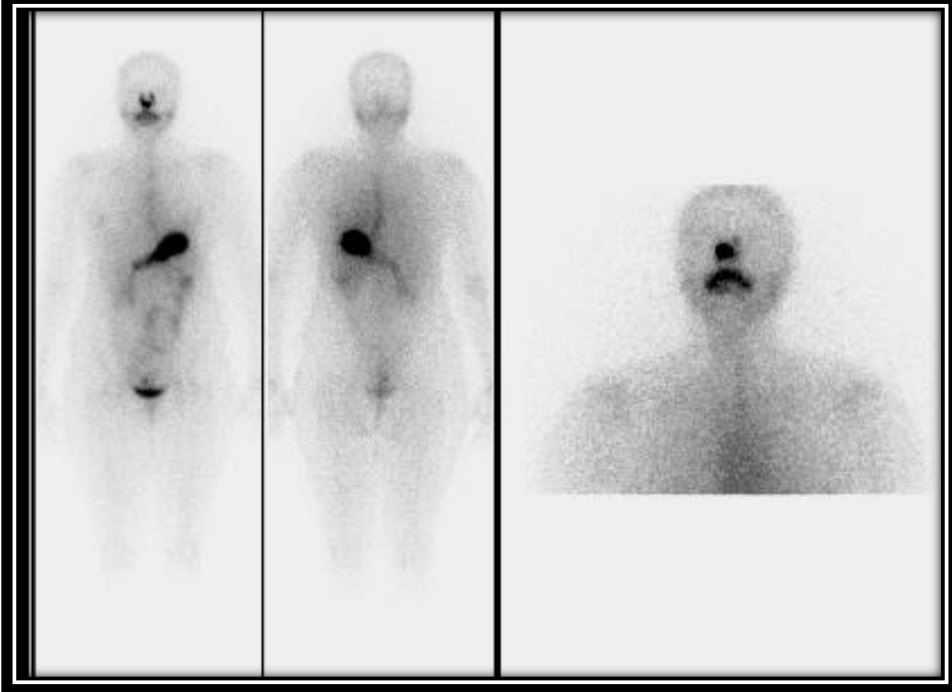
Role of colour Doppler US: colour Doppler mode shows marked internal vascularity, indicating increased likelihood that nodule is malignant. This was a papillary carcinoma.

A32 years old female patient with neck swelling

- Agents and procedure
- Findings
- Differential diagnosis
- Other investigations
- Final diagnosis
- Management



March 2014

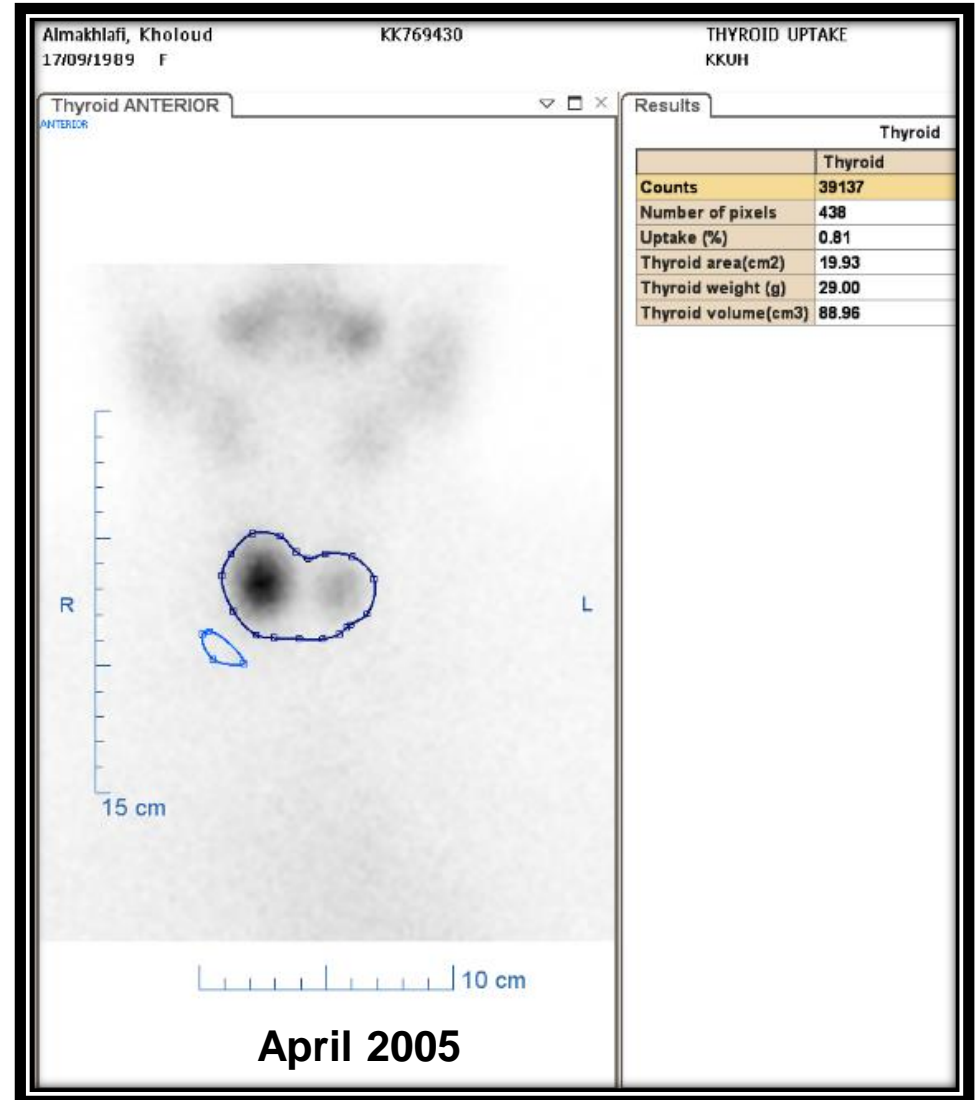
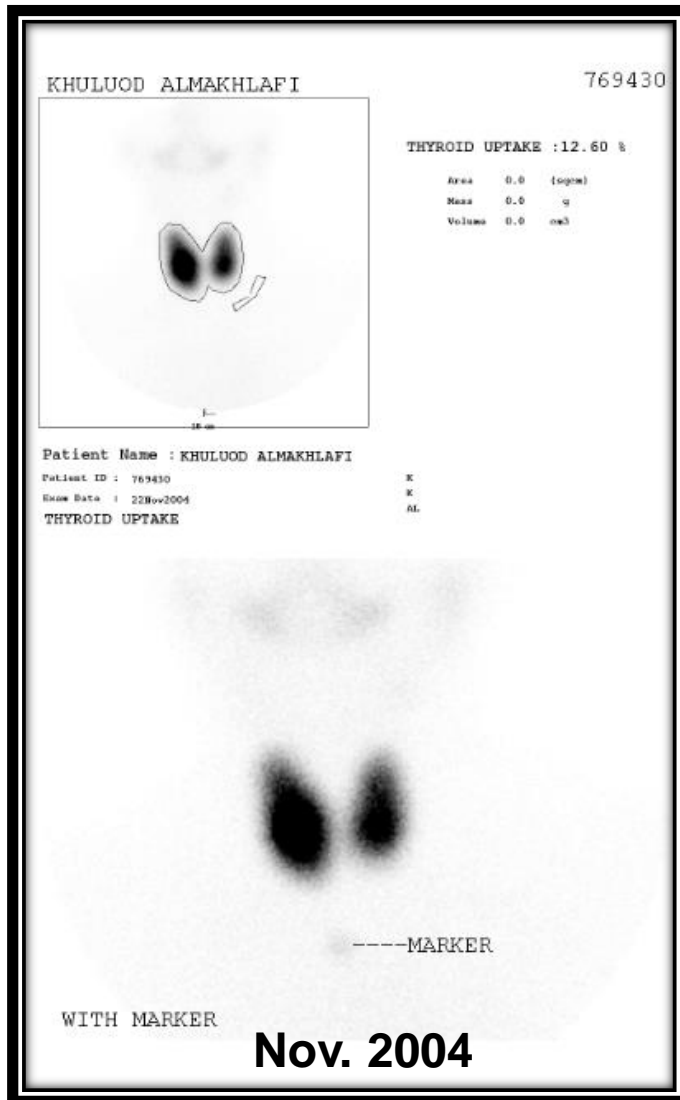


October 2014

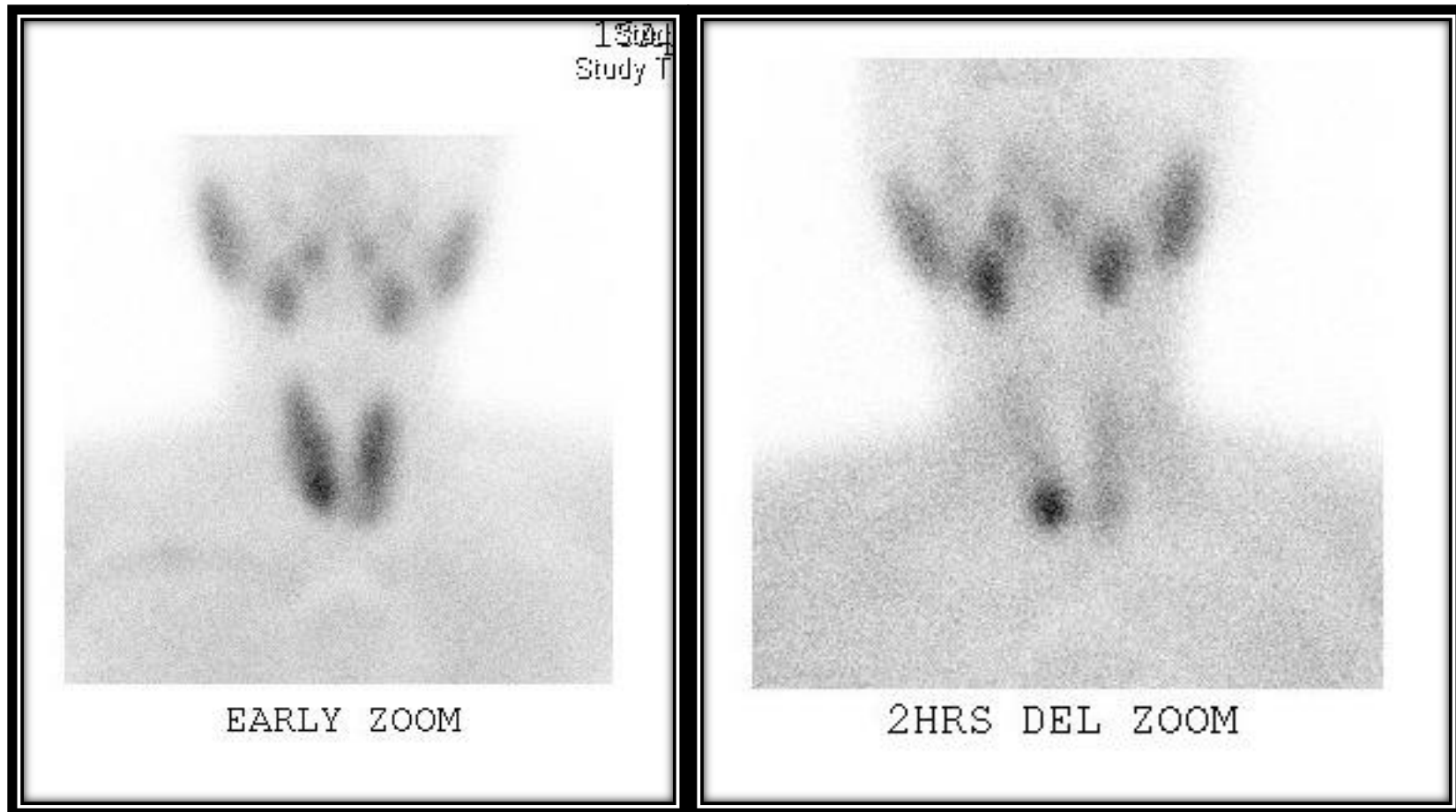
Agent and procedure.

Findings

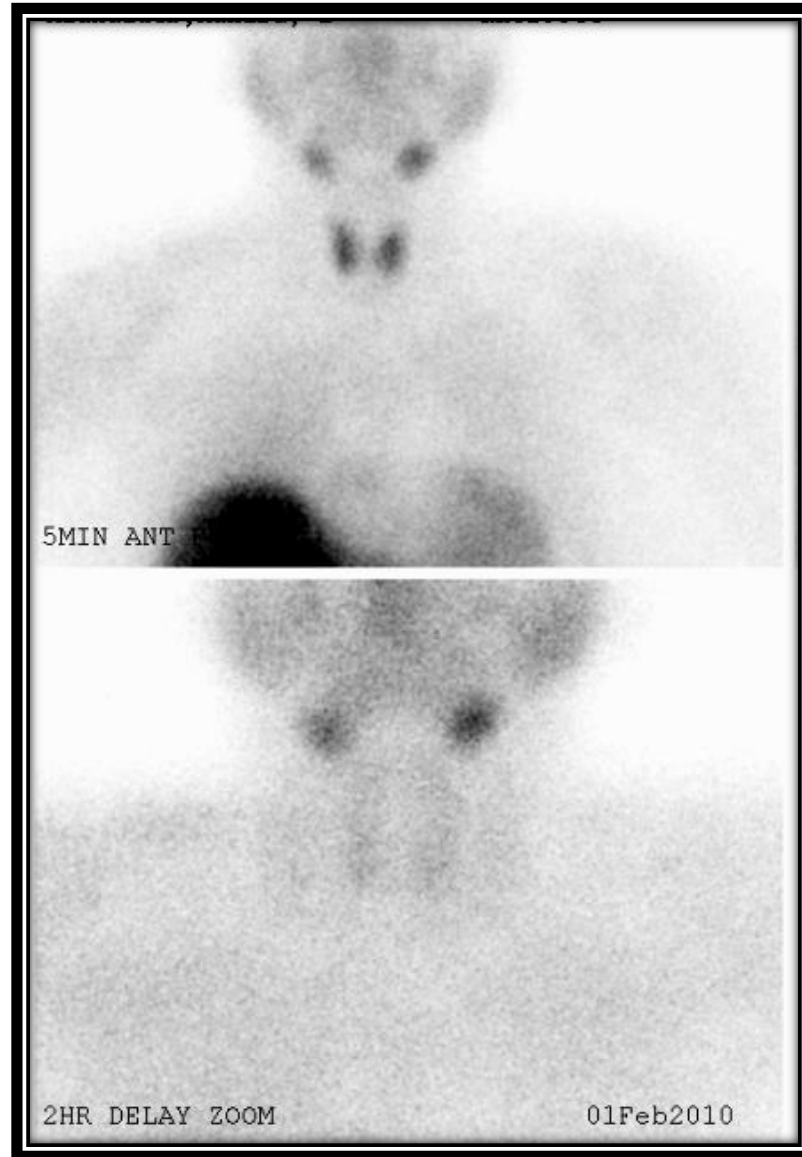Conclusion



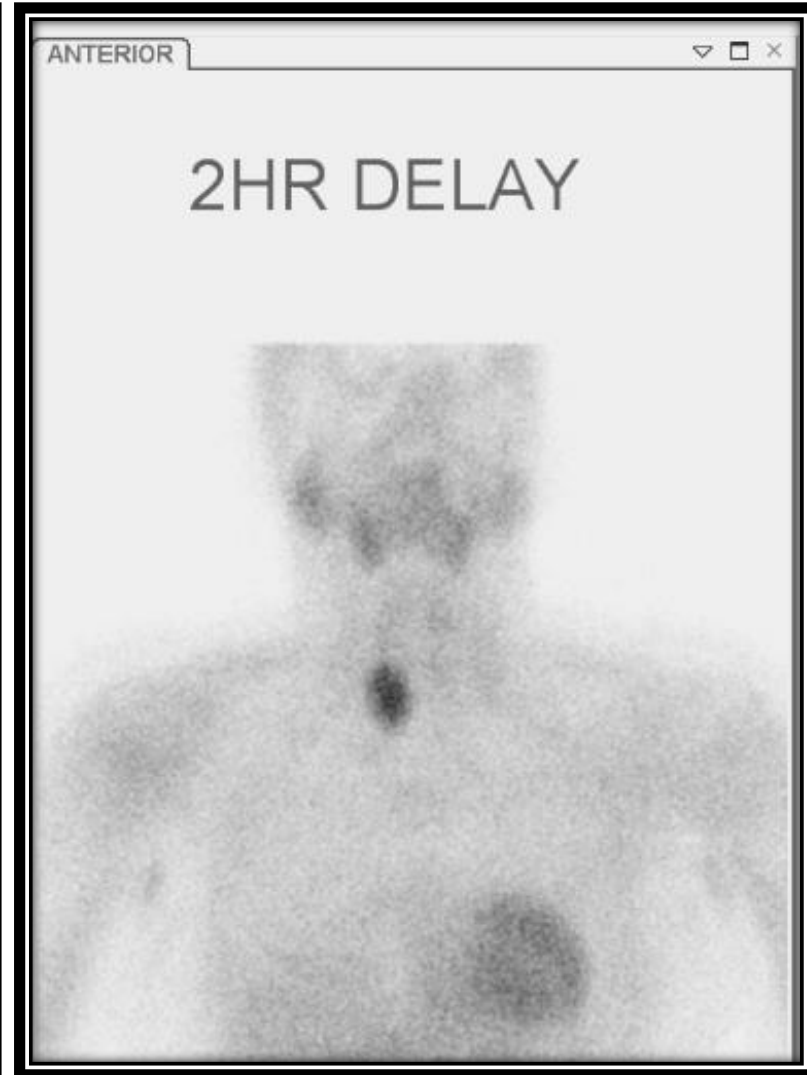
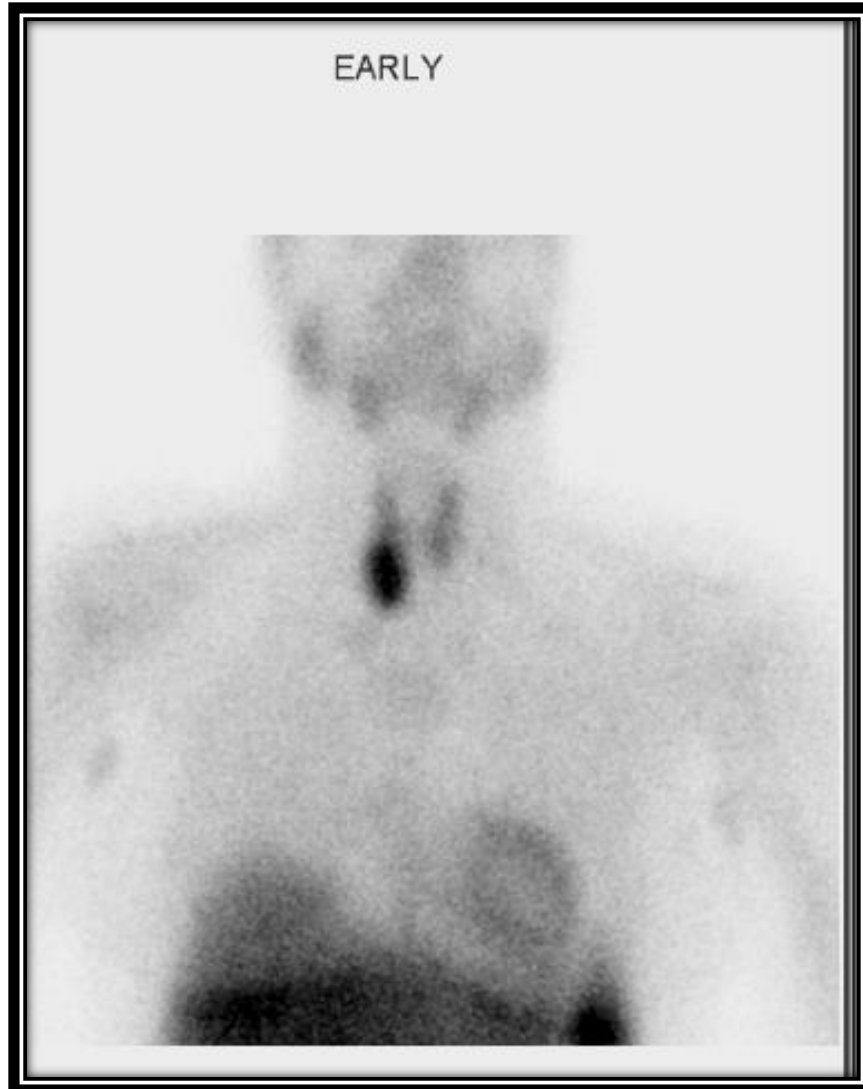High PTH and High Ca



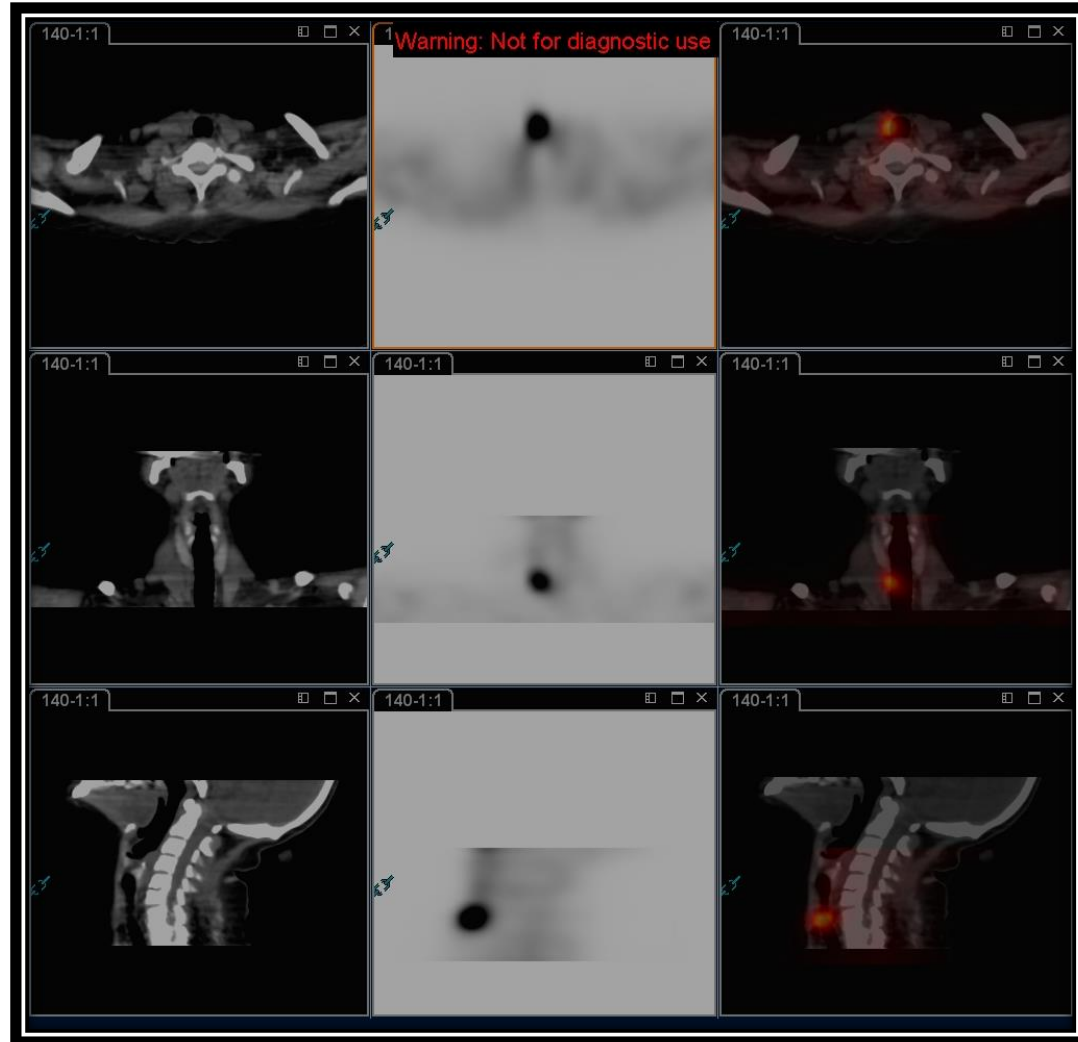
High PTH and High Ca



High PTH and High Ca...1



High PTH and High Ca...II



- Agent and procedure
- Findings
- Final diagnosis

