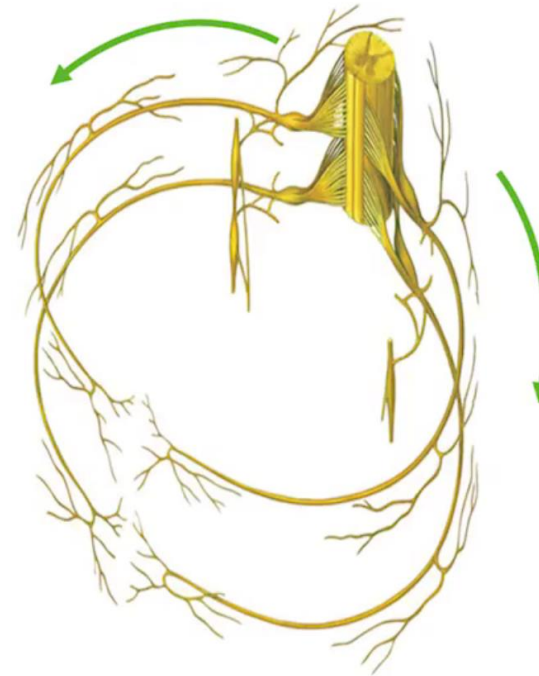


Nerve supply of the anterolateral abdominal wall

Tuqa Alkaf&Nuha Alslamah

Nerve supply – thoracoabdominal nerves

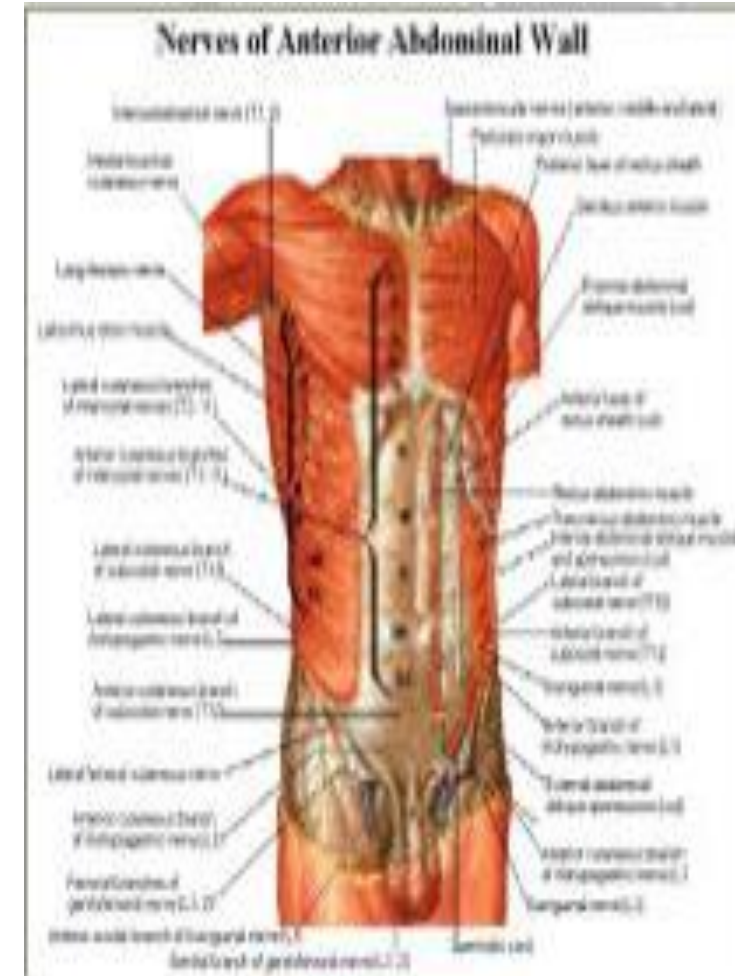
- Thoracoabdominal nerves (T7-11)
 - Subcostal (T12)
 - Iliopogastric (L1)
 - Ilioinguinal (L1)
-
- These nerves run within the internal oblique and transversus abdominis muscle layers



Nerve Supply of Anterolateral Abdominal Wall

- Skin and muscles of anterior wall supplied mainly by ventral rami of inferior six thoracic nerves (i.e., the continuation of the inferior intercostal nerves, T7 to T11) and subcostal nerve (T12).
 - Inferior part supplied by two branches of ventral ramus of first lumbar nerve via iliohypogastric and ilioinguinal nerves.
 - Main trunks of intercostal nerves pass anteriorly from intercostal spaces and run between internal oblique and transversus abdominis muscles.

Common nerve supply of the skin and the muscles of the anterolateral wall explain why palpating the abdomen with cold hands causes the muscles of the abdominal wall to contract.



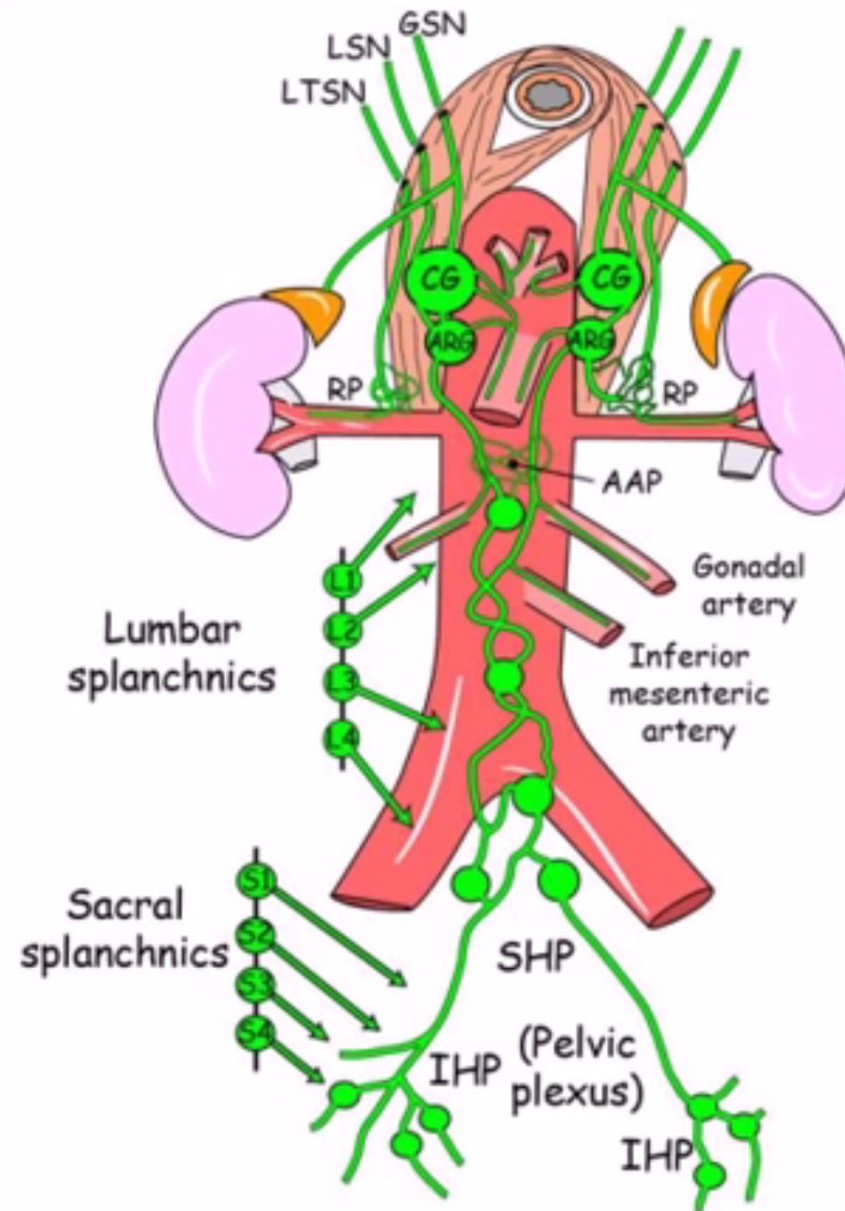
Nerve Supply of the Posterior Abdominal Wall

- Psoas major: ventral rami of L1-L3 spinal nerves.
 - Iliacus: branch of femoral nerve (L2-L3).
- Quadratus lumborum: ventral rami of T12, L1-L4.

Sympathetic nerve supply

The sympathetic supply includes:

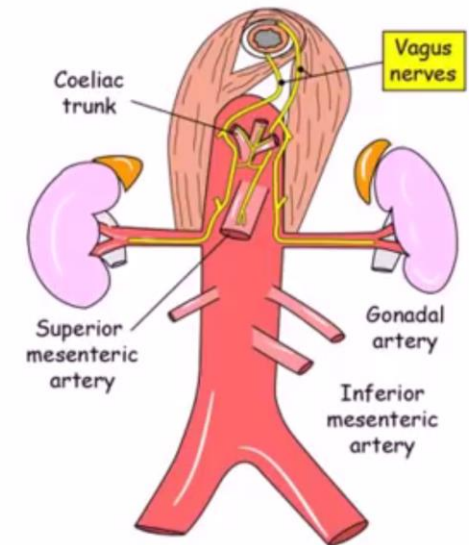
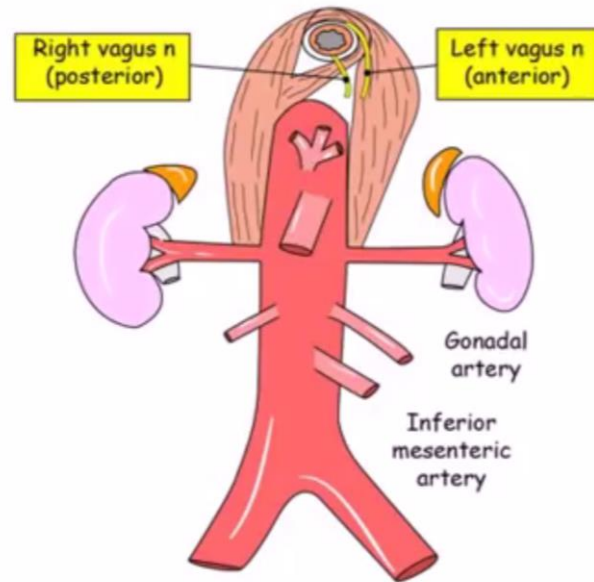
- _Greater splanchnic nerve (T5-9)
- _Lesser splanchnic nerve (T9-10)
- _Lowest (least) splanchnic nerve (T12)
- _Lumbar splanchnic nerves (L1-3)
- _Sacral splanchnic nerves



Parasympathetic nerve supply

The parasympathetic supply includes:

- _Vagus nerve
- _Pelvic splanchnic nerve (S2-4)
- _These project to the paravertebral plexuses, which are situated anterior to the aorta and vertebral column.



- **Abdominal Part of Oesophagus**

- - Anterior gastric nerve contain mainly left vagal fibers.
- - Posterior gastric nerves mainly the right vagal fibers
- - Few sympathetic fibers from greater splanchnic nerve.

- **Nerves Of Stomach:**

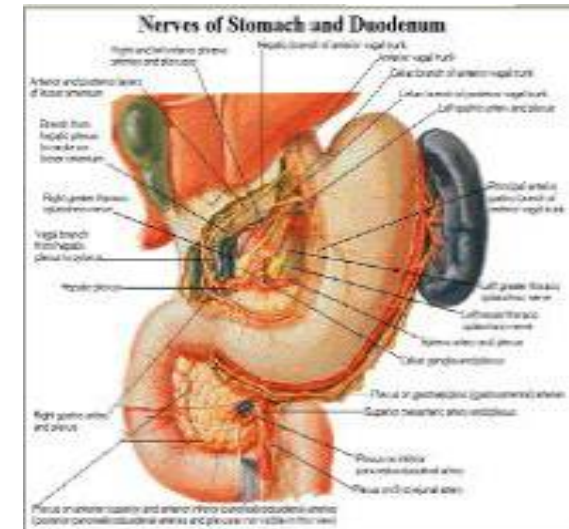
- - Derived from celiac sympathetic plexus and right and left vagus nerve.
- - Sympathetic innervation of stomach carries a proportion of pain transmitting nerve fibers.
- - While parasympathetic vagal fibers are secretomotor to gastric glands and motor to muscular wall of stomach.

- **Nerve Supply of Small Intestine**

- • Autonomic nerves reach wall of small intestine with its blood vessel.
- Parasympathetic vagal supply augments peristaltic activity and intestinal secretion. Sympathetic supply, which is vaso constrictor and normally inhibits to peristalsis is from T9 and T10 spinal segments.


- **Nerve Supply of large intestine**

- • Parasympathetic N/supply to large intestine is partly from vagi and partly from pelvic splanchnic nerve.
- • Sympathetic supply is derived from spinal cord segment T10-L2.



<u>Part</u>	<u>Segment(s)</u>	<u>Referred pain</u>
<u>Oesophagus (causal part)</u>	<u>T5-6</u>	<u>Retrosternal/ epigastrium</u>
<u>Stomach</u>	<u>T6-10</u>	<u>Epigastrium</u>
<u>Small intestine (duodenum, ileum and jejunum)</u>	<u>T9-10</u>	<u>Umbilical</u>
<u>Large intestine to splenic flexure</u>	<u>T11-L1</u>	<u>Umbilical</u>
<u>Splenic flexure to rectum</u>	<u>L1-2</u>	<u>Hypogastrium</u>
<u>Liver and gallbladder</u>	<u>T7-9</u>	<u>Epigastrium/right hypochondrium</u>

<u>Part</u>	<u>Segment(s)</u>	<u>Referred pain</u>
<u>Spleen</u>	<u>T6-10</u>	<u>Left hypochondrium</u>
<u>Pancreas</u>	<u>T6-10</u>	<u>Epigastrium</u>
<u>Kidney</u>	<u>T10-L1</u>	<u>Posterior lumbar</u>
<u>Suprarenal</u>	<u>T8-L1</u>	<u>Posterior lumbar</u>
<u>Gonads</u>	<u>T10-11</u>	<u>Lumbar to groin</u>



VOMITING



THE DEFINITION:

Nausea:

- Urge to vomit, "sick to stomach" or "queasy"

Vomiting (Emesis):

- Forcible expulsion of stomach contents

HOW DOES VOMITING OCCUR?

Vomiting occurs when the vomiting centers are stimulated:

1. **The Chemoreceptor Trigger Zone:** This area is located in the floor of the 4th ventricle and blood can directly reach it. This explains why some drugs cause or stop vomiting.
2. **The Vagus Nerve:** This is the 10th cranial nerve and gets activated whenever the pharynx is activated and the gag reflex results.
3. **The Vestibular System:** This system controls balance and sends its input to the CNS via the vestibular nerve, any disturbance of balance (such as motion sickness), eventually resulting in vomiting.

HOW DOES VOMITING OCCUR?

4. **Vagal and Enteric Nervous System:** The nervous system of the gut, when stimulated, can induce vomiting via the vagal afferents or its rich sympathetic nervous supply. The gastrointestinal tract can be irritated by chemotherapy, radiation, certain drugs, severe distension and infection

5. **The CNS:** When the higher brain centers such as the cerebrum are affected by stress or certain psychiatric conditions, this can also result in vomiting.

So to sum up, whatever stimulates these five components will stimulate the vomiting center, thus causing vomiting.

PHASES OF VOMITING:

1. Nausea, sweating and salivation
2. Retching
3. Expulsion of gastric contents through the mouth

THE PHYSIOLOGY BEHIND VOMITING:

Vomiting is mediated by the **parasympathetic & sympathetic nervous system** along with the **motor system**

- The parasympathetic nervous system causes excessive salivation to protect the tooth enamel from the acid contents
- The sympathetic nervous system causes sweating as well as increase in heart rate
- The motor system causes a deep breath so that the vomitus is not aspirated, reverse peristalsis begins from the small intestine so that its contents are brought up to the stomach, passing the pyloric sphincter, which lies relaxed due to the parasympathetic activity. the esophagus or stomach do not contract, Then how is the vomitus expelled? two processes: inspiration against a closed glottis(lowers the thoracic pressure) and contraction of the abdominal musculature (increases abdominal pressure) thus propelling the contents of the small intestine to move easily from a region of high pressure to a region of low pressure.

VOMITING: THE MOLECULAR LEVEL:

Vomiting is mediated by neurotransmitters such as histamine, dopamine, **serotin**, **neurokinin** and **vasopressin**, with the former three being the main controllers. That is why dopamine, serotonin and histamine antagonists are given for the suppression of vomiting.

CAUSES:

A-Neurologic :

Migraine Headache

Vertigo

Meningitis

B-Metabolic :

Renal Failure

Liver Failure or Cirrhosis

Addison's Disease

Diabetic Ketoacidosis

Pregnancy

C-Electrolyte Abnormalities:

Hyponatremia

Hypocalcaemia

Hyperkalemia

CONT:

D- Gastrointestinal :

Pyloric Stenosis

Small Bowel Obstruction

Appendicitis

Cholecystitis

Acute Pancreatitis

Food Poisoning

E- Miscellaneous :

Myocardial Infarction

Congestive Heart Failure

Myocardial Ischemia or infarction

Otitis Media

Acute Nephritis

Urinary Tract Infection

VOMITING HISTORY

Associated Factors:

Weight Loss

- Malignancy
- Peptic Ulcer Disease

Diarrhea

- Viral Gastroenteritis

Fever

- Acute Gastroenteritis (most common cause)
- Cholecystitis
- Appendicitis
- Hepatitis

Headache

CONT:

Onset :

A- Abrupt Onset:

- Gastroenteritis or Food Poisoning
- Pancreatitis
- Cholecystitis

B-Insidious Onset:

- Gastroesophageal Reflux
- Medication Induced Vomiting
- Metabolic Disorders
- Pregnancy

CONT:

Associated Pain :

Right upper quadrant pain:

- Cholecystitis

Epigastric Pain:

- Pancreatitis

Severe pain:

- Cholecystitis
- Pancreatitis
- Peritonitis
- Appendicitis
- Small Bowel Obstruction

CONT:

Timing:

Vomiting prior to eating breakfast:

- Alcoholism
- Uremia

During or immediately after eating:

- Peptic Ulcer Disease
- Pyloric Stenosis
- Eating Disorder e.g. Anorexia Nervosa

One to four hours after a meal:

- Peptic Ulcer Disease
- Malignancy

Associated with new medication or dosage change

CONT:

Characteristics of Emesis :

Regurgitation of undigested food:

- Achalasia
- Esophageal Stricture

Large residues of gastric contents (partly digested food):

- Gastroparesis
- Gastric Outlet Obstruction

Projectile Vomiting (with or without Nausea):

- Increased Intracranial Pressure

EXAMINATION

A- Observe for dehydration:

- Weight loss
- Dry mucus membranes
- Tachycardia

B- Neurologic Examination:

- Nystagmus
- Peripheral Neuropathy
- Cerebellar exam (coordination and gait testing)

CONT:

C- Abdominal examination:

- Abdominal distention
- Inguinal Hernia or abdominal wall Hernia
- Abdominal tenderness to palpation:
 - Epigastric Pain: Gastric Ulcer
 - Right upper quadrant pain: Cholecystitis
- Bowel sounds:
 - High pitched suggests Bowel Obstruction
 - Absent or decreased suggests ileus

D- Skin:

- Jaundice

REFERENCES

<http://www.fpnotebook.com/GI/Sx/Vmtng.htm>

<https://theclinicaljournal.wordpress.com/2012/04/16/the-pathophysiology-of-vomiting/>



ABDOMINAL PAIN

Rana Alsultan

History of Abdominal pain

1)Patient Demographics :

Name, Age ,sex

2)Presenting complaint. (CO? / Presented through clinic or ER?)

3)History of presenting complaint, including investigations, treatment and referrals already arranged and provided..

History of presenting complaint

Site- localization (well, poor), point with one finger

Onset – *When did the symptom start? / Was the onset acute or gradual?*

Duration – *minutes / hours / days / weeks / months / years*

Character - *sharp (stabbing) , colic (cramping) , dull*

radiation- and Migration-

Severity – *initial pain score (1-10) , awakens at night , effect patient activity*

Course – *worsening, improving, or continuing to fluctuate?*

Intermittent or continuous? – *always present or does it come and go?*

Precipitating factors – *eg: meal , position* **Relieving factors** – *eg: meal , position*

time (*diurnal variation*)

History of presenting complaint

Previous episodes – *has the patient experienced this symptoms previously?*

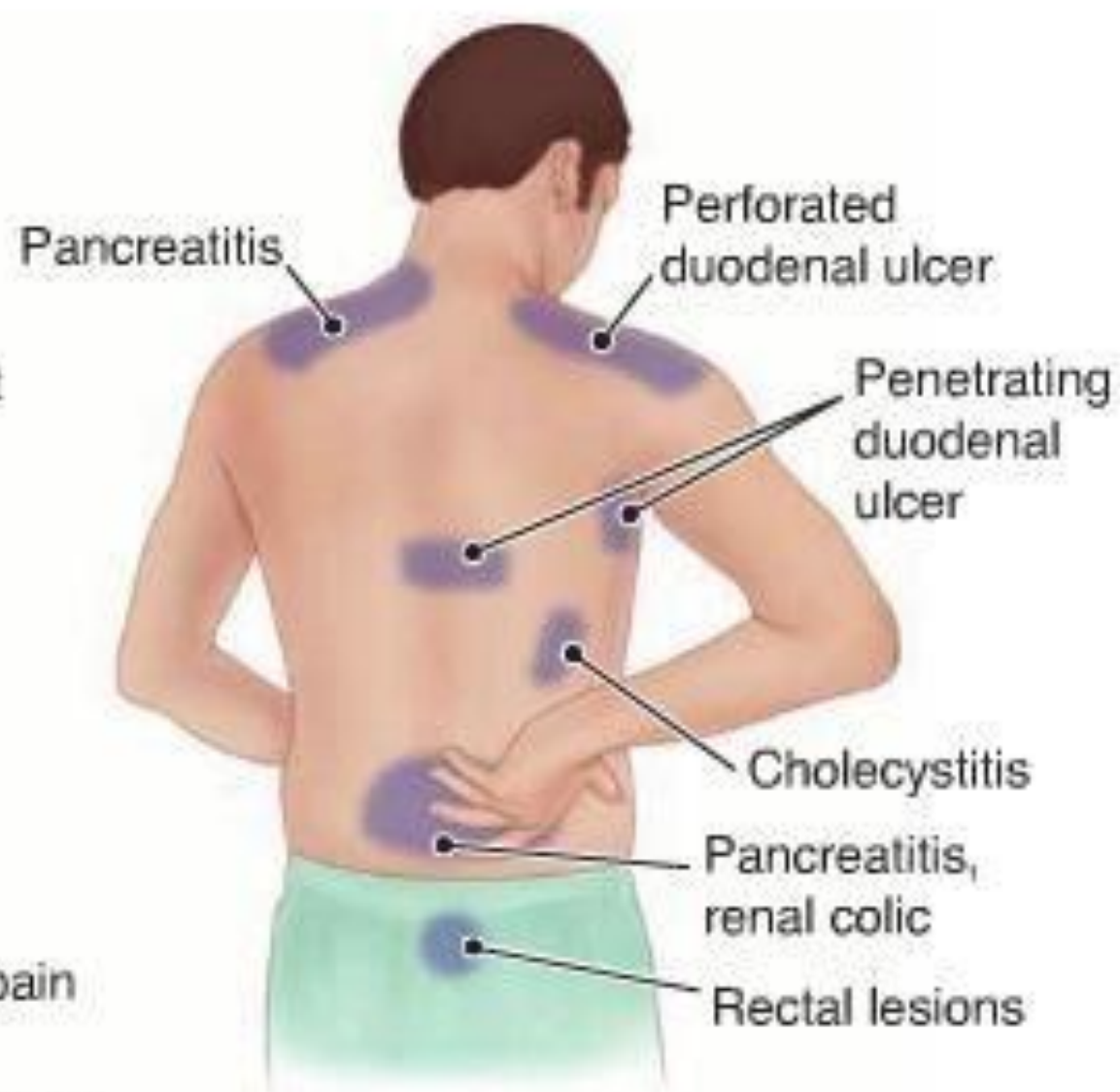
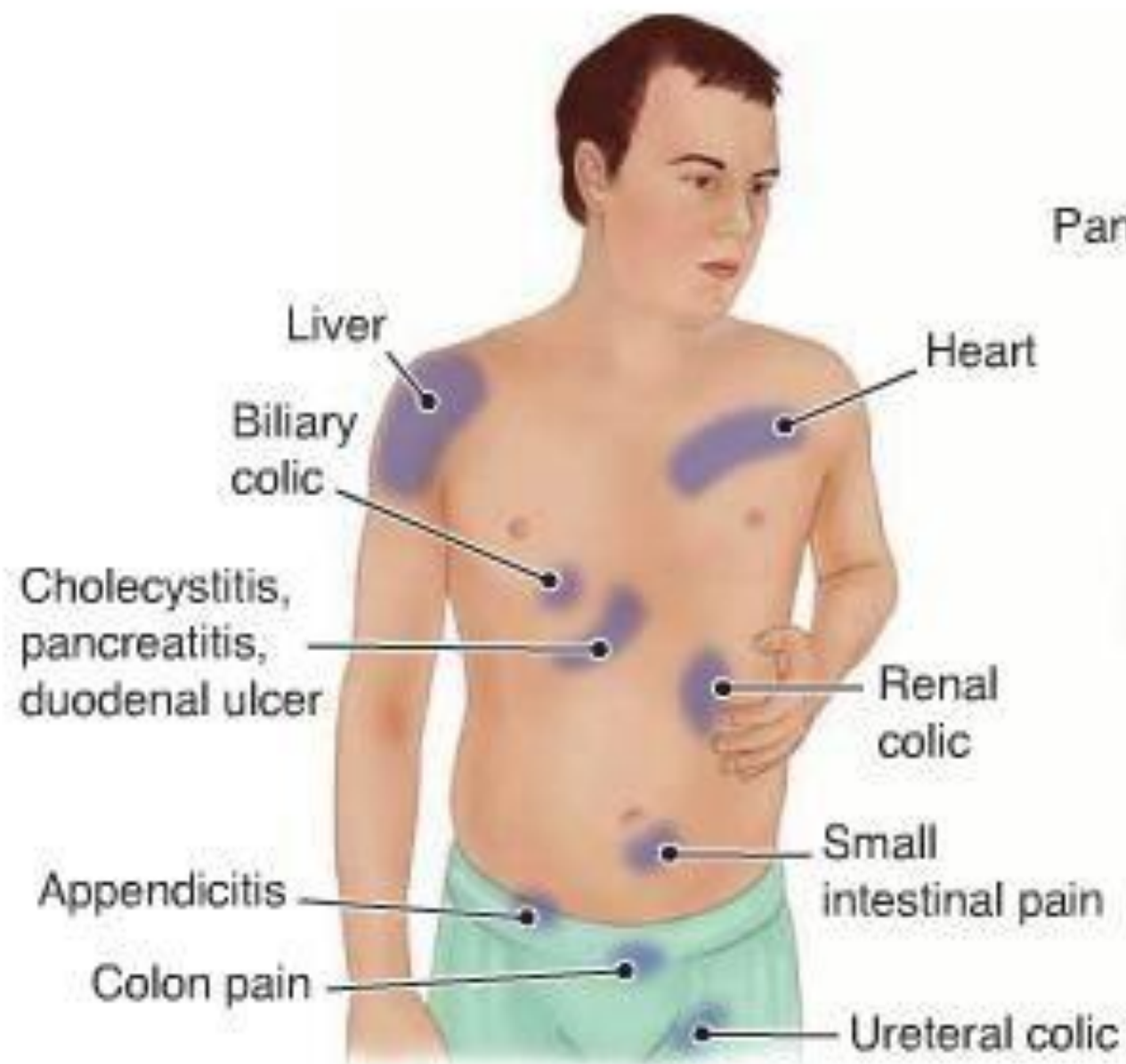
Constitutional symptoms: *fever / malaise / fatigue/ weight loss*

Key gastrointestinal symptoms:

Dysphagia / Odynophagia ,Nausea / vomiting , Gastroesophageal reflux, Abdominal distension ,constipation / diarrhoea ,jaundice /chills

Common Causes Of Abdominal Pain

<ul style="list-style-type: none"> Costochondritis Biliary colic (Gallstones) Gallbladder infection Pulled Muscles Hepatitis Kidney stone Pneumonia 	<ul style="list-style-type: none"> Acid Reflux Heartburn Heart Attack Gastritis Stomach Ulcer Duodenal Ulcer Pancreatitis Epigastric Hernia 	<ul style="list-style-type: none"> Pneumonia Costochondritis Spleen Infection Enlarged Spleen Hepatitis Kidney Stone Constipation Trapped Wind
<ul style="list-style-type: none"> Kidney Stone Kidney Infection Trapped Wind Constipation Pulled Muscle Appendicitis 	<ul style="list-style-type: none"> Stomach Ulcer Intestinal Obstruction Constipation Worm Infestation Crohns Disease Food Poisoning Trapped Wind Umbilical Hernia 	<ul style="list-style-type: none"> Constipation Trapped Wind Diverticulitis Irritable Bowel Syndrome Kidney Stone / Infection Crohns Ulcerative Colitis
<ul style="list-style-type: none"> Appendicitis Urine Infection Constipation Ectopic Pregnancy Mid Cycle Pain Pelvic Infection (PID) Endometriosis Ovarian Cyst Trapped Wind Hernia 	<ul style="list-style-type: none"> Trapped Wind Constipation Bladder Infection (Cystitis) Retention Of Urine Menstrual Cramps Endometriosis Pelvic Infection (PID) Fibroids Miscarriage Symphysis Pubis Dysfunction 	<ul style="list-style-type: none"> IBS Crohns Ulcerative Colitis Diverticulitis Constipation Trapped Wind Mid Cycle Pain Endometriosis Pelvic Infection Ovarian Cyst Ectopic Pregnancy Hernia



4) Past medical and surgical history: significant past diseases/illnesses, including complications, trauma, surgery, blood transfusion .

5) Drug history and Allergy: prescribed and over-the-counter, allergic reaction/ relievers.

6) Family history: especially parents, siblings and children.

7) Social history: smoking, alcohol, accommodation and living arrangements, marital status, baseline functioning, occupation, pets and hobbies.

8) Gynecological History : LMP, Pregnancy, abortion, delivery, illnesses.

9) Systems review: cardiovascular system, respiratory system, gastrointestinal system, nervous system, musculoskeletal system, genitourinary system



Abdominal examination

Raghad Almisfer

GENERAL APPEARANCE

- Unwell, pale , sweaty, lie flat on the bed, be , avoid movement .
- Jaundice, anemic
- Foetor oris
- Palpable lymph node
- Tonsillitis
- Chest : basal right side pneumonia
- Vital sign :
- Tem: high HR : tachycardia RR: tachypnea BP : hypotension

INSPECTION

- Abdominal distention : bowel obstruction
- Abdominal swellings: due to abnormal enlargement of the liver, kidneys or spleen
- Scars : adhesions
- umbilicus (Cullen's sign) and in the left flank (Grey Turner's sign).
- Bulge : hernia
- Dilated vein : portal hypertension, inferior vena cava occlusion
- Movement of abdomen with respiration : rigid abdomen peritonitis
- Reaction with cough and respiration
- Visible Peristalsis : bowel obstruction , pyloric stenosis

PALPATION

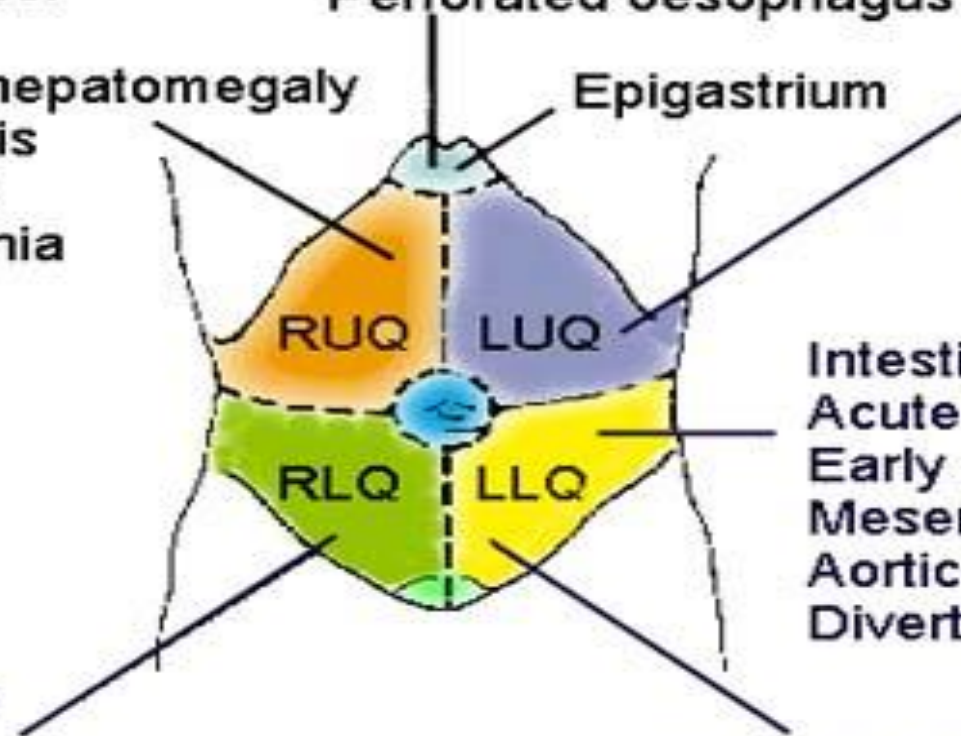
- Gentle palpation :
- Tenderness
- guarding: inflamed parietal peritoneum , acute cholecystitis , acute pancreatitis ,acute gastritis ,peptic ulcer ,acute diverticulitis
- Rigidity: peritonitis , perforated peptic ulcer

- Deep palpation:
- Rebound tenderness: peritonitis
- Palpable organs : splenomegaly sickle cell disease , palpable kidney : hydronephrosis : UTI
- Mass : stomach carcinoma , appendix mass abscess , acute diverticulitis , colon cancer ,TB , liver abscess
- Murphy's sign : acute cholecystitis
- Rovsing's sign

Acute cholecystitis
 Duodenal ulcer
 Hepatitis
 Congestive hepatomegaly
 Pyelonephritis
 Appendicitis
 (R) Pneumonia

Myocardial infarct
 Peptic ulcer
 Acute cholecystitis
 Perforated oesophagus

Ruptured spleen
 Gastric ulcer
 Aortic aneurysm
 Perforated colon
 Pyelonephritis
 (L) Pneumonia



Intestinal obstruction
 Acute pancreatitis
 Early appendicitis
 Mesenteric thrombosis
 Aortic aneurysm
 Diverticulitis

Appendicitis
 Salpingitis
 Tubo-ovarian abscess
 Ruptured ectopic pregnancy
 Renal/ureteric stone
 Incarcerated hernia
 Mesenteric adenitis
 Meckel's diverticulitis
 Crohn's disease
 Perforated caecum
 Psoas abscess

Sigmoid diverticulitis
 Salpingitis
 Tubo-ovarian abscess
 Ruptured ectopic pregnancy
 Incarcerated hernia
 Perforated colon
 Crohn's disease
 Ulcerative colitis
 Renal/ureteral stone

PERCUSSION

- Resonance: intestinal obstruction
- Loss of liver dullness: gastrointestinal perforation
- Dullness: free fluid, full bladder
- Shifting dullness: free fluid

AUSCULTATIONS

- Absent sounds: paralytic ileus
- Hyperactive sounds: mechanical obstruction, gastroenteritis
- Bruit: mesenteric ischemia

Vaginal examination : bi manual palpation of adnexa induce pain , pus from cervical canal , mass in one side tubo-ovarian abscess

Rectal examination: pain with examination
diverticulitis

Mass , blood



ABDOMINAL PAIN INVESTIGATIONS

Thekra Ibrahim Alolayan

General investigations

- FBC (Hb & WCC)
- Amylase (Pancreatitis)
- U&Es, LFTs
- Clotting (acute pancreatitis, sepsis, DIC, liver disease)
- Glucose (BM)
- G&S (X-match if necessary)
- ABG
- ECG

Continue

- Cardiac enzymes (if appropriate)
- Urinalysis
- Pregnancy test
- Radiology
 - -Erect CXR
 - -Supine AXR
 - -USS (gynae pathology)
 - -IVU (renal/ureteric colic)
 - -CT scanning
- Laparoscopy

EXAMINATION OF FAECES

- -MACROSCOPY
- a] Large, loose, bulky, frothy & offensive – malabsorption
- b] Greasy - steatorrhoea
- c] Blood & mucus – dysentery, ulcerative colitis, CA rectum
- d] Clay coloured – obstructive jaundice
- e] Dark – hemolytic jaundice
- f] Black & tarry – upper GI bleed
- g] Fresh blood – lower GI bleed
- -MICROSCOPY

CHEMICAL EXAMINATION

- a] occult blood
- b] faecal fat estimation
- c] faecal nitrogen

EXAMINATION OF VOMITUS

- A] undigested food – gastric outlet obstruction
- B] faecal odour - gastrocolic fistula , intestinal obstruction

ASCITIC FLUID EXAMINATION

- **1-APPEARANCE:**
- -Haemorrhagic – malignant ascites
- -Purulent – pyogenic peritonitis
- -Straw coloured - tuberculous peritonitis
- -Milky – chylous ascites

- **2-OTHER TESTS**

- **A] Serum ascites albumin gradient:**

- HIGH (>1.1 g/dl)-portal hypertension

- LOW (<1.1 g/dl)- TB peritonitis, malignancy, hypoproteinemia.

- **B] GASTRIC ACID STUDY**

- 3.7 ± 2.1 mEq/L , in males

- 2.2 ± 1.7 mEq/L , in females

- low output = gastric ulcer

- CA raised = duodenal ulcer, Z.E syndrome

RADIOLOGY

- 1-PLAIN RADIOGRAPH
- Indications:
 - a) a/c abdominal emergencies
 - b) to delineate radio opaque calculi
 - c) to detect organomegaly
- Features :
 - # Soft tissues
 - # Radio opaque calculi Foreign bodies , Calcified lymph nodes , Phleboliths , Calcification along aorta / its branches
 - # bowel obstruction, paralytic ileus – gas & multiple fluid levels# bowel perforation – gas seen under diaphragm – erect picture

- 2-CONTRAST STUDIES

- Indications :

- a) anatomical abnormalities

- b) abnormalities in motility

- -**BARIUM SWALLOW**: oesophagus

- -**BARIUM MEAL**: stomach & small intestine

- -**BARIUM ENEMA**: Large intestine

- -**DOUBLE CONTRAST TECHNIQUE**: gastric ulcer from carcinoma, duodenal ulcer.

- **3-ULTRASOUND:**
- -insensitive to intestinal lesions
- -ascites, local collections of fluid
- -pancreatic lesions

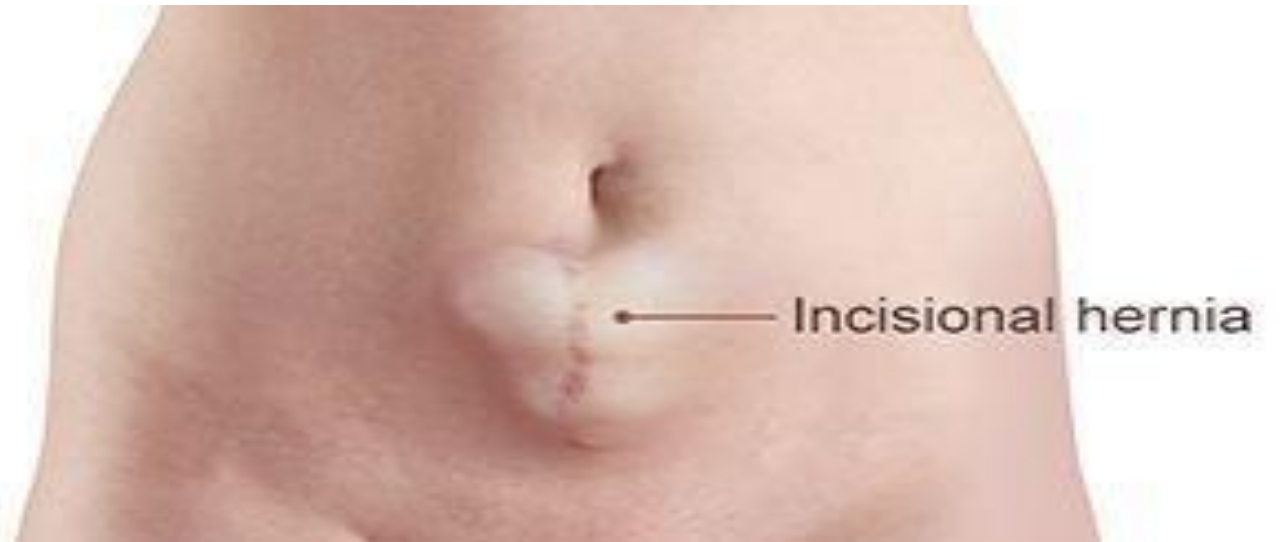- 4-ENDOSCOPY SIGMOIDOSCOPY:
- -Lesions up to splenic flexure
- -COLONOSCOPY: large intestinal lesions
- 5-OTHERS
- CT: Abscess, fluid, nodes
- MRI
- LAPAROSCOPY: peritoneum- inspected directly

Incisional hernia

Maha ALGhofaili

Definition

- bulge or protrusion at or near the area of a surgical incision.



Epidemiology

- The highest reported incidence is with midline abdominal incision
- Upper abdominal incision have a higher risk compared to lower abdominal
- Among patients with SSI 25% will develop an incisional hernia.

Causes

Are due to Failure of fascial tissues to heal and close which is related to:

- ▣ Mechanical factors

Increased intra abdominal pressure due to chronic cough ,constipation , urinary obstruction (BPH) and pregnancy.

- ▣ Patient factors

Infection, Malnutrition, chronic illness, smoking obesity, CTD and Steroid use.

- ▣ Technical factors

Technical issues during closure.

Clinical features

- ▣ Bulge at the site of previous incision , the lesion may become large with increased intra abdominal pressure.
- ▣ Aching sensation radiating into the area if incision.
- ▣ No pain or tenderness upon examination

Incarcerated

- ▣ Painful enlargement of the previous hernia
- ▣ Inability to manipulate the hernia
- ▣ N/V

Clinical features

Strangulated

- Symptoms of incarcerated hernia.
- systemic toxicity.

investigations

- Complete blood count (CBC) - Results are nonspecific, but leukocytosis with left shift may occur with strangulation
- Electrolyte, blood urea nitrogen (BUN), and creatinine levels - It is advisable to assess the hydration status of the patient with nausea and vomiting.
- Lactate levels - Elevation may reflect hypoperfusion; a normal level does not necessarily rule out strangulation

Treatment

Malak ALGhamdi

Indications to perform a hernia repair

- Symptoms such as pain and abdominal enlargement
- Risk of incarceration (hernia sacs with a small neck that contain bowel)

open repair of incisional hernias

- The weakened tissue of the abdominal wall is re-incised and a repair is reinforced using a prosthetic mesh

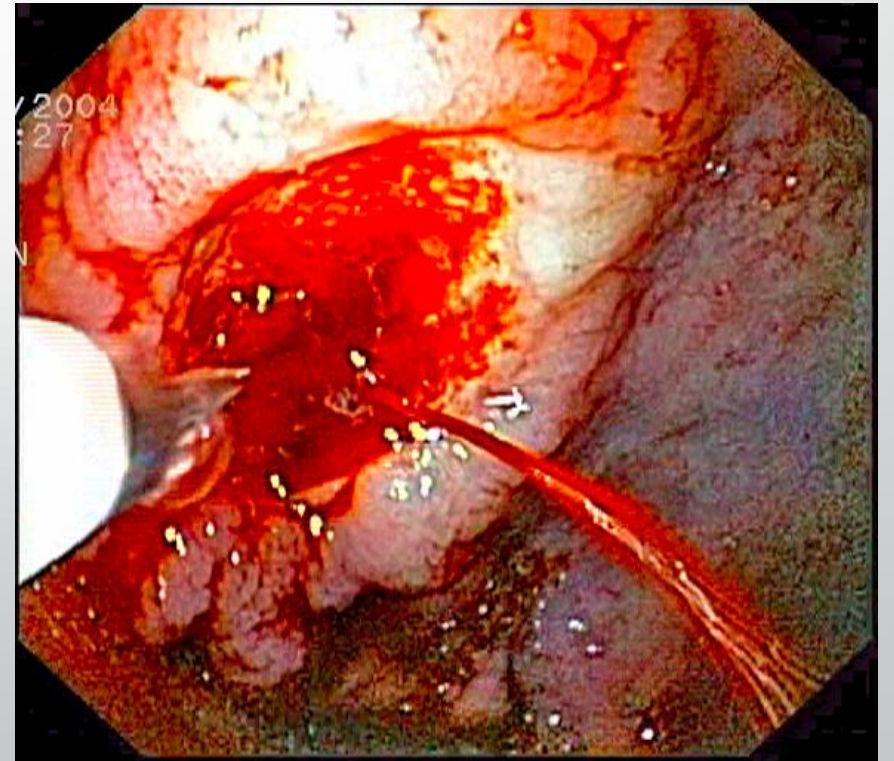
Complications:

- infection of the incision (A mesh infection requires a complete removal of the mesh and results in surgical failure)
- significant postoperative pain.
- recurrence rates after open repair are up to 20%

Laparoscopic incisional hernia repair

- surgical mesh is placed through small incisions to the side of the hernia.
- minimize the potential for wound complications such as infections
- less painful and speed recovery.
- the laparoscopic approach has been criticized for not resecting the hernia sac and not restoring the anatomy, thereby allowing the persistence of abdominal bulging

UPPER GASTROINTESTINAL BLEEDING



Background

- Acute gastrointestinal bleeding is a potentially life-threatening abdominal emergency that remains a common cause of hospitalization.
- Upper gastrointestinal bleeding (UGIB) is defined as bleeding derived from a source proximal to the ligament of Treitz.
- UGIB results in more than 300,000 hospital admissions annually in the US, with a mortality of 7% to 10%.
- The annual incidence in the United Kingdom is 50 to 150 per 100,000, with the highest incidence in socio-economically deprived areas. Ordinarily, mortality is secondary to hypovolaemic shock.

Etiology

- Patients with UGIB can typically be segregated into 2 groups: those with variceal lesions (either oesophageal or gastric) and those with non-variceal lesions (most commonly peptic ulcers).
- The most frequently encountered aetiologies of UGIB are as follows:
- PUD (35% to 50%)
- Gastroduodenal erosions (8% to 15%)
- Oesophagitis (5% to 15%)
- Varices (5% to 14%)
- Mallory-Weiss tears (15%)
- Vascular malformations, including aortoenteric fistulae (5%)
- Other conditions (e.g., malignancy, coagulopathy) constitute the remainder.

Oesophagitis (10%)
Usually with hiatus hernia

NSAIDs *H. pylori*
↓ ↓
Peptic ulcer (35-50%)

Vascular malformations (5%)

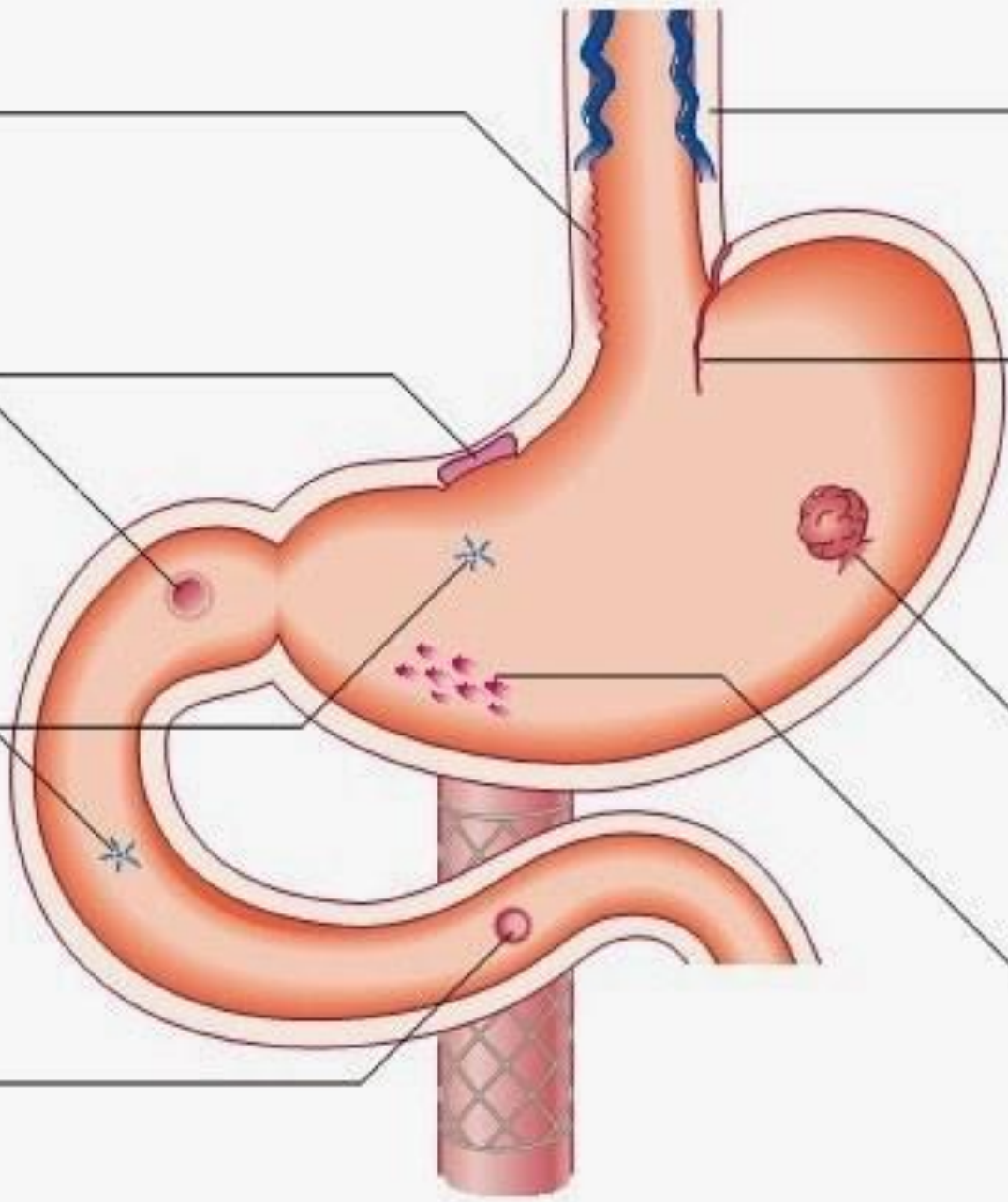
Aortic graft
↓
Aorto-duodenal fistula (0.2%)

Liver Portal vein disease thrombosis
↓ ↓
Varices (2-9%)

Retching
↓
Mallory-Weiss tear (5%)

Cancer of stomach or oesophagus (2%)

NSAIDs Alcohol
↓ ↓
Gastric erosions (10-20%)





Clinical presentation

HISTORY

- **Nausea and vomiting**

Coffee-ground emesis is suggestive of a slower, possibly intermittent bleed, and melaena with UGIB rather than with lower GI bleeding (LGIB).

Conversely, brisk haematemesis is suggestive of an actively bleeding lesion, most often a variceal bleed (especially in patients with signs of liver disease or portal hypertension)

UGIB starting after vomiting or retching is suggestive of a Mallory-Weiss tear



- **Melena**

Melena is overwhelmingly associated with UGIB.

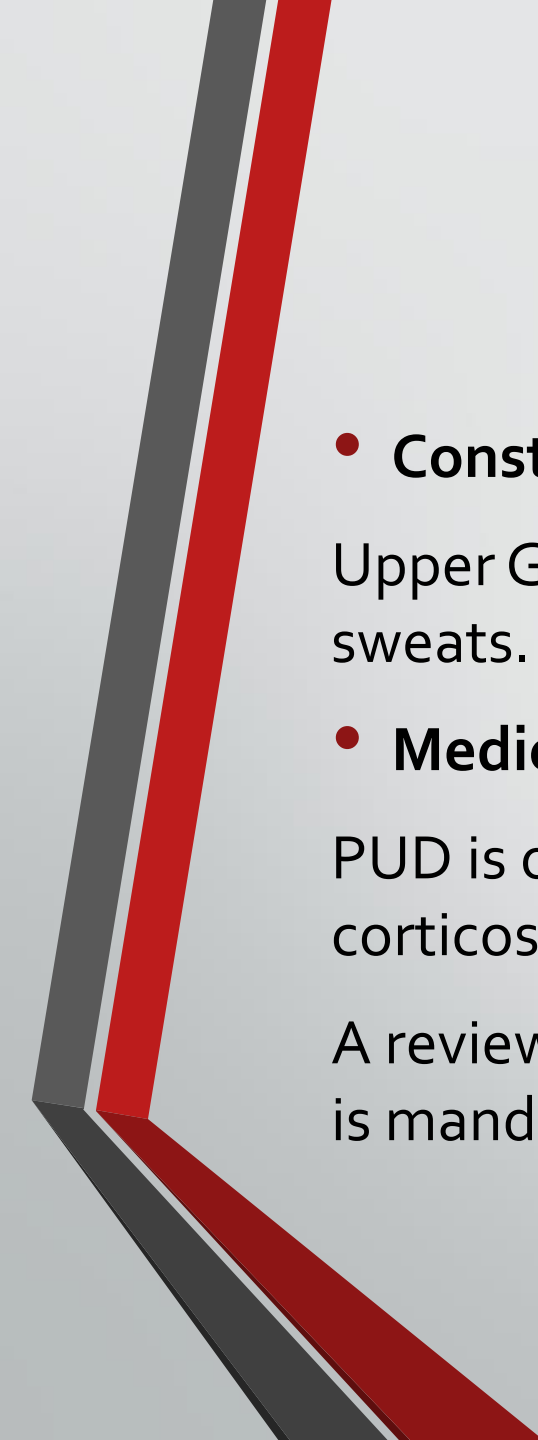
Melaena by itself is not reason enough to obtain an emergency endoscopy, but quantifying the amount of melaena can still be helpful for triaging patients.

bismuth-containing products (e.g., Pepto-Bismol) and iron supplements can make the appearance of stools dark or black. A digital rectal examination, including a faecal occult blood test, must be conducted.



- **Haematochezia**

Haematochezia is more often seen in LGIB than in UGIB. However, bright red blood per rectum can be seen in a brisk UGIB where the rapidity of the transit time precludes any digestion.



- **Constitutional symptoms**

Upper GI tumours can be associated with involuntary weight loss or night sweats.

- **Medications**

PUD is often caused by the use of NSAIDs, alone or in combination with corticosteroids and/or antiplatelet or anticoagulant agents.

A review of the patient's medications to identify potentially causative agents is mandatory.



- **History of alcoholism or chronic liver disease**

Conditions causing portal hypertension predispose patients to developing varices. Any history of chronic and excessive alcohol use, intravenous drug use (or other behaviour that places people at risk of contracting hepatitis), or underlying liver disease strongly suggests a variceal bleed and proper precautions (i.e., intravenous octreotide) are warranted.

- **Other medical history**

Oesophagitis is often seen in the context of long-standing heartburn

Any prior history of PUD makes a recurrence more likely.

AVMs are associated with cirrhosis, end-stage renal disease, advanced age, and von Willebrand's disease.

A history of a vascular graft or aortic aneurysm should markedly heighten clinical suspicion for aortoenteric fistulae.

Coagulopathy should be considered with history of genetic abnormalities of clotting (e.g., haemophilia, von Willebrand's disease).

- **Social history**

Aside from NSAID use, PUD can also frequently be caused by underlying *Helicobacter pylori* infection. It is important to assess the risk of *H pylori* infection.

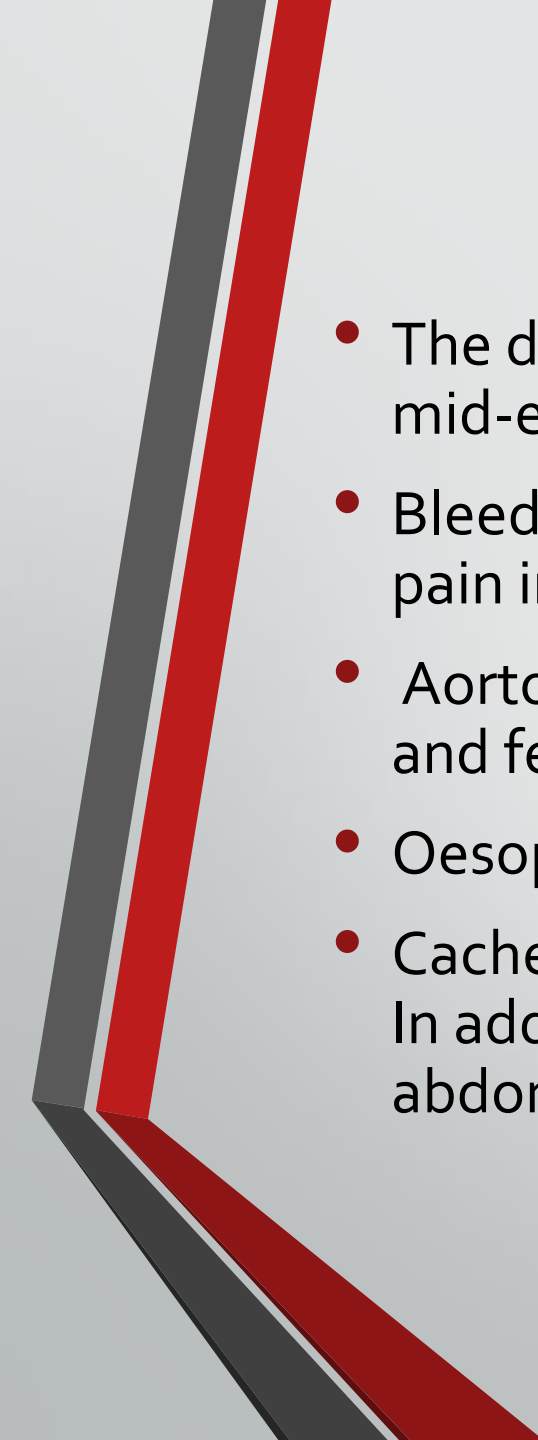
PHYSICAL EXAMINATION

- **Vital signs**

can be used to estimate the patient's volume status. tachycardia with hypotension should trigger aggressive volume resuscitation. If the patient is stable, orthostatic BPs should be obtained. Capillary refill, moisture in the mucous membranes, and absence of pallor can also assist in assessing the degree of anaemia/hypovolaemia

- **Digital rectal examination**

Mandatory. Visual inspection of the perineum can rule out the presence of external haemorrhoids. Faecal occult blood testing should be conducted.

- 
- The degree, location, and character of pain and discomfort can be helpful. mid-epigastric tenderness to palpation is common.
 - Bleeding is sometimes accompanied by mid-epigastric pain or retrosternal pain in patients with a Mallory-Weiss tear.
 - Aortoenteric fistulae can present with significant abdominal or back pain and fever.
 - Oesophagitis is sometimes associated with hoarseness.
 - Cachexia should heighten concern for a GI tumour or other type of tumour. In addition, patients with upper GI tumours sometimes have a palpable abdominal mass and/or enlarged liver.

Workup

- Approach :
 - A complete blood cell (CBC) count with platelet count and differential is necessary to assess the level of blood loss in a patient with upper gastrointestinal bleeding. Where possible, having the patient's previous results is useful to gauge this loss. CBC should be checked frequently (q4-6h) during the first day.
 - Assessing patients' calcium levels is useful in identifying individuals with hyperparathyroidism as well as in monitoring calcium in patients receiving multiple transfusions of citrated blood. Hypercalcemia increases acid secretion.
 - A gastrin level may identify the rare patient with gastrinoma as the cause of UGIB and multiple ulcers.

Workup

- An electrocardiogram (ECG) should be ordered to exclude arrhythmia and cardiac disease, especially acute myocardial infarction due to hypotension.
- Esophagogastroduodenoscopy may increase the risk of arrhythmias.
- Performing a troponin test may be useful in identifying patients with severe coronary ischemia or atypical myocardial infarction.
- orthostatic testing should be performed to assess and document a hypovolemic state. A positive tilt test finding is defined as an SBP decrease of 10 mm Hg and a pulse rate increase of 20 bpm with standing compared to the supine position.

Workup

- Assessment of hemorrhagic shock
 - defined as a pulse rate >100 bpm or SBP < 100 mm Hg
 - patients who present in hemorrhagic shock have a mortality rate of up to 30%.

Hemorrhage may be classified based on the amount of blood loss, as noted in the following table.

Table 2. Estimated Fluid and Blood Losses in Shock

	Class 1	Class 2	Class 3	Class 4
Blood Loss, mL	Up to 750	750-1500	1500-2000	>2000
Blood Loss,% blood volume	Up to 15%	15-30%	30-40%	>40%
Pulse Rate, bpm	< 100	>100	>120	>140
Blood Pressure	Normal	Normal	Decreased	Decreased

Workup

- Hemoglobin Value and Type and Crossmatch Blood
 - Based on the patient's initial hemoglobin level and clinical assessment of shock, a type and screen or type and crossmatch should be ordered.
 - The patient should be crossmatched for 2-6 units, based on the rate of active bleeding. The hemoglobin level should be monitored serially in order to follow the trend
 - Patients with significant comorbid conditions (eg, advanced cardiovascular disease) should receive blood transfusions to maintain myocardial oxygen delivery to avoid myocardial ischemia.
 - One of the criteria used to determine the need for surgical intervention is the number of units of transfused blood required to resuscitate the patient. The more units required, the higher the mortality rate. Operative intervention is indicated once the blood transfusion number reaches more than 5 units

Workup

- BMP, BUN, and Coagulation

- The basic metabolic profile (BMP) is useful in evaluating for renal comorbidity; however, blood in the upper intestine can elevate the BUN level as well. Measurement of coagulation parameters is necessary to assess for continued bleeding. Abnormalities should be corrected rapidly.
- The BUN-to-creatinine ratio increases with upper gastrointestinal bleeding. A ratio of greater than 36 in a patient without renal insufficiency is suggestive of UGIB.
- The patient's prothrombin time (PT), activated partial thromboplastin time (PTT), and international normalized ratio (INR) should be checked to document the presence of coagulopathy. The coagulopathy may be consumptive and associated with a thrombocytopenia.
- A platelet count of less than 50 with active acute hemorrhage requires a platelet transfusion and fresh frozen plasma in an attempt to replete lost clotting factors.

Workup

- Endoscopy
 - Endoscopic examination of the upper GI tract provides useful information regarding the source and site of bleeding.
 - Endoscopy should be performed immediately after endotracheal intubation (if indicated), hemodynamic stabilization, and adequate monitoring in an intensive care unit (ICU) setting have been achieved.



Endoscopic findings and their incidence rate in patients with upper GI bleeding (UGIB) include the following

- ❖ Duodenal ulcer - 24.3%
- ❖ Gastric erosion - 23.4%
- ❖ Gastric ulcer - 21.3%
- ❖ Esophageal varices - 10.3%
- ❖ Mallory-Weiss tear - 7.2%
- ❖ Esophagitis - 6.3%
- ❖ Duodenitis - 5.8%
- ❖ Neoplasm - 2.9%
- ❖ Stomal (marginal) ulcer - 1.8%
- ❖ Esophageal ulcer - 1.7%
- ❖ Other/miscellaneous - 6.8%

Workup

- Chest radiographs
 - Chest radiographs should be ordered to exclude aspiration pneumonia, effusion, and esophageal perforation; abdominal scout and upright films should be ordered to exclude perforated viscus and ileus.
- Computed Tomography Scanning
 - the evaluation of liver disease for cirrhosis,
 - cholecystitis with hemorrhage,
 - pancreatitis with pseudocyst and hemorrhage,
 - aortoenteric fistula (images may reveal thickened bowel, perigraft fluid collection, extraluminal gas, or inflammatory changes in the area of the duodenum and the aortic graft).
- Angiography
 - Angiography may be useful if bleeding persists and endoscopy fails to identify a bleeding site.

Workup

- Nasogastric Lavage

- A nasogastric tube is an important diagnostic tool, and tube placement can reduce the patient's need to vomit.
- This procedure may confirm recent bleeding (coffee ground appearance), possible active bleeding (red blood in the aspirate that does not clear), or a lack of blood in the stomach (active bleeding less likely but does not exclude an upper GI lesion).
- The characteristics of the nasogastric lavage fluid (eg, red, coffee grounds, clear) and the stool (eg, red, black, brown) can indicate the severity of the hemorrhage. Red blood with red stool is associated with an increased mortality rate from more active bleeding compared with negative aspirate findings with brown stool.

Table 4. Effect of the Color of the Nasogastric Aspirate and of the Stool on UGIB Mortality Rate

Nasogastric Aspirate Color	Stool Color	Mortality Rate, %
Clear	Brown or red	6
Coffee-ground	Brown or black	8.2
	Red	19.1
Red blood	Black	12.3

Workup

- Histologic Findings

- The bleeding vessel lies in the deepest layer of the ulcer. Fibrinoid necrosis is observed at the site of perforation of the vessel. Pseudoaneurysmal dilation of the vessel may be present at the site of perforation. Biopsy samples should be taken from the edge of a gastric ulcer to rule out carcinoma.
- The characteristic lesion of H pylori is chronic active gastritis with the organisms observed after routine staining. The lesion of gastric antral vascular ectasia is capillary dilation with fibrin clots and fibromuscular hyperplasia.

Management

- The goal of medical therapy in upper gastrointestinal bleeding (UGIB) is to correct shock and coagulation abnormalities and to stabilize the patient so that further evaluation and treatment can proceed. High doses of proton pump inhibitors may reduce the need for endoscopic therapy
- Resuscitation of a hemodynamically unstable patient begins with assessing and addressing the ABCs (ie, airway, breathing, circulation) of initial management.


Management


- Pulmonary artery catheters may be helpful to guide therapy. Foley catheter placement is mandatory to allow a continuous evaluation of the urinary output as a guide to renal perfusion. T
- Once the maneuvers to resuscitate are underway, insert a nasogastric tube and perform an aspirate and lavage procedure.
- Once the ABCs have been addressed, Consultation with a surgeon should be considered for all patients with gastrointestinal hemorrhage.



- Treatment include the following

- Treatment includes the following:
- Secure the airway
- Insert bilateral, 16-gauge (minimum), upper extremity, peripheral intravenous lines
- Replace each milliliter of blood loss with 3 mL of crystalloid fluid
- In patients with severe coexisting medical illnesses, pulmonary artery catheter insertion for monitoring hemodynamic cardiac performance
- Foley catheter placement for continuous evaluation of urinary output as a guide to renal perfusion
- Endoscopic hemostatic therapy for bleeding ulcers and varices
- Surgical repair of perforated viscus
- For high-risk peptic ulcer patients, high-dose intravenous proton pump inhibitors

- 
- Indications for surgery in patients with bleeding peptic ulcers include the following:
 - Severe, life-threatening hemorrhage not responsive to resuscitative efforts
 - Failure of medical therapy and endoscopic hemostasis with persistent recurrent bleeding
 - A coexisting reason for surgery (eg, perforation, obstruction, malignancy)
 - Prolonged bleeding, with loss of 50% or more of the patient's blood volume
 - A second hospitalization for peptic ulcer hemorrhage

- 
- Treatment-related contraindications and precautions
 - Ideally, the patient should be stabilized prior to endoscopy and abnormalities in coagulation should be corrected. When this is not possible, the judgment of an experienced endoscopist is vital.
 - Contraindications to upper endoscopy include an uncooperative or obtunded patient, severe cardiac decompensation, acute myocardial infarction (unless active, life-threatening hemorrhage is present), and perforated viscus (eg, esophagus, stomach, intestine).
 - Contraindications to emergency surgery include impaired cardiopulmonary status and bleeding diathesis.

References

- <http://emedicine.medscape.com/article/187857-overview>



Thank you