



# Esophageal diseases

## Objectives:

1. Surgical anatomy.
2. Symptoms of esophageal diseases: a. Dysphagia | b. Pain. | c. Regurgitation.
3. Examination.
4. Investigation: a. Blood test. | b. Radiology. | c. Endoscopy. | d. Computed tomography. | e. Ultrasonography. | f. Laparoscopy. | G. Manometry and pH studies.
5. Impacted foreign bodies.
6. Corrosive oesophagitis.
7. Perforation.
8. Motility disorder: a. Achalasia. | b. Diffuse esophageal spasm. | c. Nutcracker oesophagus.
9. Plummer-vinson syndrome.
10. Pouches.
11. Gastro-oesophageal reflux: a. Hiatus hernia. | b. Barrett's oesophagus.
12. Tumours of the oesophagus: a. Benign tumours. | b. Carcinoma of the oesophagus.

## Resources:

- Davidson's.
- Slides
- Surgical recall.
- Raslan's notes.

**Done by:** Lamyia Alsaghan & Rana Albarrak

**Sub-leader:** Omar Alotaibi

**Leaders:** Abdulrahman Alsayyari & Monerah Alsalouli

**Reviewed by:** Luluh Alzaghayer

[ [Color index](#) | [Important](#) | [Notes](#) | [Extra](#) ]

[ [Editing file](#) | [Feedback](#) | [Share your notes](#) | [Shared notes](#) ]

Once you stop learning  
you start dying.

## Basic review:

• **Length:** about 25 cm long

• **Extension:**

(1) starts at cricoid cartilage - **C6** (2) passes through the diaphragm to join the stomach at **T10** (3) final 2-4 cm lie within the peritoneal cavity, terminates at **T11** by entering the cardiac orifice of the stomach.

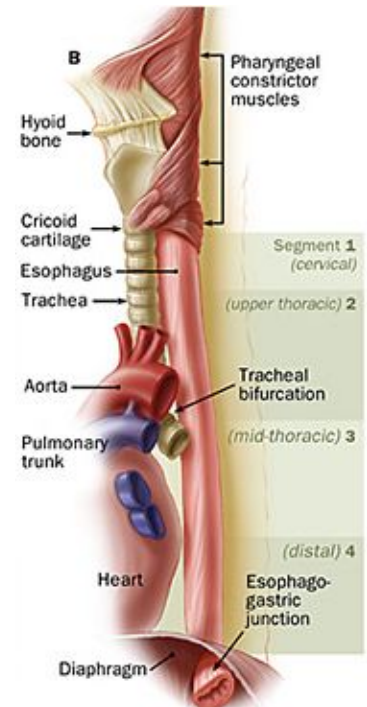
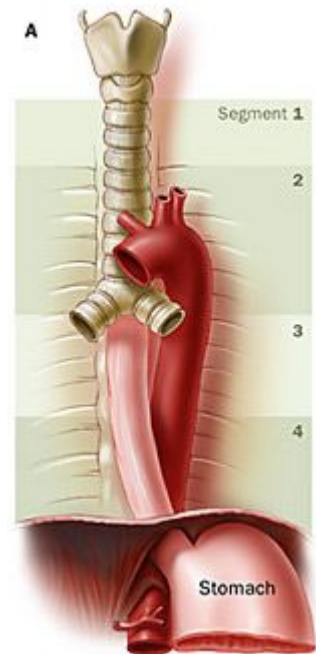
• The esophagus is a tubular structure with **four** layers:

Mucosa	Submucosa	Musculosa externa	Outer layer
Lined by Non-Keratinized stratified squamous epithelium.	Mucous glands and lymphatics. [Meissner's plexus: nerve fibers and nerve cells]	<u>Outside:</u> longitudinal [Auerbach's (myenteric) plexus in between the 2 layers] <u>Inside:</u> circular • <b>Upper</b> 1/3: both are skeletal. • <b>Middle</b> 1/3: inner is smooth, outer is skeletal. • <b>Lower</b> 1/3: both are smooth.	<b>Adventitia:</b> upper two thirds <b>Serosa:</b> lower one third

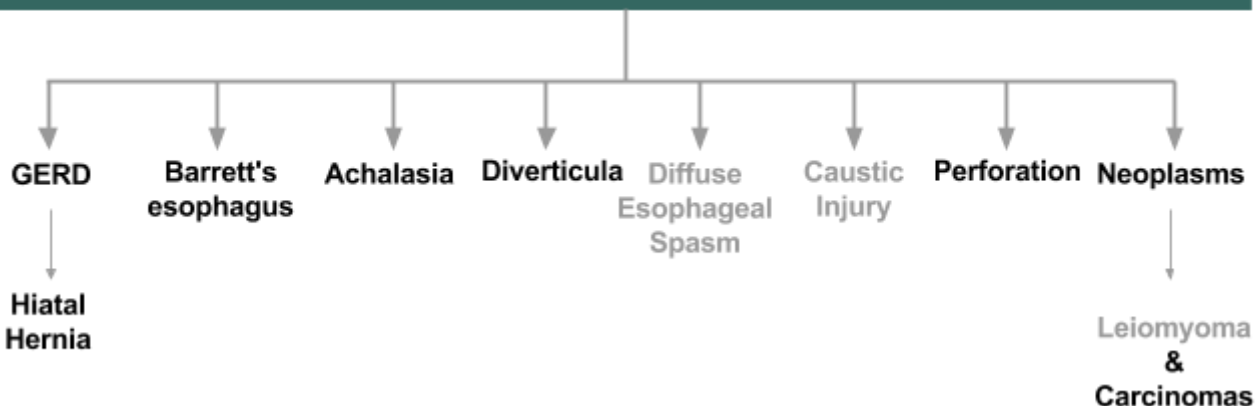
• **Parts:** cervical, thoracic and abdominal portions.

Region	Cervical	Thoracic	Abdominal
<b>Arterial supply</b>	Inferior thyroid artery	<b>Thoracic aorta</b> (bronchial arteries and branches)	Inferior phrenic & <b>left gastric arteries</b> (from celiac trunk)
<b>Venous drainage</b>	Inferior thyroid veins	Hemiazygos & <b>azygos</b> veins (systemic circulation).	Left gastric vein (portal circulation) Note: Connection between these veins are important in the formation of varices.
<b>Lymph drainage</b>	Deep cervical nodes.	Superior & inferior mediastinal nodes.	Celiac lymph nodes
<b>Nerve supply</b>	<u>Sympathetic:</u> preganglionic (T5&T6)   postganglionic (cervical & coeliac ganglia) <u>Parasympathetic:</u> glossopharyngeal   <b>vagus</b> and recurrent laryngeal nerves		
<b>Constrictions</b>	<b>Pharyngeal-esophageal</b> At junction with pharynx.	<b>Aorto-bronchial</b> Crossing of aortic arch & left main bronchus	<b>Diaphragmatic (LES)</b> At junction with stomach

- Esophagus has two sphincters:
  - **Upper sphincter:** cricopharyngeus.
  - **Lower sphincter:** cannot be defined anatomically, 3-5 cm high-pressure area located in the region of esophageal hiatus of the diaphragm.



## Esophageal diseases



**Note:** last 5 pages are **extra** questions and clinical micro-vignettes. Check them out if you can!

⊘ The ones in **Grey** Dr. Sami did not explain during the lecture **but mentioned in the slides & objectives.**

# GASTROESOPHAGEAL REFLUX DISEASE

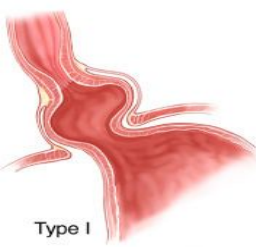
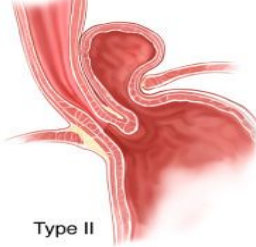
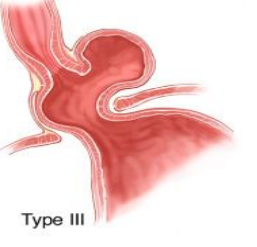

## Definition

It is often a chronic and relapsing condition characterized by **symptoms OR mucosal damage produced by abnormal reflux of gastric contents** into the esophagus when **pressure of the high-pressure zone in the distal esophagus is too low to prevent gastric contents from entering the esophagus.**

(LES has the primary role of preventing reflux)

- GERD is often associated with a **hiatal hernia**: sliding, rolling and mixed.

### Types of hiatal hernias

Type I <sup>1</sup>	Type II	Type III	Type IV
<b>Sliding Hiatal Hernia</b>	<b>Rolling (paraesophageal) Hernias (10%)</b>		
<b>Most common (90%)</b>	<b>No acid reflux</b>	May be associated with GERD	
1. Portion of the stomach cardia slides through the diaphragmatic hiatus. 2. Gastroesophageal junction lay within chest cavity resulting in negative pressure in the chest. 3. Pressure will keep LES opened → reflux of acid  <b>(Strong association with GERD) .</b>	Localized defect in the phrenoesophageal membrane while the <b>gastroesophageal junction remains fixed</b> to the preaortic fascia and the median arcuate ligament. <b>The gastric fundus then serves as the leading point of herniation.</b>	Have elements of <b>both types I and II hernias</b>	Associated with a <b>large defect</b> in the phrenoesophageal membrane, <b>allowing other organs, such as colon, spleen, pancreas and small intestine to enter the hernia sac.</b>
			
Type I	Type II	Type III	Type IV

## Clinical features of hiatal hernias

- **Heartburn** (pyrosis) and **regurgitation** → caused by reflux of acid.
- **Esophagitis** → persistent acid reflux → **ulceration, bleeding** with anemia, fibrosis, strictures formation.
- **Epigastric and lower chest pain** especially in paraesophageal hernias → may be a medical emergency<sup>2</sup>.
- **Palpitations & hiccups** → caused by mass effect of the hernia irritating the pericardium & diaphragm.

<sup>1</sup> you will be asked about this type in the exam :)

<sup>2</sup> owing to the obstruction and strangulation of the stomach.

### List the mechanisms by which the lower esophageal sphincter prevent acid reflux?

- Physiological high pressure zone (not true sphincter).
- Mucosal rosette at the cardia which acts as a plug.
- Angles of His<sup>3</sup>.
- Diaphragmatic sling (crura).
- High pressure area at the lower end of the esophagus caused by positive intra-abdominal pressure.

### Clinical Presentations of GERD

- Patients who **lack typical** symptoms you may see the following complications:
  - **Asthma** → caused by aspiration of acid.
  - **Hoarseness** → caused by irritation of vocal cords caused by acid reflux.

“Classic” GERD	Extravesophageal Manifestations of GERD		
	Pulmonary	ENT	Others
<ul style="list-style-type: none"> <li>• <b>Heartburn</b> and/or <b>regurgitation</b>:</li> <li>- Postprandial.</li> <li>- Aggravated by change of position</li> <li>- Prompt relief by antacid.</li> </ul>	<ul style="list-style-type: none"> <li>• <b>Asthma.</b></li> <li>• <b>Aspiration pneumonia.</b> <ul style="list-style-type: none"> <li>• Chronic bronchitis.</li> <li>• Pulmonary fibrosis.</li> </ul> </li> </ul>	<ul style="list-style-type: none"> <li>• <b>Hoarseness.</b></li> <li>• <b>Chronic cough.</b> <ul style="list-style-type: none"> <li>• Laryngitis.</li> <li>• Pharyngitis.</li> <li>• Globus Sensation.</li> <li>• Dysphonia.</li> <li>• Sinusitis.</li> <li>• Subglottic Stenosis.</li> <li>• Laryngeal Cancer.</li> </ul> </li> </ul>	<ul style="list-style-type: none"> <li>• <b>Nasuea</b></li> <li>• <b>Occasional vomiting</b></li> <li>• <b>Waterbrash (hypersalivation)</b></li> <li>• <b>Epigastric pain</b> <ul style="list-style-type: none"> <li>• Chest Pain</li> <li>• Dental Erosion.</li> </ul> </li> </ul>

### Complicated GERD

- **Dysphagia**: difficulty swallowing (food sticks or hangs up, mainly caused by strictures)
- **Odynophagia**<sup>4</sup>: pain with swallowing (caused by ulcers in the esophagus)
- **Bleeding.**
- **Barrett's esophagus** (columnar metaplasia with goblet cells): metaplasia without goblet cells is not BE.

### Diagnostic Tests for GERD

Diagnosis is made by (1) good history (2) endoscopy (3) sometimes a 24-hour esophageal pH study. If young + NO alarming symptoms → empirical treatment may be appropriate without doing any investigations.

- Barium swallow<sup>5</sup>.
- **Endoscopy**: to diagnose and rule out complications
- **Ambulatory pH manometry** “**most diagnostic**”: 24-hour-pH monitor.
- **Esophageal manometry** to know the motility of the esophagus usually done before surgery
- CXR is normal unless it's complicated.

### Barium types (EXTRA)

Barium swallow	Barium meal	Barium follow through	Small intestine enema	Barium enema
to examine pharynx and <b>esophagus</b> can detect narrowing (stricture), hiatal hernias, tumours, GERD, disorders of swallowing.	to examine <b>stomach and duodenum</b> can detect ulcers, small fleshy lumps (polyps), tumours, etc.	to examine <b>small intestine</b> . drink the barium liquid & wait 10-15 min before X-ray can detect ulcers, small fleshy lumps (polyps), tumours, etc.	to examine <b>small intestine</b> barium is poured through the small intestine by NGT can detect ulcers, small fleshy lumps (polyps), tumours, etc.	to examine <b>colon</b> can detect ulcers, small fleshy lumps (polyps), tumours, etc.

<sup>3</sup> An acute angle created between the cardia at the entrance to the stomach, and the esophagus.

<sup>4</sup> In general, may be due to a mechanical obstruction or intrinsic dysmotility.

<sup>5</sup> Barium swallow in general is used: if endoscopy is unavailable, patient is not candidate, to exclude pharyngeal pouch & perforation, complementary to endoscopy (provide additional anatomical information ex, hiatal hernia).

## Treatment

### • Lifestyle Modifications:

- Elevate head of bed 4-6 inches.
- Avoid eating within 2-3 hours of bedtime.
- Lose weight if overweight.
- Stop smoking.
- Modify diet
  - Eat more frequent but smaller meals.
  - Avoid fatty/fried food, peppermint, chocolate, alcohol, carbonated beverages, coffee & tea.
- OTC (over-the-counter) medications prn<sup>6</sup> (as needed).

### • Acid Suppression Therapy for GERD:

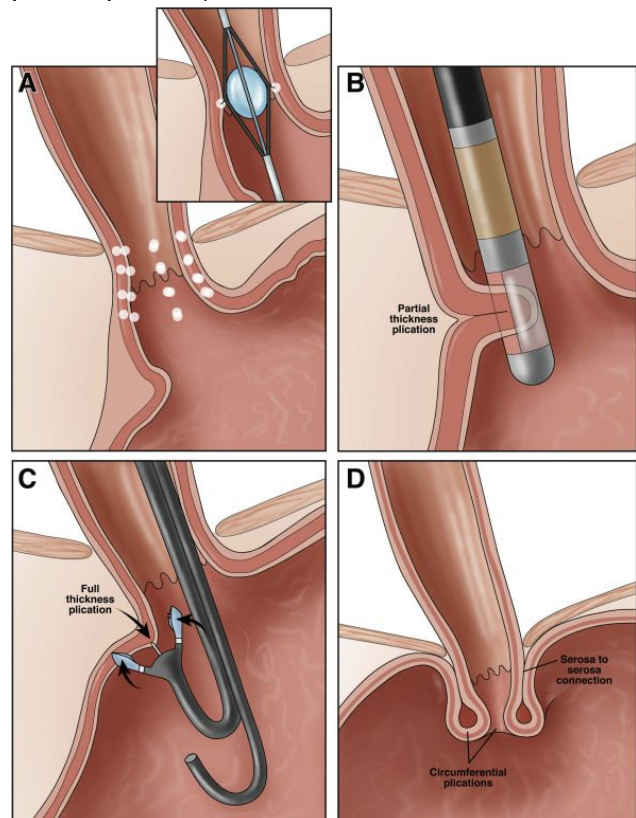
H2 Receptor Antagonists (H2RAs)	Proton Pump Inhibitors (PPIs) “more effective”
Cime <b>tidine</b> (Tagamet®) Ranitidine (Zantac®) Famotidine (Pepcid®) Nizatidine (Axid®)	Ome <b>prazole</b> (Prilosec®) Lansoprazole (Prevacid®) Rabep <b>razole</b> (Aciphex®) Pantop <b>razole</b> (Protonix®) E <b>so</b> meprazole (Nexium®)

### • Anti-Reflux Surgery: “Indications for Surgery”

- **Failed medical management**; usually due to high volume acidic reflux.
- **Patient's preference** despite successful medical management (due to lifestyle considerations)<sup>7</sup>
- **Complications of GERD** (e.g. Barrett's esophagus; grade III or IV esophagitis)
- **Complications of large hiatal hernia** (e.g. bleeding, dysphagia).
- **Atypical symptoms** (asthma, hoarseness, cough, chest pain, aspiration) and reflux documented on 24-hour pH monitoring.

### • Endoscopic GERD Therapy:

- A. Stretta procedure:** Radiofrequency energy delivered to the LES.
- B. Endoscopic plication:** Suture ligation of the cardia.
- C. Enteryx:** Submucosal implantation of inert material in the region of the lower esophageal sphincter.
- D. Nissen fundoplication “most common”:** Gastric fundus wrapped around the lower esophageal sphincter



<sup>6</sup> Abbreviation meaning "when necessary" (from the Latin "pro re nata")

<sup>7</sup> Including age, time or expense of medications, etc.

# BARRETT'S ESOPHAGUS

## Definition

A condition whereby a columnar epithelium replaces the stratified squamous epithelium that normally lines the distal esophagus (**intestinal metaplasia**).

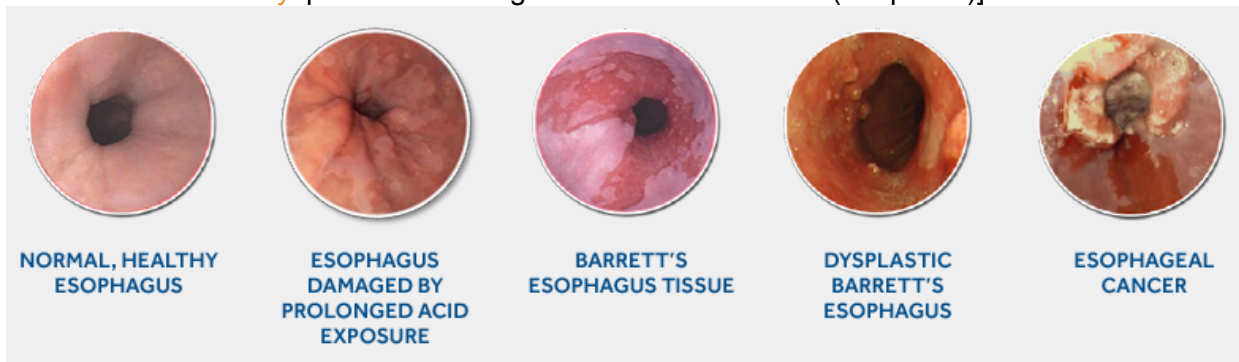
Surface epithelium of Barrett's esophagus: columnar epithelium **WITH** goblet cells!

## Risk Factors

### • Chronic GERD:

- Injury of squamous epithelium → promotes repair through columnar metaplasia.
- Metaplastic cells may be **more resistant to injury** from reflux and are **more prone to malignancy**.

[continuous exposure to GERD (esophagitis + hyperplasia) → Barrett's esophagus (intestinal metaplasia) → dysplasia -low or high- → adenocarcinoma (neoplasia)]



- 10% of patients with GERD develop Barrett's esophagus.
- **More common in men | aged 55 to 63 years.**
  - Incidence of **adenocarcinoma** of the esophagus men > women.
  - Women with **BE** are increasing in number (diminished differences in lifestyles among men & women).
- 40-fold increase risk for developing **esophageal carcinoma** in patients with **Barrett's esophagus**.

## Symptoms

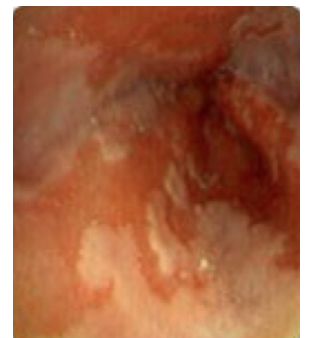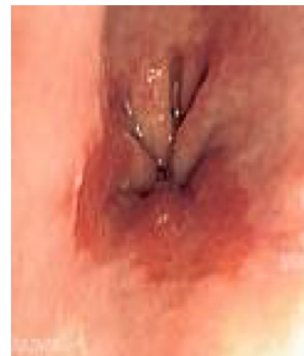- Many patients are asymptomatic.
- Most patients present with **symptoms of GERD**: Heartburn, regurgitation, acid or bitter taste in the mouth, excessive belching<sup>8</sup>, and indigestion.
- Recurrent respiratory infections, adult asthma, & infections of head & neck are common.

## Diagnosis

- Diagnosis is made by: **Endoscopy & histopathology**
  - **Endoscopy**: shows visible segment of columnar mucosa within the esophagus.
  - **Pathology** (biopsy): identifies intestinal metaplasia.

**White area** → normal lining of the esophagus (stratified squamous)

**Erythema** in between → most probably is intestinal metaplasia (simple columnar with goblet cells) should be confirmed with microscope "biopsy"



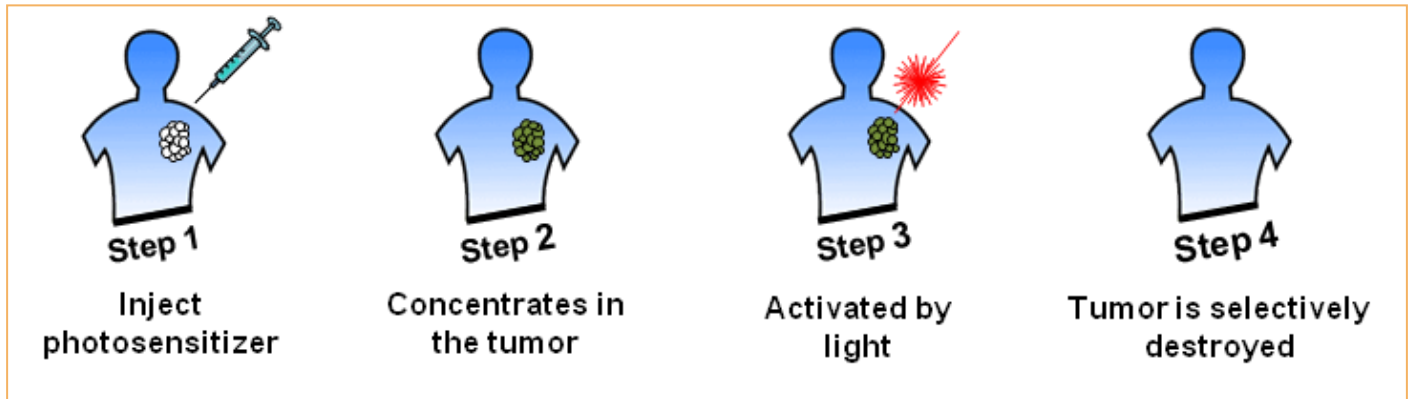
<sup>8</sup> Burping

## Treatment

### • Barrett's esophagus

1. **Yearly surveillance endoscopy** is recommended in all patients. Patients are placed on acid suppression medication and monitored for changes in their reflux symptoms.
2. **Photodynamic therapy (PDT)** is the most common ablative method used to treat BE.

### Photodynamic therapy (PDT)



### • Low-grade dysplasia

1. **Surveillance endoscopy**
  - 6-months intervals for the first year.
  - Annually after the first year if there has been no changes.
2. **Endoscopic mucosal resection (EMR)** is gaining favor for the treatment of Barrett's esophagus with low-grade dysplasia.

### • High-grade dysplasia

**Esophageal resection** for Barrett's esophagus is recommended.

Pathologic data on surgical specimens demonstrate a 40% risk for adenocarcinoma within a focus of high-grade dysplasia.

### • Antireflux surgery

- Benefits of antireflux surgery are controversial in patients with BE.
- Those in favour of surgery argue that medical therapy and endoscopic surveillance may treat the symptoms but fail to address the problem.
- Problem is a functional impairment of the LES that leads to chronic reflux and metaplastic transformation of the lower esophageal mucosa.
- **Surgery renders the LES competent and restores the barrier to reflux.**
- Studies have demonstrated regression of metaplasia to normal mucosa up to 57% of the time in patients who have undergone antireflux surgery.

# ACHALASIA

## Definition

Achalasia is an uncommon disease of esophageal motility disorder. It is characterized by partial or complete degeneration of the myenteric plexus of Auerbach that innervate LES and esophageal body.

The **main** feature is failure of relaxation of the lower esophageal sphincter.

## Possible etiologies (etiology is not clear)

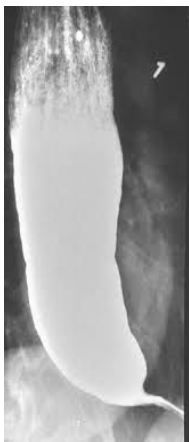- Autoimmune.
- **Infectious:** Trypanosoma cruzi “ **Chagas disease**<sup>9</sup> ” → causes secondary achalasia.
- Gastroesophageal junction tumors sometimes mimic achalasia (pseudoachalasia)

## Clinical features

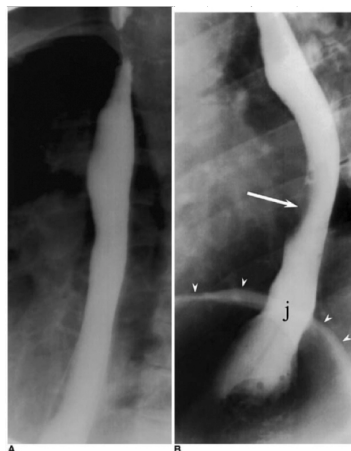
- Common in **young patients** (25-50 years) | males = females
- Most common presenting symptoms (**in order**):
  - 1. Progressive dysphagia:** to both solids & liquids at the same time  
[If dysphagia occurs for solids first and then liquids → carcinoma]
  - 2. Regurgitation/nocturnal regurgitation** of esophageal contents → nighttime cough & aspiration.
  - 3. Others:** chest pain | Heartburn<sup>10</sup> | Halitosis | Weight loss (in end-stage disease)
- Patients prefer eating while standing up to make the gravity help them to swallow.  
Gravity is responsible for food leaving the oesophagus rather than peristalsis in achalasia, so the patient finds it easier to eat when standing.

## Diagnosis

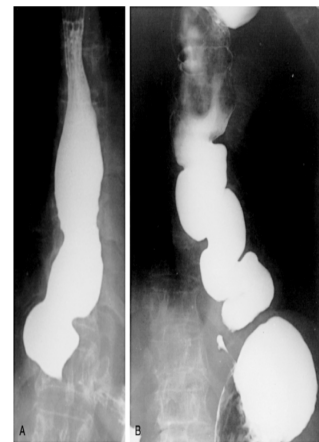
- **CXR:** may show air-fluid level.
- **Barium study**<sup>11</sup>: **(1) classic finding bird's beak** (gradual tapering at the end of the esophagus)  
It also shows **(2) dilated esophagus** **(3) air-fluid level** ∴ may be secondary to retained secretions.
- **Upper endoscopy** is the **NEXT** diagnostic test in a patient with suspected achalasia.
  - **Findings:** **(1)** Dilated esophagus with retained food or secretions. **(2)** Normal in ≈44% of patients.
  - Difficulty traversing the GEJ → suspicion of **pseudoachalasia** due to neoplastic infiltration of the distal esophagus.



**Bird's beak**



**Normal esophagram**<sup>12</sup>



**Nutcracker esophagus (DES)**

<sup>9</sup> Causes degeneration of the myenteric plexus, leading to a motor disorder of the oesophagus.

<sup>10</sup> Maybe related to direct irritation of the esophageal lining by retained food, pills, or acidic byproducts of bacterial metabolism of retained food.

<sup>11</sup> Initial test if we suspect achalasia (from the history)

<sup>12</sup> (**arrow**): air-bubble [can be distinguished from a true lesion because the air bubble moves during examination]  
(**j**): gastroesophageal junction | (**arrowheads**): diaphragm



- **Esophageal manometry** [has the highest sensitivity (**Most accurate**) for achalasia diagnosis]
  - Aperistalsis of the distal esophageal body.
  - Incomplete or absent LES relaxation.
  - Hypertensive LES
  - **Manometric variants of achalasia:** vigorous achalasia (best known)
    - Defined by the presence of normal to high amplitude esophageal body contractions in the presence of a nonrelaxing LES. May represent an early stage of achalasia.

## Secondary forms of achalasia

- **Cancer** (most concerning etiology): can present as achalasia through mechanical obstruction of the GEJ.
- **Post fundoplication achalasia:** (increasingly recognized etiology): caused by mechanical obstruction of the GEJ by the fundoplication or diaphragmatic crural closure.
- **Following bariatric surgery:** using a gastric band device which constricts the proximal stomach a few centimeters below the LES.
- **Chagas disease:** parasitic infection caused by *Trypanosoma cruzi* which can cause secondary achalasia.

## Treatment

- **Primary therapeutic goal:** to reduce LES basal pressure.
- **Primary desired outcome:** symptoms relief, particularly of dysphagia.
- **Treatment options**<sup>13</sup>: medical therapy, botulinum toxin injection, pneumatic dilation, and surgical myotomy.

### • Medical Therapy:

- Inconvenient, reserved for patients awaiting or unable to tolerate invasive treatment modalities.
- **Nitrates** were first recognized as an effective treatment of achalasia.
  - Their systemic vasodilatory effects and headaches limit their tolerability by patients.
- **Calcium channel blocker** have a better side-effect profile when compared with nitrates
  - 30% of patients report adverse side effects (peripheral edema, hypotension, and headache)

### • Botulinum Toxin Injection: (endoscopically)

- **Administration:** Injection of LES  
It **requires reinjection** although it is apparent that with repeated injections, the response rates reported are similar or lower to that achieved with the initial injection.  
Response rates at 1 month following administration average 78% , By 6 months, the clinical response rate drops to 58% and by 12 months to 49%
- **Mechanism of action:**  
Blocks excitatory-acetylcholine-releasing neurons generated by LES basal muscle tone.
- **Characteristics:**  
Easy to administer | associated with relatively few side effects.
- **Indication:**  
Patients who are not candidates for more invasive treatments given the limitations of the efficacy and durability of response.

### • Pneumatic Dilation: “first-line”

- One of the most effective first line **therapies** for achalasia.
- **Procedure:** placing an endoscopy that inflates a device to enlarge the lower esophagus.
- Long-term follow-up studies reported significant symptom relapse of 50% at 10 years.
- **Complications of pneumatic dilation:**
  - Gastroesophageal reflux (25-35%)
  - Esophageal perforation (3%)

<sup>13</sup> **None of them are very useful**, treatment of choice depends on several factors including age, surgical risk, comorbidities, severity, patient preference, and locally available expertise according to new guidelines.

### • **Surgical Therapy: “best treatment”**

- Surgical myotomy: laparoscopic Heller's myotomy (common) & open surgical myotomy (rare)
- **Heller myotomy: muscles of the cardia (lower esophageal sphincter or LES)** are cut, allowing food and liquids to pass to the stomach | high success rates | hospital stays only for few days.
- Laparoscopic Heller myotomy shows excellent results (98% symptomatic improvement at 5.3 years)
- **Complications:**
  - Acid exposure<sup>14</sup>.
  - Dysphagia
    - As a consequence of esophageal peristaltic dysfunction even with a successful myotomy .
    - Delayed recurrence of postoperative dysphagia is most commonly caused by development of a recurrent high pressure zone at the LES or a peptic stricture complicating acid reflux.

#### Complication of Heller's myotomy:

Early: perforation

Late: reflux esophagitis & recurrent dysphagia from an inadequate myotomy.

### • **Surgery Versus Pneumatic Dilation:**

- Several studies have reported success rates of surgery more than pneumatic dilation.
- **Surgery is more effective but more dangerous** than pneumatic dilation.
- Pneumatic dilation: long-term follow-up studies reported significant symptom relapse of 50% at 10 years.

### • **Refractory achalasia**

Achalasia that is refractory to therapy with Heller myotomy, options are limited.

### • **Esophagectomy**

Considered if there is marked dilation, sigmoid esophagus (>10 cm dilation of distal esophagus)  
Such patients may respond to Heller's myotomy.

### • **Complications of achalasia**

- **Primary complications:** progressive malnutrition and aspiration.  
(related to the functional obstruction caused by the nonrelaxing LES)
- **Secondary complications** (uncommon but important):
  - Formation of epiphrenic diverticulum
  - Esophageal cancer (most commonly **squamous cell carcinoma**)

Prevalence of esophageal cancer in achalasia ≈3% | Incidence ≈197 cases per 100,000 persons per year.

---

<sup>14</sup> Surgery is often combined with partial fundoplication to reduce the incidence of postoperative acid reflux & GERD.

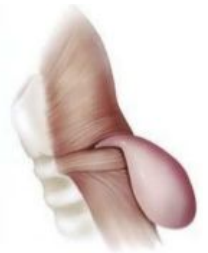# ESOPHAGEAL DIVERTICULA<sup>15</sup>

- Most diverticula are a result of: (1) primary motor disturbance. | (2) abnormality of the UES or LES.
- Can occur in several places along the esophagus. The three most common sites:
  - **Pharyngoesophageal (Zenker's).**
  - Peribronchial (mid-esophageal).
  - Epiphrenic.

True diverticulum	False diverticulum
ALL LAYERS of esophageal wall (mucosa - submucosa - muscularis)	Mucosa and submucosa <u>ONLY</u>
<b>True diverticulum (Traction)</b> <b>Results from:</b> External inflammatory mediastinal lymph nodes adhering to the esophagus	<b>Pulsion (pressure) diverticula:</b> Caused by <b>elevated intraluminal pressures</b> ; generated from abnormal motility disorders. It includes: <b>Zenker's &amp; epiphrenic diverticulum</b>

## Pharyngoesophageal (Zenker's) Diverticulum

- Most common | usually in **older** male patients | 7th decade of life.
- Found herniating into **Killian's triangle** (between the oblique fibers of the thyropharyngeus muscle and the horizontal fibers of the cricopharyngeus muscle). Incoordination of swallowing and failure of relaxation of the cricopharyngeus muscle cause the herniation.



## Symptoms & Diagnosis

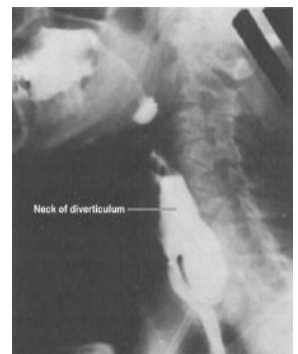
- **Common:** patients complain of a **sticking** (gurgling) in the throat.
  - **Especially common in elderly: Halitosis<sup>16</sup>** | voice changes | retrosternal pain | respiratory infections.
  - **Signs of progressive disease:** nagging **cough** | hypersalivation | intermittent **dysphagia**.
  - **As pouch increase in size regurgitation** of foul-smelling & undigested material is common.
  - **Most serious complication** if untreated **aspiration pneumonia** or lung abscess.
- \* A lump in the neck might be seen (pharyngeal pouch) | might be asymptomatic.

### • **Diagnosis is made by barium esophagram**

(which demonstrates pouch + uncoordinated swallowing).

Esophageal manometry and endoscopy are **NOT** needed to make a diagnosis.

Endoscopy rather confirms the diagnosis. It must be performed with care to avoid accidental perforation of the pouch.



## Treatment

- **Open surgical repair:** (myotomy + resection of pouch) **"gold standard of treatment"**
  - Myotomy of proximal & distal thyropharyngeus and cricopharyngeus muscles.
  - Pouch resection: **diverticulectomy<sup>17</sup>/diverticulopexy<sup>18</sup>** through an incision in the left neck.
- **Endoscopic repair** is an alternative to open surgical repair: **endoscopic Dohlman procedure** (also known as endoscopic Zenker's **diverticulotomy<sup>19</sup>**): by dividing the common wall between the esophagus & diverticulum using a laser or stapler.

<sup>15</sup> Also known as (pouches): protrusions of mucosa through a weak area in the muscle wall.

<sup>16</sup> **Bad breath.**

<sup>17</sup> **Diverticulectomy:** surgical excision (resection) of a diverticulum.

<sup>18</sup> **Diverticulopexy:** without resection. Usually by securing the tip to a nearby structure so diverticulum no longer fills.

<sup>19</sup> **Diverticulotomy:** surgical incision into diverticulum.

# DIFFUSE ESOPHAGEAL SPASM

- Seen **most often** in: women | patients with multiple complaints | middle-aged to elderly.
- Basic pathology:
  - Motor abnormality (hypermotility) of the esophageal body.
  - Most notable in the lower 2/3 of the esophagus.
  - Esophageal contractions are repetitive, irregular, simultaneous, and of high amplitude.

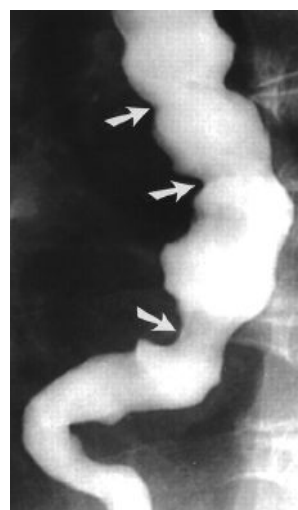## Symptoms & Diagnosis

- **Clinical presentation** (typically): non-cardiac retrosternal chest pain | intermittent dysphagia.
  - **Exacerbating factors:** eating or exertion (may mimic angina) | times of heightened emotional stress.
  - **Associated symptoms:**
    - **Common:** regurgitation of esophageal contents and saliva.
    - **Uncommon:** acid reflux (can aggravate the symptoms, as can cold liquids)
  - **Triggering factors:** gallstones | peptic ulcer disease | pancreatitis.
- Diffuse esophageal spasm can be precipitated by GERD and this should be excluded by 24-hour pH studies.
- **Comorbidities:** Irritable bowel syndrome | pyloric spasm.
  - **Diagnosis:** made by esophagram and manometric studies.  
manometry is required to make the diagnosis

## Treatment

- Mainstay of treatment for DES is **nonsurgical**. Pharmacologic or endoscopic intervention are preferred.  
Medical treatment includes: calcium channel blockers, sublingual GTN and proton pump inhibitors.
- Surgery is reserved for patients with:
  - Recurrent incapacitating episodes of dysphagia and chest pain.
  - NO response to medical treatment.

Surgical treatment involves a long myotomy but the results are unpredictable and most patients will be treated medically.



“Corkscrew sign”

# CAUSTIC INJURY

- **Children** → usually accidental ingestion | small quantities.
- **Teenagers and adults** → deliberate ingestion during suicide attempts | larger quantities.
- **Alkali** ingestion is more **common** and much **more devastating** than acid ingestion because of its lack of immediate symptoms and almost always lead to significant destruction of the esophagus.

## Three Phases of Tissue Injury From Alkali Ingestion

Phase	Tissue injury	Onset	Duration	Inflammatory response	Symptoms
<b>1</b>	Acute necrosis.	1-4 days	1-4 days	Coagulation of intracellular proteins.	*Oral and substernal pain *Hypersalivation *Odynophagia & dysphagia *Vomiting & Hematemesis
				Inflammation.	
<b>2</b>	Ulceration & granulation	3-5 days	3-12 days	Tissue sloughing.	Symptoms may disappear
				Granulation of ulcerated tissue bed.	
<b>3</b>	Cicatrization & scarring	3 weeks	1-6 months	Adhesion formation.	Dysphagia reappears; as fibrosis and scarring begin to narrow the esophagus.
				Scarring	

## Symptoms & Diagnosis

Other symptoms	Physical examination	Investigations
<ul style="list-style-type: none"> <li>• <b>Symptoms of respiratory distress:</b> hoarseness, stridor, and dyspnea → suggest upper airway edema and are usually worse with acid ingestion.</li> <li>• <b>Pain: chest &amp; back</b> → may indicate perforation of <u>mediastinal esophagus</u>, <b>abdominal</b> → may indicate <u>abdominal visceral perforation</u>.</li> </ul>	<ul style="list-style-type: none"> <li>- Evaluation of: mouth, airway, chest, and abdomen.</li> <li>- Careful inspection of: lips, palate, pharynx, and larynx.</li> <li>- Abdomen is examined for signs of perforation.</li> </ul>	<ol style="list-style-type: none"> <li><b>1. Early endoscopy</b> is recommended 12 to 24 hours after ingestion to <u>identify the grade of the burn</u>.  <b>First degree:</b> Mucosal hyperemia, edema  <b>Second degree:</b> Limited hemorrhage, exudates, ulcerations, pseudomembrane formation.  <b>Third degree:</b> Mucosal sloughing, deep ulcerations, massive hemorrhage, complete luminal obstruction, charring, perforation</li> <li>2. Questionable chest and abdominal exams → Serial chest and abdominal radiographs are indicated</li> </ol>

**Treatment** (The best cure for this condition is an ounce of prevention)

- Management of the acute phase is aimed at limiting and identifying the extent of the injury.
- It begins with **neutralization** of the ingested substance:
  1. **Alkalis** (including lye) are neutralized with half-strength vinegar or citrus juice.
  2. **Acids** are neutralized with milk, egg whites, or antacids.
- Emetics and sodium bicarbonate need to be **avoided** because they can increase the chance of **perforation**.

First-Degree Burn	Second-Degree Burns	Third-Degree Burns
<ul style="list-style-type: none"> <li>• <b>48 hours of observation.</b></li> <li>• Oral nutrition can be resumed when a patient can painlessly swallow saliva.</li> <li>• A repeat endoscopy and barium esophagram are done in follow-up at intervals of 1, 2, and 8 months.</li> <li>• <b>Acid suppression.</b></li> </ul>	<ul style="list-style-type: none"> <li>• <b>Aggressive resuscitation.</b></li> <li>• The patient is monitored in the ICU.</li> <li>• <b>NPO with IV fluids   IV antibiotics</b></li> <li>• Fiberoptic intubation (if needed)</li> <li>• <b>Acid suppression.</b> PPIs are started.</li> </ul>	<ul style="list-style-type: none"> <li>• <b>Fiberoptic intubation</b> (if needed)</li> <li>• <b>Inhaled steroids.</b></li> </ul>

# ESOPHAGEAL PERFORATION<sup>20</sup>

- Perforation of the esophagus is a **surgical emergency**.
- ≤ 24-hrs early detection and surgical repair → 80%-90% survival. | ≥ 24-hrs → survival less than 50%.

**Etiology:** [common sites of perforation are at sites of anatomical narrowing (constrictions)]

Intraluminal	Outside the wall	Spontaneous:
<b>Foreign body ingestion (14%)</b>  <b>Iatrogenic;</b> most esophageal perforations occur after endoscopic <sup>22</sup> instrumentation for a diagnostic endoscopy (rare) or therapeutic procedure, such as dilatation (commoner).	<b>Trauma (10%)</b> (by penetrating injuries such as knife wounds to the neck but are rare)	<b>Forceful vomiting (Boerhaave's syndrome) (15%)</b>  A tear to the esophageal mucosa <u>only</u> following vomiting is known as a <b>Mallory-Weiss tear</b> and tends to cause haematemesis and pain. <sup>21</sup>

## Symptoms and Diagnosis [depend on the site and size of the perforation]

Perforation that may be present		
Cervical perforations	Thoracic perforations	Abdominal perforations
<b>Neckache, stiffness</b> due to contamination of the prevertebral space. <b>Local tenderness, and surgical emphysema</b>	<b>Retrosternal chest pain</b> (lateralizing to the side of perforation) and <b>dysphagia</b> * If pleural space is involved → pneumothorax or pleural effusion → shock, SOB and cyanosis. * Mediastinitis and septic shock	<b>Epigastric pain</b> that radiates to the back if the perforation is posterior. <b>Peritonitis and a rigid abdomen.</b>

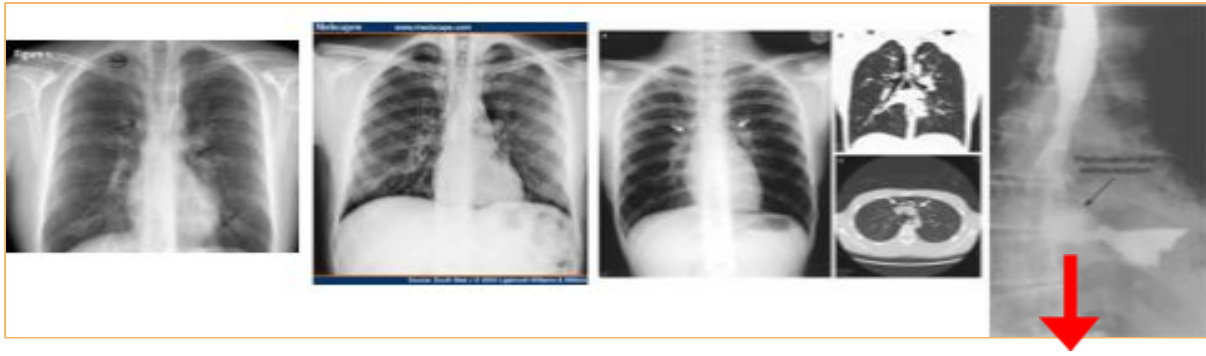- **Consistently associated with:** neck, substernal, or epigastric pain.
- **Other associated symptoms:** vomiting, hematemesis, or dysphagia.
- **History of:** trauma | advanced esophageal cancer | violent retching (ex. Boerhaave's syndrome) | swallowing a foreign body | recent instrumentation → must raise the question of esophageal perforation.
- With increased mediastinal and pleural contamination → hemodynamic instability.
- **On examination:**
  - Tachypnea, tachycardia, and a low-grade fever but have no signs of perforation.
  - Subcutaneous air in the neck or chest, shallow decreased breath sounds, or a tender abdomen.
- **Laboratory values** of significance: ↑ **WBCs** count & ↑ **salivary amylase** in blood or pleural fluid.
- **Imaging:** diagnosis of an esophageal perforation may be made **radiographically**.
  - **CXR:** may demonstrate **hydropneumothorax or pneumomediastinum**
  - **Contrast esophagram with water soluble contrast (ex. Gastrografin)** barium swallow is contraindicated as it may leak and cause severe inflammation and fibrosis (mediastinitis + peritonitis) Most perforations (found above GEJ on left lateral wall of esophagus) → results in 10% false-negative rate if patient is not in lateral decubitus position.
  - **Chest CT<sup>23</sup>** shows mediastinal air and fluid at the site of perforation
- **Surgical endoscopy:**
  - Has to be performed if (1) esophagram is negative (2) operative intervention is planned.
  - **Endoscopy suggests mucosal injury if:**
    - (1) blood, mucosal hematoma, or a flap is seen
    - (2) esophagus is difficult to insufflate.

<sup>20</sup> One of the most important DDx for anyone who collapses with chest pain, shortness of breath or vomiting.

<sup>21</sup> **Boerhaave syndrome:** transmural perforation of the esophagus | **Mallory-Weiss syndrome:** nontransmural esophageal **tear** that is also associated with vomiting

<sup>22</sup> **Any patient complains of chest pain, fever or vomiting after endoscopy think of perforation.**

<sup>23</sup> **To confirm the diagnosis.**

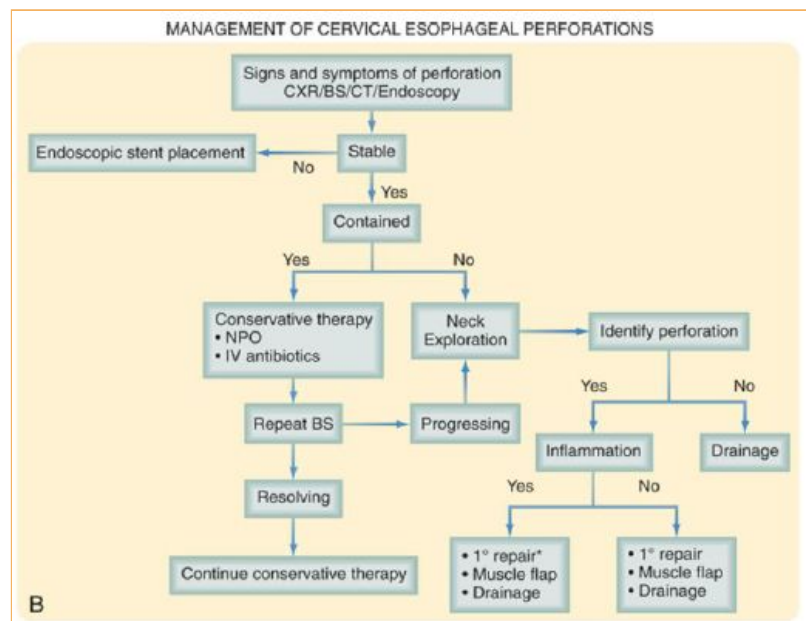
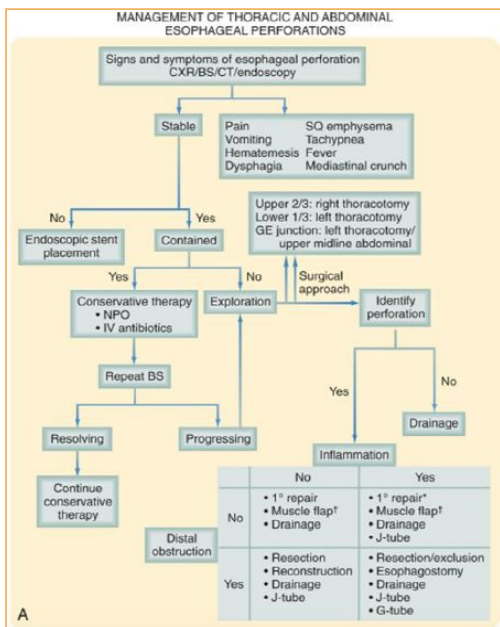


Picture demonstrating perforation and extravasation

## Treatment

1. If perforation is suspected → appropriate resuscitation with placement of large-bore peripheral IV catheters, a urinary catheter, and a secured airway (before patient is sent for diagnostic testing)  
Note that perforation can progress rapidly to **hemodynamic instability and shock** if patient is not stabilized.
2. **IV fluids and broad-spectrum antibiotics** are started immediately, and the patient is monitored in an ICU.
3. **The patient is kept NPO, and nutritional access needs are assessed** (total parenteral nutrition TPN)
4. Further management:
  - Dependent on several variables: stability of the patient, extent of contamination, degree of inflammation, underlying esophageal disease, and location of perforation.
  - Surgery is not indicated for every patient. The most critical variable that determines the surgical management of an esophageal perforation is the **degree of inflammation surrounding the perforation**. (**small perforation treated conservatively | big perforation treated with surgical intervention**)
    - Patient presents within 24 hours of perforation & minimal inflammation → primary surgical repair.
    - Perforation progresses with time (inflammation & friable tissues) → patient may NOT be amenable to primary repair.

Summary: if you suspect perforation **(1)** Resuscitation & stabilization **(3)** Diagnostic testing **(4)** IV fluids, IV Abx, NPO (TPN) in ICU **(5)** Further management varies: a) Surgical repair with large perforations & minimal inflammation <24 hrs b) Conservative management is enough with small perforations & progressive inflammation >24 hrs

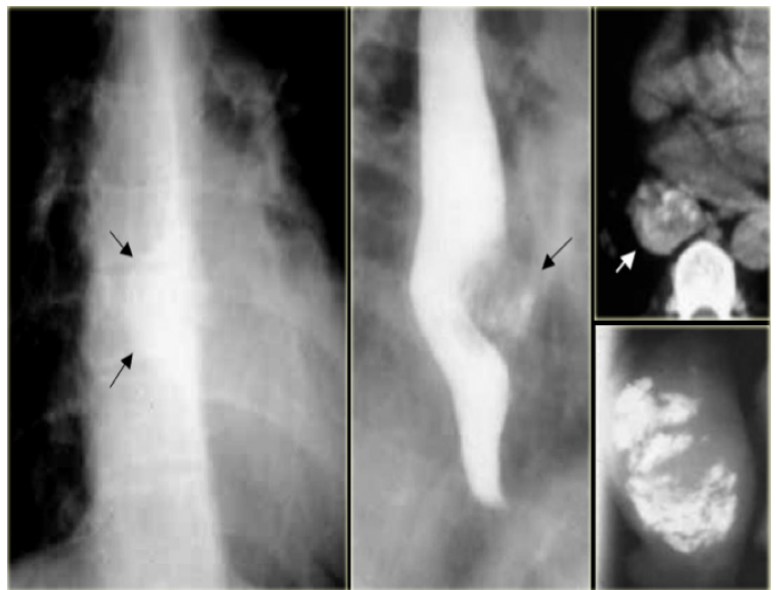

# LEIOMYOMA

- Leiomyomas constitute 60% of all benign esophageal tumors.
- Men > women | 4th and 5th decades.
- They are found in the distal two thirds of the esophagus more than 80% of the time
- They are usually solitary and remain intramural, causing symptoms as they enlarge.
- Recently, they have been classified as a **gastrointestinal stromal tumor (GIST)**:
  - Most common mesenchymal tumors of the gastrointestinal tract and can be benign or malignant.
  - Nearly all GIST tumors occur from mutations of the c-KIT oncogene, which codes for the expression of c-KIT (CD117).
- All leiomyomas are slow-growing benign tumors with malignant transformation being rare (progressively symptomatic with time if it becomes malignant)

## Symptoms and Diagnosis

- Many leiomyomas are asymptomatic.
- Dysphagia, bleeding and pain are the most common symptoms (can result from even the smallest tumors).
- A chest radiograph is NOT usually helpful to diagnose leiomyomas, but on **barium esophagram**, a leiomyoma has a characteristic appearance.
- During endoscopy, extrinsic compression is seen, and the overlying mucosa is noted to be intact
- Diagnosis also can be made by an endoscopic ultrasound (EUS), which will demonstrate a hypoechoic mass in the submucosa or muscularis propria.



## Treatment

- Although observation is acceptable in patients with small (<2 cm) asymptomatic tumors or other significant comorbid conditions, in most patients, **surgical resection is advocated**.
- **Surgical enucleation of the tumor remains the standard** of care and is performed through a thoracotomy or with video or robotic assistance.
- The mortality rate is less than 2%, and success in relieving dysphagia approaches 100%.



# CARCINOMA OF THE ESOPHAGUS

- Esophageal cancer is the fastest growing cancer in western countries.
- It is of TWO common types:

Squamous cell carcinoma	Adenocarcinoma
<ul style="list-style-type: none"> <li>• Accounts for most esophageal cancers diagnosed.</li> <li>• Arise from the squamous mucosa that is native to the esophagus and is found in upper and middle third of esophagus 70% of the time.</li> <li>• Caustic ingestion, <b>achalasia</b>, bulimia, tylosis (an inherited autosomal dominant trait), <b>Plummer-Vinson syndrome</b>, external-beam radiation, and esophageal diverticula all have known associations with squamous cell cancer.</li> </ul>	<ul style="list-style-type: none"> <li>• In the US and Western countries, esophageal adenocarcinoma is noted in up to 70%. More common in white males</li> <li>• There are a number of factors that are responsible for this shift in cell type:               <ul style="list-style-type: none"> <li>○ Increasing incidence of <b>GERD</b>.</li> <li>○ Western diet.</li> <li>○ Increased use of acid-suppression medications.</li> </ul> </li> <li>• <b>(1) Adaptive measure: squamous-lined distal esophagus → metaplastic columnar epithelium (<b>Barrett's esophagus</b>)</b></li> <li>• <b>(2) Progressive changes from Barrett's esophagus → dysplastic cells → development of esophageal adenocarcinoma.</b></li> </ul>

Risk factors:

The most important risk factors for adenocarcinoma of the oesophagus are reflux and obesity.

- **Smoking and alcohol** both increase the risk for foregut cancers by 5-fold combined.
- **Food additives:** nitrosamines (found in pickled), smoked foods and long-term ingestion of hot liquids.
- **Intake of caffeine, fats, acidic and spicy foods** → decreased tone in LES and → increase in reflux.

Others: Leukoplakia, achalasia, consumption of salted fish.

- The 5-year survival rate varies: 70% with polypoid lesions (good), 15% with advanced tumors (poor).

## Symptoms

- Early-stage cancers may be asymptomatic or mimic symptoms of GERD.
- Most patients with esophageal cancer present with **progressive dysphagia** and **weight loss**.
- Because of the distensibility of the esophagus, a mass can obstruct two thirds of the lumen before symptoms of dysphagia are noted.
- **Signs of advanced disease:**
  - **Ominous signs of advanced disease:** choking, coughing, aspiration from a tracheoesophageal fistula, and hoarseness (vocal cord paralysis from direct invasion into the recurrent laryngeal nerve)
  - **Systemic metastases:** to liver (hepatomegaly/ascites/abdominal mass/jaundice), bone (excessive pain), and lung (respiratory symptoms). + lymph nodes ( supraclavicular lymph node in particular<sup>24</sup>)

Other general features of malignancy: anorexia, anaemia and lassitude (lethargy)

## Diagnosis

- There is a plethora of modalities available to diagnose and stage esophageal cancer.
- Radiologic tests, endoscopic procedures, and minimally invasive surgical techniques all add value to a solid **staging** workup in a patient with esophageal cancer.

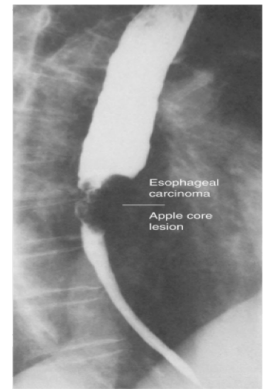
<sup>24</sup> **Esophageal cancer** metastasize to **right** supraclavicular lymph node | **Gastric cancer** metastasize to **left** supraclavicular (Virchow's node)

## • Esophagram

- Primary investigation when access to **endoscopy is limited**.
- A barium esophagram is recommended for any patient presenting with dysphagia.

**NOTE:** It is mentioned in the slides and by Dr. Sami that esophagram is the initial investigation of **dysphagia**. HOWEVER we have asked two expert GI consultants who specialise in endoscopy, searched books & articles they all say after taking good full history endoscopy is the next step “generally speaking” unless you suspect other ddx (ex. achalasia) then you add esophagram on top of your list of investigations.

- Is able to differentiate intraluminal from intramural lesions and to discriminate between **intrinsic** (from a mass protruding into the lumen) and **extrinsic** (from compression of a structures outside the esophagus) compression.
- The **classic finding: apple-core lesion** in patients with esophageal cancer.
- Esophagram is **not specific** for cancer.



## ★ Endoscopy “first-line & most accurate investigation for dysphagia”

- **The diagnosis of esophageal cancer is made best from an endoscopic biopsy.**
- Any patient undergoing surgery for esophageal cancer **must** have an endoscopy performed by the operating surgeon before entering the operating room for a definitive resection.

Even if the diagnosis is made initially by barium swallow, it must always be confirmed by endoscopy and biopsy.

## • Computed Tomography: “to stage malignancy”

- CT scan of the chest and abdomen is important to assess the length of the tumor, thickness of the esophagus and stomach, regional lymph node status and Distant disease to the liver and lungs.

## • Positron Emission Tomography:

- PET scan evaluates the primary mass, regional lymph nodes, and distant disease.
- Sensitivity and specificity > CT; however, they remain **low** for definitive staging.

## • Endoscopic Ultrasound: Mostly used for staging the ‘T’ and ‘N’ component of TNM staging.

- Most critical component of **esophageal cancer staging**. The information obtained from
- **Guide both medical & surgical therapy.**
- **Obtain biopsy samples** of masses & lymph nodes in paratracheal, subcarinal, paraesophageal, celiac region.

## Treatment

- Chemotherapy.
- Radiation therapy.
- Chemoradiotherapy.
- Surgical resection.

**Surgical resection ONLY:** tumor in the esophagus ONLY

**Neoadjuvant therapy** (chemo then resection): tumor in the esophagus + adjacent lymph nodes.

**Chemo +/-radiotherapy:** tumor in the esophagus + metastasis.

**Palliative care<sup>25</sup> only:** tumor in the esophagus + metastasis almost everywhere.

The majority will have palliative rather than curative treatment.

Esophagectomy with palliative intent is no longer appropriate as few patients recover enough to gain any benefit before they die of their disease.

<sup>25</sup> Focuses on providing patients with relief from symptoms for life-limiting illnesses.

## Recall:

### Anatomic Considerations of the Esophagus:

#### Q1: What are the primary functions of the Upper and Lower Esophageal Sphincters?

UES: swallowing | LES: prevention of reflux

#### Q2: The esophageal venous plexus drains inferiorly into the gastric veins. Why is this important?

Gastric veins are part of the portal venous system; portal hypertension can thus be referred to the esophageal veins, leading to varices → hematemesis

#### Q3: Identify the esophageal muscle type:

- Proximal 1/3 → Skeletal muscle
- Middle 1/3 → Smooth muscle and skeletal muscle.
- Distal 1/3 → Smooth muscle.

#### Q4: Identify the blood supply to the esophagus:

- Proximal 1/3 → Inferior thyroid, anterior intercostals
- Middle 1/3 → Esophageal arteries, bronchial arteries
- Distal 1/3 → Left gastric artery, left inferior phrenic artery

#### Q5: What is the length of the esophagus?

< 25 cm in the adult (40 cm from teeth to LES)

#### Q6: Why is the esophagus notorious for anastomotic leaks?

Esophagus has no serosa (same as the distal rectum) except for the lower part

#### Q7: What nerve runs with the esophagus?

Vagus nerve (which also innervates the esophagus)

### Esophageal Reflux:

#### Q1: What is esophageal reflux?

- Excessive reflux of gastric contents into the esophagus, "heartburn".

#### Q2: What are the causes?

- Decreased lower esophageal sphincter (LES) tone (>50% of cases).
- Decreased esophageal motility to clear refluxed fluid.
- Gastric outlet obstruction.
- Hiatal hernia in ≈ 50% of patients.

#### Q3: What are the signs/symptoms?

- Heartburn (pyrosis), regurgitation, respiratory problems/pneumonia from aspiration of refluxed gastric contents; substernal pain (also known as retrosternal pain or noncardiac chest pain NCCP).

#### What is the difference between heartburn and substernal pain?

Heartburn: BURNING sensation usually centered in the middle of the chest near the sternum, caused by acid reflux.  
Substernal pain (retrosternal pain): ANY PAIN situated or perceived behind or below the sternum.

#### Q4: What disease must be ruled out when the symptoms of GERD are present?

- Coronary artery disease.

#### Q5: What tests are included in the workup?

- Esophagogastroduodenoscopy (EGD).
- Upper Gastrointestinal Series (UGI) contrast study with esophagogram.
- 24-hour acid analysis (pH probe in esophagus).
- Esophageal Manometry.
- Electrocardiogram (EKG\ECG).
- Chest x-ray (CXR).

#### Q6: What is the medical treatment?

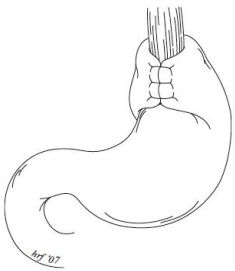
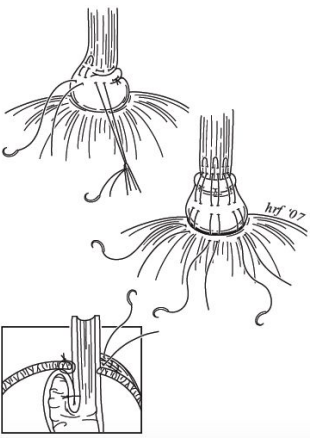
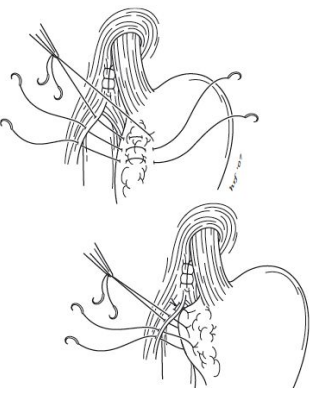
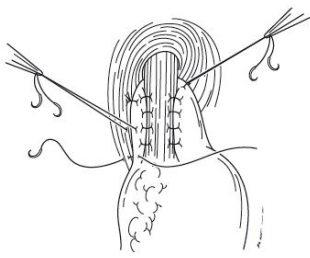
- Small meals.
- Proton-pump inhibitors (PPIs) or H2 blockers.
- Elevation of head at night and no meals prior to sleeping.

#### Q7: What are the indications for surgery?

- Intractability (failure of medical treatment).
- Respiratory problems as a result of reflux and aspiration of gastric contents (e.g., pneumonia).
- Severe esophageal injury (e.g., ulcers, hemorrhage, stricture, ± Barrett's esophagus).

#### Q8: Define the following surgical options for severe GERD:

Lap Nissen	Belsey mark IV	Hill	Toupet
360 fundoplication - 2 cm long (laparoscopically)	240 to 270 fundoplication performed through a thoracic approach.	Arcuate ligament repair (close large esophageal hiatus) and gastropexy to diaphragm (suture stomach to diaphragm)	Incomplete (around 200°) posterior wrap (laparoscopic) often used with severe decreased esophageal motility.

Lap Nissen	Belsey mark IV:	Hill	Toupet:
			

**Q9: How does the Nissen wrap work?**

- Thought to work by improving the lower esophageal sphincter:
- 1. Increasing LES tone. | 2. Elongating LES  $\approx$  3 cm. | 3. Returning LES into abdominal cavity.

**Q10: What are the postoperative complications of Lap Nissen?**

- 1. Gas-bloat syndrome (Inability to burp or vomit) | 2. Stricture. | 3. Dysphagia .
- 4. Spleen injury requiring splenectomy | 5. Esophageal perforation. | 6. Pneumothorax.

**Barrett's Esophagus**

**Q1: What is Barrett's esophagus?**

Columnar metaplasia from the normal squamous epithelium as a result of chronic irritation from reflux

**Q2: What is the major concern with Barrett's esophagus?**

Developing cancer.

**Q3: What type of cancer develops in Barrett's esophagus?**

Adenocarcinoma.

(patients with GERD might develop Barrett's esophagus, patients with Barrett's esophagus might develop adenocarcinoma)

**Q4: What is the treatment of Barrett's esophagus with dysplasia?**

Non-surgical: endoscopic mucosal resection and photodynamic therapy.

Other options include radiofrequency ablation, cryoablation (these methods are also often used for mucosal adenocarcinoma)

**Achalasia**

**Q1: What is Achalasia?**

- 1. Failure of the LES to relax during swallowing. | 2. Aperistalsis of the esophageal body.

**Q2: What are the proposed etiologies?**

- 1. Neurologic (ganglionic degeneration of Auerbach's plexus, vagus nerve, or both); possibly infectious in nature.
- 2. Chagas' disease in South America.

**Q3: What are the associated long term conditions?**

Esophageal carcinoma secondary to Barrett's esophagus from food stasis.

**Q4: What are the symptoms?**

Dysphagia for both solids and liquids, followed by regurgitation; dysphagia for liquids is worse.

**Q5: What are the diagnostic findings?**

- Radiographic contrast studies reveal dilated esophageal body with narrowing inferiorly.
- Manometry: motility studies reveal failure of the LES to relax during swallowing and aperistalsis of the esophageal body.

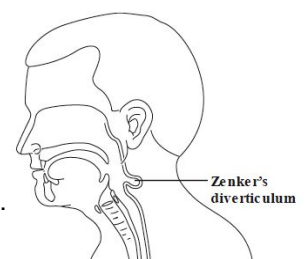
**Q6: What are the treatment options?**

- 1. Upper endoscopy and balloon dilation of the LES.
- 2. Laparoscopic Heller myotomy of the lower esophagus and LES (6 cm) and 2 cm onto the stomach.

**Zenker's Diverticulum**

**Q1: What is Zenker's Diverticulum (also known; pharyngeal pouch)?**

Pharyngoesophageal diverticulum; a false diverticulum containing mucosa and submucosa at the upper esophageal sphincter at the pharyngoesophageal junction through Killian's triangle.



**Q2: What are the signs/symptoms?**

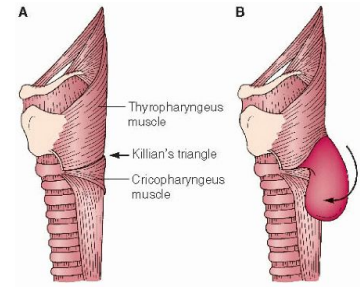
Dysphagia, neck mass, halitosis (bad breath), food regurgitation, heartburn.

**Q3: How is the diagnosis made?**

Barium swallow.

**Q4: What is the treatment?**

1. One stage cricopharyngeal myotomy and diverticulectomy.
2. Other options are cricopharyngeal myotomy and diverticulopexy to the prevertebral fascia or transoral stapling of the common wall between the diverticulum and the esophagus with diverticulum  $\geq 3$ cm (to fit the stapler)

**Diffuse Esophageal Spasm****Q1: What is Diffuse Esophageal Spasm?**

Strong, non-peristaltic contractions of the esophageal body; sphincter function is usually normal.

**Q2: What is the associated condition?**

Gastroesophageal reflux.

**Q3: What are the symptoms?**

Spontaneous chest pain that radiates to the back, ears, neck, jaw, or arms.

**Q4: What is the differential diagnosis?**

Angina pectoris | Psychoneurosis | Nutcracker esophagus.

**Q5: What are the associated diagnostic tests?**

- Esophageal manometry: motility studies reveal repetitive, high-amplitude contractions with normal sphincter response.
- Upper GI may be normal, but 50% show segmented spasms or corkscrew esophagus.
- Endoscopy.

**Q6: What is the classic finding of esophageal contrast study (UGI)?**

“Corkscrew esophagus”

**Q7: What is the treatment?**

- Medical (antireflux measures, calcium channel blockers, nitrates).
- Long esophagomyotomy in refractory cases.

**Caustic Esophageal Strictures****Q1: Which agents may cause strictures if ingested?**

Lye, oven cleaners, drain cleaners, batteries, sodium hydroxide tablets (Clinitest).

**Q2: How is the diagnosis made?**

History | EGD (esophago-gastro-duodenoscopy) is clearly indicated early on to assess the extent of damage (<24 hrs); scope to level of severe injury (deep ulcer) only | water soluble contrast study for deep ulcers to rule out perforation.

**Q3: What is the initial treatment?**

1. NPO/IVF/H2-blocker. | 2. Do not induce emesis. | 3. Corticosteroids (controversial-probably best for shallow/moderate ulcers), antibiotics (penicillin/gentamicin) for moderate ulcers. | 4. Antibiotic for deep ulcers. | 5. Upper GI at 10 to 14 days.

**Q4: What is the treatment if a stricture develops?**

Dilation with Maloney dilator (Mercury- filled rubber dilator) /balloon catheter | In severe refractory cases, esophagectomy with colon interposition or gastric pull-up

**Q5: What is the long-term follow-up?**

Because of increased risk of esophageal squamous cancer (especially with ulceration), patients endoscopies every other year

**Esophageal perforation (boerhaave's syndrome):****Q1: What is it?**

Postemetic esophageal rupture.

**Q2: Why is the esophagus susceptible to perforation and more likely to break down an anastomosis? No serosa.****Q3: What is the most common location?**

Postero-lateral aspect of the esophagus (left), 3 to 5 cm above the gastro-esophageal junction.

**Q4: What is the cause of rupture?**

Increased intraluminal pressure, usually caused by violent retching and vomiting.

**Q5: What is the associated risk factor?**

Esophageal reflux disease (50%)

**Q6: What are the symptoms?**

Pain post-emesis (may radiate to the back, dysphagia) (think Boerhaave's = BoerHEAVES)

**Q7: What are the signs?**

Left pneumothorax, Hamman's sign, left pleural effusion, subcutaneous/mediastinal emphysema, fever, tachypnea, tachycardia, signs of infection by 24 hours, neck crepitus, widened mediastinum on CXR.

**Q8: What is Mackler's triad?**

1. Emesis | 2. Lower chest pain | 3. Cervical emphysema (subQ air).

**Q9: What is Hamman's sign?**

"Mediastinal crunch or clicking" produced by the heart beating against air-filled tissues.

**Q10: How is the diagnosis made?**

History, physical examination, CXR, esophagram with water-soluble contrast.

**Q11: What is the treatment?**

Surgery within 24 hours to drain the mediastinum and surgically close the perforation and placement of pleural patch; broad-spectrum antibiotics

**Q12: Overall, what is the most common cause of esophageal perforation?**

Iatrogenic (most commonly cervical esophagus).

**Esophageal carcinoma**

**Q1: What are the two main types of esophageal Carcinoma?**

1. Adenocarcinoma at the gastroesophageal junction. | 2. Squamous cell carcinoma in most of the esophagus.

**Q2: What is the most common histology?**

Worldwide: squamous cell carcinoma (95%). | USA: adenocarcinoma.

**Q3: What is the age and gender distribution?**

Sixth decade of life | male

**Q4: What are the etiologic factors (5)?**

1. Tobacco. | 2. Alcohol. | 3. GE reflux. | 4. Barrett's esophagus. | 5. Radiation.

**Q5: What are the symptoms?**

Dysphagia | weight loss | Others: chest pain, back pain, hoarseness, symptoms of metastasis.

**Q6: What comprises the workup? How is the diagnosis made?**

1. UGI (localizes tumor) | 2. EGD (obtains biopsy and assesses resectability) | 3. Endoscopic (endoesophageal) ultrasound (EUS) | 4. Full metastatic workup (CXR, PET-CT scan, LFTs)

**Q7: What is the differential diagnosis?**

Leiomyoma | Metastatic tumor | Lymphomas | Benign stricture | Achalasia | Diffuse esophageal spasm | GERD.

**Q8: Describe the stages, treatment and prognosis of adenocarcinoma esophageal cancer :**

Stage I	Stage IIa	Stage IIb	Stage III	Stage IV
<b>Tumor:</b> invades lamina propria, muscularis mucosa, or submucosa (T1) <b>Nodes:</b> negative	<b>Tumor:</b> invades muscularis propria (T2) <b>Nodes:</b> negative (N0)	<b>1. Tumor:</b> invades muscularis propria (T2) <b>Nodes:</b> positive regional nodes (N1) <b>2. Tumor:</b> invades adventitia. <b>Nodes:</b> negative (T3N0)	<b>1. Tumor:</b> invades adventitia (T3) <b>Nodes:</b> positive regional nodes (N1) <b>2. Tumor:</b> invades adjacent structures. <b>Node:</b> any (T4anyN)	<b>Distant metastasis</b>
Esophagectomy with gastric pull-up.	Esophagectomy with gastric pull-up.	1. Esophagectomy with gastric pull-up. <b>or</b> 2. Neoadjuvant chemoradiation, restaging, and esophagectomy with gastric pull-up.	Neoadjuvant chemoradiation, restaging, and esophagectomy with gastric pull-up.	Chemoradiation and esophageal stent for palliation.
66%	25%		10%	Essentially 0%

**Q8: What are the different approaches to esophagectomy?**

1. McKeown ("three hole"): laparotomy, right thoracotomy, left neck incision, and cervical esophagogastric anastomosis.  
2. Ivor Lewis: laparotomy, right thoracotomy, and intrathoracic esophagogastric anastomosis  
3. Transhiatal: laparotomy, left neck incision, and cervical esophagogastric anastomosis  
(Hybrid or total minimally invasive approaches using laparoscopy and/or thoracoscopy or even robotic techniques are now employed)

**Q9: Has radiation therapy and/or chemotherapy been shown to decrease mortality?**

No.

**Q10: What is the postop complication rate?**

< 33% (mainly due to anastomotic leak, pulmonary complications, and atrial fibrillation)

**Q13: What finding on final pathology of resected specimen is associated with the best long-term survival in patients who have undergone neoadjuvant treatment?**

Pathologic complete response, i.e. no residual tumor (occurs in 25–30%)

## Clinical micro-vignettes

**A 42-year-old woman has heartburn after meals and a sour taste in her mouth. For the past 4 to 6 months she has had symptoms several times per week. Symptoms are worse when she lies down or bends over. Antacids help somewhat. The patient has no dysphagia, vomiting, abdominal pain, exertional symptoms, melena, or weight loss.**  
GERD

**54-year-old woman with reflux disease and columnar epithelium on distal esophageal biopsy.**  
Barrett's esophagus

**54-year-old woman with dysphagia (to both liquid and solids) and intermittent chest pain; food "comes up" after falling asleep at night; manometry reveals high LES pressures that do not decrease with swallowing; absent esophageal peristalsis.**  
Achalasia

**A 45-year-old man with minimal past medical history began to have difficulty swallowing with the sensation of food getting stuck in his throat. Symptoms were evident with solid food, and he would often unpredictably regurgitate undigested food. This was particularly difficult in social and professional situations. He took antireflux medication for heartburn and often felt these pills got stuck in his throat. He also noted increasing episodes of halitosis/bad breath and frequently woke in the middle of the night with a coughing fit.**  
Zenker's Diverticulum

**A 19-year-old college student presents to the emergency department with excruciating retrosternal chest pain that radiates to the back. She describes the pain as sharp and worsens with swallowing. She reports that her symptoms began after vomiting 1 hour ago. Medical history is significant for anorexia nervosa. Her temperature is 100.4°F (38°C), blood pressure is 135/90 mmHg, pulse is 105/min, and respirations are 20/min. On physical exam, there is crepitus upon chest palpation. A barium esophagram is performed and shows leakage of water-soluble contrast from the lower thoracic esophagus.**  
Boerhaave Syndrome.

**A patient had an endoscopy, then after 6 hours he experienced fever, chest pain, dysphagia, upper GI bleeding and odynophagia. What's the diagnosis? Endoscopy was complicated by perforation.**

**Q1: What investigations you would do?**

- Chest x-ray → pneumomediastinum (air within the mediastinum).
- Barium swallow → extravasation.

**Q2: What is your management?**

1. NPO
2. IV fluids (D5 0.5NS)
3. Abx
4. Surgery

• If a patient is on IV fluids and can have nothing per mouth, after 2-3 days you should give him total parenteral nutrition (TPN) because it has fat, glucose and proteins that are important for the patient nutrition. A patient can rely on TPN only up to one year.

### **Mnemonic for Plummer-vinson syndrome:**

The plumber "vinson" **DIGS** with his **dOg** for an **IRON** pipe.

**D**ysphagia | **I**ron deficiency anemia | **G**lossitis | **S**quamous cell carcinoma | **O**esophageal web

**IRON**: Treatment with iron supplements | endoscopic dilatation & biopsy to rule out cancer.