

VASCULAR INVESTIGATIONS

Abdulmajeed Altoijry, MD, MSc, FRCSC
Assistant Professor & Consultant Vascular Surgeon
King Saud University Medical City
King Saud University

➤ Sensitive:

➤ Operator dependent:

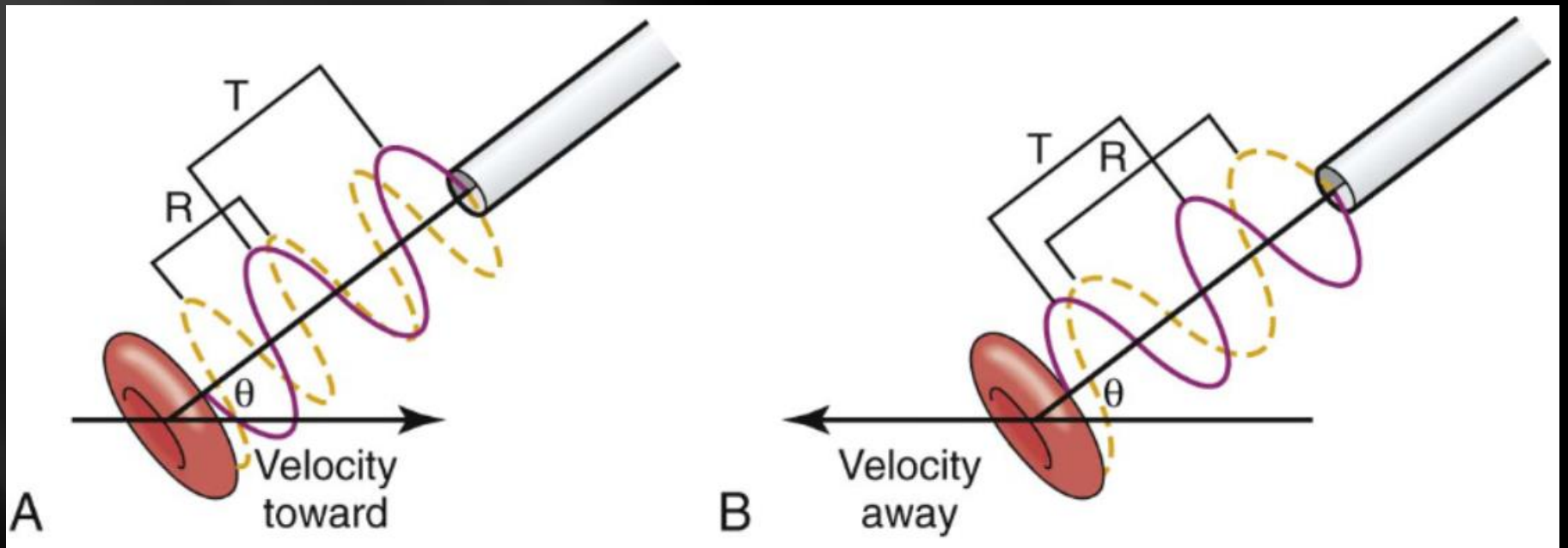
➤ Toxic:

➤ Therapeutic:

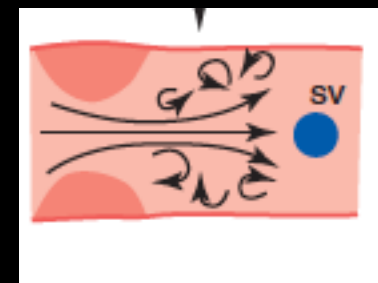
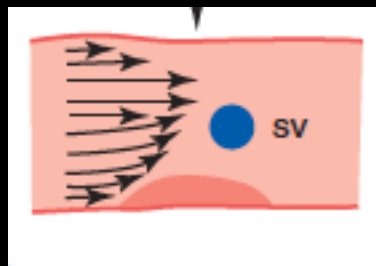
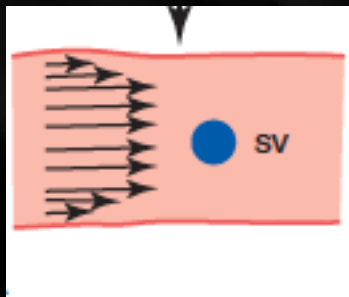
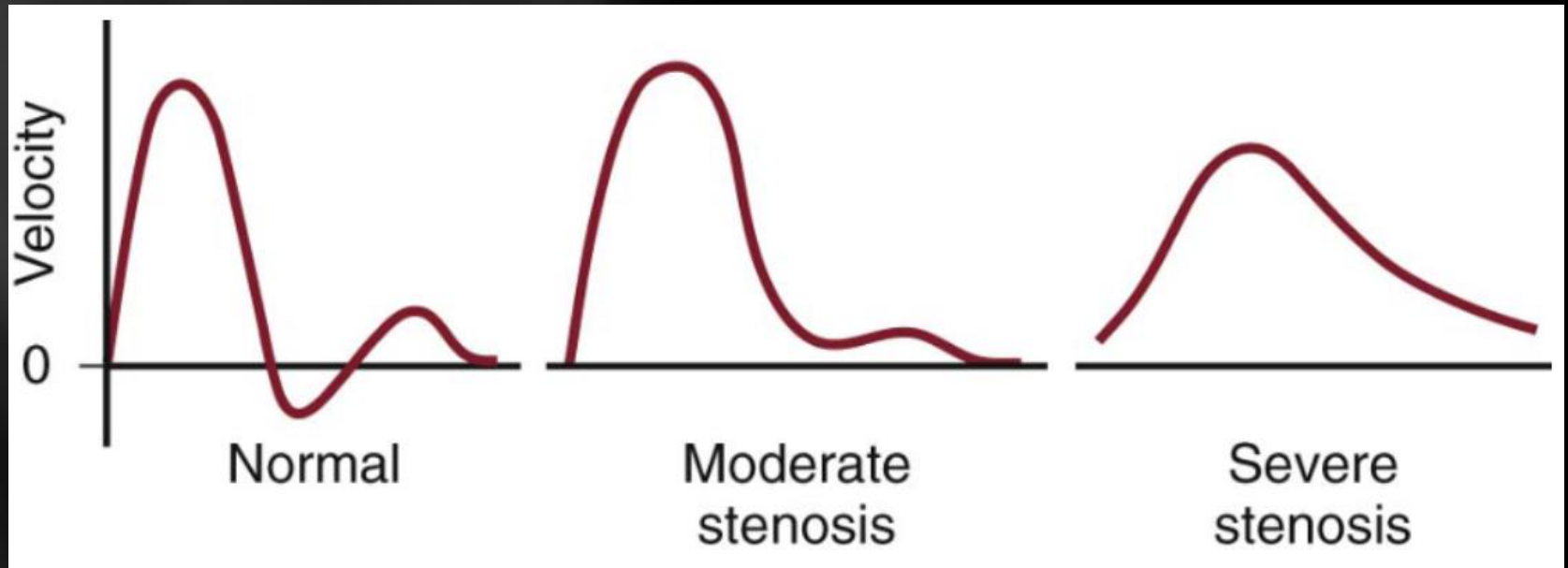
HANDHELD DOPPLER



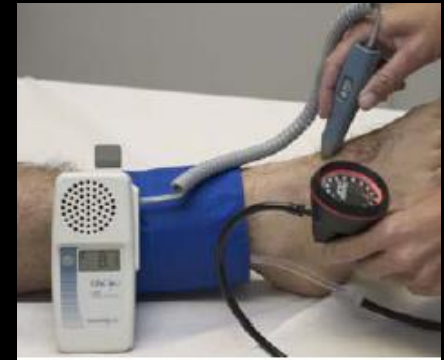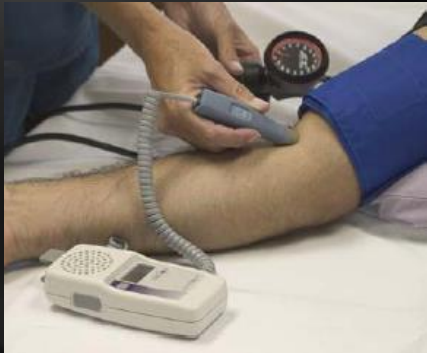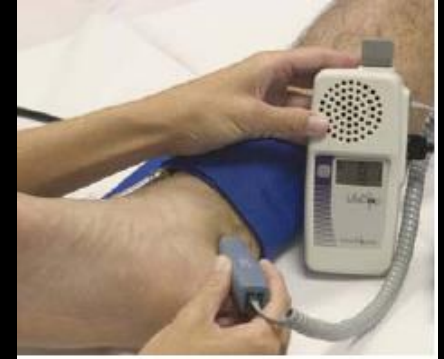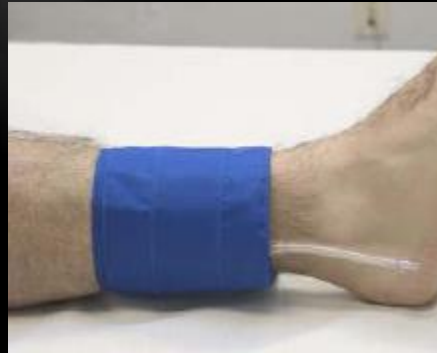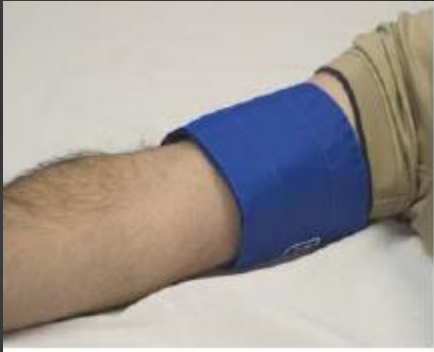HANDHELD DOPPLER



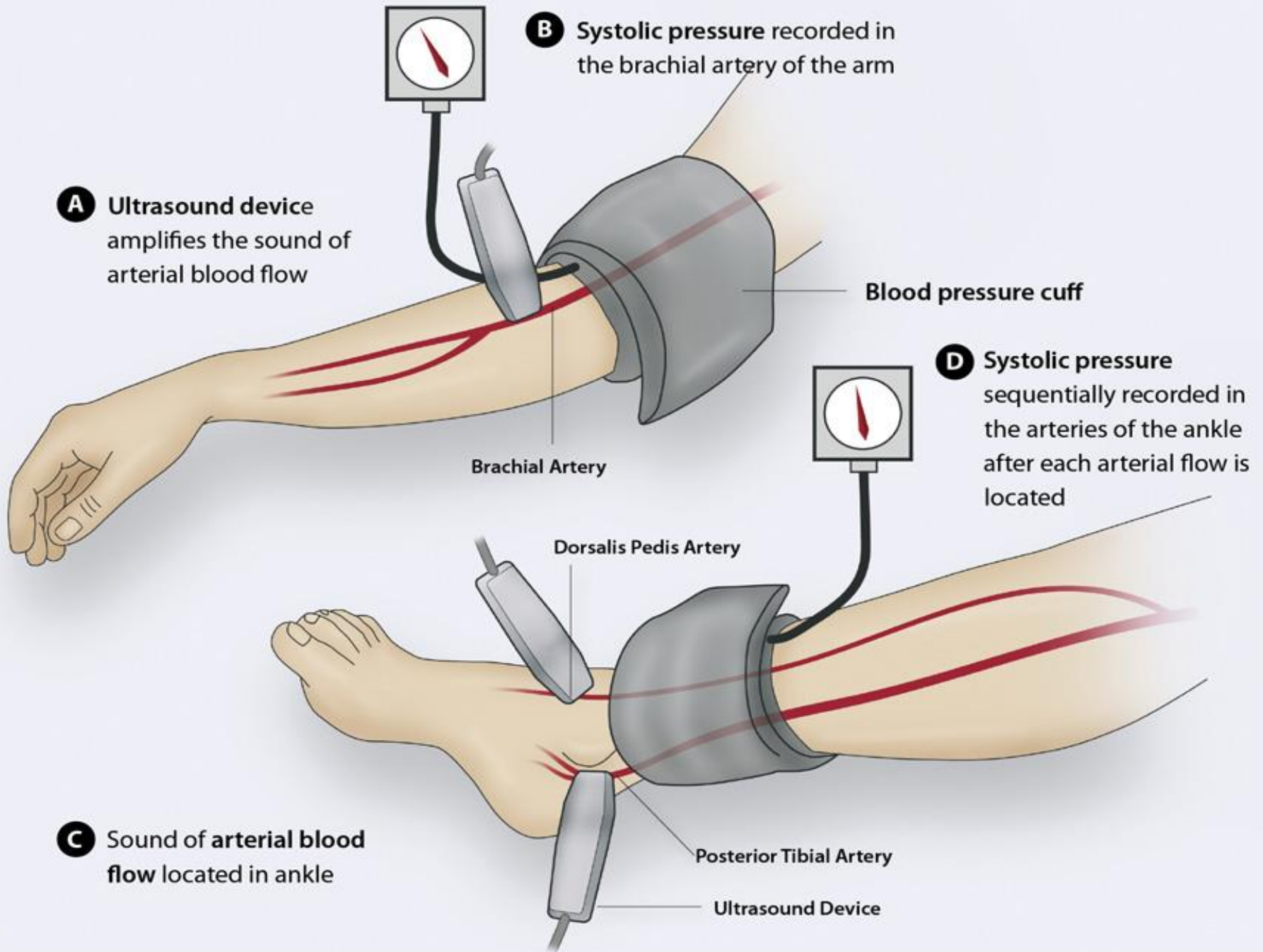
HANDHELD DOPPLER



ANKLE BRACHIAL INDEX



$ABI = \text{ANKLE SBP (PT OR DP)} / \text{HIGHEST ARM SBP}$

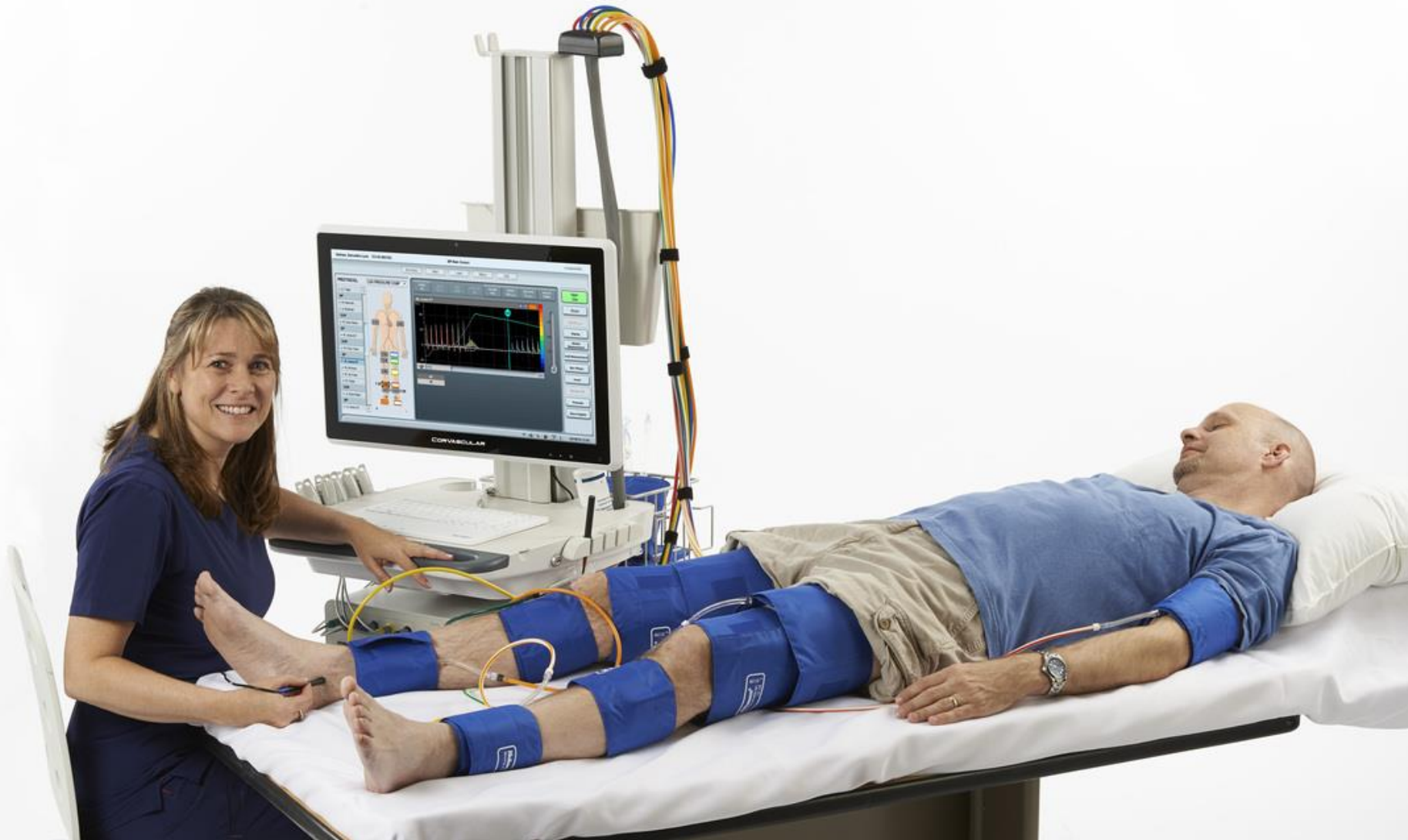


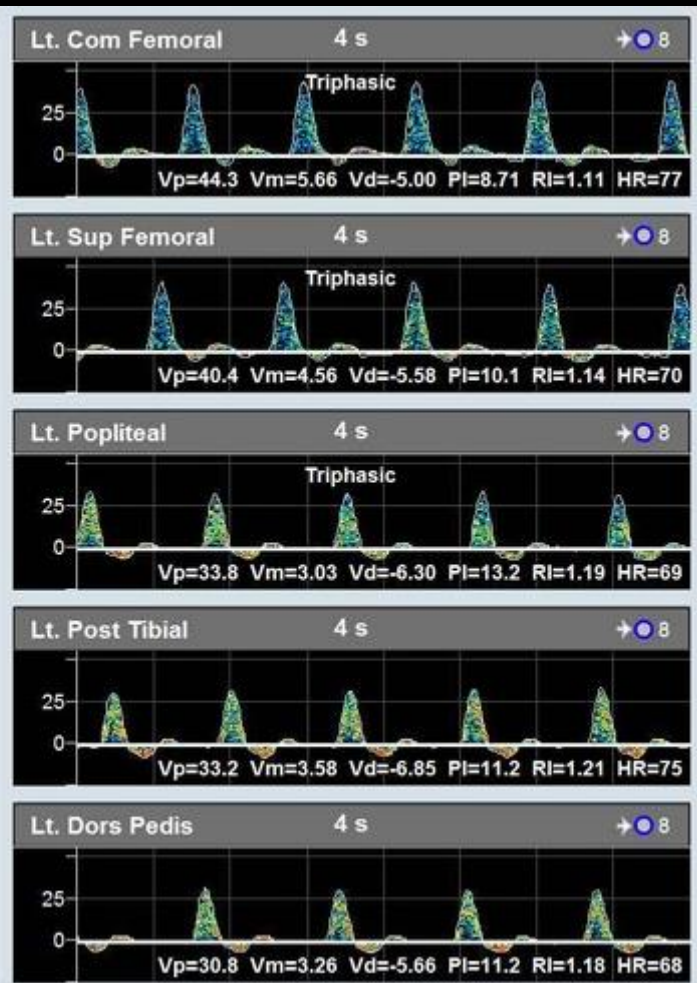
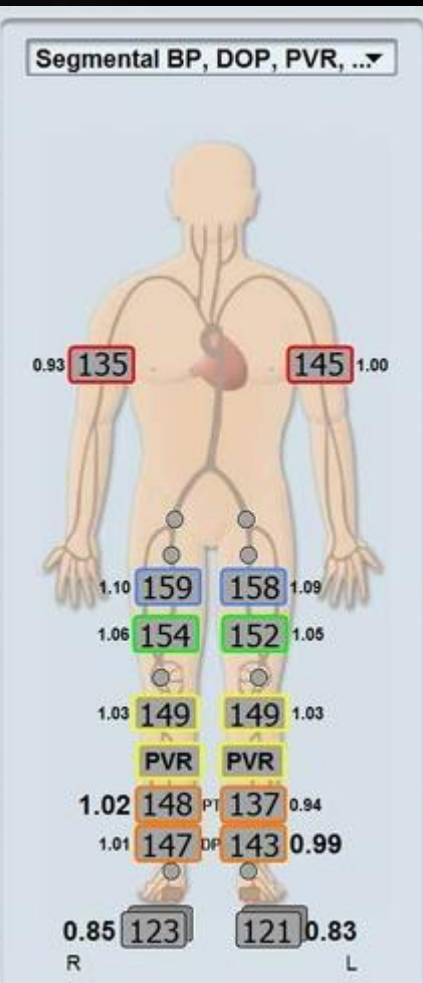
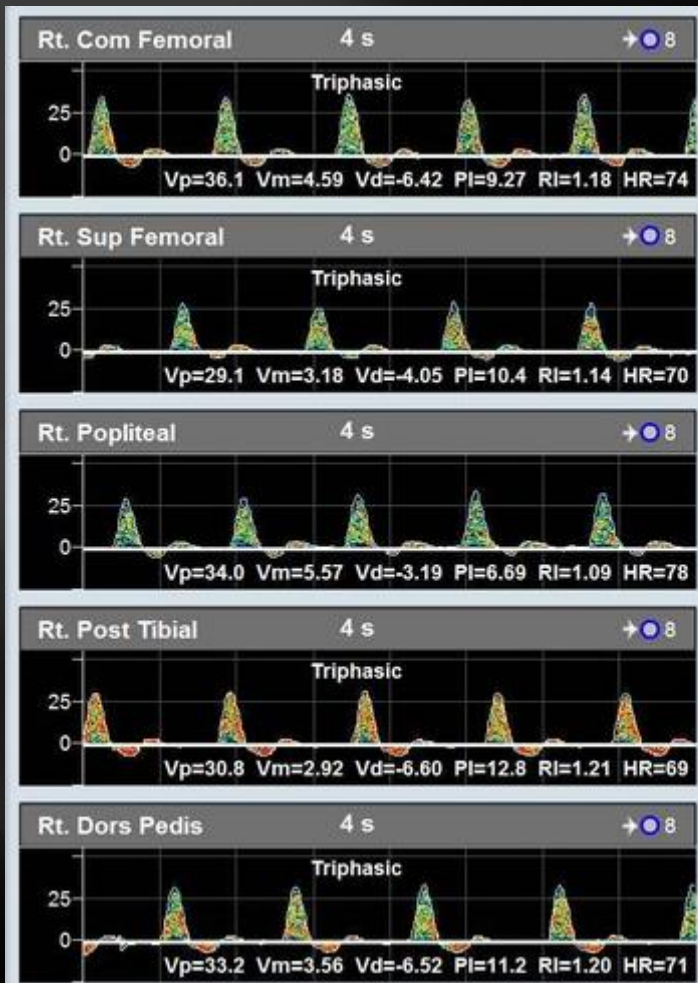
Interpretation of ABI

>1.30	Noncompressible
1.00–1.29	Normal
0.91–0.99	Borderline (equivocal)
0.41–0.90	Mild to moderate peripheral arterial disease
0.00–0.40	Severe peripheral arterial disease

The ABI has limited use in evaluating calcified vessels that are not compressible as in Diabetics

SEGMENTAL PRESSURE





➤ Sensitive: ✓

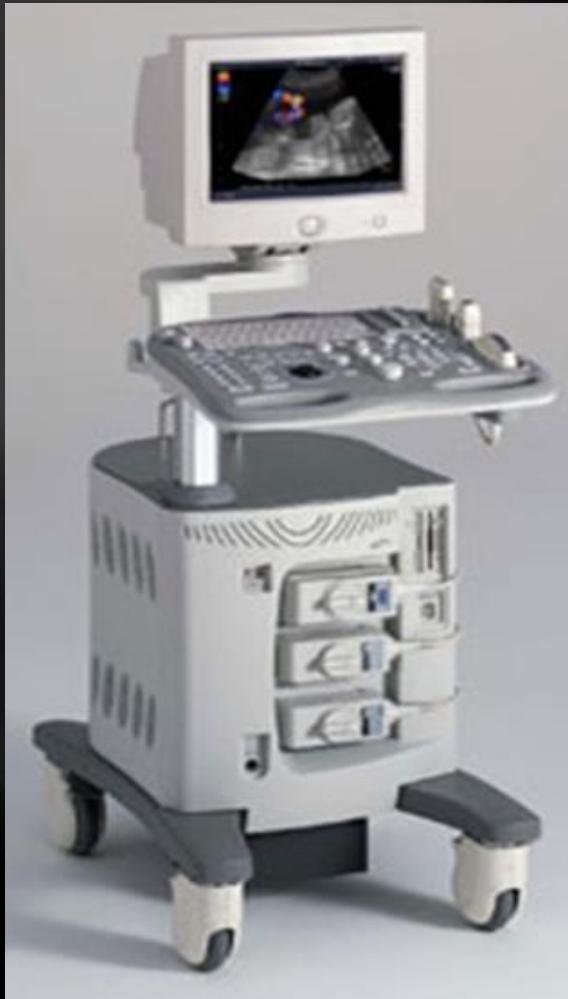➤ Operator dependent: ✓✓✓

➤ Toxic: ✗

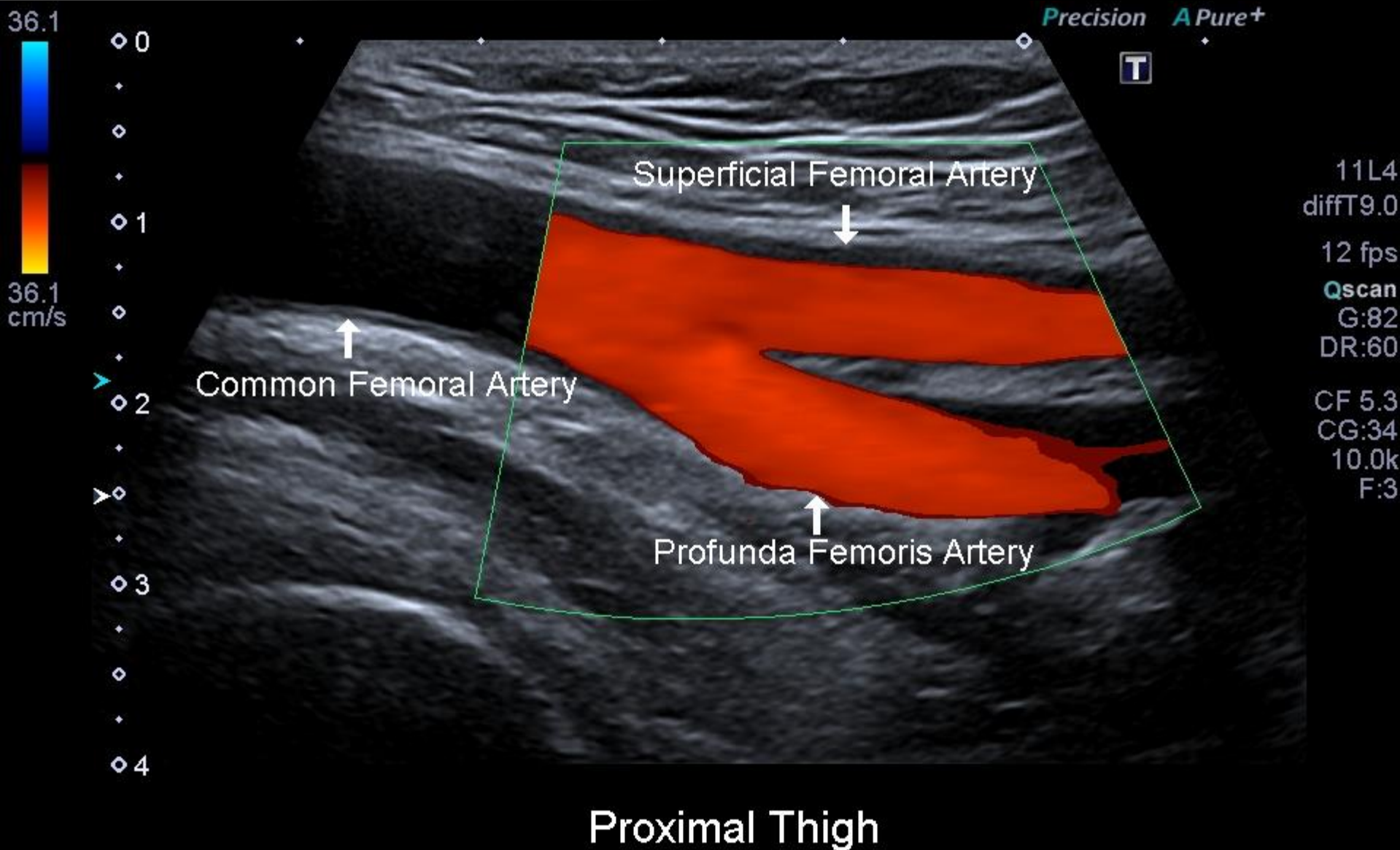
➤ Therapeutic: ✗

DUPLEX ULTRASOUND

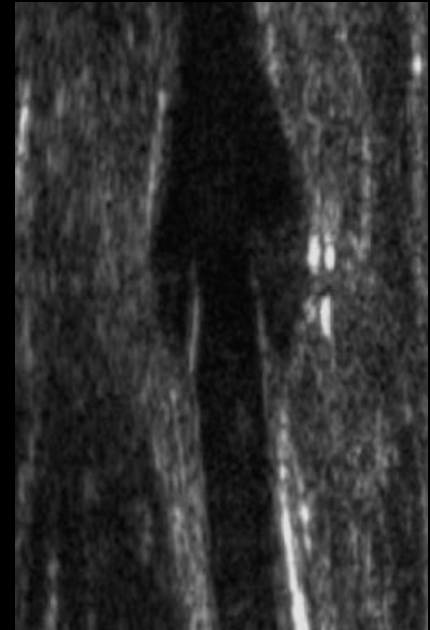
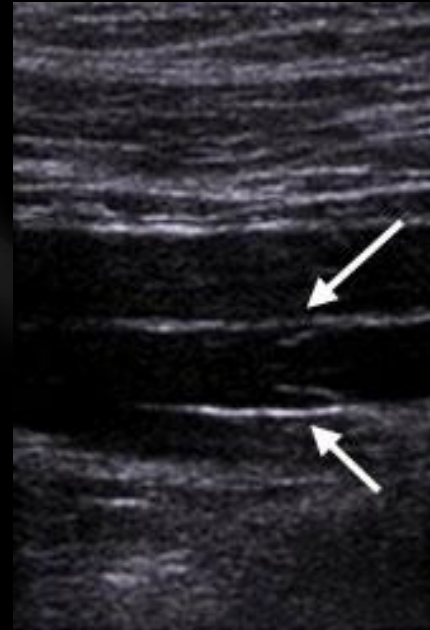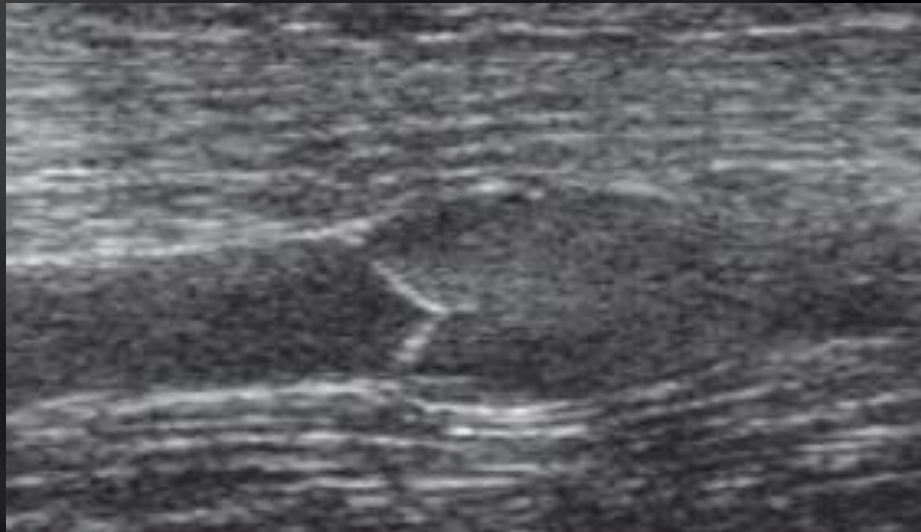
B - mode + Color Doppler



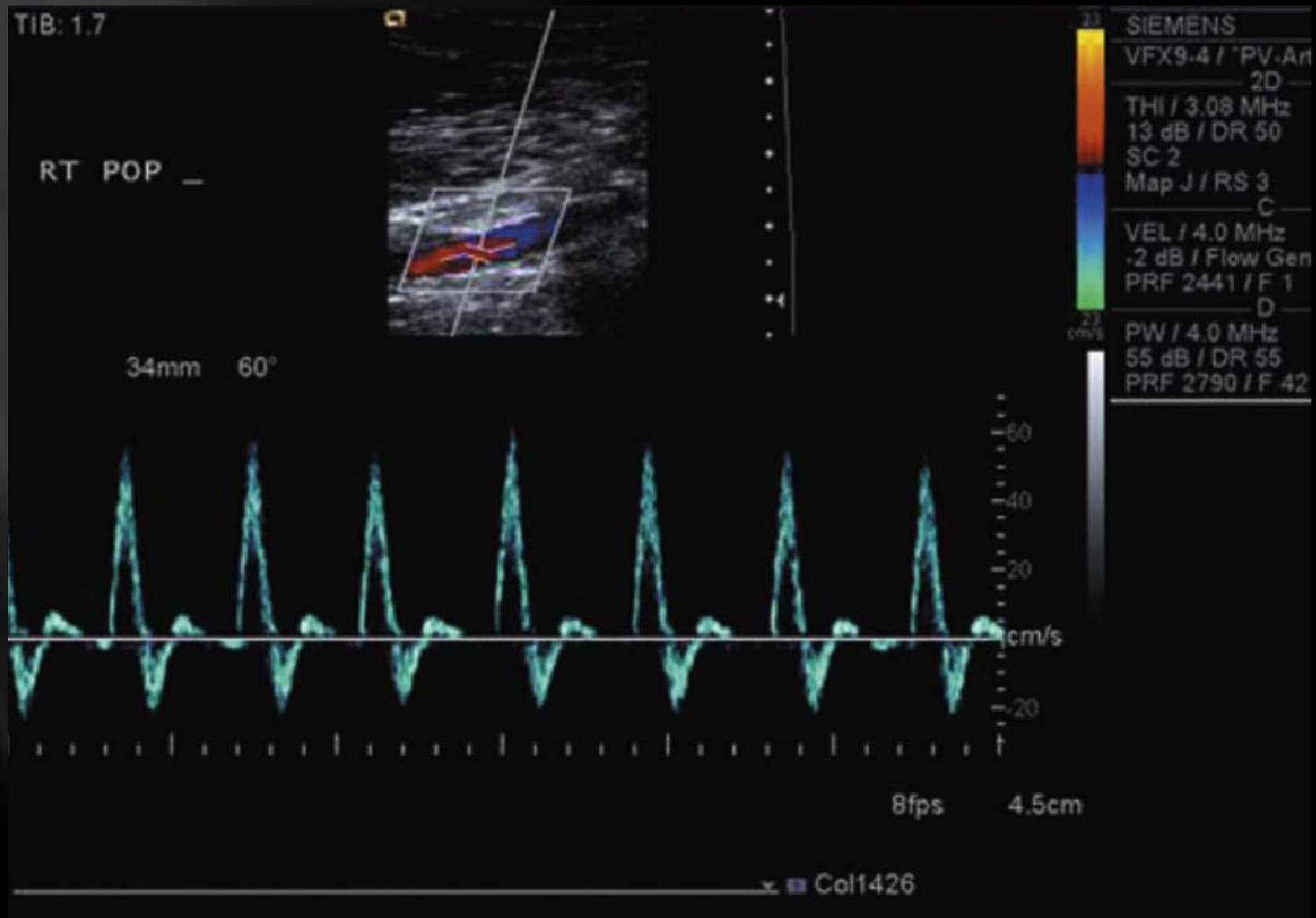
DUPLEX ULTRASOUND



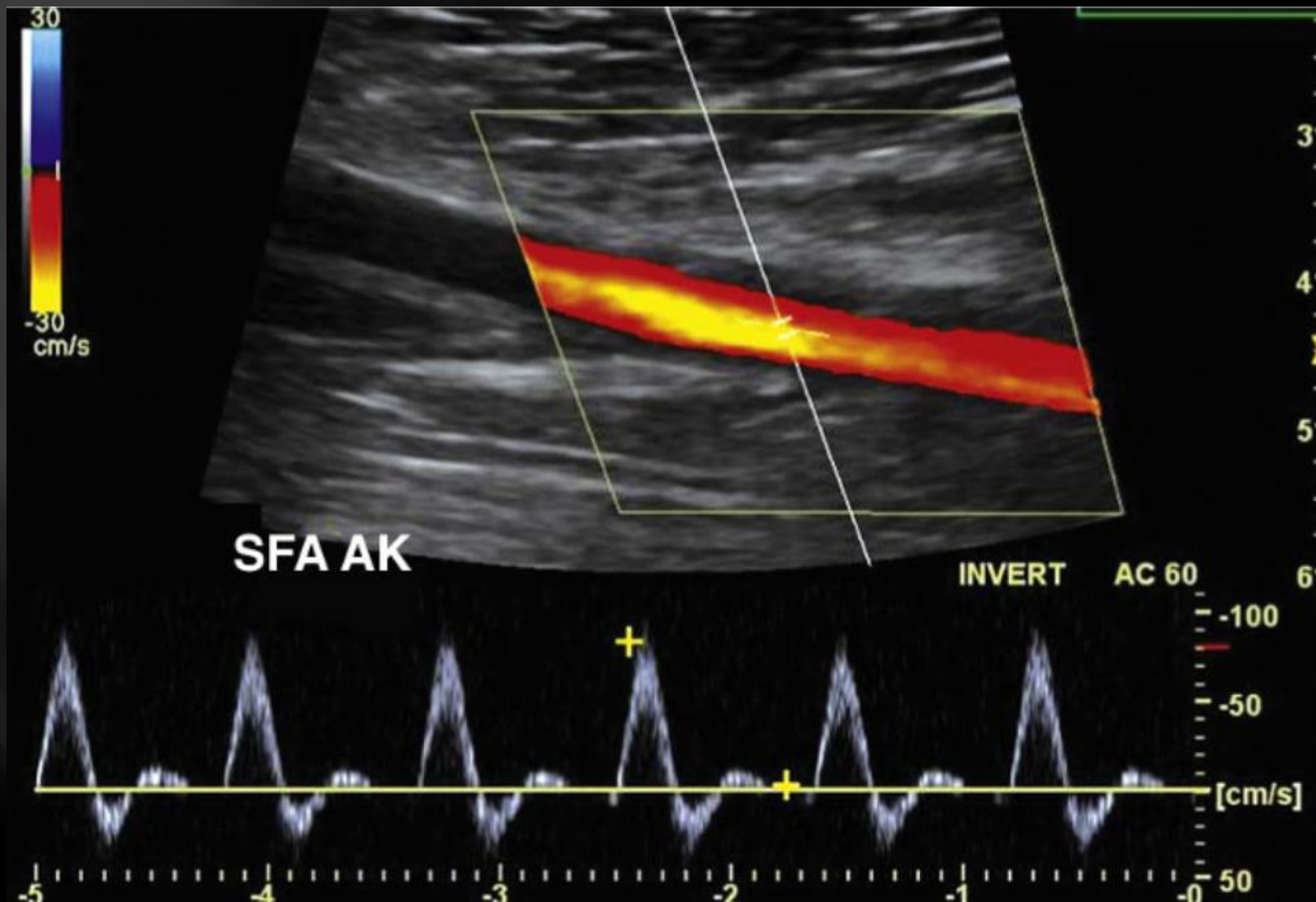
DUPLEX ULTRASOUND



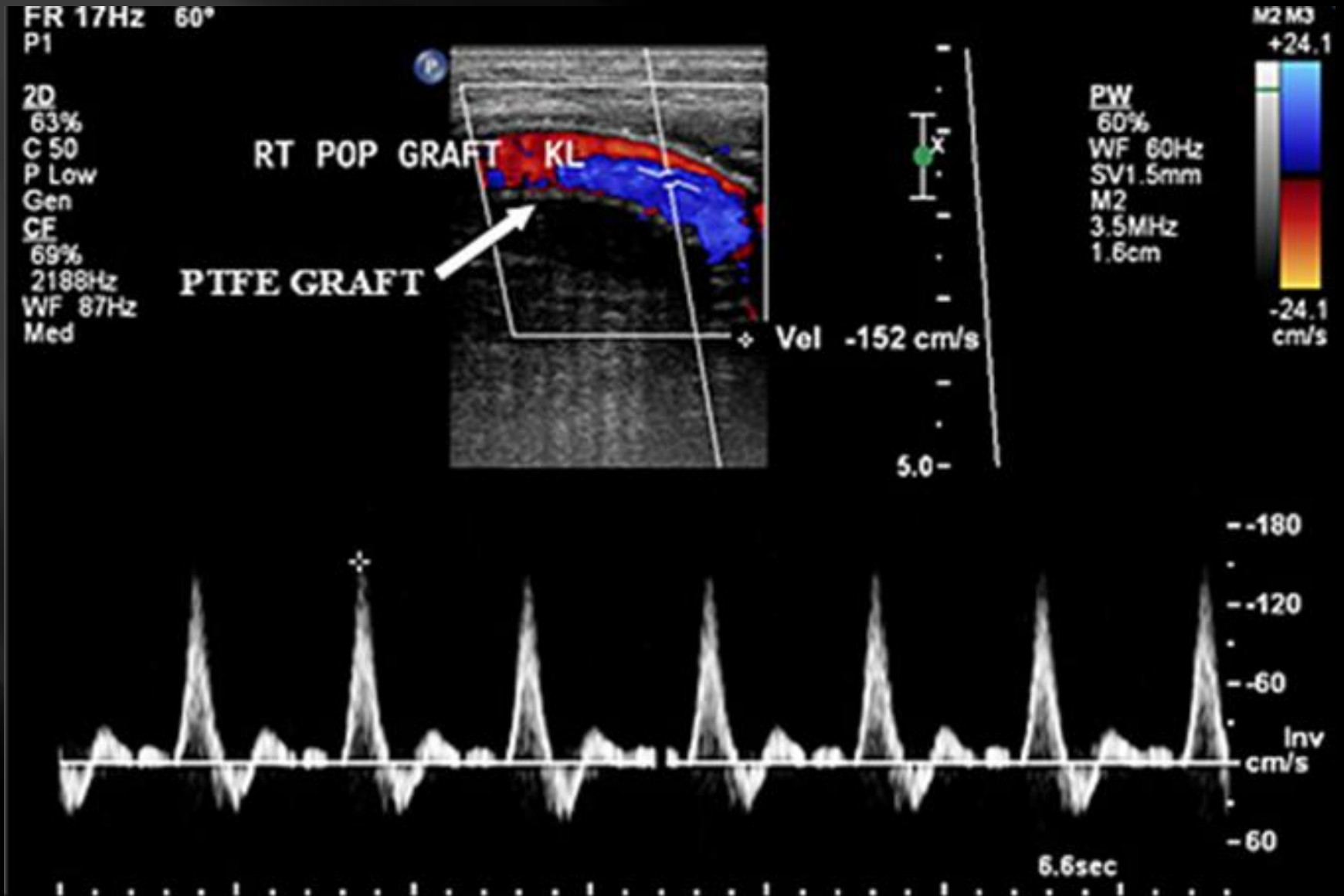
DUPLEX ULTRASOUND



DUPLEX ULTRASOUND



DUPLEX ULTRASOUND



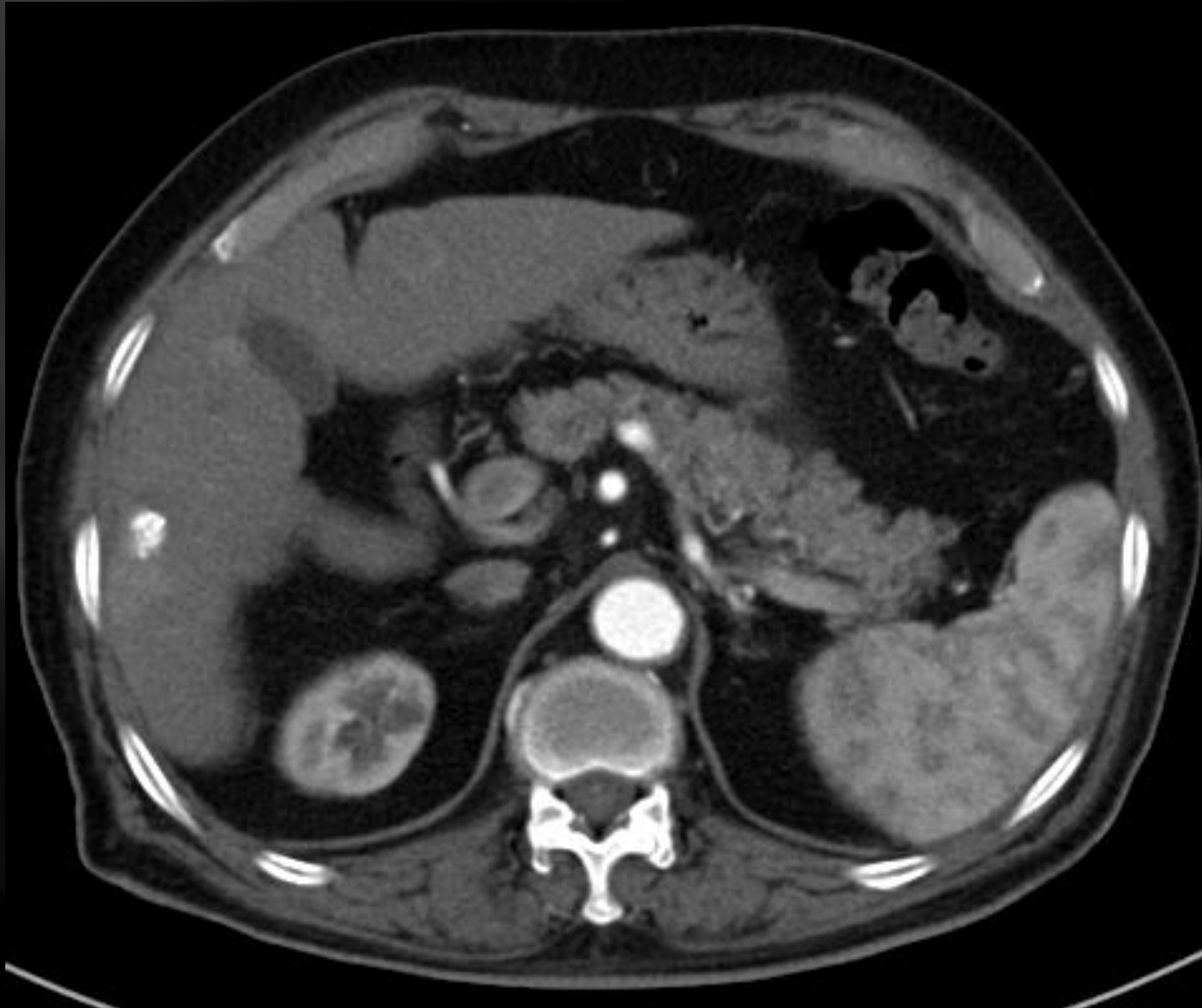➤ Sensitive: ✓✓✓

➤ Operator dependent: ✓✓✓

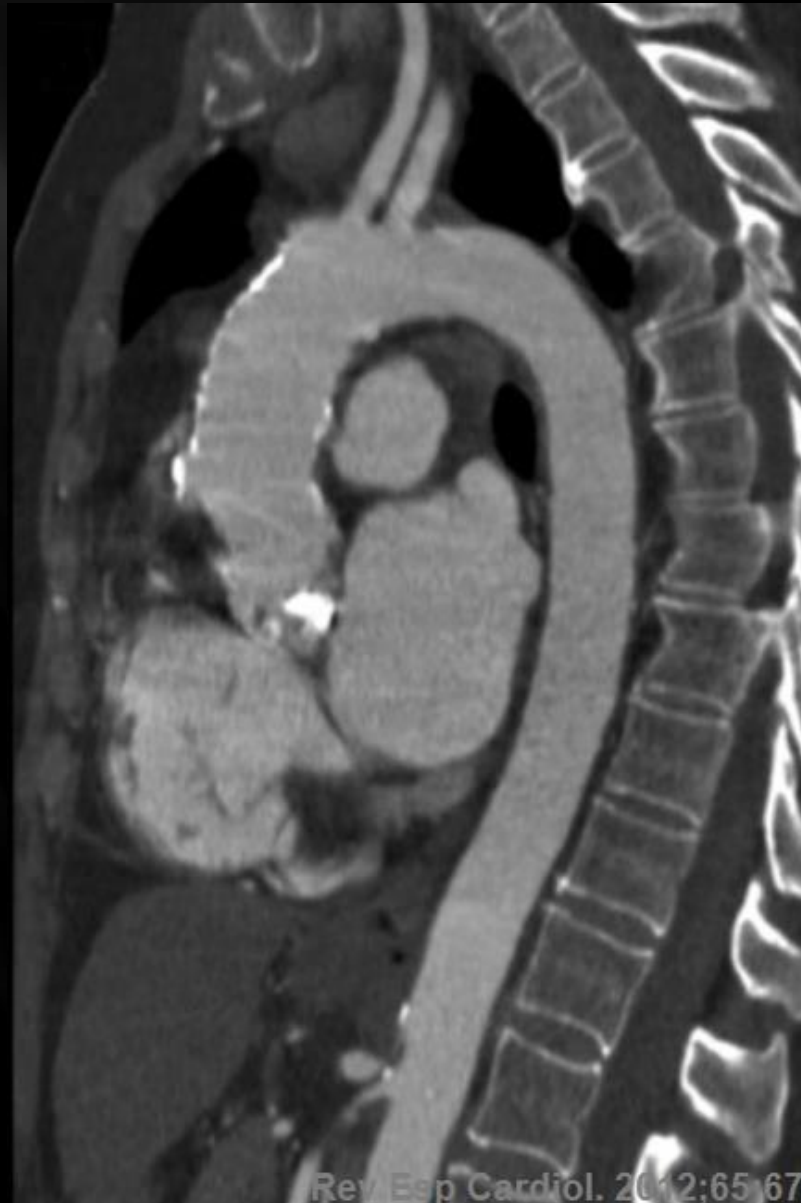➤ Toxic: ✗

➤ Therapeutic: ✗

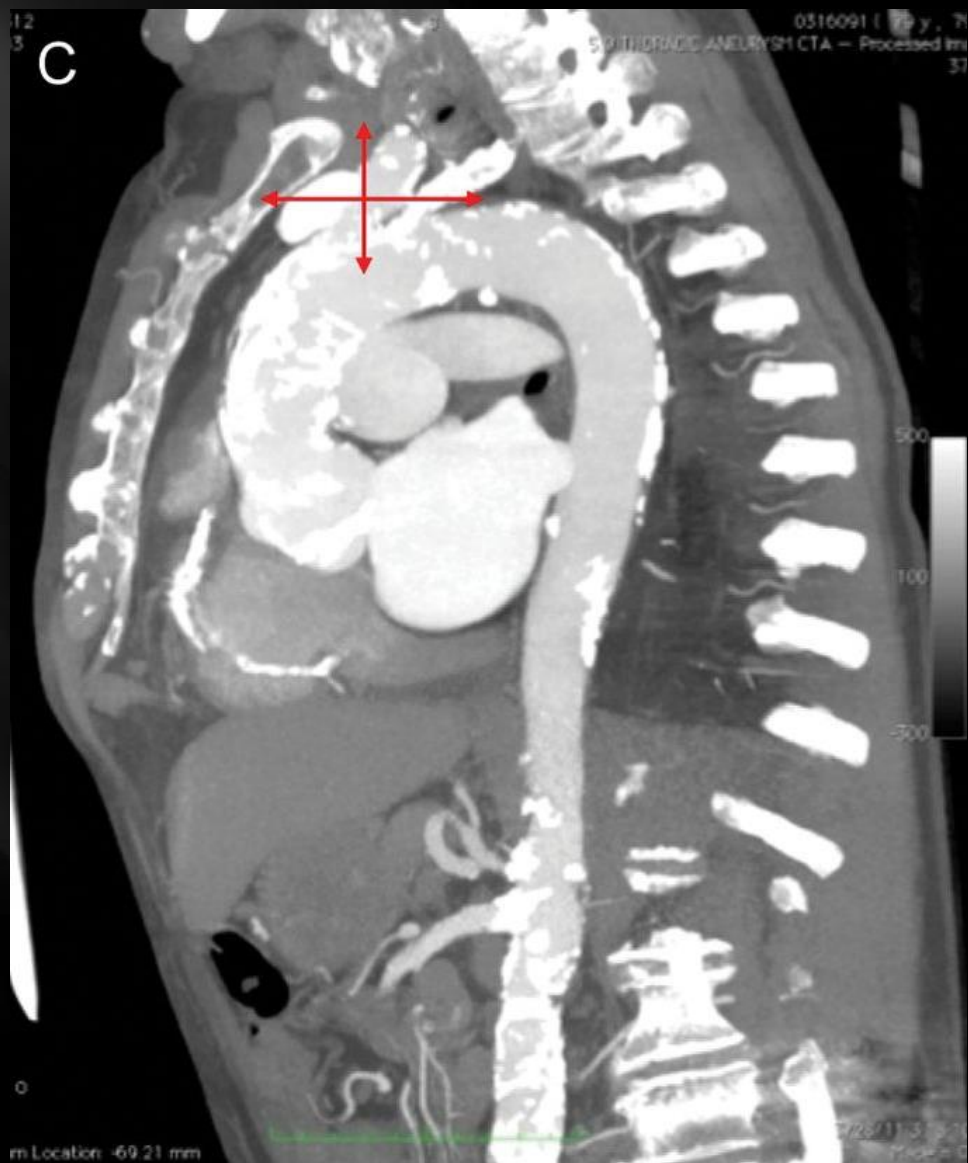CT ANGIOGRAM



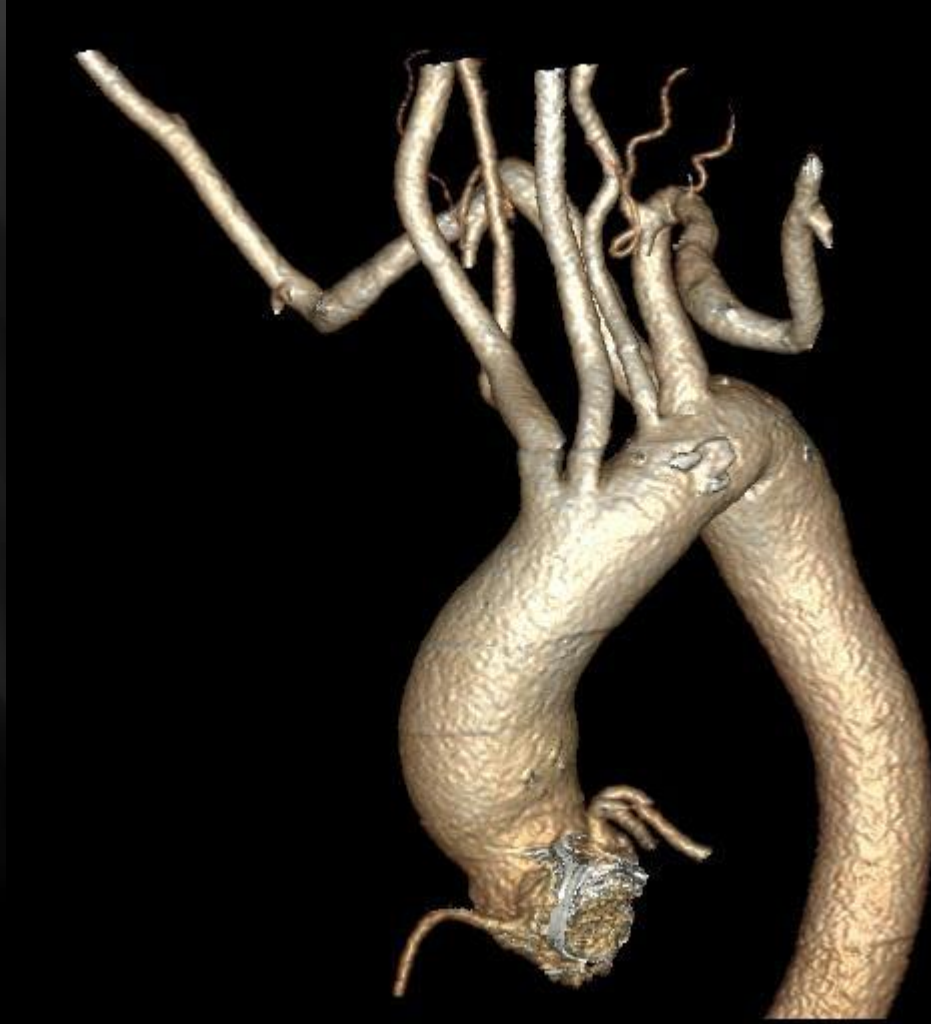CT ANGIOGRAM



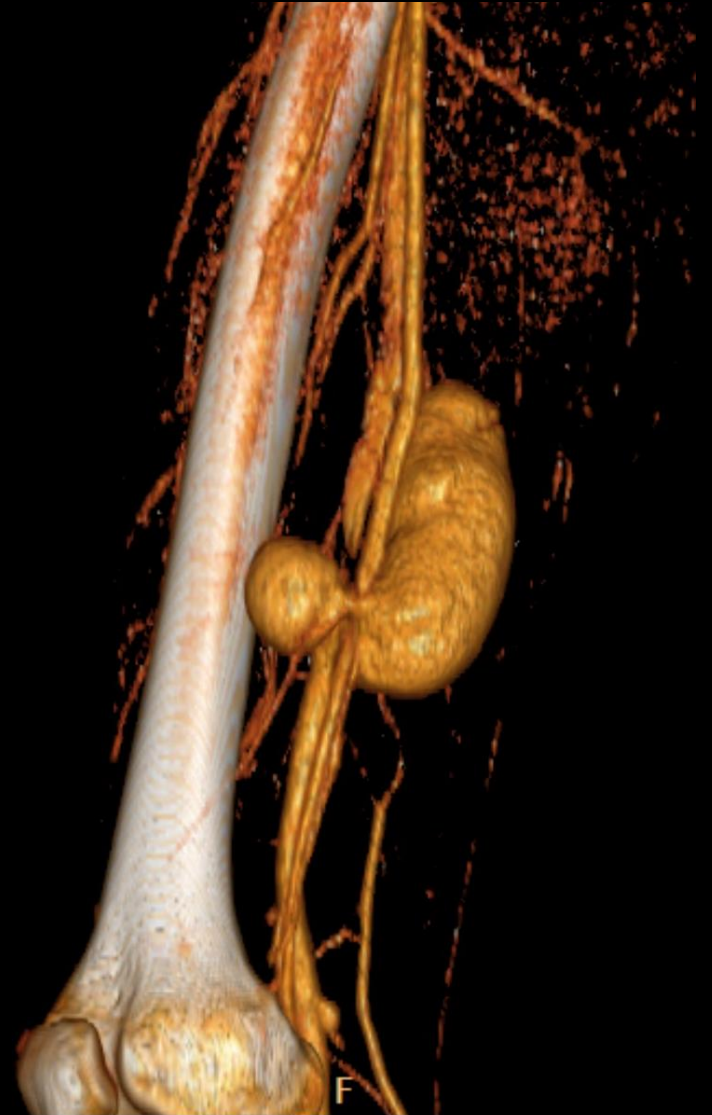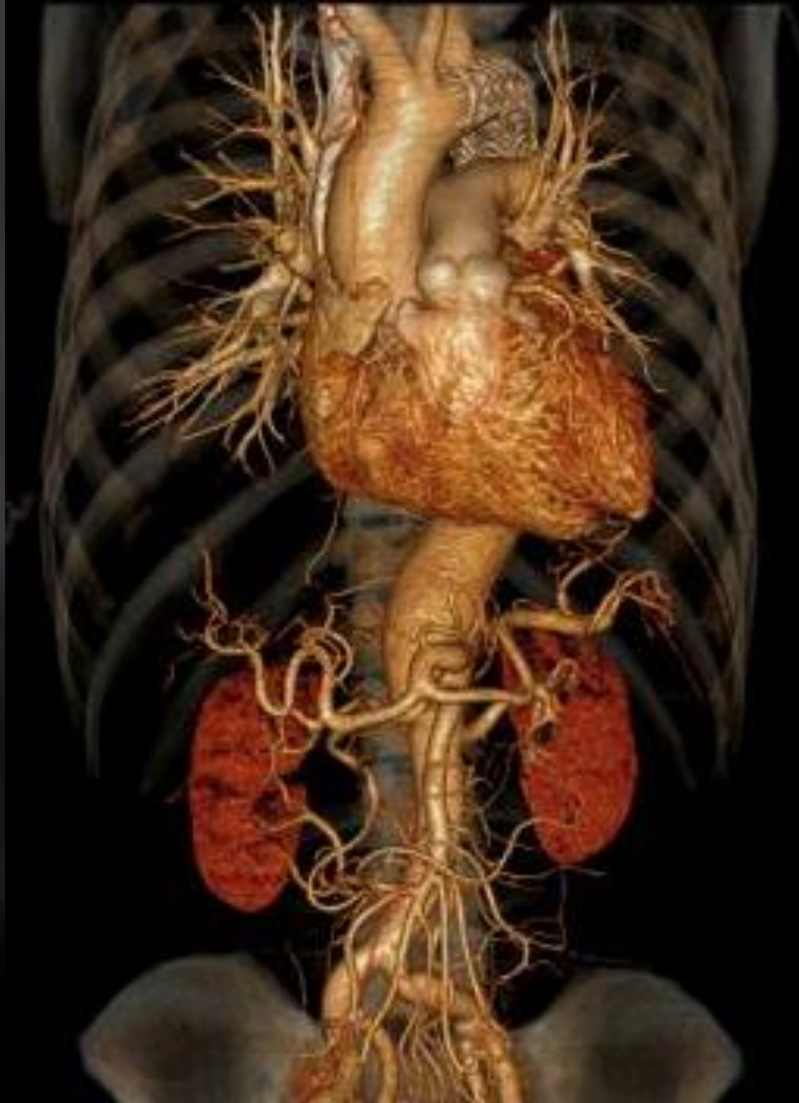CT ANGIOGRAM



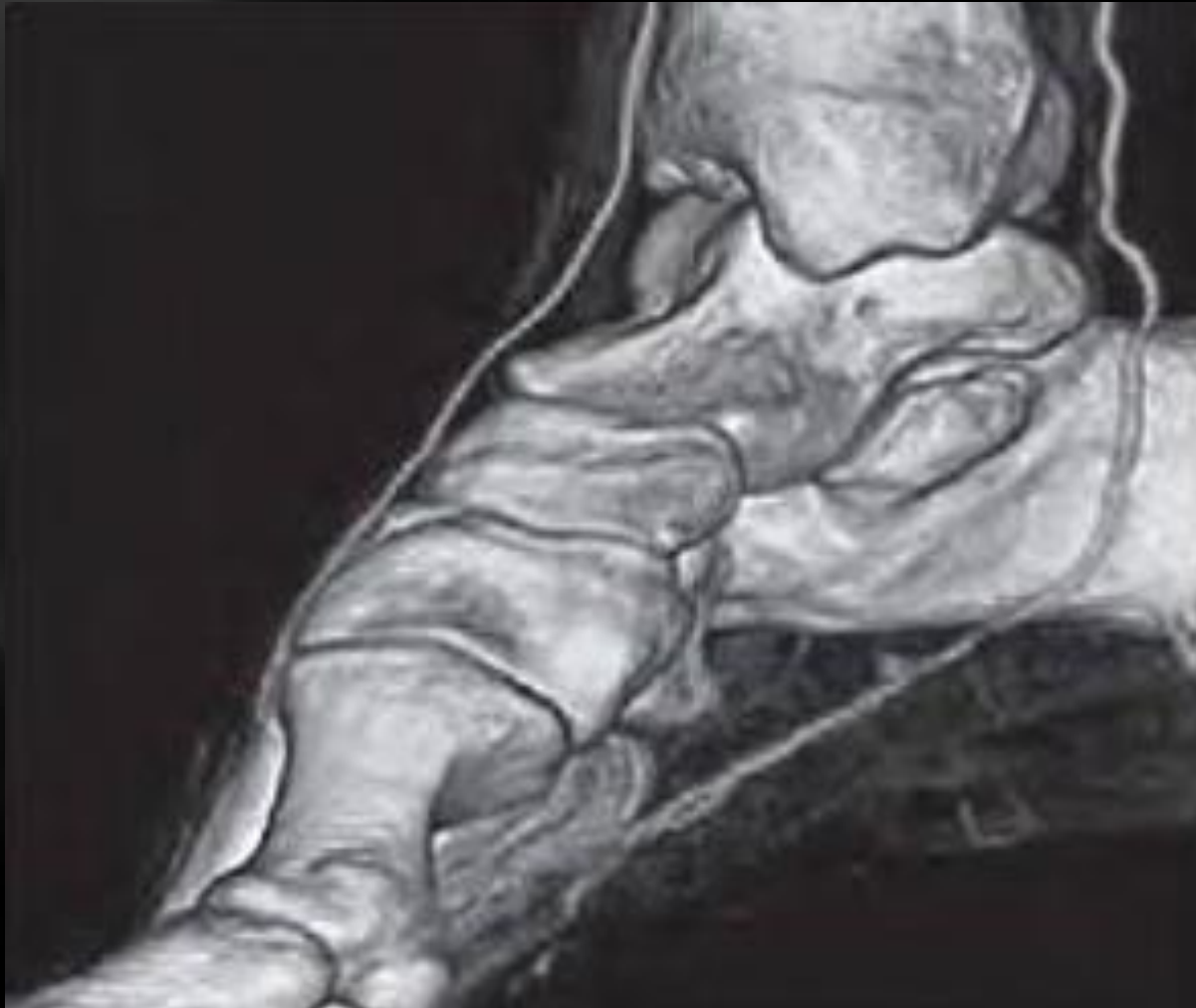CT ANGIOGRAM



CT ANGIOGRAM



CT ANGIOGRAM



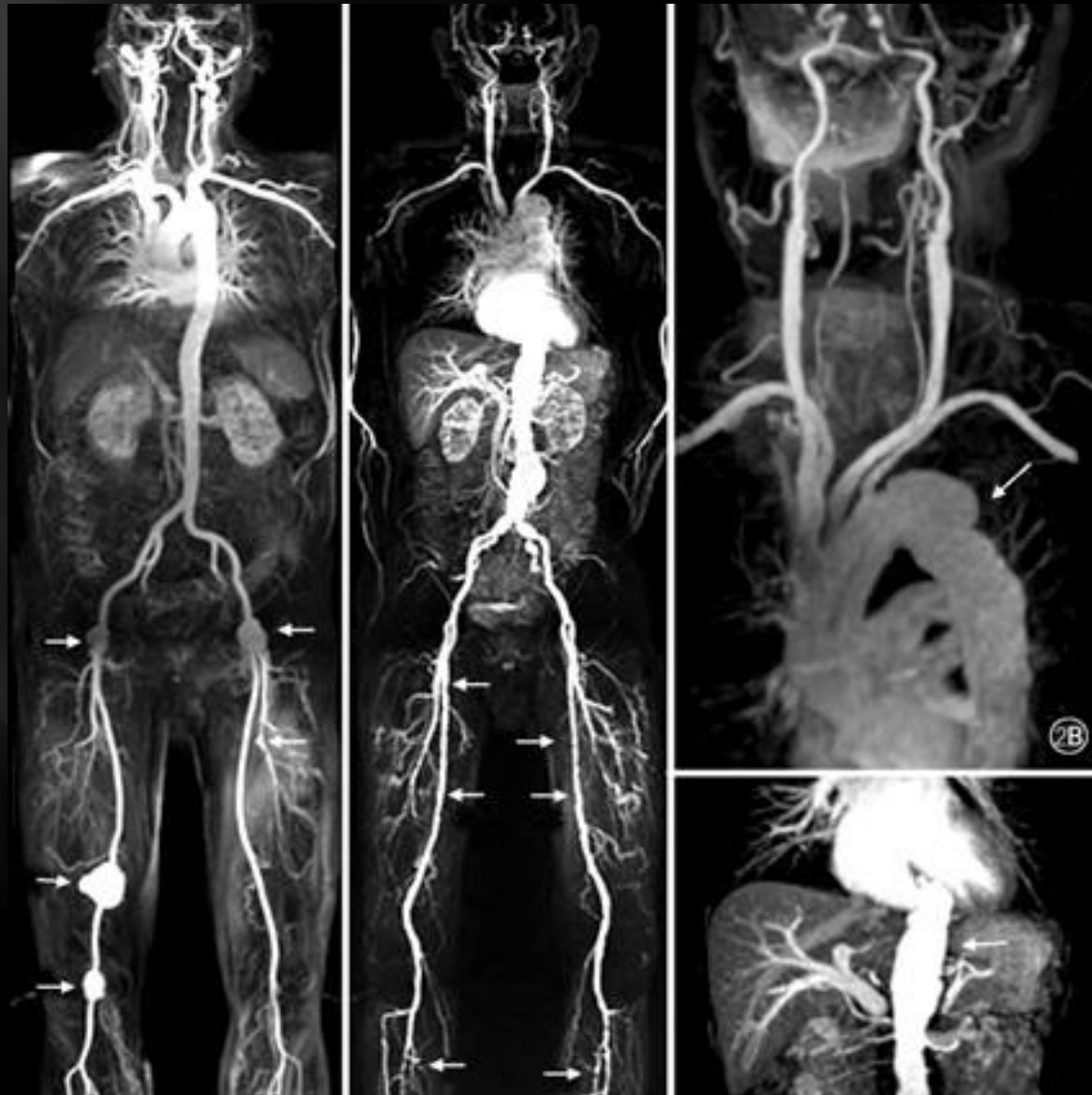➤ Sensitive: ✓✓✓✓✓

➤ Operator dependent: ✗

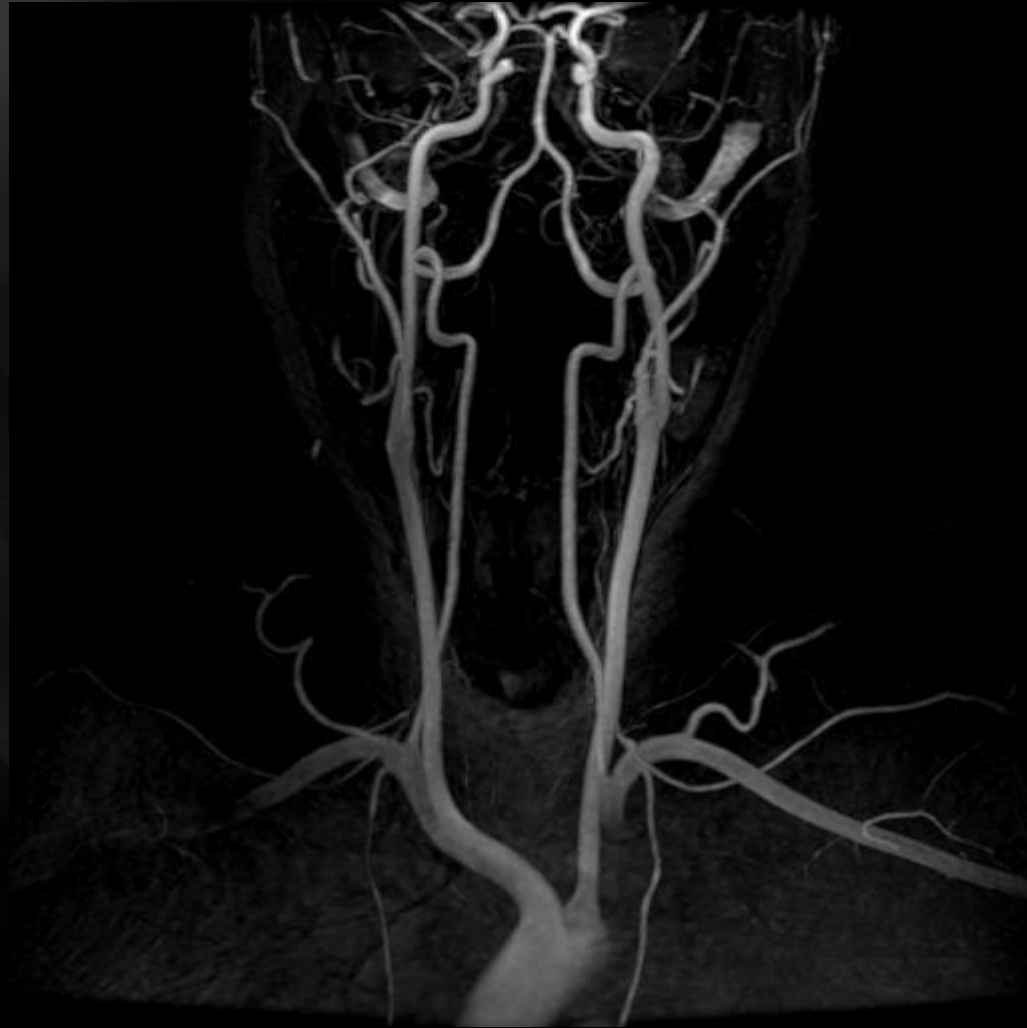
➤ Toxic: ✓✓✓

➤ Therapeutic: ✗

MR ANGIOGRAM



MR ANGIOGRAM



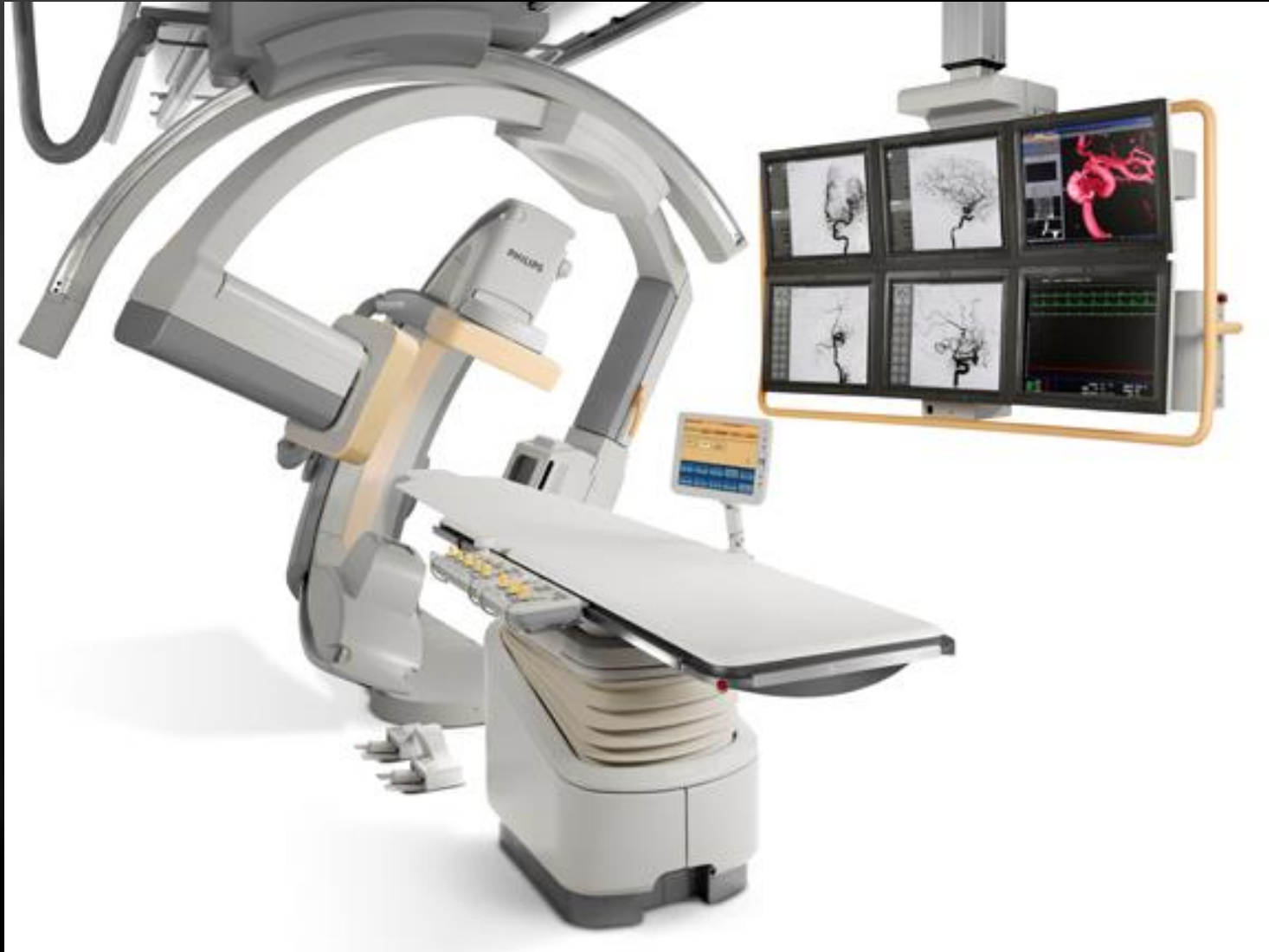➤ Sensitive: ✓✓✓✓

➤ Operator dependent: ✗

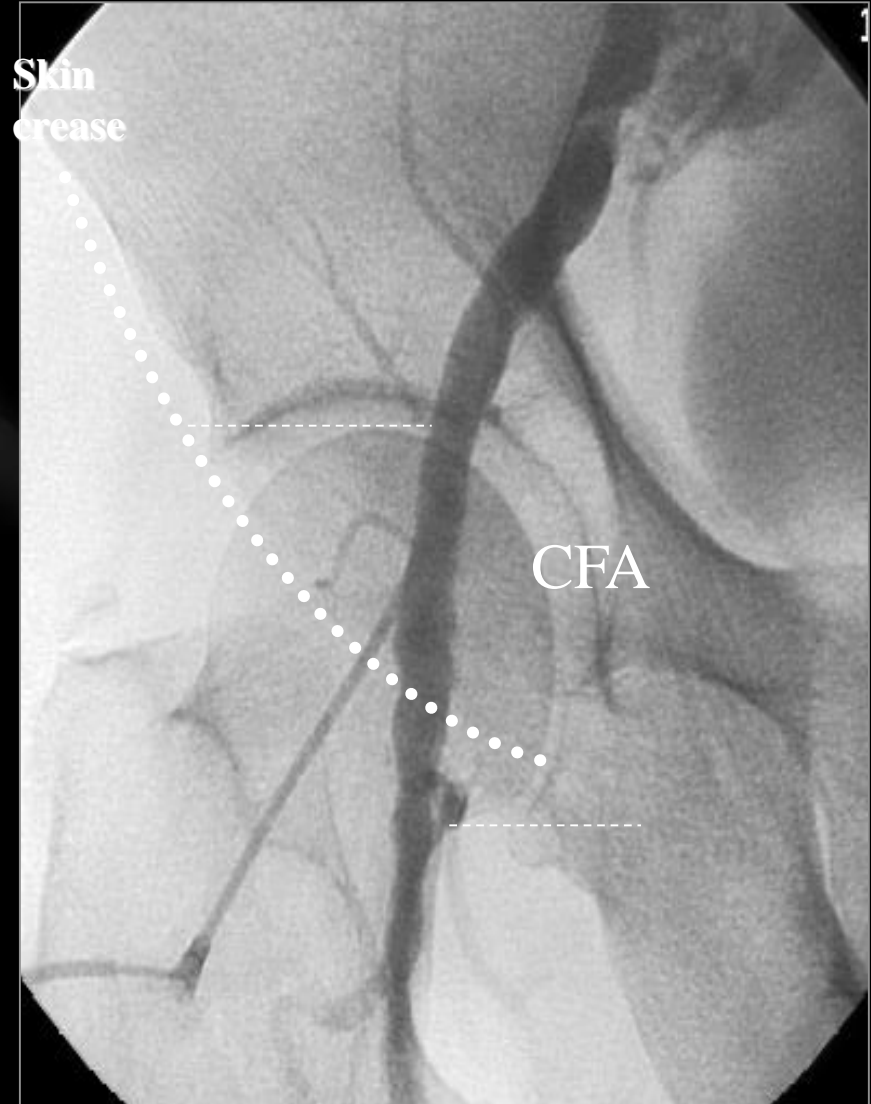
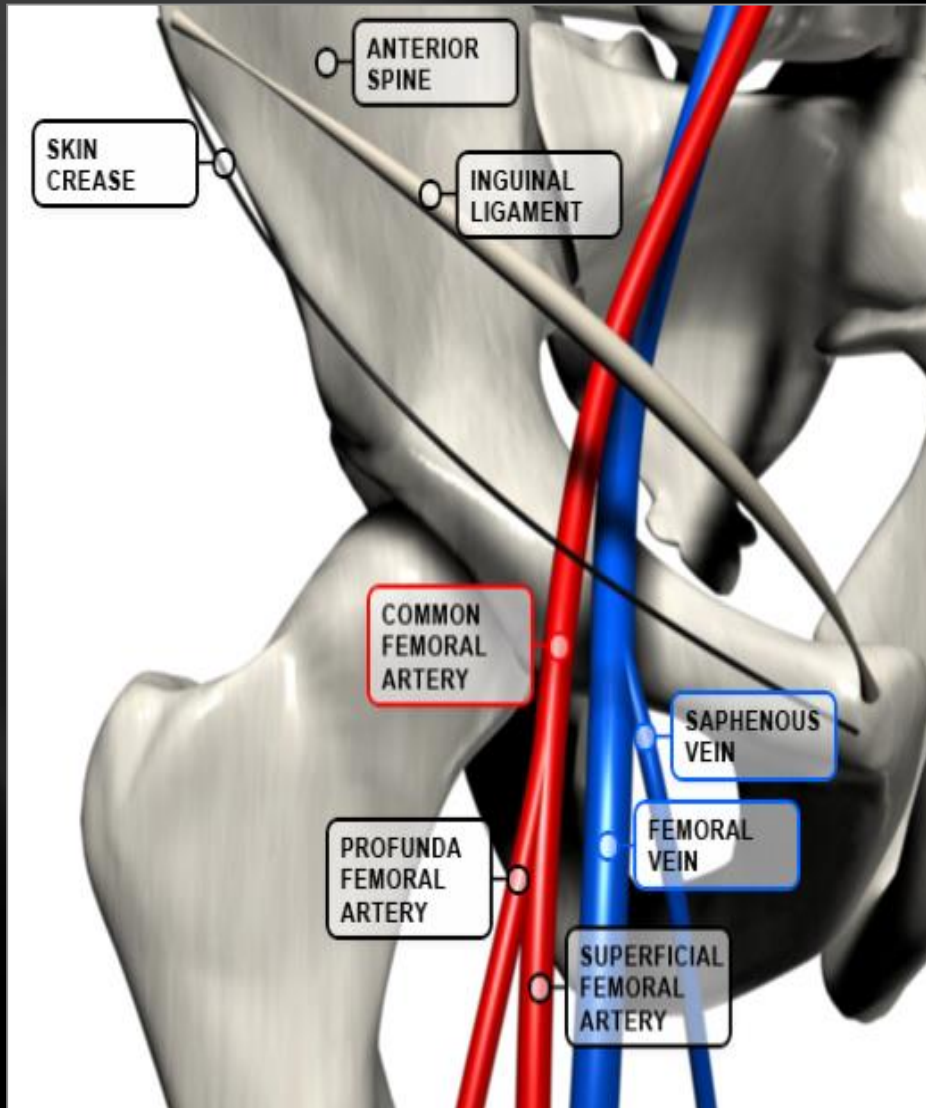
➤ Toxic: ✓✓✓

➤ Therapeutic: ✗

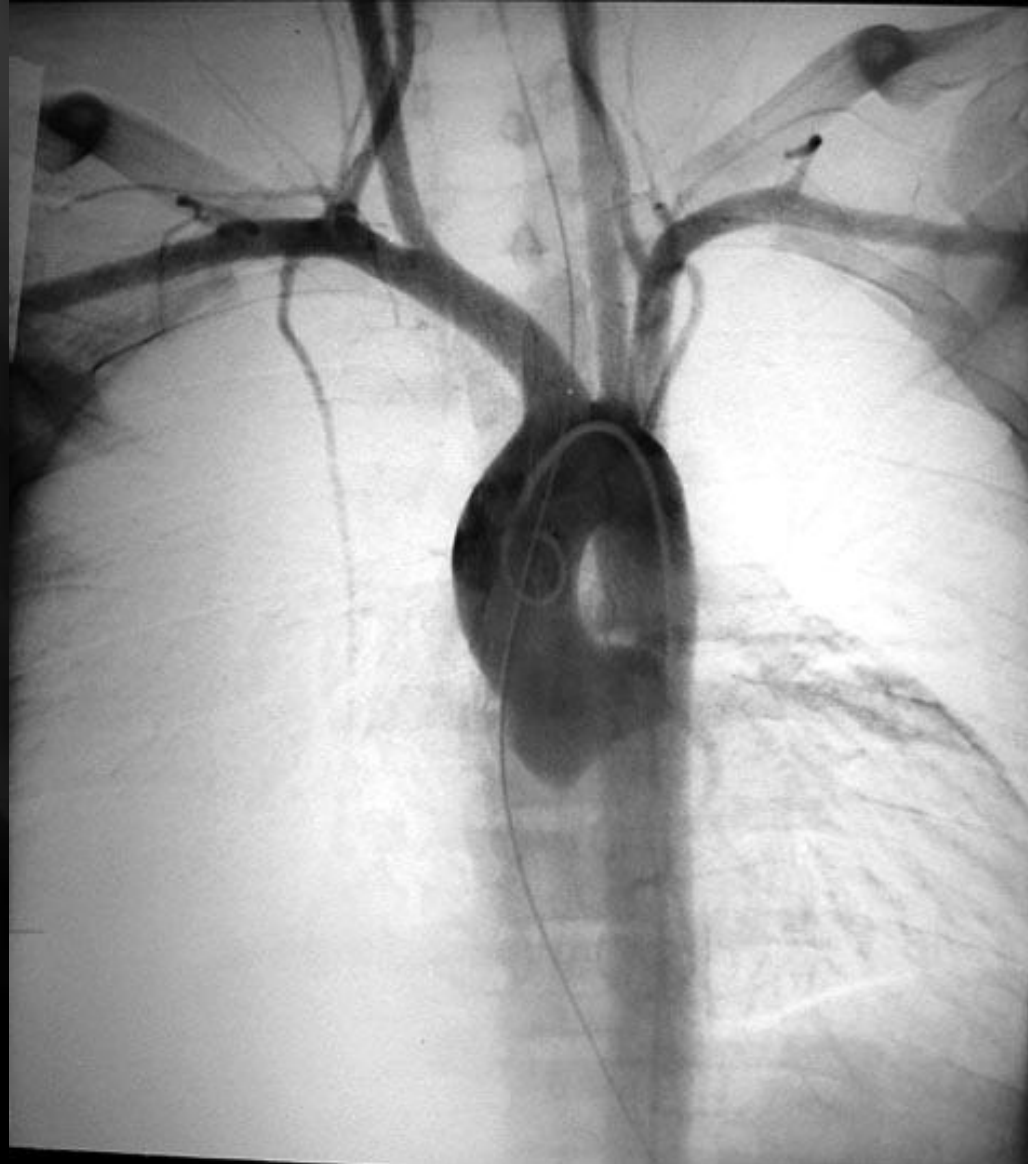ANGIOGRAPHY



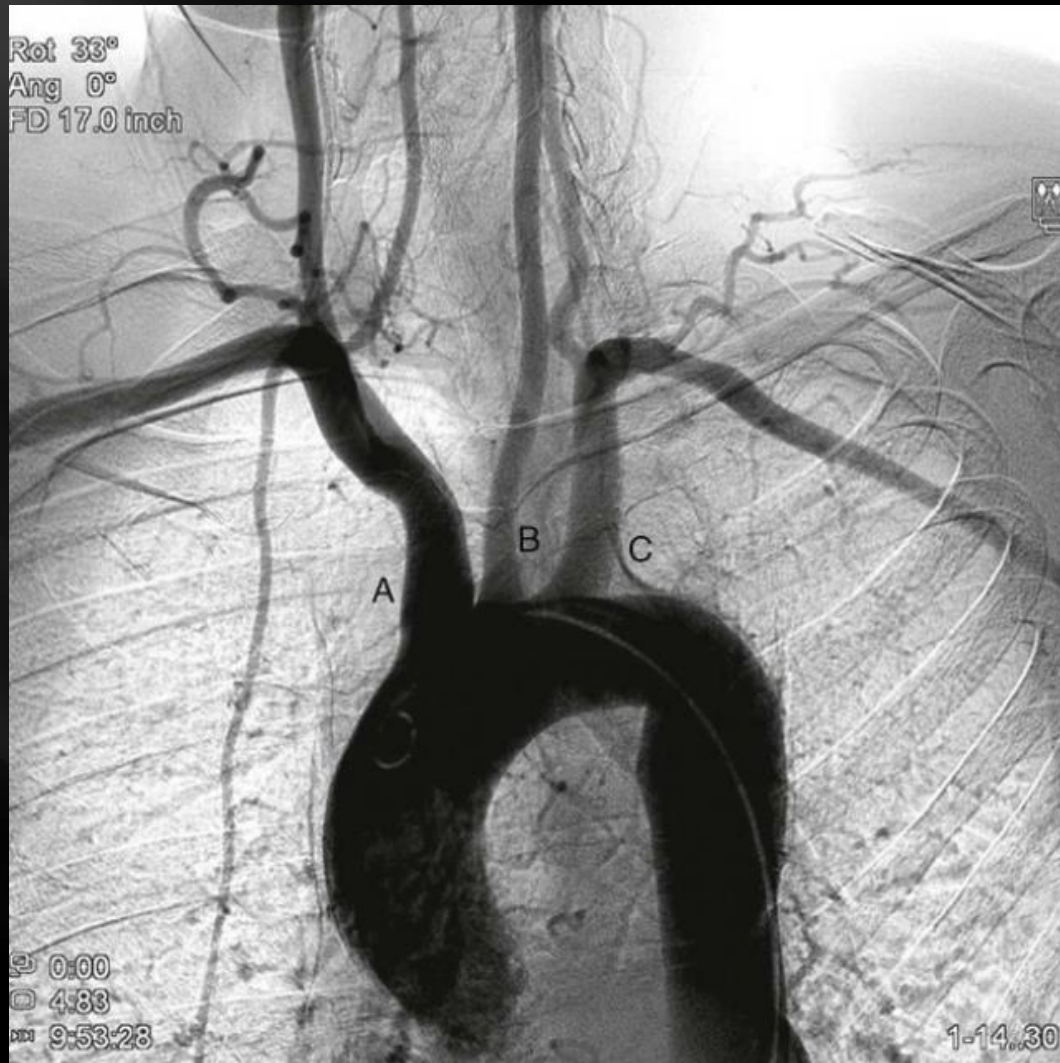
Femoral Artery



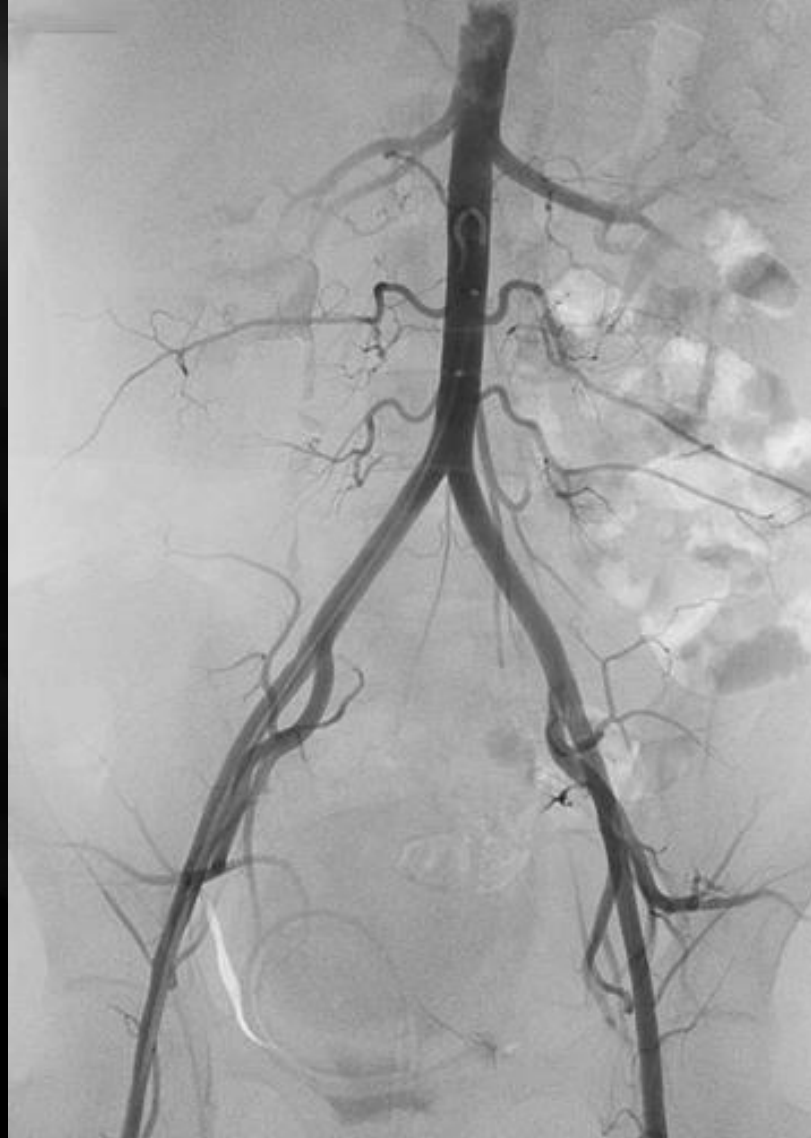ANGIOGRAPHY



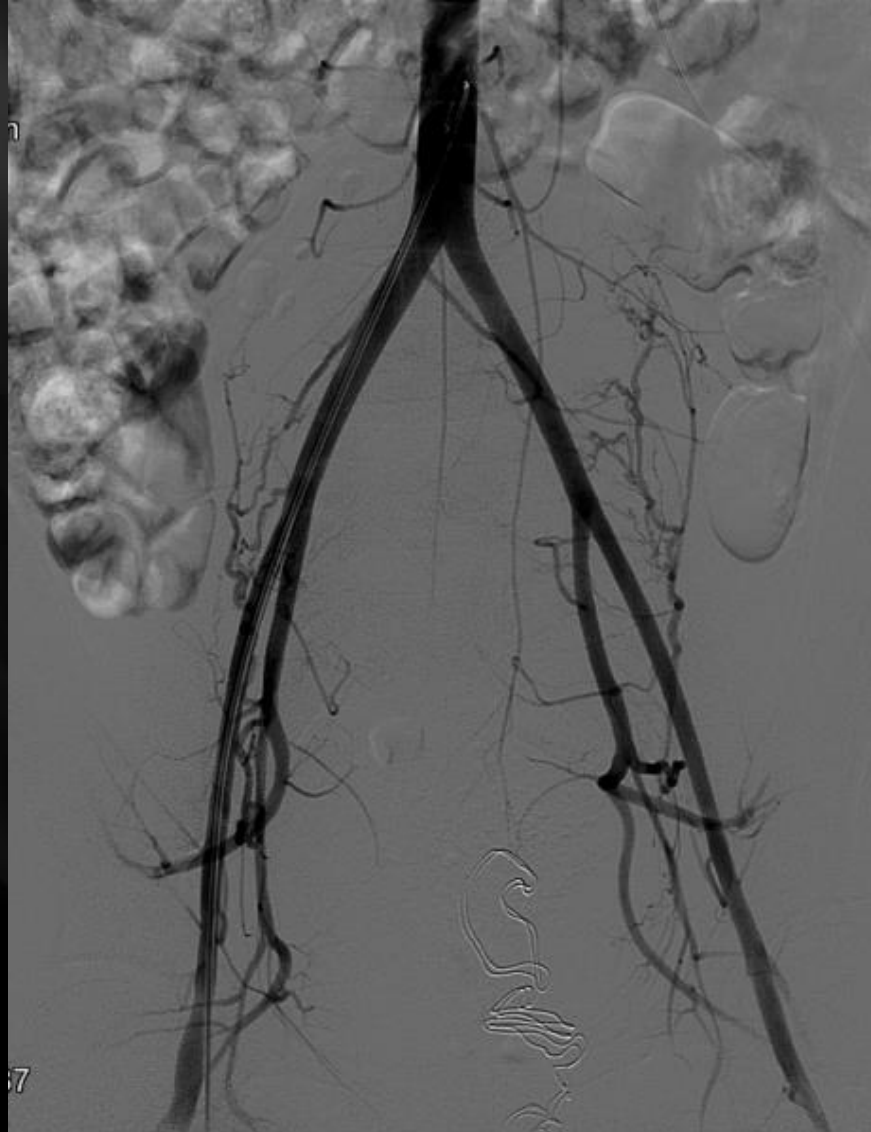ANGIOGRAPHY



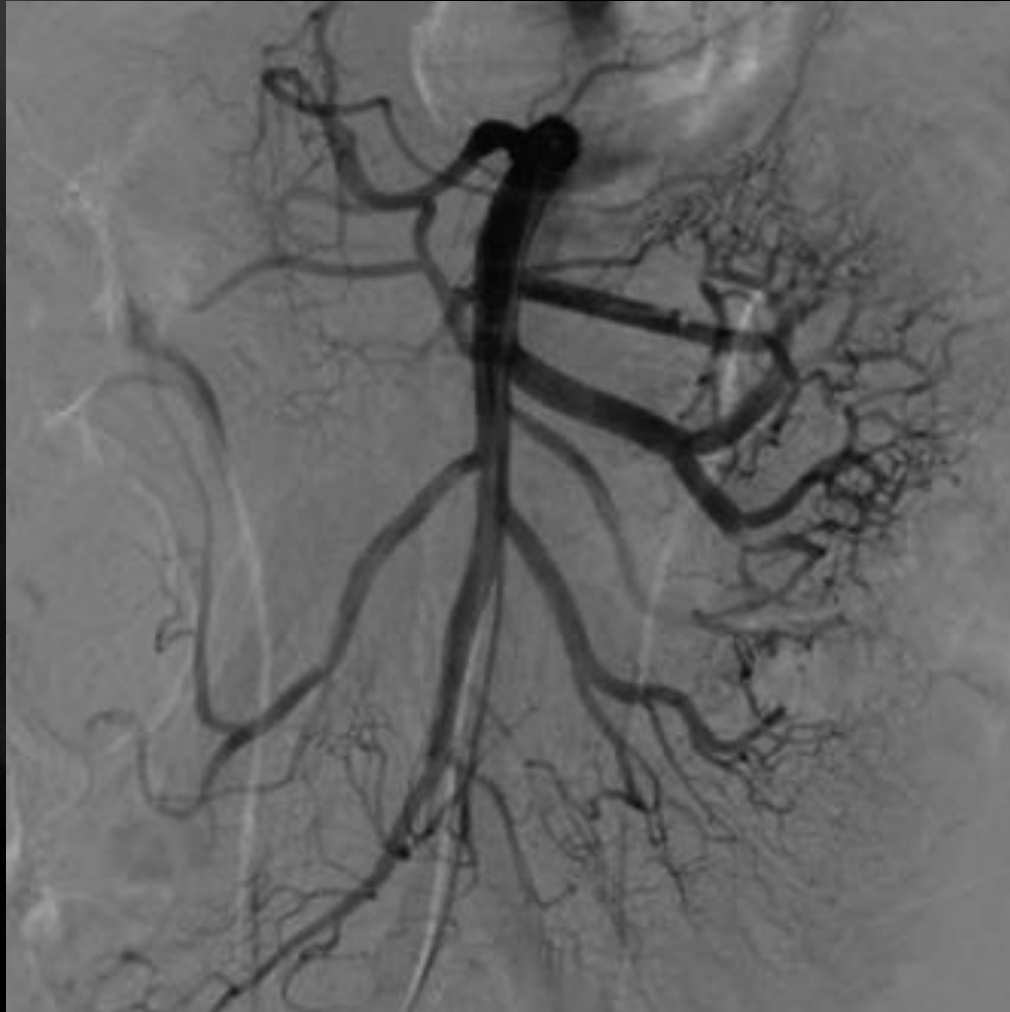ANGIOGRAPHY



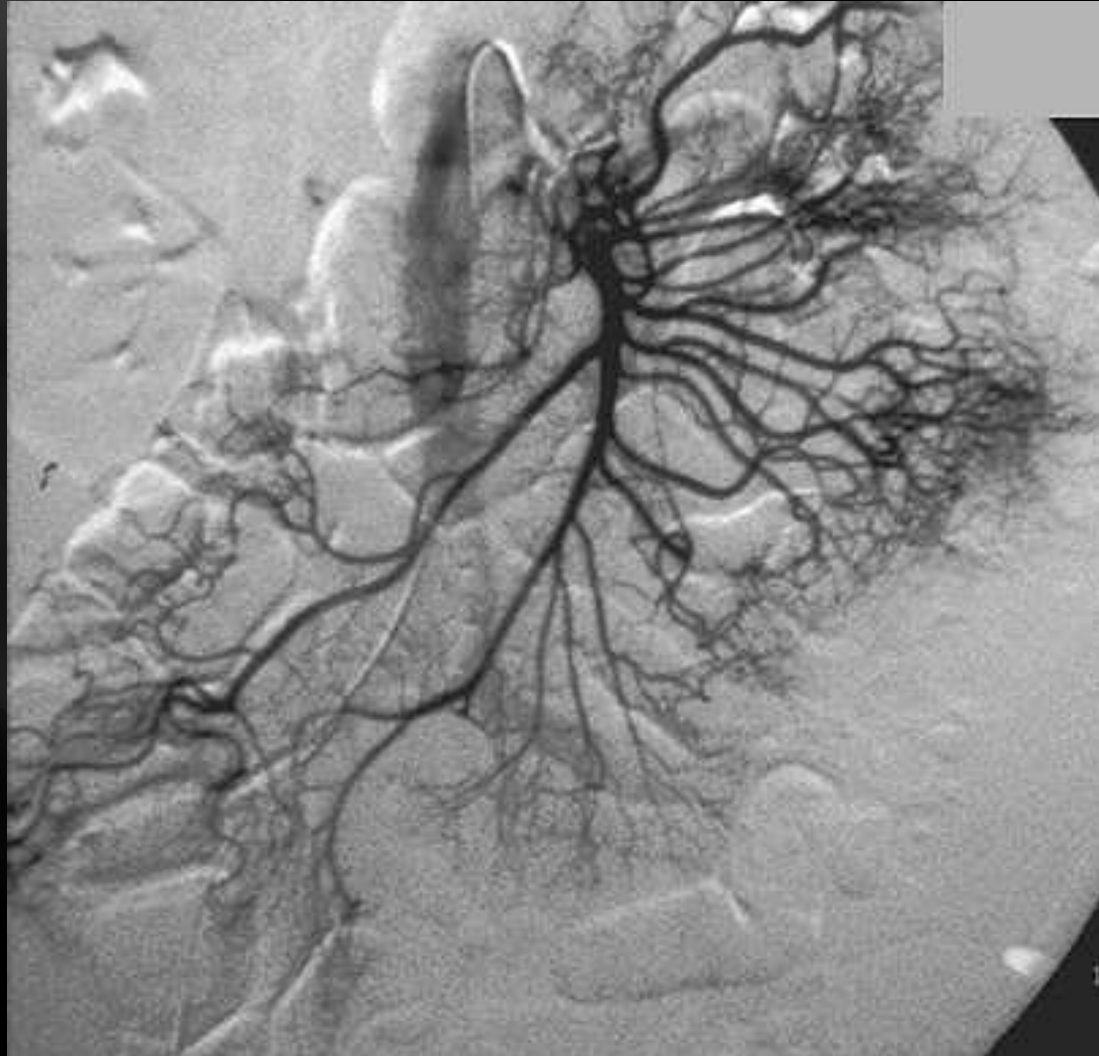
ANGIOGRAPHY



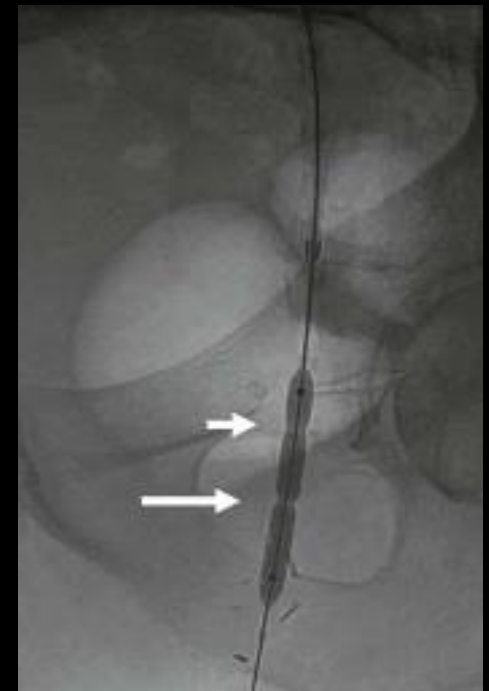
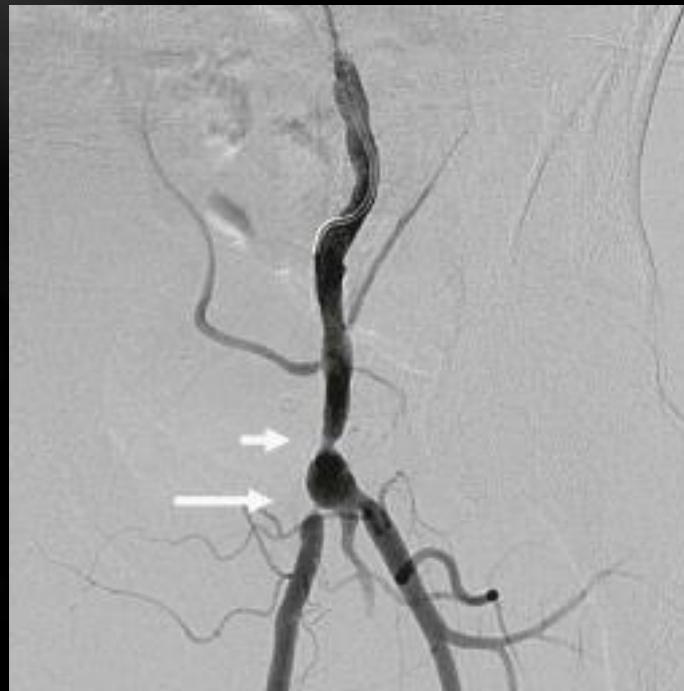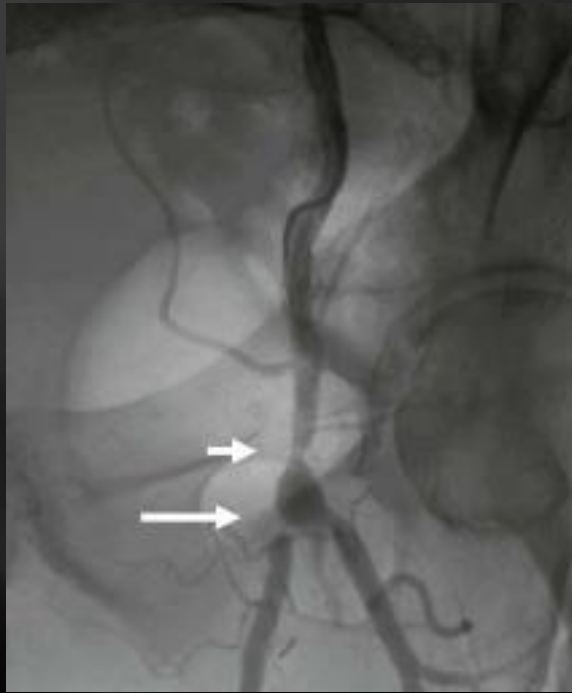ANGIOGRAPHY



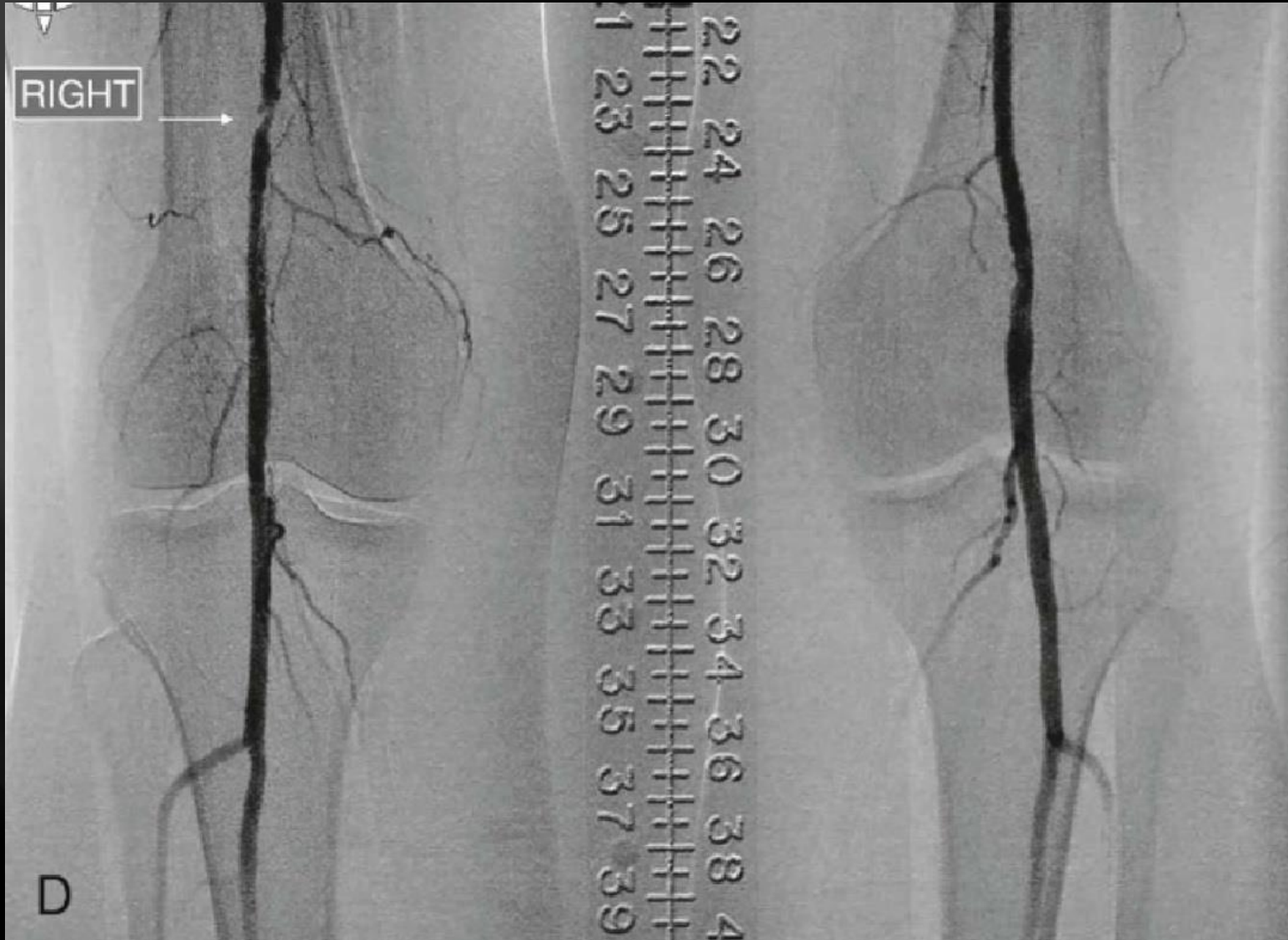ANGIOGRAPHY



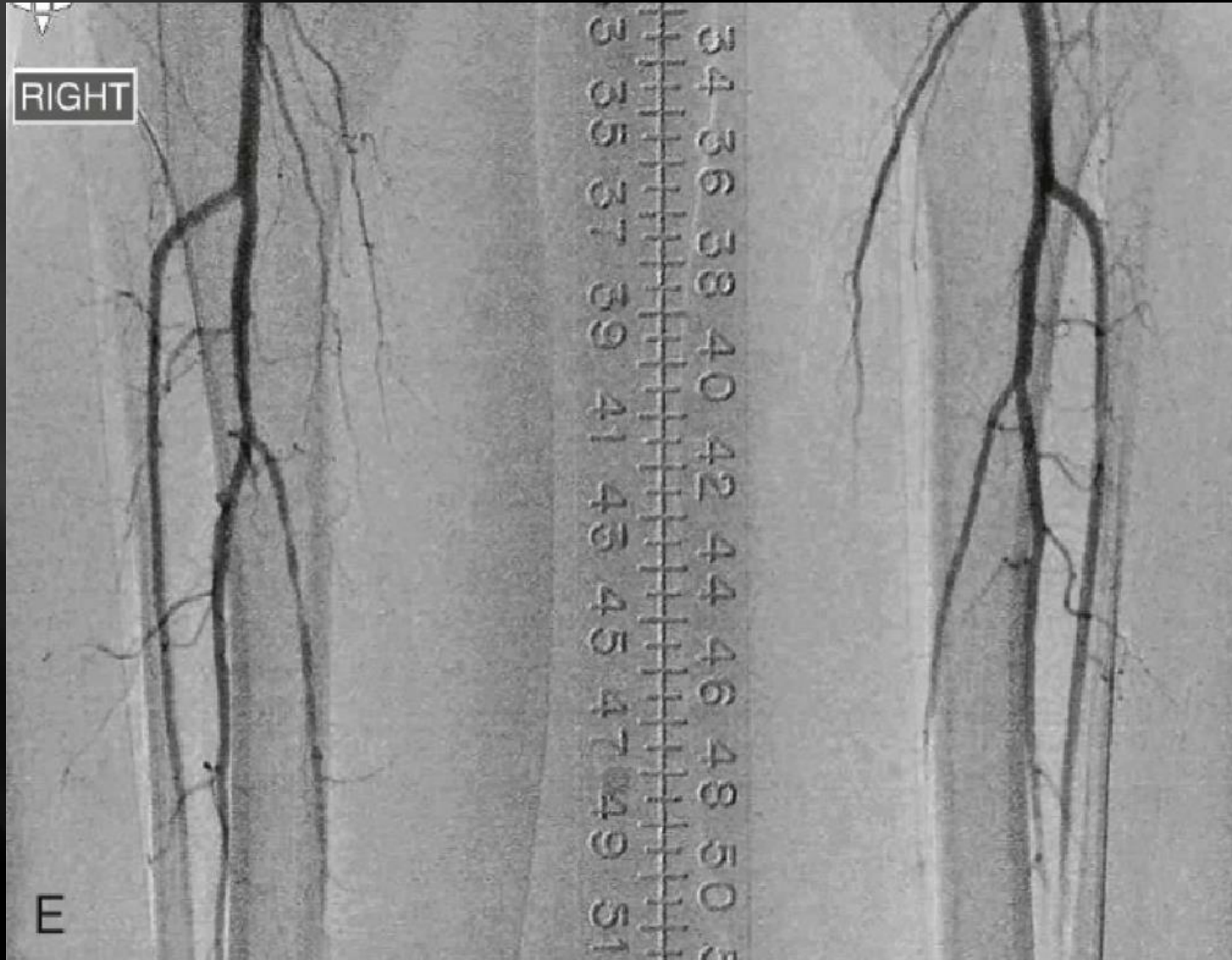
ANGIOGRAPHY



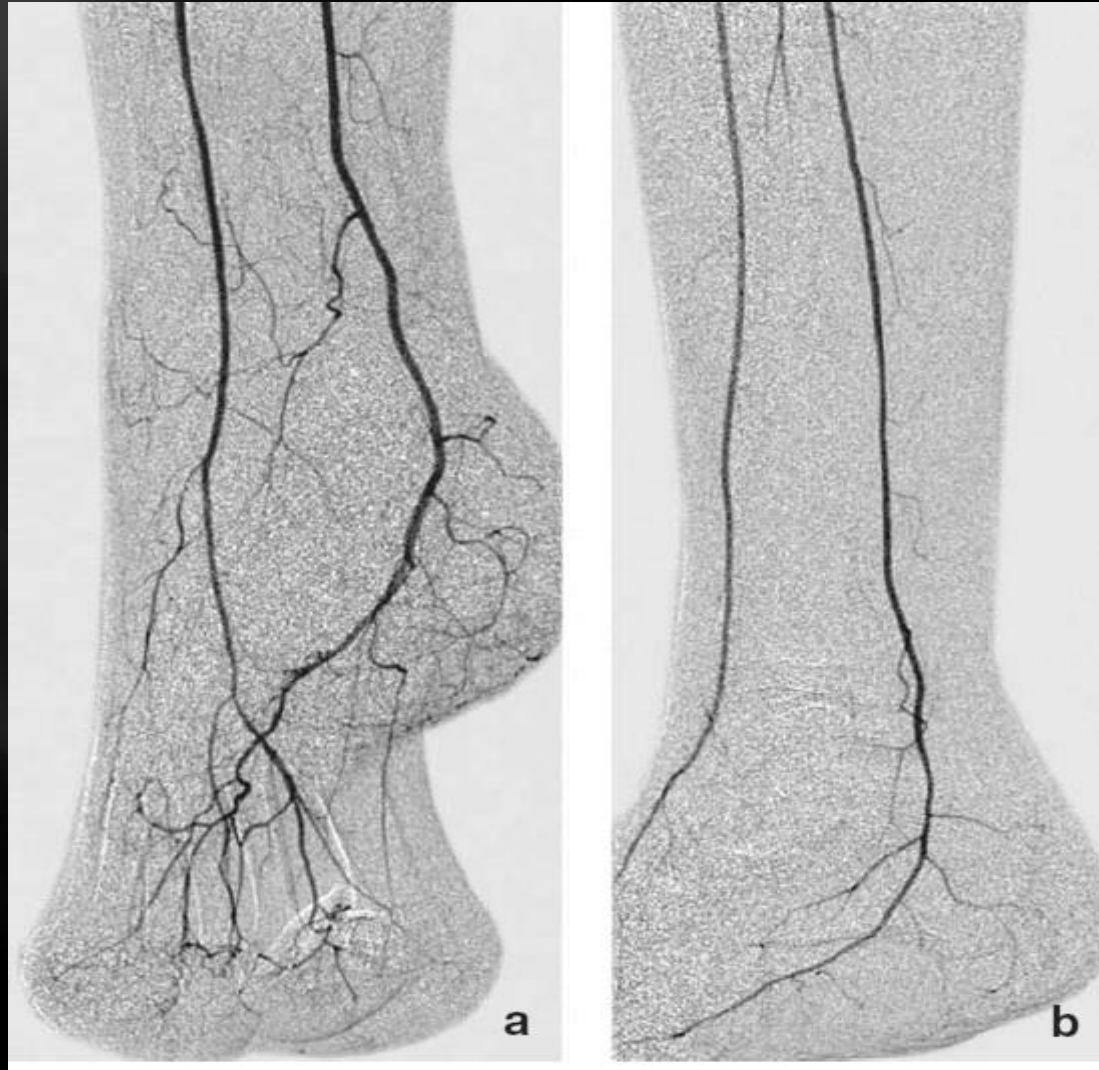ANGIOGRAPHY



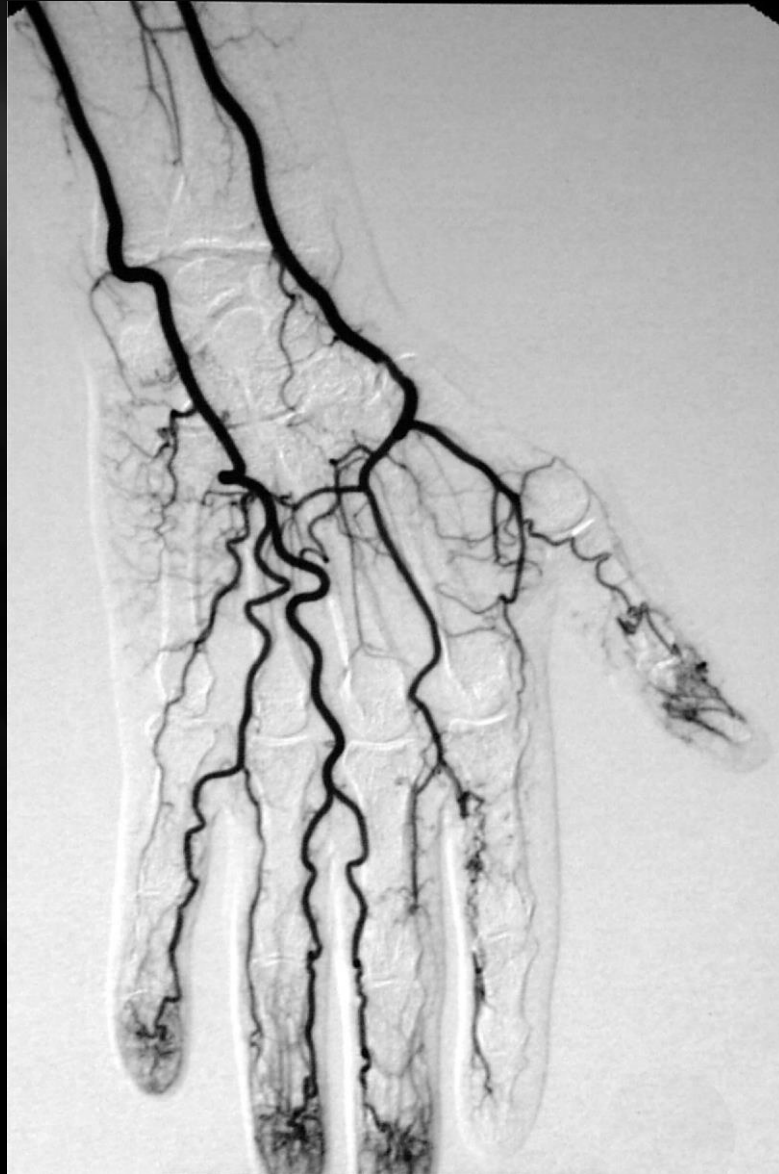ANGIOGRAPHY



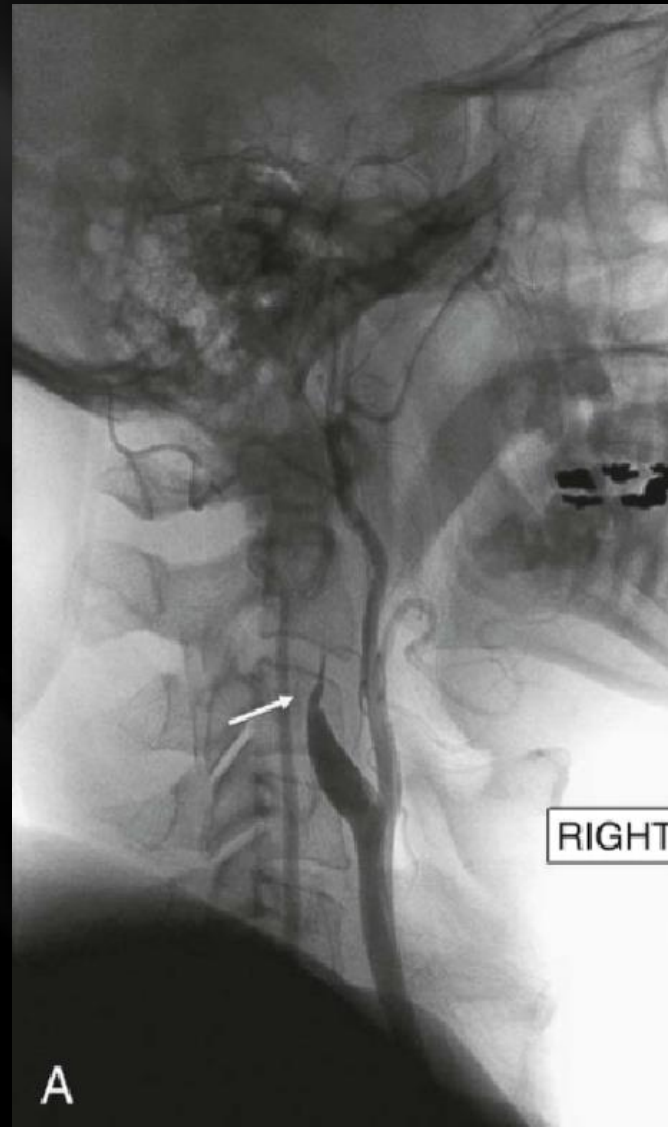ANGIOGRAPHY



ANGIOGRAPHY



ANGIOGRAPHY



➤ Sensitive: ✓✓✓✓✓

➤ Operator dependent: ✗

➤ Toxic: ✓✓✓

➤ Therapeutic: ✓✓✓

THANK YOU