

Anemia

Ahmed Jamal ,MD

**Consultant Adult hematology and stem cell transplantation
KSUH**

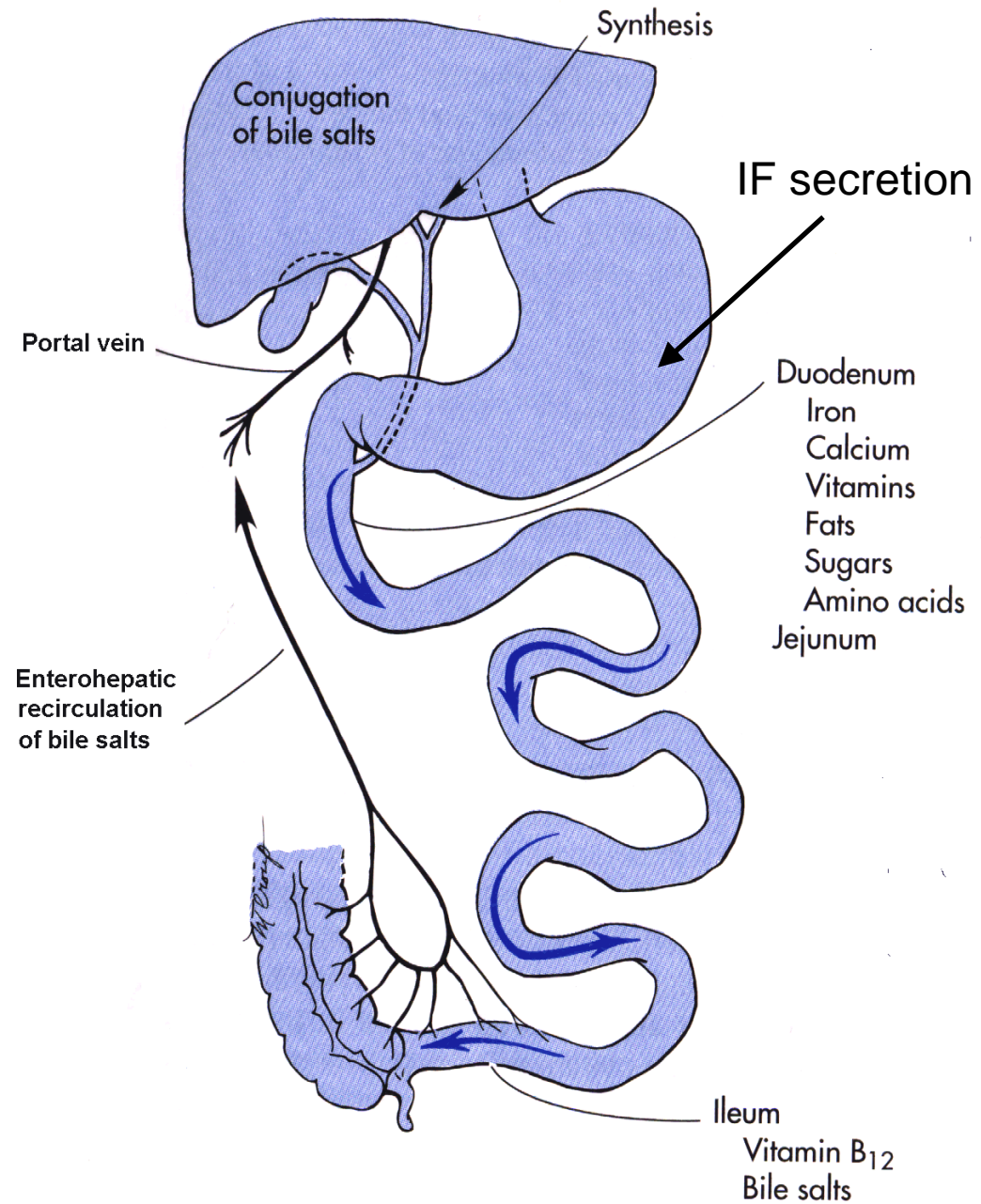
Anemia is a laboratory diagnosis

	<u>Men</u>	<u>Women</u>
Hemoglobin (g/dL)	13-17.4 g/dl	12-15.3
Hematocrit (%)	42-50%	36-44%
RBC Count ($10^6/\text{mm}^3$)	4.5-5.9	4.1-5.1
Reticulocytes	$1.6 \pm 0.5\%$	$1.4 \pm 0.5\%$
WBC (cells/mm^3)	~4,000-11,000	
MCV (fL)	80-96	
MCH (pg/RBC)	30.4 ± 2.8	
MCHC (g/dL of RBC)	34.4 ± 1.1	
RDW (%)	11.7-14.5%	

Presentation/history

- Acute or chronic/ Mild,moderate,severe.
- Mild anemia:
 - few or no symptoms; may be discovered accidentally on lab test
- May complain of:
 - Fatigue, decr. exercise tolerance, SOB, palpitations, lightheadedness on arising
 - Sore tongue (glossitis), cracking mouth corners (angular cheilitis), peripheral paresthesias (numb toes, etc.)
- Hx:
 - , FH anemia,diet, melena/hematochezia, malabsorption syndromes, Crohn's disease

Sites of absorption of iron and vitamin B12



Presentation/history

- Symptomology is poorly related to absolute lab values
 - Patients with gradual onset may be asymptomatic with quite low Hb/HCT
 - Acute onset can cause symptoms with relatively less anemia
- Mild anemia may be “normal” or “OK” for a menstruating woman, but you should always seek a cause in a man or a postmenopausal woman (or child)

Differential diagnosis

Consider:

- Anemia
- Hypothyroidism
- Depression
- Cardiac (congestive heart failure, aortic stenosis)
- Pulmonary causes of SOB
- Chronic fatigue syndrome, others

Physical examination

- Pallor (may be jaundiced– think hemolytic)
- Tachycardia, bounding pulses, signs of HF
- Systolic flow murmur
- Glossitis
- Decreased vibratory sense/ joint position sense (B12 deficiency, w/ or w/o hematologic changes)
- Ataxia (severe B12/folate deficiency)

Labs

- For all: CBC, reticulocyte count, ± peripheral smear
- For some (further workup):
 - LDH, Bilirubin
 - B12, folate, hemoglobin electrophoresis
 - Bone marrow aspirate to assess possible defective hematopoiesis
 - Other labs to assess underlying cause and other differential diagnoses (e.g. thyroid function tests, etc.)

Approach to anemia

- First, is the problem ineffective erythropoiesis, or is it destruction of RBCs?
- Ineffective erythropoiesis can come from a variety of causes
- What test will tell you which is the problem?

Answer: _____

A-Ineffective erythropoiesis

- All with normal/low reticulocyte count
 - Microcytic: think Fe⁺⁺ deficiency
 - Macrocytic: think B12/folate deficiency
 - Normocytic: think anemia of chronic disease, marrow problems, or other problems

Ineffective erythropoiesis

1-Fe⁺⁺ deficiency anemia

- Most commonly due to chronic bleeding .
- May be dietary .
- Iron balance is very close in menstruating women, so Fe⁺⁺ deficiency is common with no other source of bleeding.

Labs in IDA

- Iron and ferritin will be low
- TIBC (total iron binding capacity) will be high, since iron stores are not saturating their binding sites on transferrin
- Microcytosis & hypochromia are hallmarks, but early Fe⁺⁺ may be normocytic (± hypochromic)
- Usually, MCH and MCV will both be low.

Labs

- Most practitioners would agree that if a patient has microcytic hypochromic anemia with a low reticulocyte count, it would be reasonable to use a trial of FeSO_4 to diagnose
- 5-10 days after initiating therapy, a robust rise in reticulocytes confirms the diagnosis

Treatment

- Iron, oral in most cases, parenteral in cases of malabsorption.
- Blood transfusion.
- All forms of iron are constipating; the amount of constipation directly relates to the amount of elemental iron delivered
 - If intolerant of FeSO_4 (cheapest), reduce the dose, rather than switching form
 - Start 325 mg QD, increase slowly to TID
- **Follow up the cause of the iron deficiency!**

Ineffective erythropoiesis

2-Macrocytic anemia

- Low/normal reticulocyte count, macrocytosis
- Most common is folate/B12 deficiency
 - Dietary: folate far more common, B12 may occur in strict vegans
 - Pernicious anemia: lack of B12 protection in stomach and gut
 - Poor uptake in terminal ileum (e.g. in Crohn's disease)
 - B12 and folate are essential for cell maturation and DNA synthesis, erythrocytes end up large, usually normochromic, since iron is not lacking
- Other: drugs, toxins, myelodysplasia

Folate deficiency

- Folate intake is usually dietary, and may be deficient with low fresh fruit & vegetable intake
- Folate supplementation prevents neural tube defects in pregnancy.
- Do NOT correct folate levels unless B12 is OK
 - Correction of folate deficiency will correct hematologic abnormalities without correcting neurological abnormalities
 - Check B12 and correct first

B12 deficiency

- Less common, usually caused by absorption problems, rather than dietary deficiency
- B12 needs Intrinsic Factor for protection from degradation in gut
 - Produced by parietal cells of stomach, protects through gut for uptake at terminal ileum
 - Pernicious anemia from immune attack of IF production.

Neurological effects

- Deficiency results in damage to dorsal columns (sensory) and lateral columns (motor) of spinal cord SACDSC
- Decreased vibration sense and position sense of joints detectable, and may affect gait, etc.
- May have positive Romberg's test
- Severe effects may include ataxia and dementia

Labs

- Folate and B12 levels
- Schilling test may be useful to establish etiology of B12 deficiency
 - Assesses radioactive B12 absorption.
- Other tests if pernicious anemia is suspected
 - Anti- parietal cell antibodies, anti-IF antibodies
 - Secondary causes of poor absorption should be sought (gastritis, ileal problems)

Treatment– supplementation

- B12 usually 1000 mg I.M. q month
 - B12 stores take a long time to deplete; missed doses are not usually a problem
 - Oral supplementation is gaining support; usually effective in pernicious anemia (1-2 mg PO QD)
- Reticulocyte count should respond in 1 wk

DD of macrocytic anemia

- B12/Folate def. (Homocystien, MMA, LDH, IB) high in B12 def.
- Hypothyroidism .
- Alcoholism.
- Liver diseases.
- MDS.
- Medications e.g : HU

Ineffective erythropoiesis

3-Anemia of chronic disease

- Normocytic anemia with ineffective erythropoiesis (reduced reticulocyte count)
- May be normochromic or hypochromic
- Low iron, and TIBC with normal or high ferritin.
- Results from
 - Chronic inflammation (e.g. rheumatologic disease): Cytokines released by inflammatory cells cause macrophages to accumulate iron and not transfer it to plasma or developing red cells (iron block anemia)
 - Renal failure (erythropoietin from kidneys)
 - Endocrine (e.g. hypothyroid)
 - Hepatic disease
- Bone marrow suppression (EPO is elevated)

Treatment

- Correct or manage underlying disease when possible
 - May need EPO injection (\$\$\$\$)
- EPO is the treatment of choice for anemia of renal failure
- In bone marrow deficiency/malignancy, treat if possible, remove precipitating drugs, may require BMT

B- Peripheral causes

- *INCREASED* reticulocyte count
- Acute blood loss
 - Very acutely, with hypovolemia, may have normal blood counts, will become anemic with volume replenishment
- Hemolytic anemias.
 1. Immune mediated (AIHA)
 2. Enzyme def. (G6PD,PK)
 3. Hemoglobinopathies (SCA,Thalassemia)
 4. Membrane defects (elliptocytosis , spherocytosis)

Immune hemolytic anemia

- IgG or IgM labeled as “warm” or “cold”
 - Antibodies on RBC result in hemolysis
- Usually acute, often with jaundice
- May be drug-induced
- Cold hemolytic anemia often post-infectious, generally not severe, worsens with exposure of periphery to cold temperatures

Coomb's test

- Detects presence of either antibody on RBC .
- Helpful in determining if a hemolytic anemia is immune-mediated .

Treatment

- Withdraw offending drug (PCN, quinidine, quinine, rifampin, others)
- Steroids/splenectomy– reduces immune function and RBC sequestration, respectively .

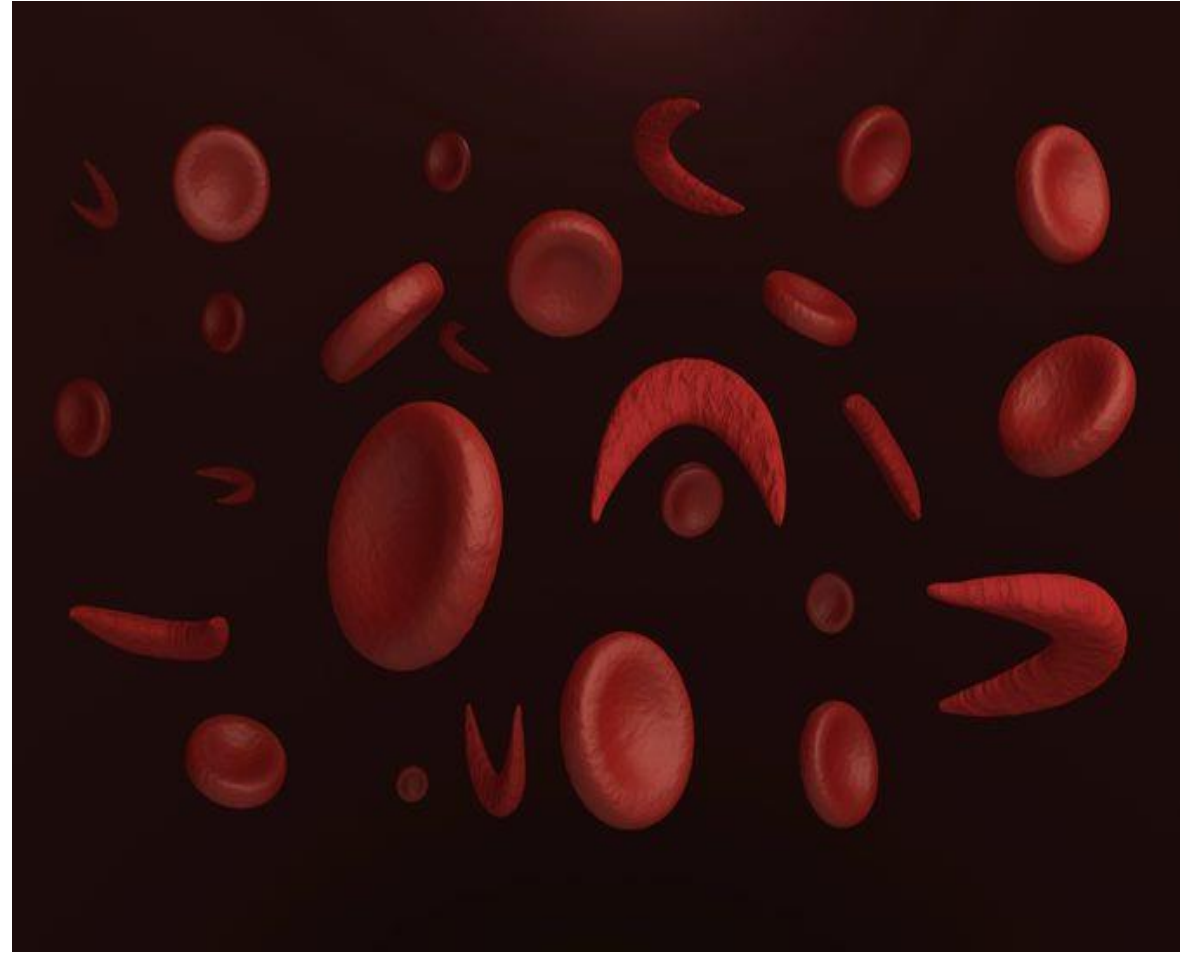
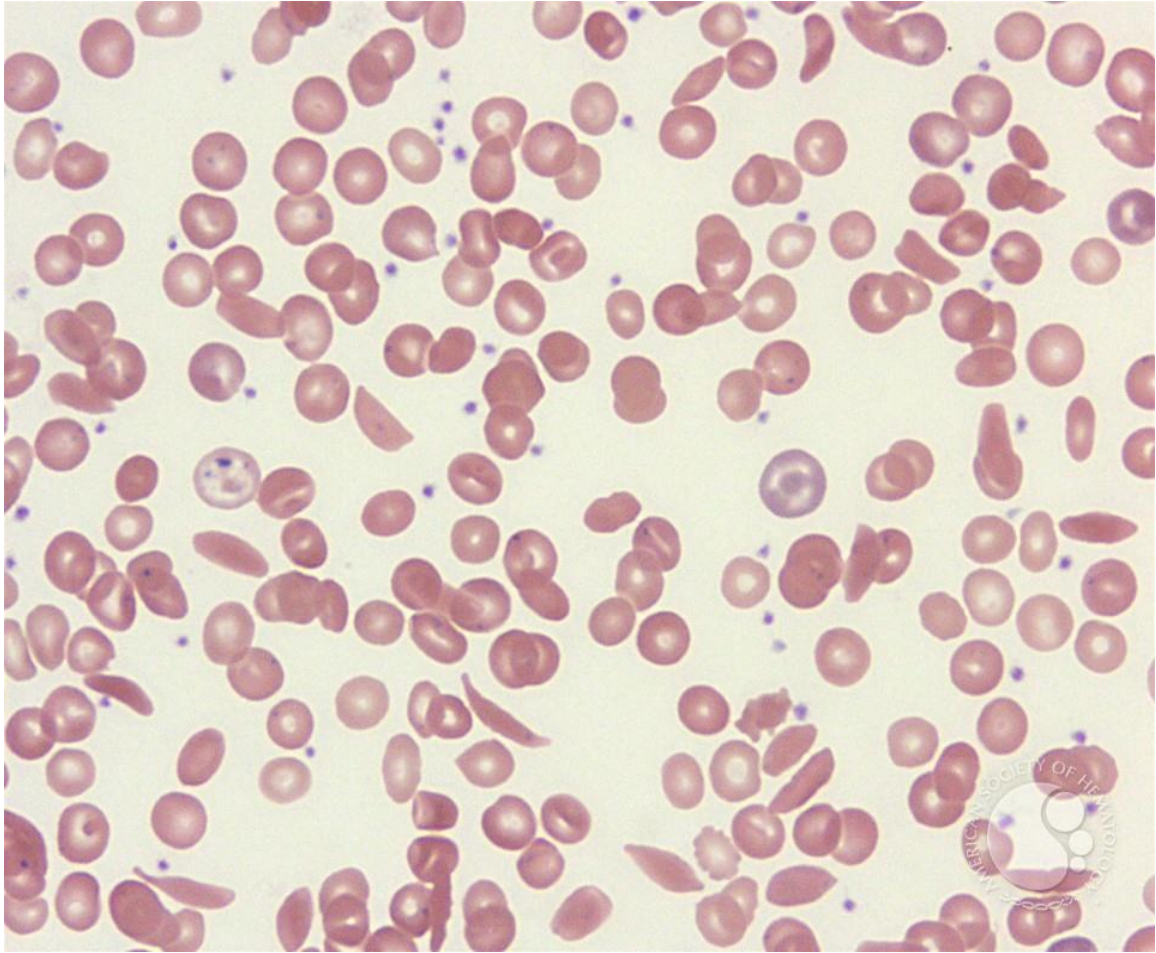
Special cases of hemolytic anemia

- Glucose-6 Phosphate Dehydrogenate deficiency
 - More common in African and Mediterranean populations
 - Lack of GPD enzyme makes cells very sensitive to oxidative stress (infection, certain drugs)
 - Treatment: avoid triggers if possible, especially inciting drugs .

Sickle cell disease

- Abnormal hemoglobin causes change in RBC shape, resulting in constant RBC destruction by the spleen, functional asplenia, susceptible to infection
- Arterial occlusion leads to infarcts, pain crises, acute chest syndrome, stroke, MI
- Keep hydrated, treat pain, take infection seriously

PB morphology in SCD



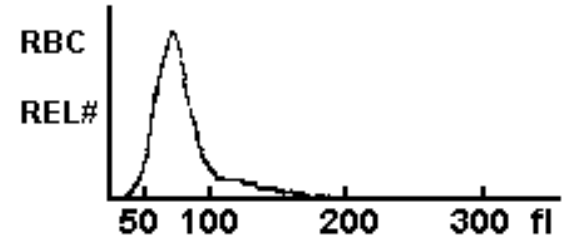
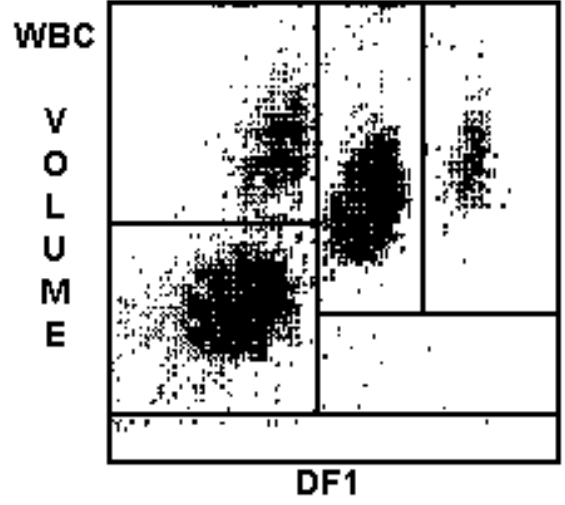
Thalassemias

- Decreased production of normal hemoglobin polypeptide chains.
- Classified according to hemoglobin chain that is affected ($\alpha, \beta, \gamma, \delta$)
- Common, variable severity of hemolysis
- Characterized by hypochromic microcytic red cells (MCV markedly decreased while MCHC only slightly decreased)
- can be suspected if electrophoresis shows a compensatory increase in Hb A2 and/or F (fetal). (Note: Hb A2 generally does not increase above 10%)

Case Studies

Anemia Case Study #1

A 72 year old male has the CBC findings shown. Peripheral RBCs are hypochromic & microcytic.

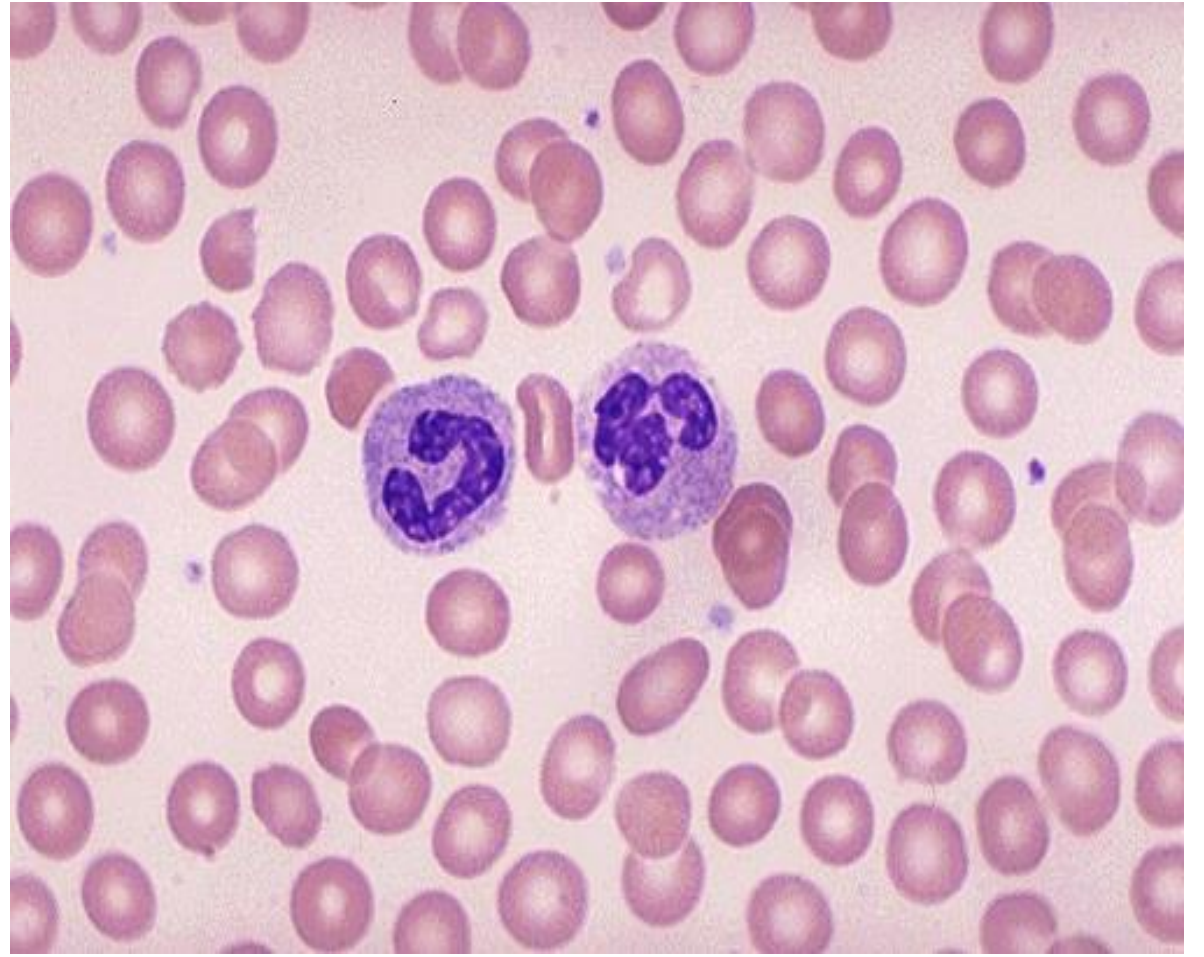
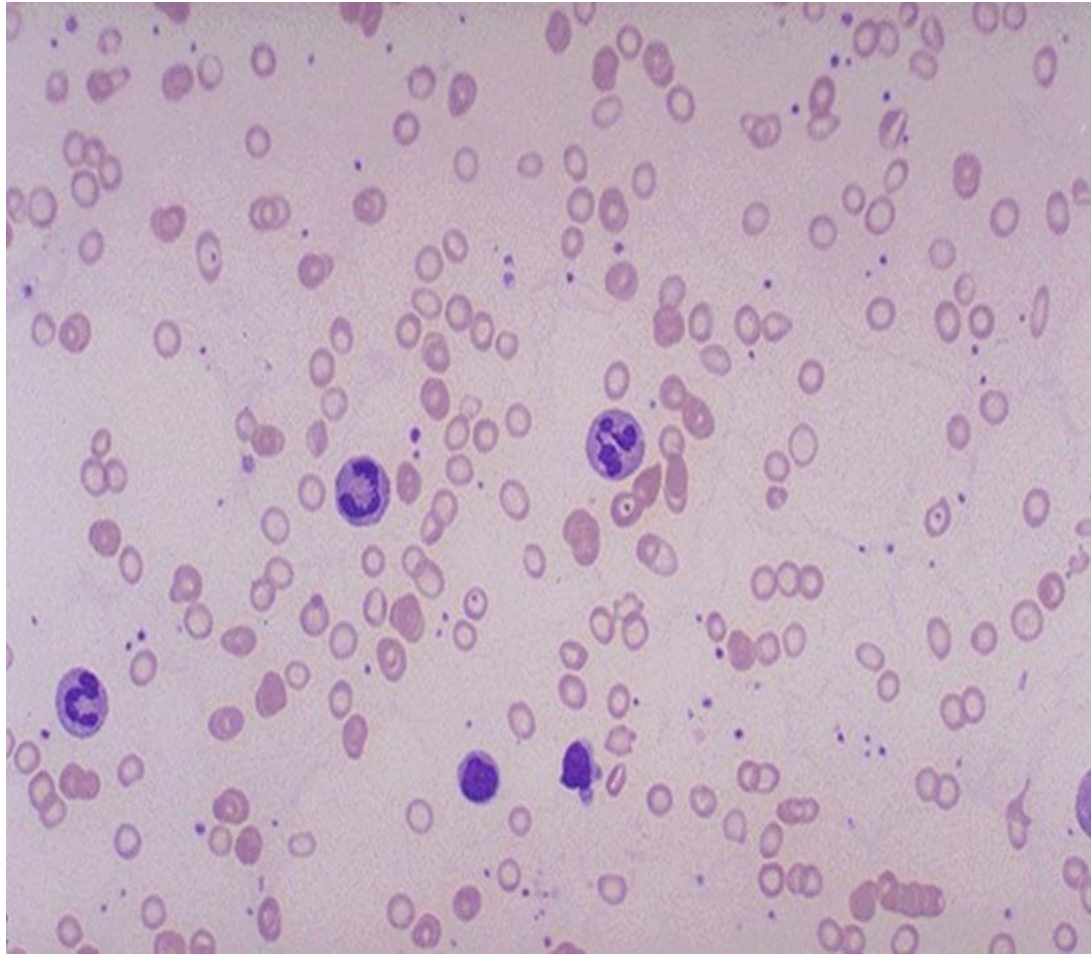


WBC	5.5	
	%	#
NE	54.7	3.0
LY	34.1	1.9
MO	7.5	0.4
EO	3.0	0.2
BA	0.7	0.0
RBC	4.28	L
HGB	9.7	L
HCT	29.9	L
MCV	69.7	L
MCH	22.6	L
MCHC	32.4	L
RDW	18.4	H
PLT	331	
MPV	8.8	

Anemia

Case Study #1

- What test would you order for this patient?
- A-Hemoglobin Electrophoresis
- B-Retic count
- C-Stool for occult blood
- D-B12 Assay
- E-Bone marrow biopsy
- F-Ferritin, Iron, TIBC



Anemia

Case Study #1

- Two questions:
 - What is your diagnosis?
 - What is the important special step for this patient?

Anemia

Case Study #1

- Answers
 - Question 1
 - Likely Iron Deficiency Anemia
 - Question 2
 - Colonoscopy

Case study #2

- 17 ys lady presented to the ER with fatigue and exercise intolerance found to have HGB 7.5g/dl normal MCV and MCH ,plat,WBCs , Reticulocytes High 5%
- Q1-What you will order lab next ?
- Q2-What you will give her immediate ttt ?
- Q3-What is your further workup ?

- A-1
- As NC NC anemia with high Ret. will order hemolytic panel .
- LDH, bilirubin ,haptoglobin, Coombs test if hemolysis .
- LDH 1550 ,D, Coombs +ve , hap. <0.01
- A2-If confirmed AIHA immediate management will be
- A-Steroids only if no serious findings .
- B-Steroids and blood if serious findings .

- A-3
- Search for underlying autoimmune disorders

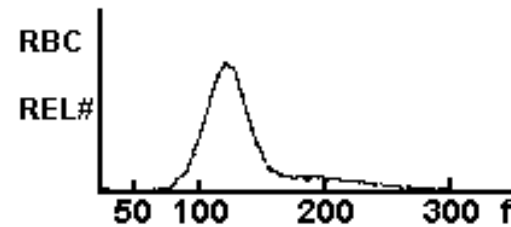
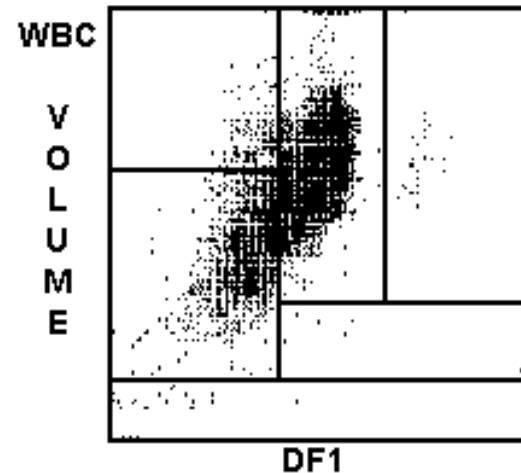
Result ANA, AntiDsDNA v.high 1:10980

Final Dx : SLE with 2ry AIHA

Anemia

Case Study #3

A 48 year old male has become progressively more fatigued at the end of the day. This has been going on for months. In the past month he has noted paresthesias with numbness in his feet. A CBC demonstrates the findings shown.

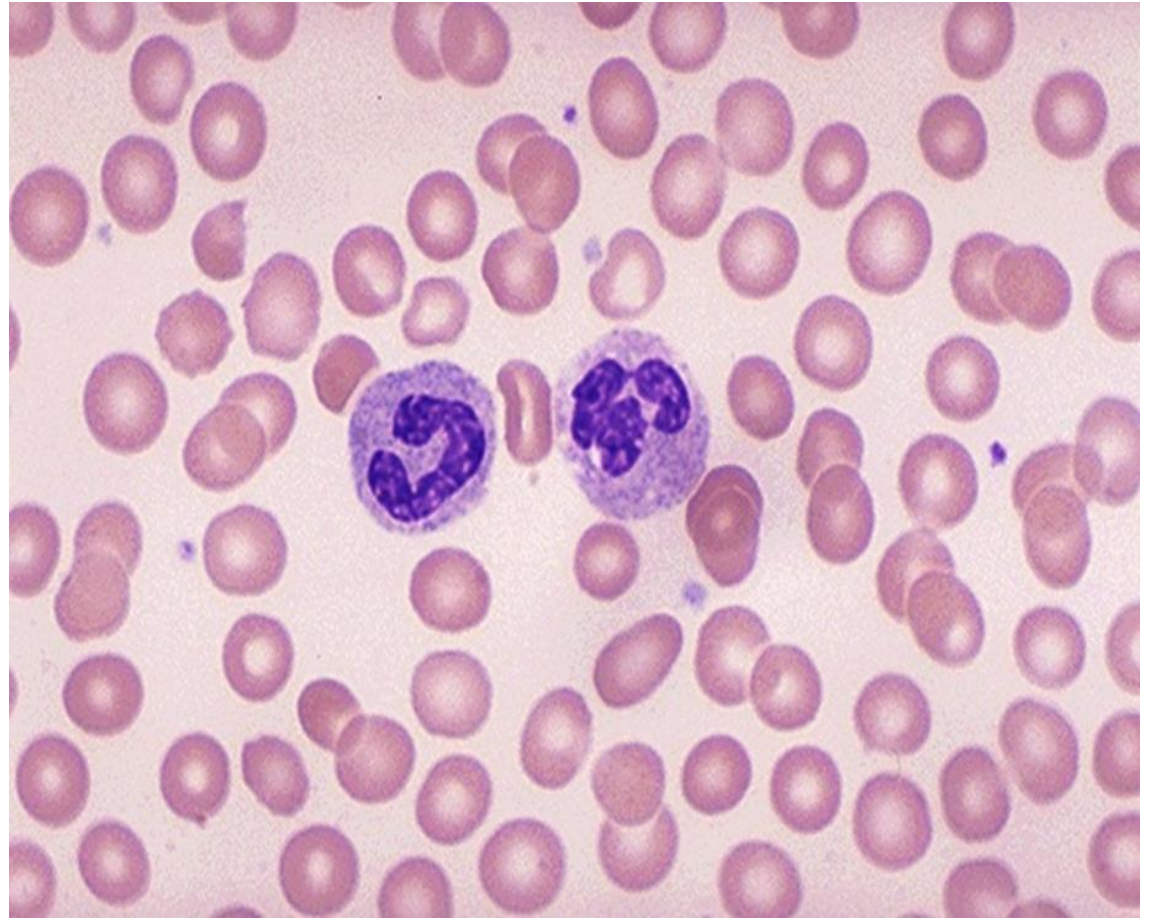
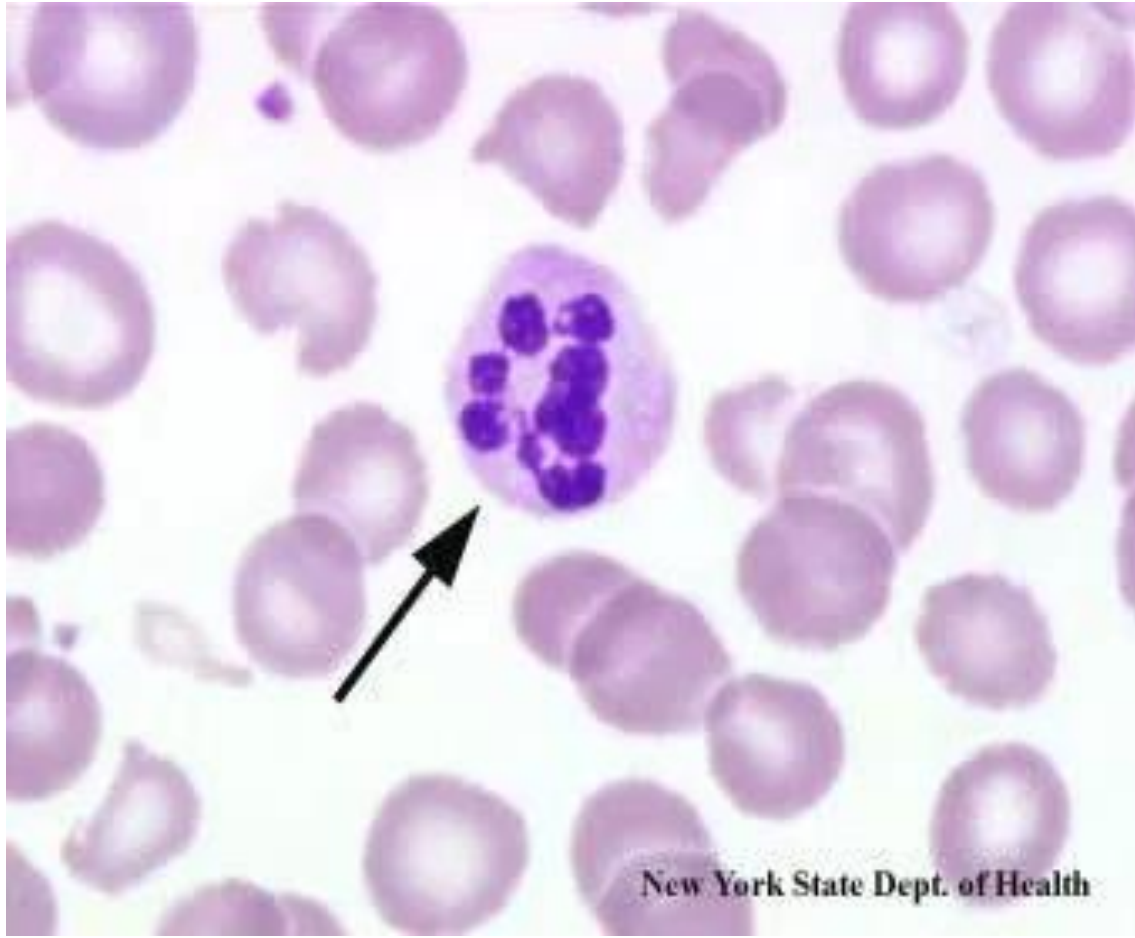

WBC	12.1	H	
	%		#
NE	71.1	H	8.5 H
LY	15.9	L	1.9
MO	3.3		0.5
EO	0.5	L	0.1
BA	8.7	H	1.1 H
RBC	2.69	L	
HGB	10.6	L	
HCT	31.6	L	
MCV	117.6	H	
MCH	39.6	H	
MCHC	33.7		
RDW	14.1		
PLT	578	H	
MPV	7.2	L	

Anemia

Case Study #3

A peripheral blood smear (the slide is representative of this condition) shows red blood cells displaying macro-ovalocytosis and neutrophils with hypersegmentation.



Anemia

Case Study #3

Which of the following tests would be most useful to determine the etiology?

- A. Hemoglobin electrophoresis
- B. Reticulocyte count
- C. Stool for occult blood
- D. Vitamin B12 assay
- E. Bone marrow biopsy

Anemia

Case Study #3

- Questions:
 - What is the diagnosis from these findings?
 - How do you explain the neurologic findings?

Anemia

Case Study #3

- Answers:
 - Question 1
 - This is a macrocytic (megaloblastic) anemia. The neurologic findings suggest vitamin B12 deficiency (pernicious anemia).
 - Question 2
 - The B12 deficiency leads to degeneration in the spinal cord (posterior and lateral columns).

Decreased Hb/HCT



Reticulocytes?


Low/normal
(Decreased/Ineffective
Production)

Increased
(Destruction/Loss)

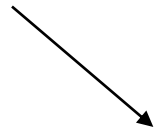


Red Cell
INDICES

Normal size &
Hb content



Large size &
normal Hb
content




Small size &
decreased Hb
content




MORPHOLOGY

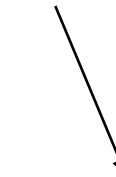Membrane
defects



Hemoglobinopathies



Enzymopathies



Environmental

وفقكم الله