

LOCALIZATION FOR MEDICAL STUDENTS

Dr. Mohammed Alanazy, MD, MSc.
Consultant and Assistant professor of Neurology

objectives

1. Recognize the importance of history taking
2. Describe all history domains when approaching a patient with a neurological problem.
3. Describe symptoms and signs of all possible localizations within the nervous system
4. In multiple case vignettes, demonstrate their ability to explore different neurological symptoms and signs and integrate the acquired information to provide a list of possible localizations.

The Approach to a Patient with Neurologic Disease

- Localization is important
 - investigation modalities differ widely depending upon the level affected

Divisions of the Neuraxis

- Cortical area
- Subcortical area
- Brainstem
- Cerebellum
- Spinal Cord
- Roots
- Plexi
- Peripheral Nerve
- Neuromuscular Junction
- Muscle

Neurologic Examination

- Higher Cortical Function
- Cranial Nerves
- Motor (inspection, tone, power, reflexes)
- Sensory
- Coordination
- Special tests
- Gait

CASE 1

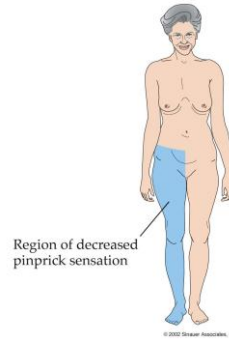
PATIENT PRESENTATION

A 71-year-old woman was referred to a neurologist with 10 months of progressive gait difficulty, right leg numbness, left leg weakness, urine retention and constipation.

KEY SYMPTOMS AND SIGNS

- Left leg weakness in HF, KF and ADF.
- Hypertonia, hyperreflexia, and left Babinski's sign
- Decreased vibration and joint position sense in the left foot and leg
- Decreased pinprick sensation on the right lower limb up to the level of the umbilicus.

Pinprick Testing

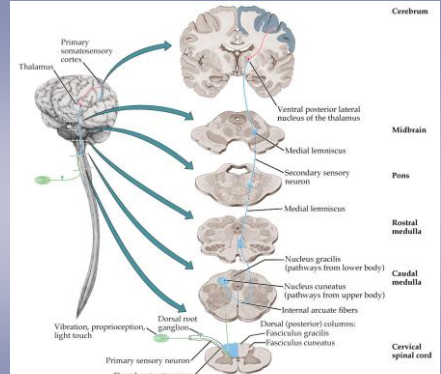
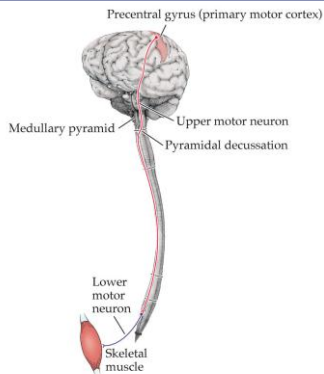
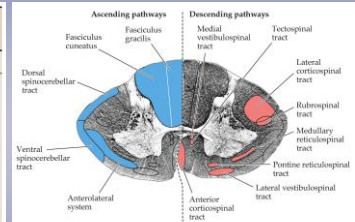


RELEVANT ANATOMICAL & CLINICAL CONCEPTS

- Lateral Corticospinal Tract
- Posterior Column–Medial Lemniscal Pathway
- Anterolateral Pathways
- Pathways for the Control of Bladder, Bowel, and Sexual Function
- Dermatomes
- Spinal Cord Lesions: Localization, Differential Diagnosis, and Treatment

TABLE 6.1 Main Long Tracts of the Nervous System

PATHWAY	FUNCTION
Lateral cortico-spinal tract	Motor
Posterior columns	Sensory (vibration, joint position, fine touch)
Anterolateral pathways	Sensory (pain, temperature, crude touch)



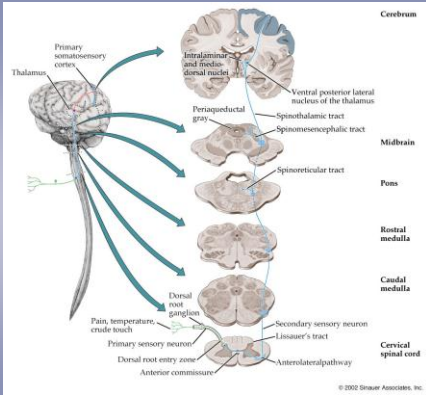


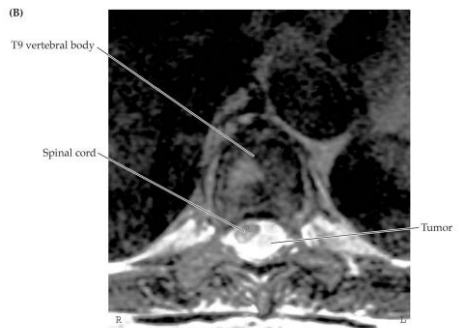
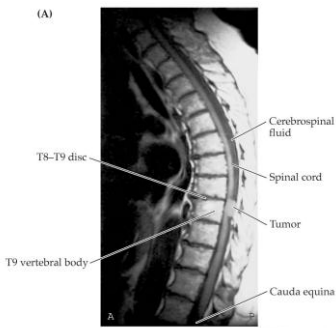
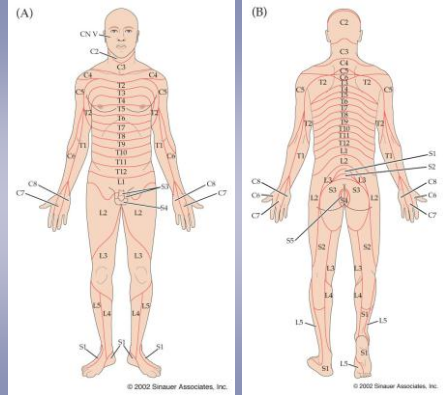
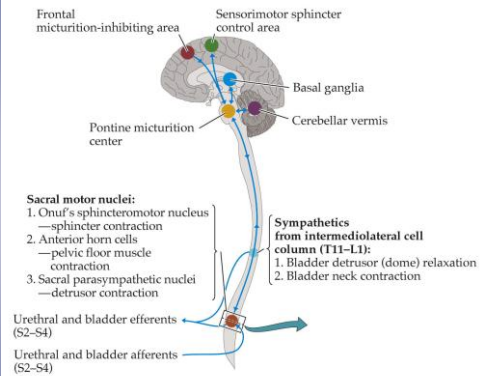
TABLE 6.4 Signs of Upper Motor Neuron and Lower Motor Neuron Lesions

SIGN	UPPER MOTOR NEURON LESIONS	LOWER MOTOR NEURON LESIONS
Weakness	Yes	Yes
Atrophy	No ^a	Yes
Fasciculations	No	Yes
Reflexes	Increased ^b	Decreased
Tone	Increased ^b	Decreased

^aMild atrophy may develop due to disuse.

^bWith acute upper motor lesions, and tone may be decreased.

© 2002 Elsevier Associates, Inc.

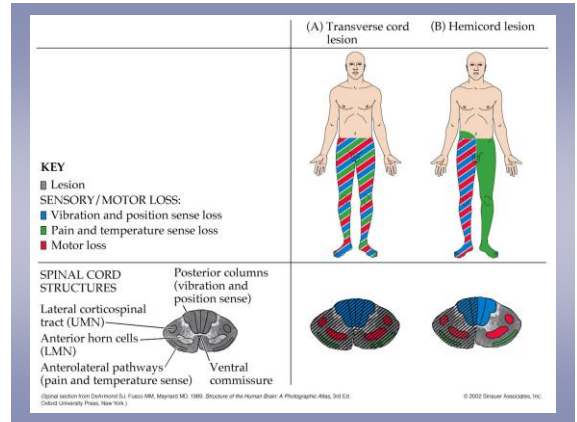


FINAL DIAGNOSIS

Meningioma compressing the left spinal cord at T9 causing Brown-Séquard syndrome

OUTCOME

Meningioma removed via laminectomy. Recovered sensation, sphincter control, and improved ambulation.



CASE 2

HAND WEAKNESS, PINPRICK SENSORY LEVEL, AND URINARY RETENTION

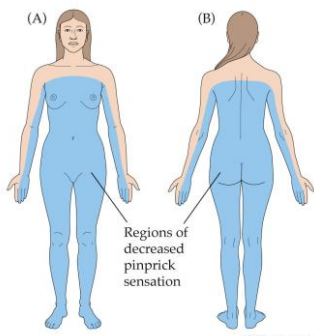
PATIENT PRESENTATION

A 26-year-old woman suddenly developed neck pain, arm pain, and bilateral upper and lower limb weakness. Shortly afterward she discovered that she had urinary retention as well as fecal incontinence.

KEY SYMPTOMS AND SIGNS

- Bilateral hand and elbow extension weakness; shoulder abduction and elbow flexion were normal.
- Hypotonia in upper limbs
- Absent triceps reflexes, but biceps and brachioradialis were normal.
- Bilateral leg weakness in HF, KF and ADF and brisk reflexes
- Sensory level to pinprick and temperature
- Vibration and proprioception were normal.
- Urinary retention, fecal incontinence, and absent rectal tone

Pinprick Testing



RELEVANT ANATOMICAL & CLINICAL CONCEPTS

- Anterolateral Pathways
- Lateral Corticospinal Tract
- Dermatomes
- Pathways for the Control of Bladder, Bowel, and Sexual Function

TABLE 3.6 Deep Tendon Reflexes

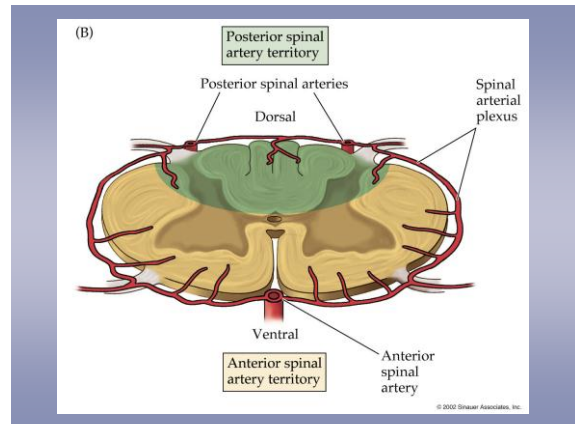
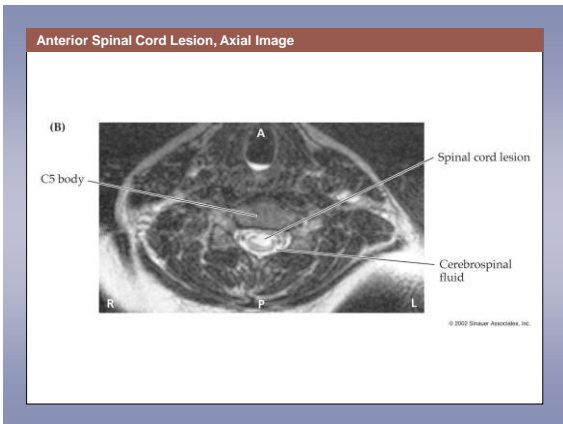
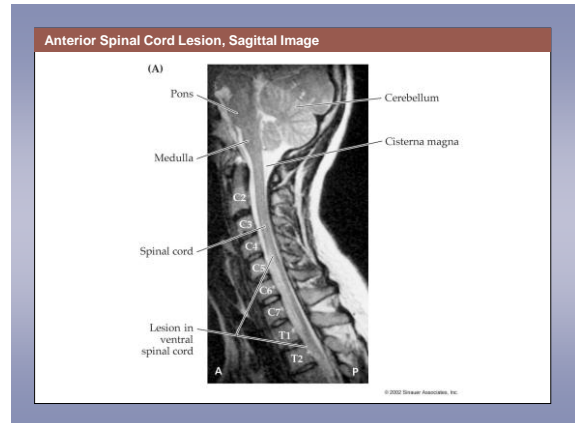
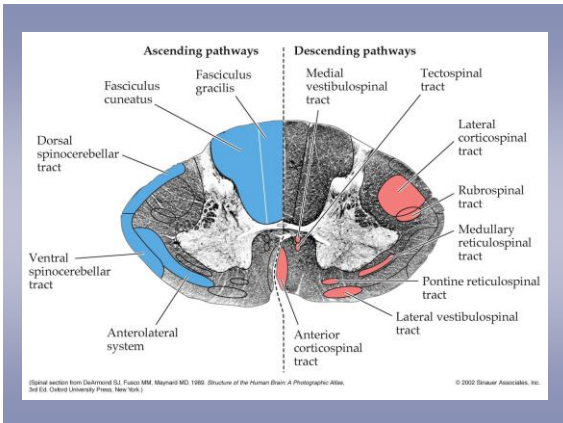
REFLEX	MAIN SPINAL NERVE ROOTS INVOLVED
Biceps	C5, C6
Brachioradialis	C6
Triceps	C7
Patellar	L4
Achilles tendon	S1

© 2002 Elsevier Associates, Inc.

	(E) Posterior cord syndrome	(F) Anterior cord syndrome
<p>KEY</p> <p>■ Lesion</p> <p>SENSORY/MOTOR LOSS:</p> <p>■ Vibration and position sense loss</p> <p>■ Pain and temperature sense loss</p> <p>■ Motor loss</p>		
<p>SPINAL CORD STRUCTURES</p> <p>Lateral corticospinal tract (LMN) — Anterior horn cells (LMN)</p> <p>Anterolateral pathways (pain and temperature sense)</p> <p>Posterior columns (vibration and position sense)</p> <p>Ventral commissure</p>		

(Spinal section from DuRoirol SJ, Fusco MM, Maynard MD. 1995. Structure of the Human Brain: A Photographic Atlas, 3rd Ed. Oxford University Press, New York.)

© 2002 Elsevier Associates, Inc.



CASE 3

FACE AND CONTRALATERAL BODY NUMBNESS, HOARSENESS, HORNER'S SYNDROME, AND ATAXIA

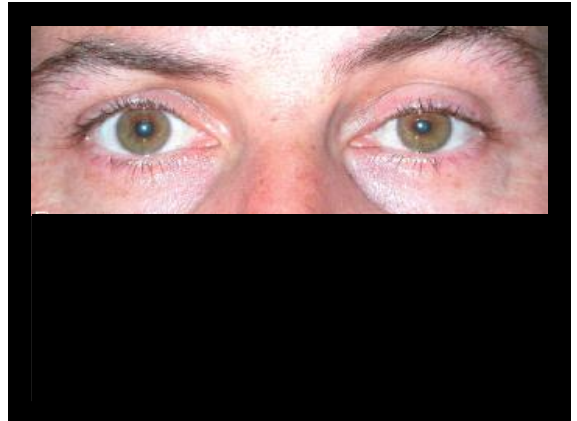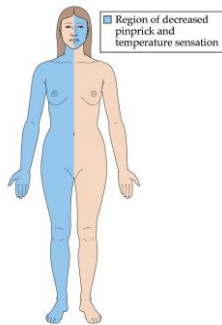
PATIENT PRESENTATION

A 22-year-old woman suddenly developed left posterior neck pain, vertigo, nausea, unsteadiness, left facial numbness, and hoarseness after chiropractic neck manipulation.

KEY SYMPTOMS AND SIGNS

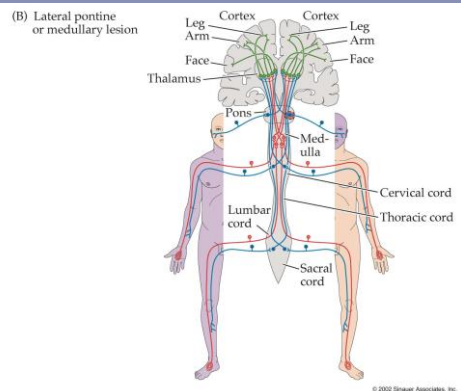
- Left ptosis, with small, reactive left pupil
- Right-beating nystagmus
- Hoarseness, with decreased palate elevation on the left and decreased left gag reflex
- Decreased pinprick and temperature sensation in the left face
- Decreased pinprick and temperature sensation in the right limbs and trunk below the neck
- Left arm and leg ataxia
- Unsteady gait, falling toward the left

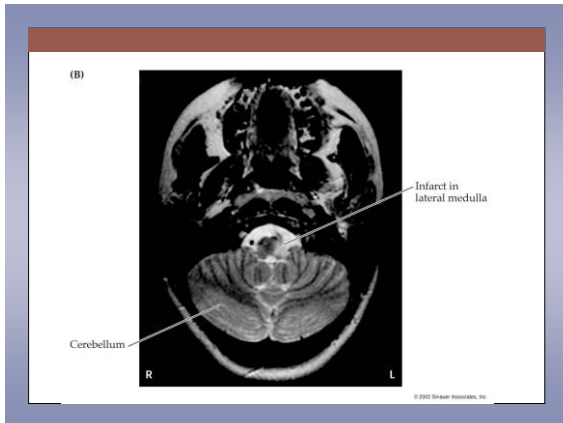
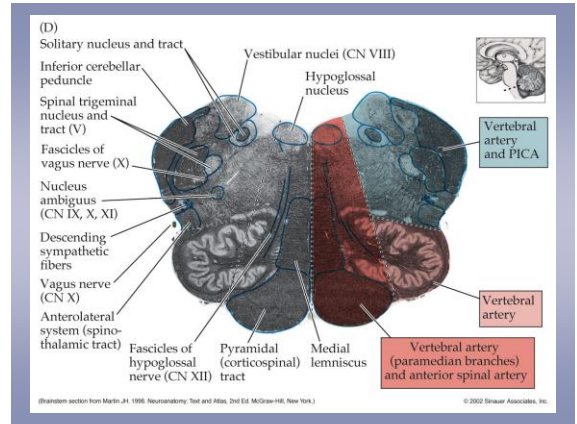
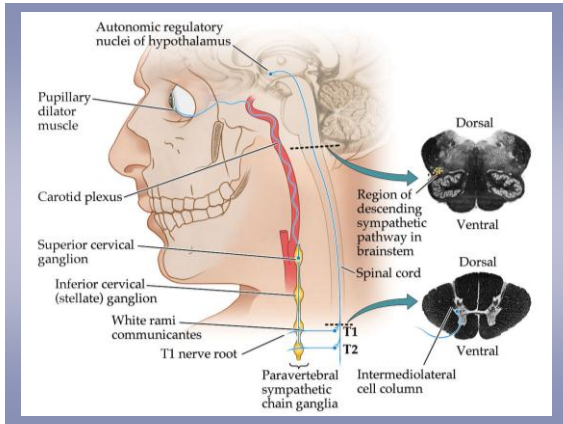
Sensory Testing



RELEVANT ANATOMICAL & CLINICAL CONCEPTS

- Anterolateral Pathways
- Trigeminal Sensory System Nuclei and Pathways (CN V)
- Sympathetic Pathways Causing Pupillary Dilation
- Vestibular Pathways (CN VIII); Vagus Nerve (CN X)
- Localization of Ataxia





FINAL DIAGNOSIS

Left vertebral dissection causing left lateral medullary syndrome (Wallenberg's syndrome)

OUTCOME

Treated with anticoagulation to reduce risk of recurrent stroke. Marked improvement of all abnormalities at 11-day follow-up, with only mild residual deficits.

Case 4

PATIENT PRESENTATION

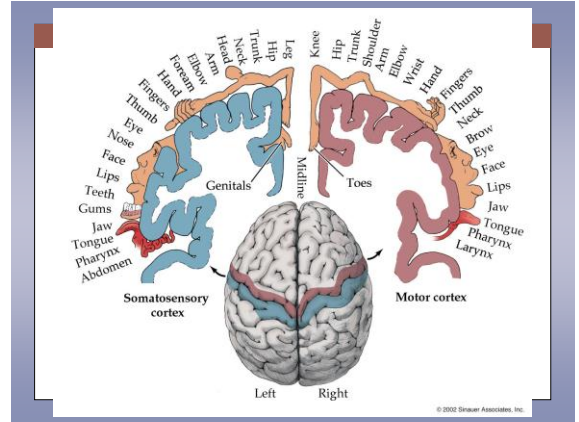
A 67-year-old woman suddenly developed inability to speak and right arm and leg weakness.

KEY SYMPTOMS AND SIGNS

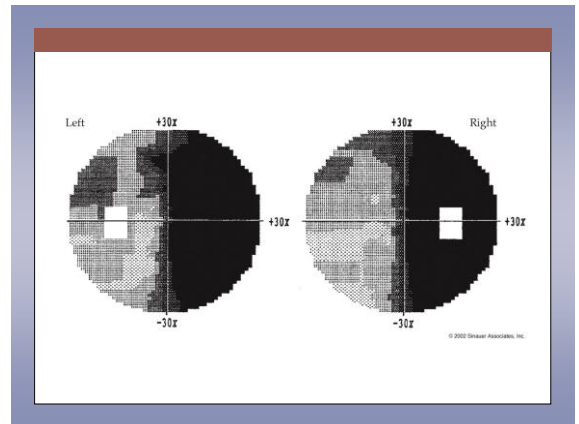
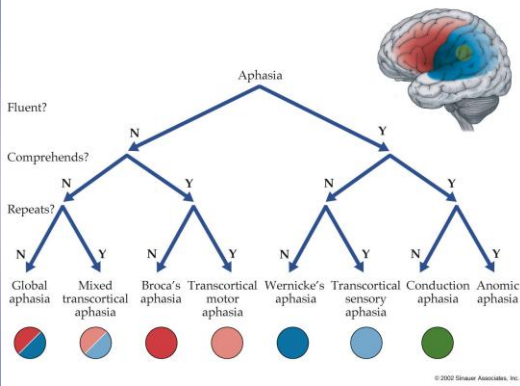
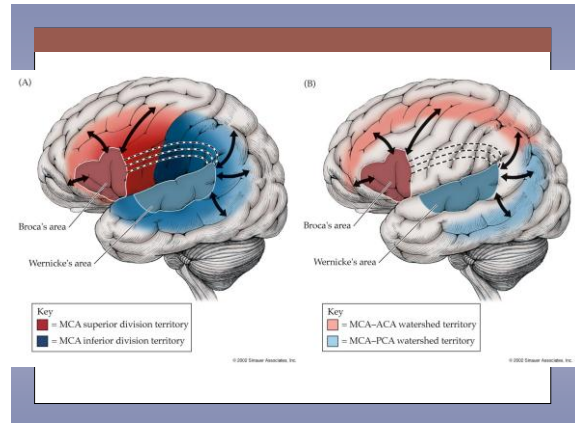
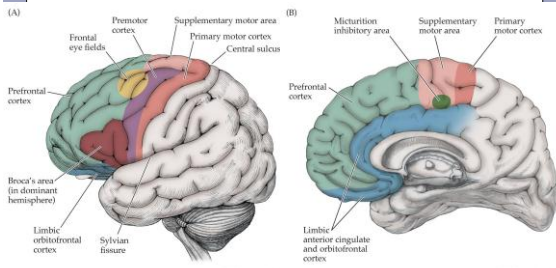
- Impaired comprehension, fluency, repetition, reading, writing, and naming.
- Gaze preference to the left.
- Right homonymous hemianopia
- Profound weakness of the right arm and leg, with weakness of the right lower face.
- Sensory loss on the right face, arm and leg
- Right arm and leg hyperreflexia, and Babinski's sign

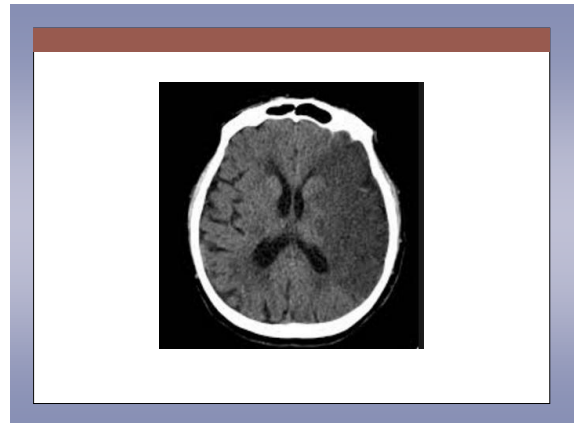
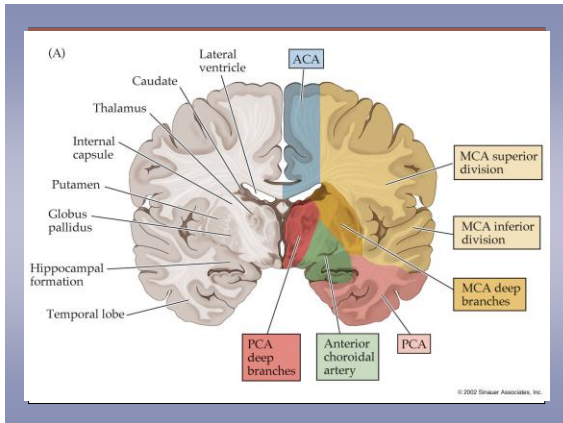
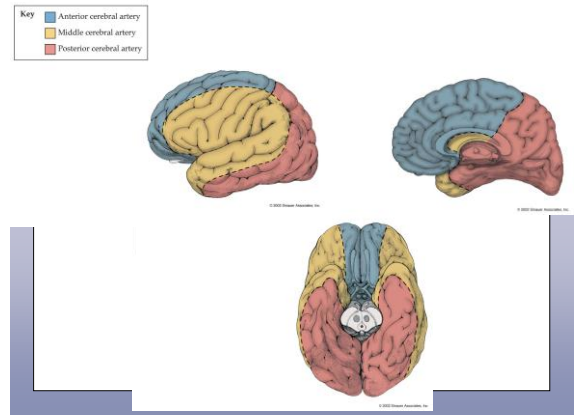
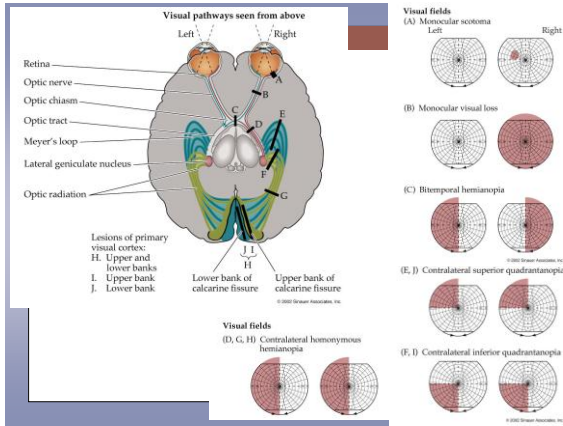
RELEVANT ANATOMICAL & CLINICAL CONCEPTS

- Language localization
- Visual field
- Somatosensory and Motor Homunculi, and Motor Association Cortex



Main Functional Areas of the Frontal Cortex





LOCATION OF INFARCT	AFFECTED TERRITORY	DEFICITS*
Left MCA superior division		Right face and arm weakness of the upper motor neuron type, and a nonfluent, or Broca's, aphasia. In some cases there may also be some right face and arm cortical-type sensory loss.
Left MCA inferior division		Fluent, or Wernicke's, aphasia and a right visual field deficit. There may also be some right face and arm cortical-type sensory loss. Motor findings are usually absent, and patients may initially seem confused or crazy, but otherwise intact, unless carefully examined. Some mild right-sided weakness may be present, especially at the onset of symptoms.
Left MCA deep territory		Right pure motor hemiparesis of the upper motor neuron type. Larger infarcts may produce "cortical" deficits as well, such as aphasia.
Left MCA stem		Combination of the above, with right hemiplegia, right hemianesthesia, right homonymous hemianopia, and global aphasia. There is often a left gaze preference, especially at the onset, caused by damage to left hemisphere cortical areas important for driving the eyes to the right.

LOCATION OF INFARCT	AFFECTED TERRITORY	DEFICITS*
Right MCA superior division		Left face and arm weakness of the upper motor neuron type. Left hemiplegia is present to a variable extent. In some cases there may also be some left face and arm cortical-type sensory loss.
Right MCA inferior division		Profound left hemiplegia. Left visual field and somatosensory deficits are often present; however, these may be difficult to test convincingly because of the neglect. Motor neglect with decreased voluntary or spontaneous initiation of movements on the left side can also occur. However, even patients with left motor neglect usually have normal strength on the left side, as evidenced by occasional spontaneous movements or purposeful withdrawal from pain. Some mild right-sided weakness may be present. There is often a right gaze preference, especially at onset.
Right MCA deep territory		Left pure motor hemiparesis of the upper motor neuron type. Larger infarcts may produce "cortical" deficits as well, such as left hemiplegia.
Right MCA stem		Combination of the above, with left hemiplegia, left hemianesthesia, left homonymous hemianopia, and profound left neglect. There is usually a right gaze preference, especially at the onset, caused by damage to right hemisphere cortical areas important for driving the eyes to the left.

TABLE 10.1 Major Clinical Syndromes of the MCA, ACA, and PCA Territories (Part 3)





LOCATION OF INFARCT	AFFECTED TERRITORY	DEFICITS*
Left ACA		Right leg weakness of the upper motor neuron type and right leg cortical-type sensory loss. Grasp reflex, frontal lobe behavioral abnormalities, and transcortical aphasia can also be seen. Larger infarcts may cause right hemiplegia.
Right ACA		Left leg weakness of the upper motor neuron type and left leg cortical-type sensory loss. Grasp reflex, frontal lobe behavioral abnormalities, and left hemineglect can also be seen. Larger infarcts may cause left hemiplegia.

TABLE 10.1 Major Clinical Syndromes of the MCA, ACA, and PCA Territories (Part 3)

LOCATION OF INFARCT	AFFECTED TERRITORY	DEFICITS*
Left PCA		Right homonymous hemianopia. Extension to the splenium of the corpus callosum can cause alexia without agraphia. Larger infarcts including the thalamus and internal capsule may cause aphasia, right hemisensory loss and right hemiparesis.
Right PCA		Left homonymous hemianopia. Larger infarcts including the thalamus and internal capsule may cause left hemisensory loss and left hemiparesis.

*Compare regions of infarcts to Figure 10.3.

© 2002 Elsevier Associates, Inc.

FINAL DIAGNOSIS

Left middle cerebral artery infarct

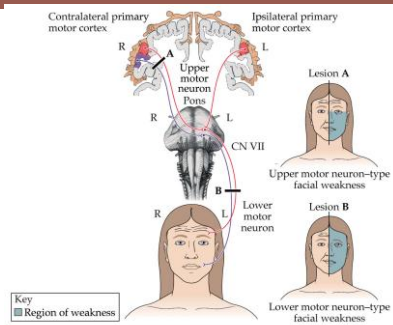
OUTCOME

Patient had persistent non fluent aphasia and weakness of the right leg, and difficulty controlling her right arm.

Case 4

- A 26- year old female developed pain behind the right ear followed by drooping of the right face and mouth deviation to the left . Her right ear was sensitive to sounds. On the next day she developed a “scratchy” painful sensation in the right eye.

Describe and localize



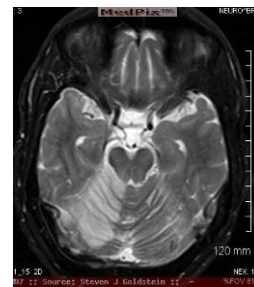
- Right Bell's palsy
- Outcome: treated with oral steroids and ophthalmic care to prevent corneal damage.
- Completely recovered at one month

Case 5

- A 70 y/o M.
- Sudden onset nausea, vomiting, and unsteadiness.
- O/E: mildly slurred speech, slowed tongue movements, dysmetria on finger-to-nose testing on the right, dysmetria on heel-to-shin testing on the right, and right dysdiadochokinesia.
- Walking: veering to the right

Localization

- Right appendicular ataxia + truncal ataxia
- Lesion in the right cerebellar hemisphere extending to the vermis, or
- Lesion of one of the ipsilateral cerebellar peduncles
- Nausea and vomiting = involvement of cerebellar vestibular circuits



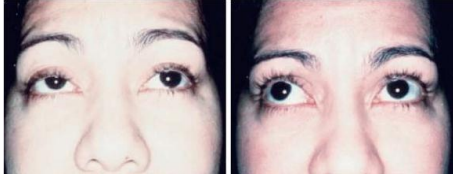Etiology

- Superior cerebellar artery infarct would be the most likely to cause ipsilateral ataxia without other brainstem findings.

Case 6

- A 24-year old female presented with bilateral fatiguable ptosis and diplopia. Her symptoms were worse with watching TV for long time and at the end of the day, and improve by sleeping.
- No other neurological symptoms

Describe and localize?



CASE 7

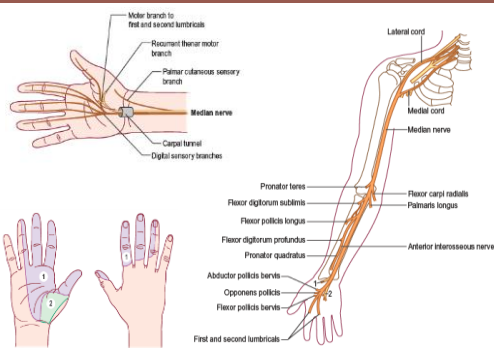
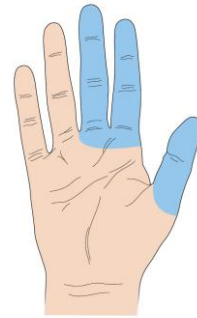PATIENT PRESENTATION

A 38-year-old truck driver who developed pain and tingling in his right thumb, index, and middle fingers over the past 2 months that occasionally radiates into the right arm and forearm. His symptoms are worse at night or when the arm is relaxed.

KEY SYMPTOMS AND SIGNS

- Mild weakness of the right APB and opponens pollicis
- Pain, tingling, and decreased pinprick sensation in the palmar aspect of the right first, second, and third fingers, sparing the thenar area

Region of Sensory Loss



FINAL DIAGNOSIS

Right carpal tunnel syndrome

OUTCOME

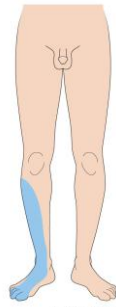
Thyroid function tests and routine blood chemistries were normal. Treatment with a removable splint at night led to recovery.

Case 8

- A 57-year-old man slipped on a wet floor on his back and developed back pain radiating down his leg to the right big toe. He noticed weakness in lifting his foot of the floor when walking.

Neurological examination:

- Normal tone
- Weakness in right big toe extension, foot dorsiflexion, eversion and inversion. Weakness in right hip abduction and mild weakness in right knee flexion.
- Decreased pain sensation over the dorsum of the foot and lateral side of the lower leg.
- Straight leg raise test reproduced pain radiating to the big toe.

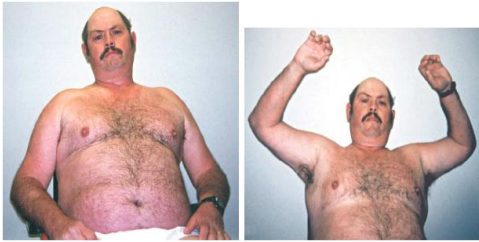

Right L4-L5 posterolateral disc herniation causing right L5 radiculopathy.

Case 9

- A 32-year-old male presented with progressive weakness in upper and lower limbs for the last 3 weeks. Weakness mainly manifested as difficulties lifting his arms above his head and getting out from his car. He described achy pain. No numbness or tingling sensation.

- Normal tone
- Bilateral weak shoulder abduction, elbow flexion and extension, hip flexion and knee flexion and extension.
- Reflexes were normal
- Sensory exam was normal.
- Plantar responses were downgoing.



- The patient was diagnosed with polymyositis
- Serum CK was > 2000.
- He improved with immunosuppressive therapy

	Myopathy	Neuropathy
Weakness	Proximal	Distal
Sensory	Normal	Impaired
Reflexes	Normal	Decreased
Fasciculations	Absent	May be present