

Nuclear Oncology



Saleh Othman , MD

Asso. Prof.& Consultant Nuclear Medicine
King Khalid University Hospital & School Of Medicine
King Saud University

Nuclear Oncology

LEARNING OBJECTIVES...



At the end of the lecture you will be able to answer the following questions:

- What are the tumor imaging and therapeutic radiopharmaceuticals?
- What are the nuclear medicine tumor imaging methods?
- What are the objectives of tumor imaging?
- What are the potential values of nuclear medicine tumor imaging methods?
- What is the role of nuclear medicine in the treatment of tumors?

Tumor Imaging

Tumor Metabolic properties



- ❖ Increased vascularization
- ❖ Increased capillary permeability
- ❖ Newly proliferated capillaries
- ❖ Increased blood flow
- ❖ Metabolically active cells
- ❖ Increased energy demand

Tumor Imaging

Tumor Specific useful properties



- ❖ High density of some common receptors
- ❖ Expression of several specific receptors
- ❖ Expression of some specific tumor antigenes

All these properties could be used for
imaging and therapy

Tumor Non-specific Diagnostic radiopharmaceuticals



- **PET or PET-CT**
 - ❖ F-18 FDG – anaerobic metabolism
- **Planar, SPECT or SPECT-CT**
 - ❖ Diphosphonates – bone scan
 - ❖ Ga-67 citrate – similar to FDG – localising agent
 - ❖ Tc99m Nanocolloid – bone marrow scan
 - ❖ Tc99m MIBI / Thallium 201 – several tumors

Demonstrate tumor sites but are *not specific for malignancy*

Tumor Specific Diagnostic radiopharmaceuticals



- PET or PET/CT:
 - ❖ Gallium -68 –octreotide analogues (Ga-68 DOTA): For neuroendocrine tumors
 - ❖ Fluorine -18-fluorodeoxythymidine(F-18-FLT): For tumor proliferation
 - ❖ Fluorine -18-fluoromisonidazole(F-18-FMISO): For tumor hypoxia
- Planar, SPECT or SPECT/CT:
 - ❖ I-123/131 MIBG for neuroendocrine tumours
 - ❖ I-131 for differentiated thyroid carcinomas
 - ❖ In-111 or Tc99m octreotide for tumours expressing somatostatin receptors.
 - ❖ Monoclonal antibodies labelled with In-111, I-123/131 or Tc-99m

*Binds directly to special tumor antigens or receptors
or are accumulated by special metabolic pathway*

Therapeutic radiopharmaceuticals

- **Non-specific**

- ❖ Sr-89, Sm-153, Re-189

- ❖ Bone pain palliation

- **Specific**

- ❖ I-131

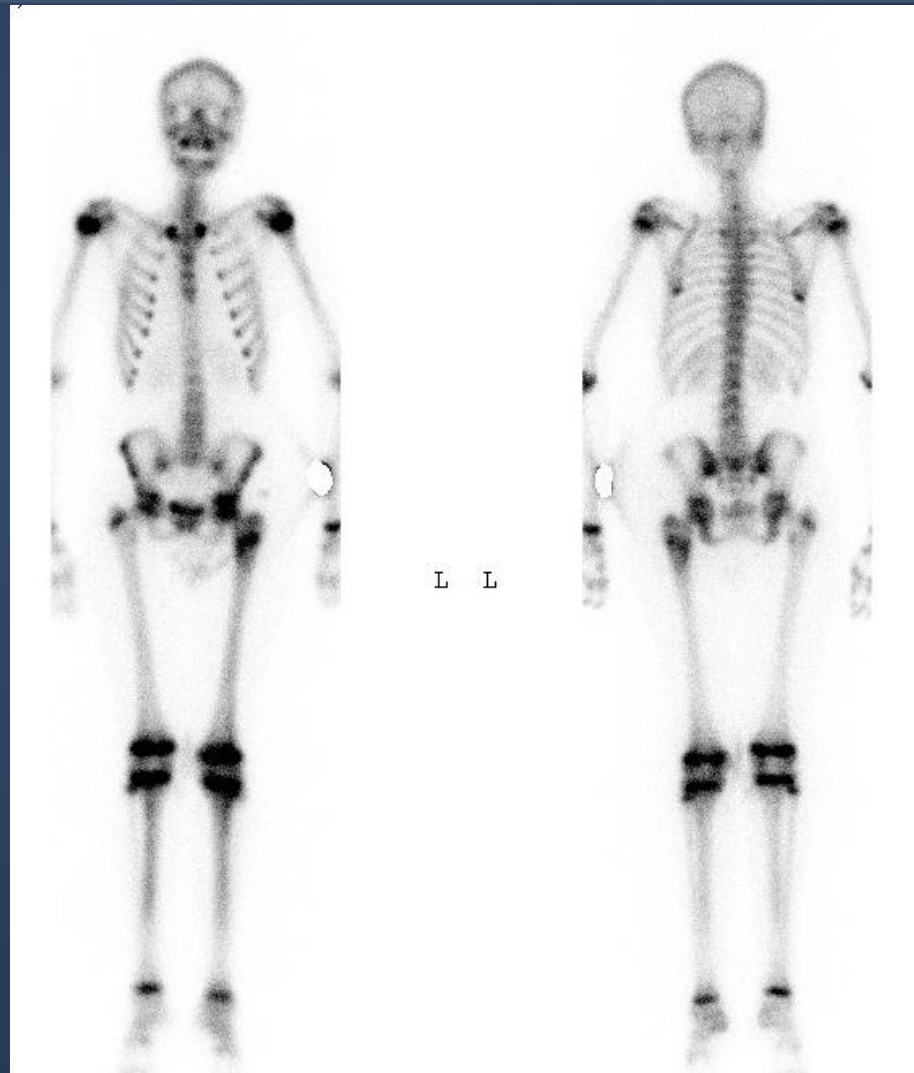
- Thyroid cancer, as specific diagnostic if tumor significantly accumulates

- ❖ Y-90

- Zevalin – monoclonal antibody for B-cell lymphomas

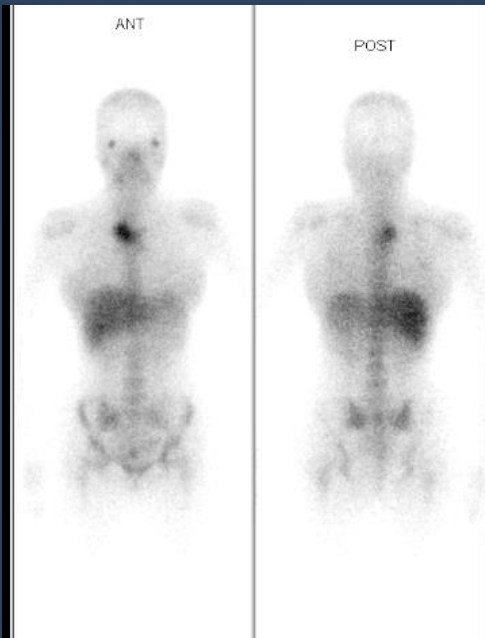
NM Imaging modalities

Planar Imaging

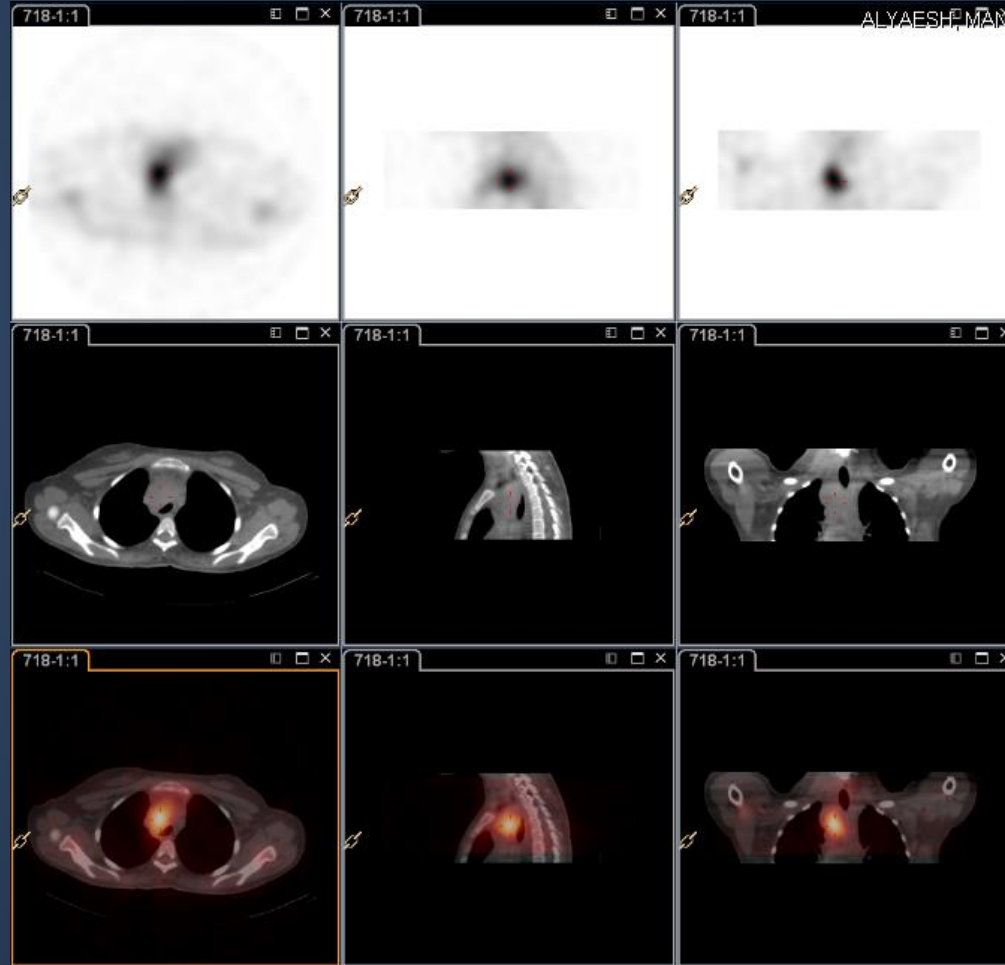


NM Imaging modalities

Single Photon Emission Computed Tomography (SPECT) and SPECT CT



Whole Body Gallium Scan : Planar Image

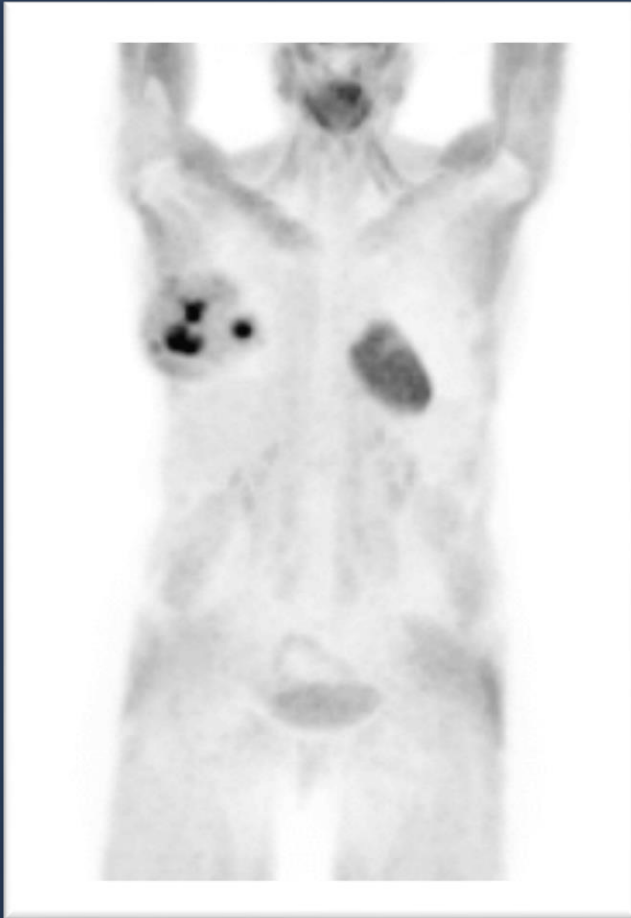


SPECT

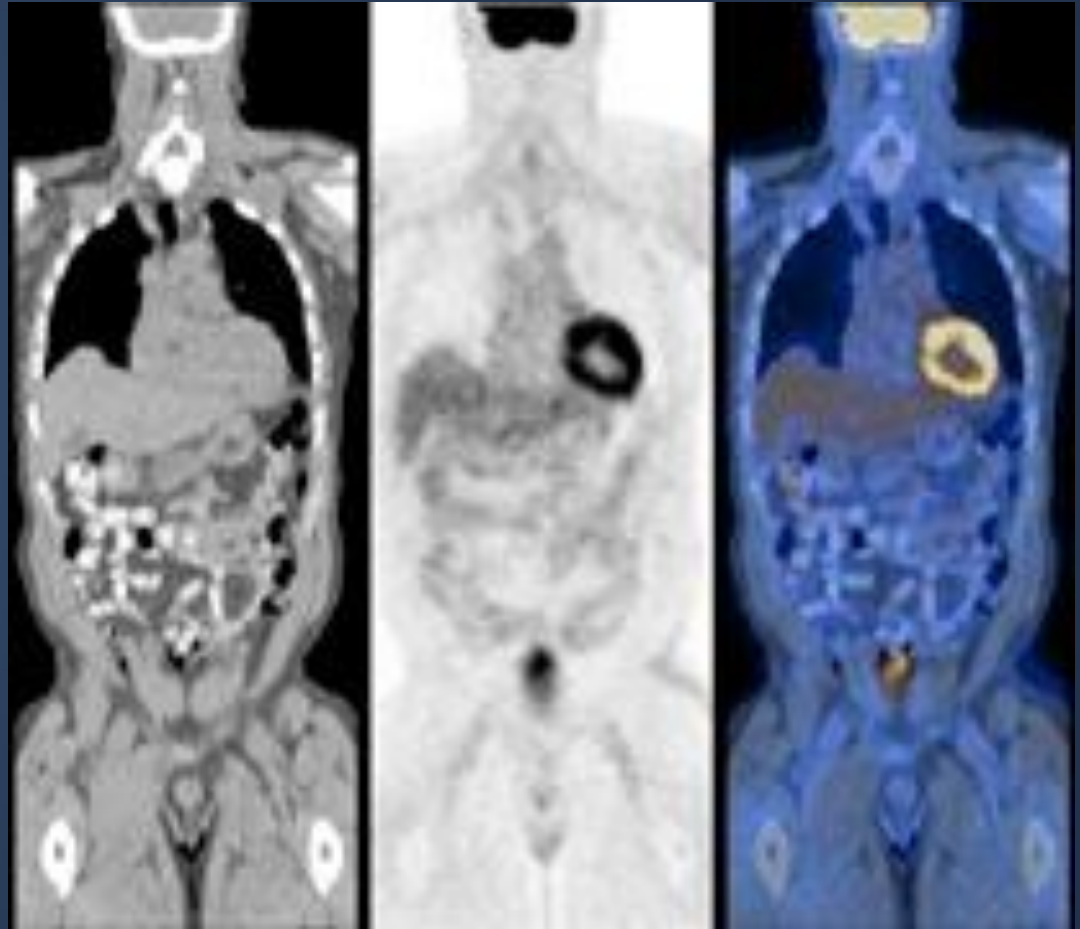
SPECT/CT

NM Imaging modalities

Positron Emission Tomography (PET) and PET CT



PET



PET/CT

Role for Nuclear Medicine In Oncology



- **Diagnosis**
 - Specific or non-specific
- **Staging**
 - Important for proper therapy
- **Follow-up**
 - Early detection of recurrence
- **Treatment**
 - Specific or non-specific

Tumor Imaging

Non specific tumor imaging agents:

- **Tc-99m MDP bone scan:** Detection and follow up of bone metastasis
- **Gallium 67 :** Staging ,Restaging & therapy assessment of HD , NHL , Lung cancer
- **Thallium 201 :** Tumor viability & tumor seeking.
{Tc-99 m Agents (MIBI ,TETRO).}
- **F18 – FDG :** Staging ,Restaging & therapy assessment of HD , NHL , Lung cancer

Specific tumor imaging agents:

- **In-111 (TC99m) Octreotide :** Neuroendocrine tumors
- **I -123 MIBG :** Neuroendocrine tumor
- **I -131 :** Lung mets. thyroid carcinoma

Bone scan

“Procedure”



- **Radiopharmaceuticals**

Technitium 99m **M**ethylene **D**iPhos**P**honate (Tc-99m **MDP**)

- **Tissue accumulation depends on**

- blood flow
- capillary permeability
- metabolic activity of osteoblasts and osteoclasts
- mineral turnover

- **Dose:** 500 to 800 MBq (Megabequerel) / 15- 20 mCi (millicurie)

- **Imaging time:** 2 to 3 hours postinjection – WB + SPECT

- **Potentials of bone scan:** Positivity many months before an abnormality can be detected on X ray

Bone Scan In Oncology

Indications



I- Metastatic Disease: Lung cancer, prostate, breast, thyroid, and renal tumours

- Diagnosis.
- Initial staging.
- Restaging.
- Asses response to therapy.

II- Primary Bone Tumors :

- Malignant or Benign
- Therapy planning for patients with primary bone malignancy (e.g. Osteogenic & Ewings sarcoma)

III- Soft tissue tumors :

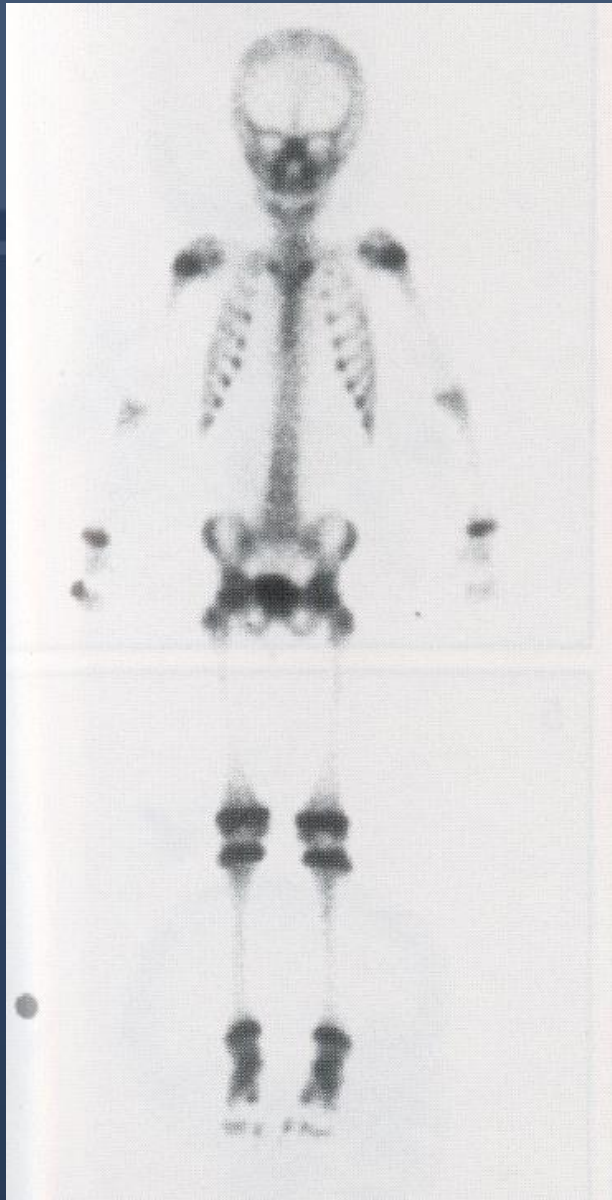
- Primary
- Metastases

Bone Scan In Oncology

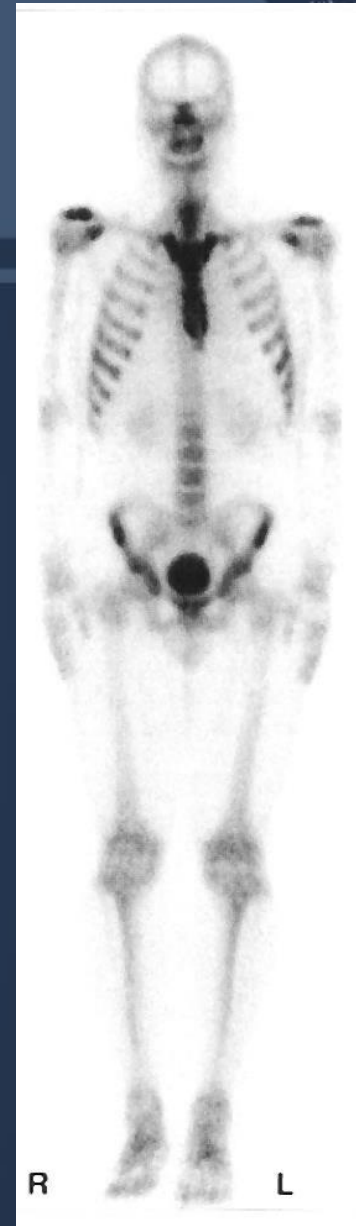Imaging features



- a. Hot lesions** : Majority of bone tumors.
- b. Cold lesions** : Purely osteolytic tumors (renal cell carcinoma, thyroid cancer, anaplastic tumors), radiation therapy
- c. Superscan** : Diffuse increased skeletal uptake with no soft tissue or kidney activity (e.g. CA prostate ,breast ,..etc).
- d. Normal distribution** : Marrow tumors
(e.g. lymphomas, leukemia, multiple myeloma).
- e. Soft tissue uptake** : Soft tissue tumors may concentrate the tracer.
- f. Flare phenomenon** – increased number of lesions in the case of effective therapy



Normal Whole Body Bone Scan



An 8 year old child

A 25 yrs old adult

Bone Scan : In Metastatic Disease

Access of Nonosseous Tumors To Bone:

- Direct Extension.
- Retrograde venous flow.
- Arterial Circulation (after venous or lymphatic access).

Epithelial Tumors:

- Reach red marrow of axial skeleton via venous and arterial flow.
- **Distribution of red marrow in adult** : calvarium, spine , pelvis , and proximal femurs and humerus
- 90% of metastasis from epithelial tumors are found in red marrow.

Metastatic Foci:

- Grows in red marrow space.
- The surrounding bone remodels through osteoclastic (resorption) and osteoblastic (deposition) activity.
- The relative balance between resorption and deposition determine whether the lesion is hot (sclerotic) , cold (lytic) or mixed pattern.
- The tracer does not concentrate in the metastatic foci (cancerous tissue) but in the surrounding reactive bone.

Bone Scan : In Metastatic Disease

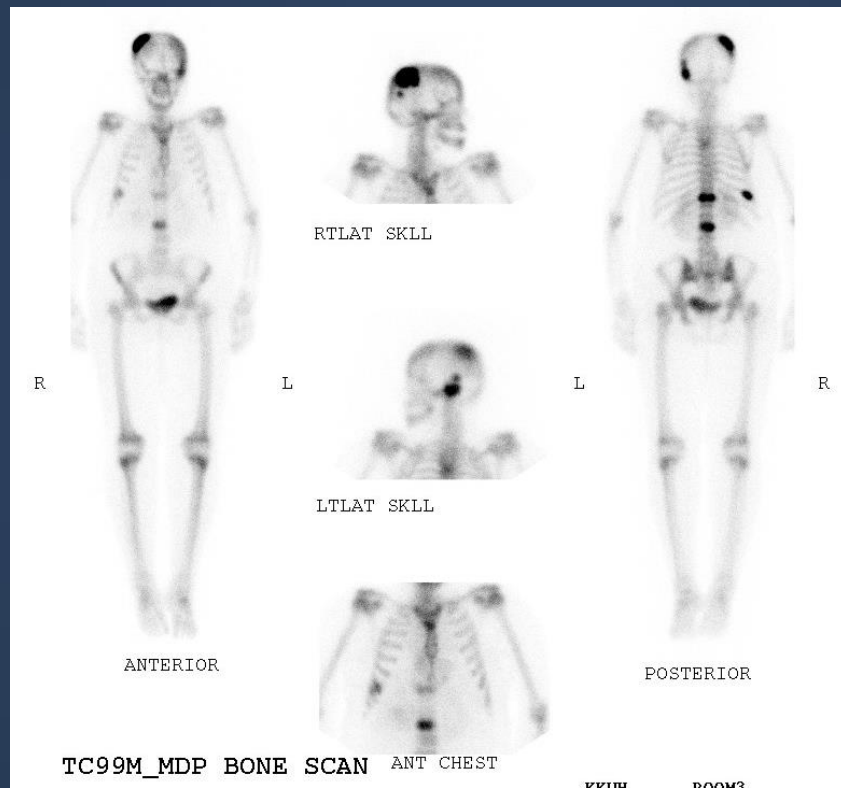
Scan Patterns:

- Solitary lesions.
- Multiple focal lesions.
- Diffuse involvement (Superscan).
- Photon deficient lesions (cold lesions).
- Flare phenomenon.
- Normal (false negative).
- Soft tissue lesions (tracer uptake in tumor).

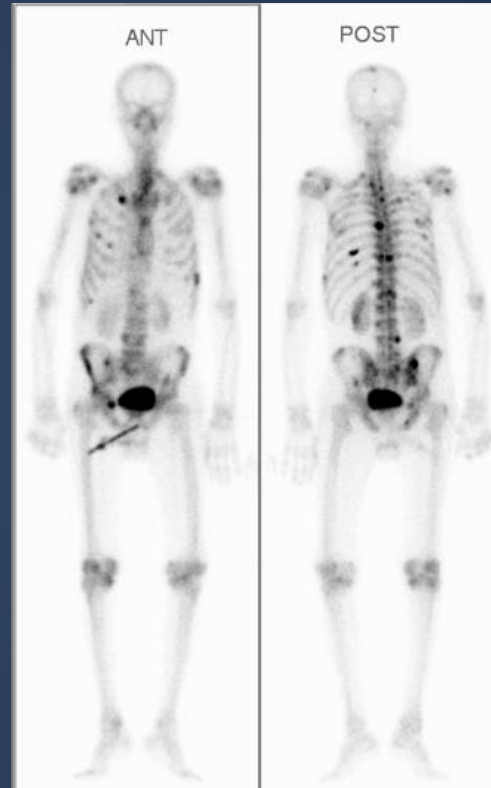
Sensitivity:

- In early stage superior to x-ray.
- In advanced stage both have high sensitivity.
- The accuracy of bone scan not known because of the lack of reference standard.
- The sensitivity is agreed to be 90% or more.

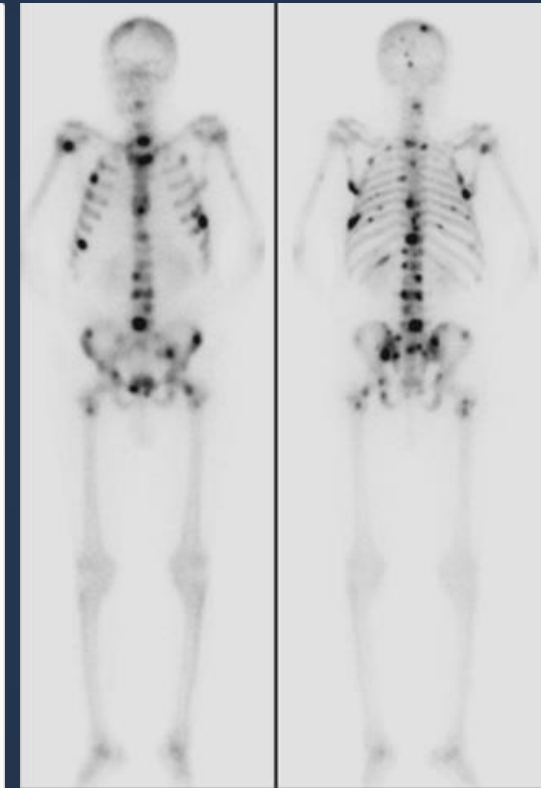
TUMOR STAGING



Ca Breast



CA LUNG



CA STOMACH

Bone Scan In Metastatic Disease

Diffuse involvement (Superscan)



Definition : Bone scan with diffuse symmetrical increased uptake and almost absence of soft tissue activity, lack of kidney activity and bone uptake seen in blood pool images.

Causes :

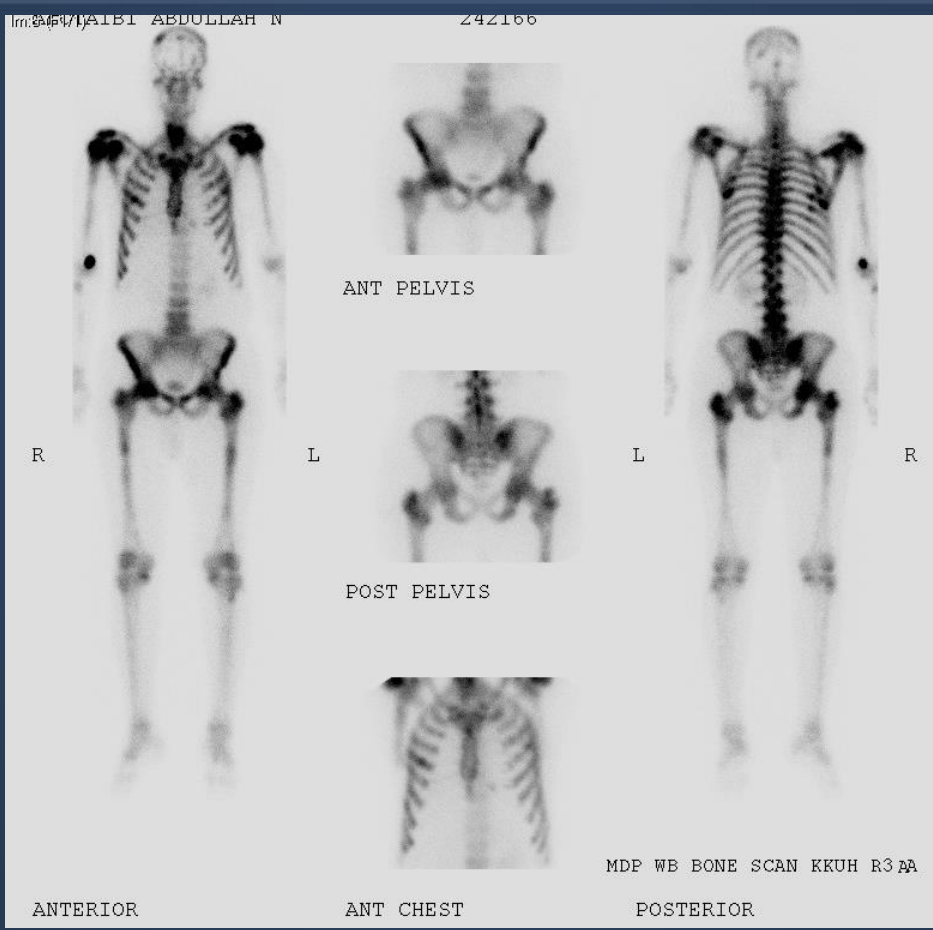
a. Bone metastases : Prostate, breast, lung, bladder and lymphoma.

b. Non tumor causes: HPT, osteomalacia, Pagets disease and fibrous dysplasia

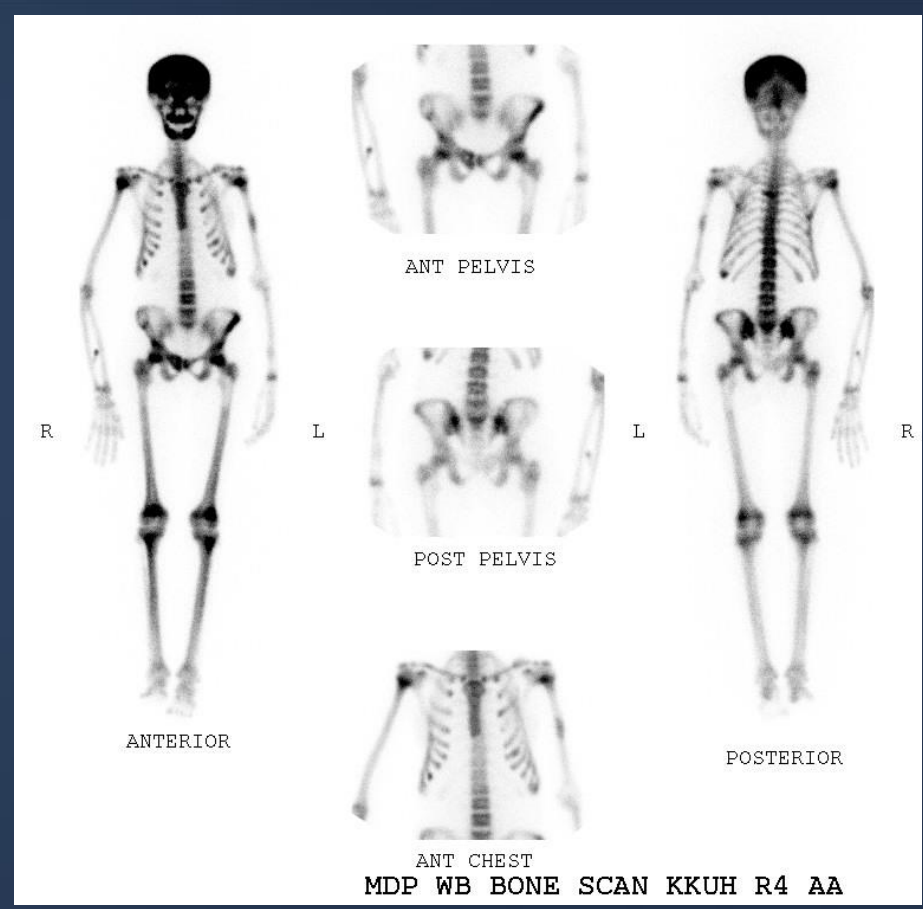
Important clues :

In metabolic bone disease the calvarium and long bones are involved unlike in bone metastases.

Superscan

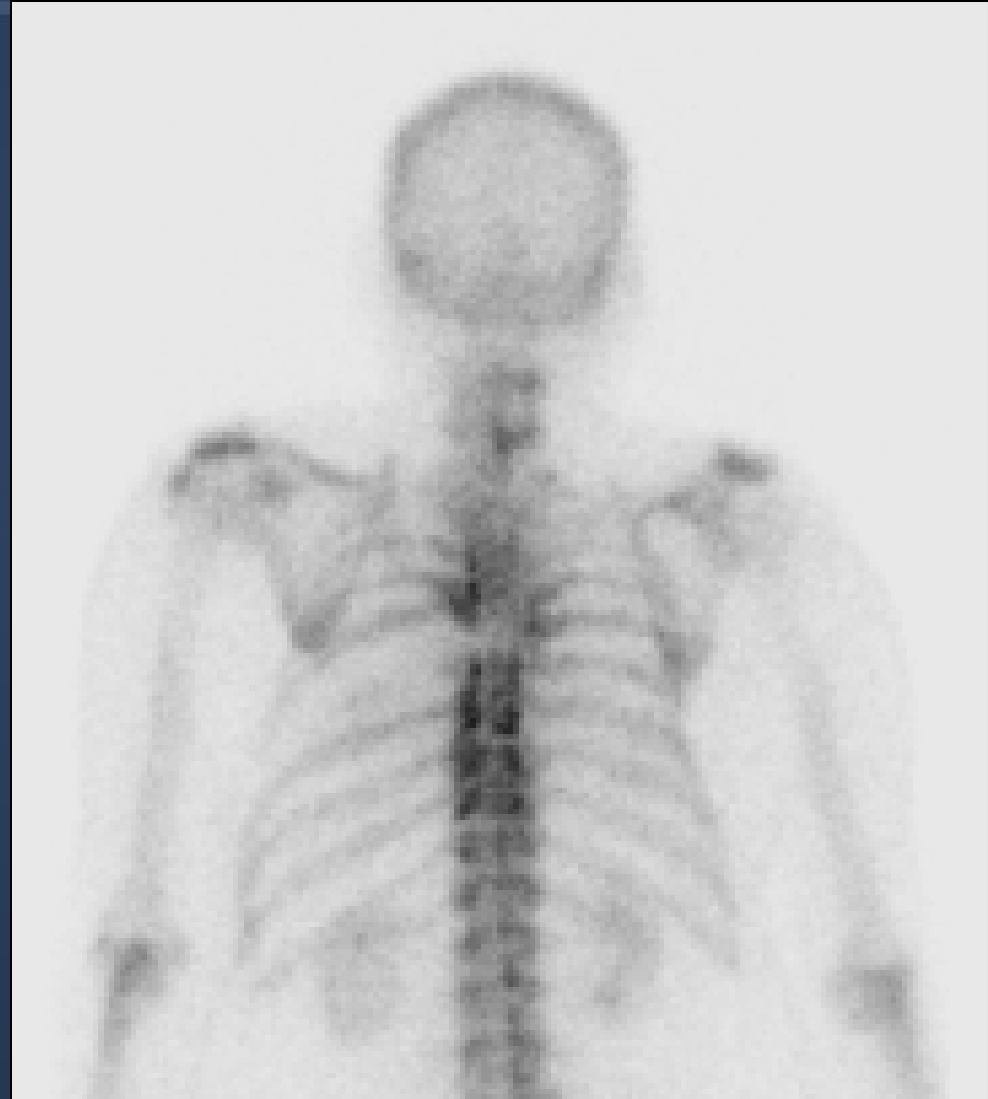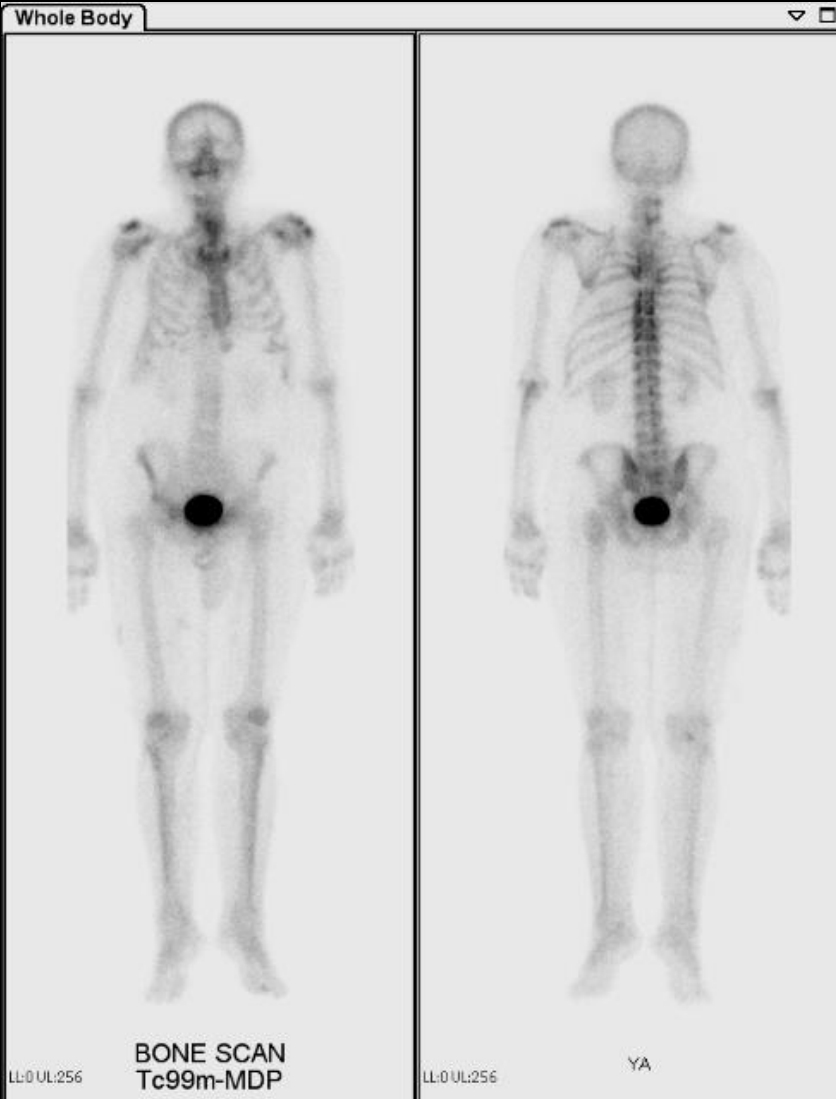


CA Prostate

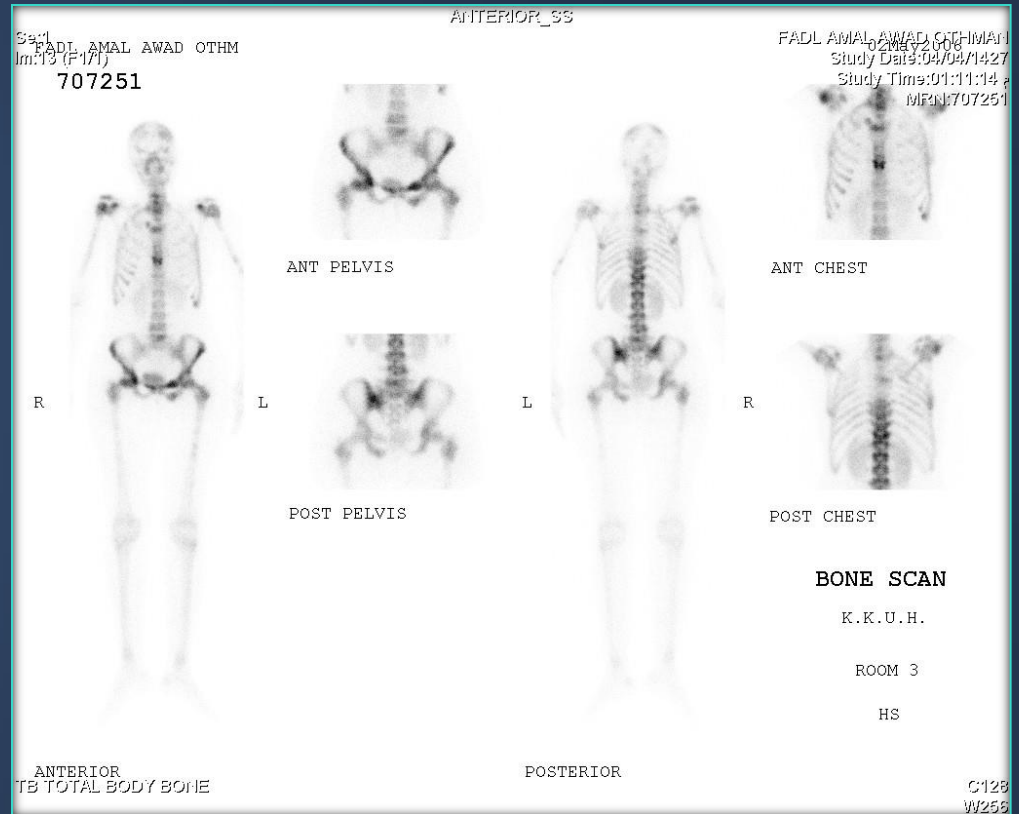
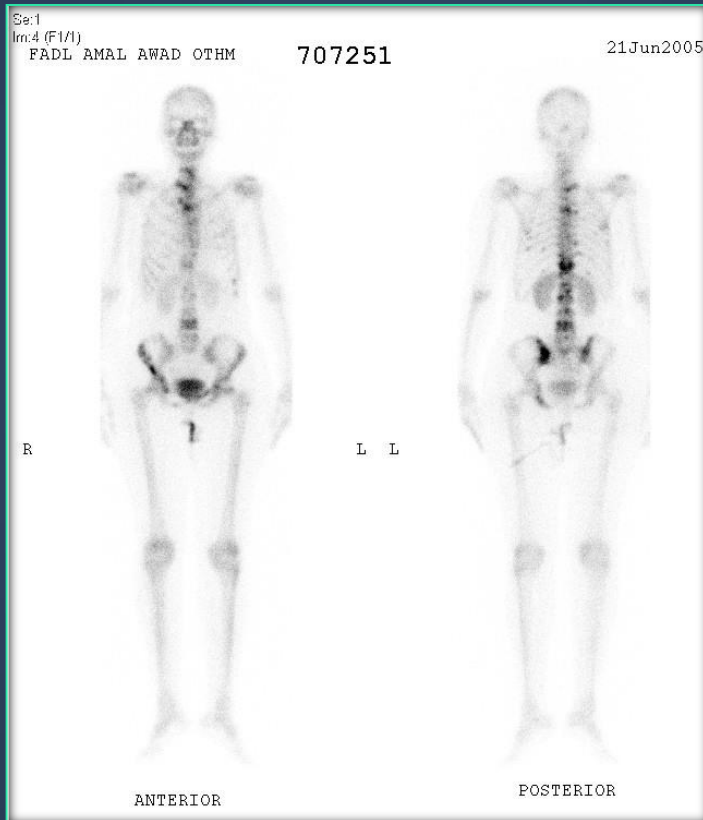

HPT

Pure Lytic Lesions

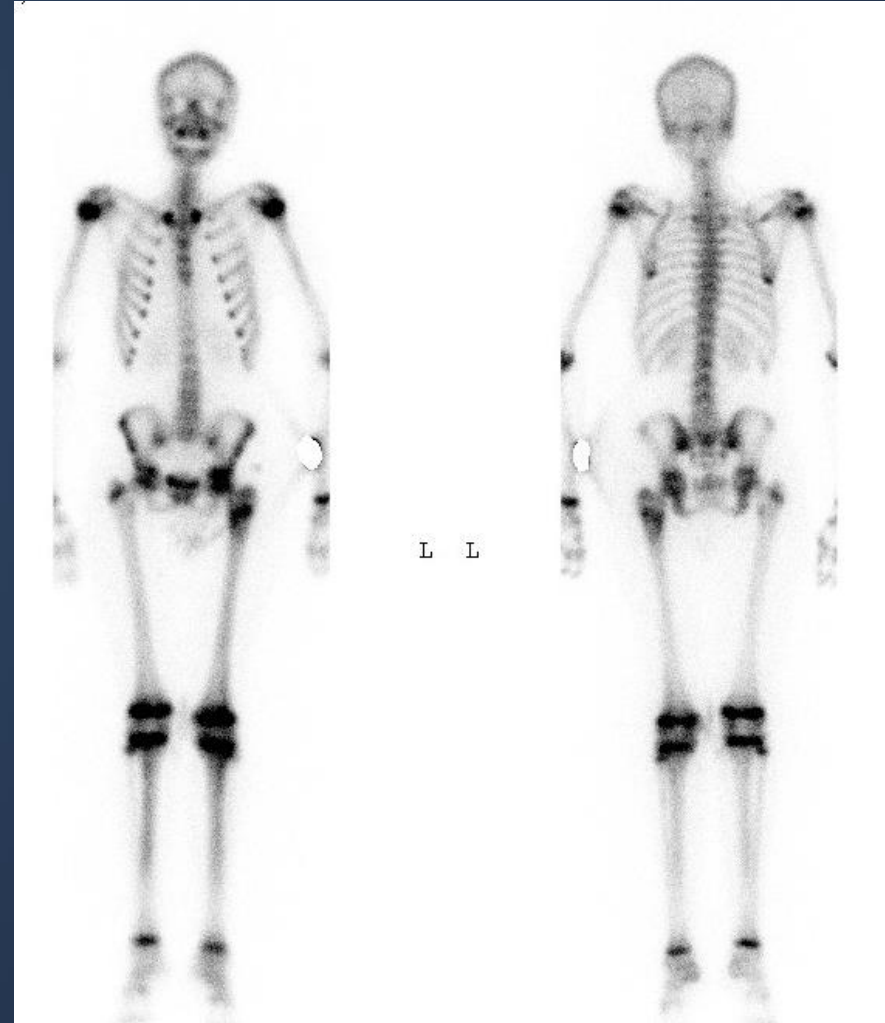
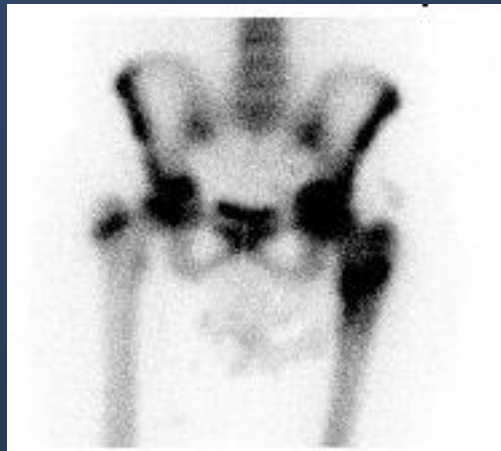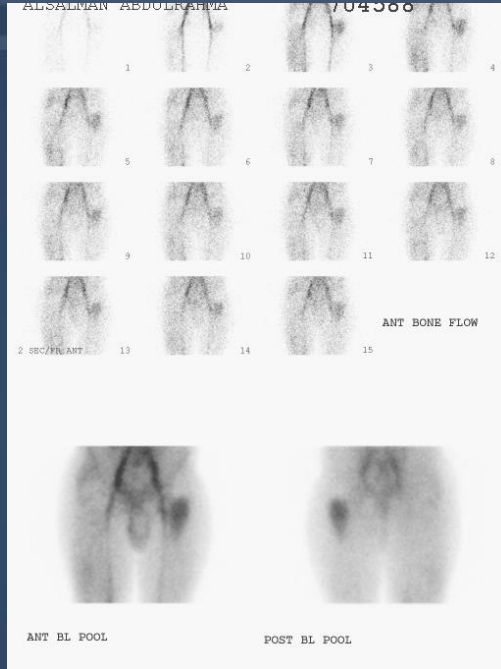

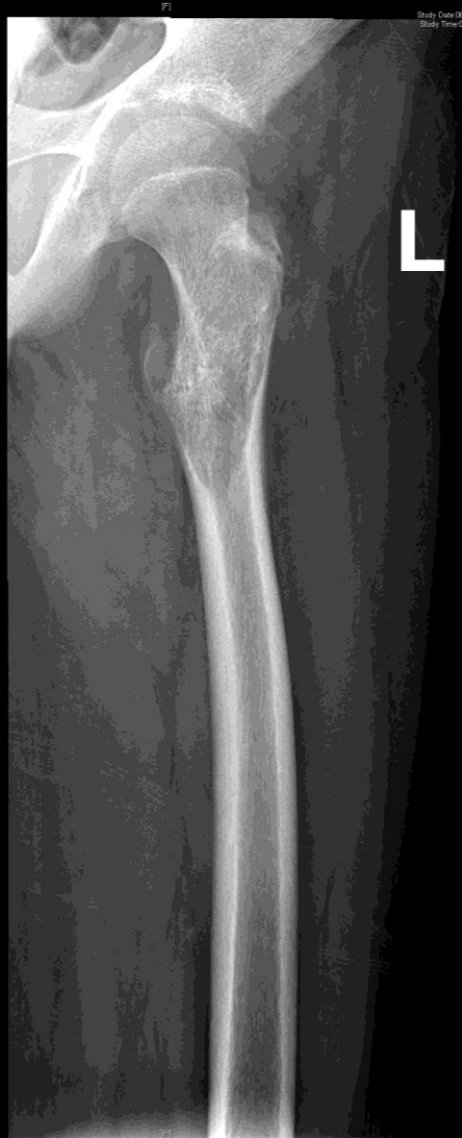
Bone Scan : Radiation Effects



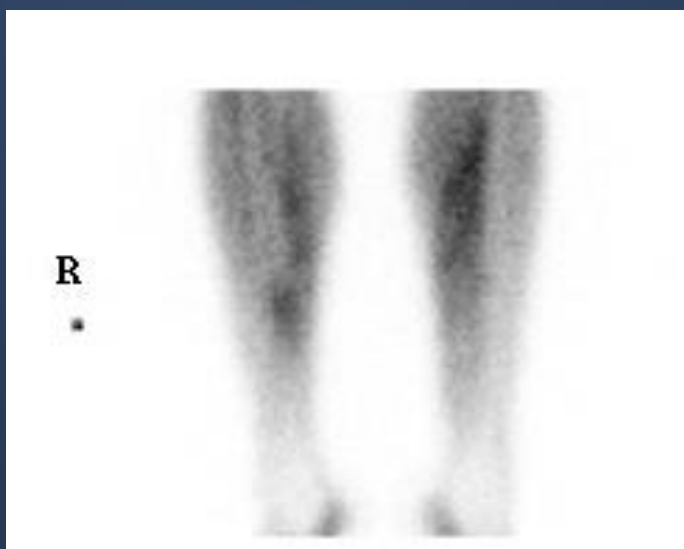
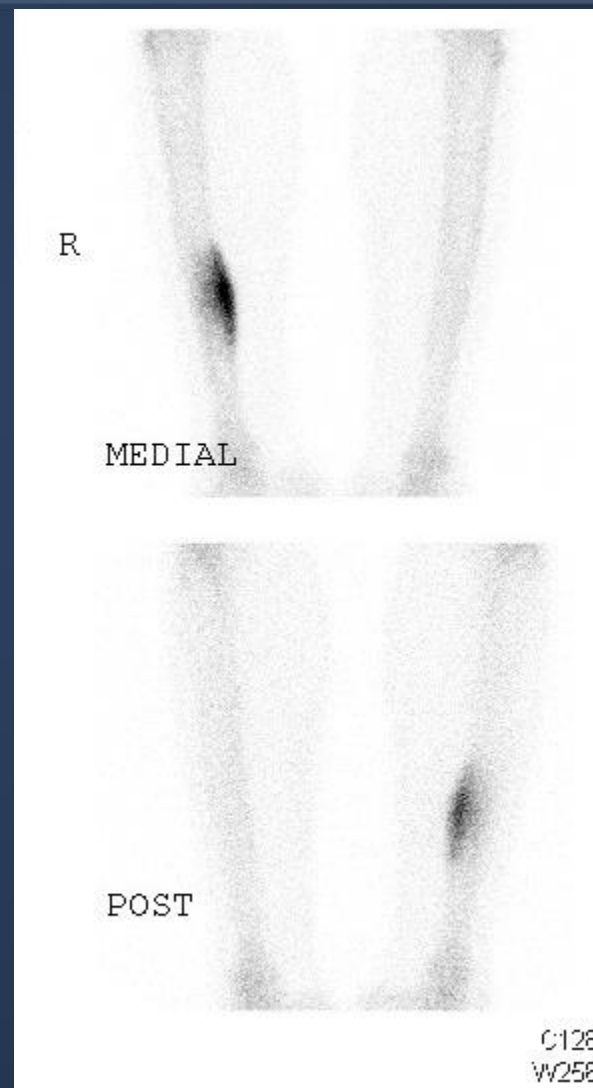
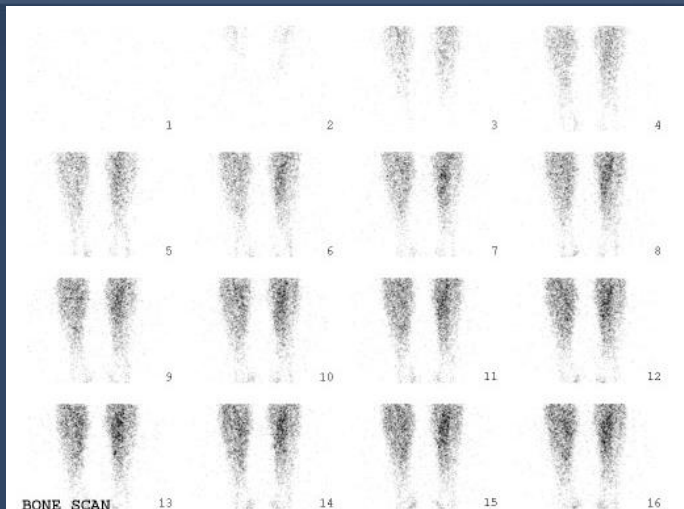
- **Hours** following radiation : **Increased uptake** due to increased blood flow and vascular permeability.
- **3-6 months** post radiation : **Decreased uptake** due to microvascular injury. Dose related (>2000 rads).
- Following Radiotherapy : Spontaneous ribs fracture may occur.

Ewing's Sarcoma

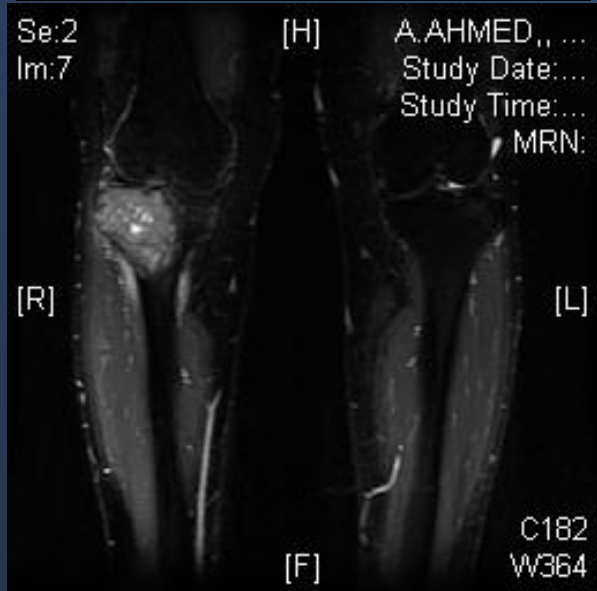
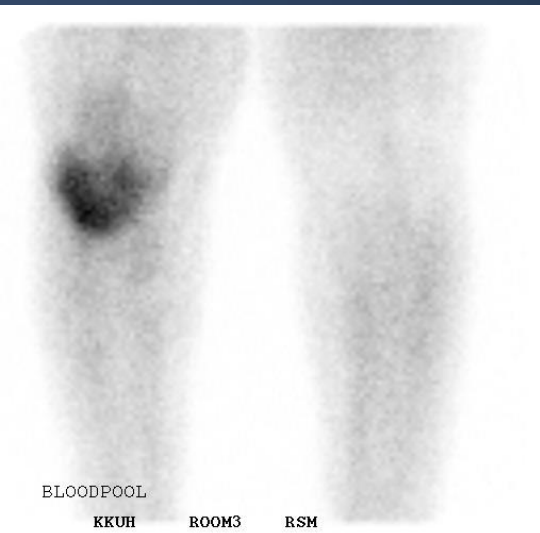
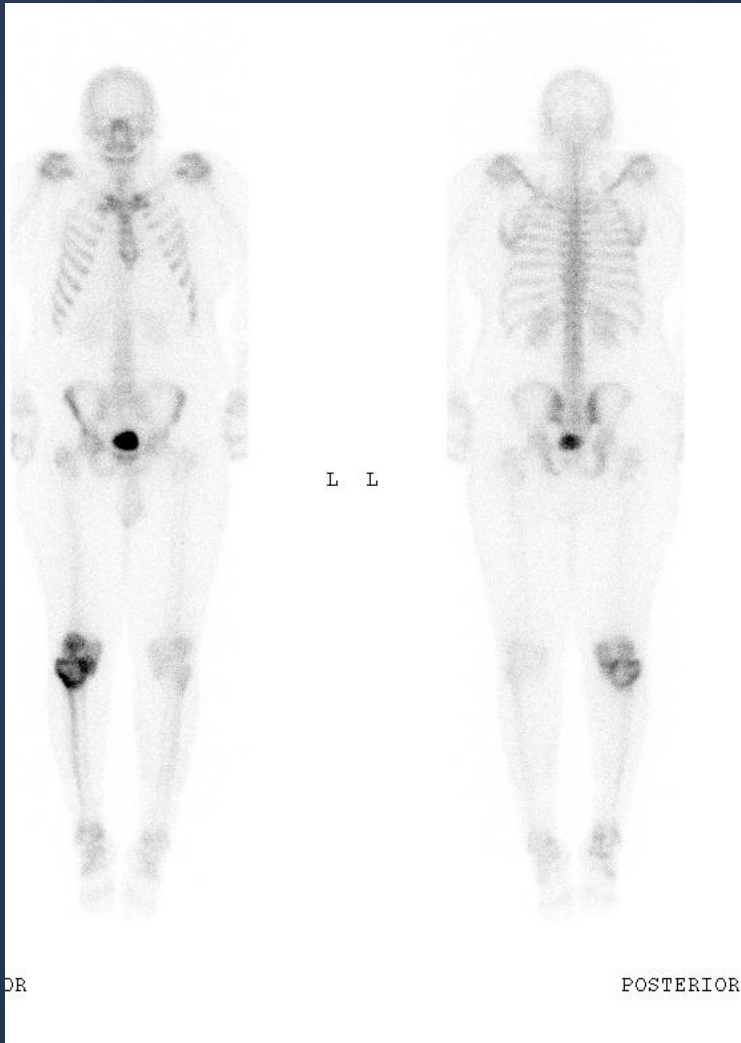
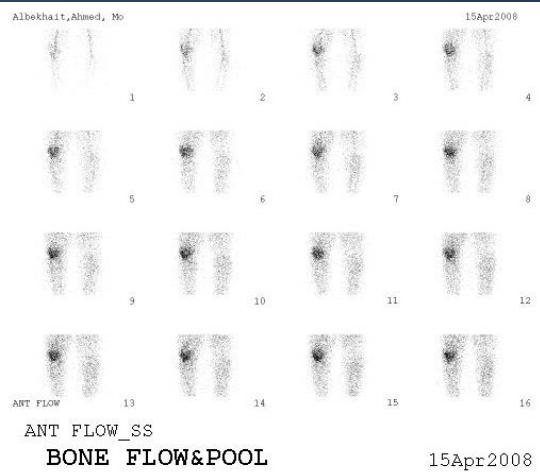
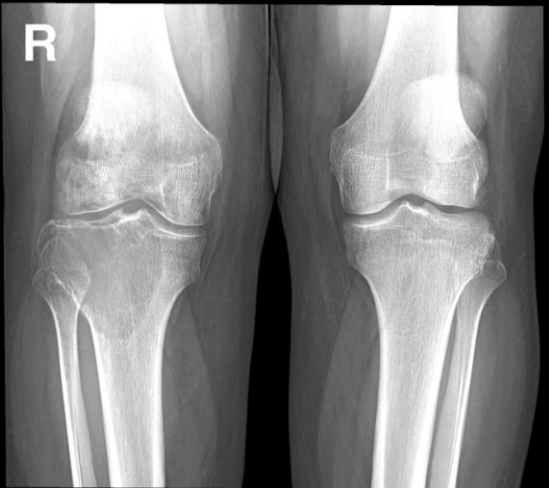

Bone Scan In Bone Tumors

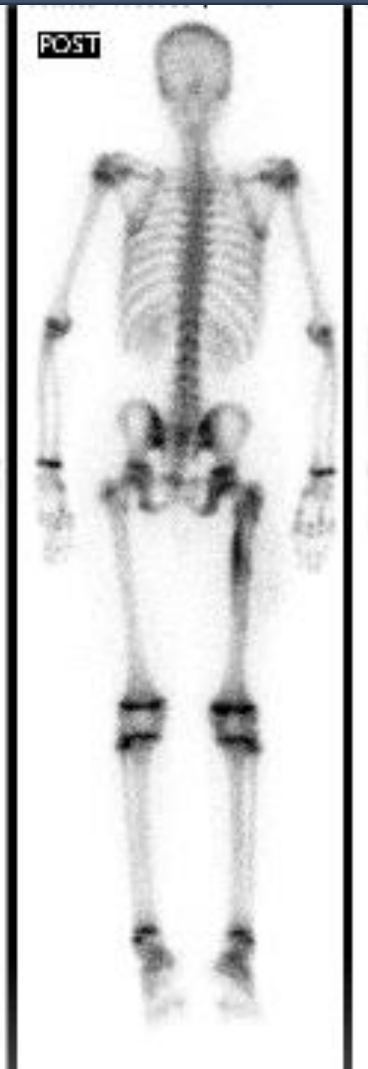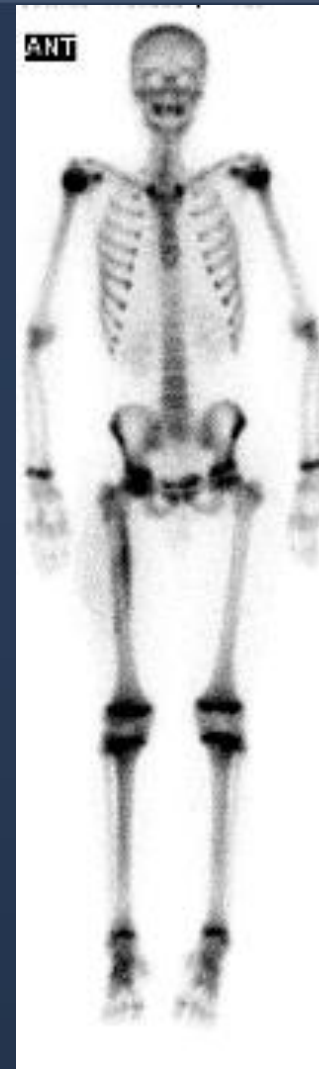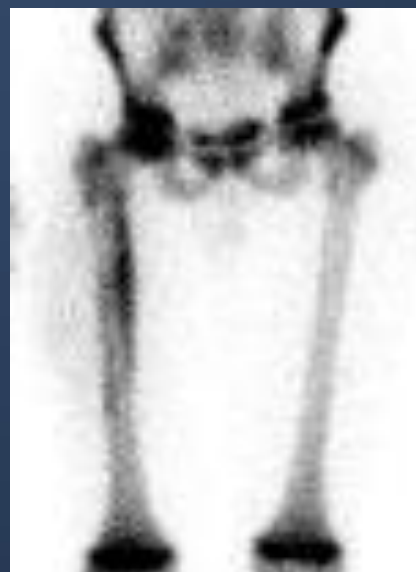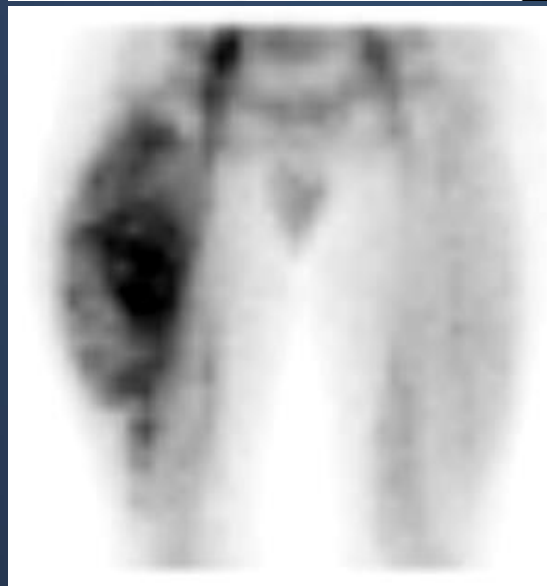
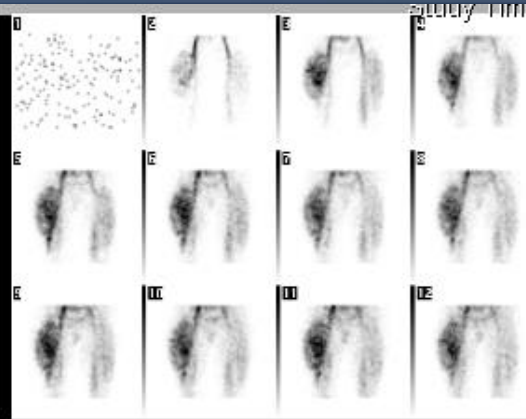
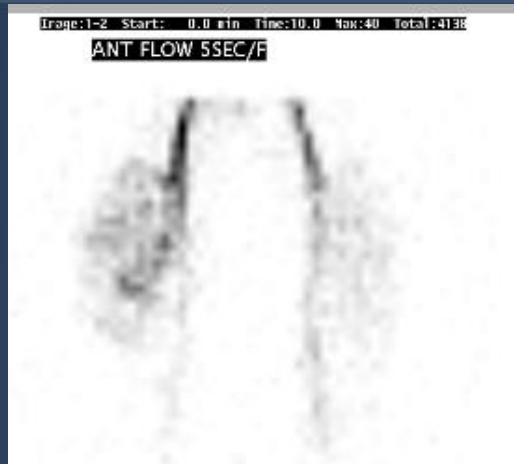Osteoid Osteoma



Giant Cell Tumor



Soft Tissue Sarcoma



Gallium 67 (Ga-67) scan



Properties: Introduced in seventies of 20th century for lymphomas

- **Mechanisms of accumulation**
 - Tumour viability
 - Blood flow
 - Capillary permeability
 - Lymphatic drainage
 - Binds to Transferrin receptors on the tumour cells
- **Non specific for infection-inflammation and tumors**
- **Excretion: Kidneys and large bowel**

Imaging Protocol:

- **Patient preparation** : Laxatives for bowel preparation post injection, nothing else
- **Several weeks post tumor therapy (FN)**
Radiation therapy and chemotherapy can alter the normal pattern of gallium distribution
- **180 MBq (4-5 mCi) is usually administered**
Imaging follows after 48 – 72 hours
WB + SPECT/SPECT CT, medium-energy collimator

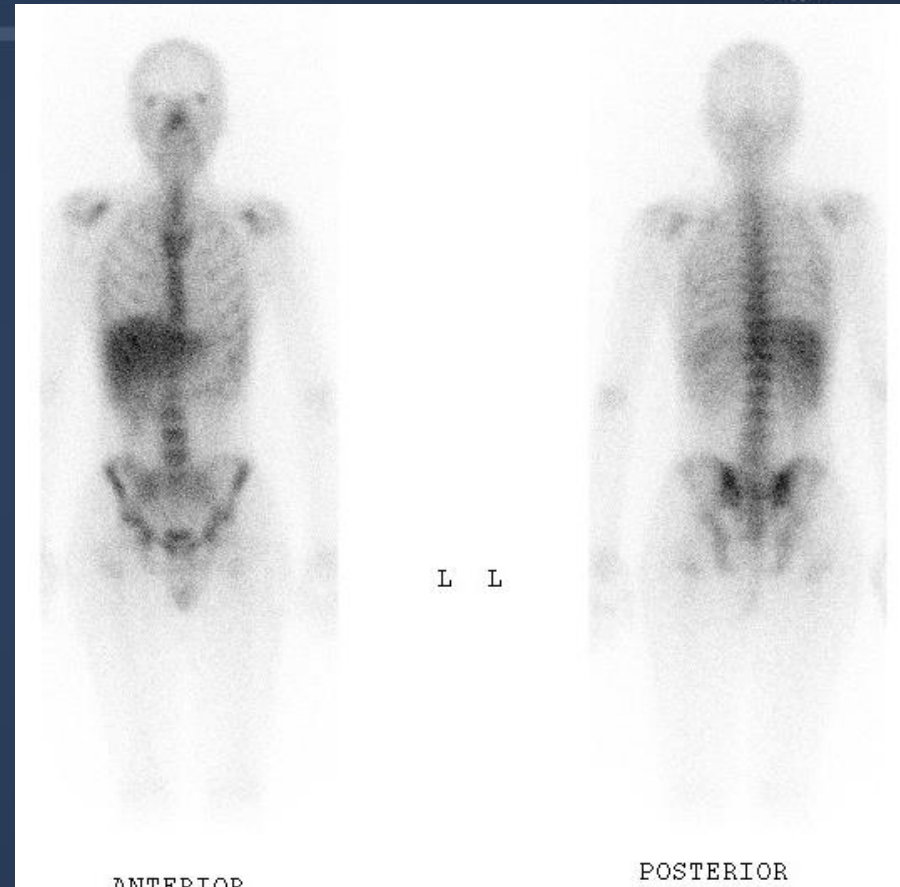Normal Ga-67 scan

Normal scan

- Accumulates in bone marrow and liver.
- Splenic uptake is variable.
- The kidneys are usually visualized and also lacrimal, salivary, nasopharyngeal and genital activity is often present.
- Female breasts can be visualized, but accumulation is physiologically symmetrical
- Radioactivity is commonly seen in the colon

Clinical indications

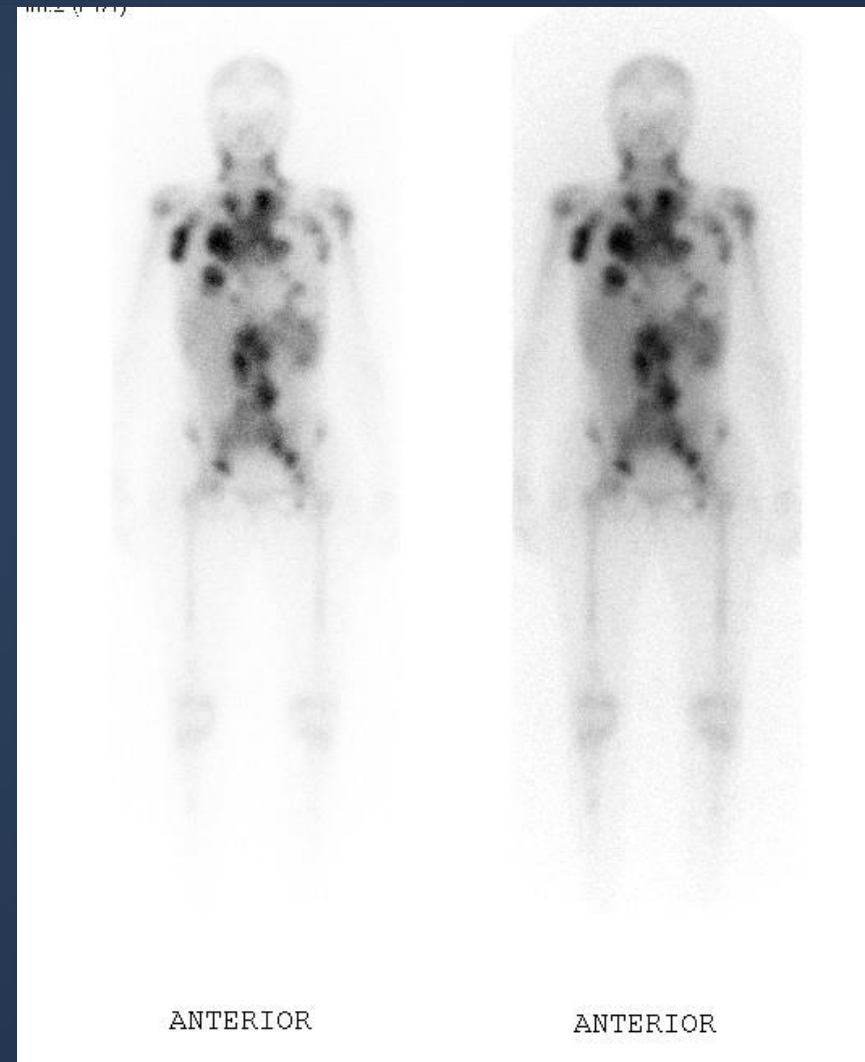
- Lymphoma
- Melanoma
- Lung cancer
- Hepatoma



Gallium Scan in Lymphomas

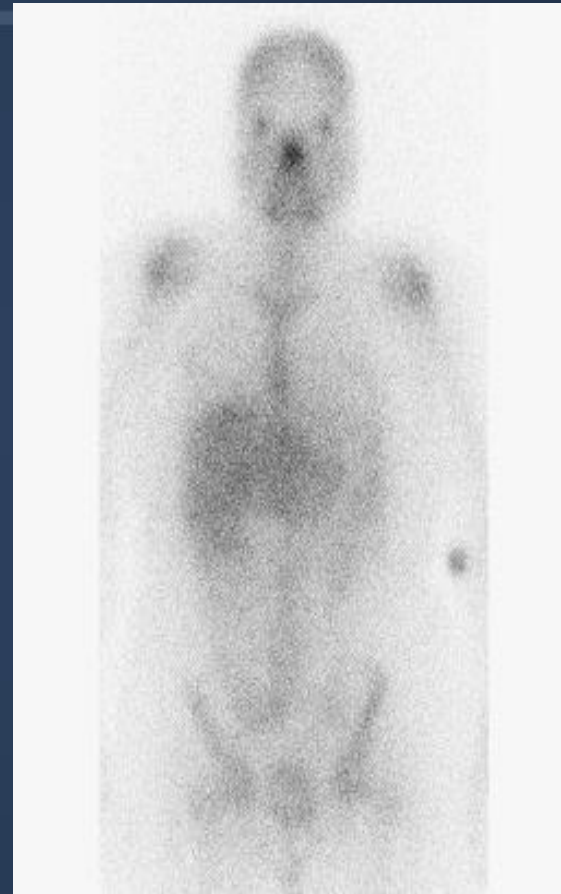
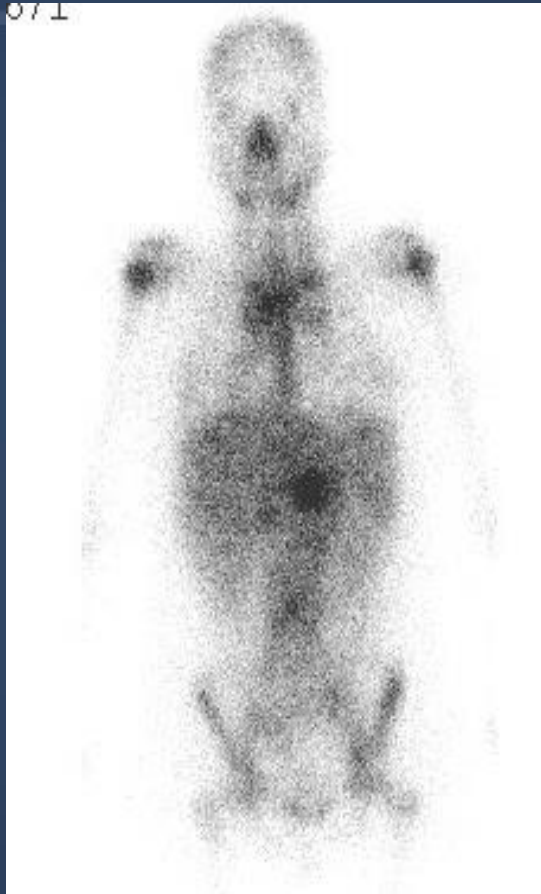

- Staging
- Follow up and monitoring of therapy
- Detection of tumor recurrence
- Differentiate posttherapy changes : tissue necrosis and fibrosis from local recurrence.



Ga-67 Scan In Lymphoma

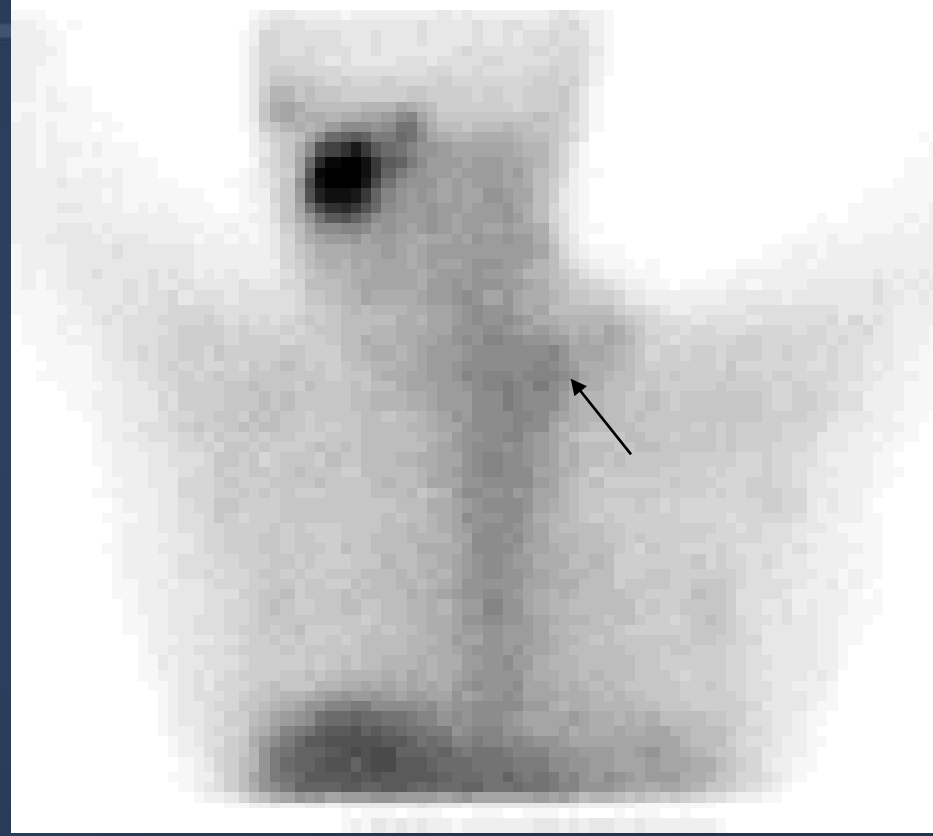
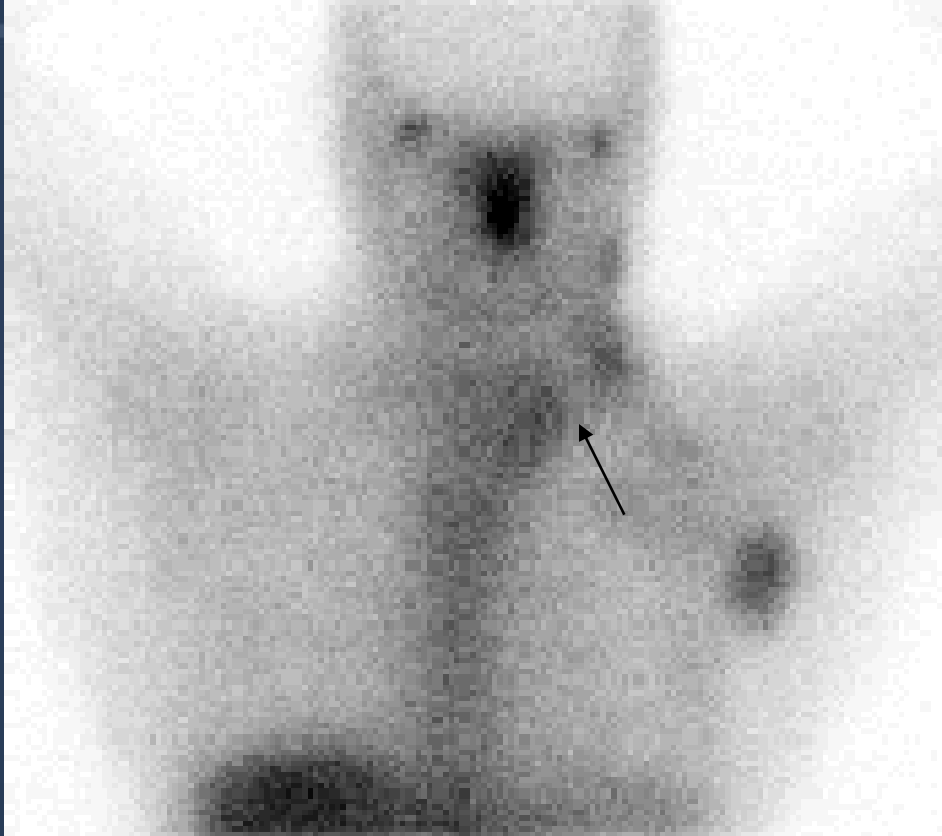
Prediction of response to therapy



Normalization of a positive pre-therapy scan : A negative scan after one cycle or at mid cycle is associated with a high likelihood of complete response .

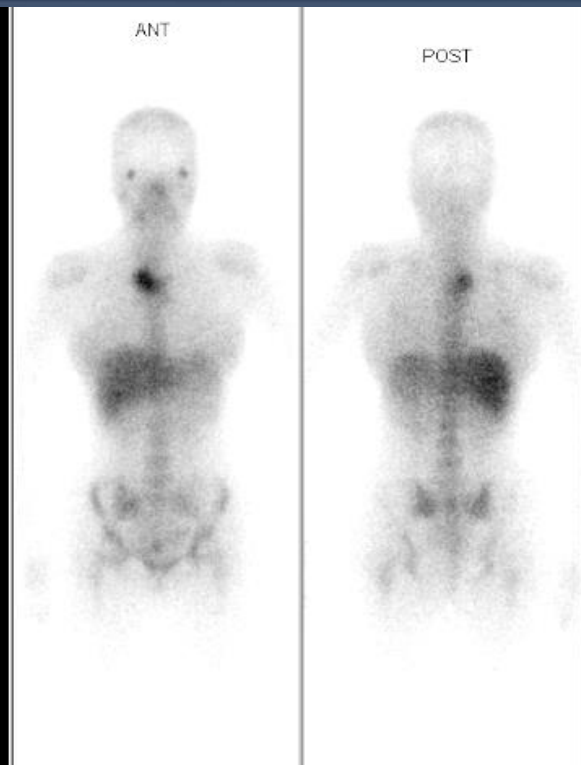
Ga-67 Scan In Lymphoma

Prediction of outcome

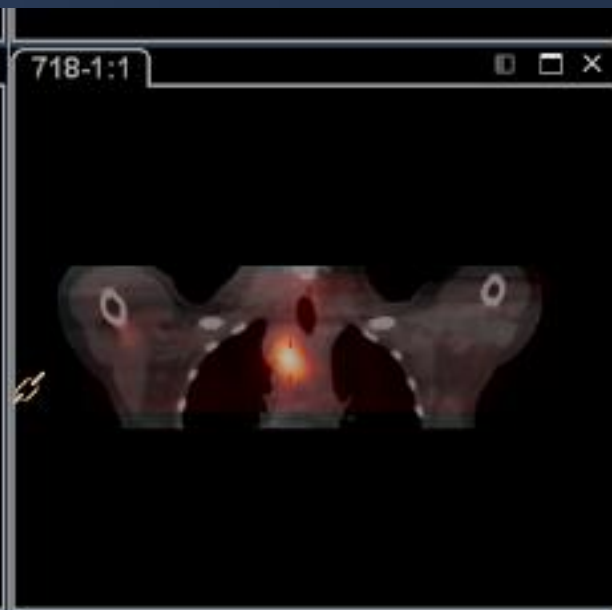
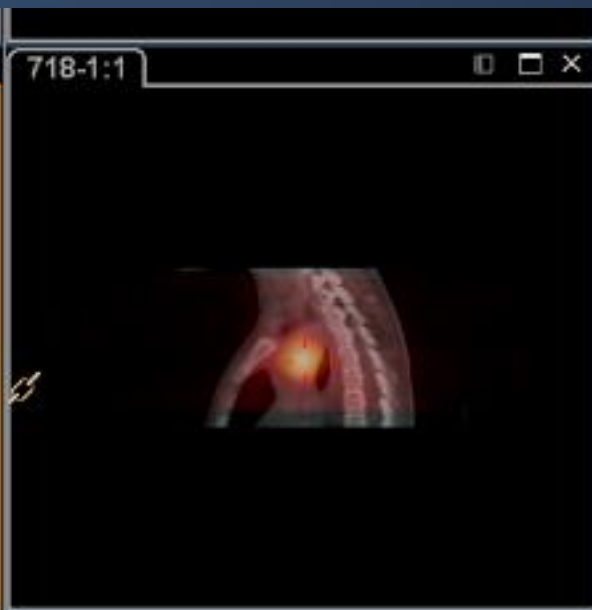
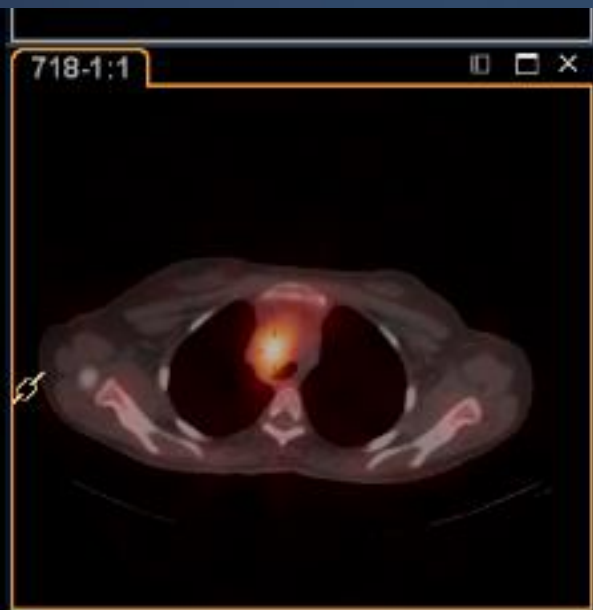Residual gallium uptake after treatment is a poor prognostic sign, indicates viable tumor and treatment should be modified.

Gallium Scan NHL



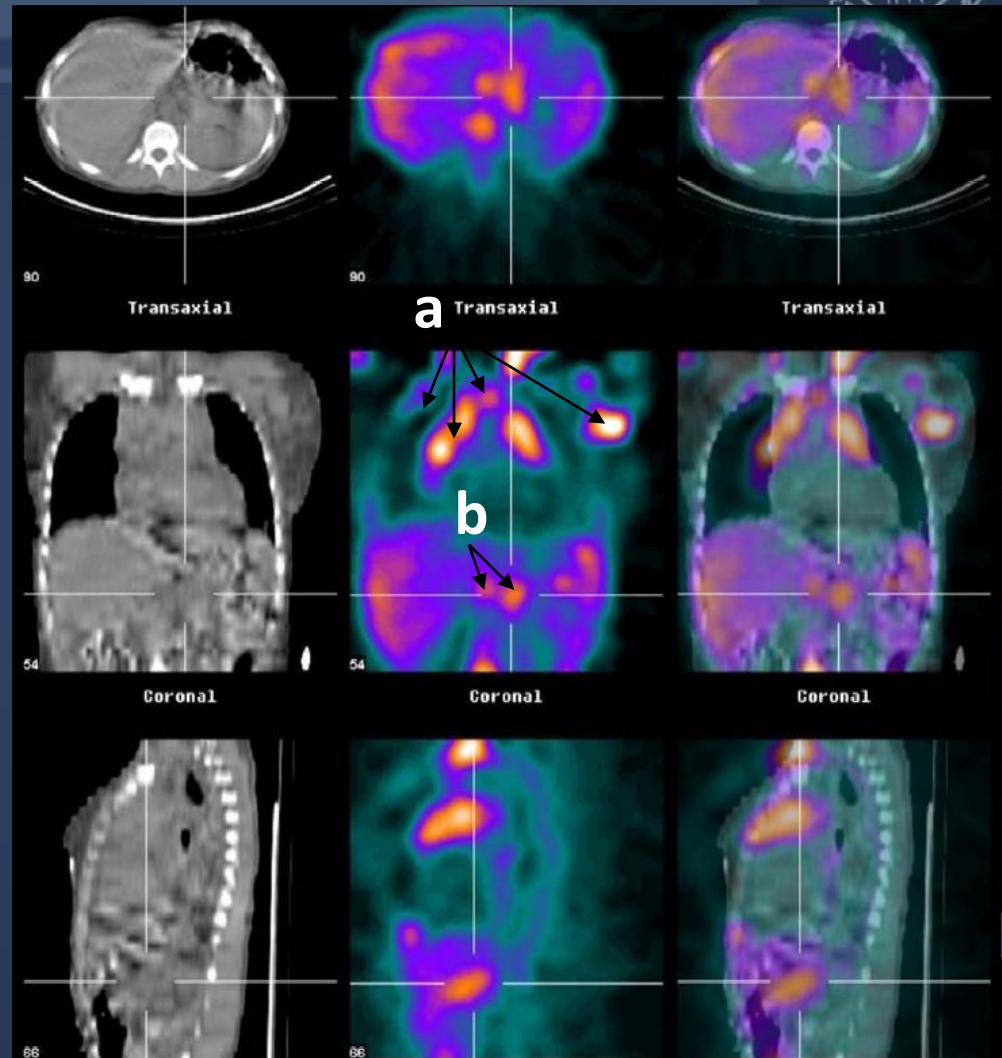
Planar Vs SPECT CT



Ga-67 SPECT/CT : Staging HD

Abnormal Ga uptake (a) in supraclavicular, axillary, Paratracheal, parahilar and para-aortic lymph nodes and in the spleen, at lesion sites corresponding to those observed on CT.

The para-aortic lymph node uptake (b) combined with CT findings allowed the diagnosis of subdiaphragmatic disease and excluding bowel activity.



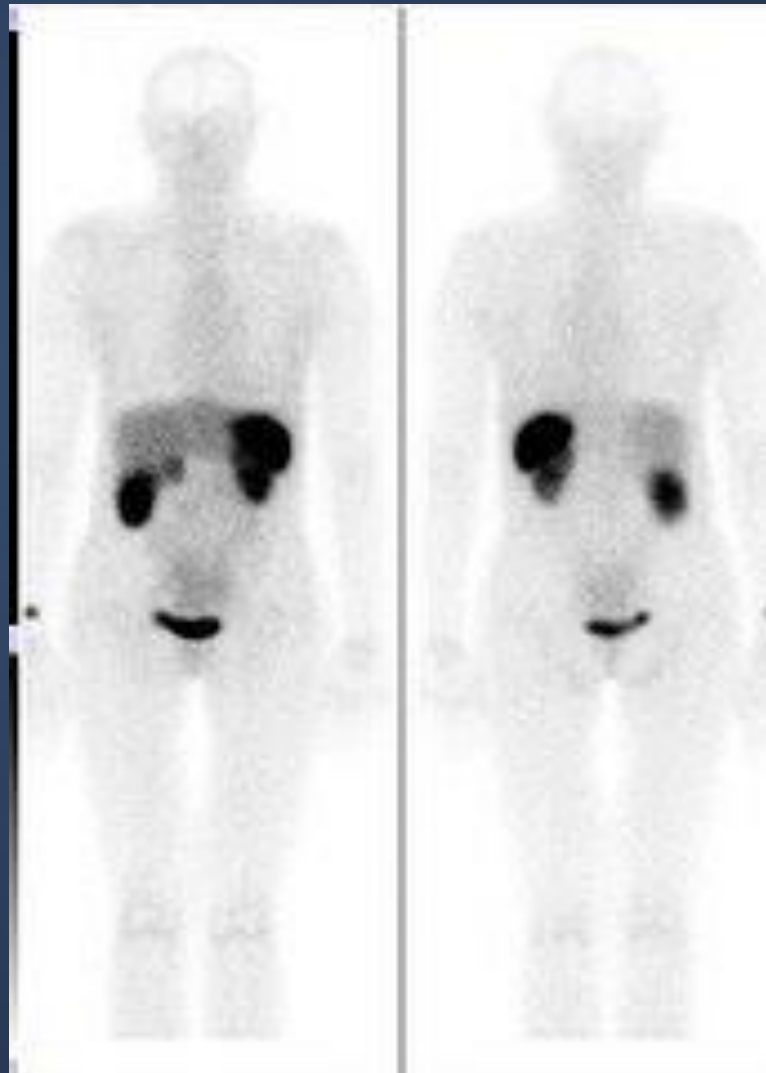
Neuroendocrine Tumors



- In-111 octreoscan.
- I123 MIBG Scan.

Somatostatin Receptor Imaging Indium-111 Octreoscan

NORMAL STUDY



In - 111 octreoscan

Insulinoma

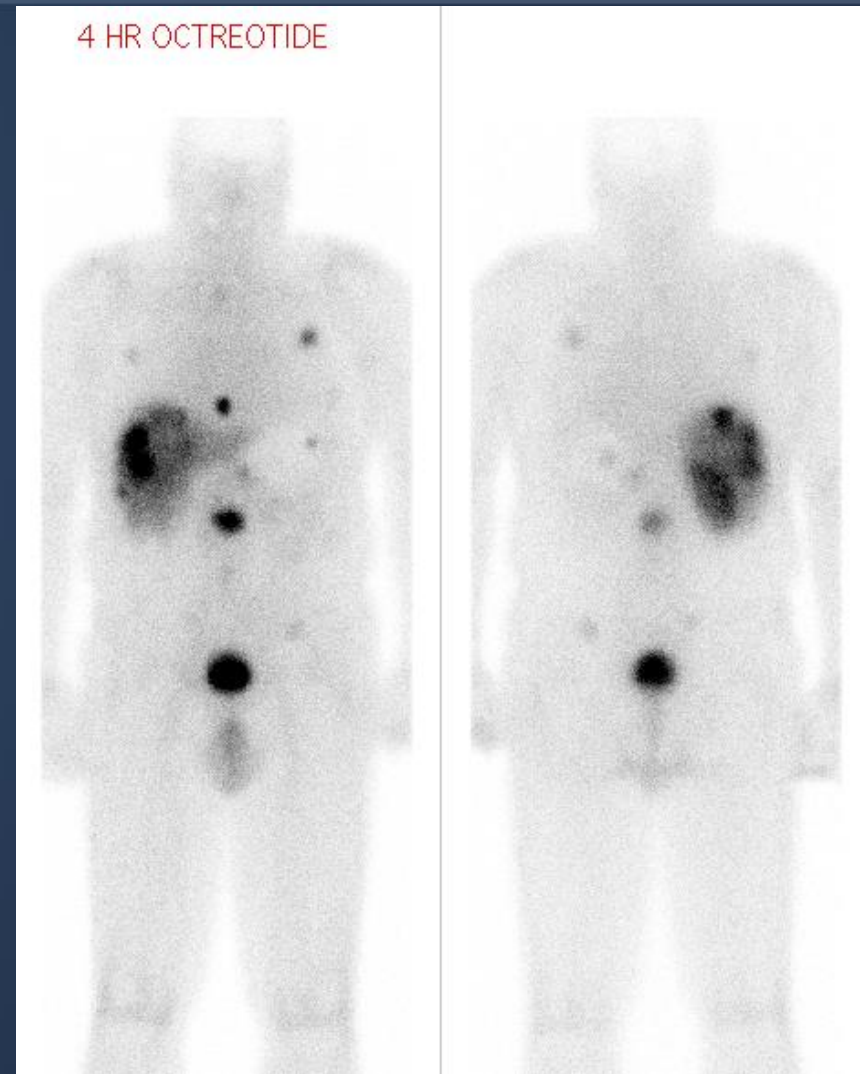


Clinical History

The patient is a 66-ys male with insulinoma, now being evaluated for evidence of recurrent and/or metastatic disease.

Findings :

Multiple lung, mediastinum , liver and abdominal metastases.





I123 MIBG Scan

- MIBG : **M**eta **I**odo **B**enzyl **G**uanidine
- Is a nor adrenaline analog
- Localizes in adrenergic tissues: catecholamines producing tumors and their metastases.
- Patient preparation: stop drugs interfering with MIBG uptake. Lugols solution to protect thyroid gland

I123 MIBG Scan

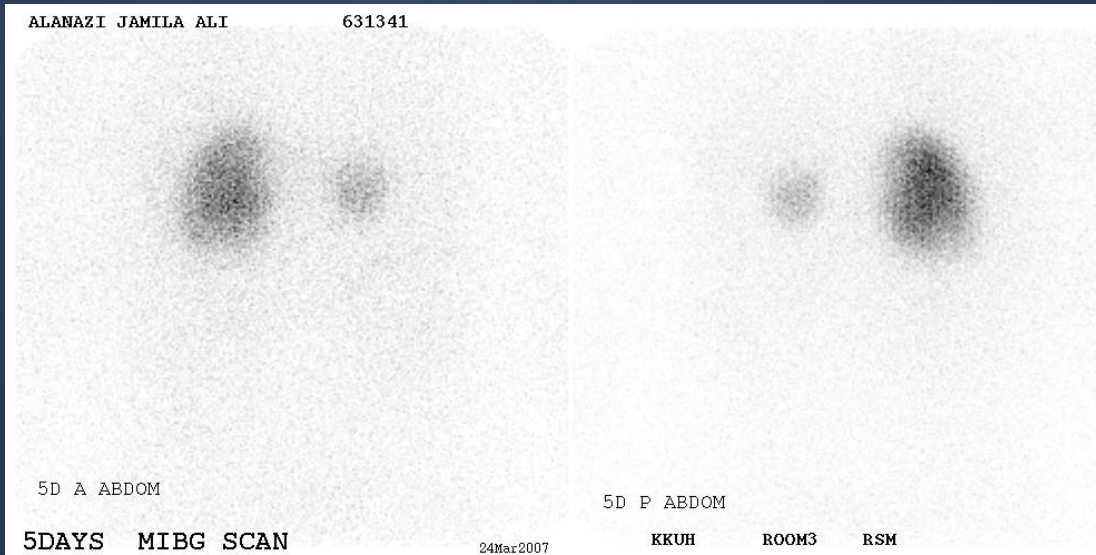
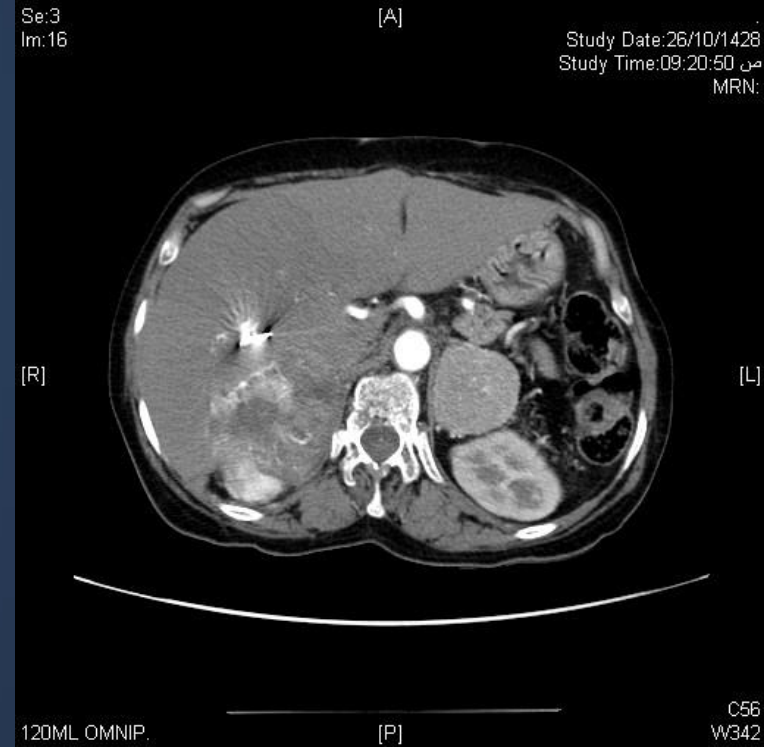
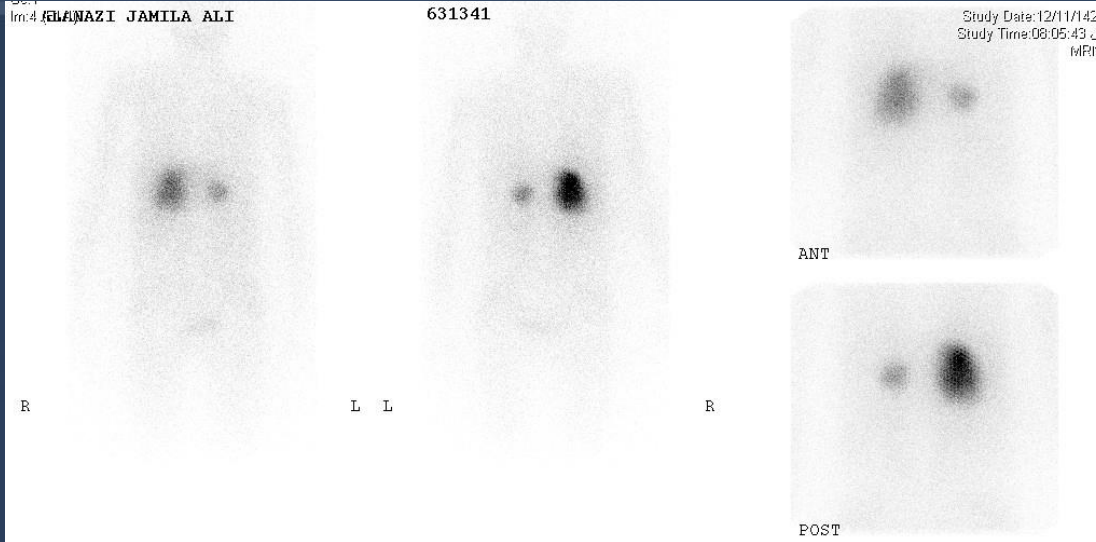
Indications



- Pheochromocytoma
- Paraganglioma
- Insulinoma
- Neuroblastoma
- Medullary thyroid carcinoma
- Carcinoid tumors

MIBG In Pheochromocytoma

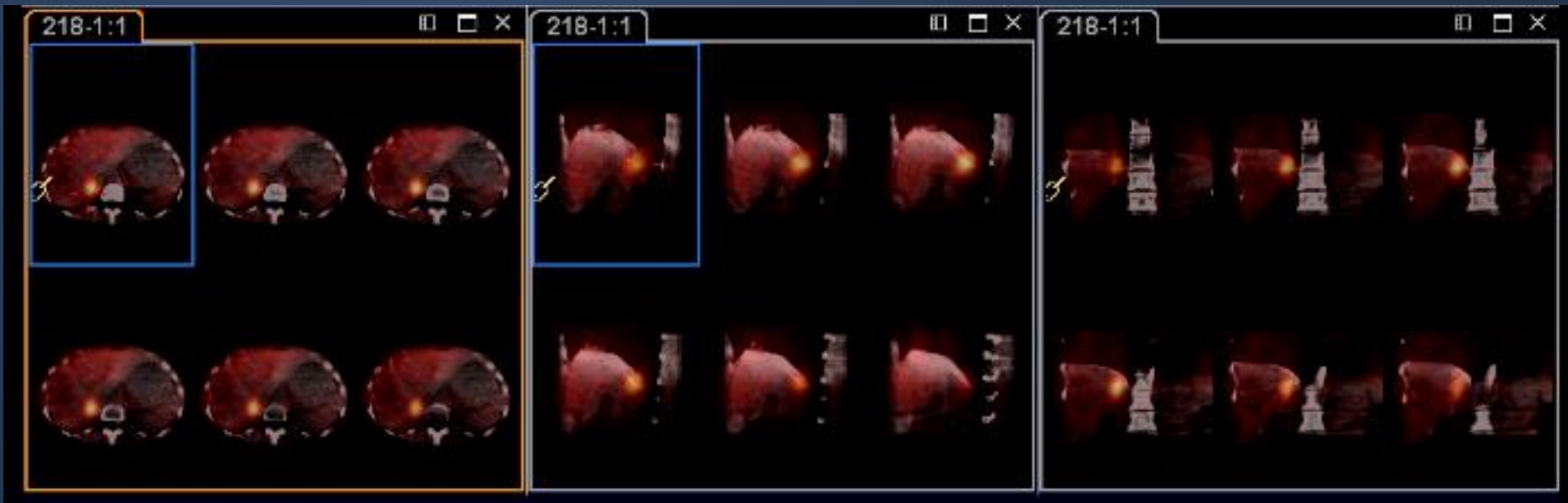
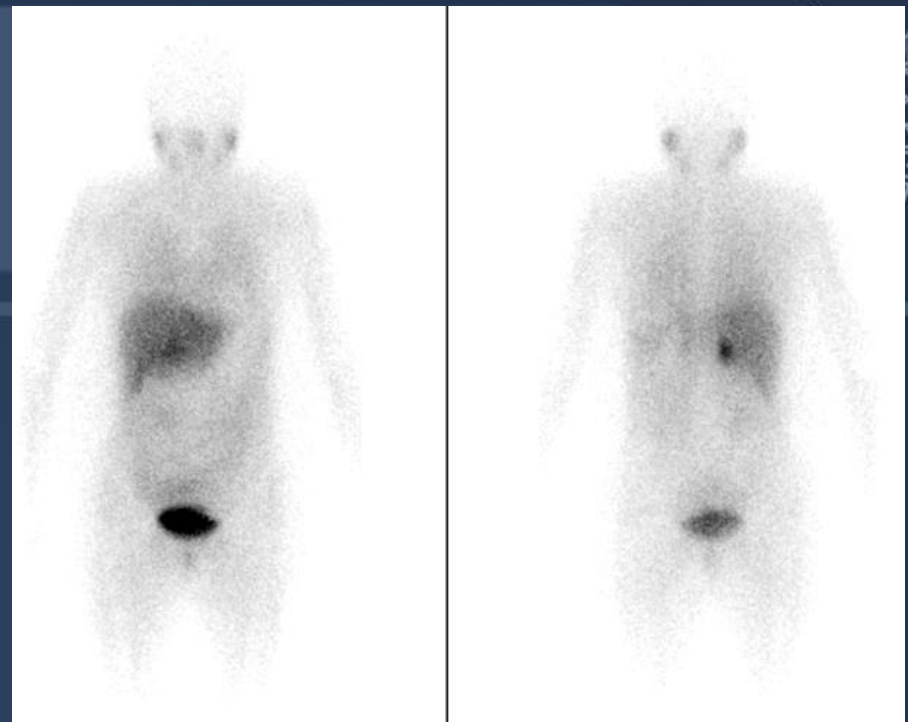
Bilateral Disease



Pheochromocytoma

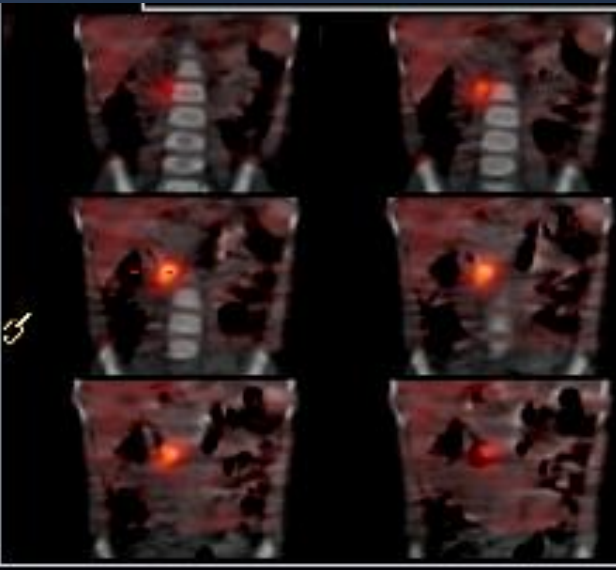
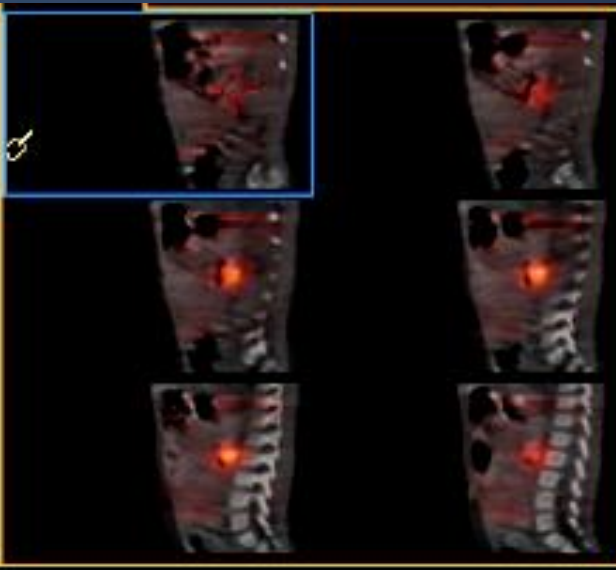
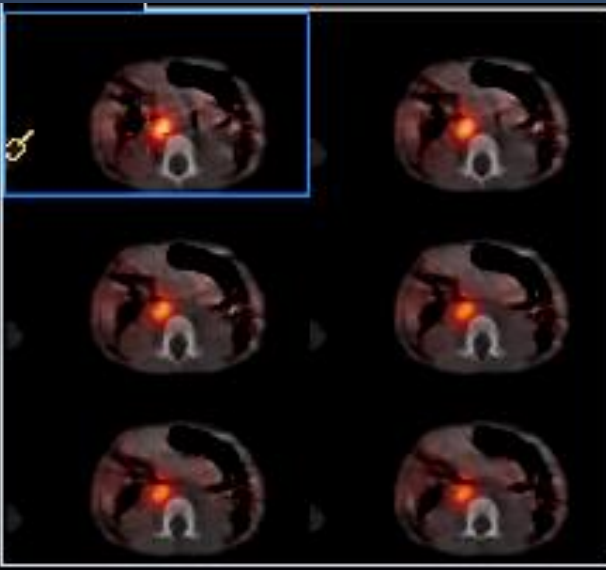
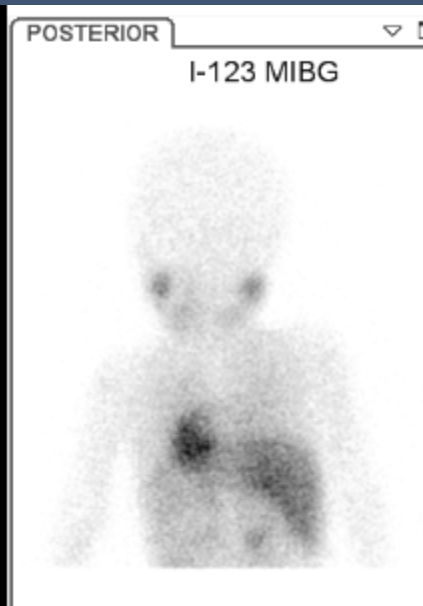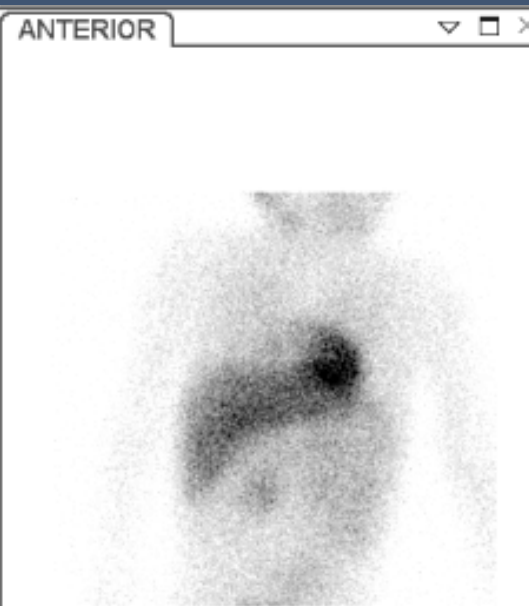
Planar Vs SPECT CT

A 41 years old female patient is with 2ndary hypertension. Right adrenal mass.
?Pheochromocytoma.



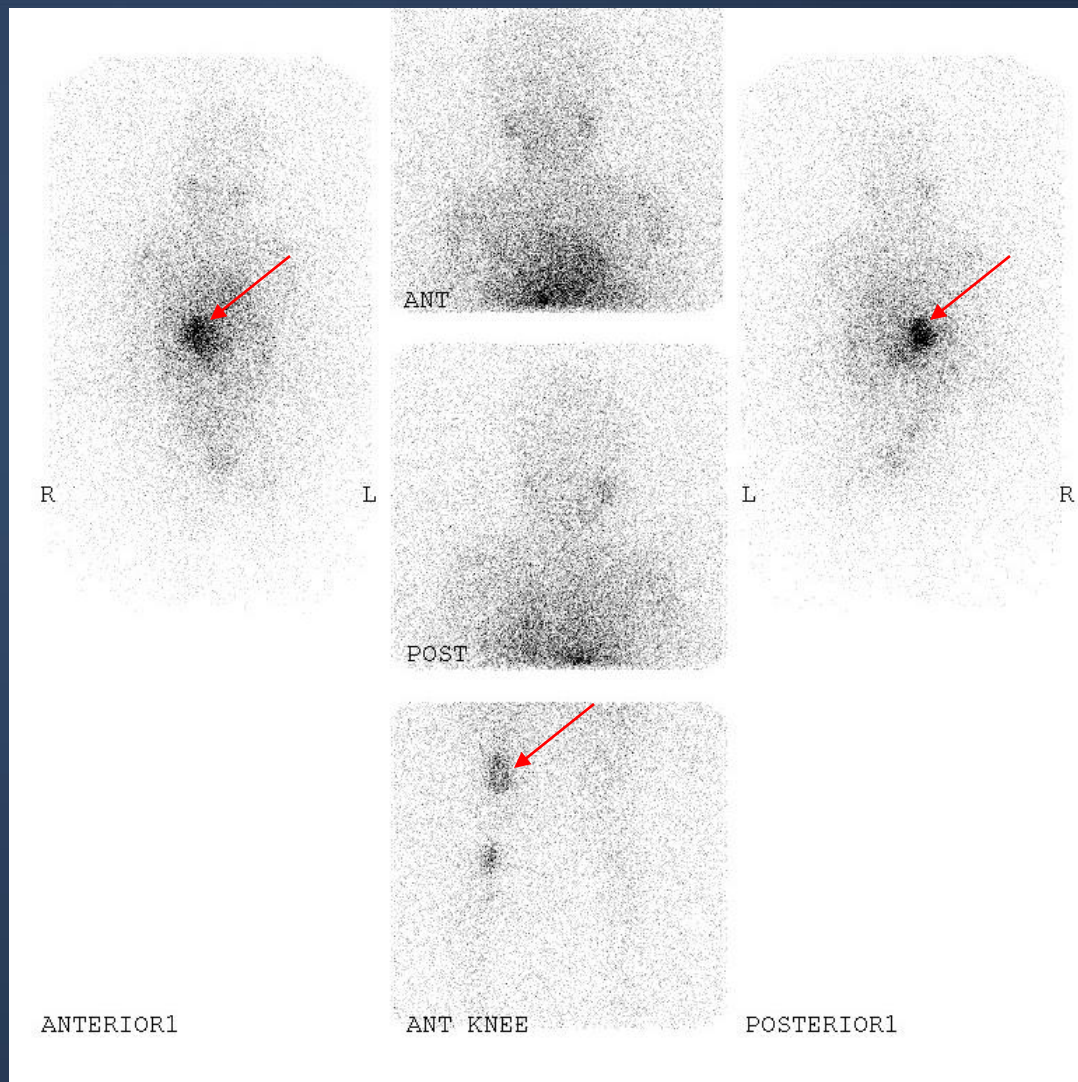
Neuroblastoma

Planar Vs SPECT CT



I131 MIBG Total body scan

1ry neuroblastoma /bone mets



THYROID METASTASES STUDY (I-123 or I-131 as Sodium Iodide)



Indications

- Detection and localization of persistent or recurrent local or distant functioning thyroid cancer

Patient Preparation

- **Stimulation of potentially functioning thyroid tissue:**
 - A. Inject recombinant human thyrotropin on 2 consecutive days and administer the iodine on the third day .**
 - B. Withdraw thyroid replacement hormones :**
 1. Thyroxine (T-4) for at least 4 weeks.
 2. Triiodothyronine (T-3) for at least 10 days.
- **The patient must not have had i.v iodinated contrast material (IVP, CT with contrast, myelogram, angiogram) for at least 3 weeks .**
- The patient should be NPO for at least 4 hours prior to radiopharmaceutical administration and for at least 1 hour afterwards .

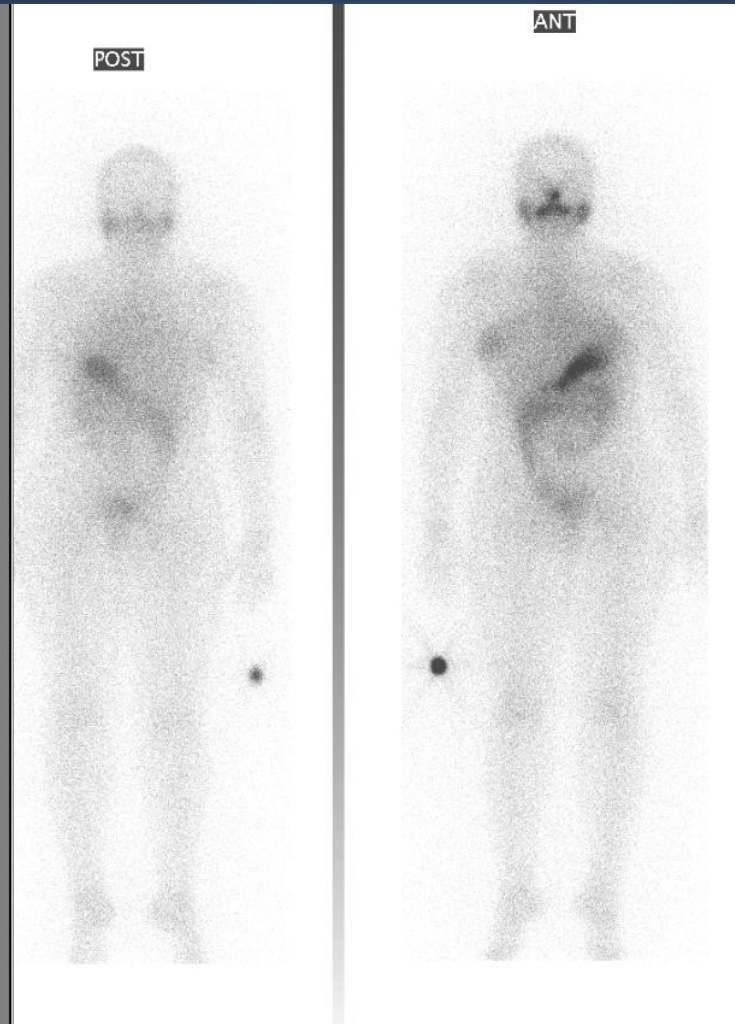
Tracer , Dose, & Technique of Administration

- Radiopharmaceutical: Oral administration
 - a. I-123 as sodium iodide : 2 mCi
 - b. I-131 as sodium iodide : 2-10 mCi

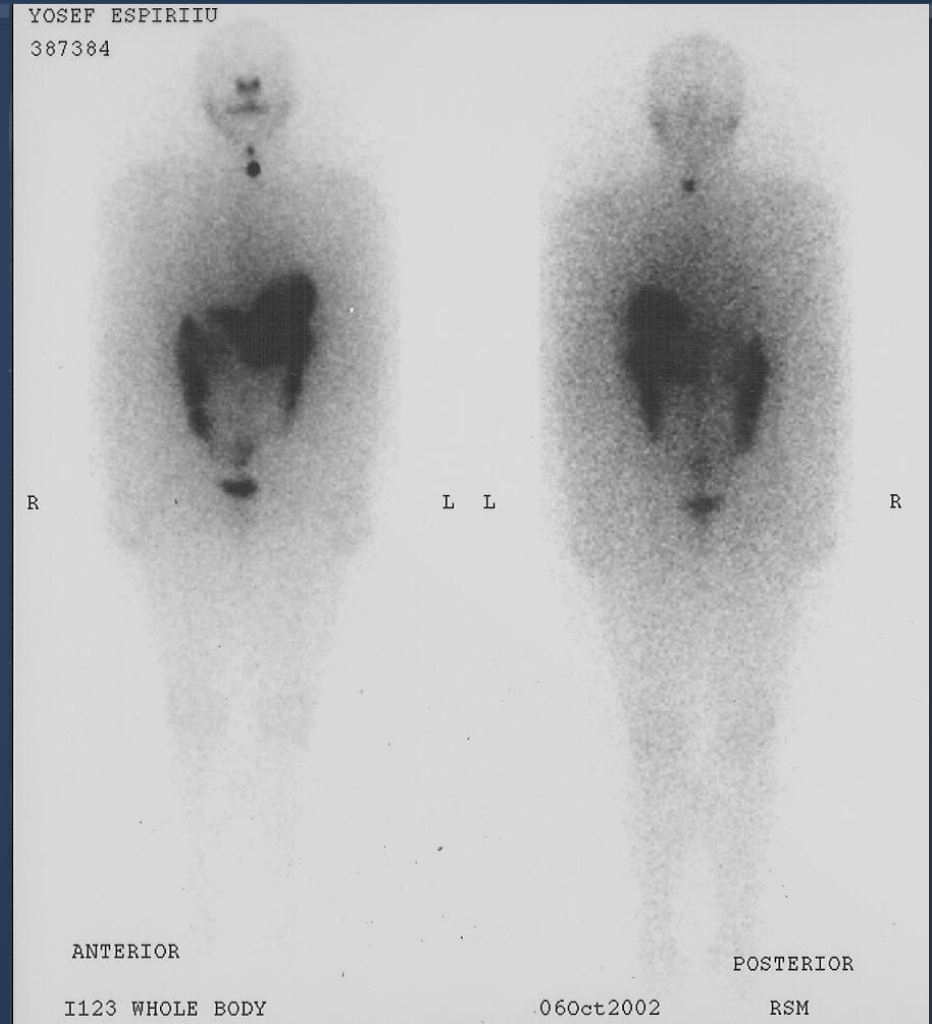Imaging using Gamma camera : Whole body scan

Thyroid Cancer

I-123 WB Scan



Negative I-123 WB Scan

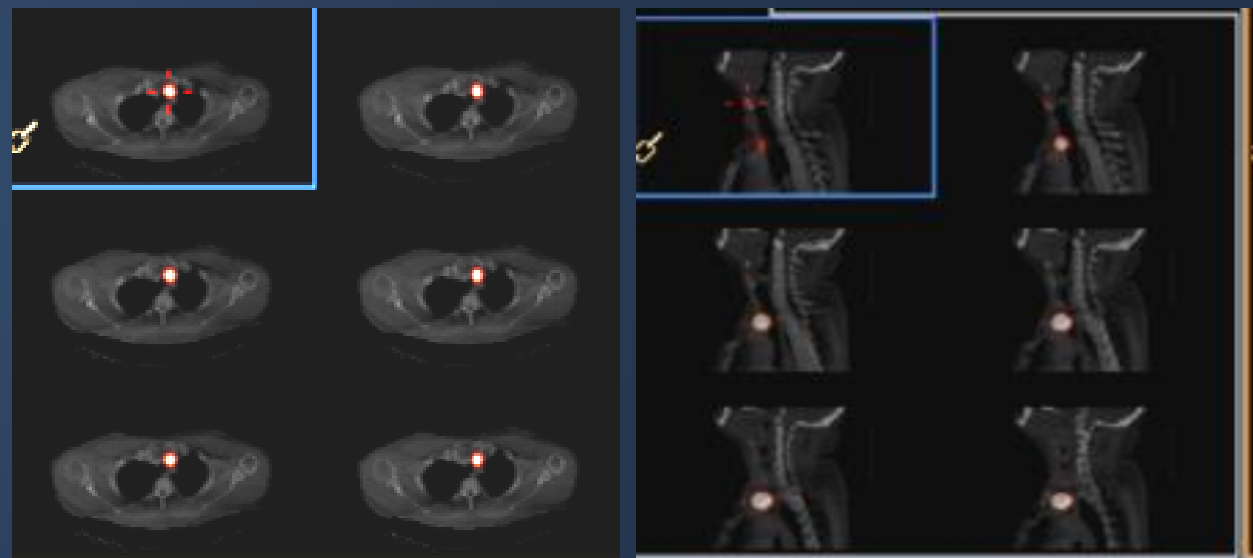
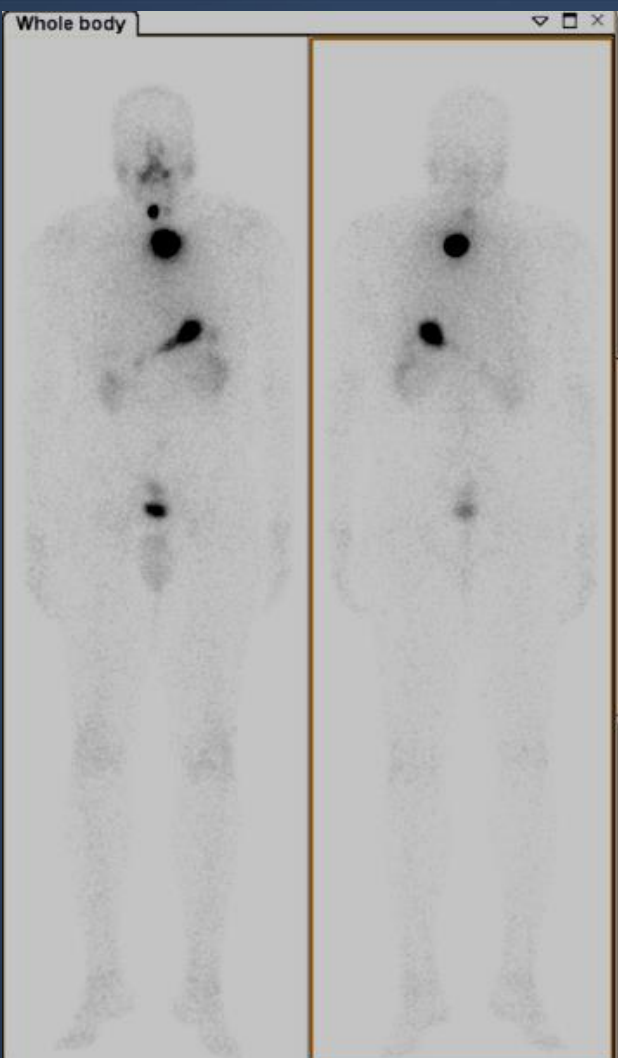


I-123 WB Scan : Post operative Thyroid remnants

I-123 WB Scan

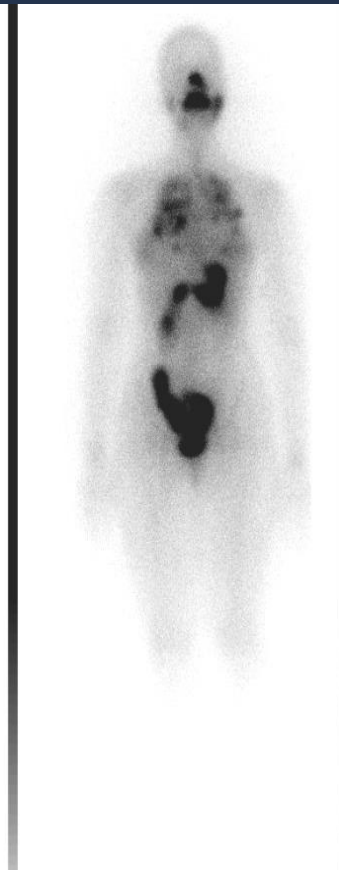
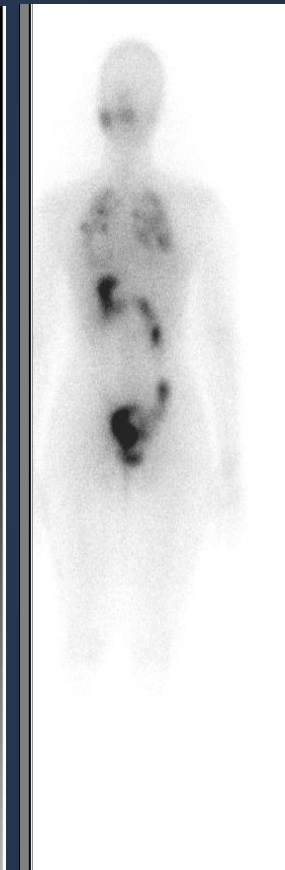
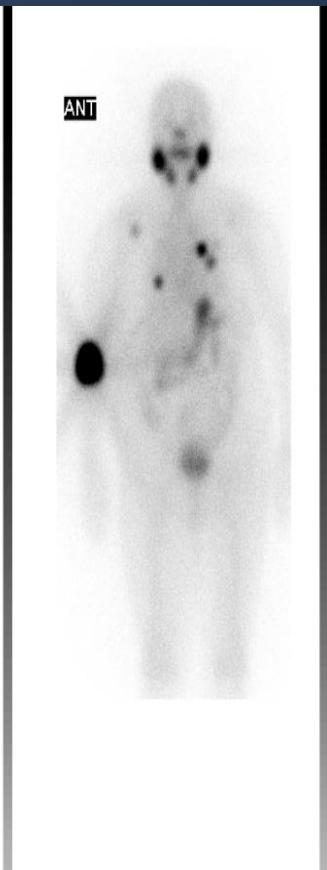
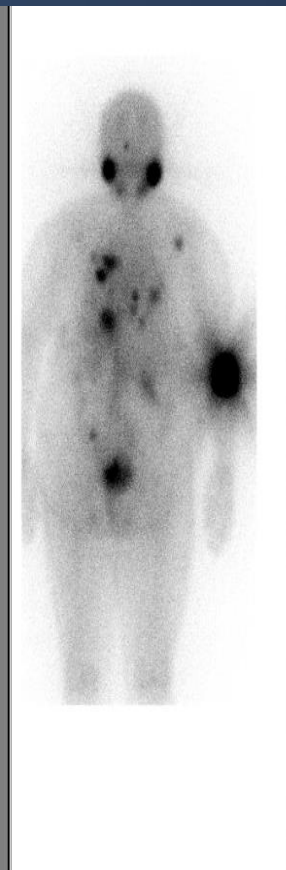
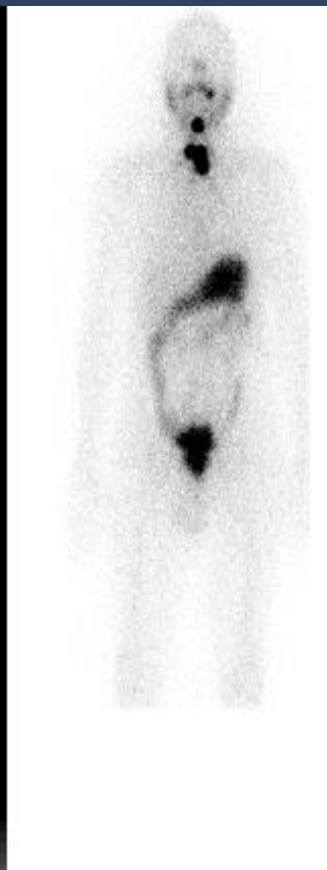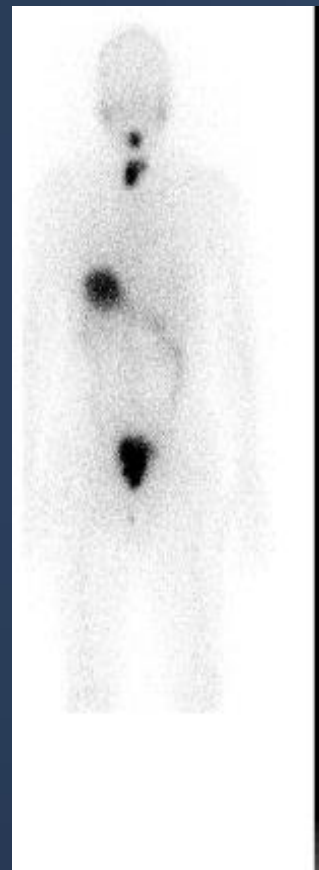
Post operative Thyroid remnants

Planar Vs SPECT CT



THYROID METASTASES STUDY

(I-123 or I-131 as Sodium Iodide)



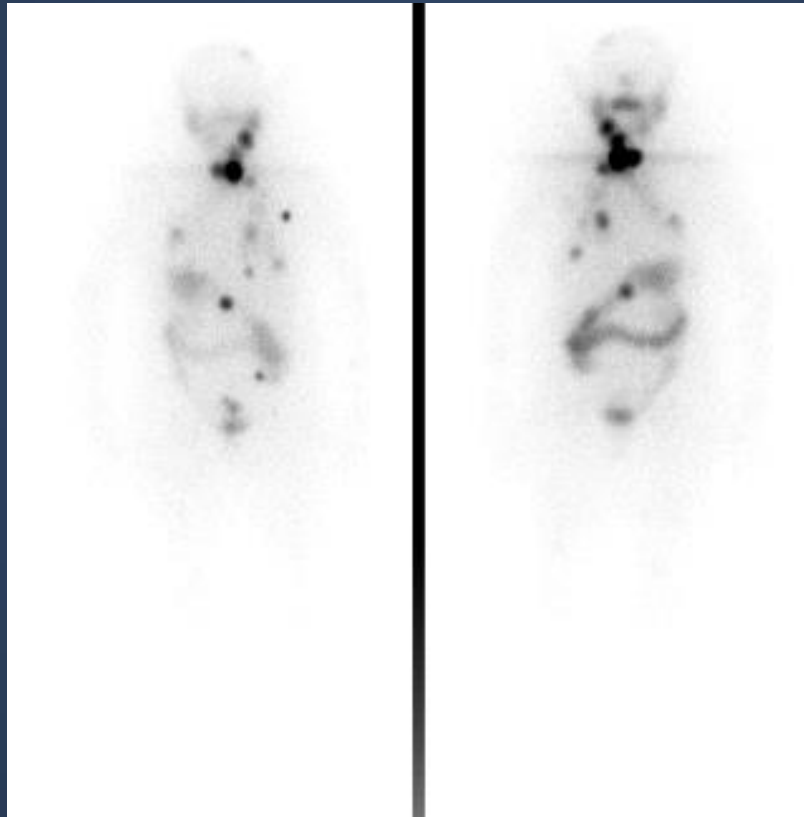
Local Recurrence

Bone Metastases

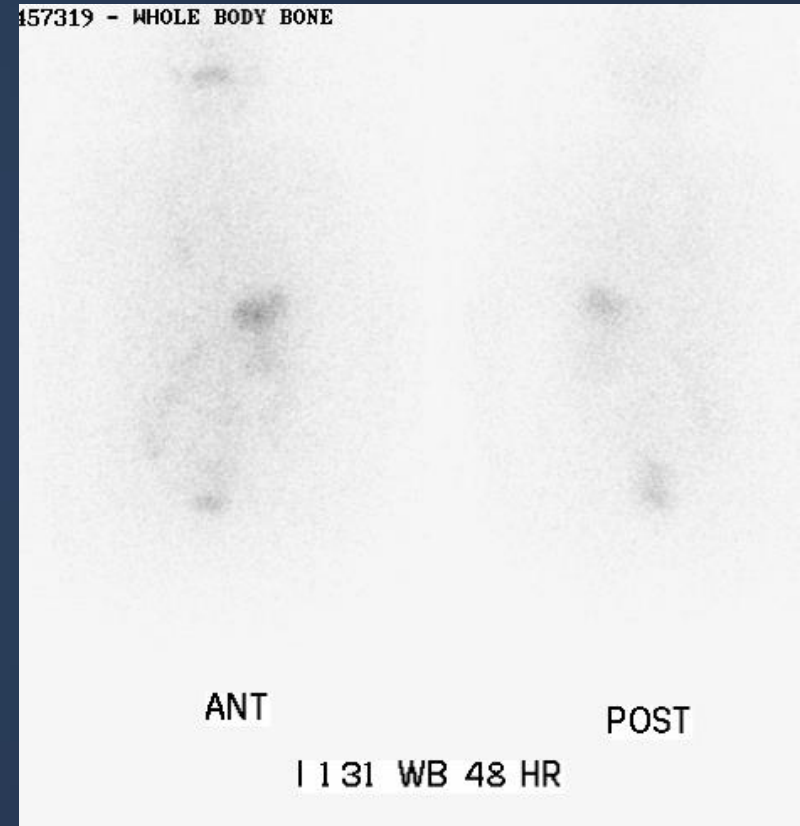
Lung Metastases

Thyroid Cancer

I-131 Pre & Post therapy



Dec04

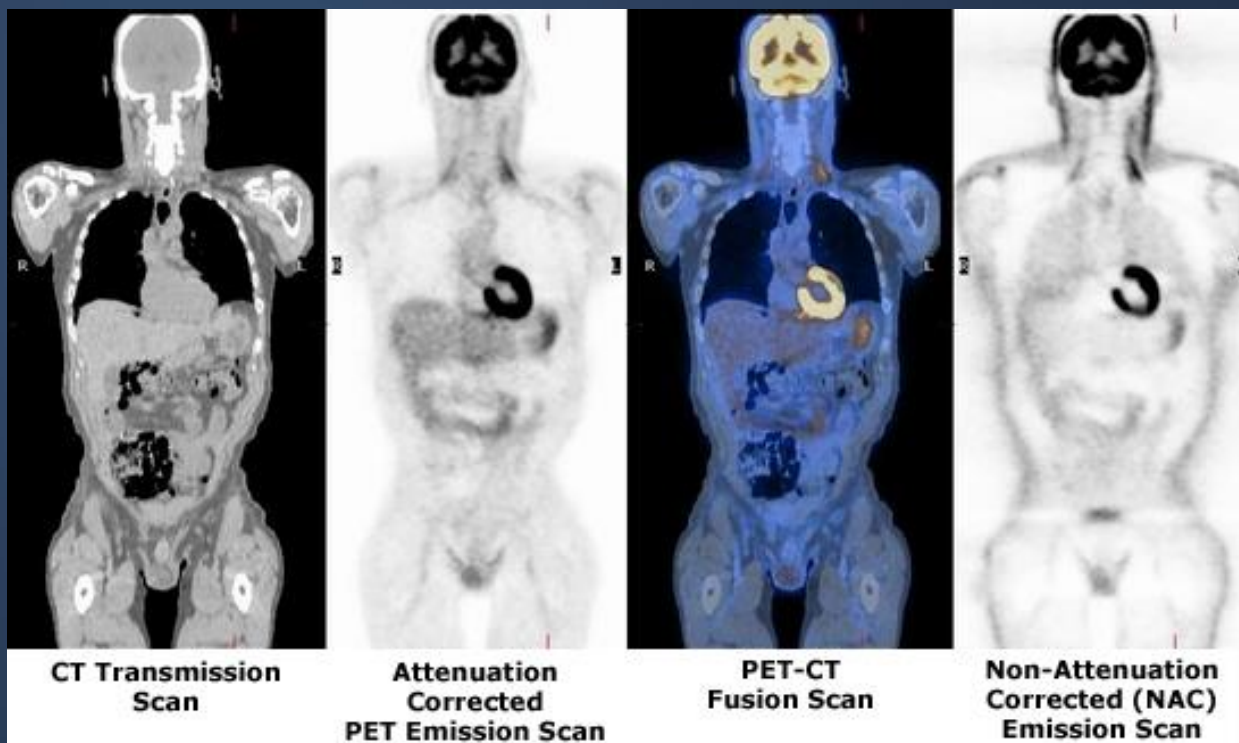


March06

Onco PET (PET and PET CT)

What is PET - CT

- PET : Positron Emission Tomography.
- CT : Computerized Tomography.
- PET-CT is the fusion of functional and anatomic information acquired almost simultaneously from which we are able to visualize form and function.



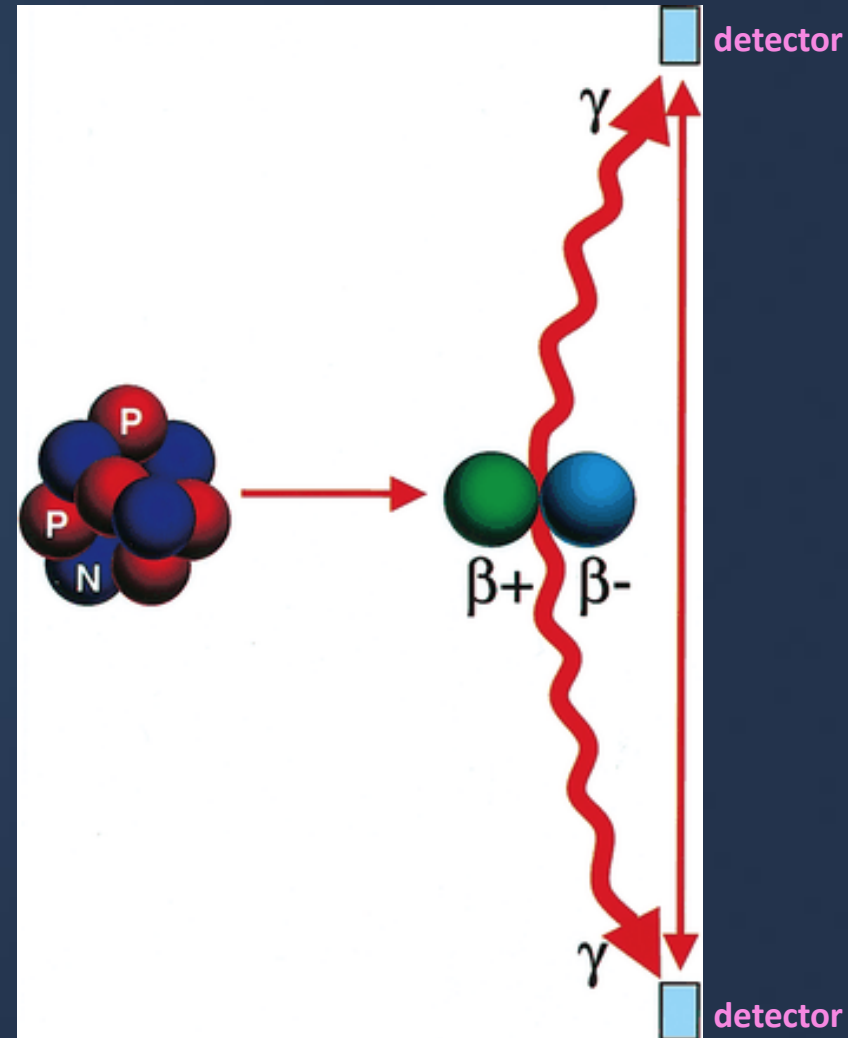
PET CT = PET + CT = Function + Form

PET : How it is performed...?

Positron emitters (e.g. F18) labelled with biologically active natural compounds such as oxygen, carbon or glucose give intravenously and reacting in the body identically to their non-radioactive counterparts.

Positrons are emitted from F18 and react with tissue electrons.....Anihilation occurs...

Two photons 511 kev each in opposite direction are emitted and detected by PET SCANNER giving an image of the normal and abnormal distribution of tracer in the body.



Positron Emitting Isotopes



I. Cyclotron produced isotopes:

<u>Isotope</u>	<u>T/2</u>
Oxygen-15	2 min
Nitrogen-13	10 min
Carbon-11	20 min
Fluorine-18	110 min

II. Generator produced isotopes:

<u>Parent</u>	<u>T/2</u>	<u>daughter</u>	<u>T/2</u>
Strontium-82	25 days	Rubidium-82	75 seconds
Zin-62	9.3 hrs	Copper-62	10 min.
Germanium-68	288 days	Gallium-68	68 min

FDG : Fluoro-2-deoxy-D-Glucose

Uptake Mechanism



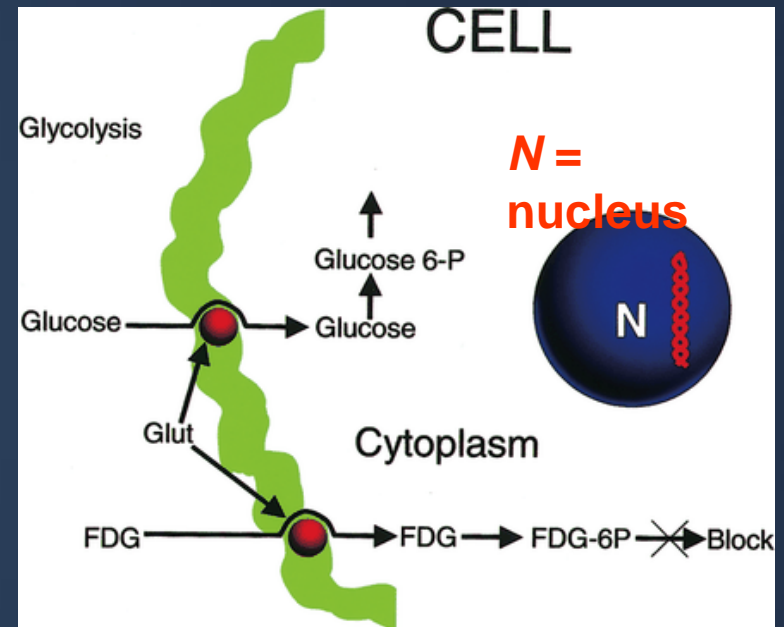
FDG is a glucose analogue used to assess glucose metabolism.

FDG transported from intravascular space to the cells by the same mechanism as the glucose.

In the cell, hexokinase acts on both FDG and glucose to form:

- FDG-6-phosphatase (FDG-6-PO₄-)
- Glucose-6-phosphatase.

FDG-6-PO₄- cannot progress further into glucose metabolism and remains trapped intracellularly in proportion to glycolytic rate of the cell.



In tumors, there is high rate of glycolysis compared to normal cells as well as higher level of hexokinase.

FDG is labeled with F18

FDG : Normal distribution

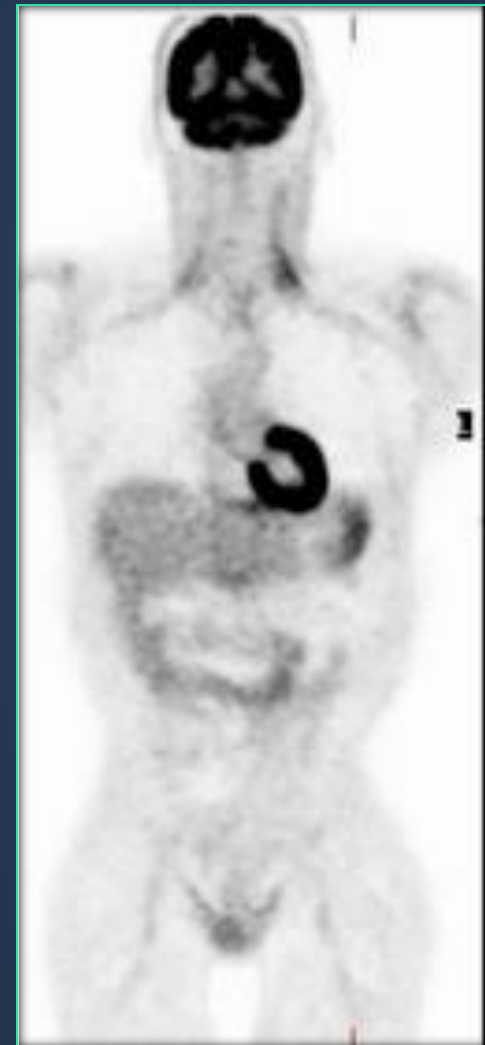
Brain & heart --- High uptake

Liver --- Less uptake

Kidneys --- Unlike glucose, FDG is excreted with urine

GI --- Mild clearance, faintly seen

Muscles --- Low, increase with exercise



FDG in Oncology



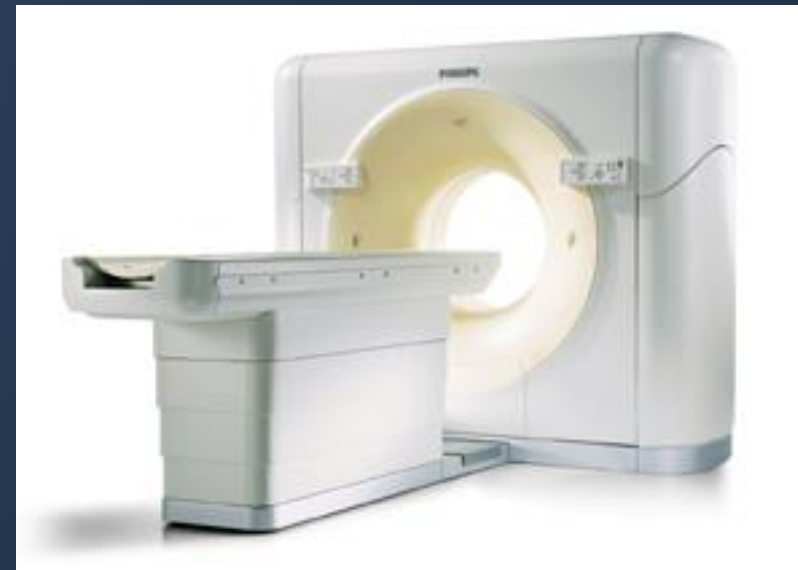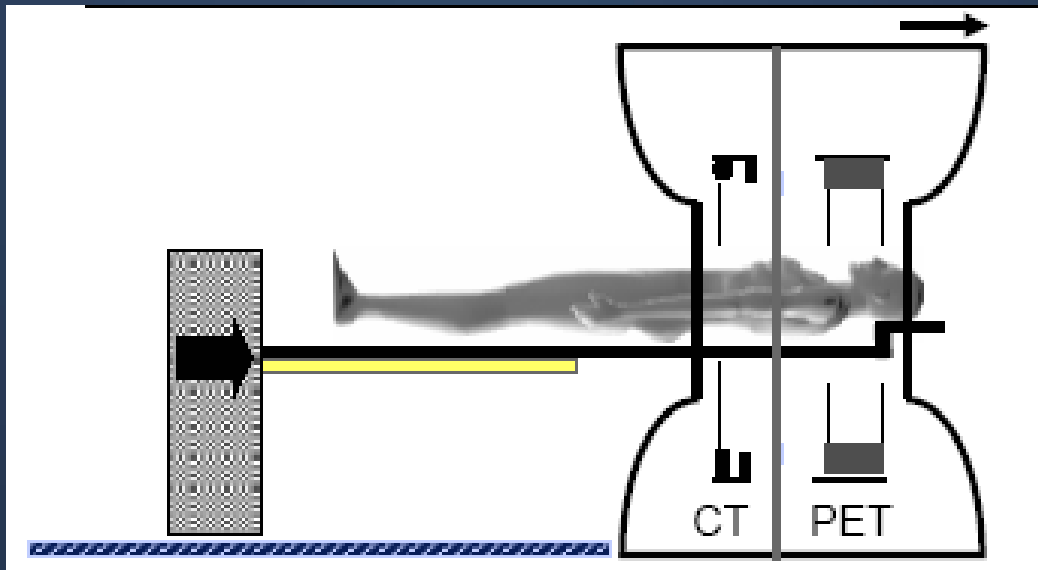
- Tumors do not have a blood tumor barrier
- FDG transport into tumors occurs at a *higher* rate than in the surrounding normal tissues.
- FDG is de-phosphorylated and can then leave the cell.
- The de-phosphorylation occurs at a *slower* rate in tumors.
- **Applications of FDG**
 - Locating unknown primaries
 - Differentiation of tumor from normal tissue
 - Pre-operative staging of disease (lung, breast, colorectal, melanoma, H&N, pancreas)
 - Recurrence vs necrosis
 - Recurrence vs post-operative changes (limitations with FDG)
 - Monitoring response to therapy

PET CT

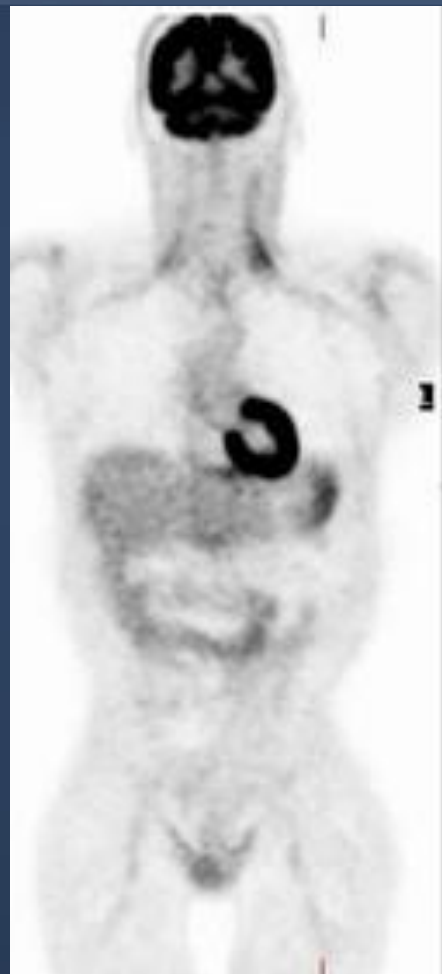
F18 FDG IMAGING PROTOCOL



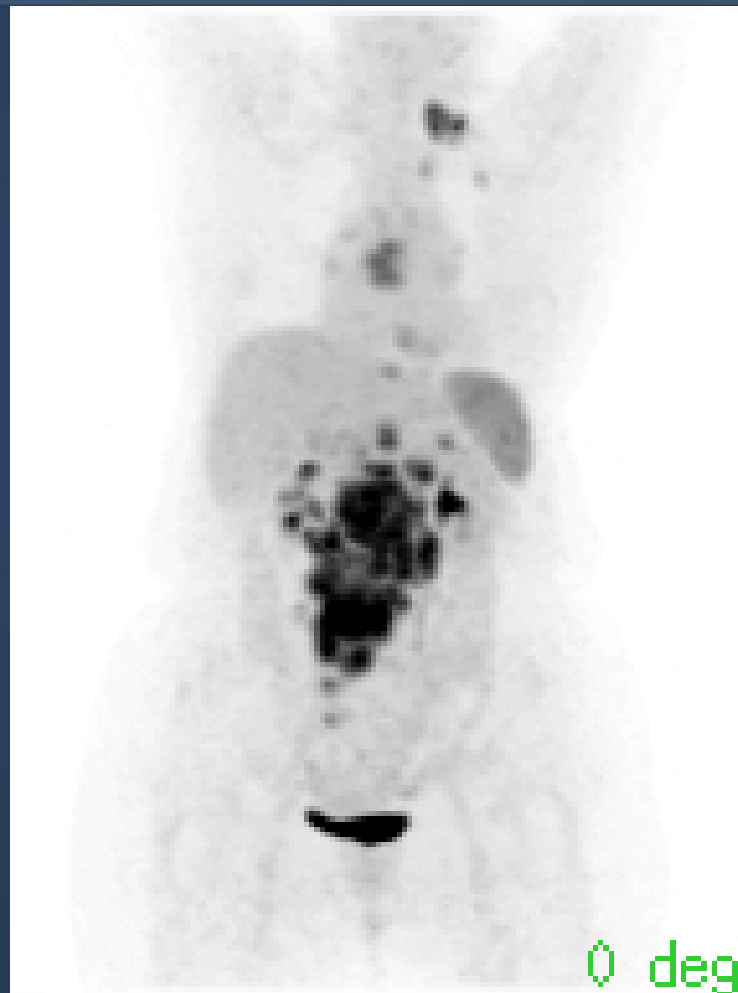- ❖ **Fasting** : 4 – 6 hours
- ❖ **Dose** : Inject 10 mCi **F18 FDG**
- ❖ **Wait (uptake phase)**: 45 -60 min then scan
- ❖ **Scanning time** : 30 min to complete PET CT study
- ❖ **SUV** : Standard uptake value (N:0.5-2.5 and Tumors > 3.0)



FDG PET

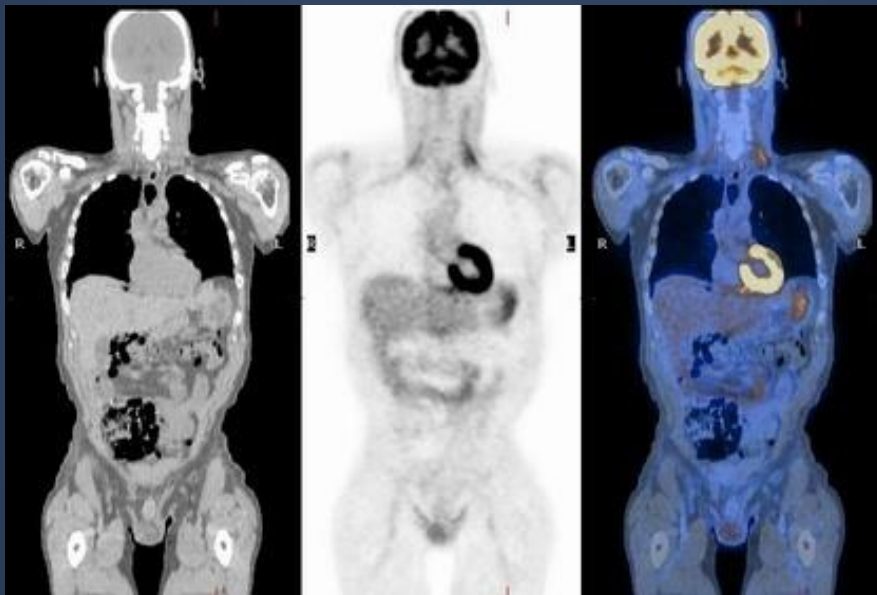


FDG PET : Normal

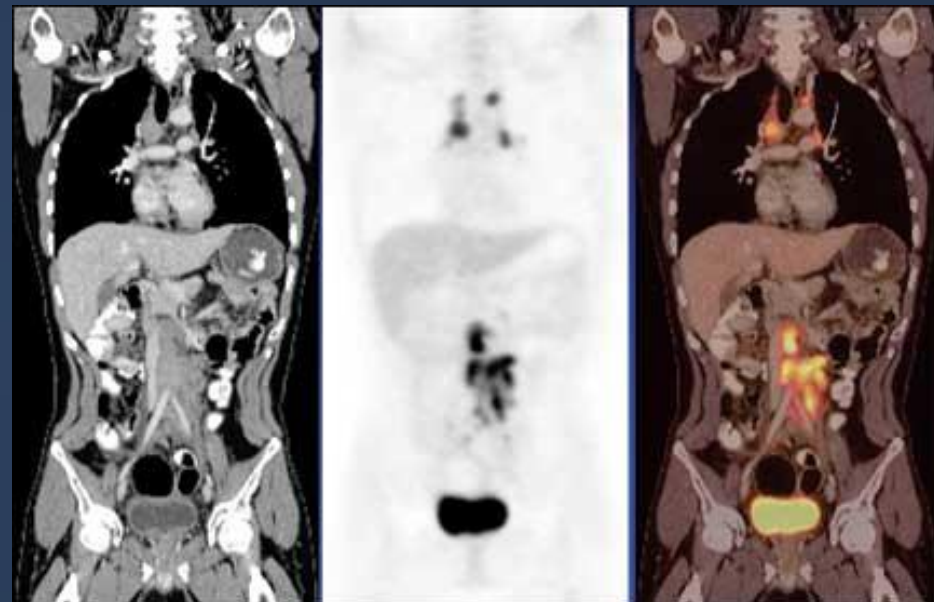


FDG PET : Staging of NHL

FDG PET-CT

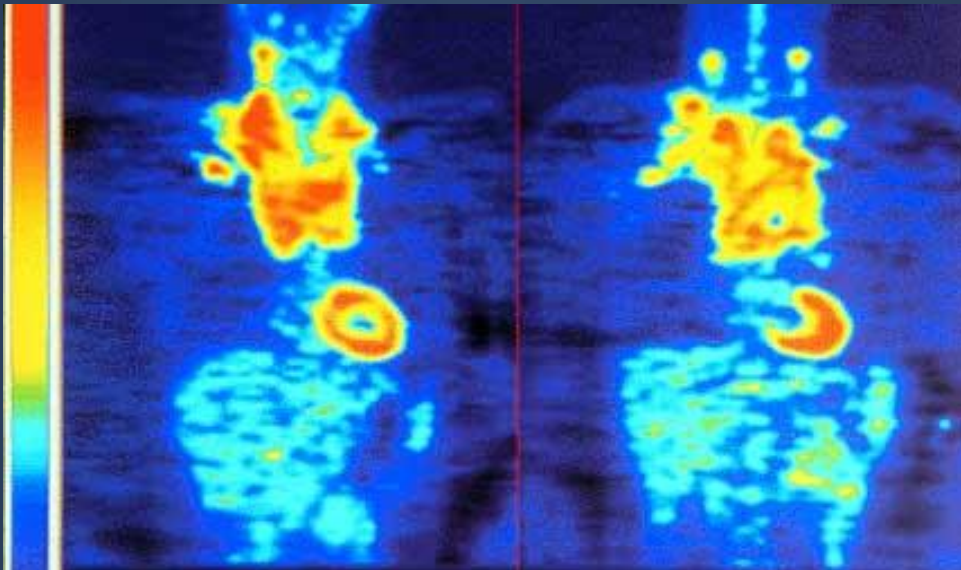


FDG PET-CT
Normal

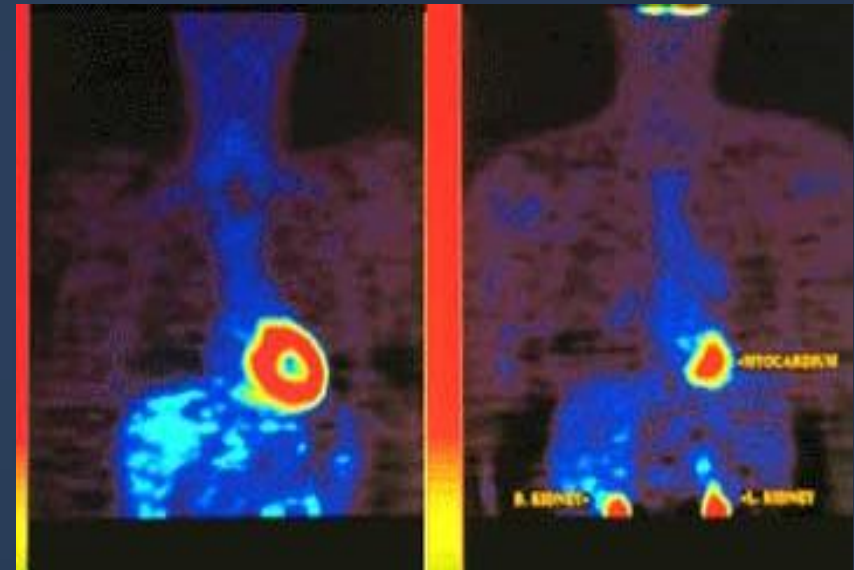


FDG PET-CT
Staging Of Lymphoma

Assessment of therapy response FDG PET in HD



Baseline

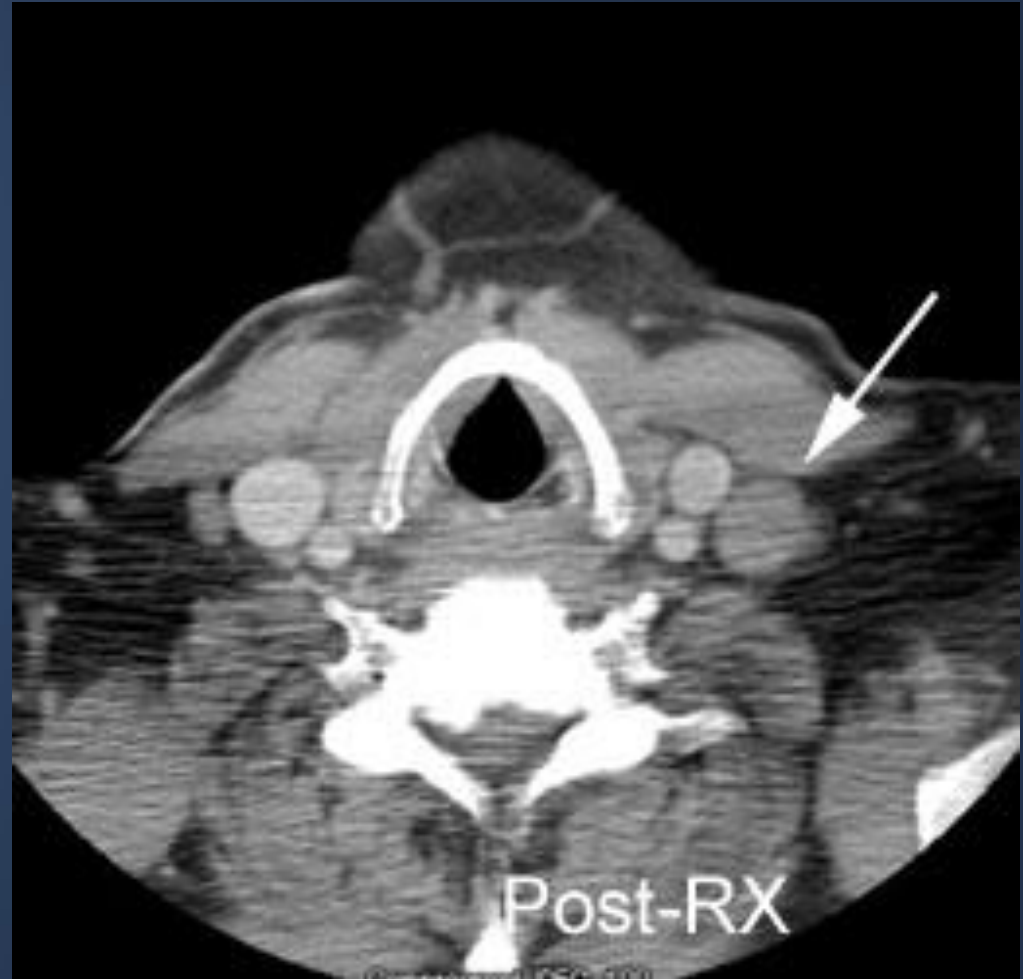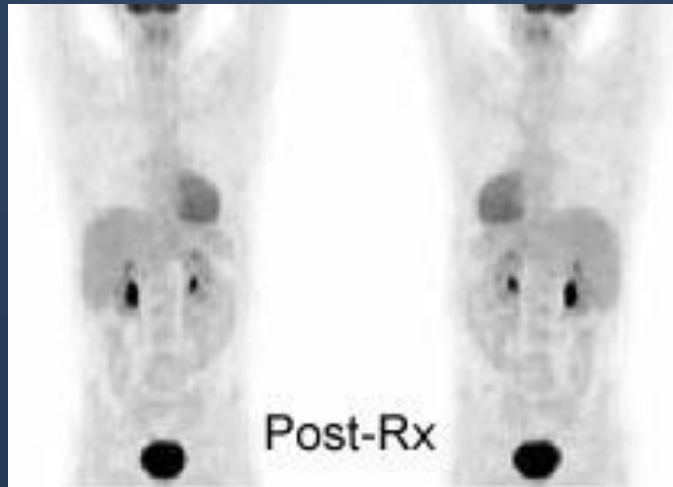
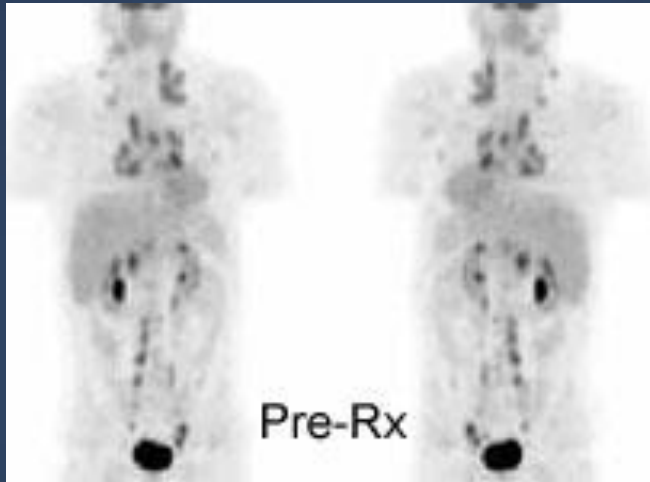


Post therapy

A 22 years old male patient with Hodgkin's lymphoma. Six months after chemotherapy, CT scan showed bilateral hilar abnormalities. FDG-PET scan did not show any activity in described CT changes.

FDG in Non-Hodgkin's lymphoma

Response to therapy



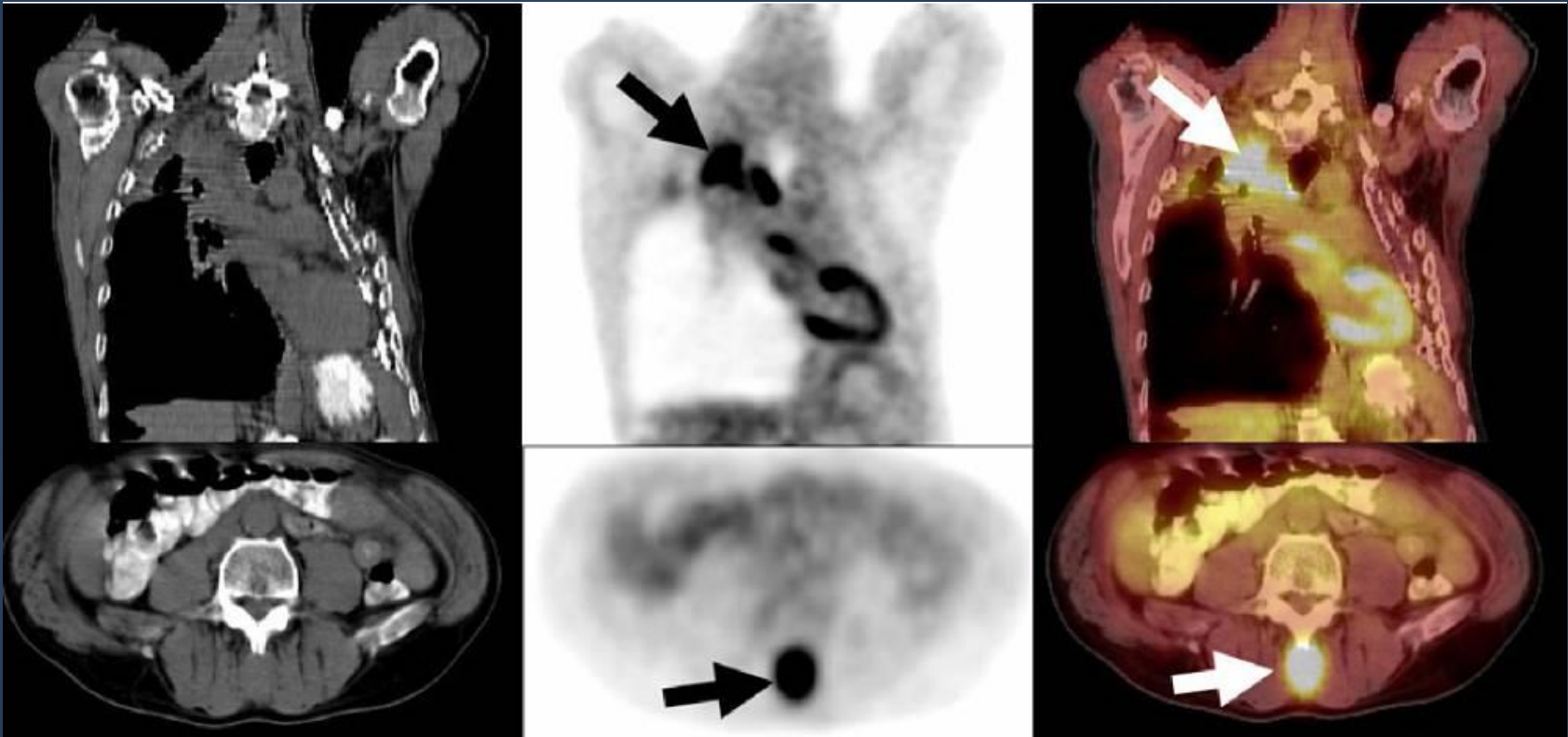
PET CT In Lymphoma



	Sensitivity	Specificity
	(%)	(%)
CT	61	89
FDG-PET	78	98
FDG-PET and CT	91	99
FDG-PET/CT	96	99

PET CT Lung Cancer

Staging



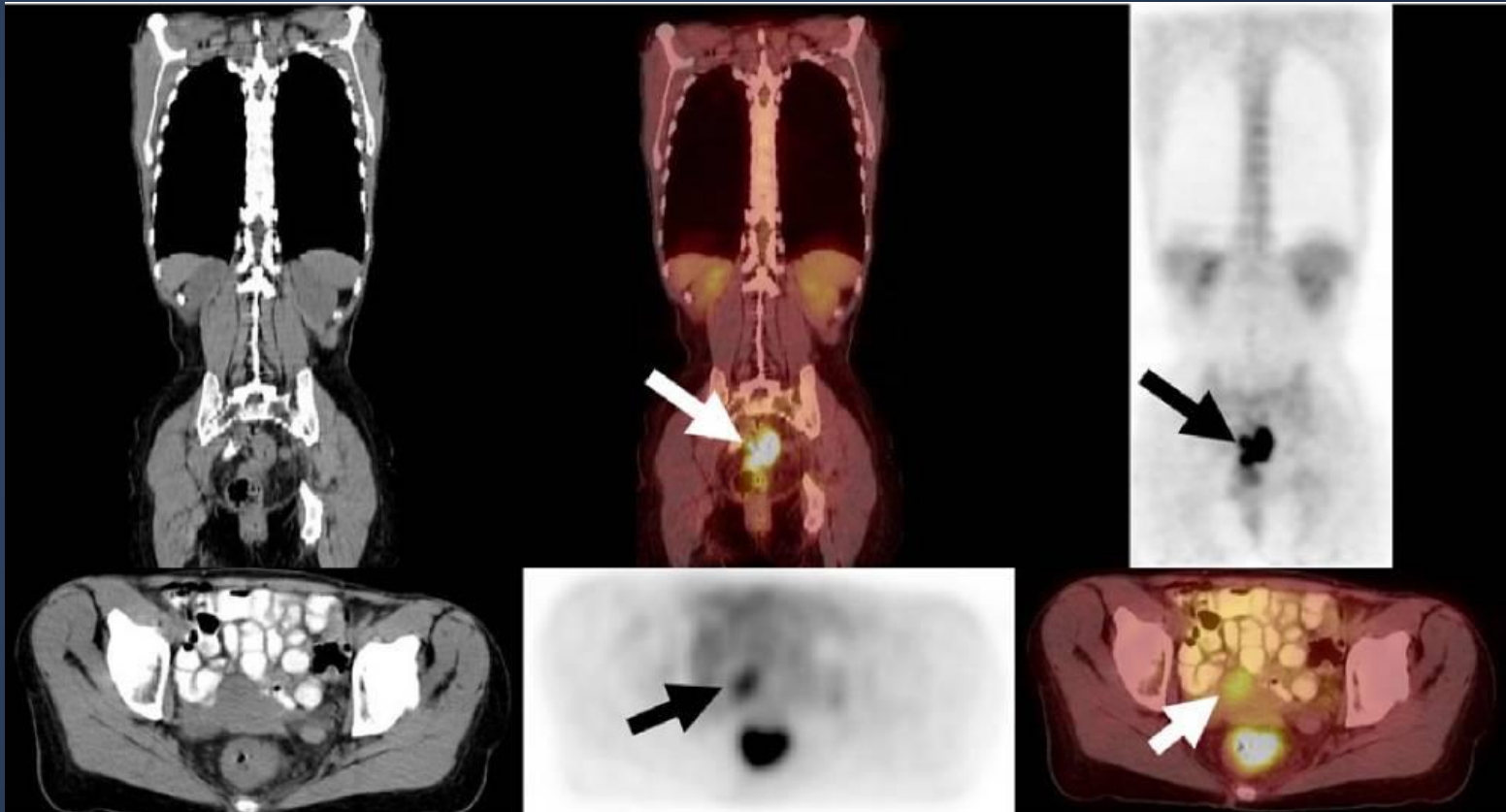
FDG avid soft tissue mass associated with a destructive L5 spinous process consistent with metastatic deposit (arrow).

FDG PET CT in Solitary Pulmonary Nodule (SPN)

Sensitivity : 82 – 100 %

Specificity : 67 – 100 %

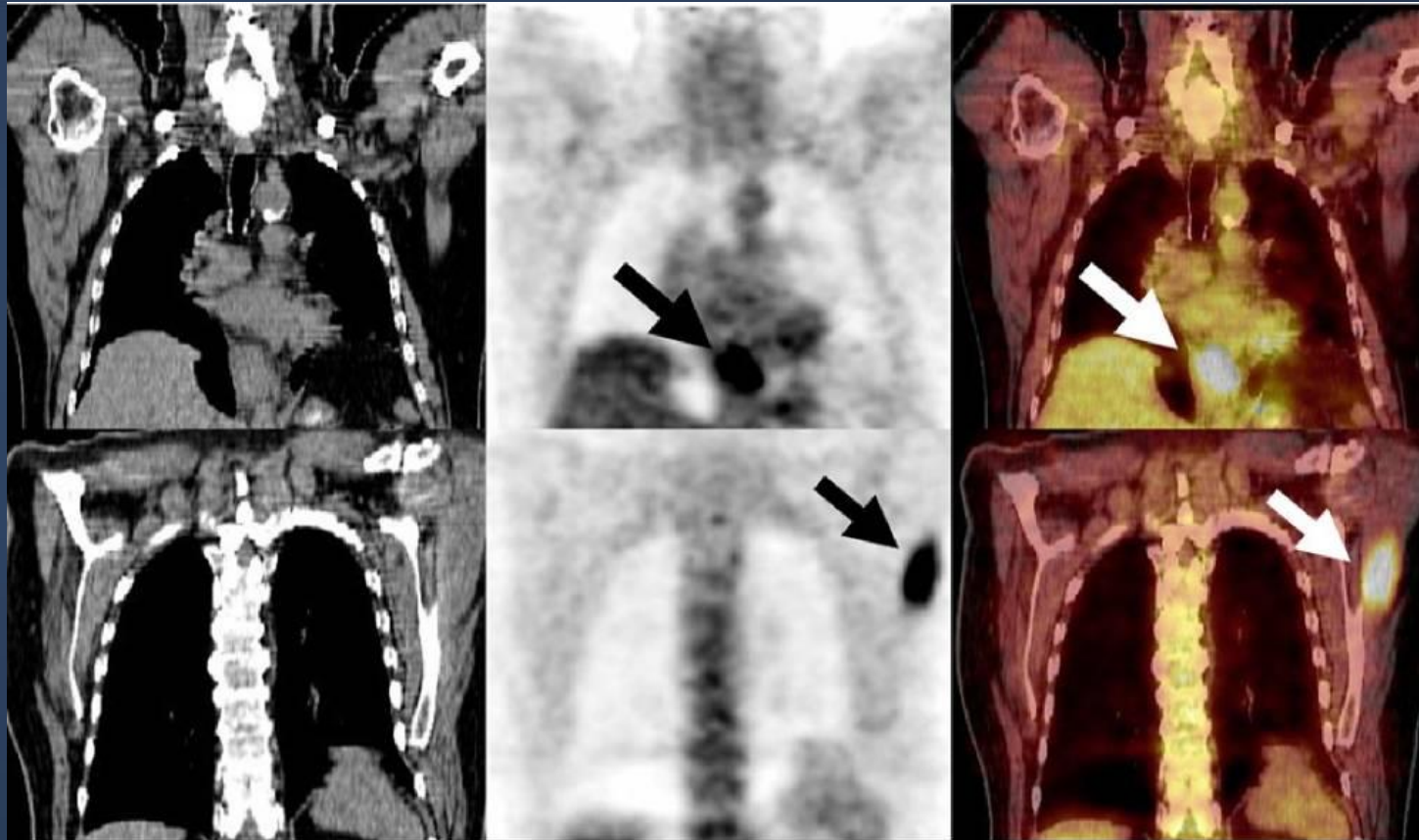
CA Rectum Staging



A 57-year-old woman presented with pain and constipation and colonoscopy revealed an obstructing rectal mass. A staging FDG-PET/CT demonstrated intense FDG avidity in a circumscribed mass-like thickening of the proximal rectum (arrows in top row images) and a focus of mild metabolic activity anterior to the rectum (bottom row arrow) which was not avid as the rectal malignancy. This was located within the uterus as seen on CT images (bottom row), and was subsequently shown to be a uterine fibroid on other imaging studies.

CA Esophagus

Staging



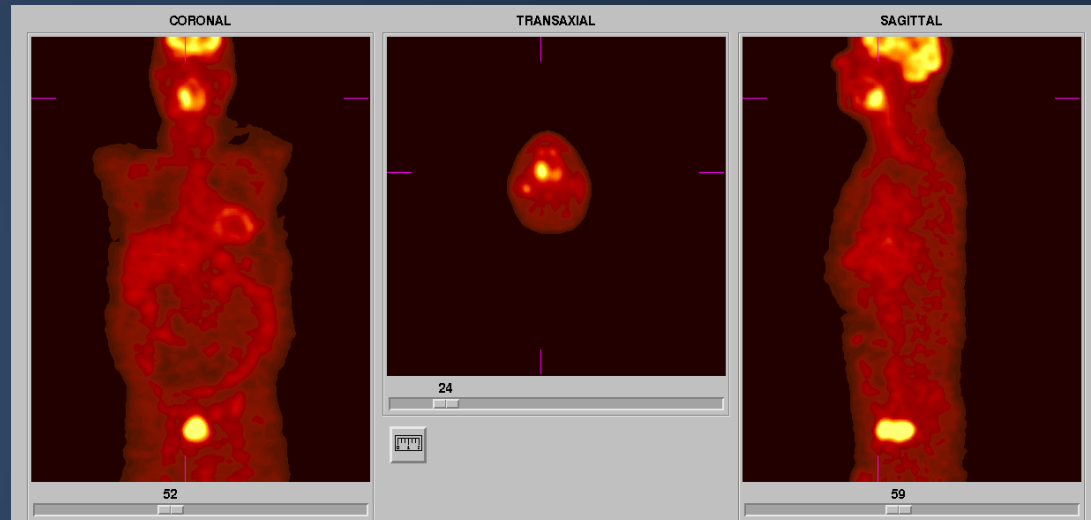
Based on FDG-PET/CT results the clinical management of this patient was changed from surgical resection of the primary tumor to combined chemo-radiation therapy.

FDG PET

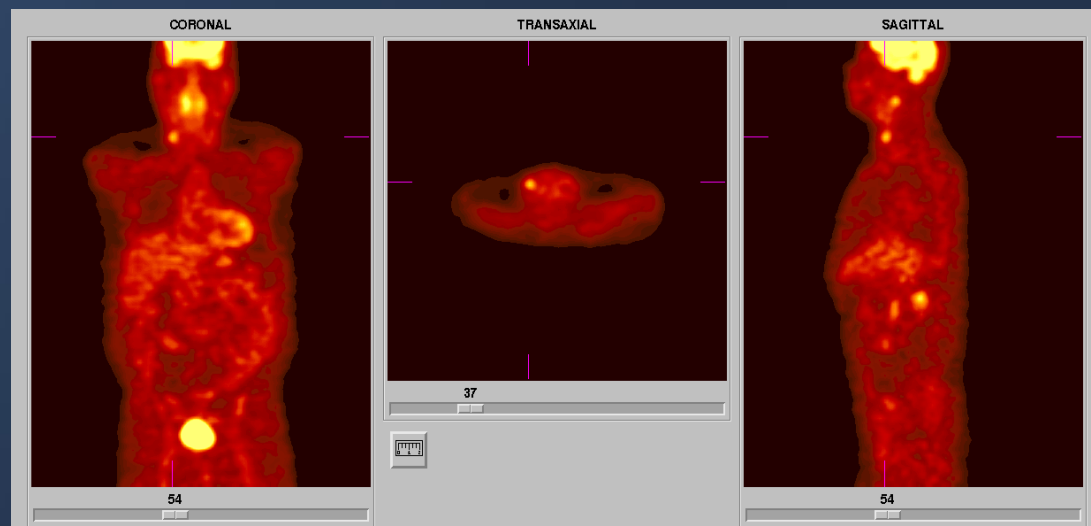
Tumor of unknown origin



Pharyngeal cancer

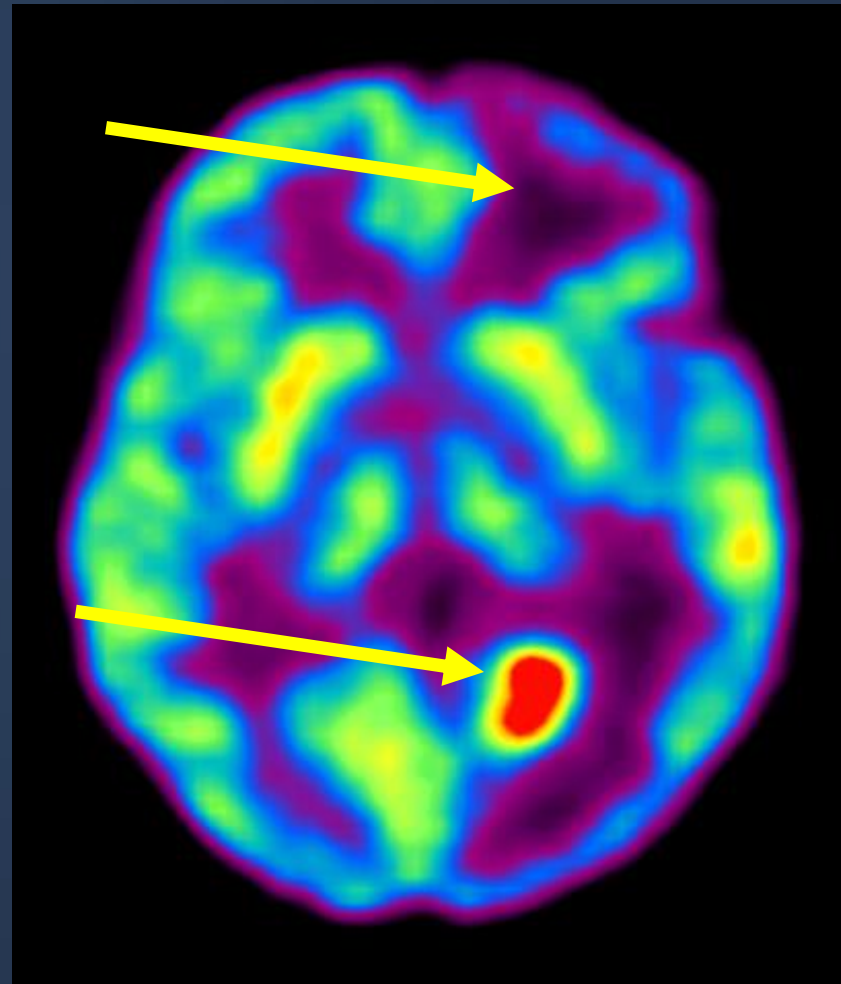
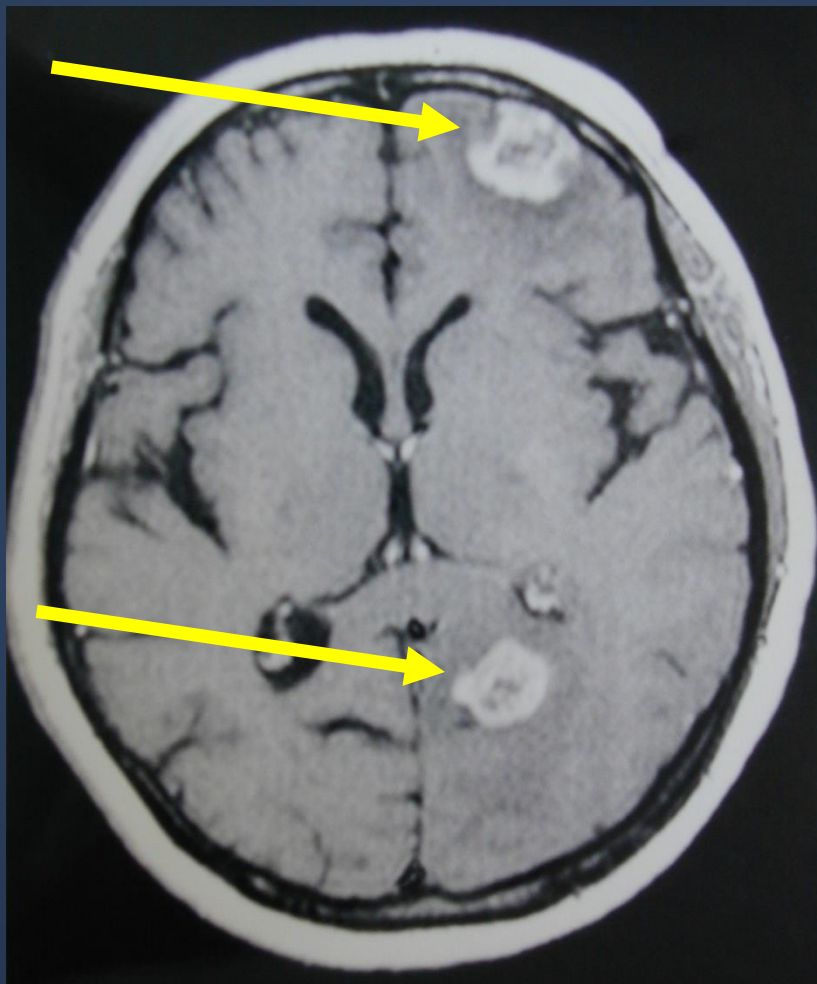


Metastatic involvement
of neck lymph nodes



FDG PET – brain tumor post therapy

Two foci on CT, only one viable tumor



Indications of PET CT



Breast Cancer*	Staging*, restaging*, and monitoring response to therapy*
Colorectal Cancer	Diagnosis*, staging* and restaging*
Esophageal Cancer	Diagnosis*, staging* and restaging*
Head & Neck Cancers (excluding CNS and thyroid)	Diagnosis*, staging* and restaging*
Lung Cancer (Non-Small Cell)	Diagnosis*, staging* and restaging*
Lymphoma	Diagnosis*, staging* and restaging*
Melanoma (Excludes evaluation of regional nodes)	Diagnosis*, staging* and restaging*
Solitary Pulmonary Nodule	Characterization of indeterminate single pulmonary nodule
Thyroid Cancer*	Restaging
Cervical Cancer*	Staging as an adjunct to conventional imaging

Somatostatin receptor PET tracers

Ga-68 DOTANOC



Radiopharmaceutical: DOTANOC , DOTATOC or DOTATATE is labeled with Ga-68

Dose: 3-5 mCi given intravenously.

PET Imaging time: 45-60 min postinjection

Clinical value: higher lesion detection rate than is achieved with (18)F-fluorodihydroxyphenyl-L-alanine PET, somatostatin receptor SPECT, CT, or MR imaging.

Sensitivity: 70-100% (depends on density of somatostatin receptors in the tumor)

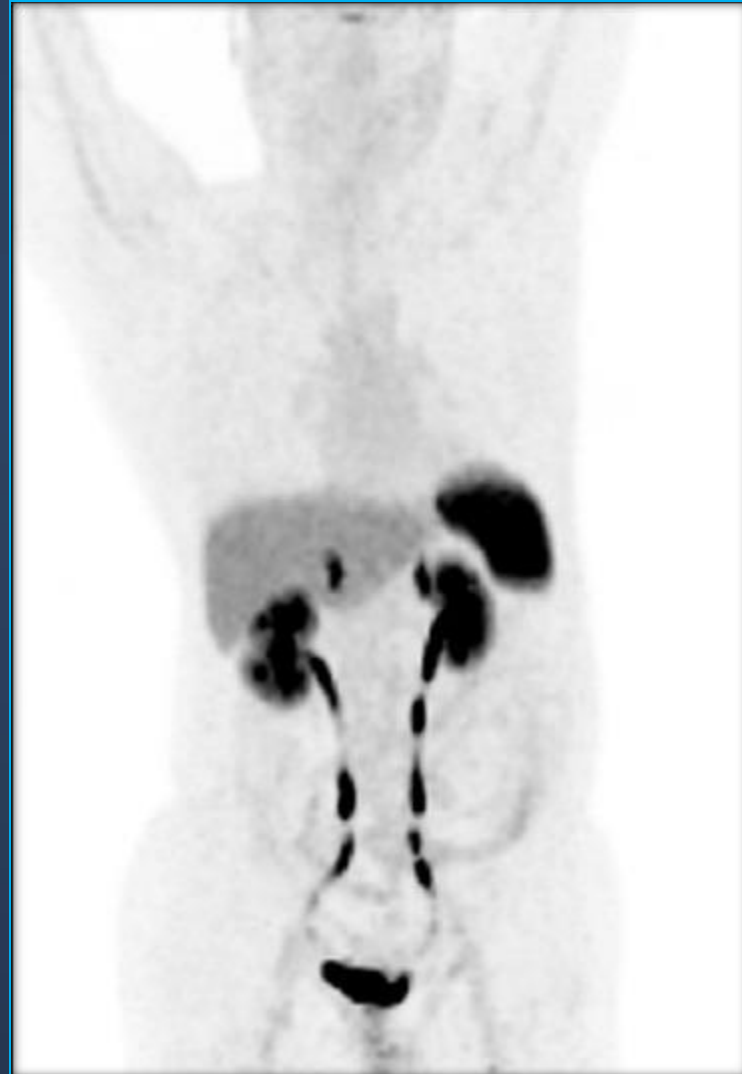Indications: Tumours with high expression of receptors of somatostatin

1. Gastroenteropancreatic tumours (e.g. carcinoids,gastrinoma, insulinoma, glucagonoma, VIPoma, etc.),
2. Sympathoadrenal system tumours (phaeochromocytoma, paraganglioma, neuroblastoma, ganglioneuroma)
3. Medullary thyroid carcinoma
4. Pituitary adenoma
5. Medulloblastoma
6. Merkel cell carcinoma
7. Small-cell lung cancer (mainly primary tumours)
8. Meningioma

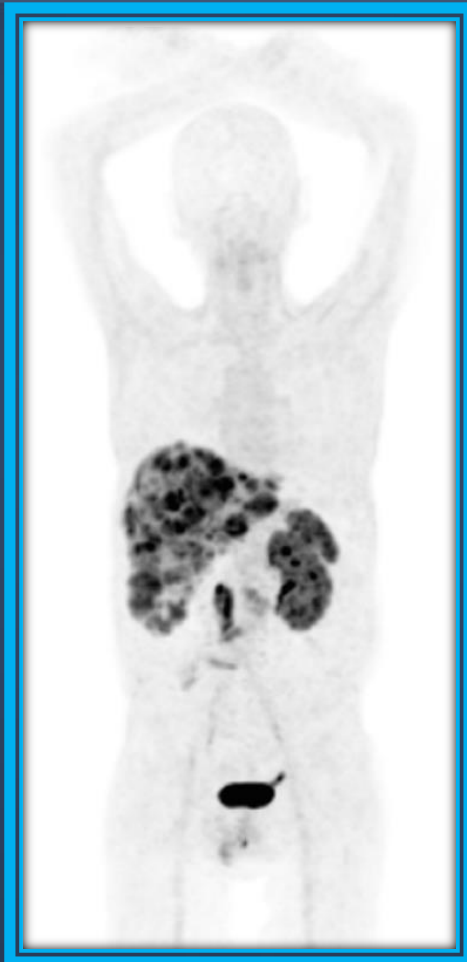Normal Distribution 68Ga-DOTA peptide PET/CT



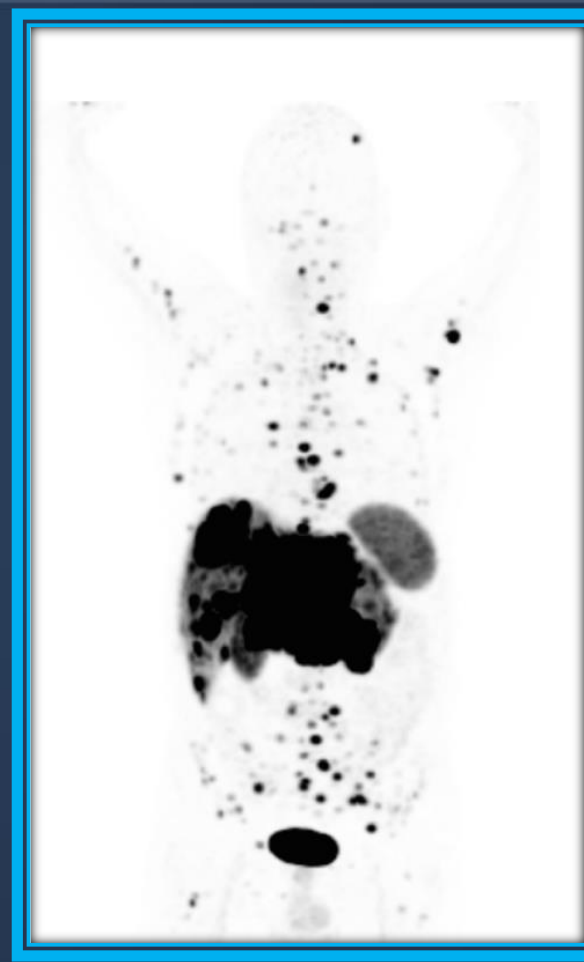
Normal tracer uptake is seen in the pituitary, salivary glands, thyroid, liver, spleen, adrenals, pancreas, kidneys, ureters, and bladder



Ga-68 DOTANOC PET



NET with multiple metastatic disease confined to the liver and abdominal cavity



NET with extensive metastatic lesions throughout the body

Ga-68 DOTANOC PET superior to In-111 Octreoscan



Carcinoid tumor :

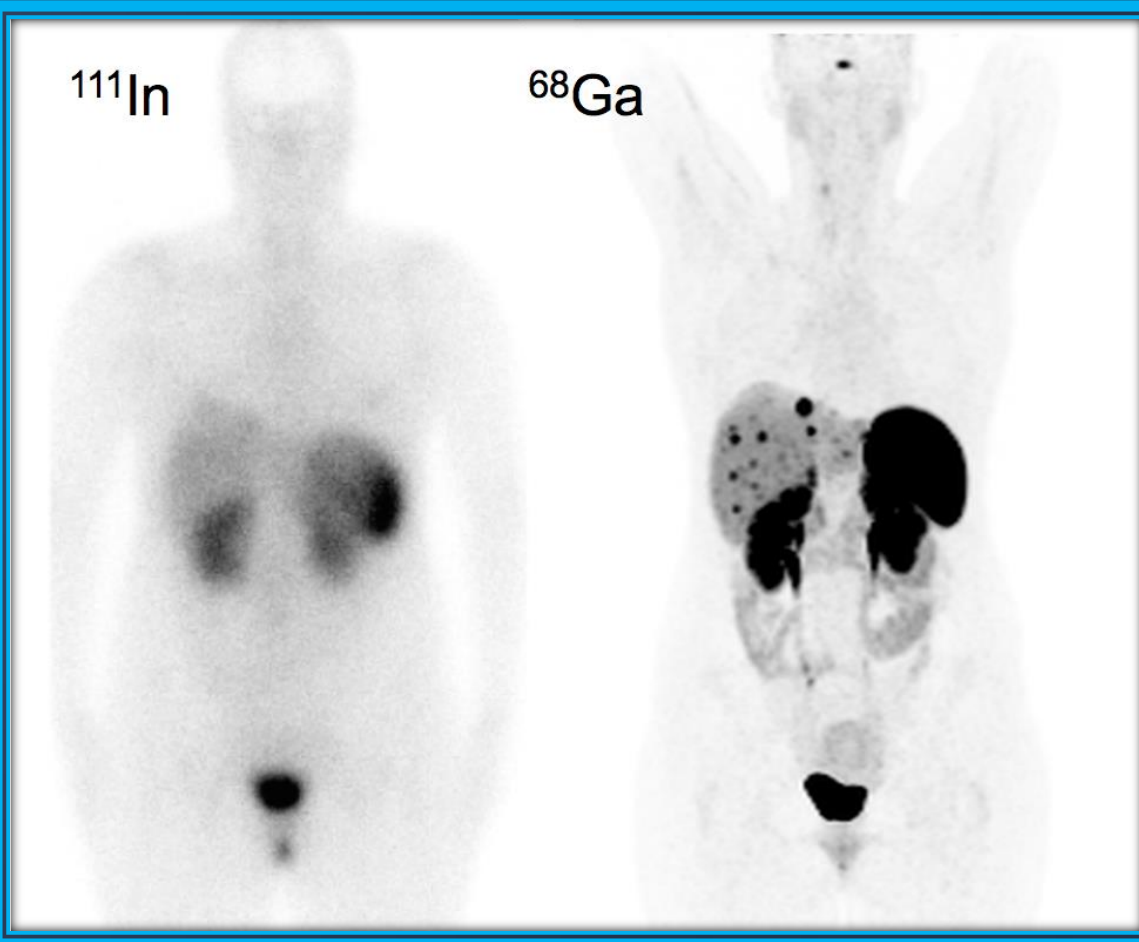
Positive ^{68}Ga -DOTA-NOC and Negative ^{111}In -Octreoscan.

^{68}Ga DOTA-NOC Findings:

Multiple metastatic lesions in the liver. (The pituitary also expresses somatostatin receptors and is visualized in the ^{68}Ga PET image, along with normal uptake in the spleen, kidneys, and bladder.)

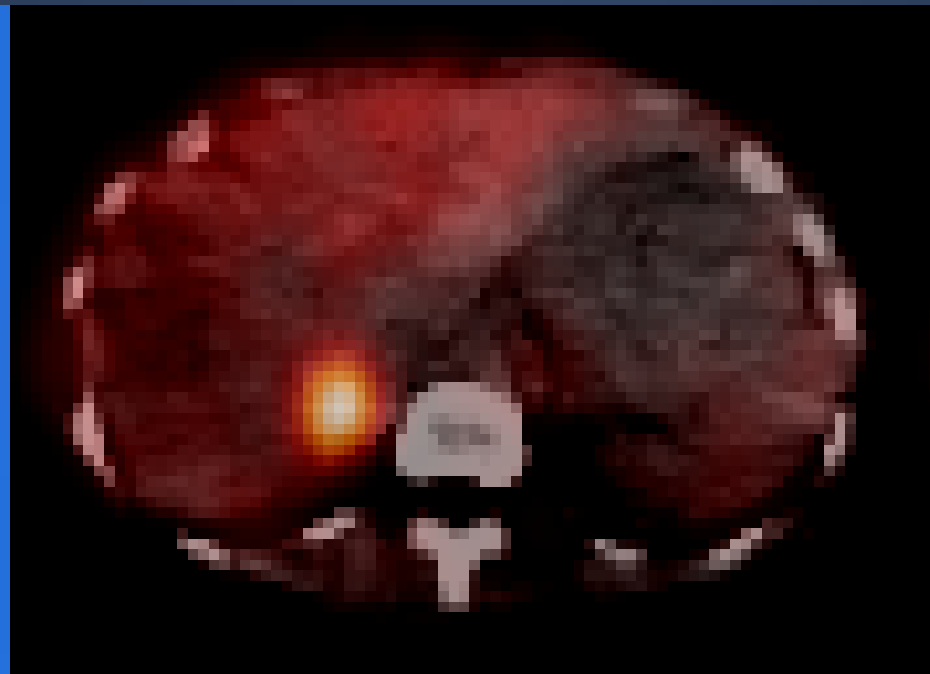
Indication of ^{68}Ga DOTA-NOC:

The ^{68}Ga PET scan was performed because the patient's symptoms were inconsistent with the ^{111}In -Octreoscan findings.

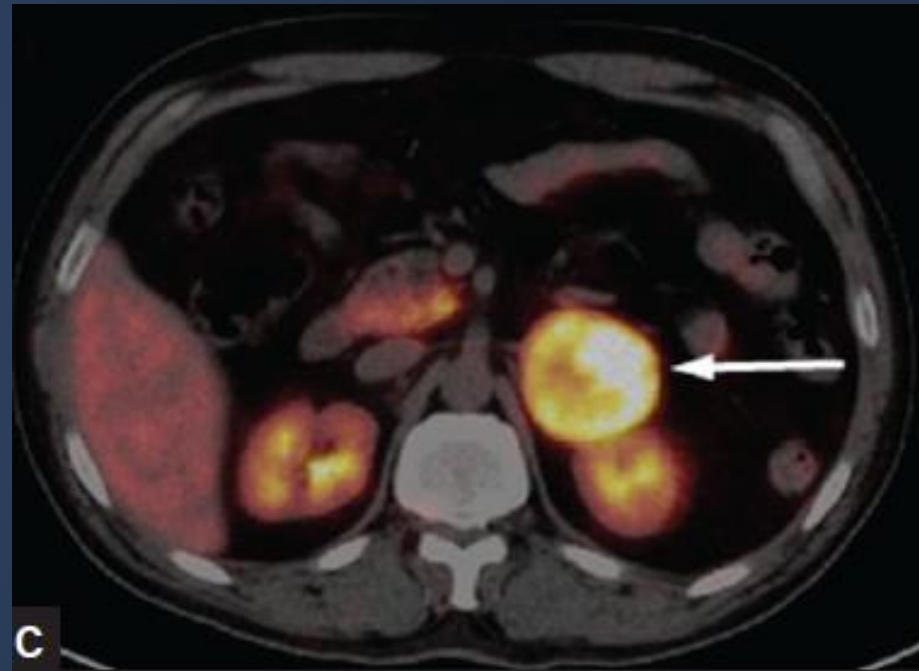


Pheochromocytoma

Ga68 DOTANOC superior to MIBG



SPECT CT - I123 MIBG



PET CT Ga68 DOTANOC

Radionuclide Therapy

Properties of the Ideal Therapeutic Radiopharmaceutical



1. Pure **beta minus emitter**
2. Medium/high **energy** (>1 meV).
3. **Effective half-life** = moderately long, e.g., days.
4. High **target:nontarget ratio**
5. Minimal **radiation dose** to patient and Nuclear Medicine personnel
6. Patient Safety
7. **Inexpensive, readily available** radiopharmaceutical.
8. Simple **preparation and quality control** if manufactured in house.

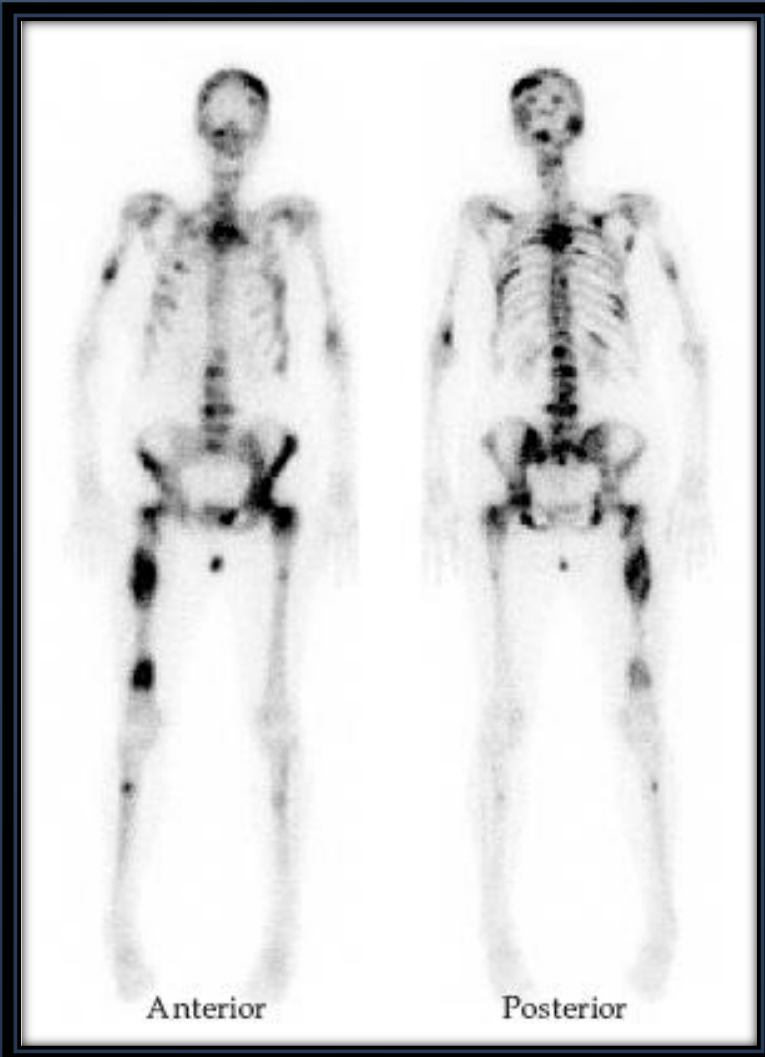
Radionuclide Therapy



<u>Agent</u>	<u>Indication</u>	<u>Dose</u>
I131 :	Thyroid cancer	100-200 mci
131 MIBG :	Neuroblastoma	100-300 mCi
Strontium-89 :	Bone metastasis	40-60uCi/kg
Sm-153-EDTMP:	Bone metastasis	1.0 mCi per kg
Phosphorus- 32 :	Polycythaemia	2.3 mCi/m ²
Y-90-Ibritumomab		
Tiuxetan [Zevalin®]:	B-Cell NHL	0.3 mCi/kg
> Platelet count > 150,000 cells/mL:	0.4 mCi/kg	
> Platelet count 100,000-150,000 cells/mL:		

The dose should never exceed 32 mCi (1,184 MBq)

Strontium-89 Therapy for Palliation of Bony Metastases



History :

A 65 Ys ,M, with CA prostate and widespread bone metastases and severe bony pain.

Admitted for palliative Strontium-89 therapy.

Procedure :

- Bone metastases was confirmed by bone scan.
- The patient was given 40 mCi of Strontium-89 I.V. according to body weight of the patient.
- The patient experienced one day of exacerbated pain which was controlled by opiates but the following day showed gradual pain relieve.

Teaching Points



NM tumor imaging

- Functional
- Sensitive
- Whole body evaluation
- Specific : Some tumors
- Targeted therapy

Objectives of NM tumor imaging

- Diagnosis
- Staging
- Guiding biopsy
- Follow up and therapy monitoring
- Detection of recurrence.

Reference book and the relevant page numbers..



- **Nuclear Medicine: The Requisites, Third Edition (Requisites in Radiology) [Hardcover]**

Harvey A. Ziessman MD, Janis P. O'Malley MD, James H. Thrall MD

Relevant Pages :

**Oncology : 264-274 , 279 -283 ,302 -345 ,
119-133 , 109 -112 ,296 -299**

