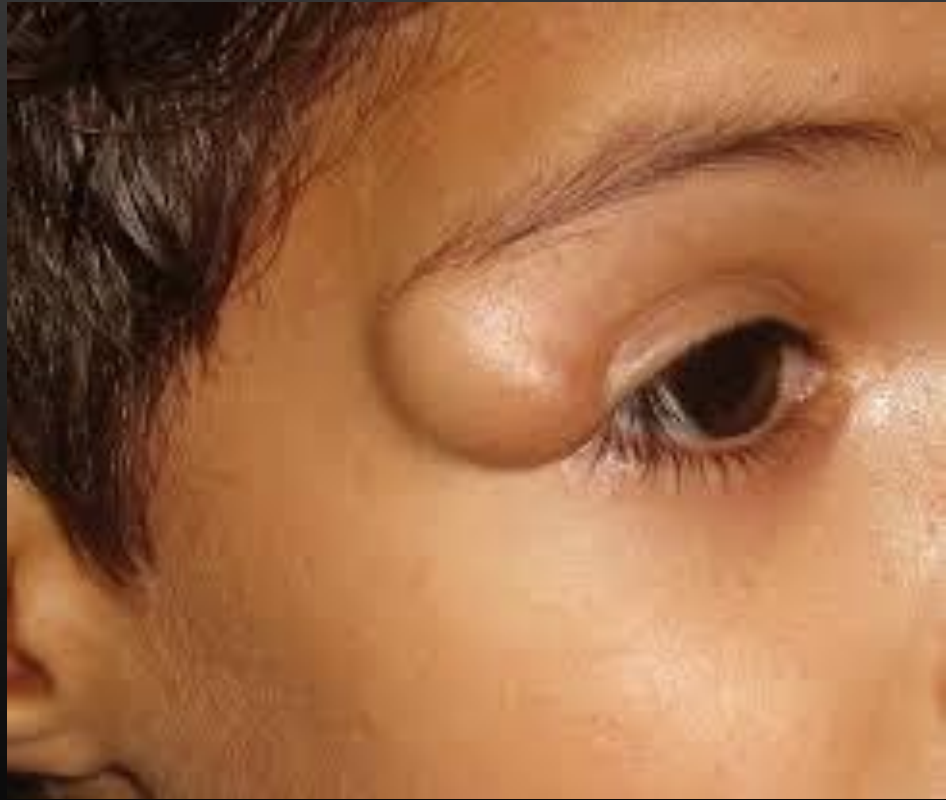

SUPERFASCIAL LUMPS

Tariq Altokhais
Associate Professor
Consultant, Pediatric Surgeon
Department of Surgery



History of a lump or an ulcer

- Duration (when was the first time noticed)
- First symptom (how the patient noticed it)
- Other symptoms
- Progression (change since notice)
- Persistence (has it ever disappear or healed)
- Any other lumps or ulcers
- Cause

Examination of a lump

Inspection:

- Shape
- Site
- Color
- Size

Palpation:

- Temperature
- Tenderness
- Surface
- Edges
- Consistency
- Mobility
- Pulsation
- Compressibility
- Fluctuation
- Transillumination

Classification

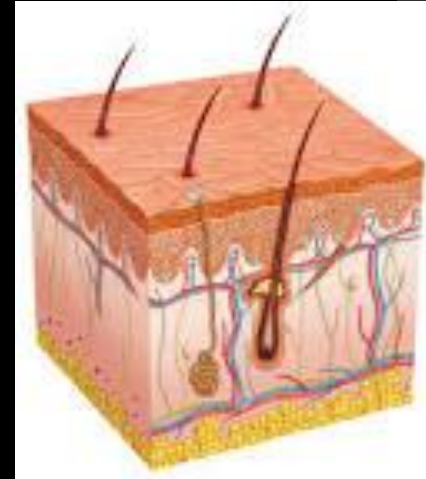
- Congenital
- Acquired:
 - Infection
 - Trauma
- Cystic
- Solid

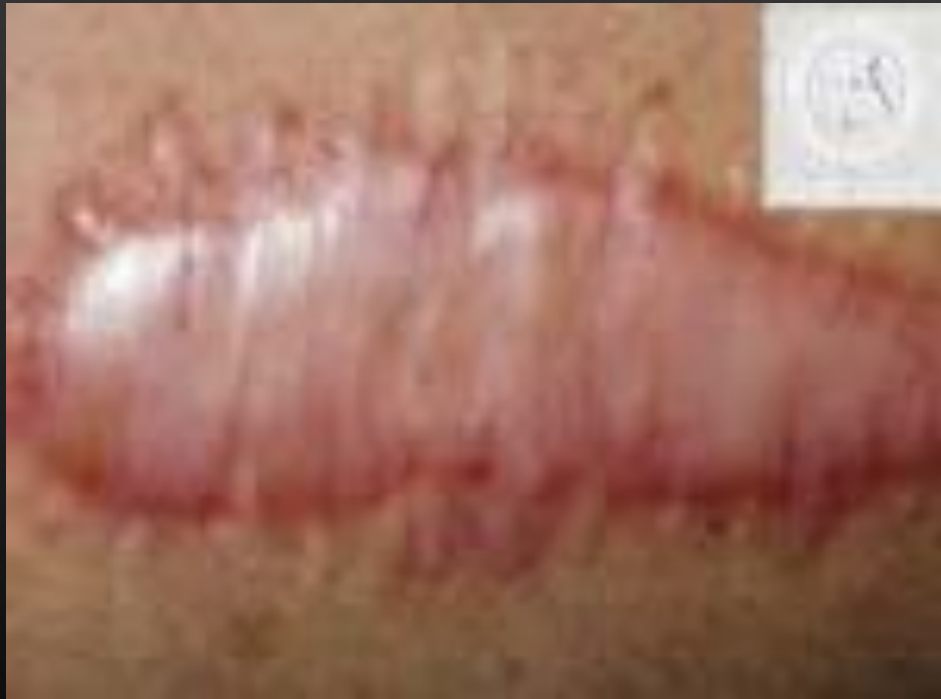Skin anatomy

Epidermis: openings of glands

Papillary dermis: basal cell layer

Dermis : contains sweat & sebaceous glands





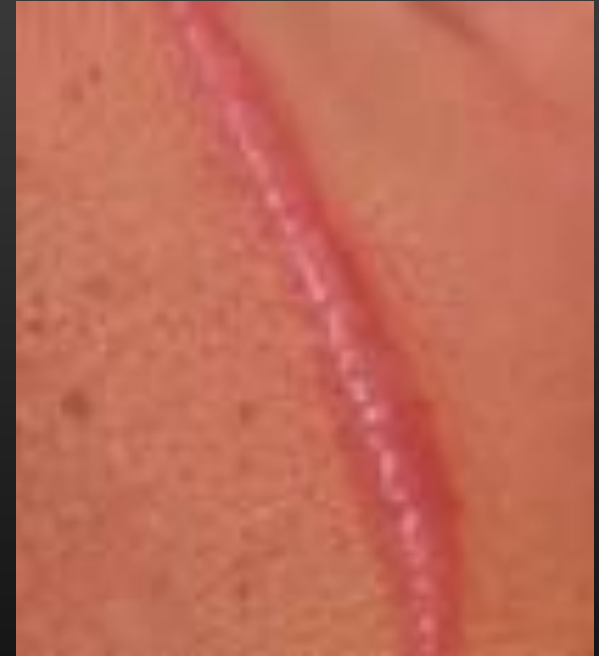Scar

- Fibrous tissue proliferation following :
 - . Trauma
 - . Surgery
 - . Infection
- It is usually flat.

Hyper trophic scar

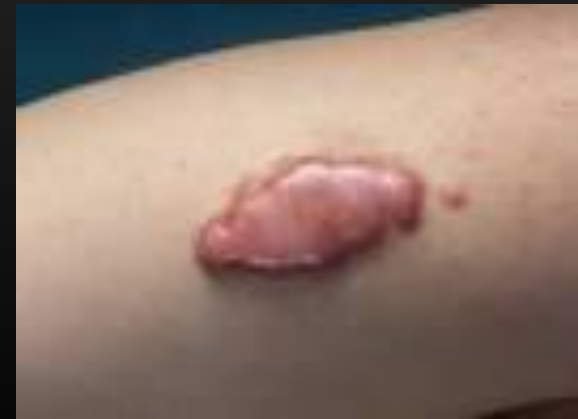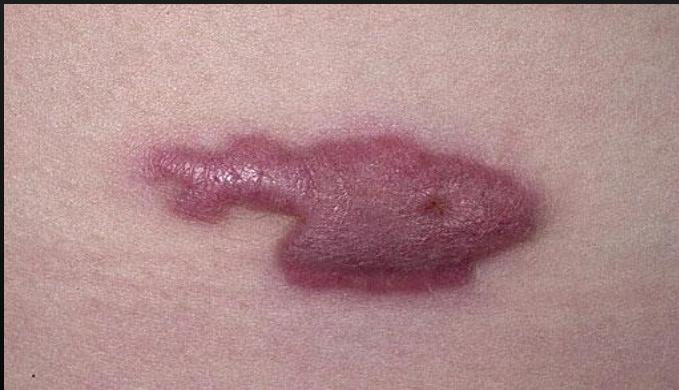Excessive fibrous tissue in a scar

- . confined to the scar
- . no neovascularization
- .wound infection is an important factor
- .clinically it is a raised , non tender swelling with no itching
- .it may regress gradually in six months
- . does not usually recur after excision

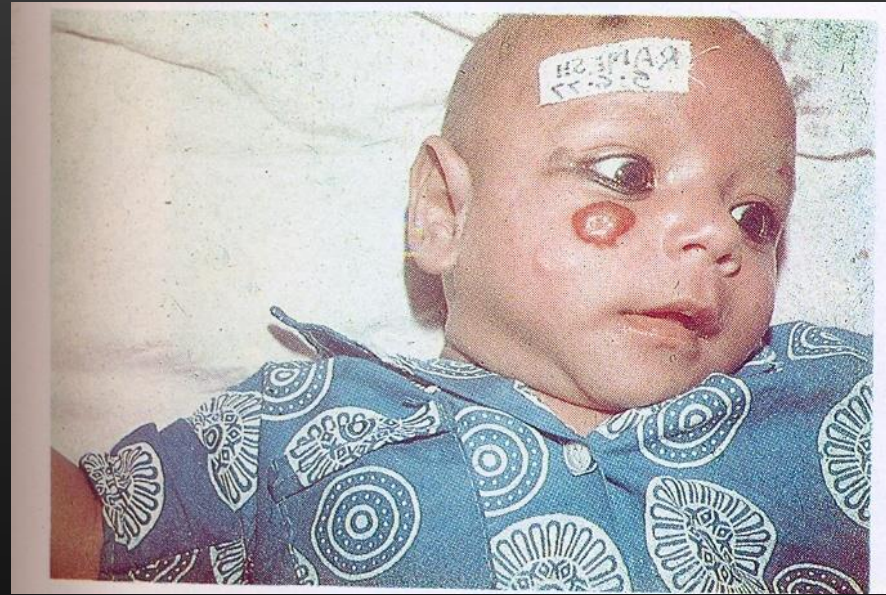
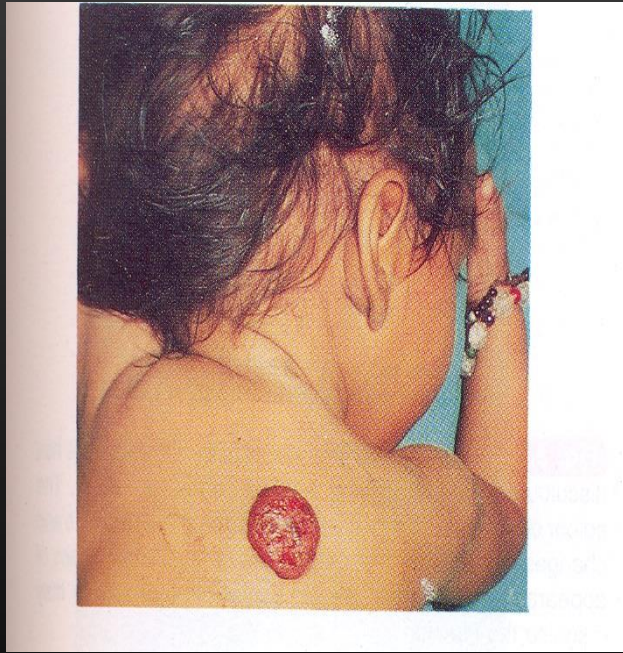
Keloid

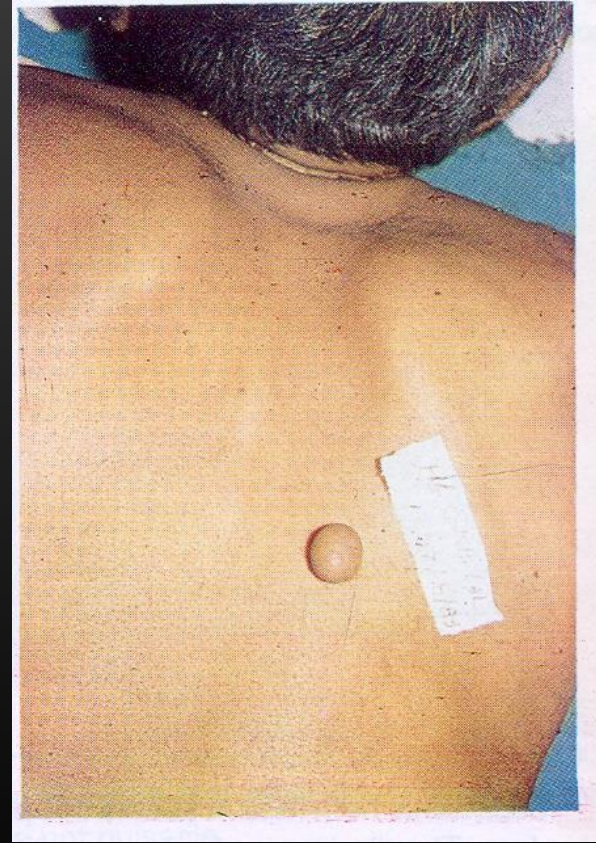
- Excessive fibrous and collagen tissue with ***neovascular proliferation*** in a scar.
- usually extends beyond the original scar



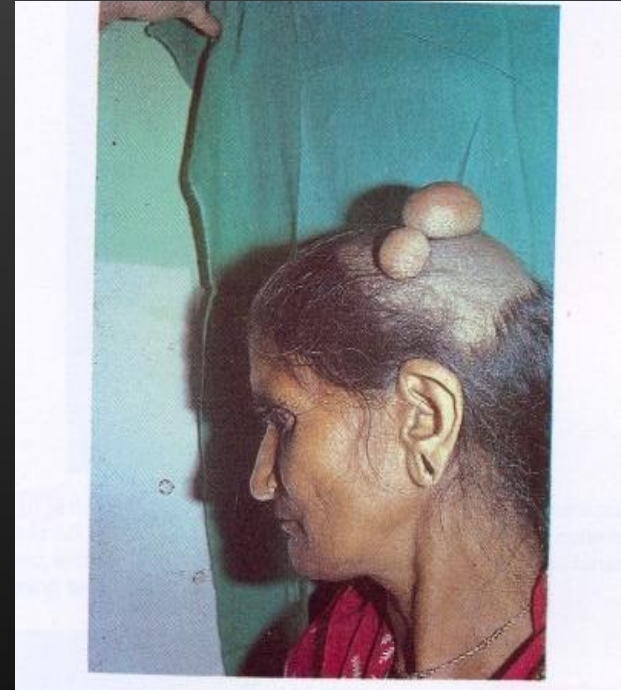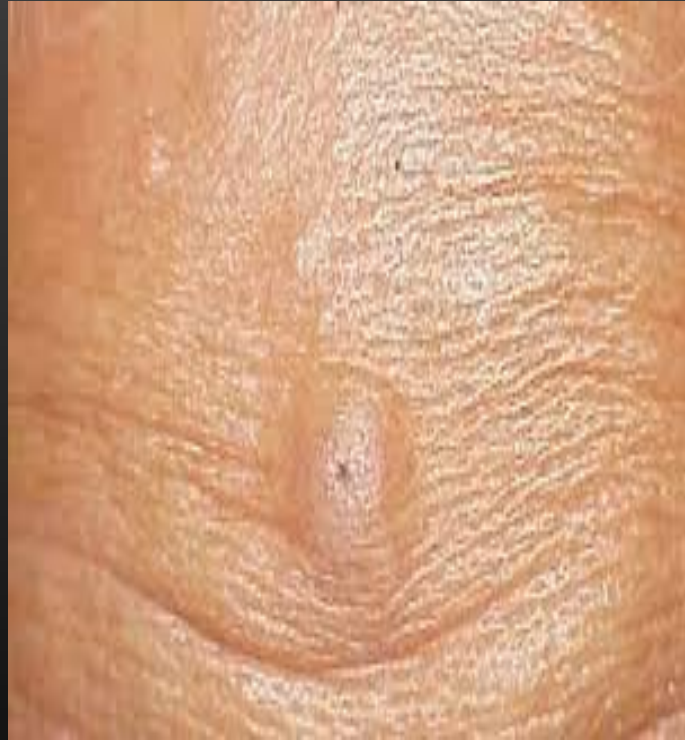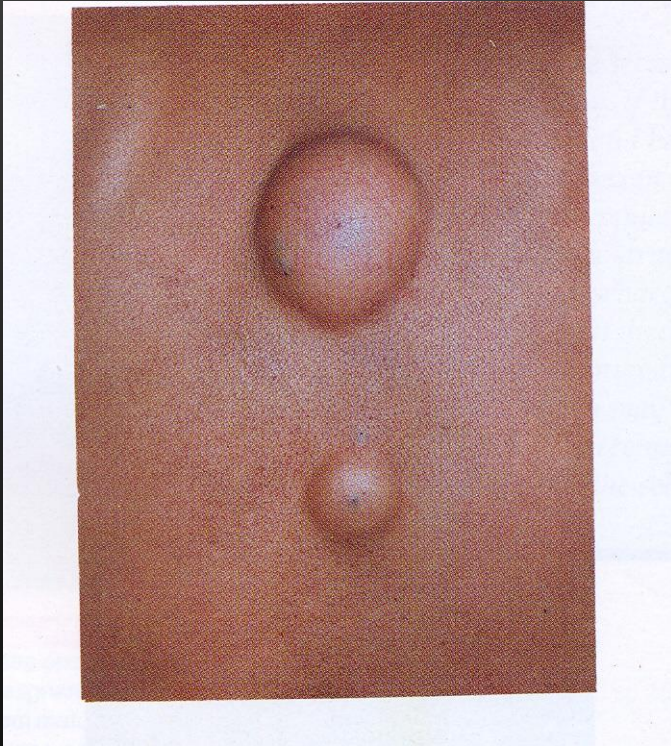
Haemangioma



Papilloma



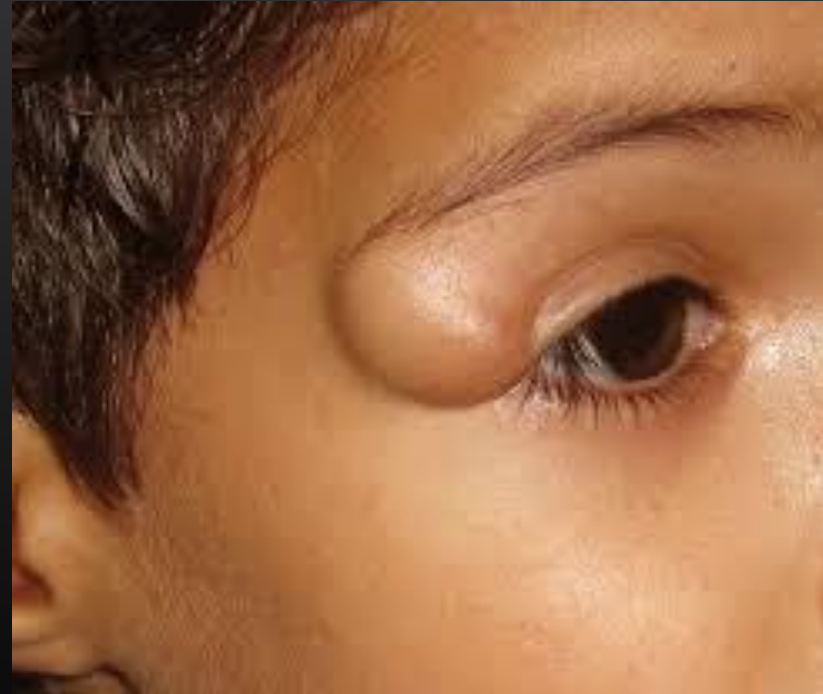Sebaceous Cyst

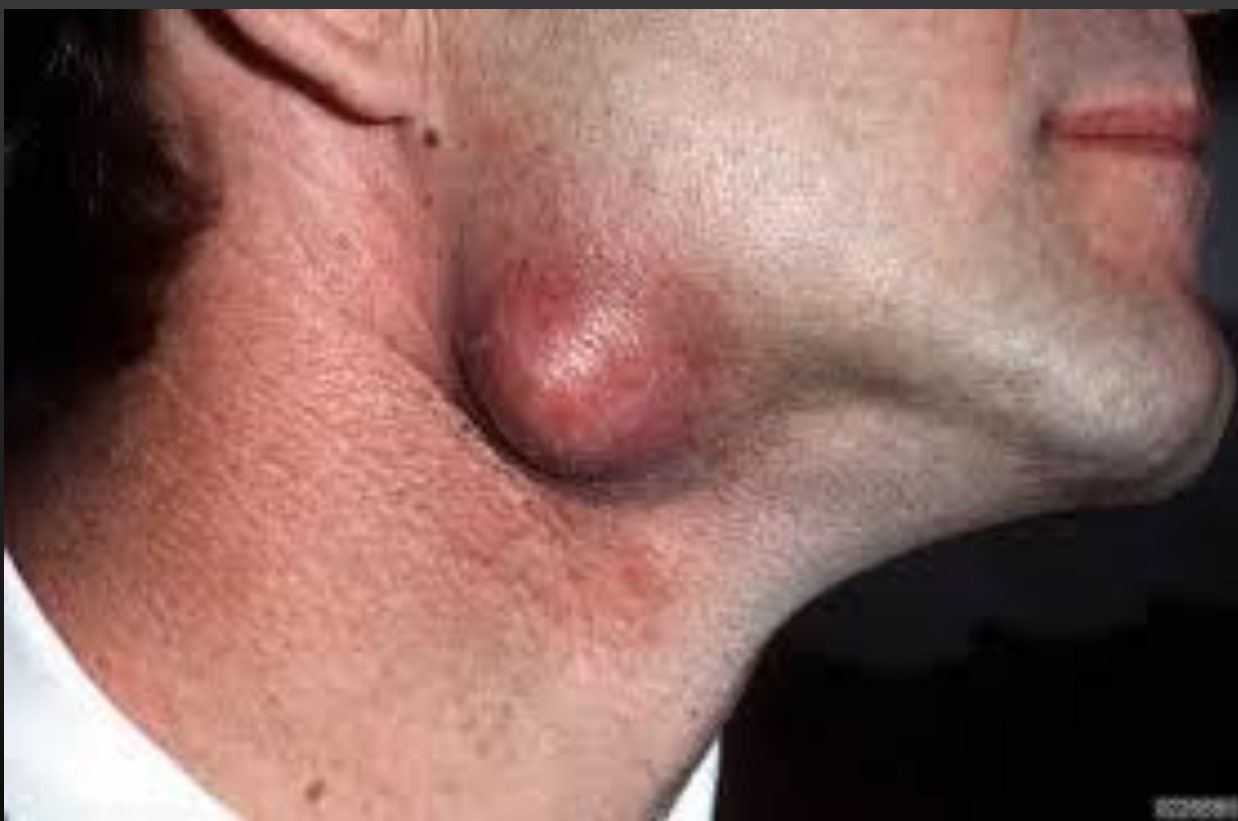

Dermoid

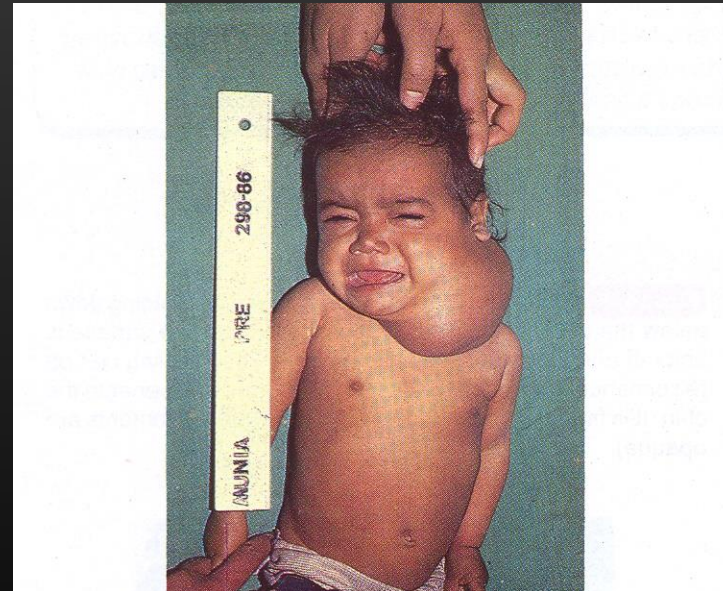
Clinical features:

- Painless, spherical, cystic mass.
- Appears in childhood or adults.
- Smooth surface.
- Not attached to skin
- No punctum
- Not compressible
- Trans-illumination test - ve .

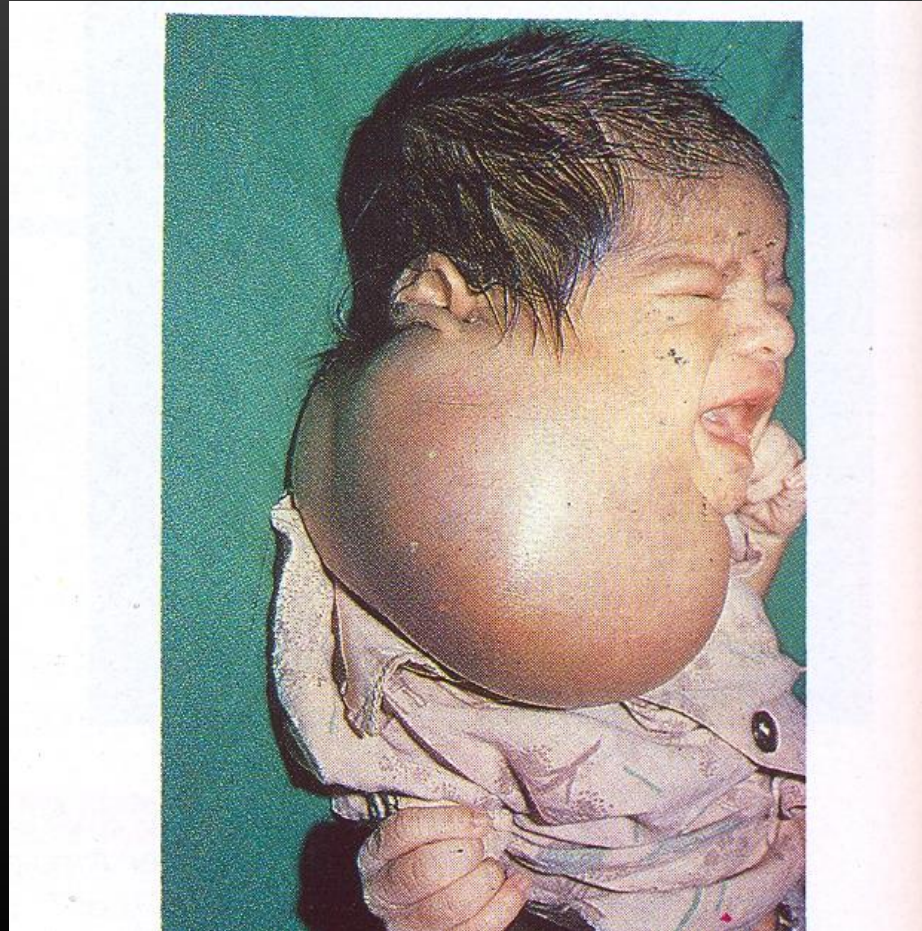




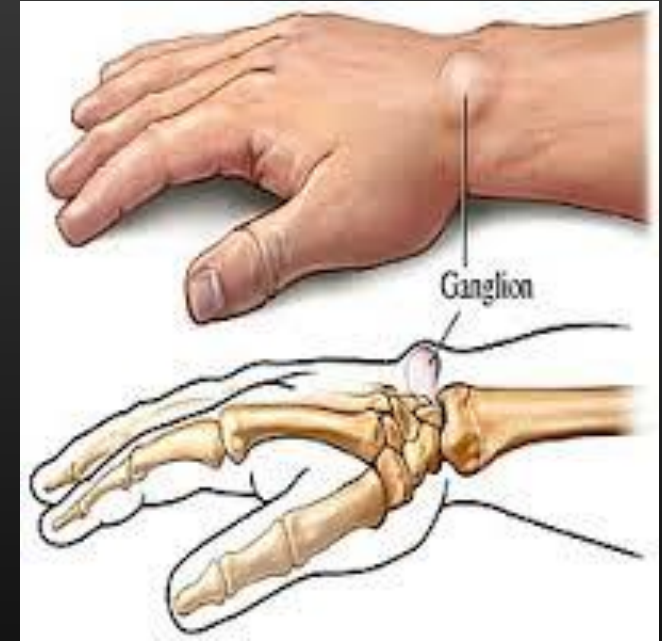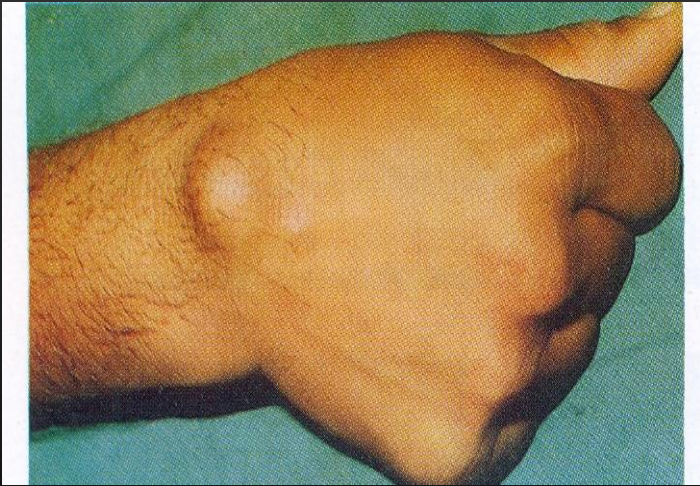
Lymphatic Malformation



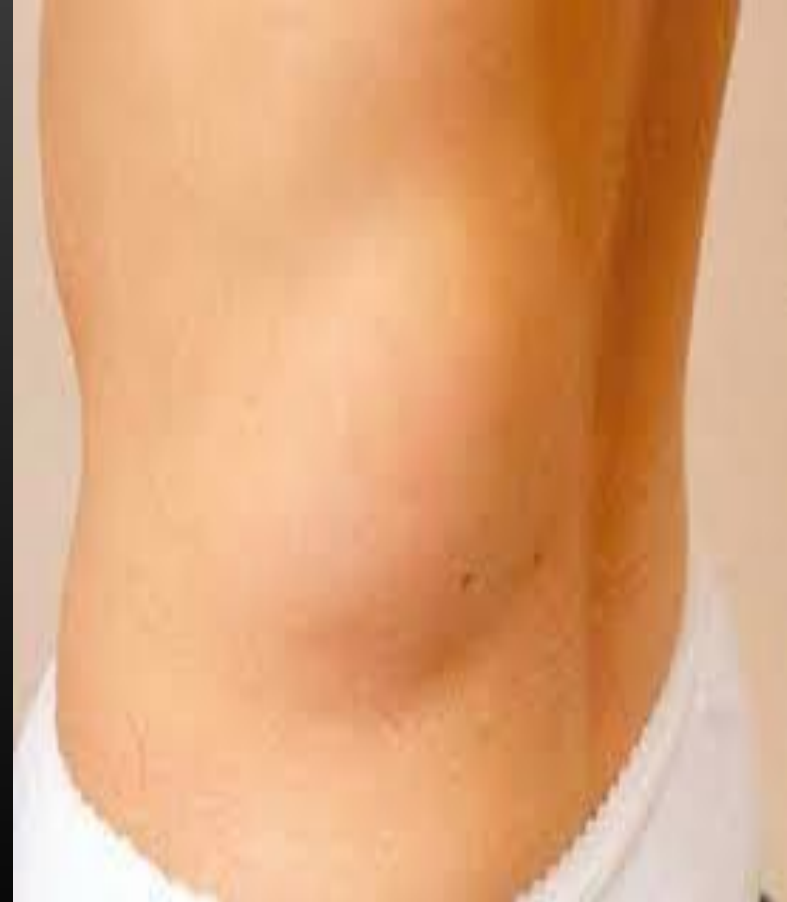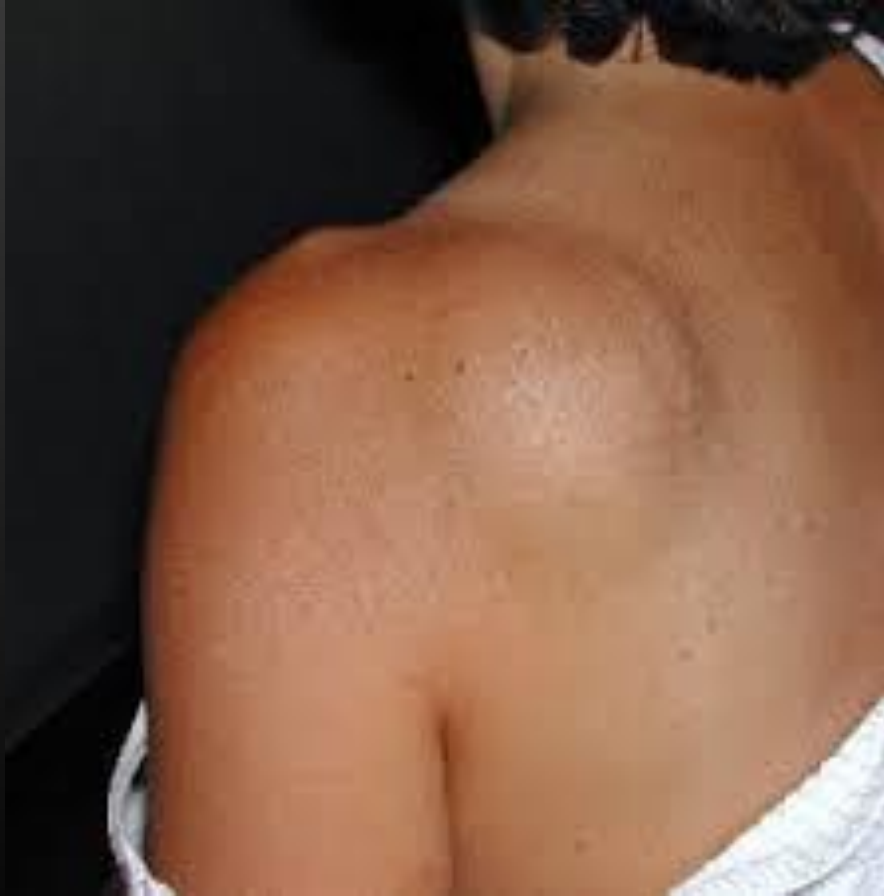Lymphatic Malformation



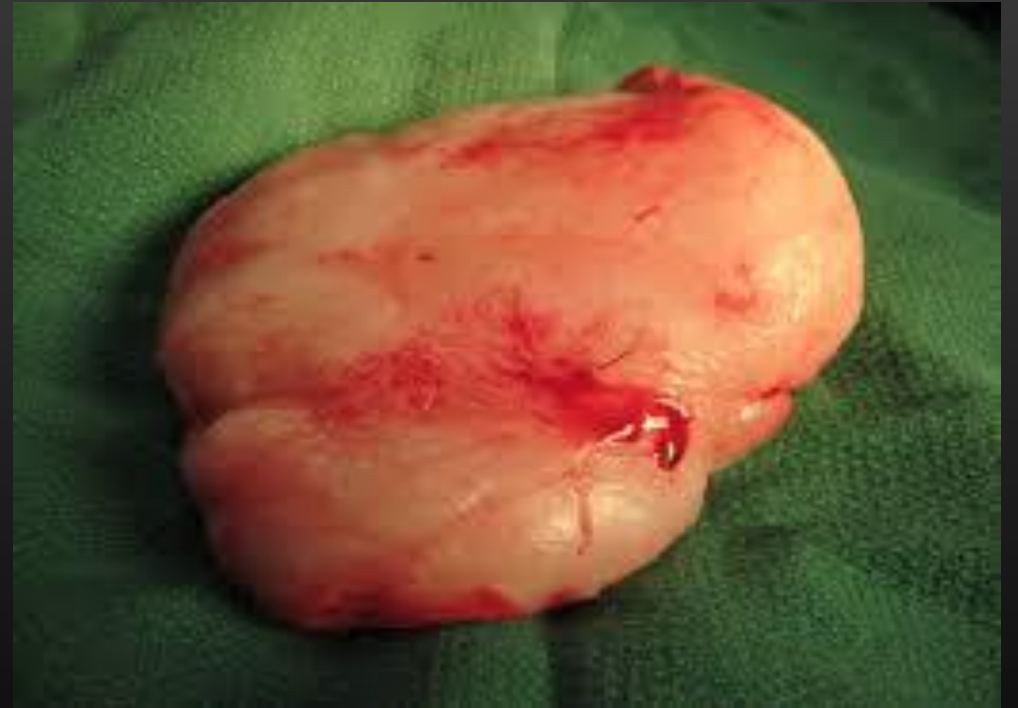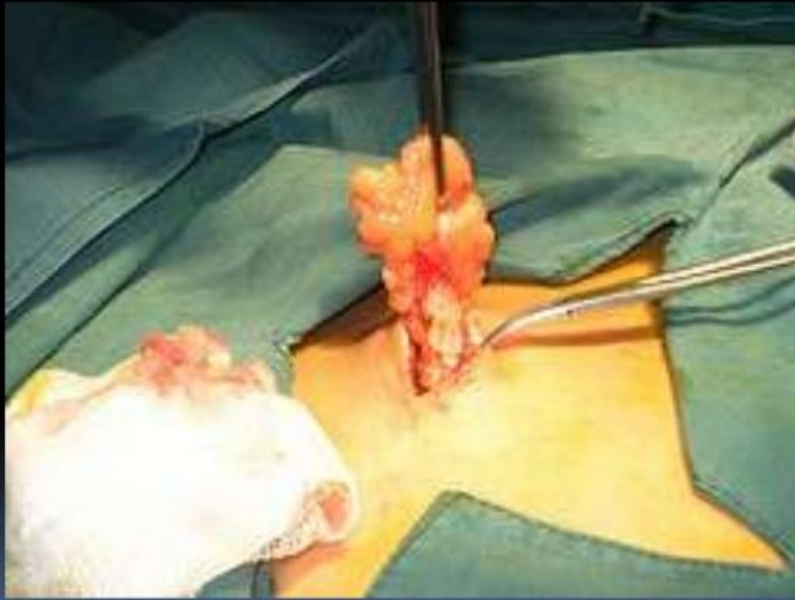
Ganglion



Lipoma



Lipoma



شكراً

Thank you