

Radiology of cardiorespiratory disease (interactive lecture)

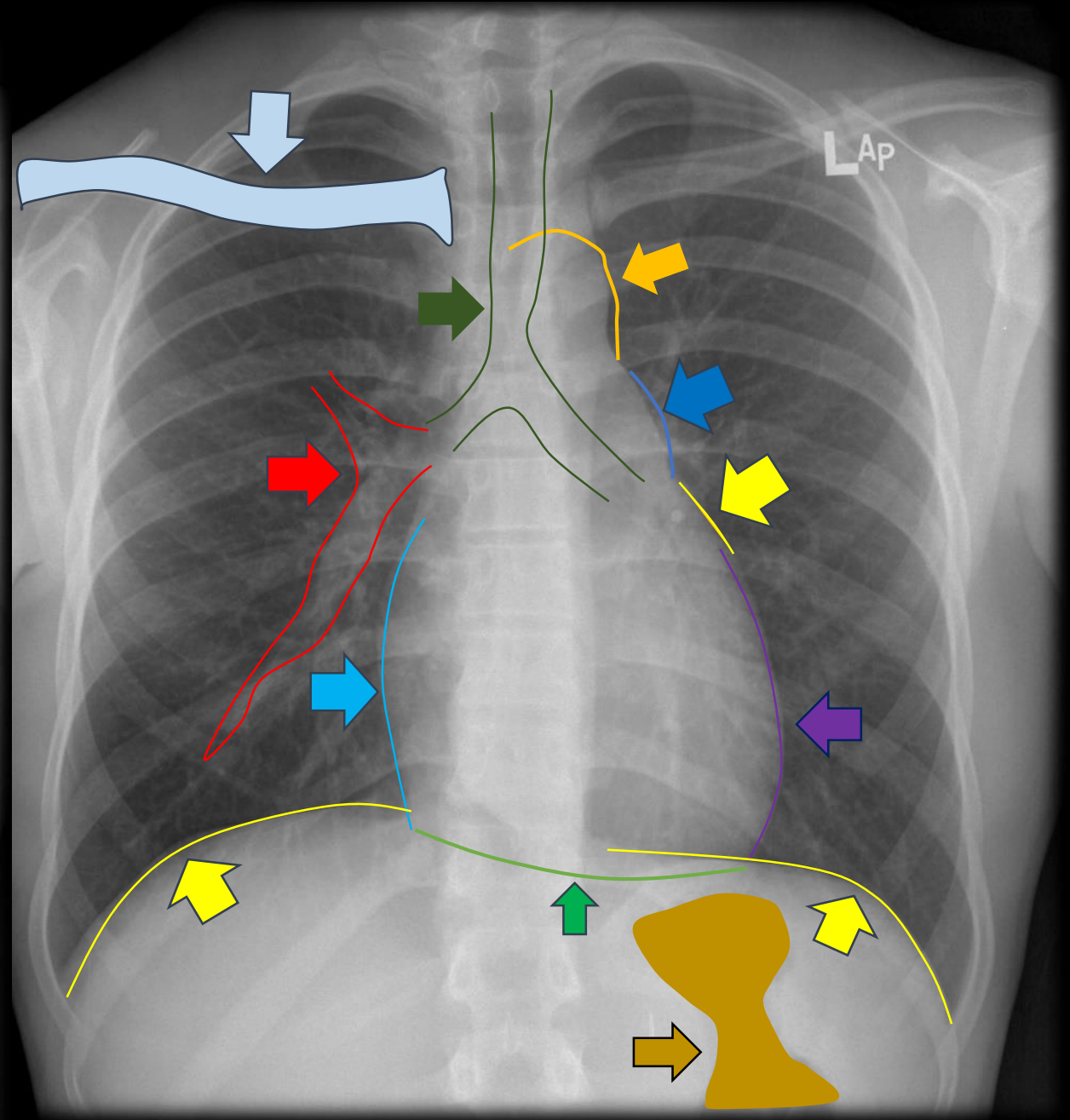
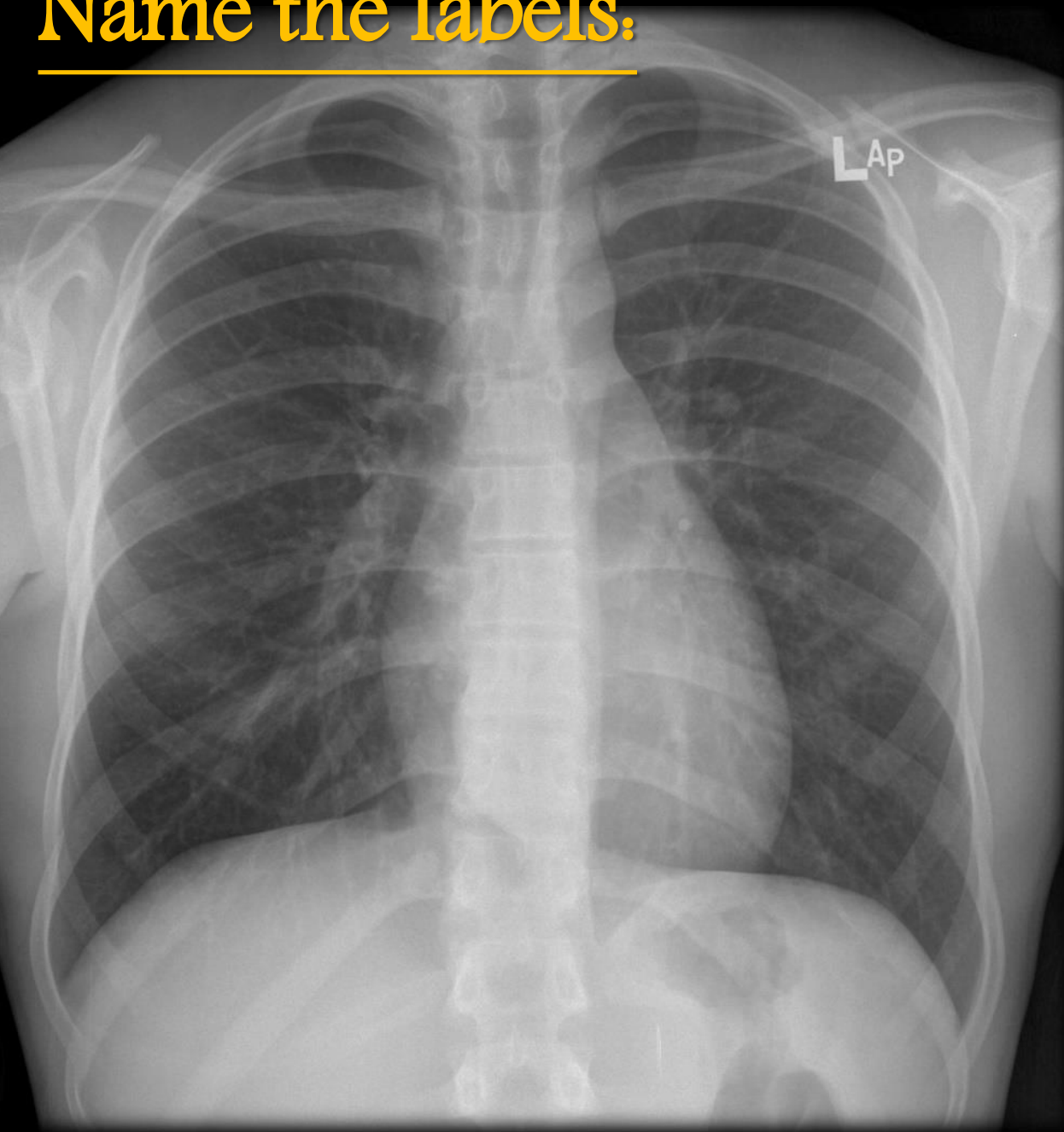
Dr. Reshaid Al Jurayyan

Assistant professor & consultant

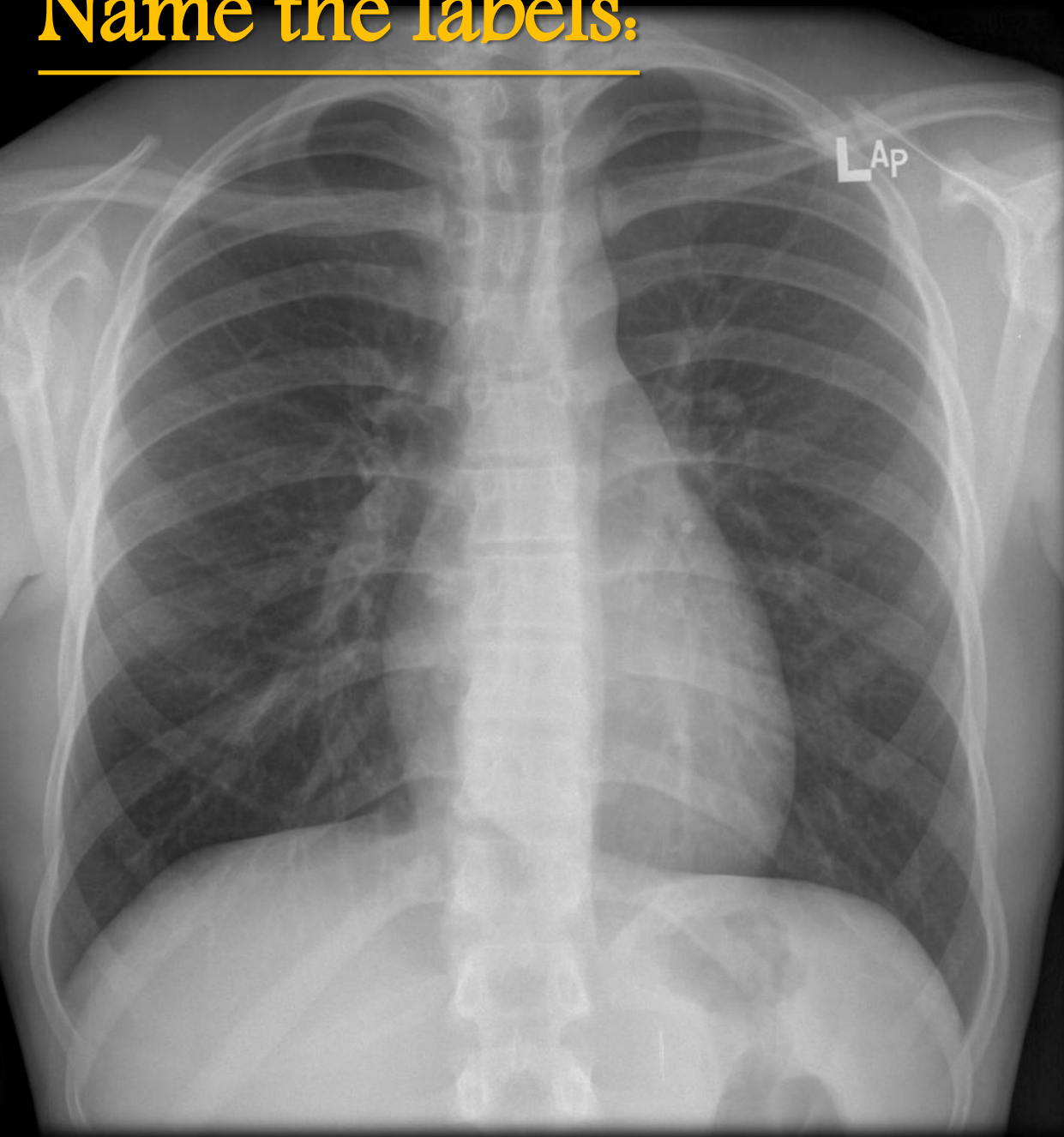
Radiology & medical imaging department

King Saud university- medical city

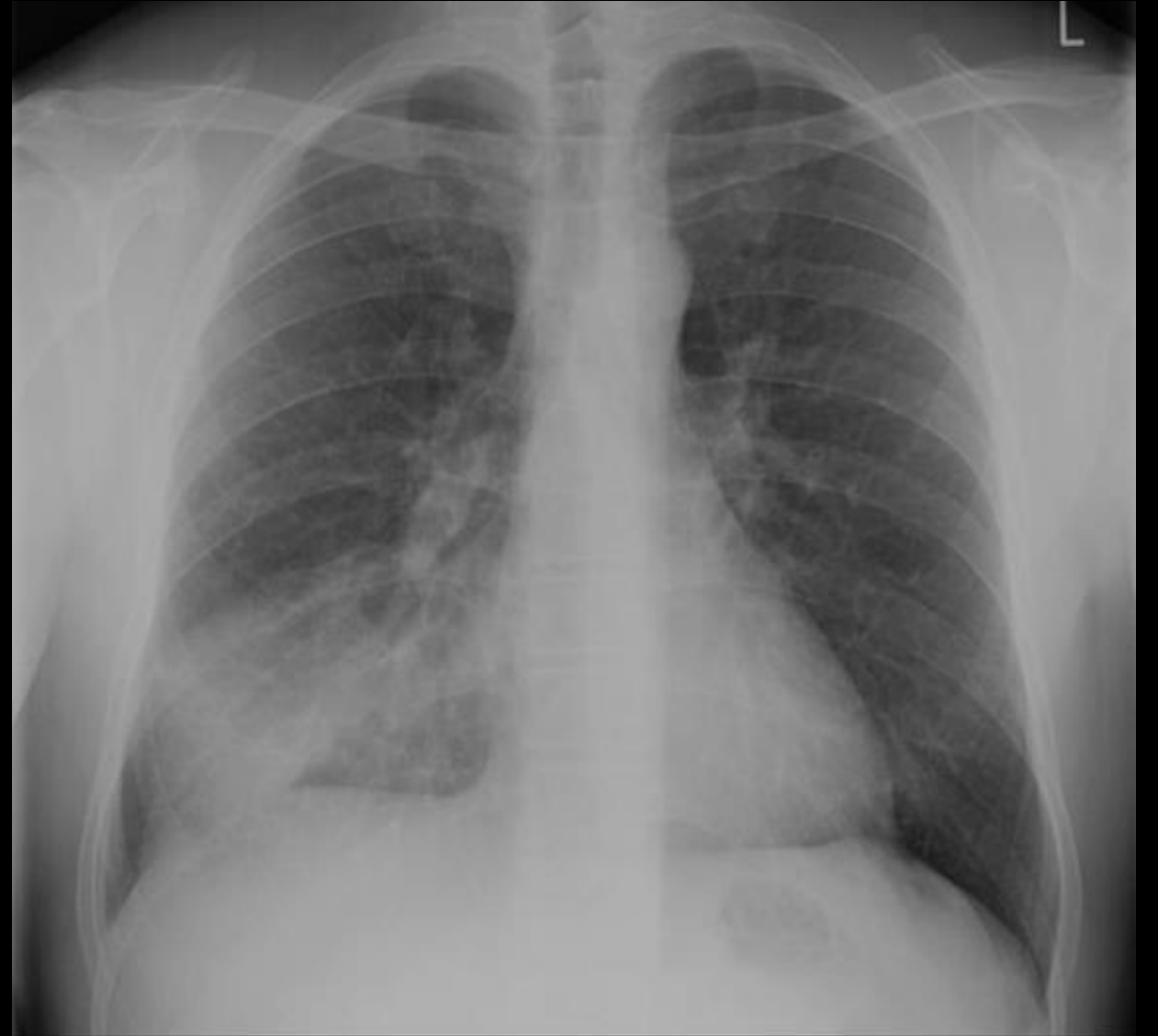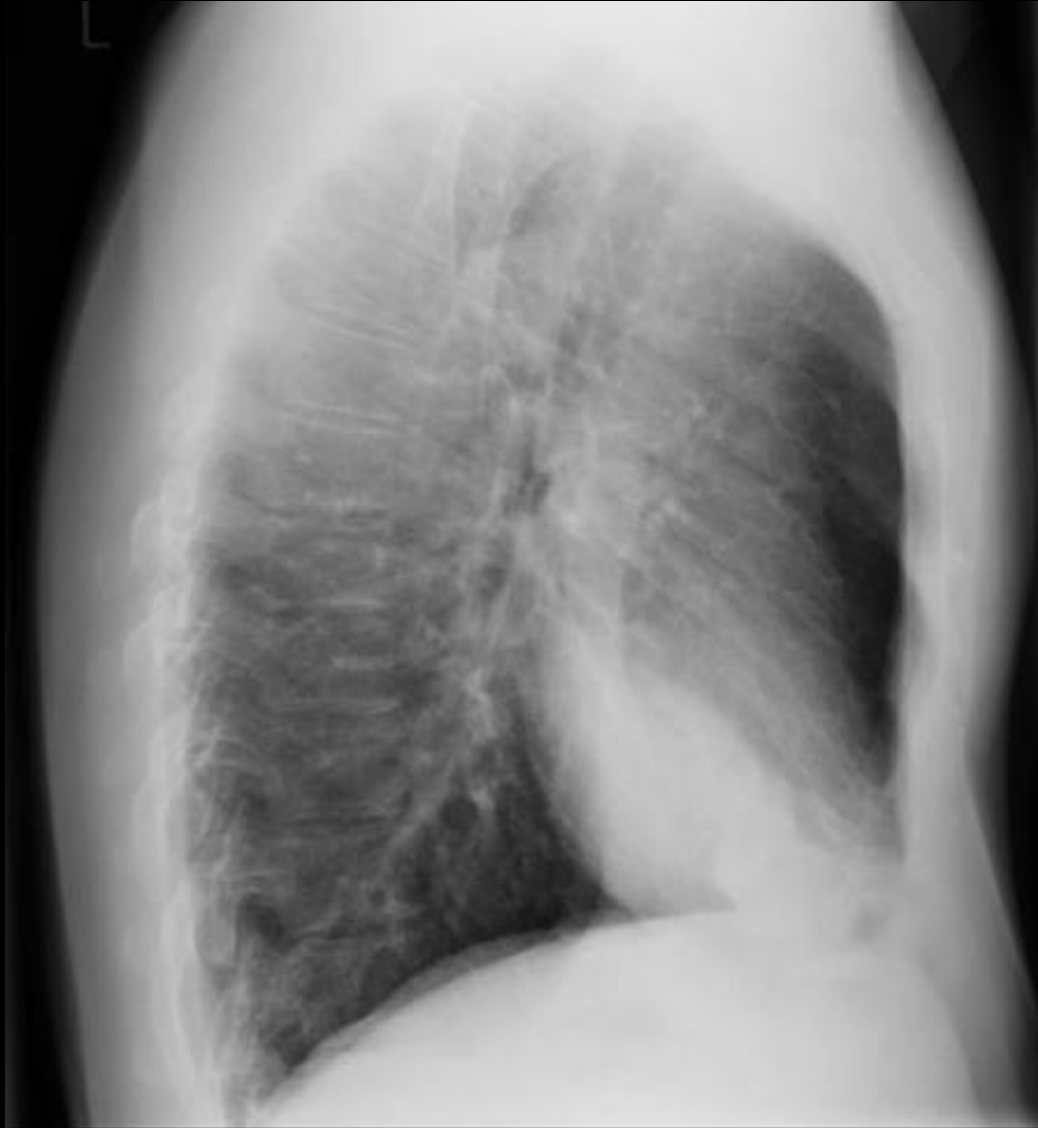Name the labels.



Name the labels.



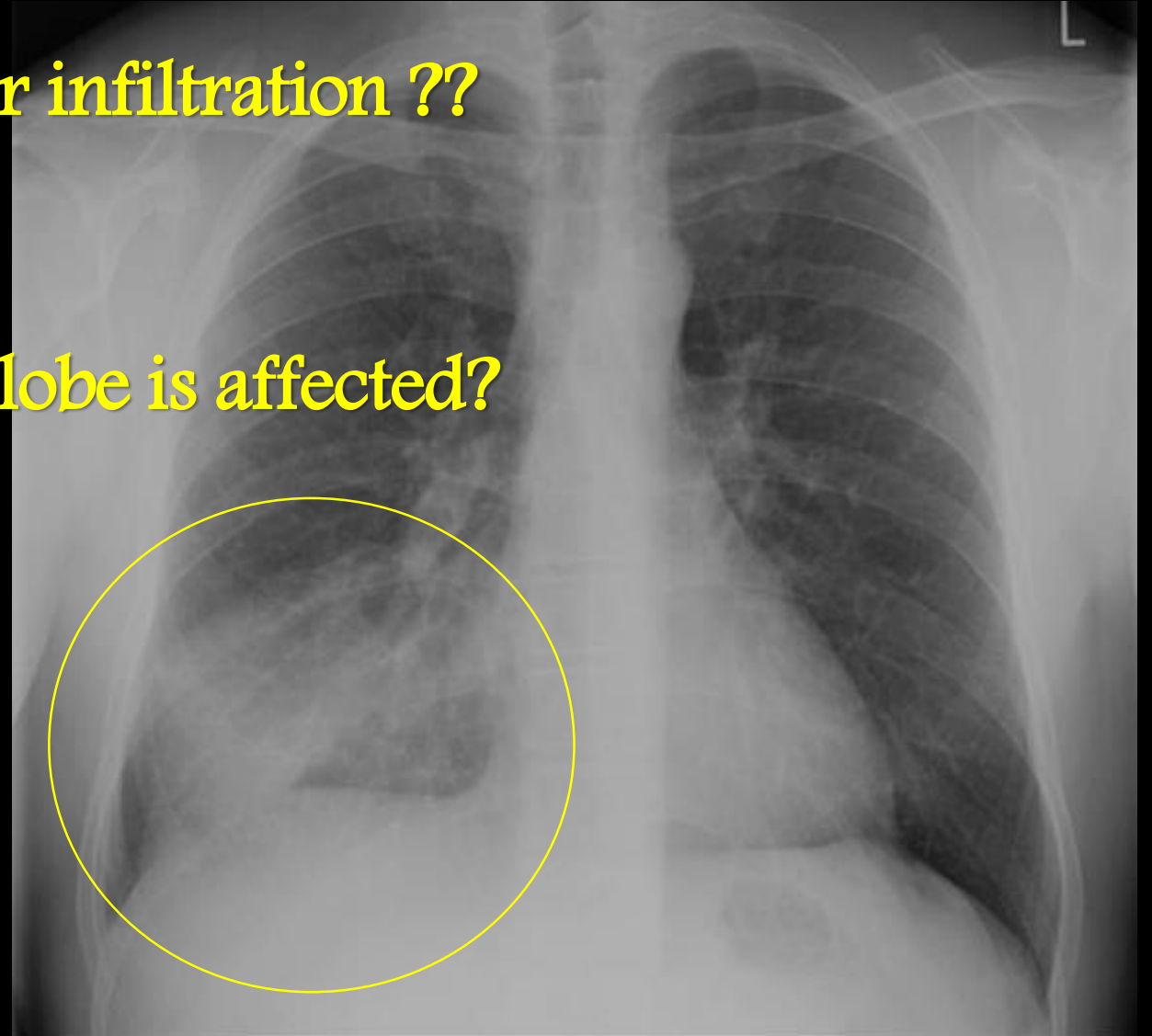
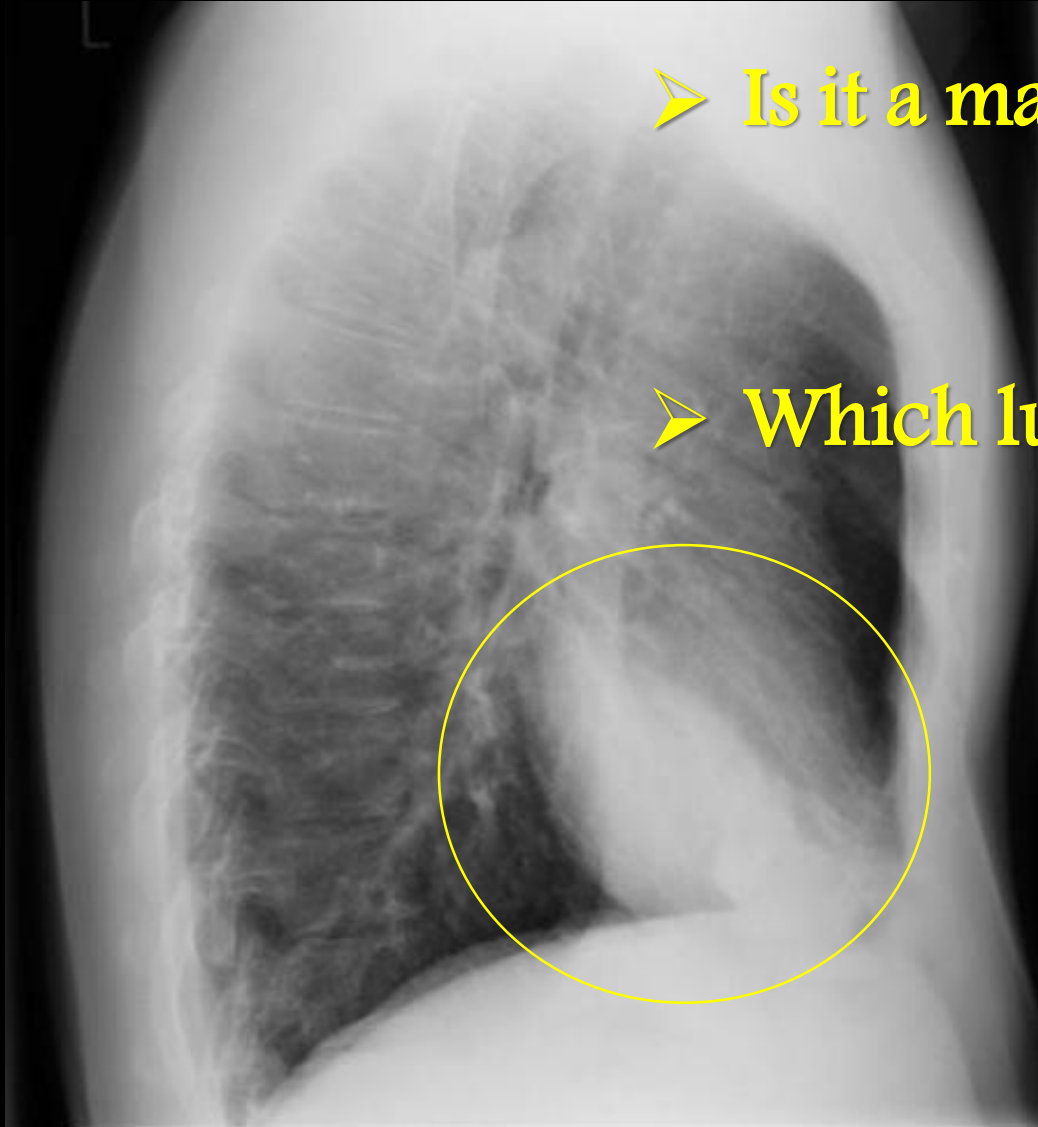
30 year-old with fever.



30 year-old with fever.

➤ Is it a mass or infiltration ??

➤ Which lung lobe is affected?



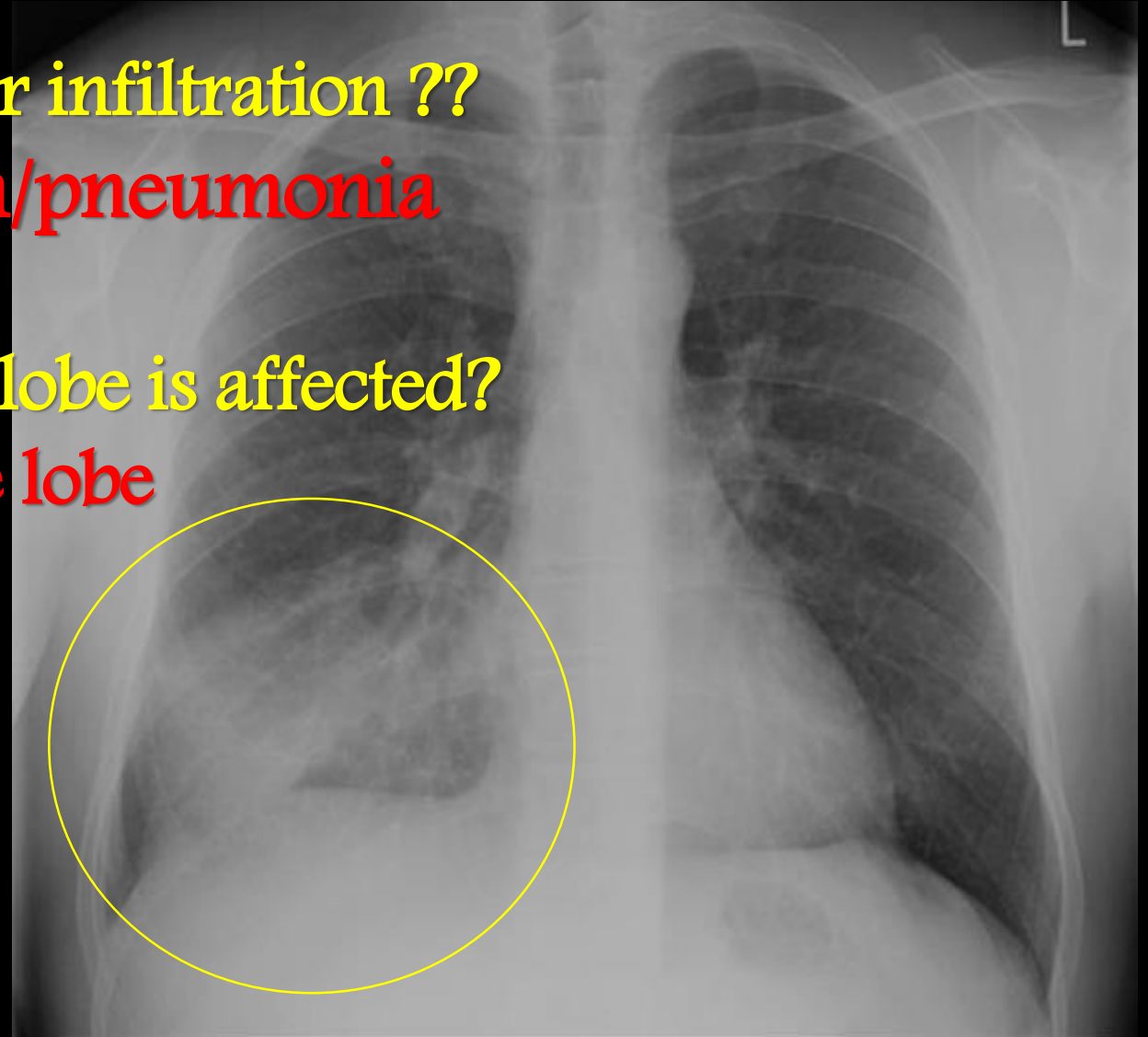
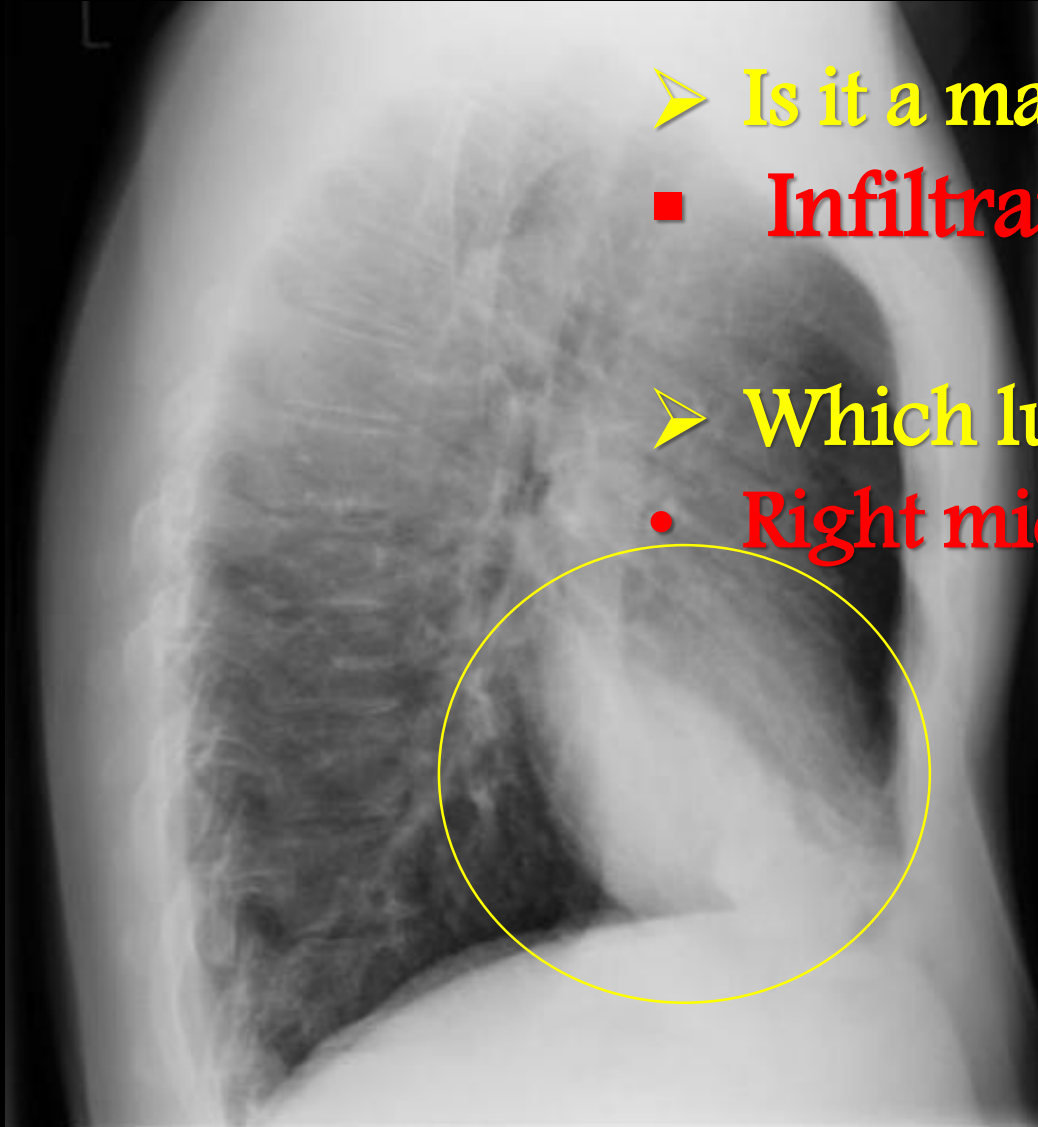
30 year-old with fever.

➤ Is it a mass or infiltration ??

▪ Infiltration/pneumonia

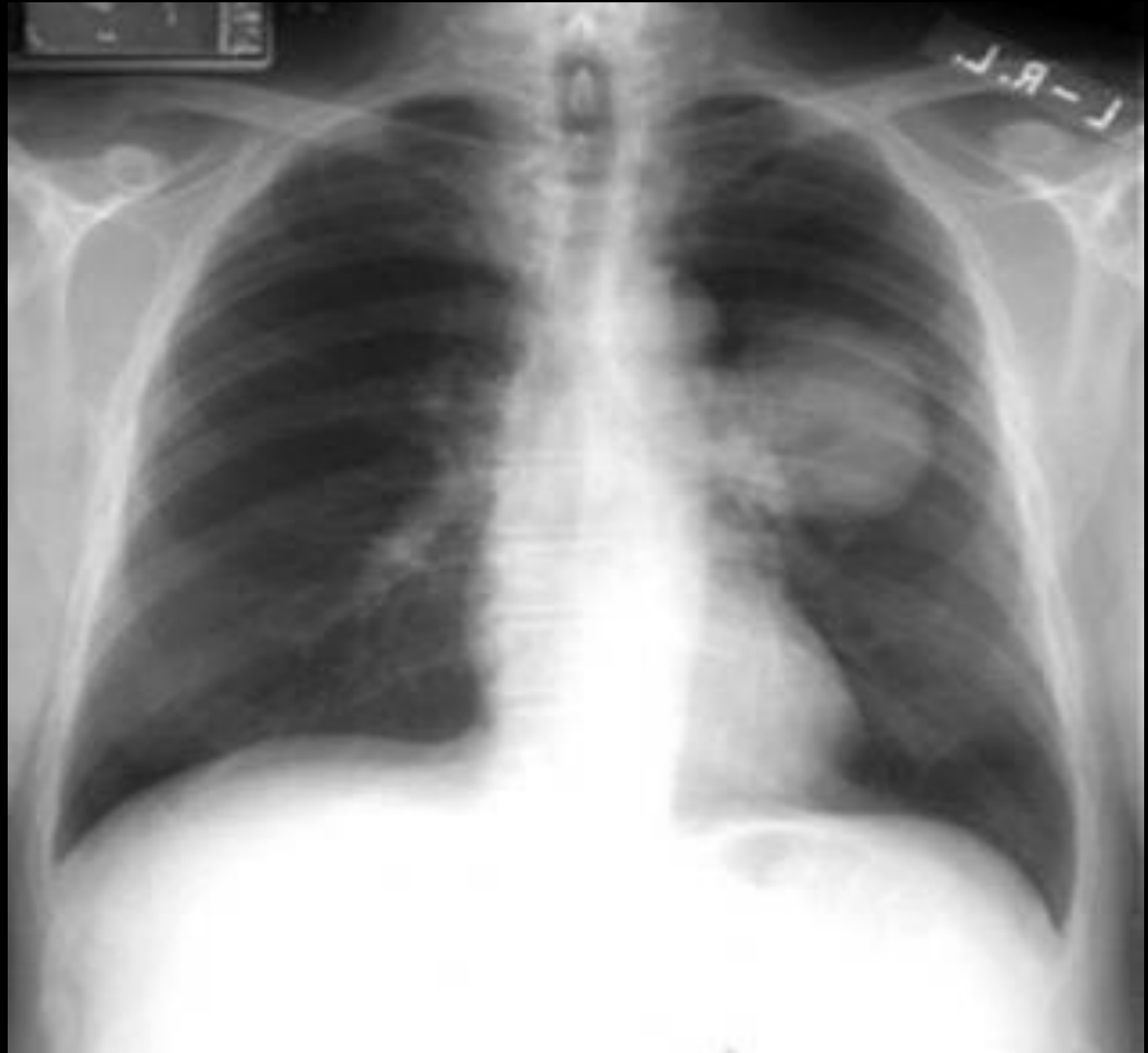➤ Which lung lobe is affected?

• Right middle lobe



50 year-old
smoker.

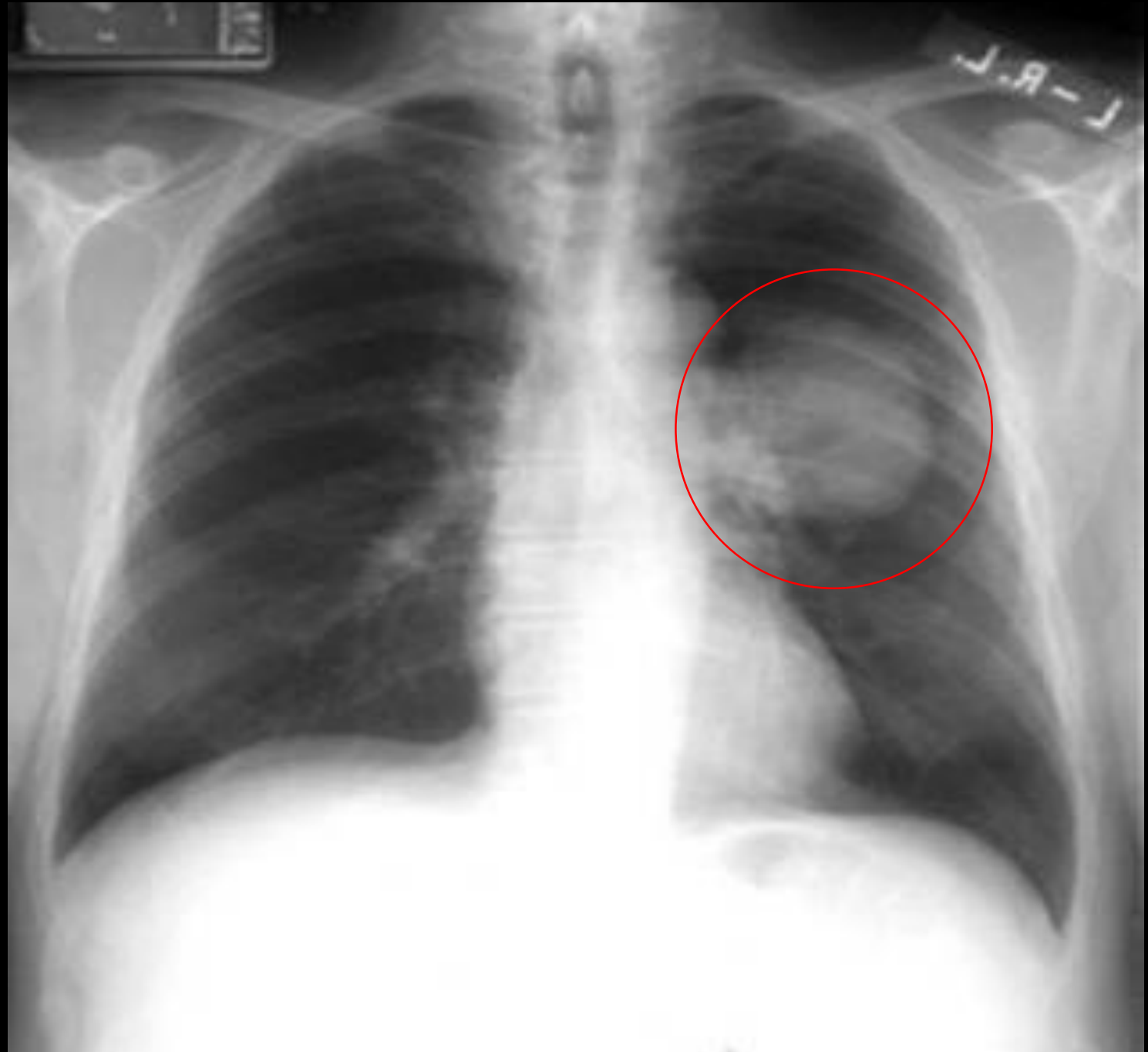
What is the most
likely diagnosis?

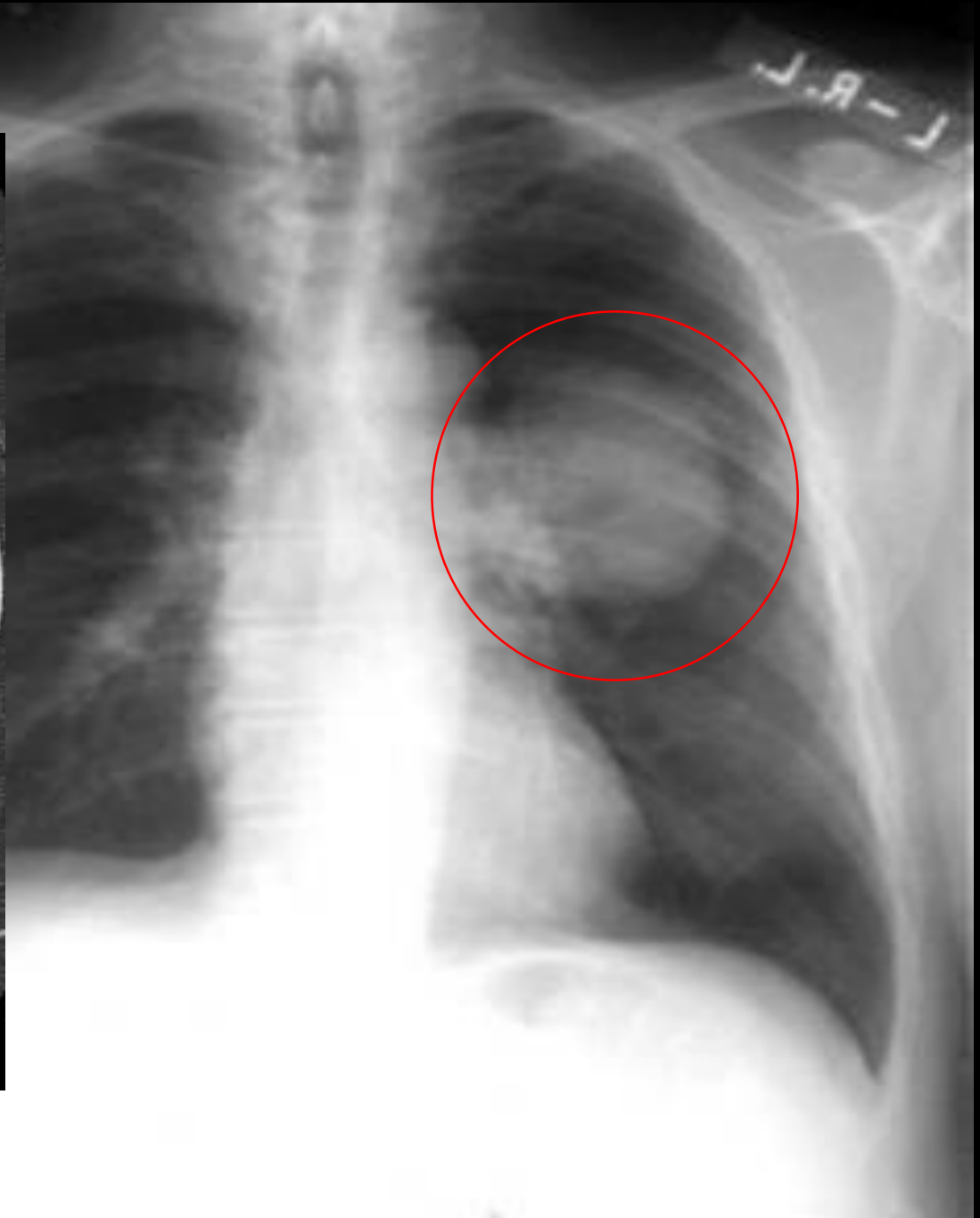
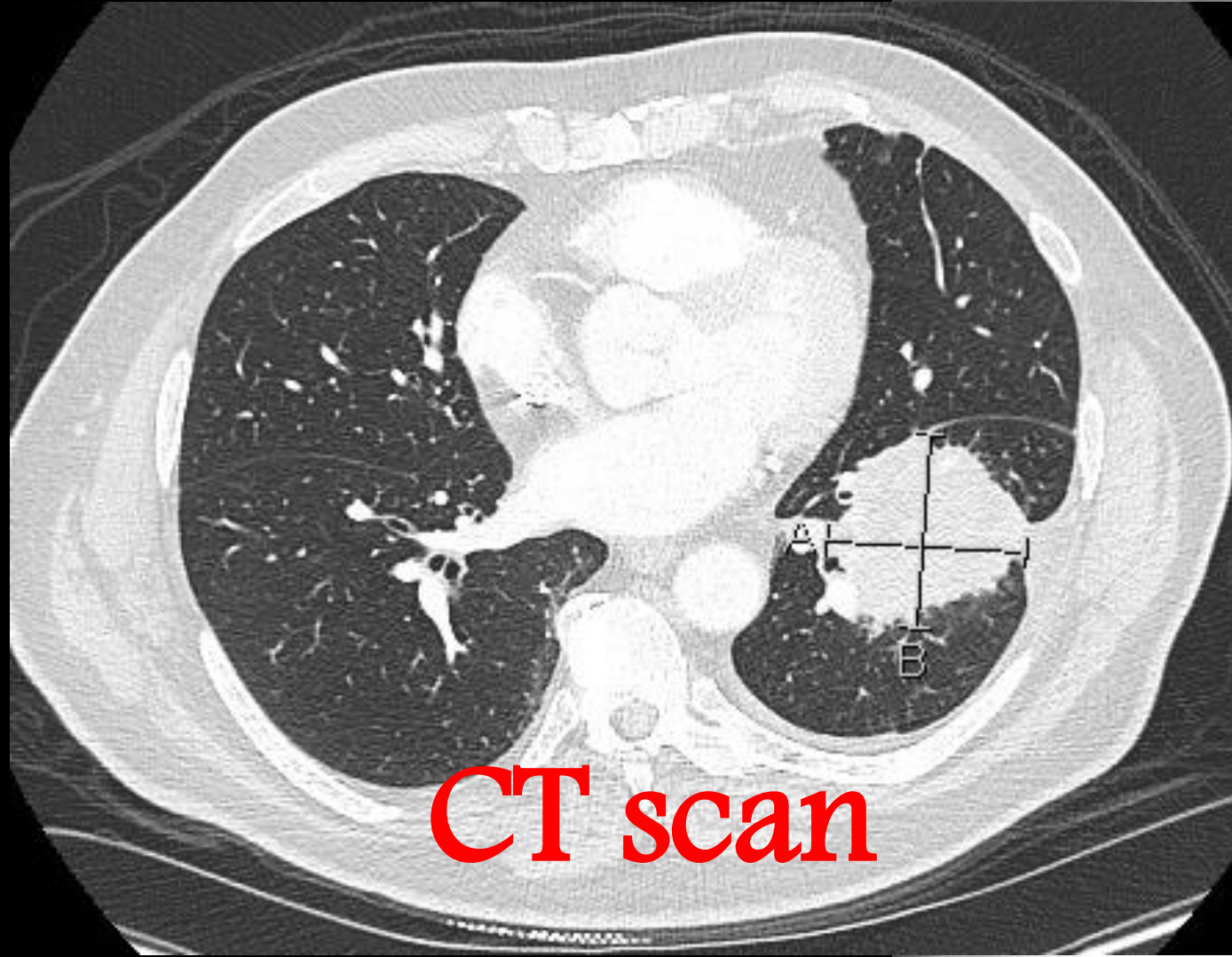


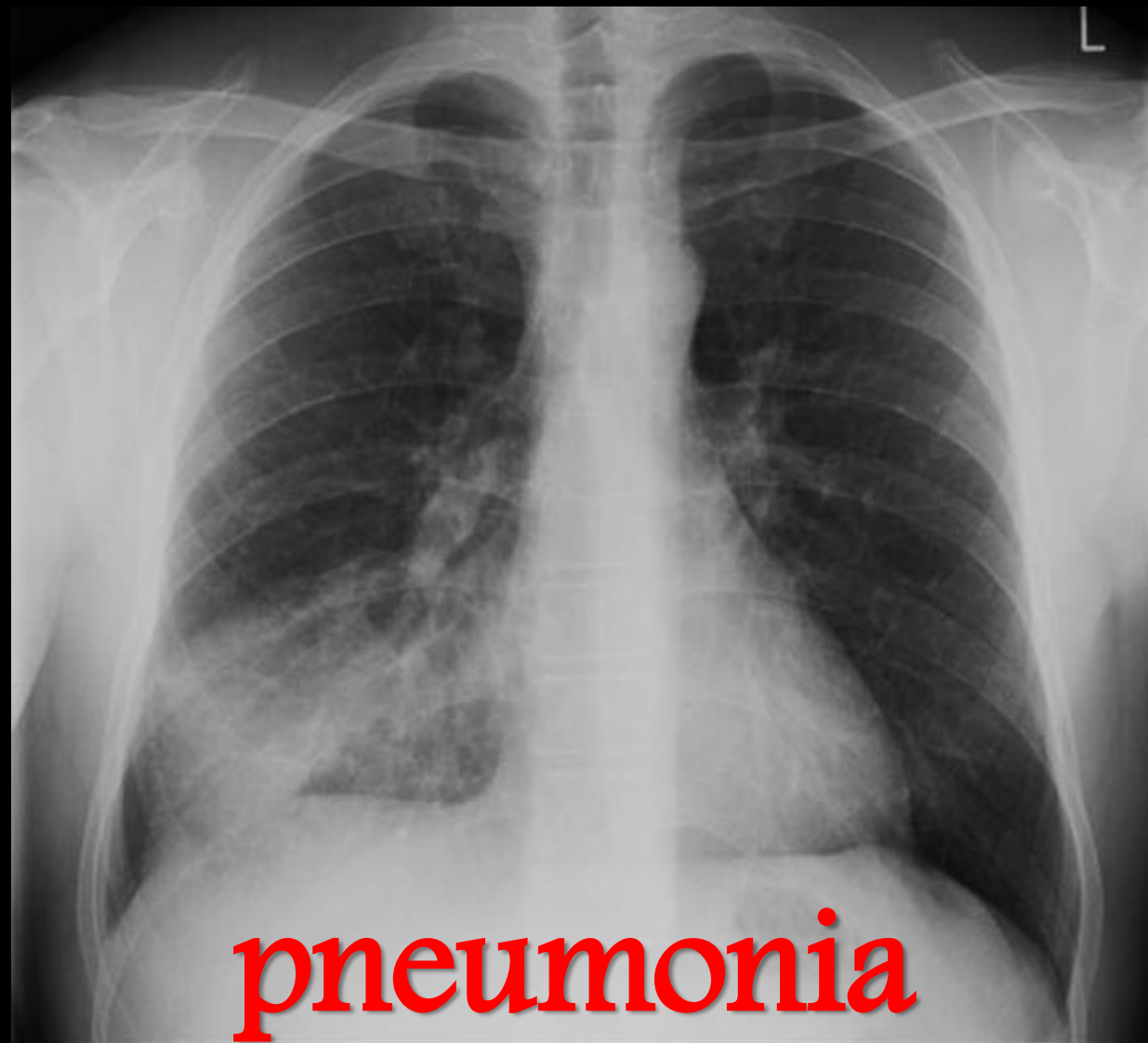
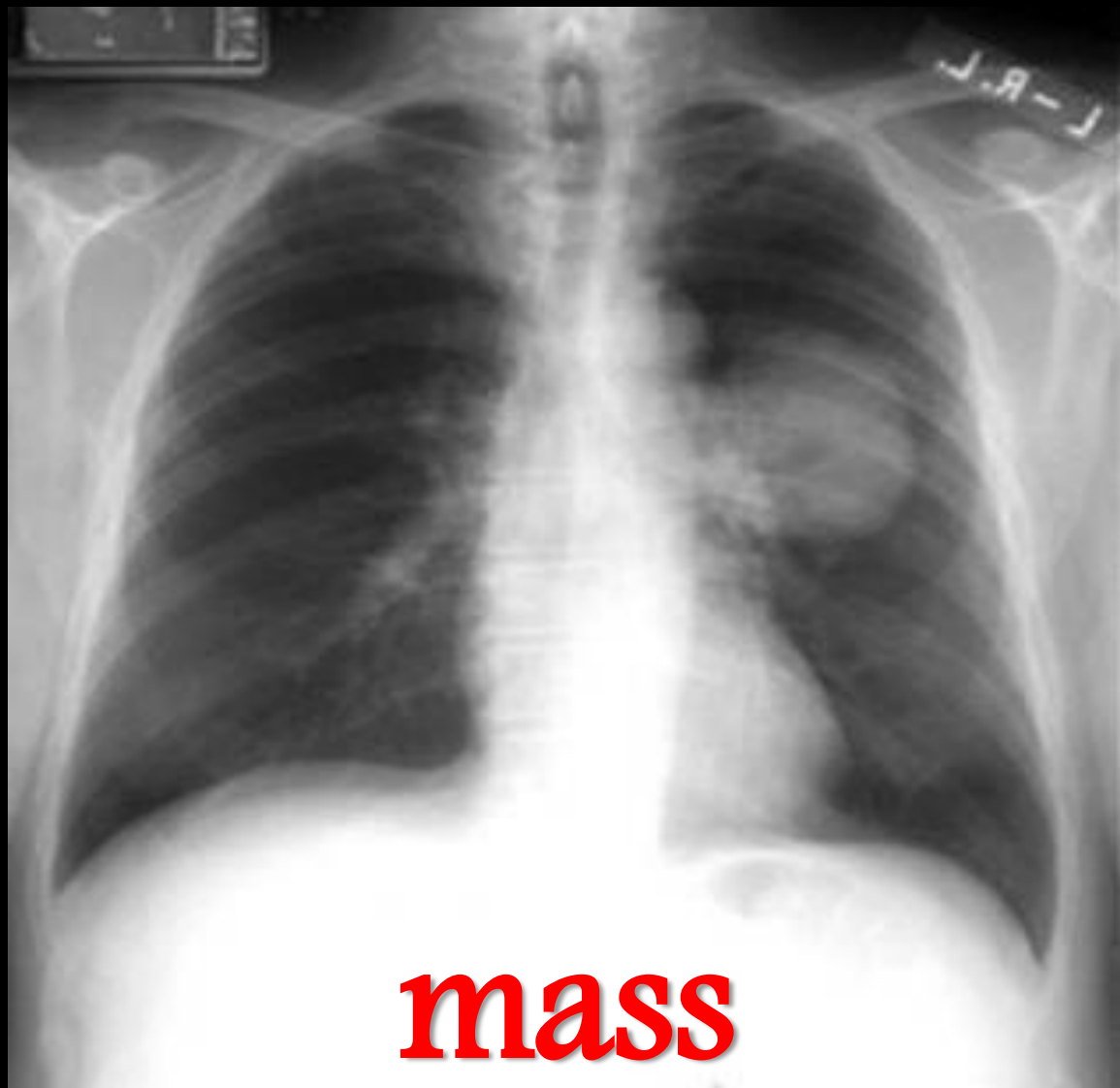
50 year-old
smoker.

What is the most
likely diagnosis?

Left lung mass.

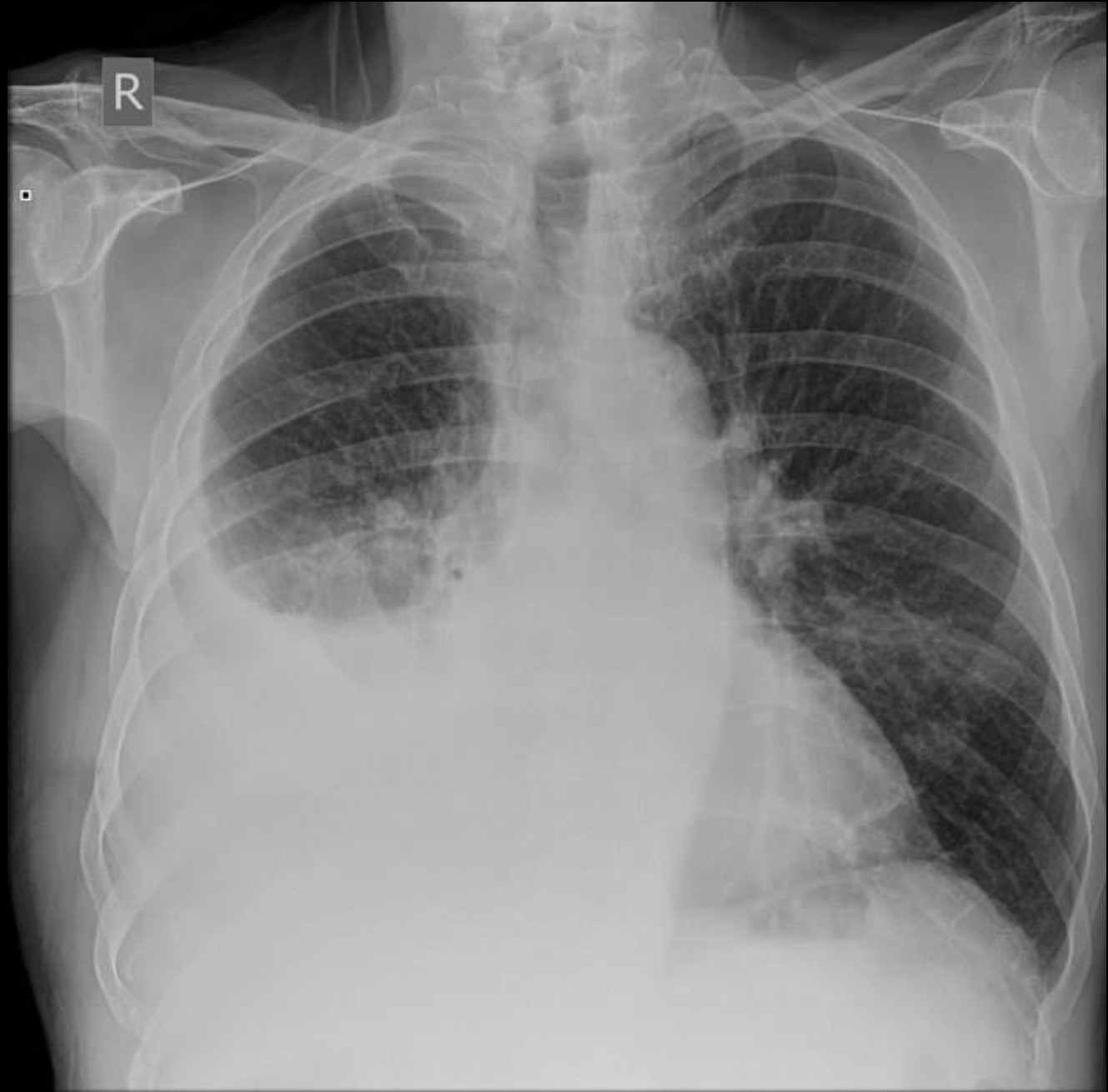






40 year-old female
complaining of
dyspnea.

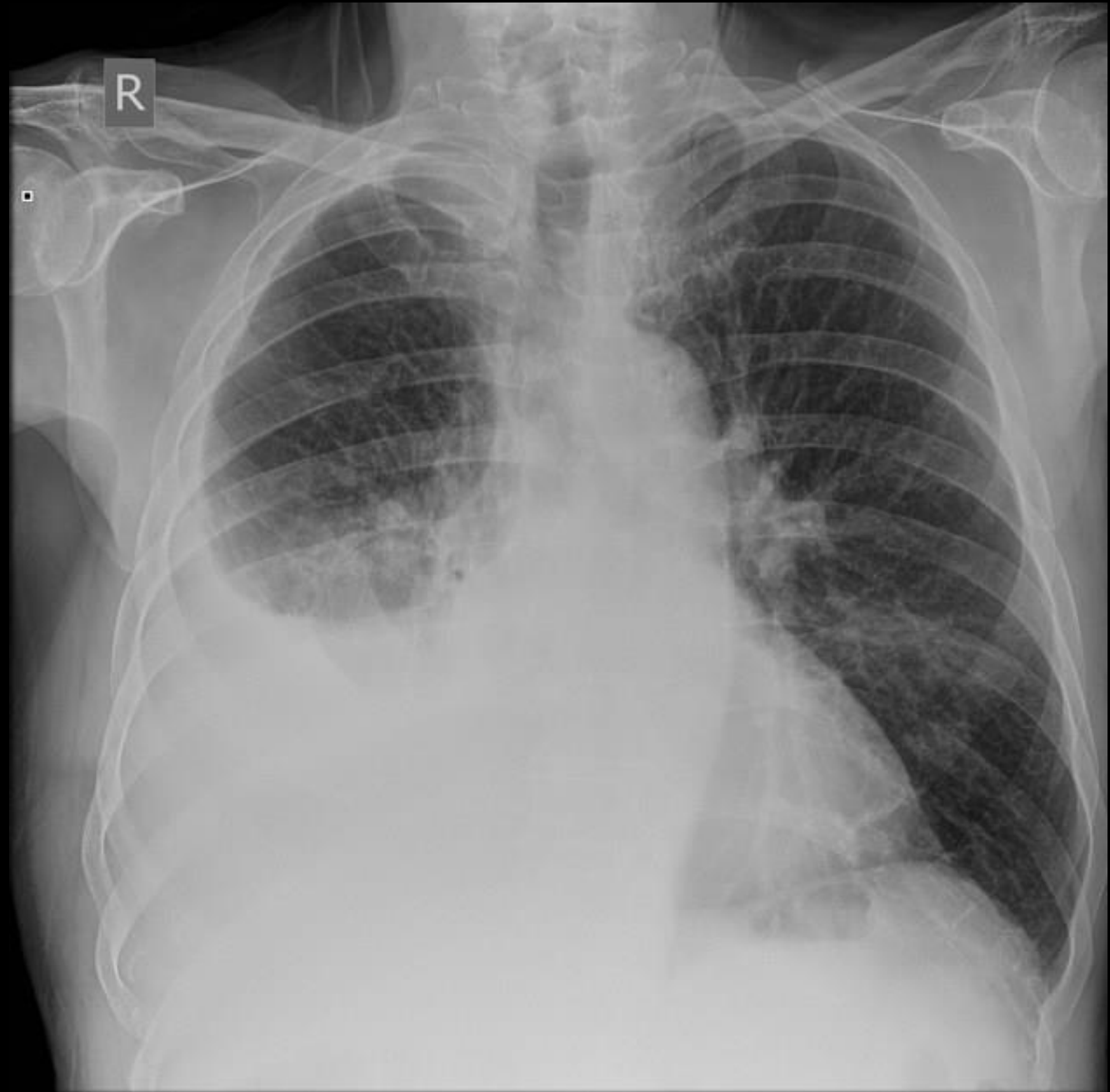
What is the most likely
diagnosis?



40 year-old female
complaining of
dyspnea.

What is the most likely
diagnosis?

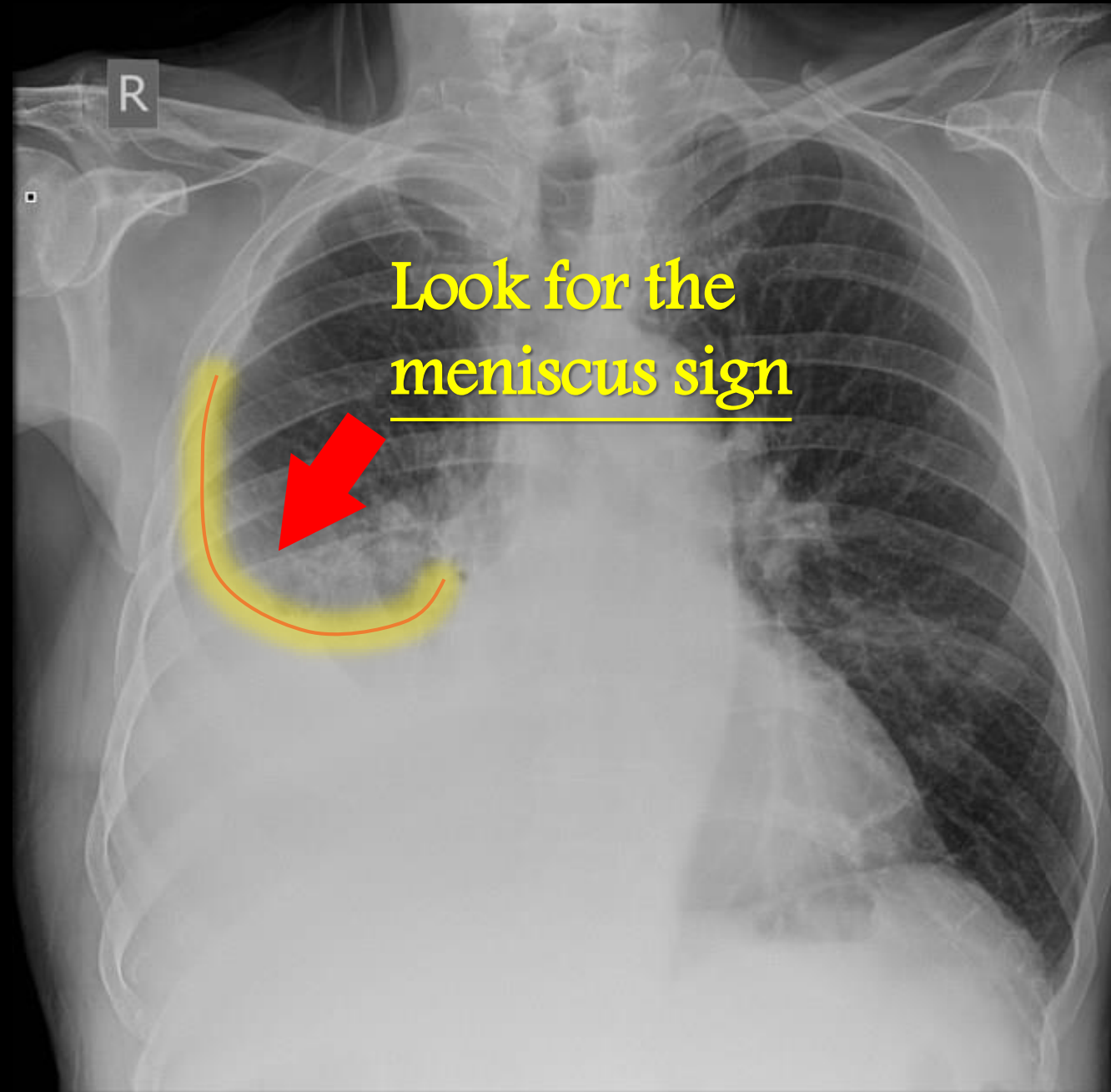
➤ Right pleural effusion.



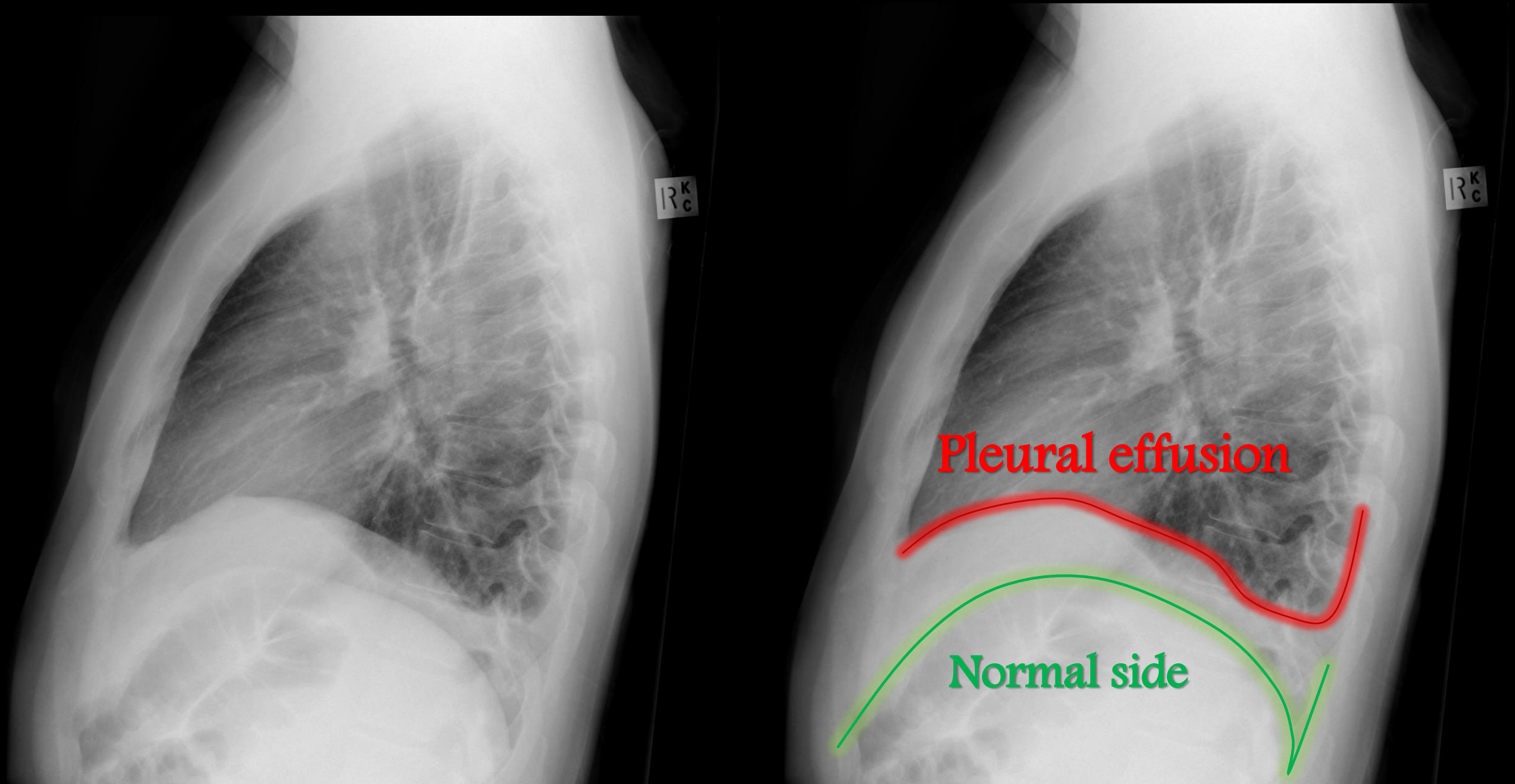
40 year-old female
complaining of
dyspnea.

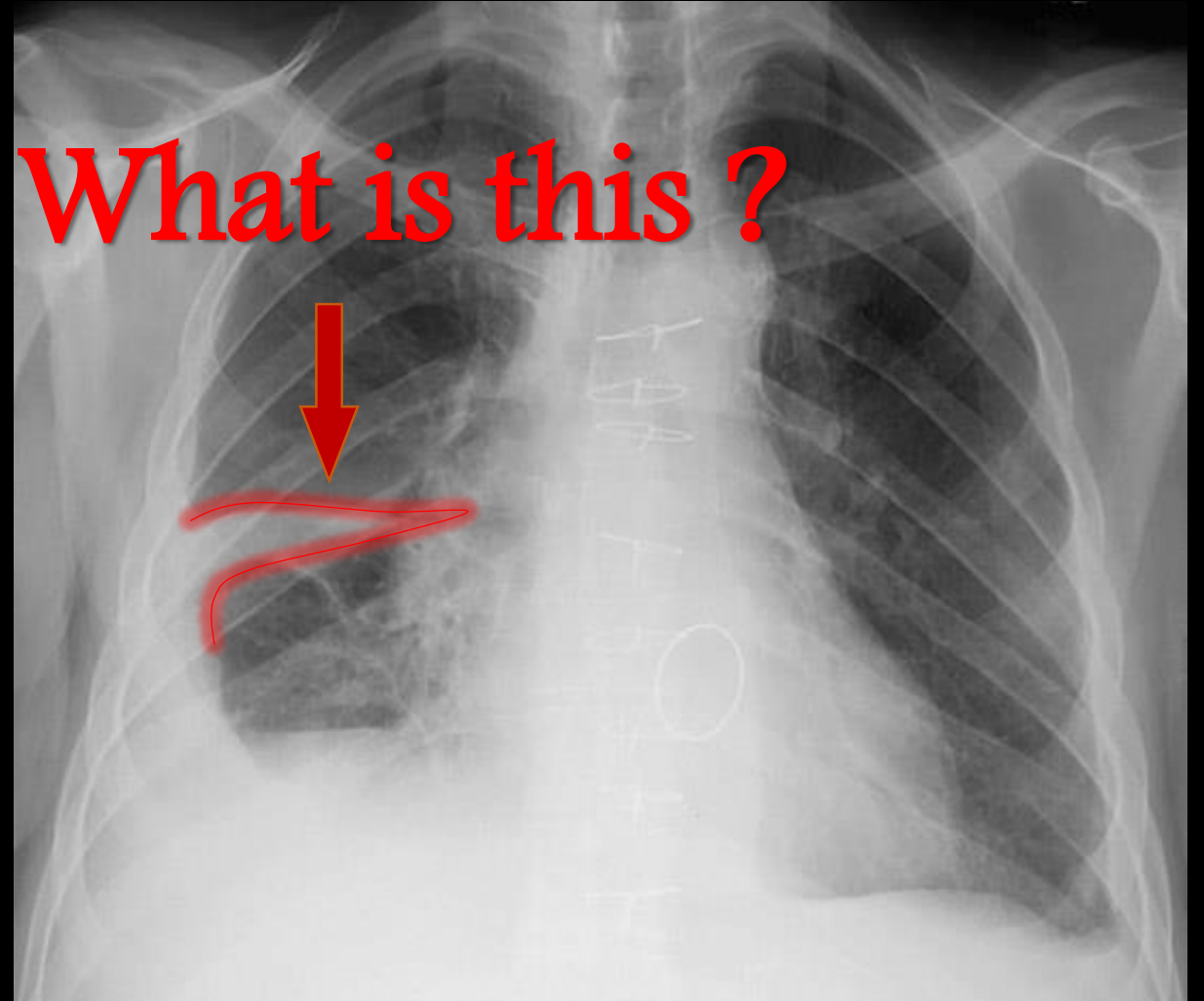
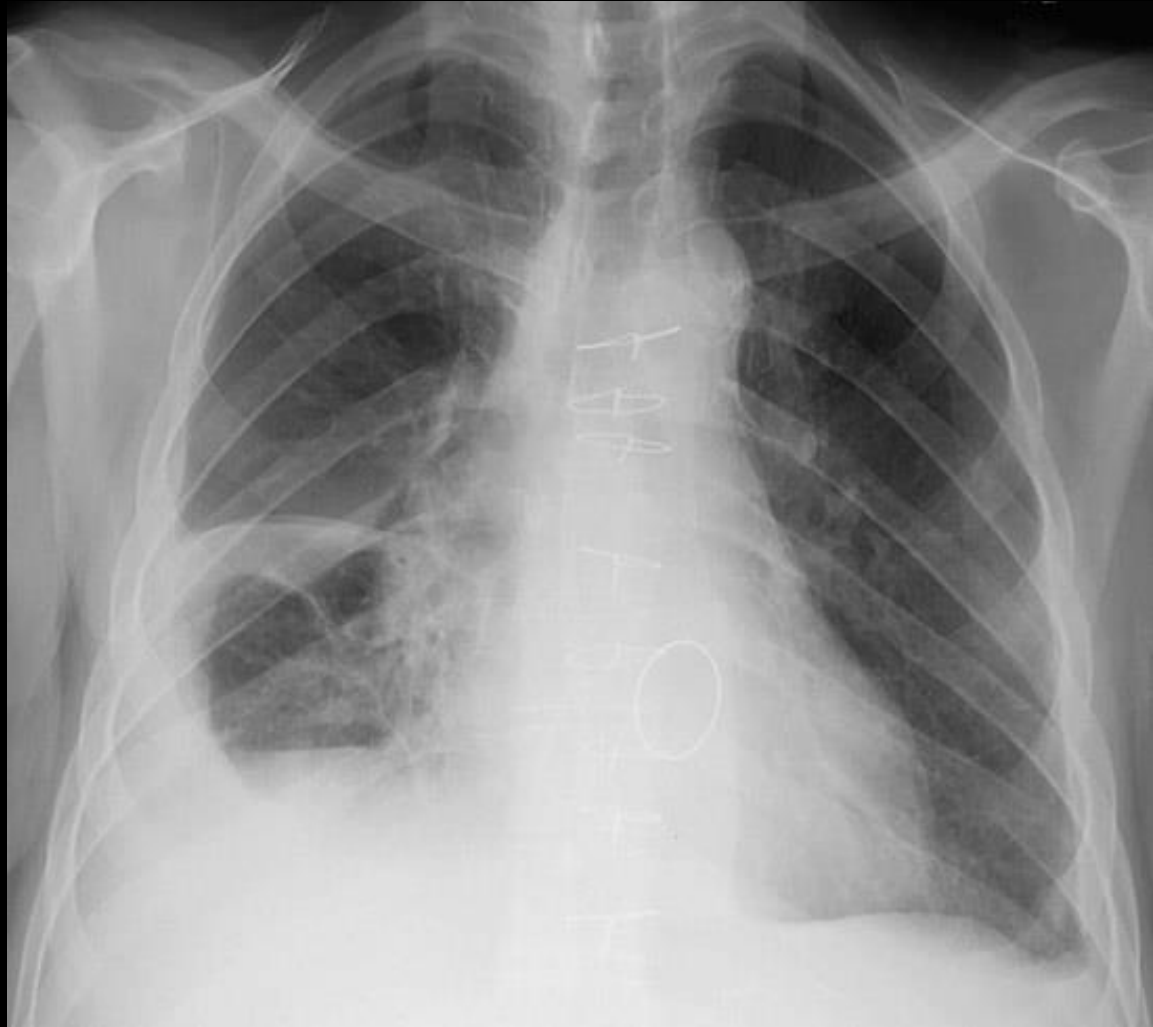What is the most likely
diagnosis?

➤ Right pleural effusion.

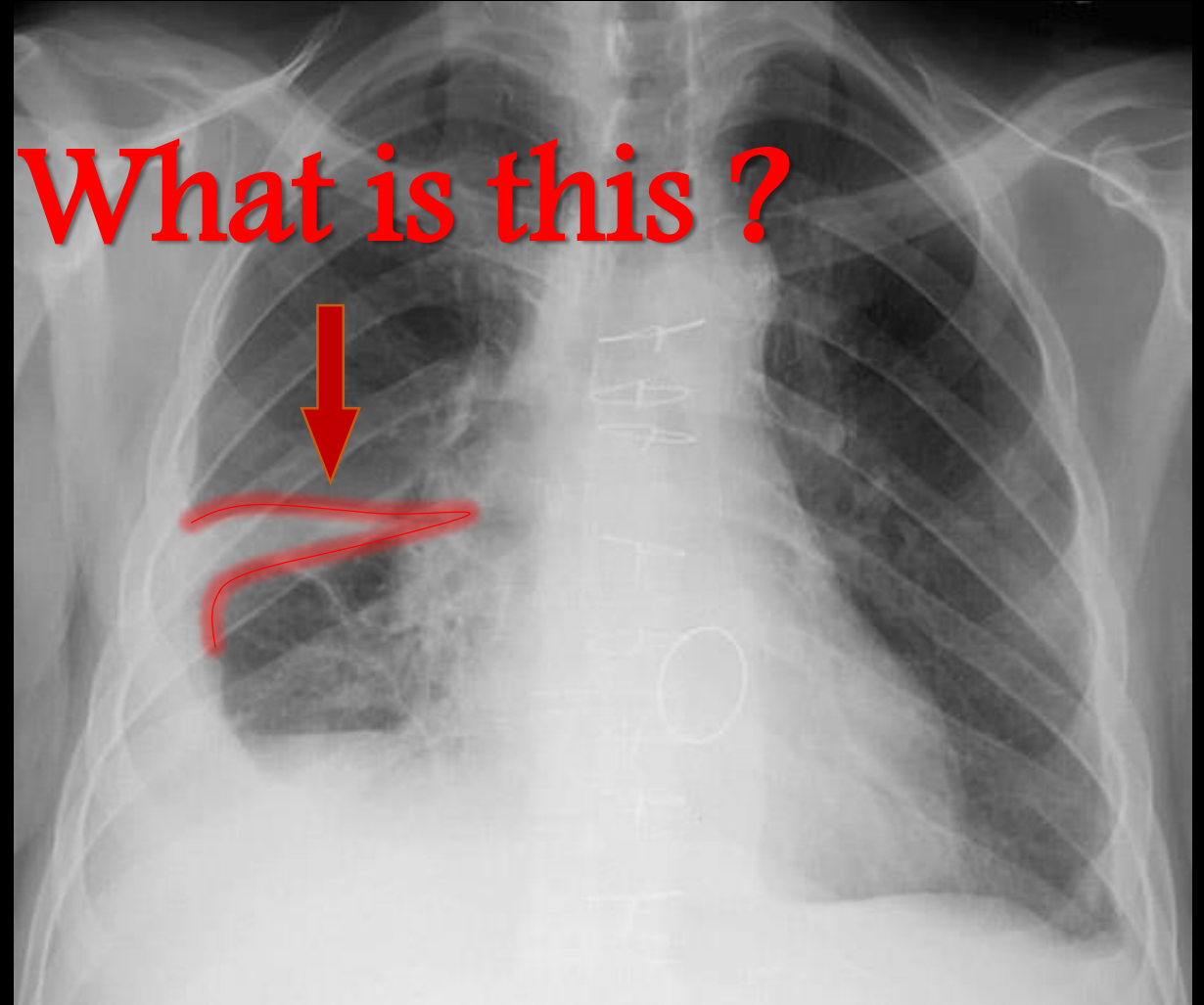
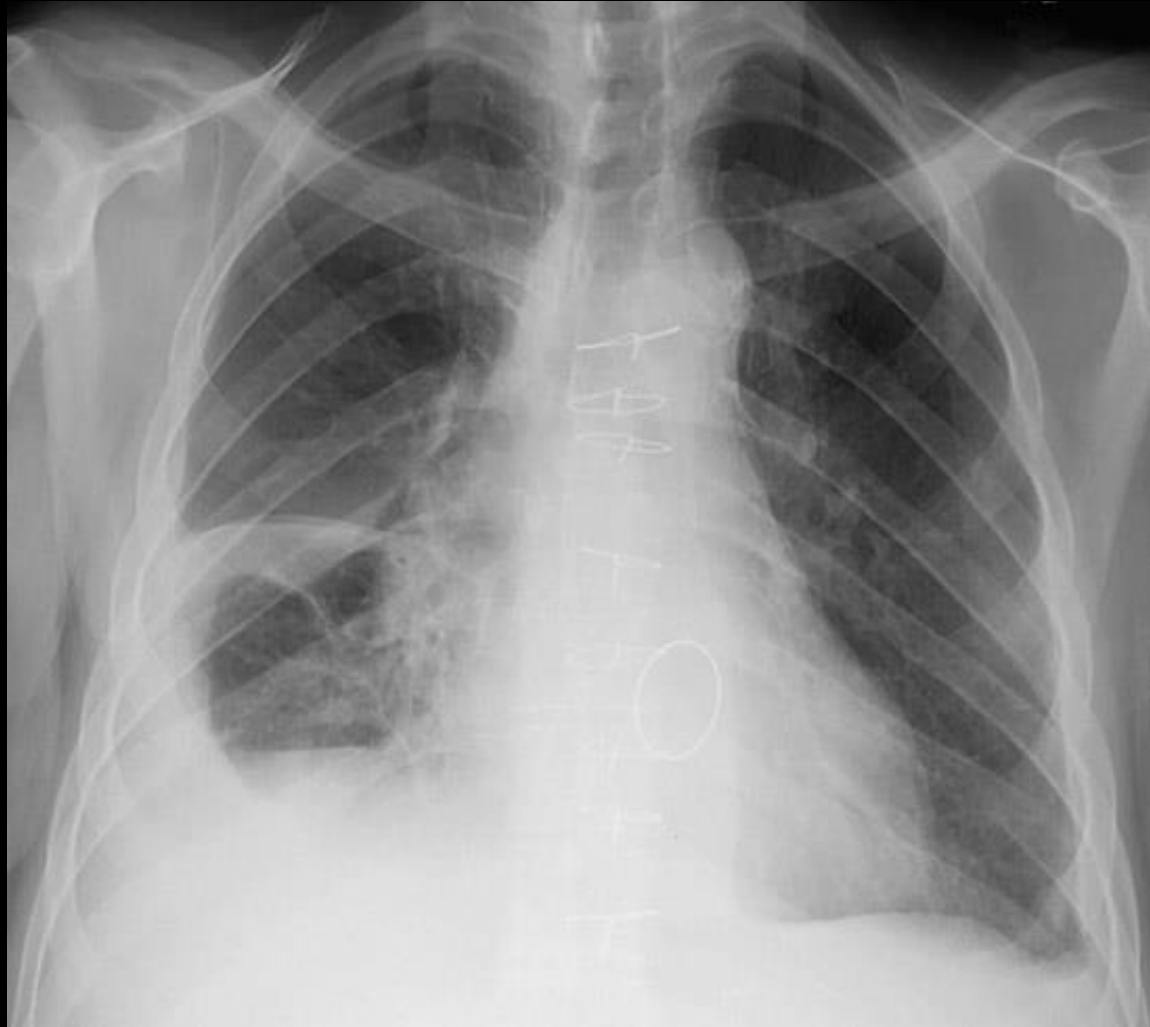

Pleural effusion on lateral view.



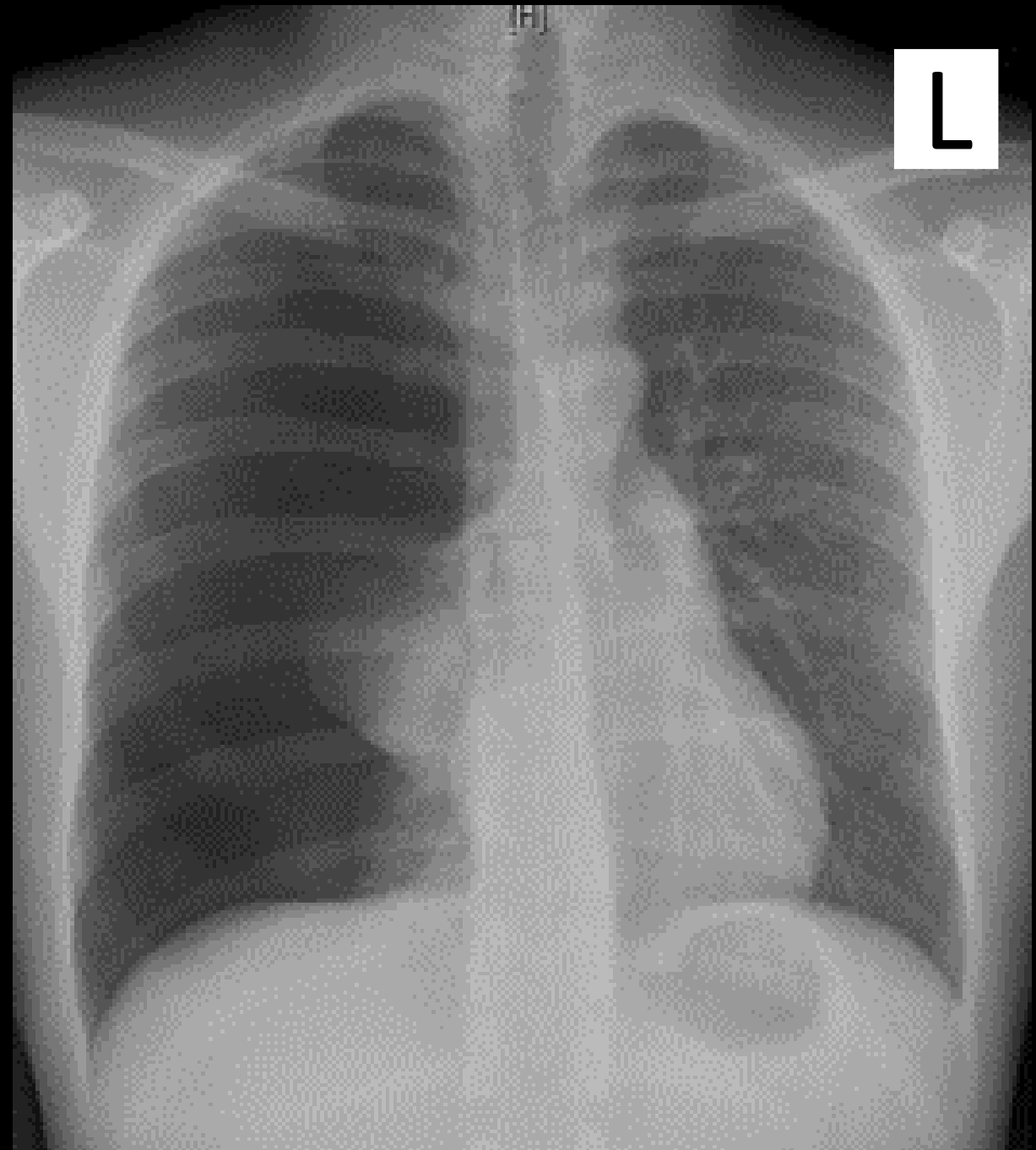


Pleural effusion (fluid tracking into right horizontal fissure)



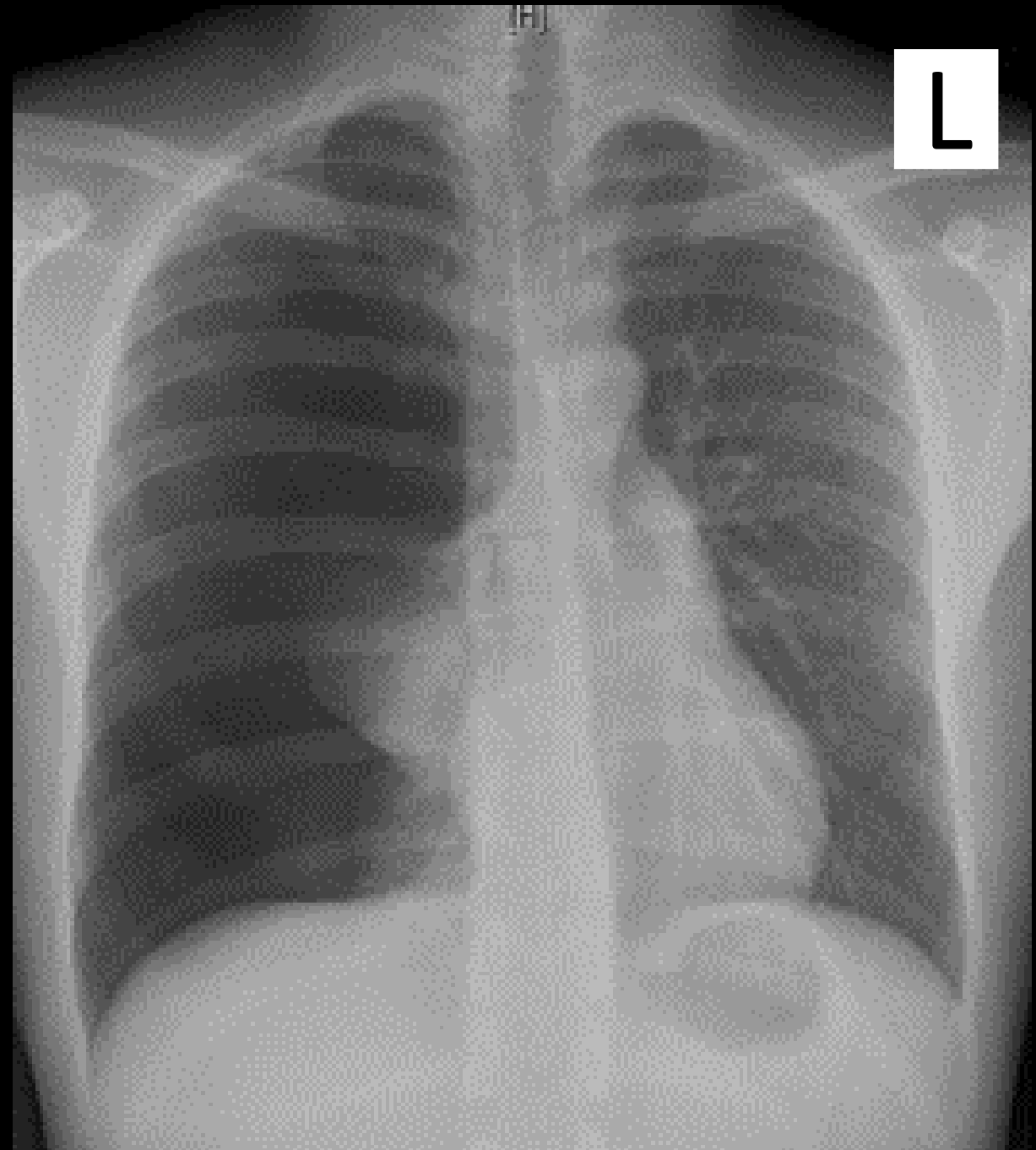
25 year-old male with with chest pain

- Which side of the chest is abnormal?
- What is the diagnosis?

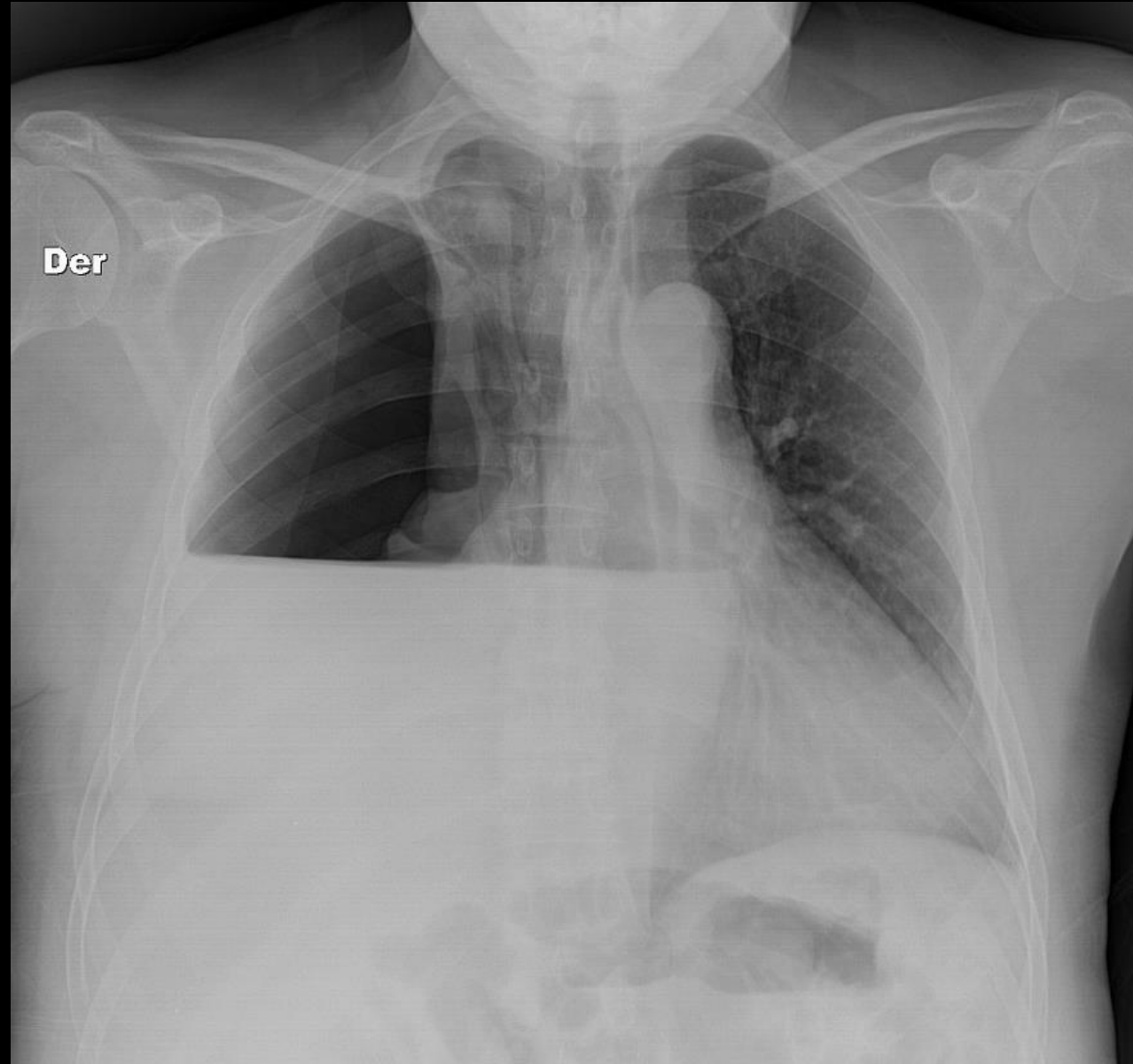


25 year-old male with with chest pain

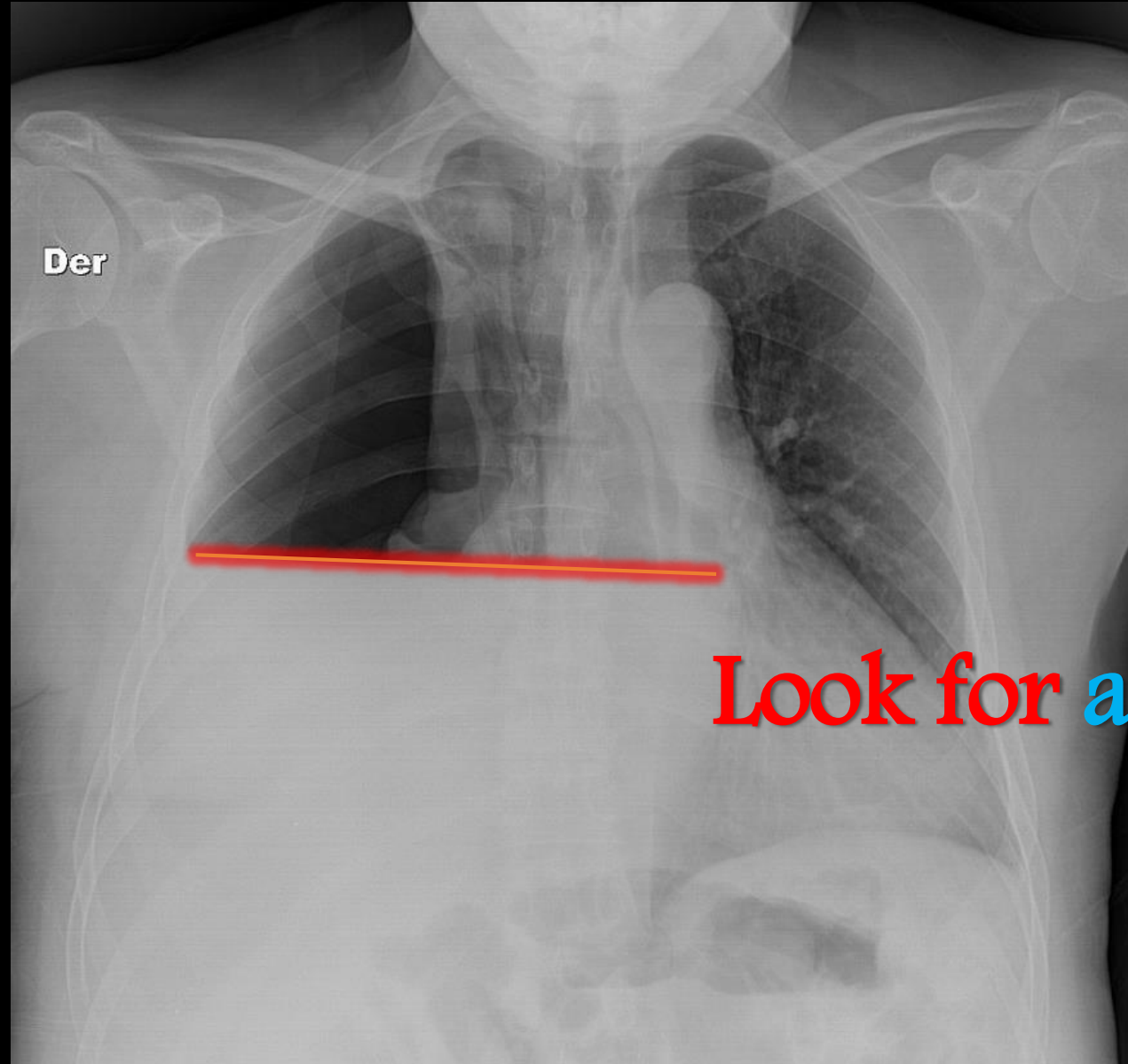
- Which side of the chest is abnormal?
 - Right side.
- What is the diagnosis?
 - Pneumothorax.



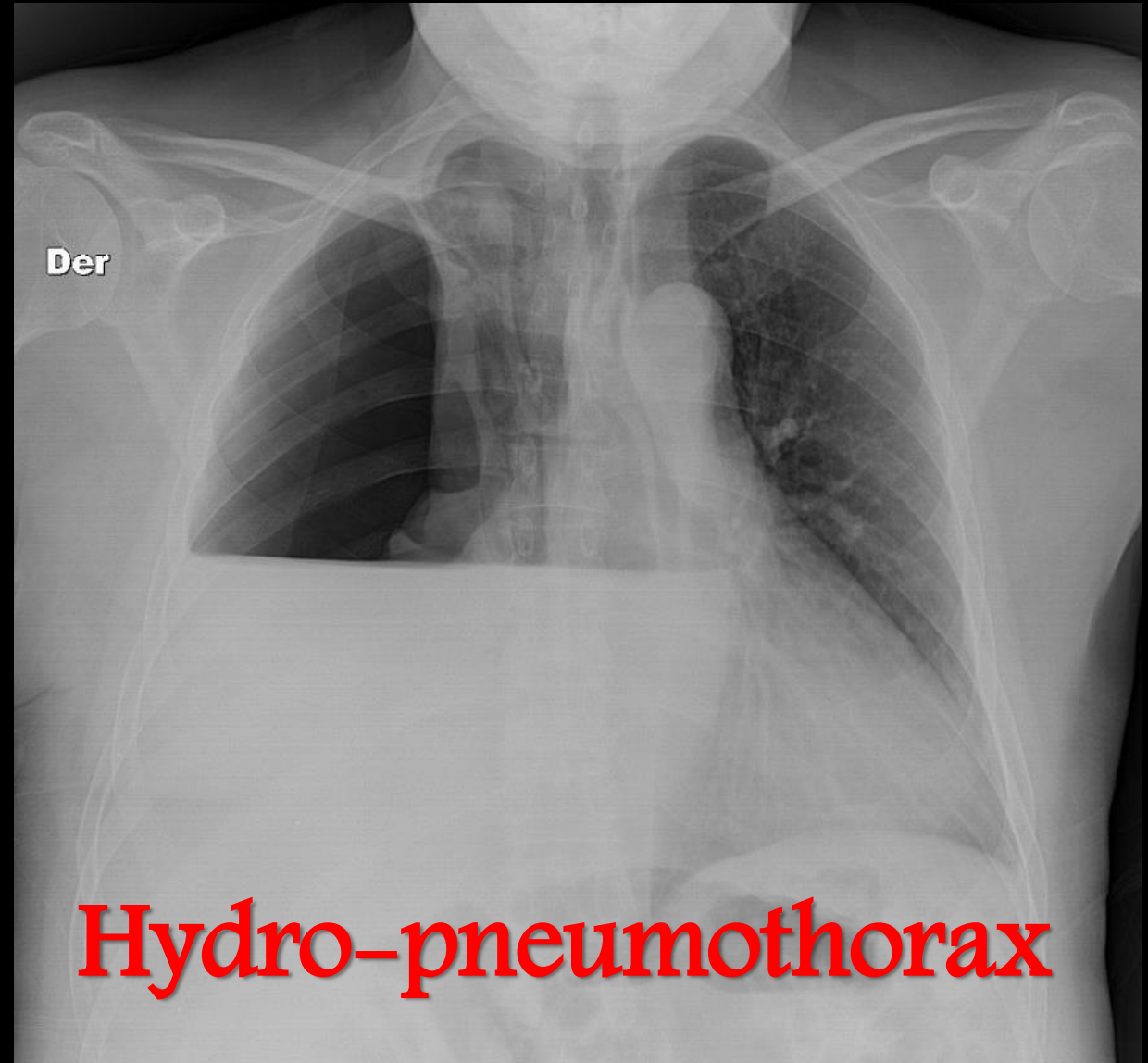
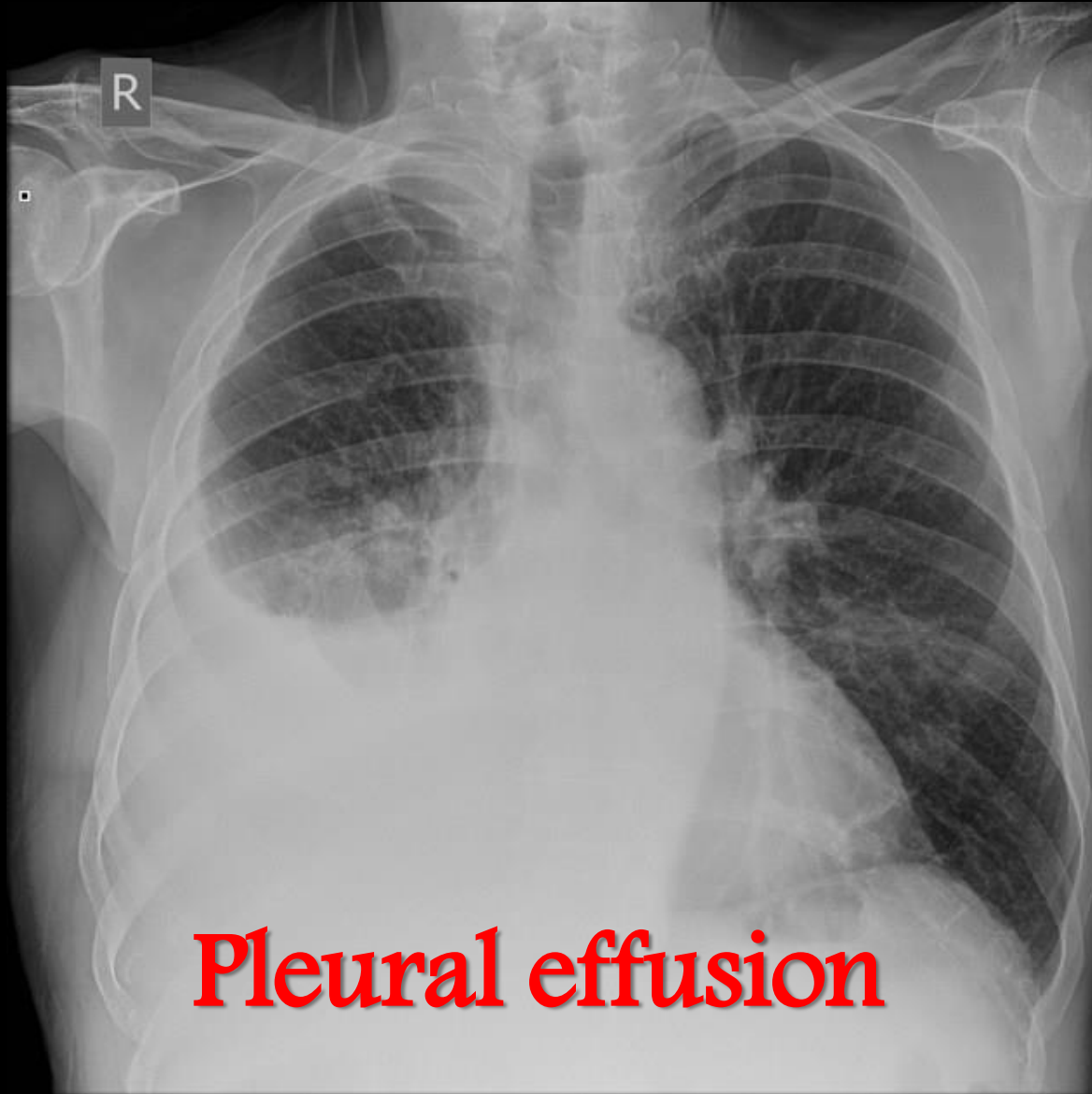
What is the diagnosis ?



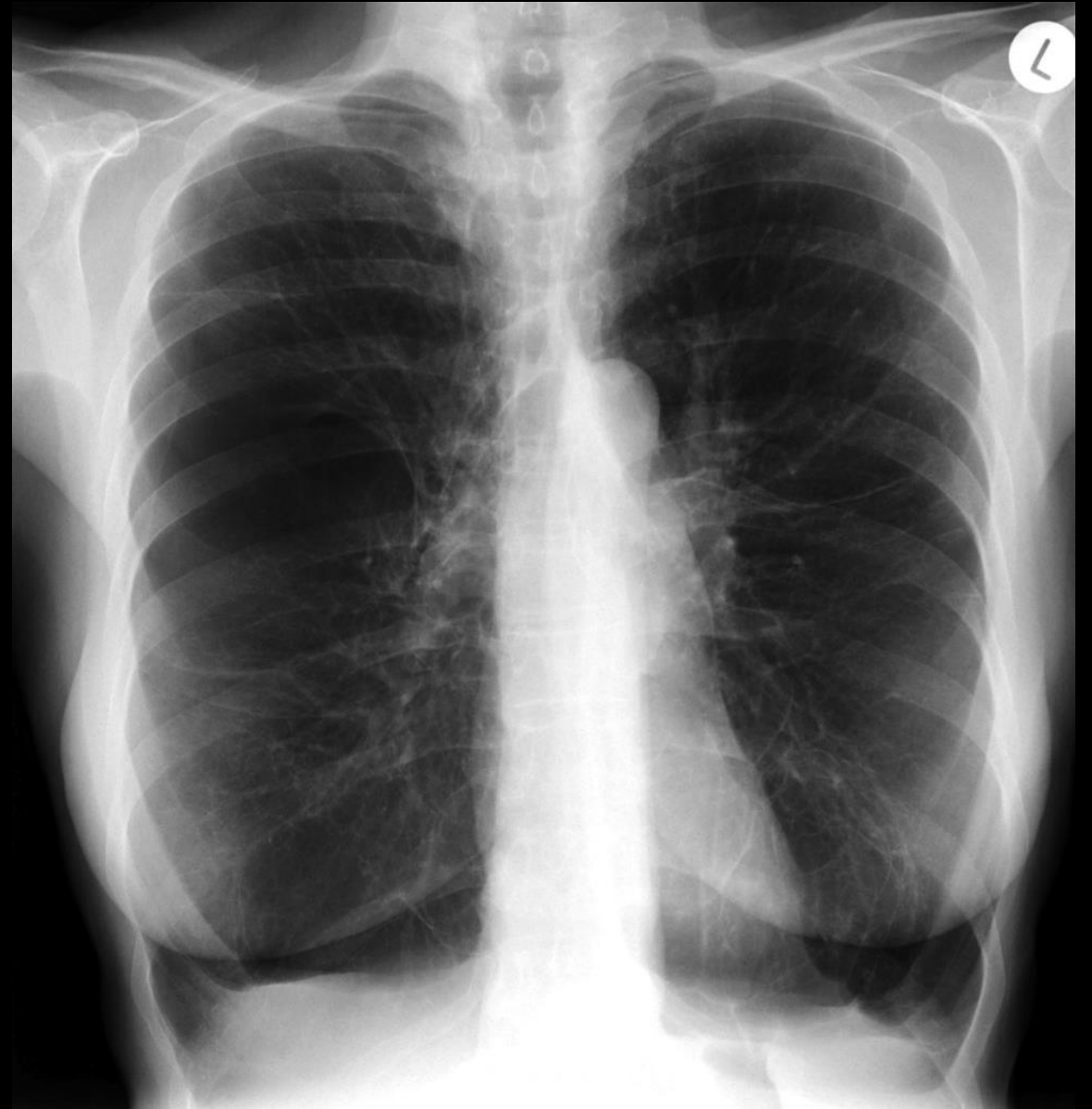
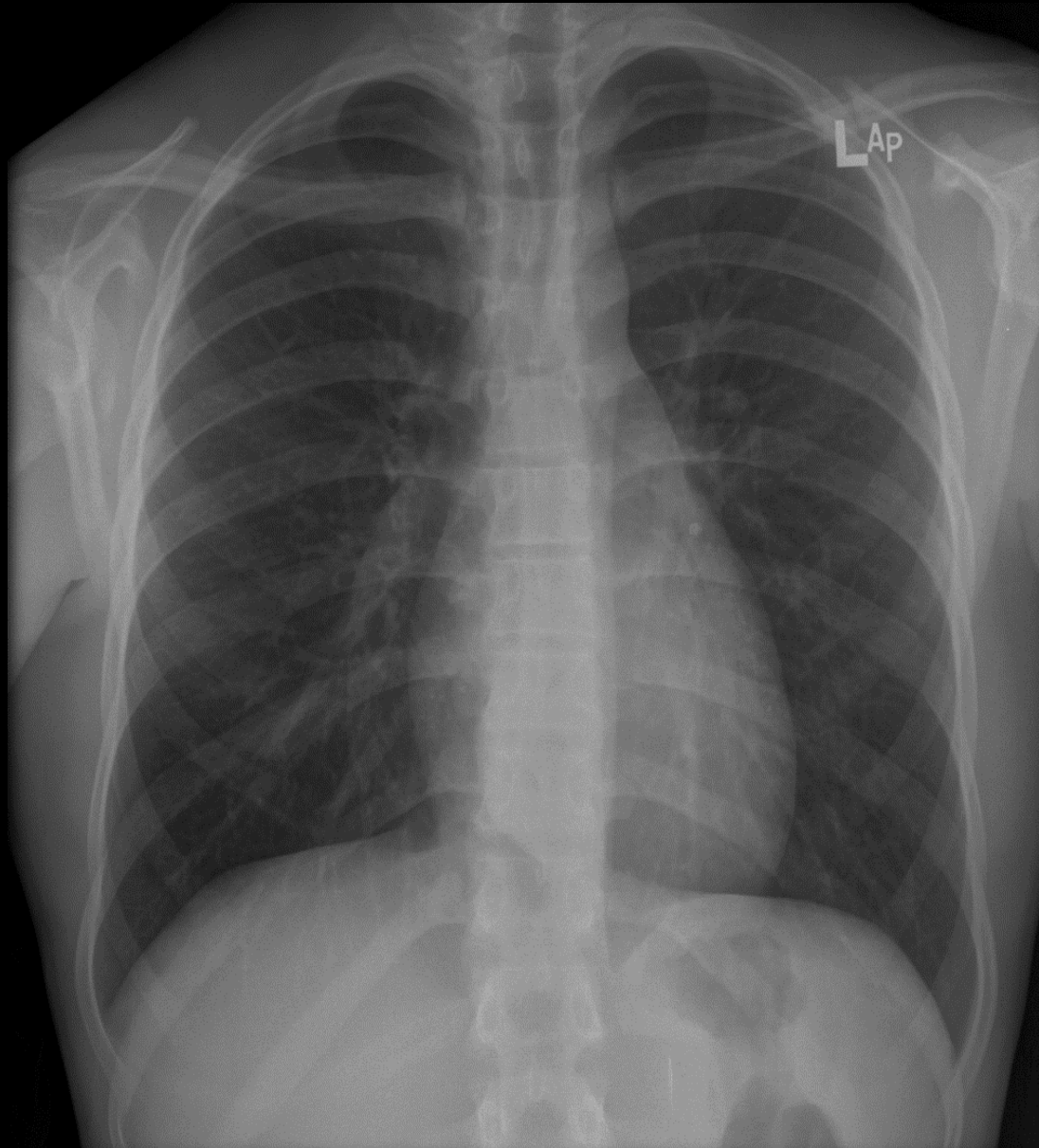
What is the diagnosis ? Hydro-pneumothorax



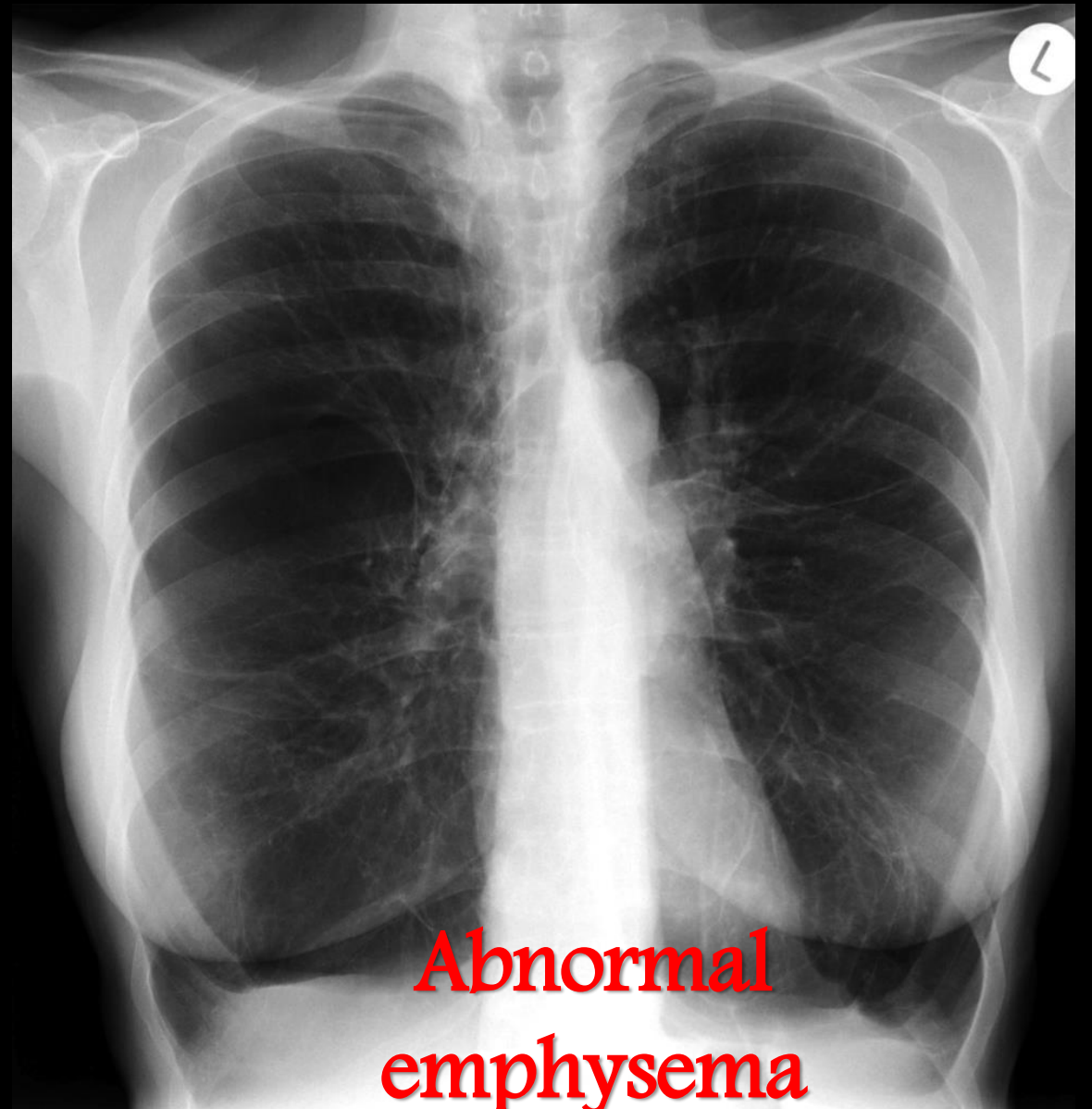
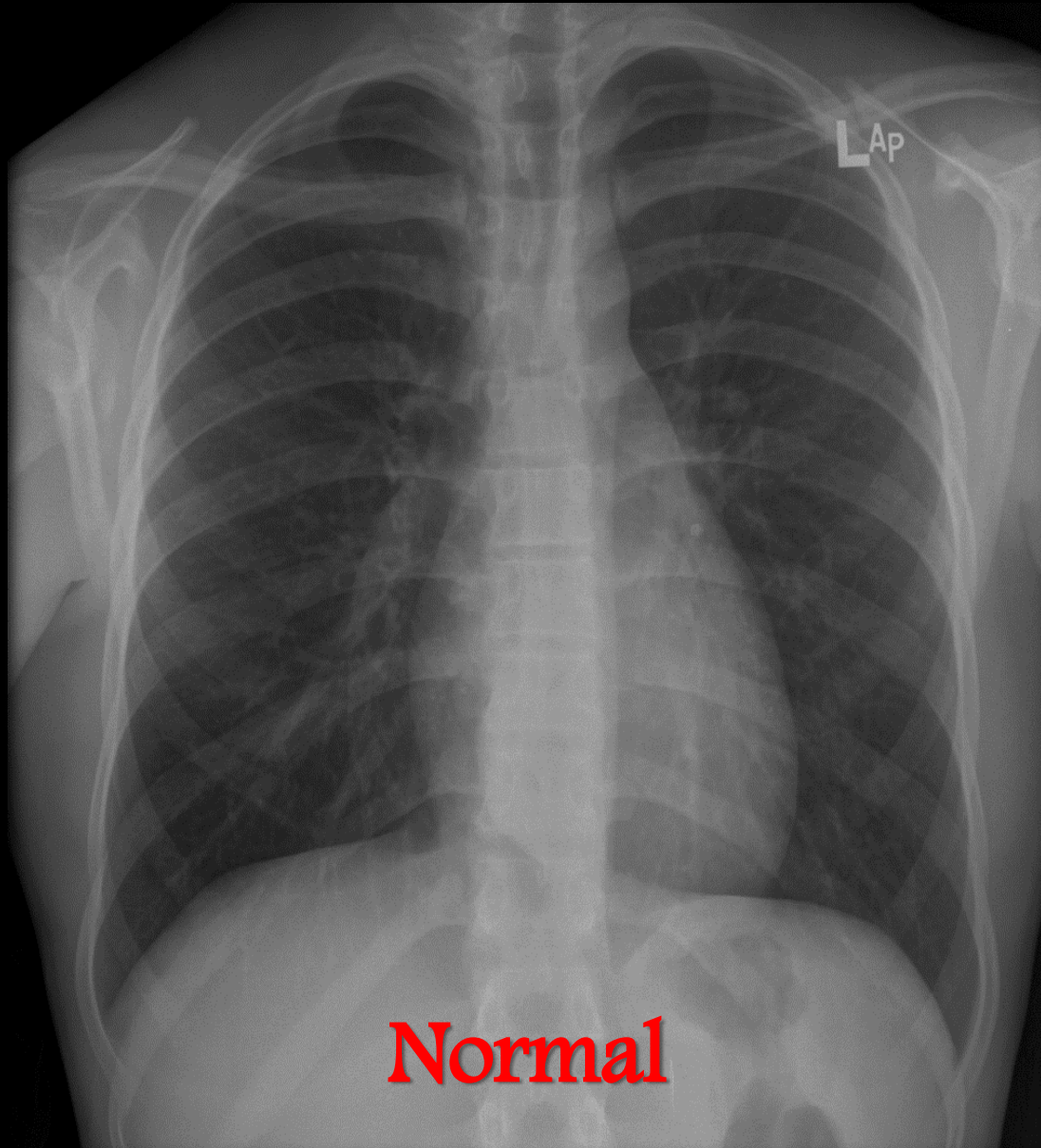
Look for air/fluid level



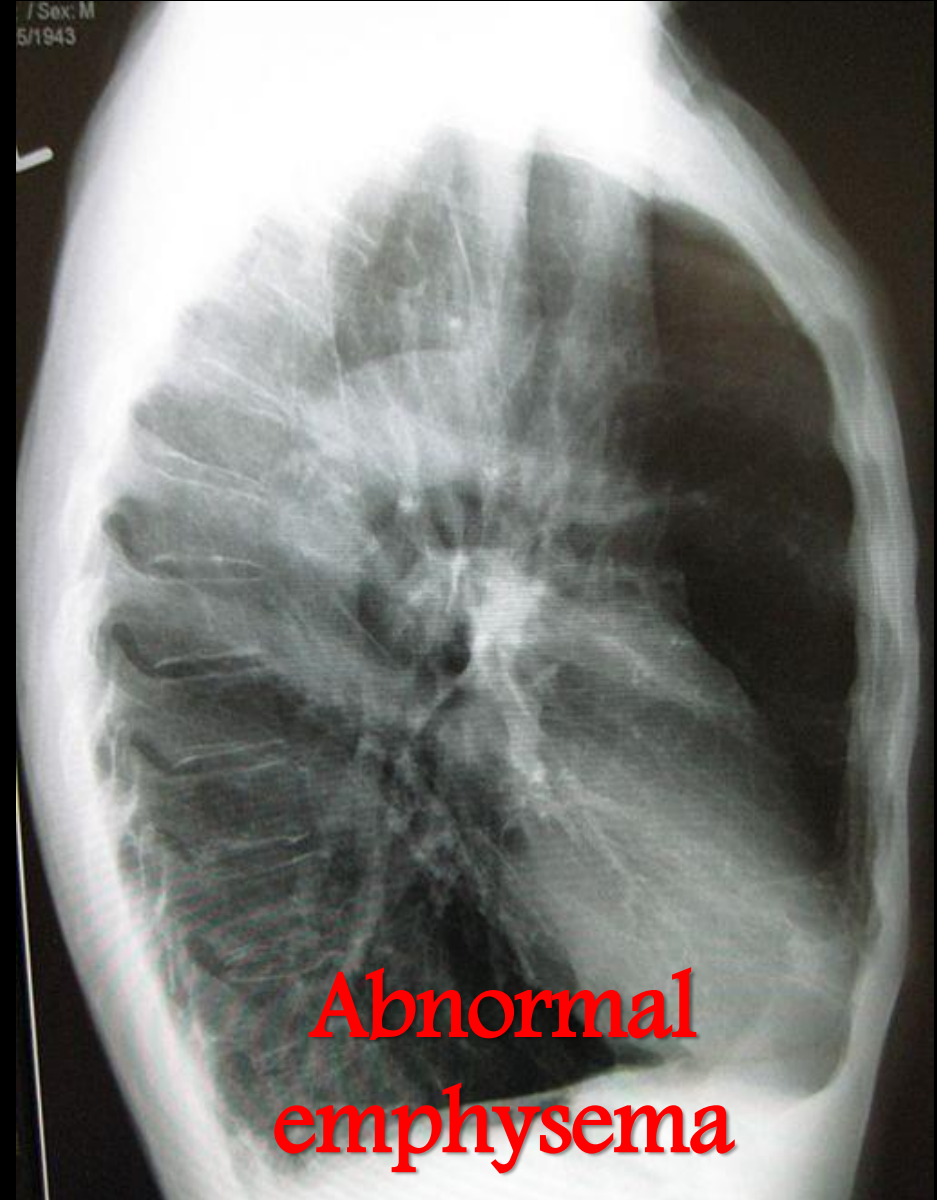
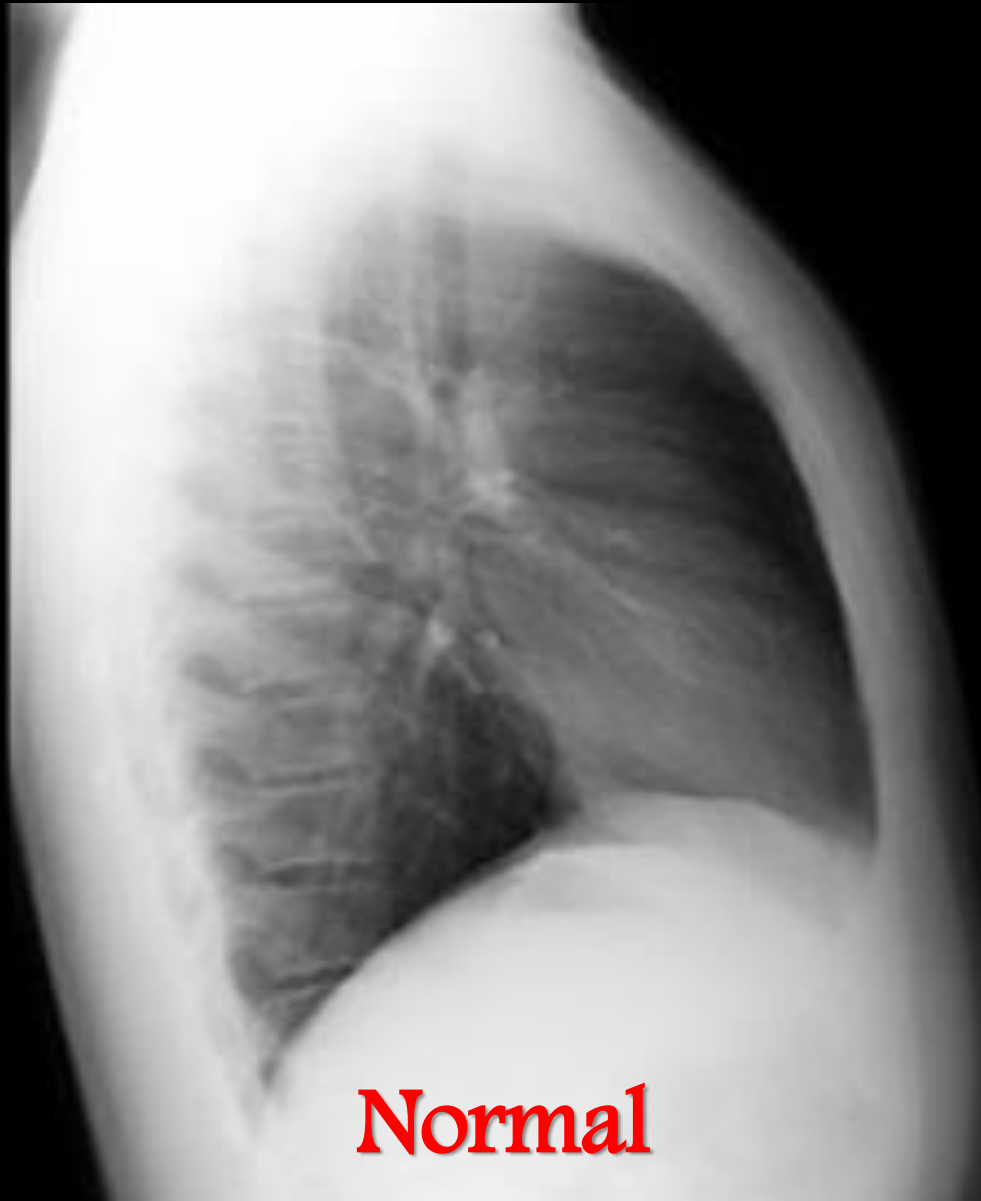Which film is abnormal? What is the abnormality?



Which film is abnormal? What is the abnormality?

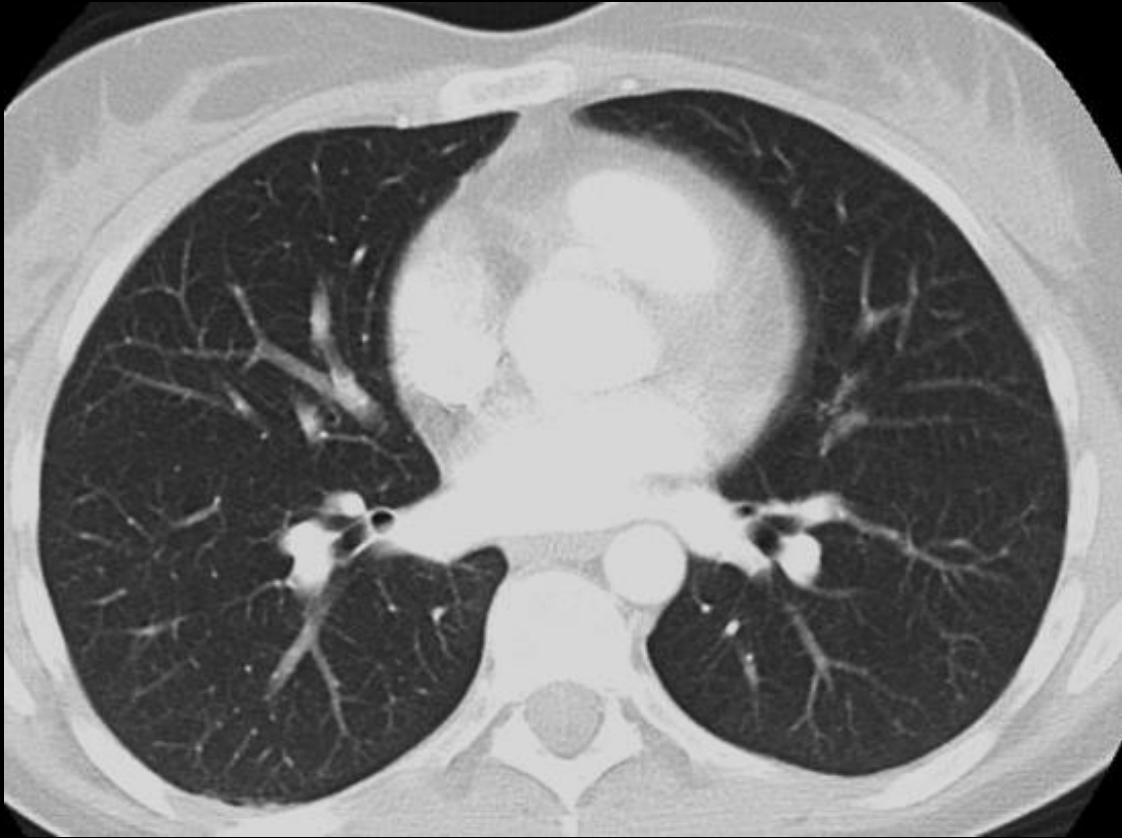


Which film is abnormal? What is the abnormality?

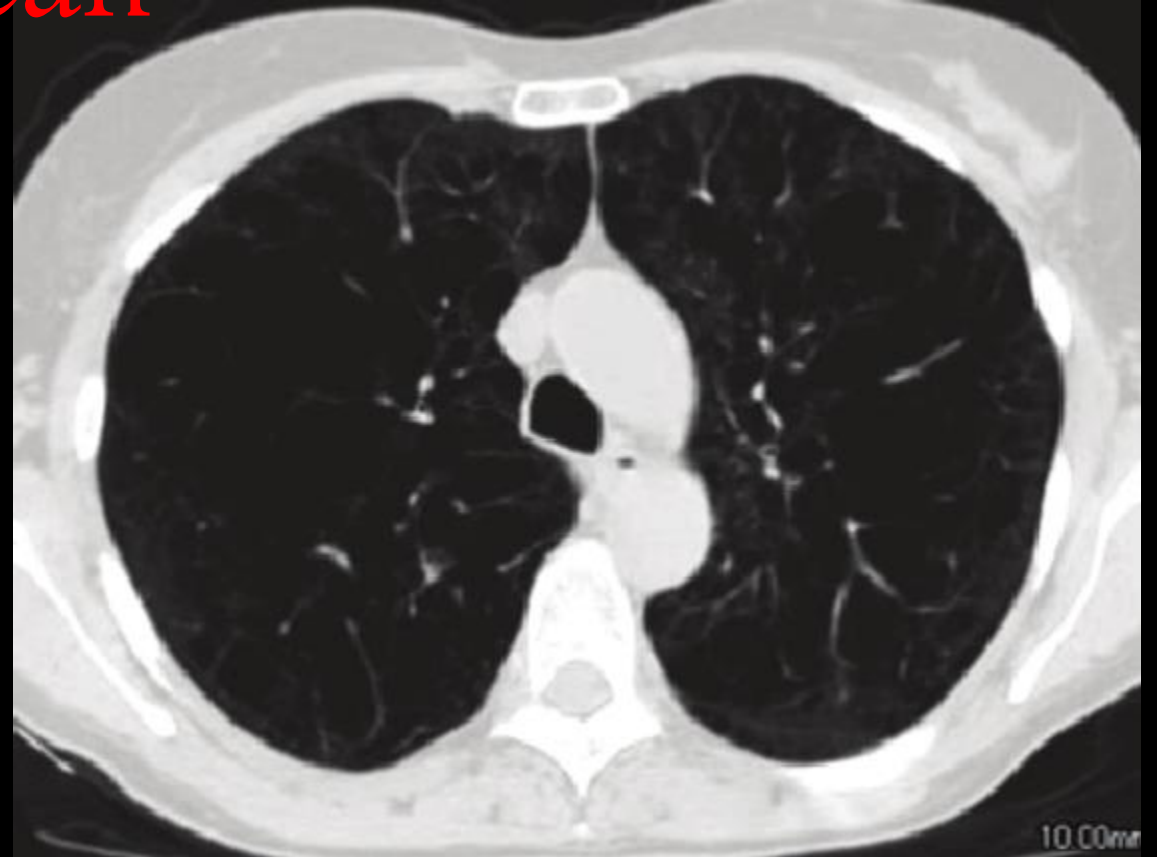

Which film is abnormal? What is the abnormality?

CT scan

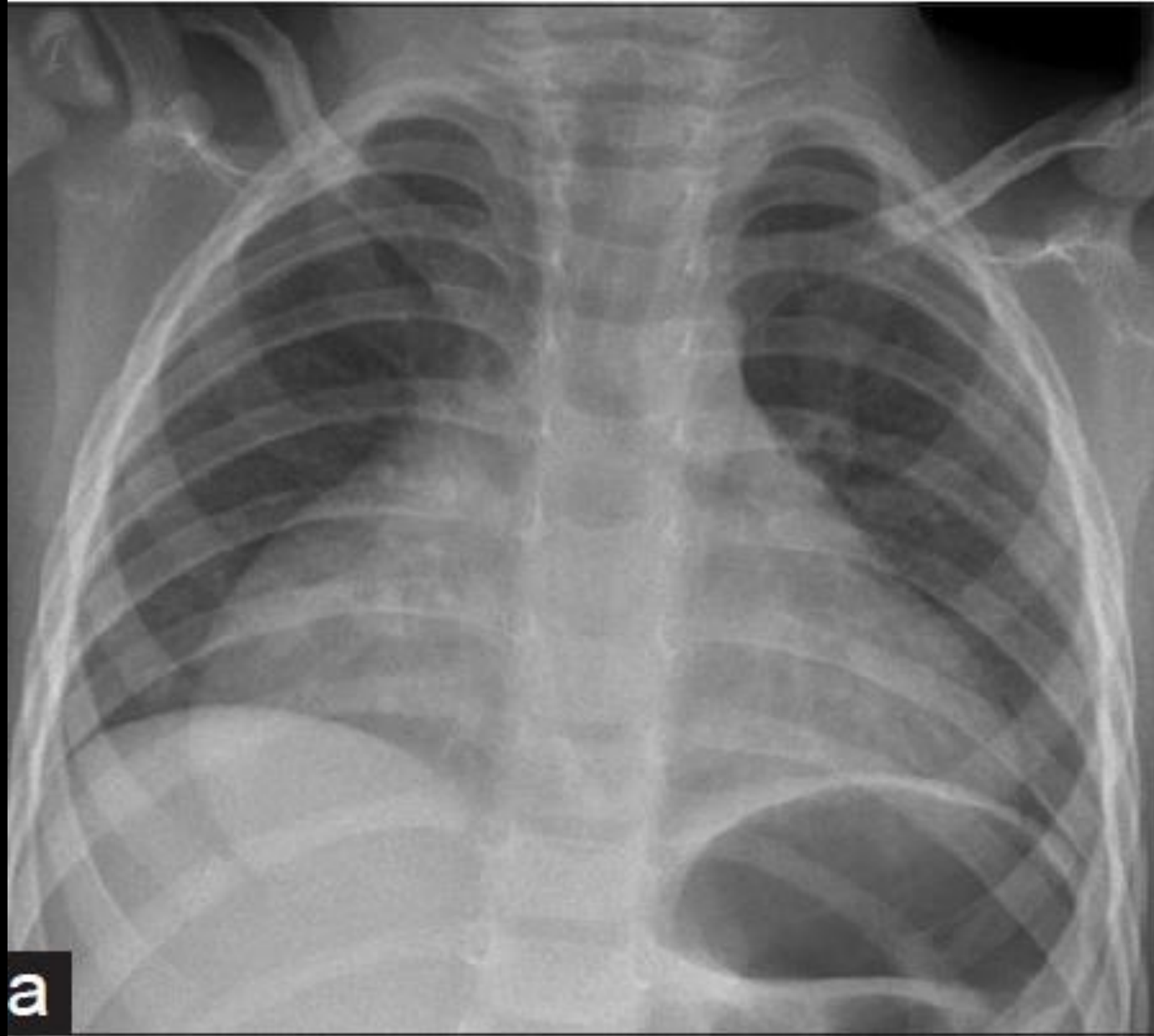


Normal



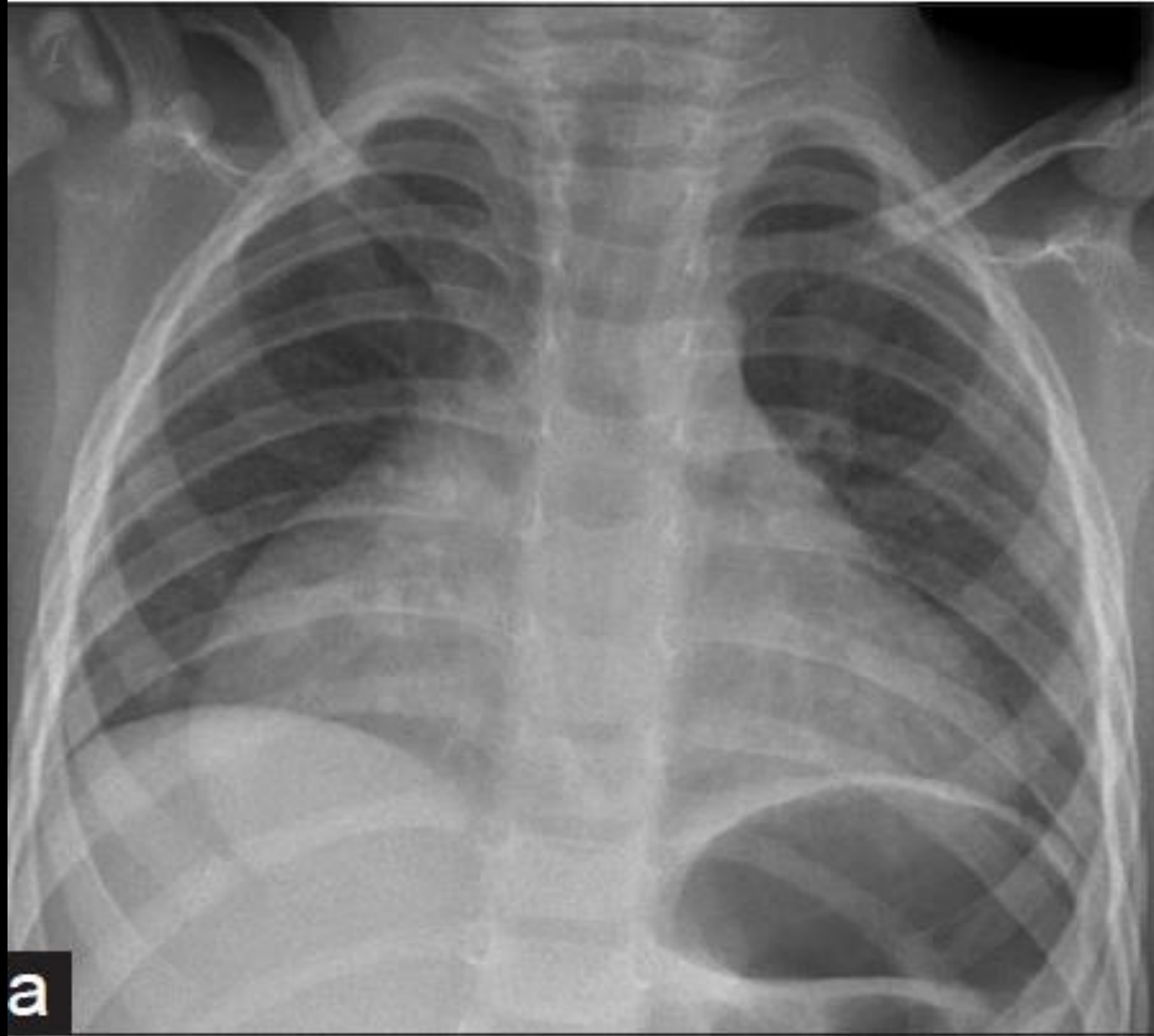
Abnormal
emphysema

What is abnormal ?



What is abnormal ?

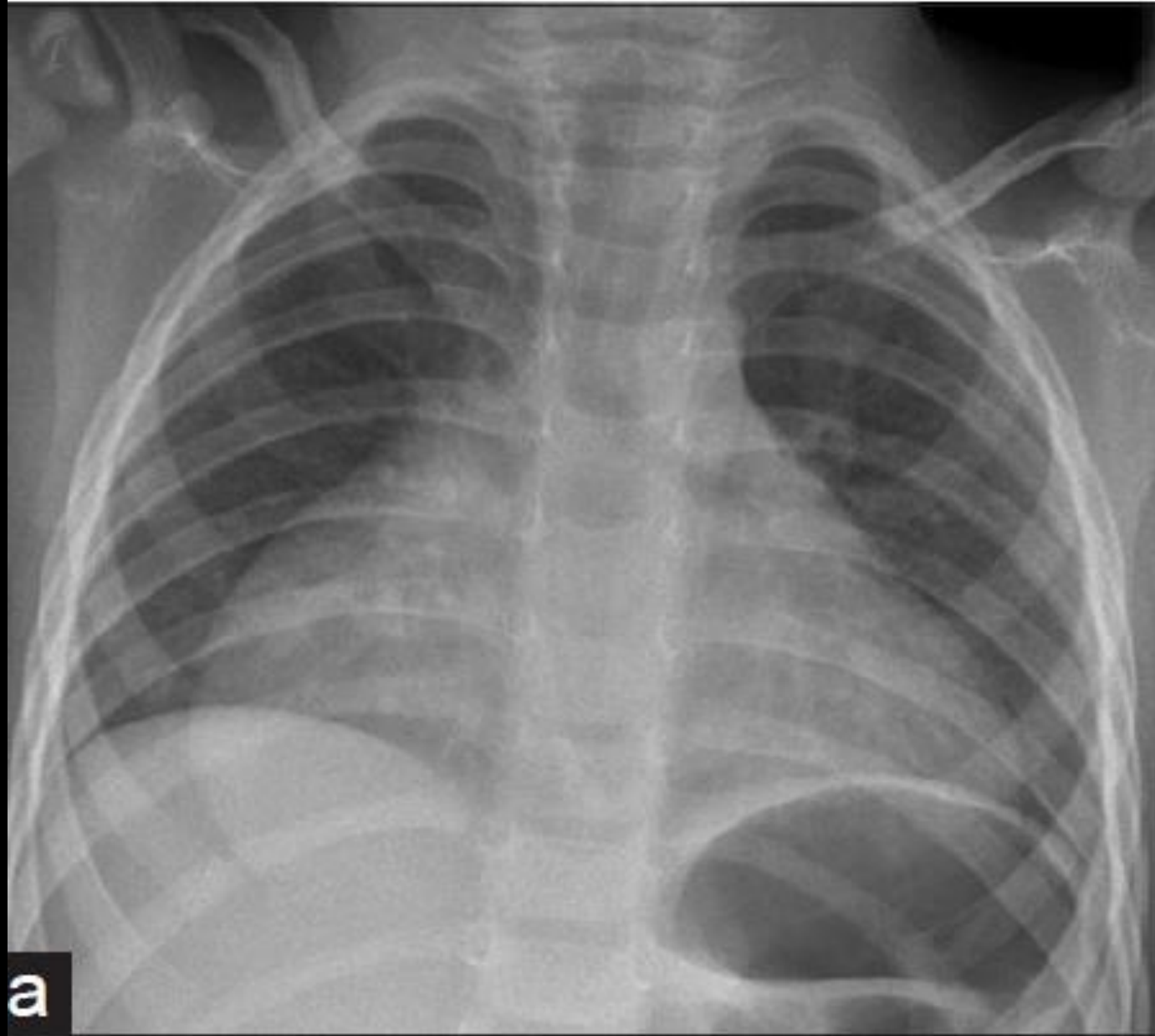
➤ Heart shadow is enlarged



What is abnormal ?

➤ Heart shadow is enlarged

Can you figure out which heart chamber is enlarged?

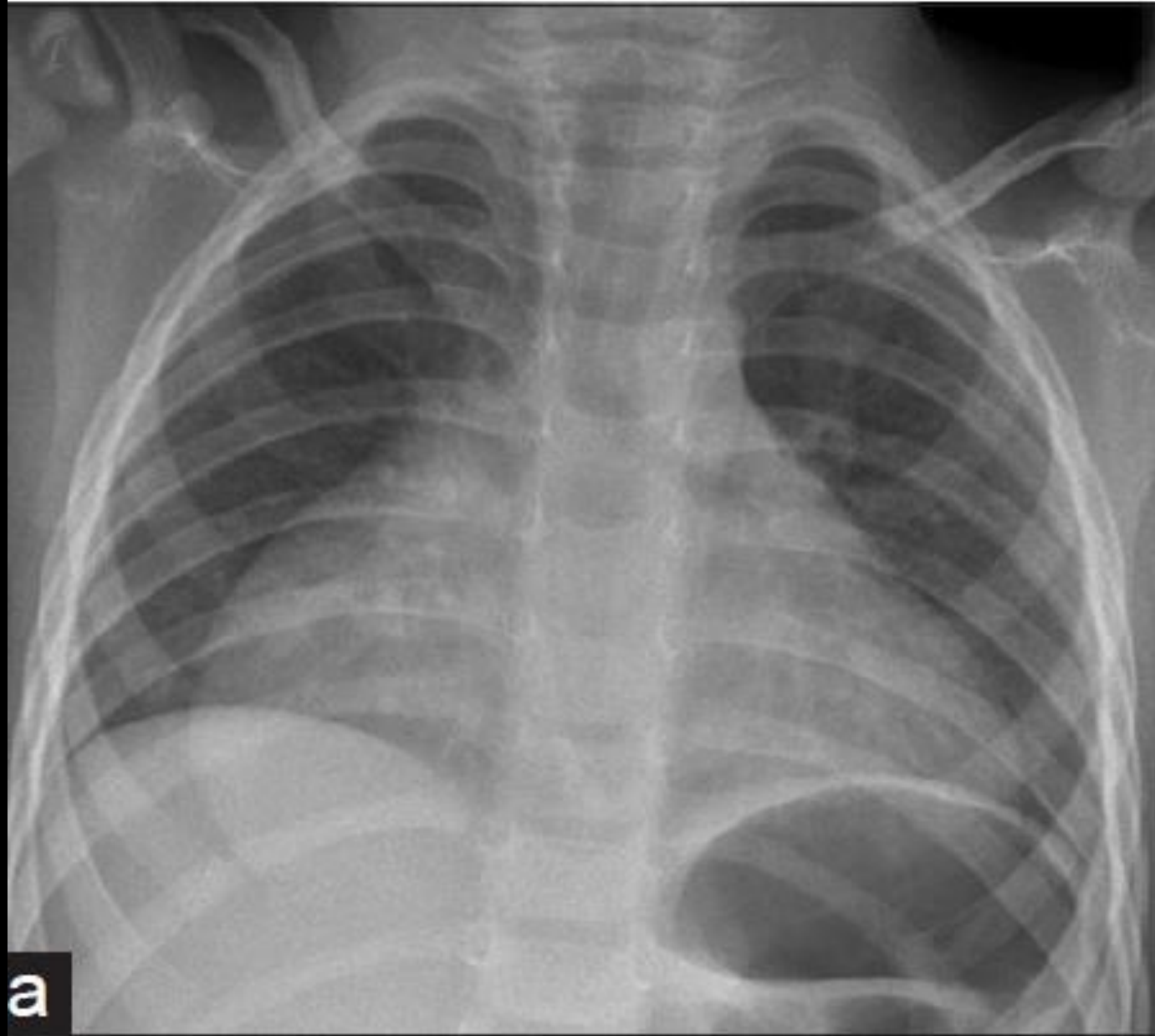


What is abnormal ?

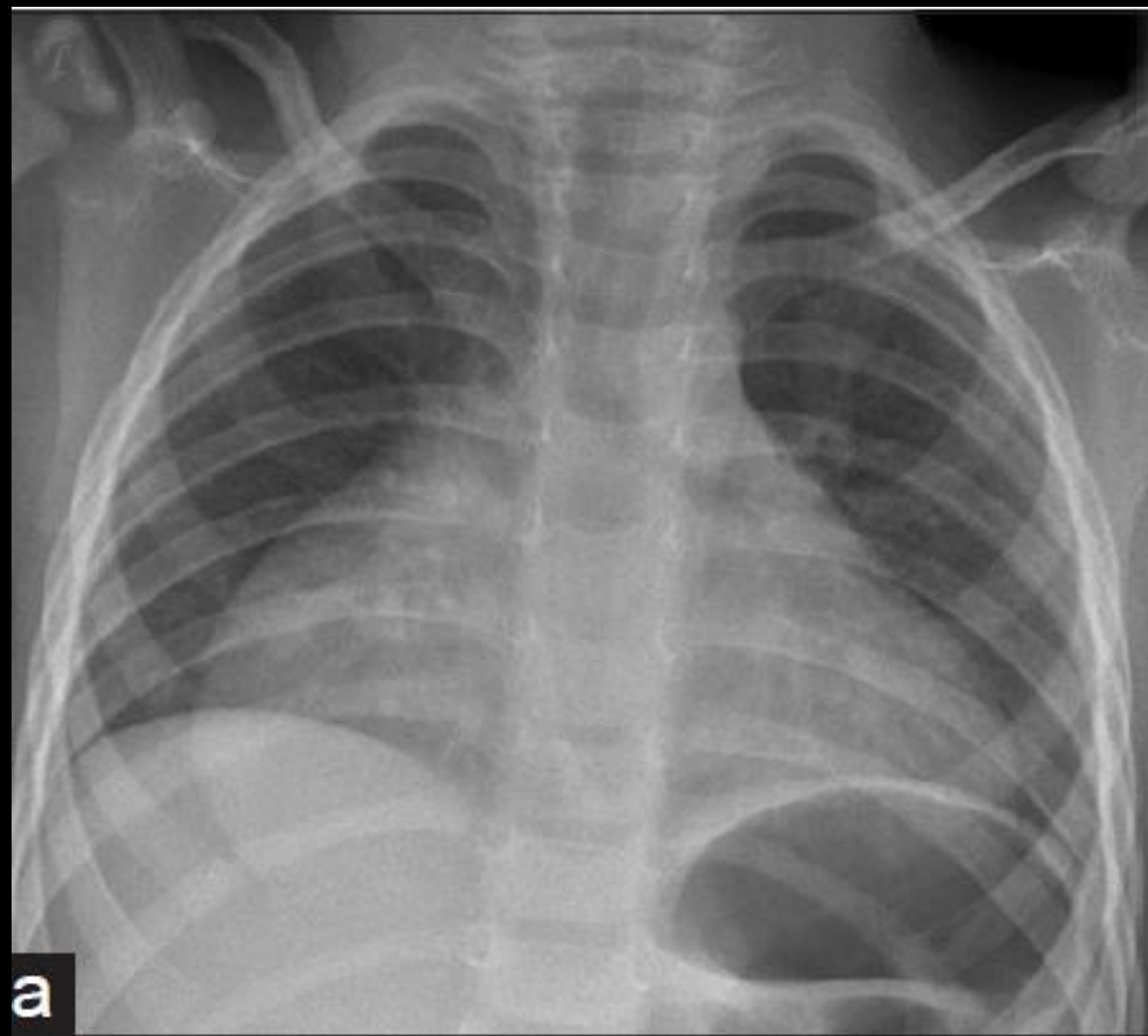
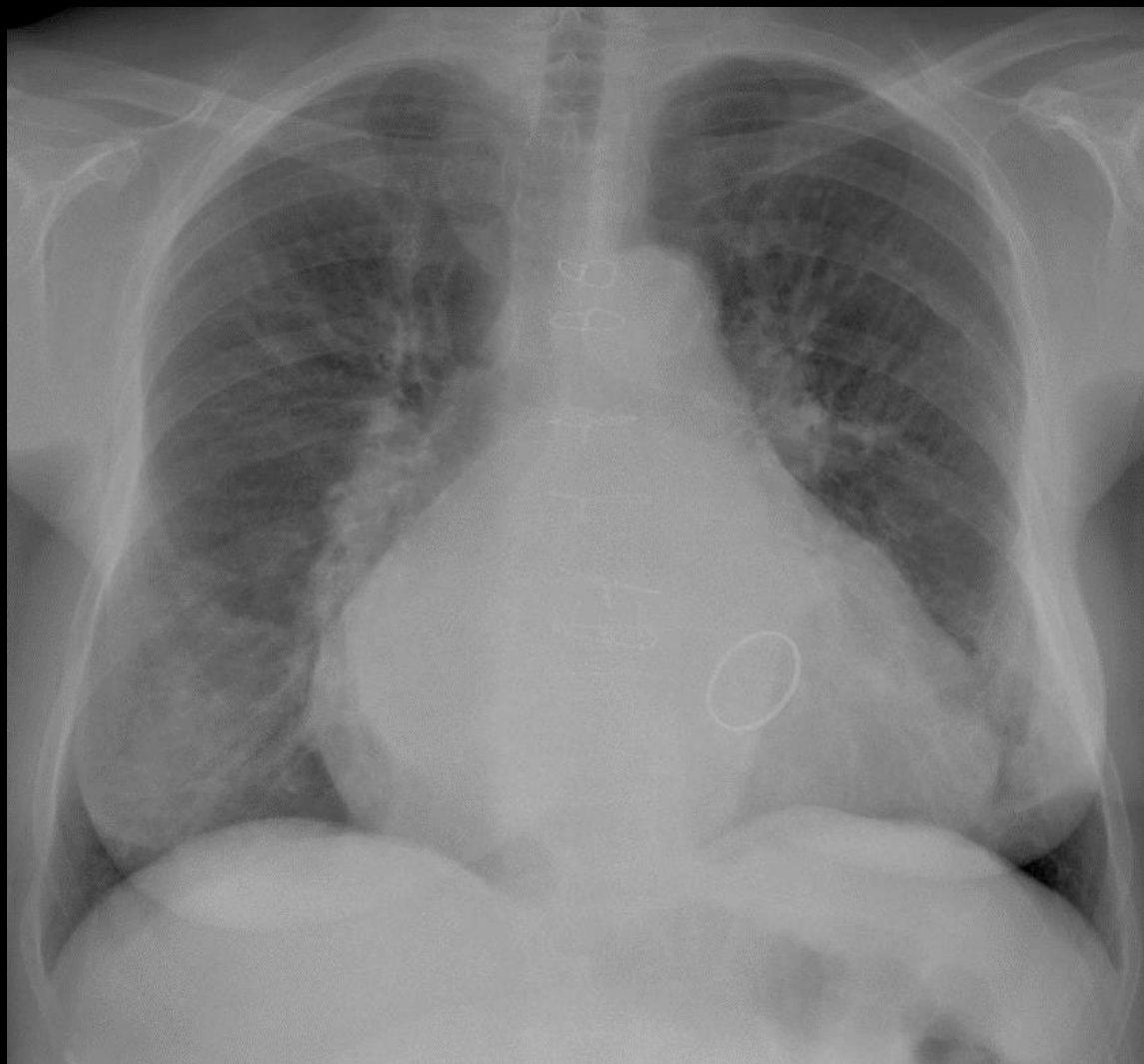
➤ Heart shadow is enlarged

Can you figure out which heart chamber is enlarged?

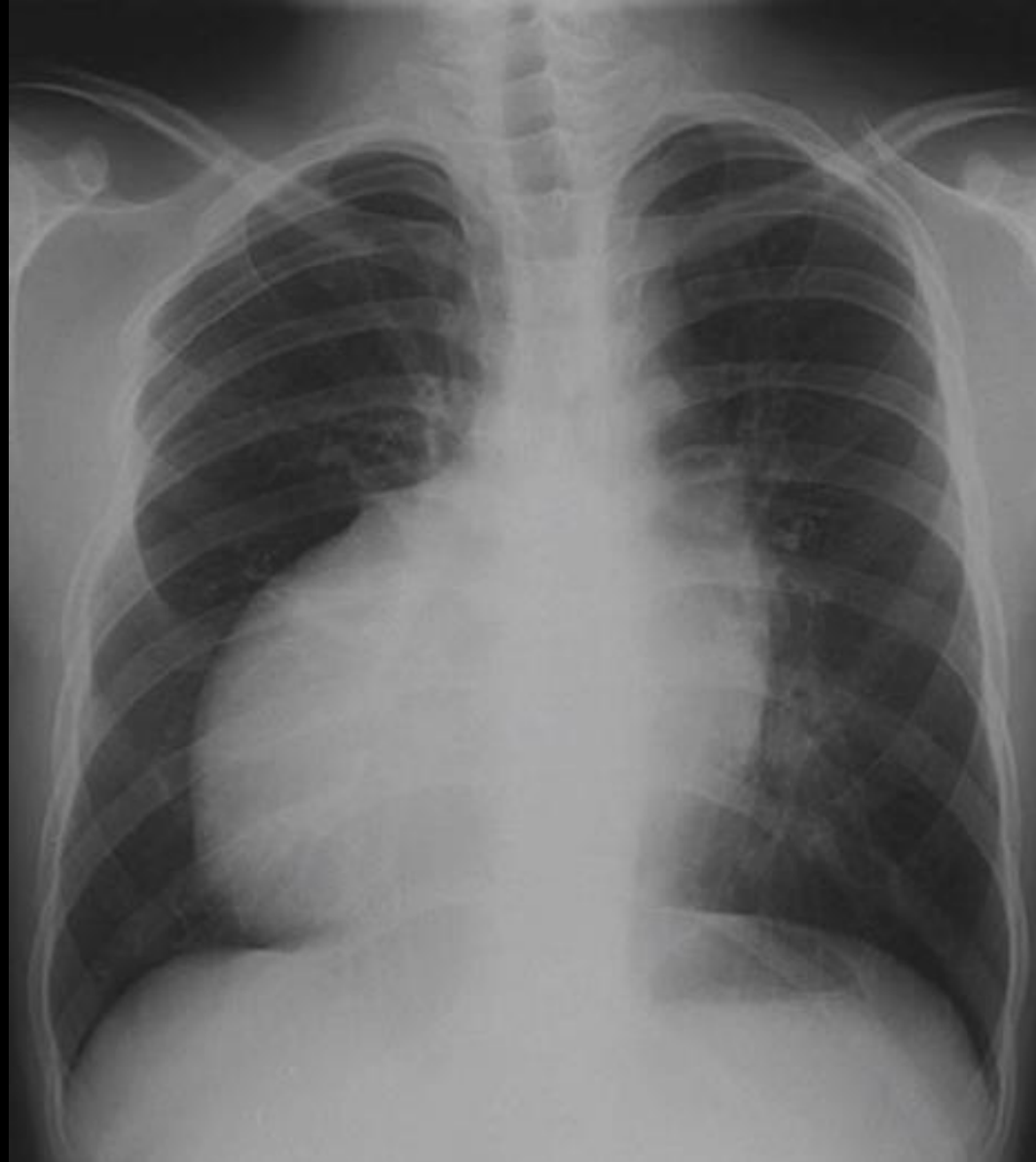➤ Right atrium



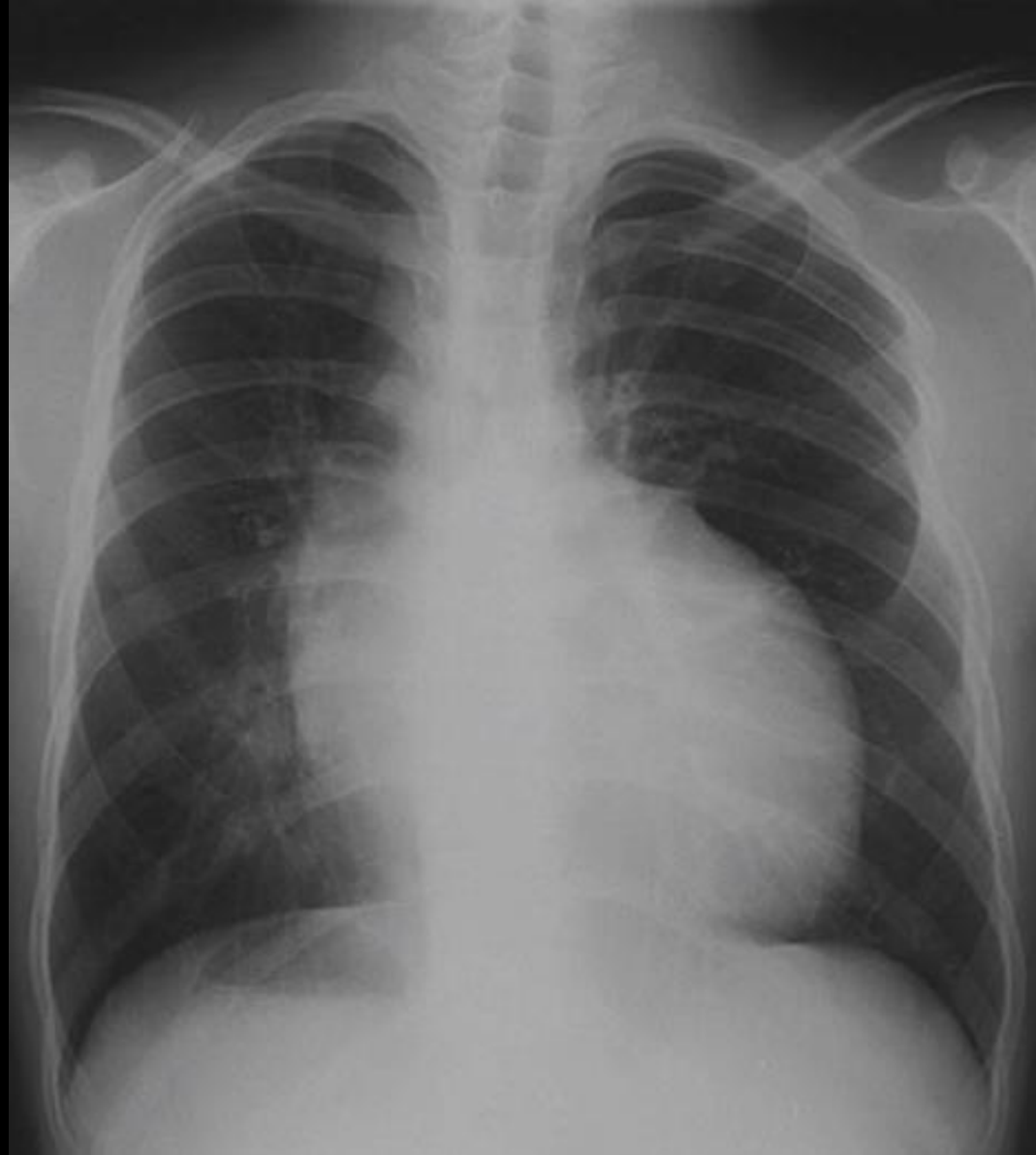Left atrium enlargement vs Right atrium enlargement



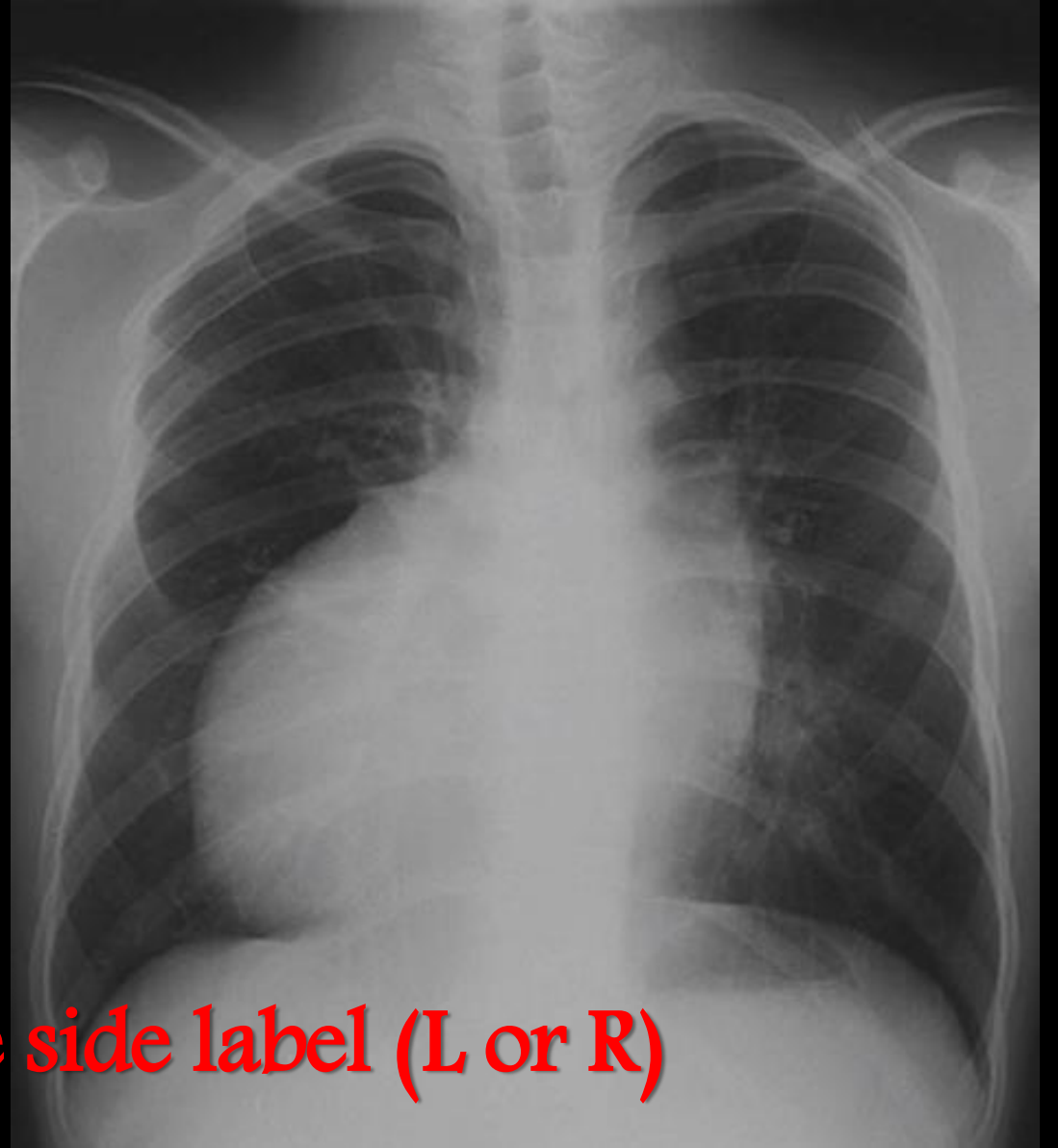
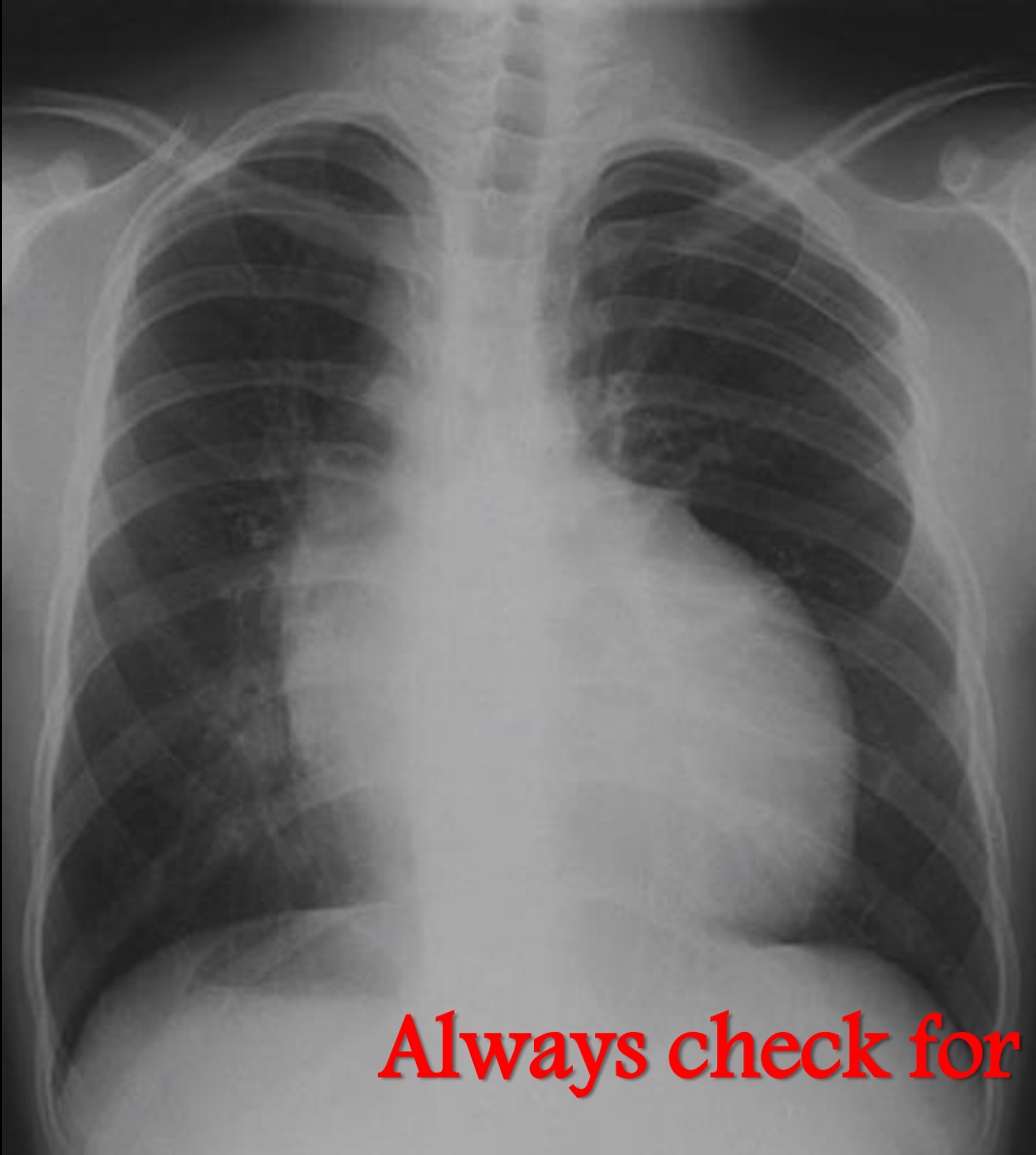What is the diagnosis?



What is the diagnosis?

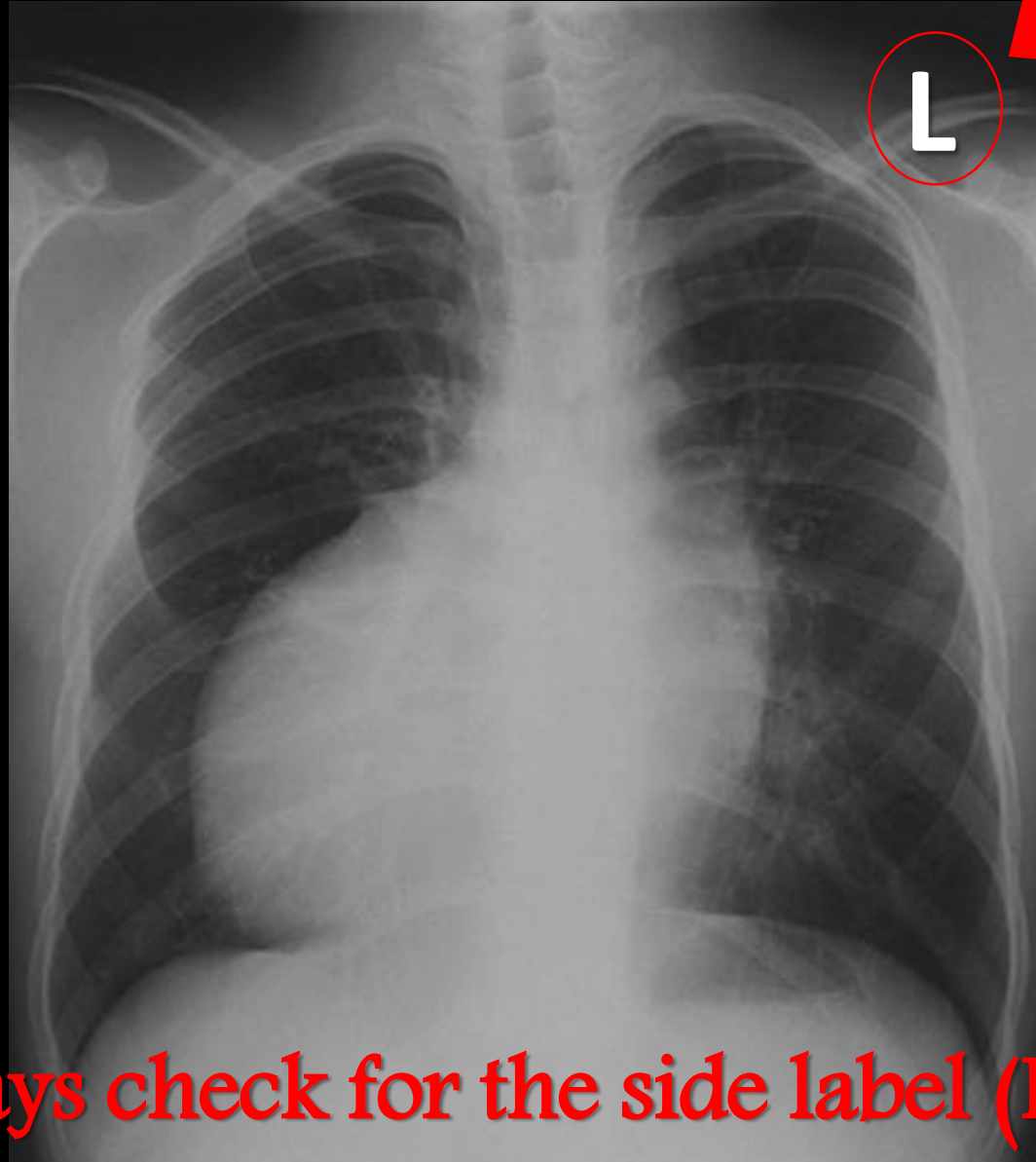

What is the diagnosis?



Always check for the side label (L or R)

What is the diagnosis?

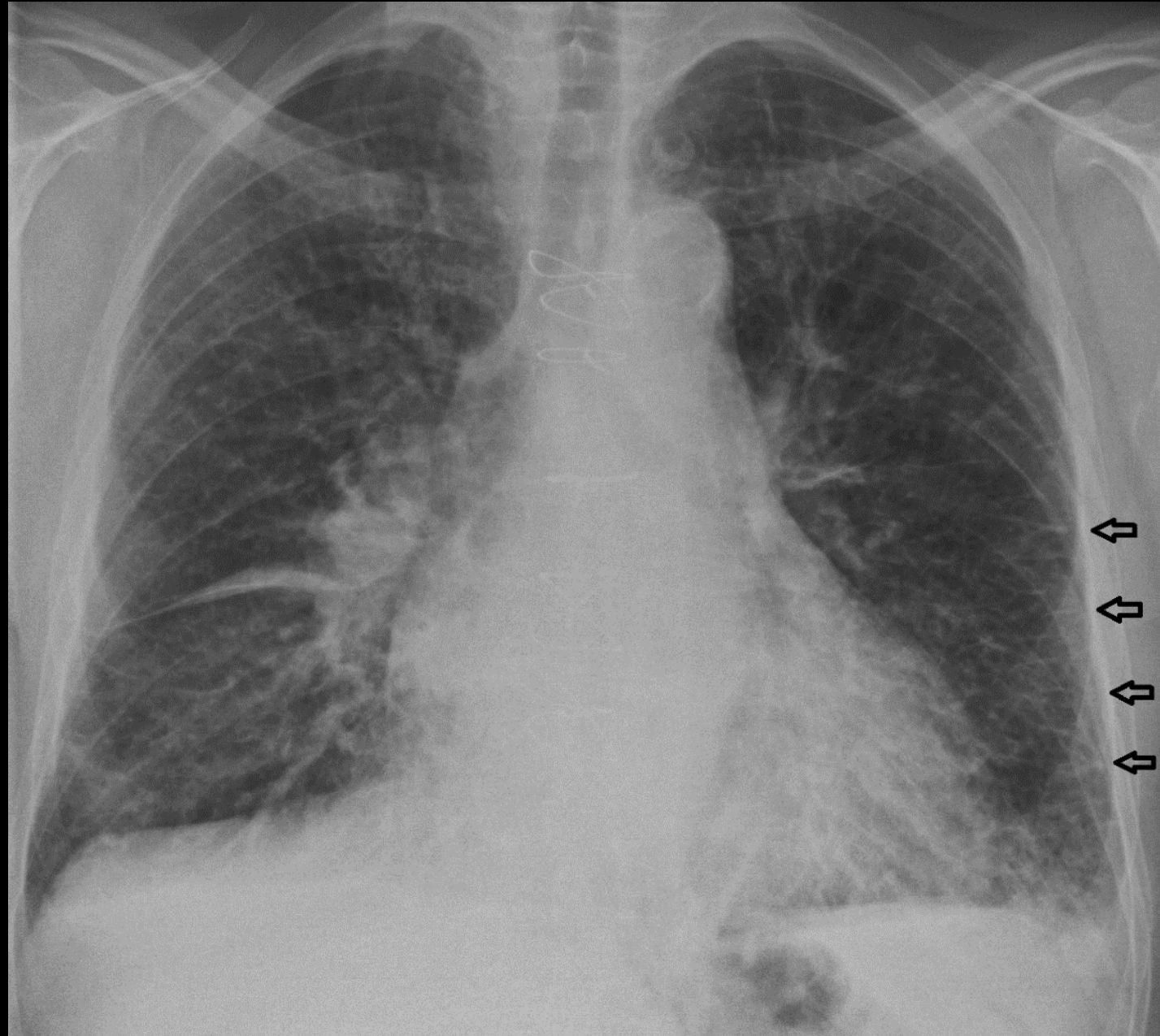


Diagnosis:
dextrocardia

Always check for the side label (L or R)

60 year –old male
with difficulty in
breathing

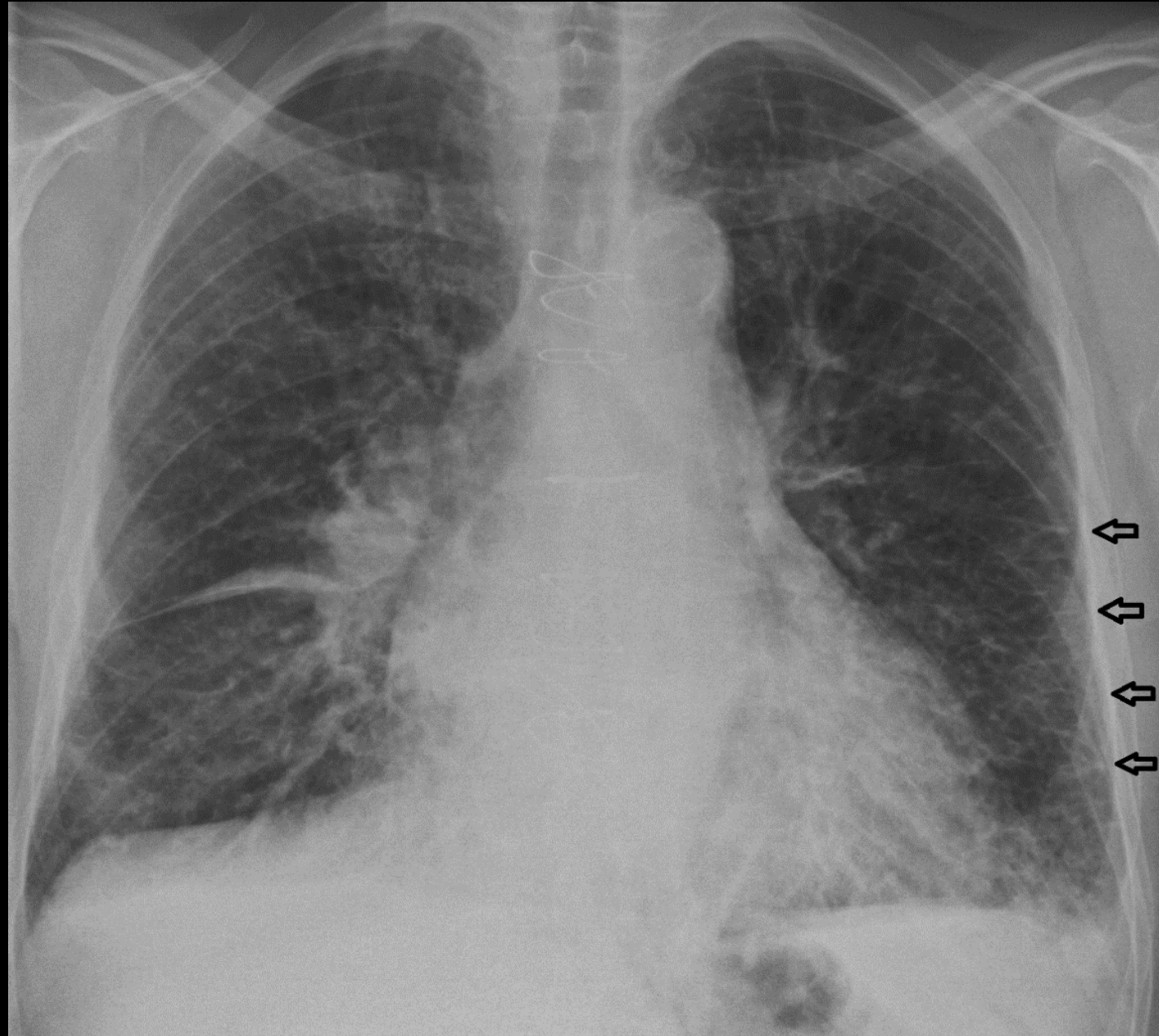
What is the most likely
diagnosis ?



60 year –old male
with difficulty in
breathing

What is the most likely
diagnosis ?

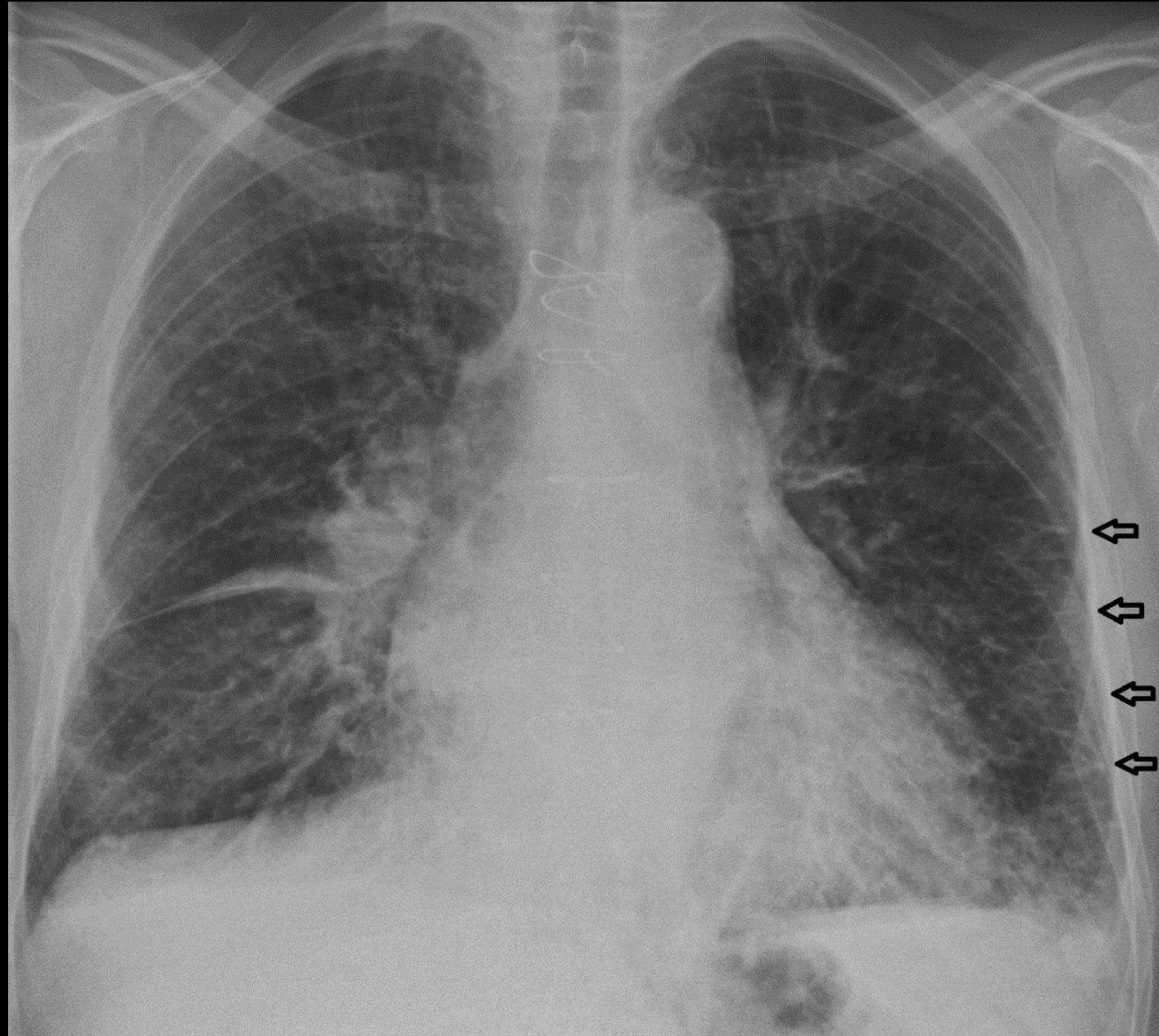
- Cardiogenic
Pulmonary edema
(interstitial)



60 year –old male
with difficulty in
breathing

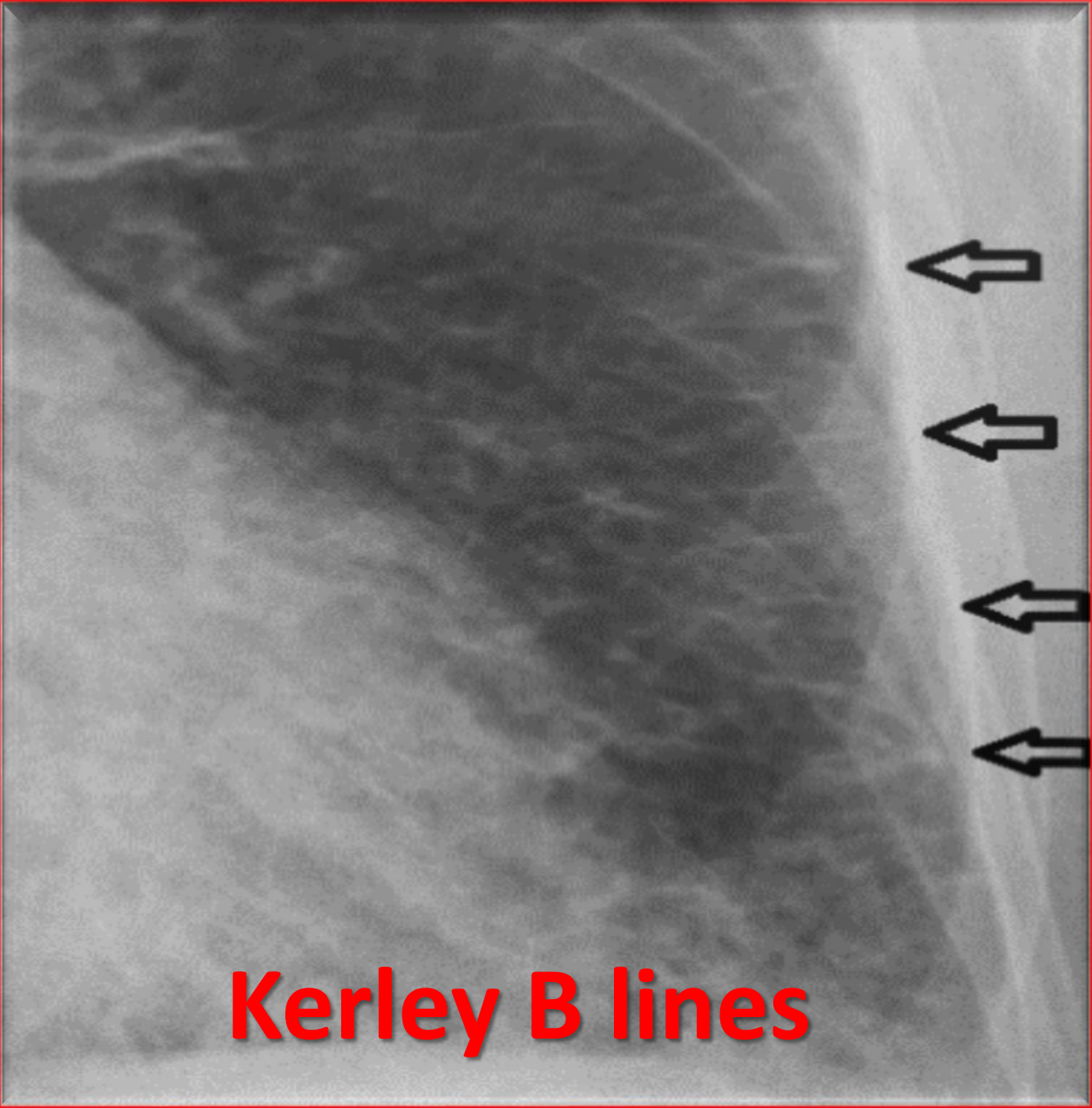

What is the most likely
diagnosis ?

- Cardiogenic
Pulmonary edema
(interstitial)

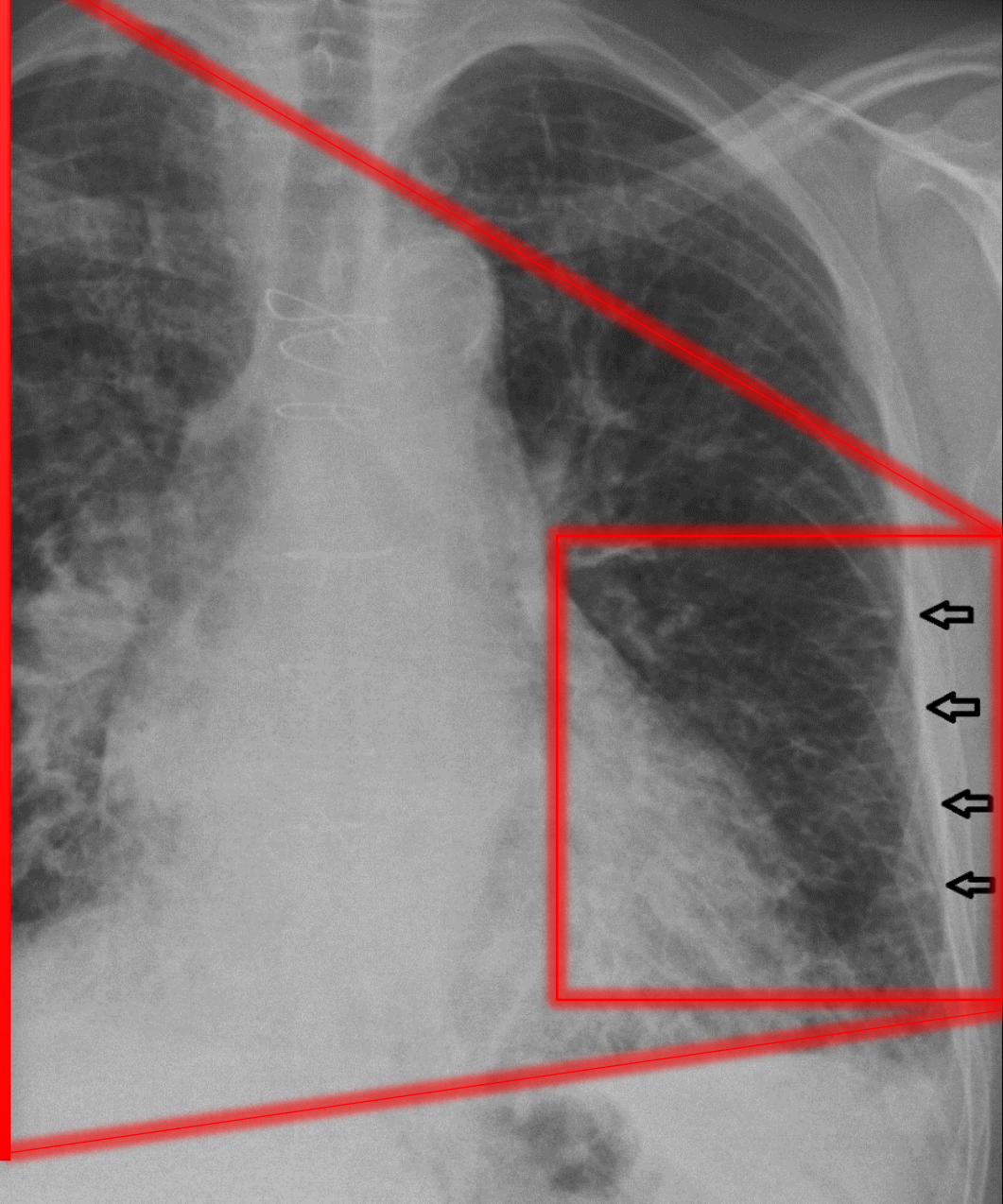


60
wi
bre

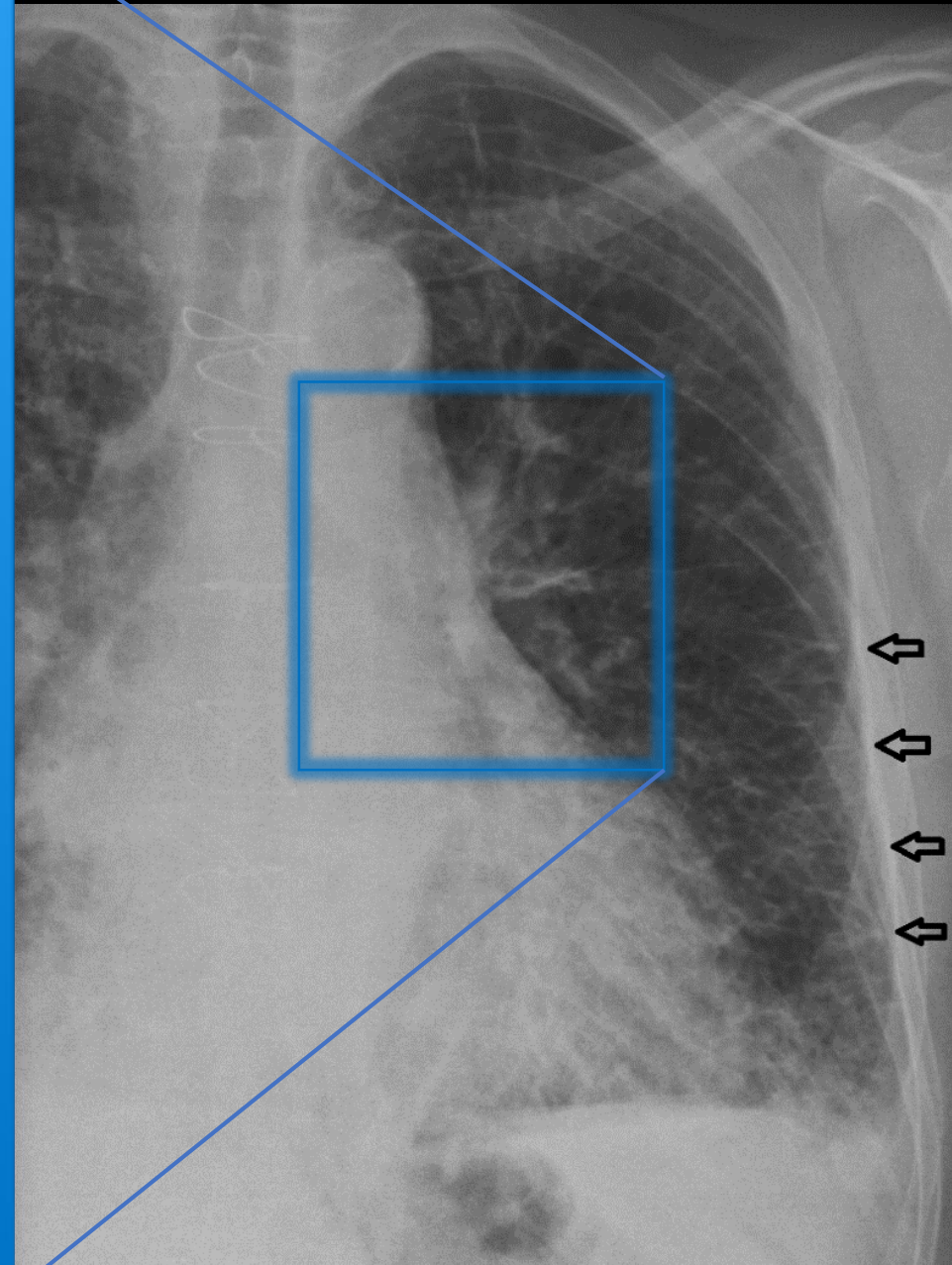
Wh
dia



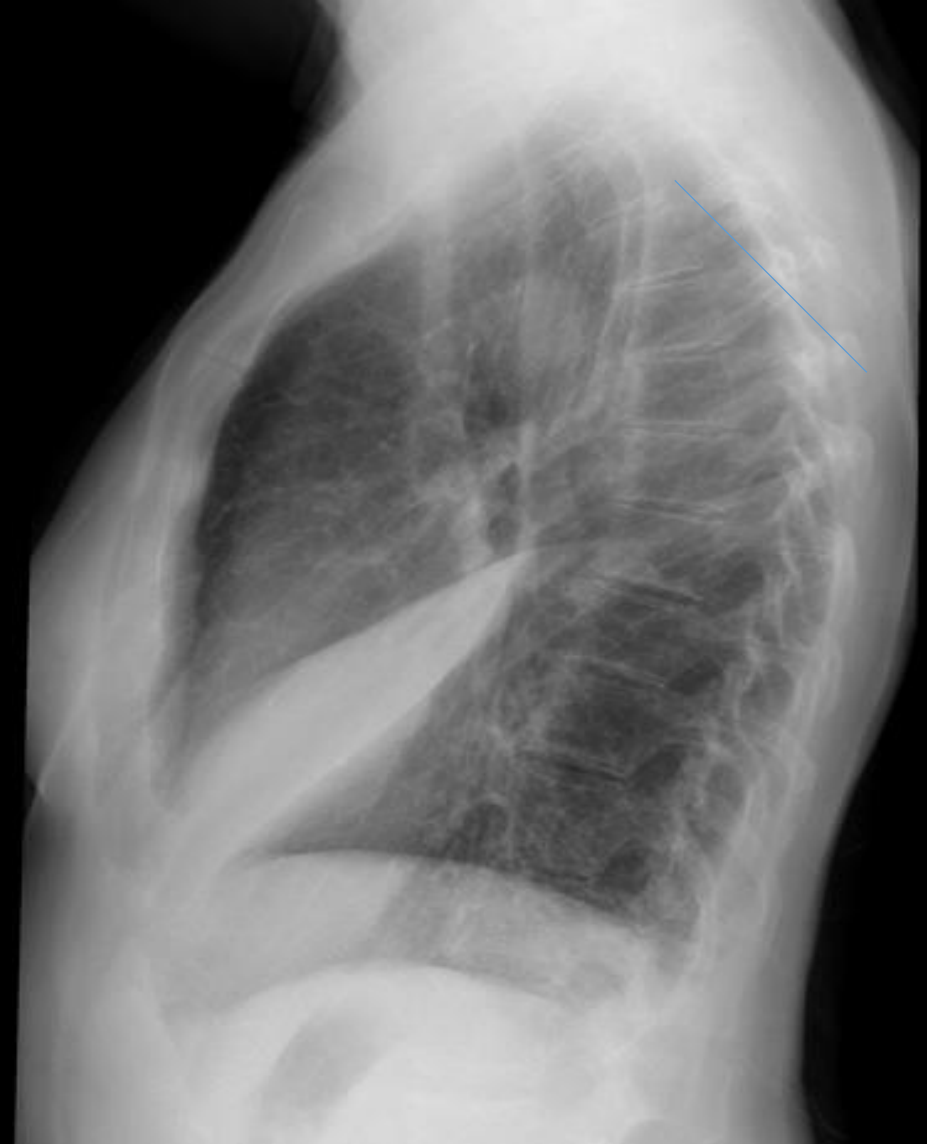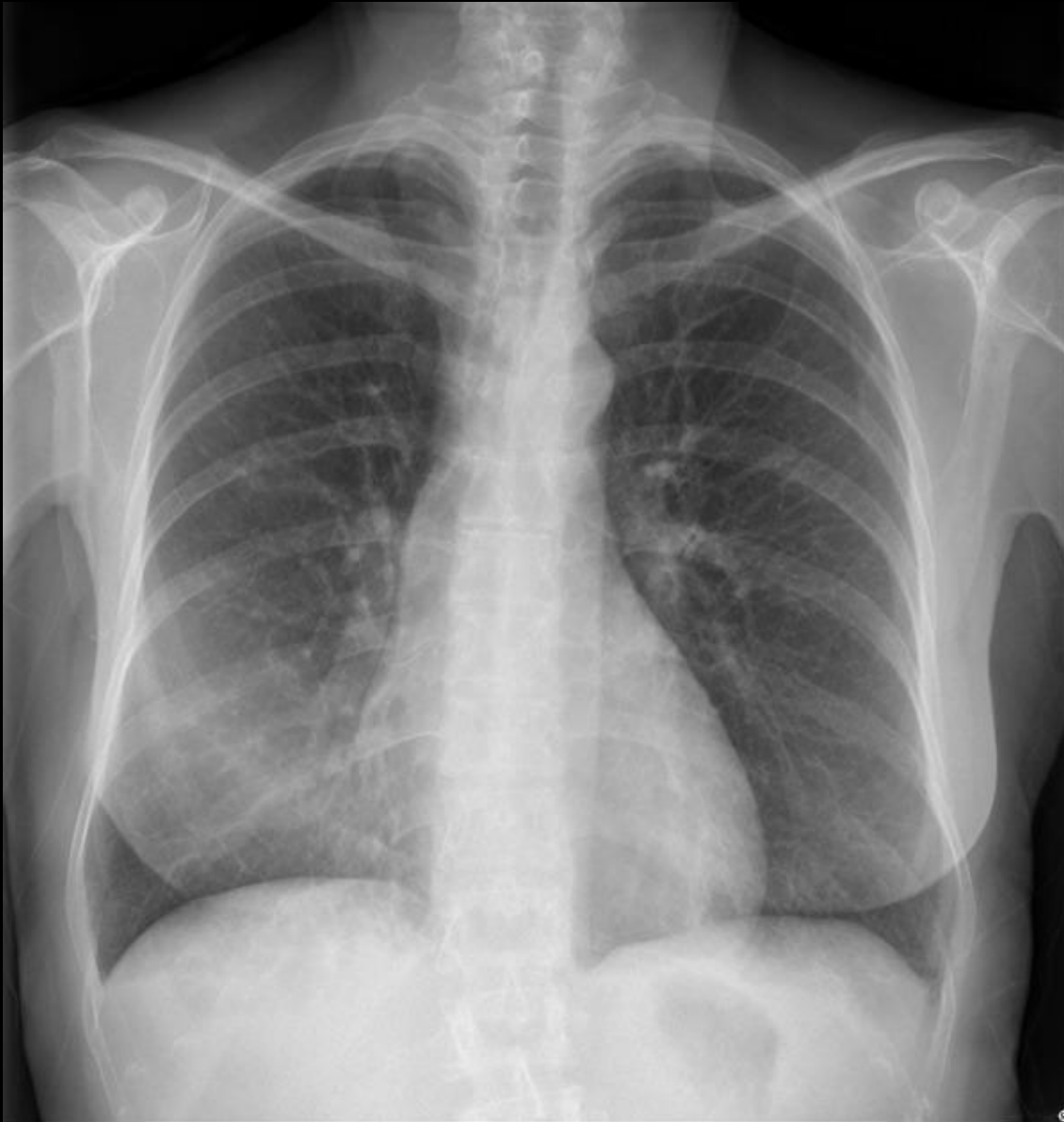Kerley B lines



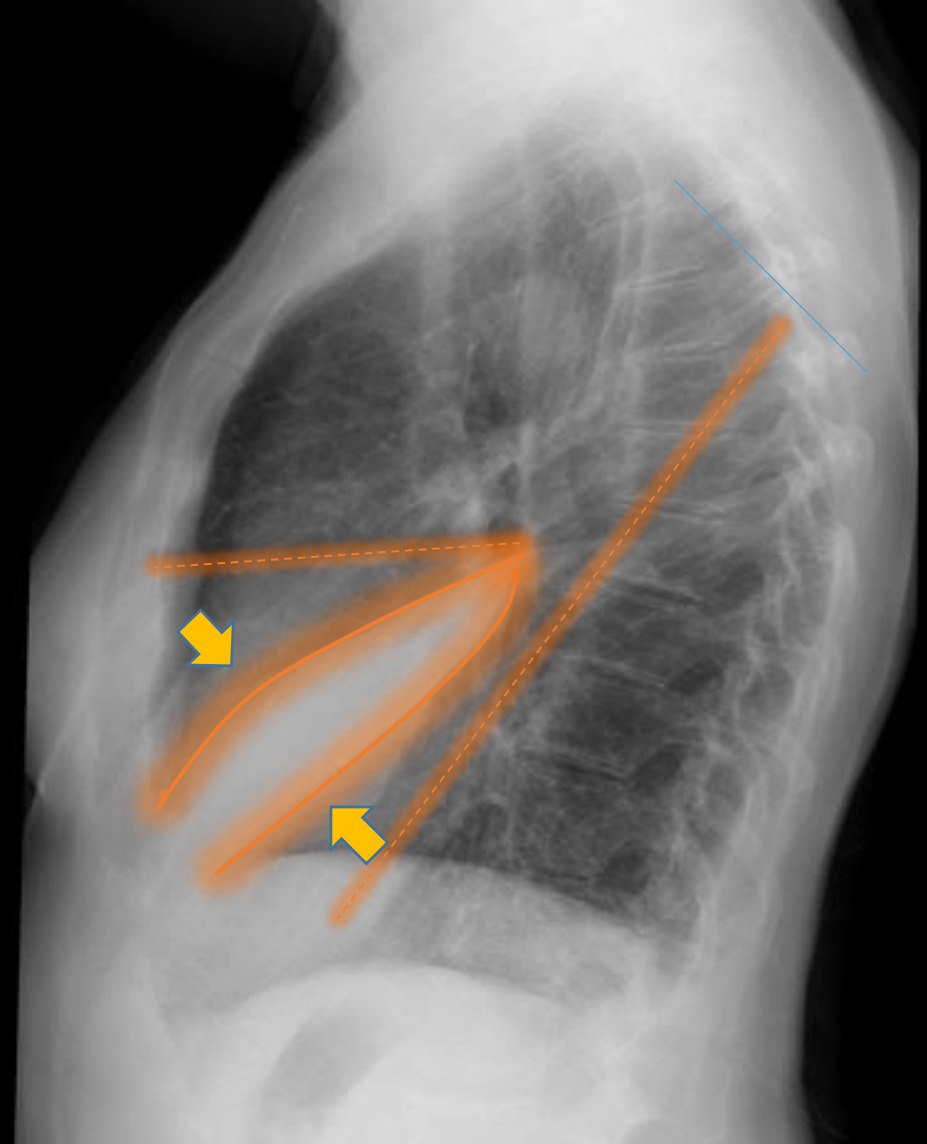
Peri broncheal
cuffing



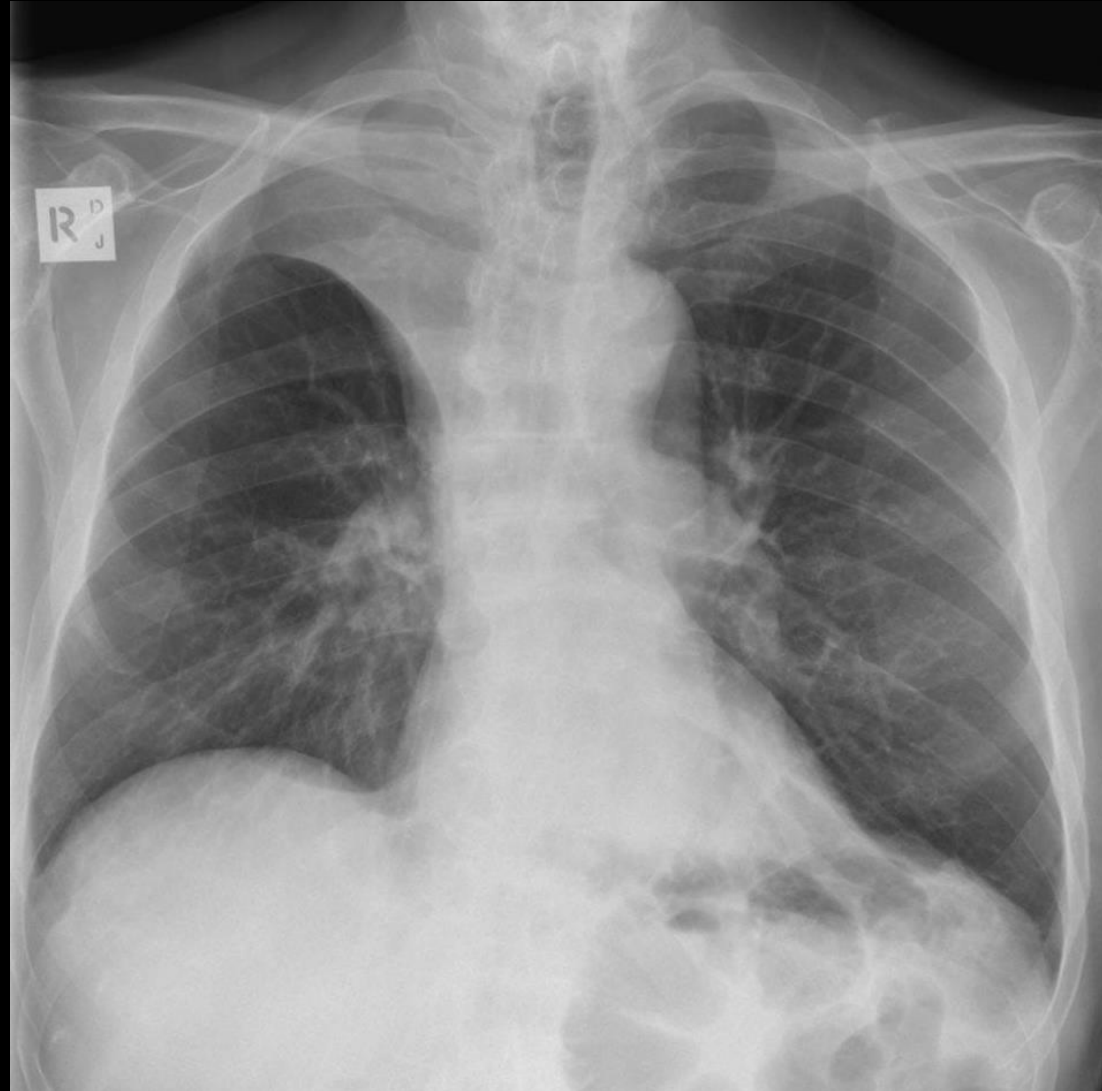
What do you see in this x ray ?



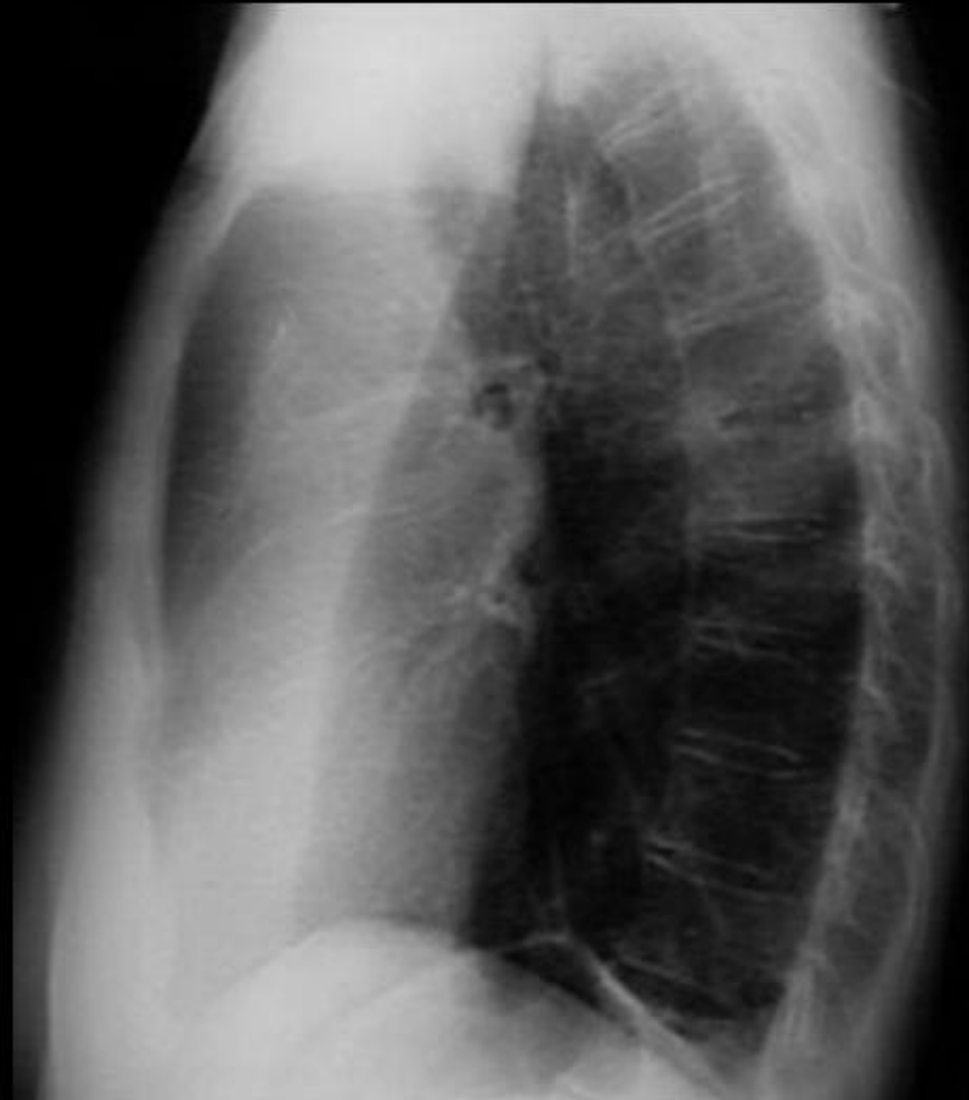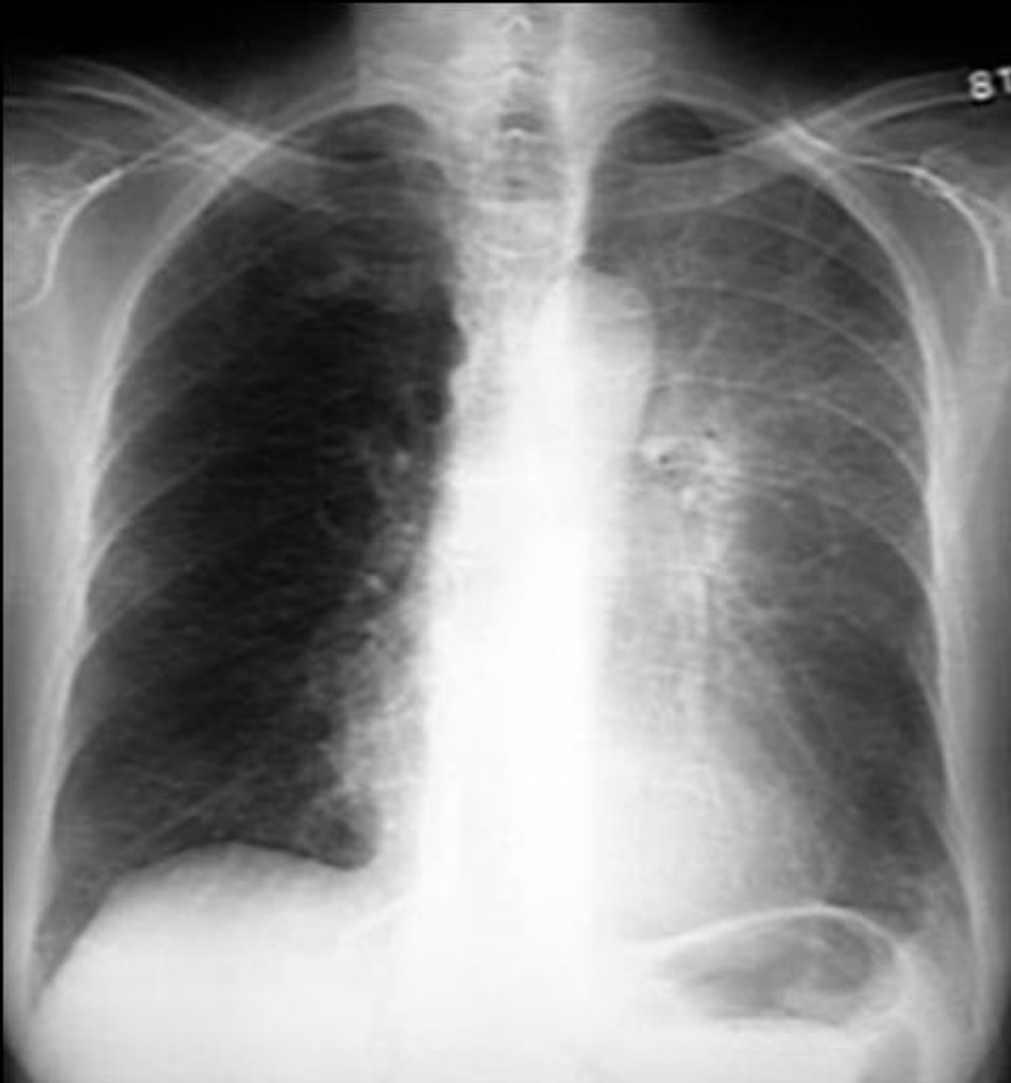What do you see in this x ray ? **Right middle lobe collapse.**



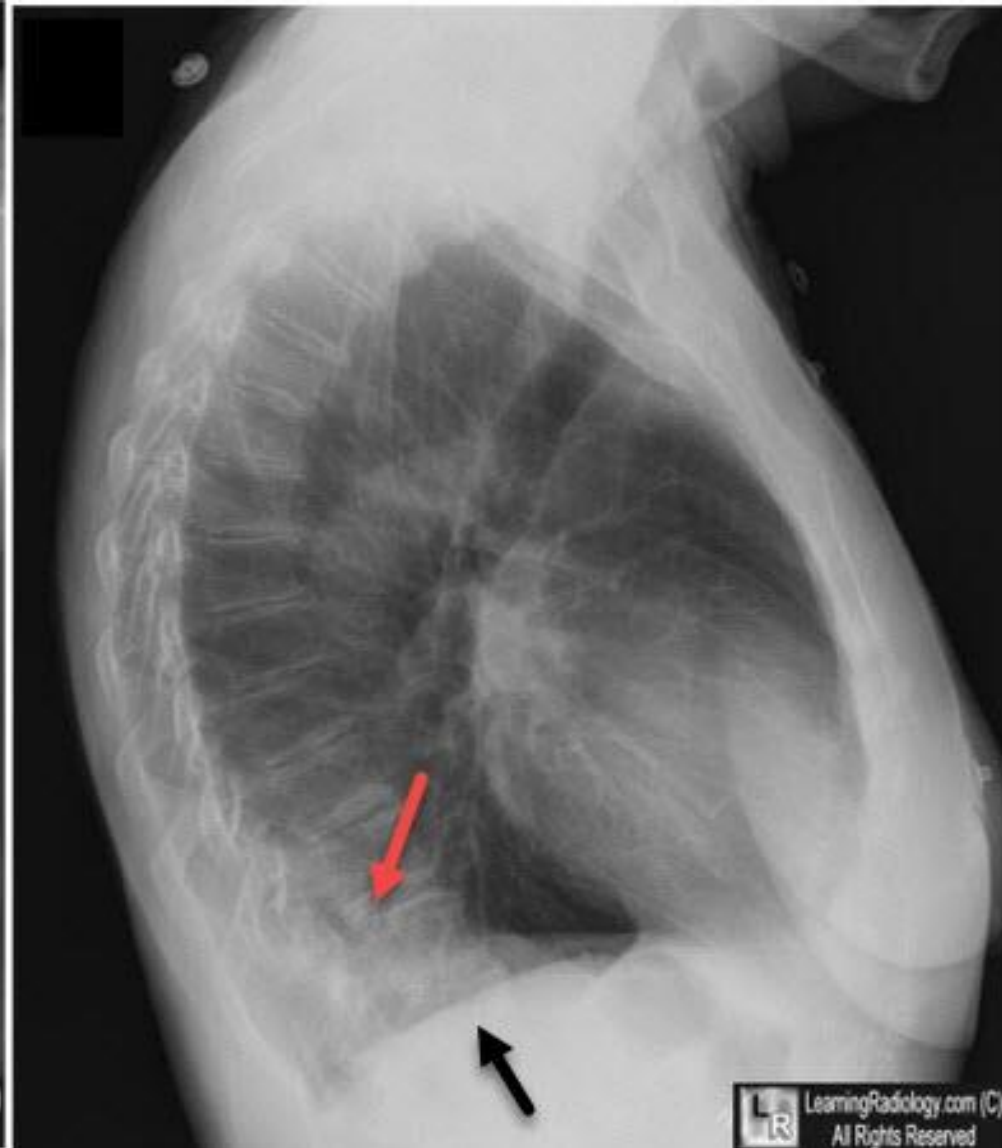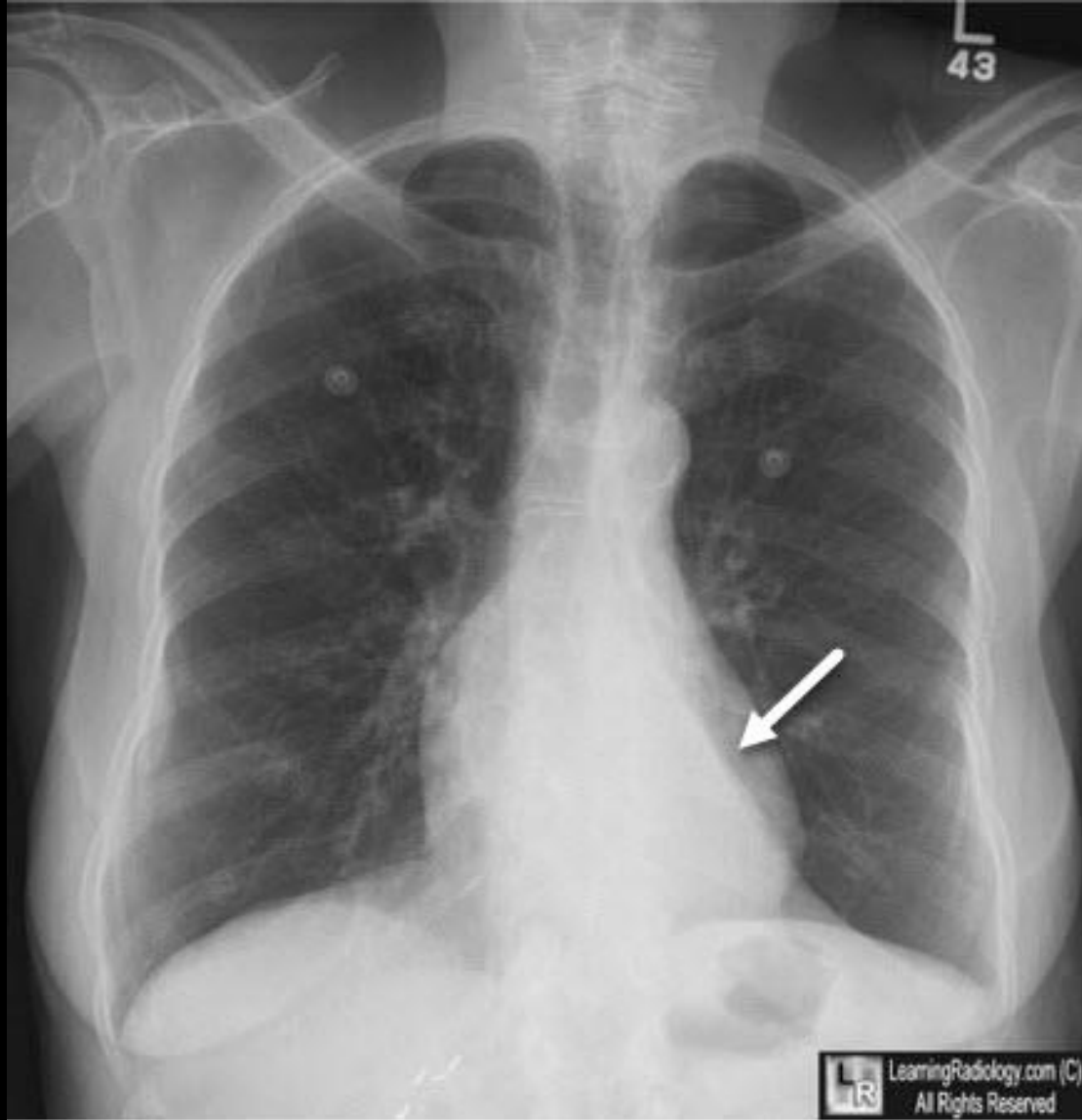
Right upper lobe collapse



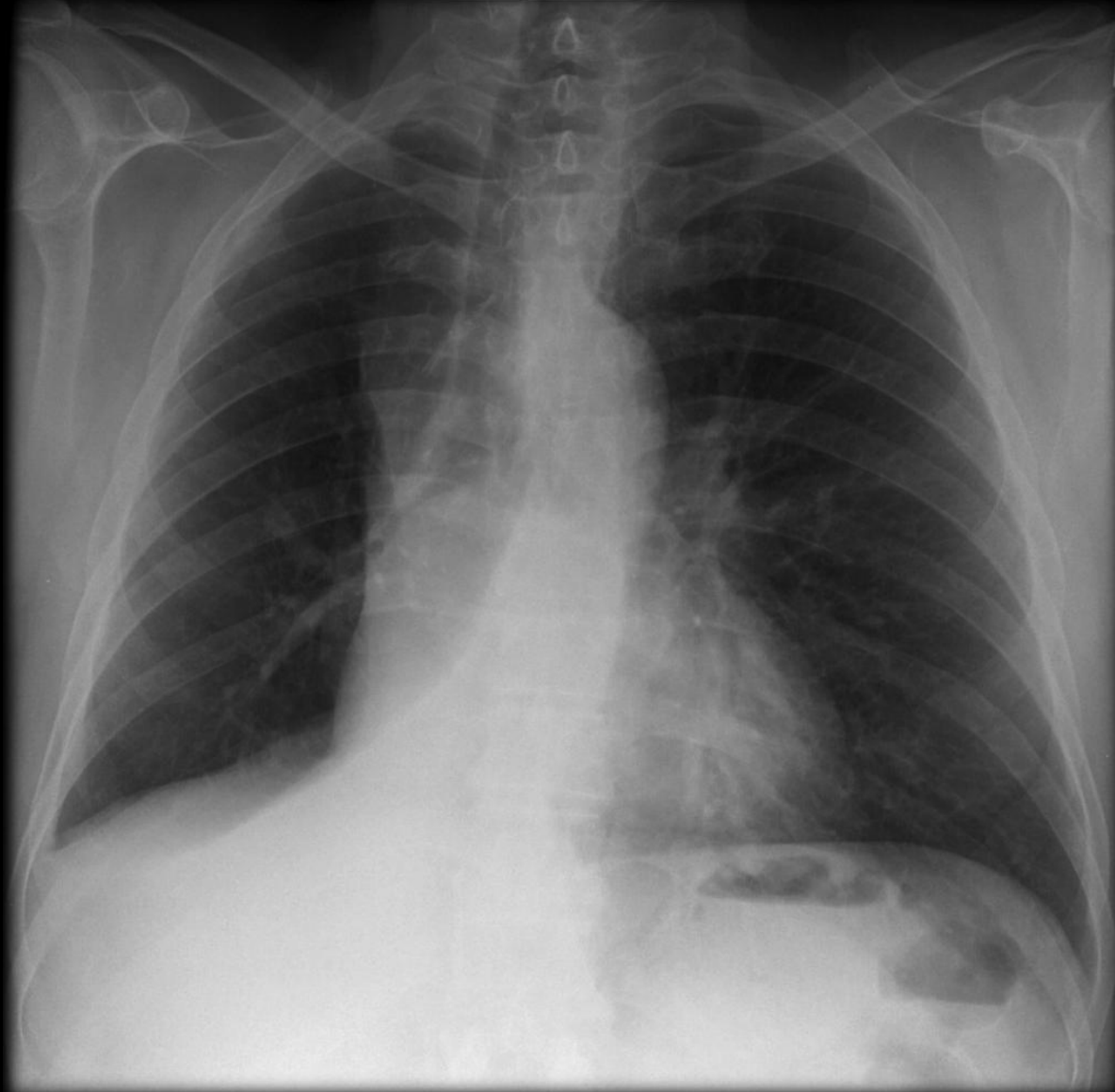
Left upper lobe collapse



Left lower lobe collapse

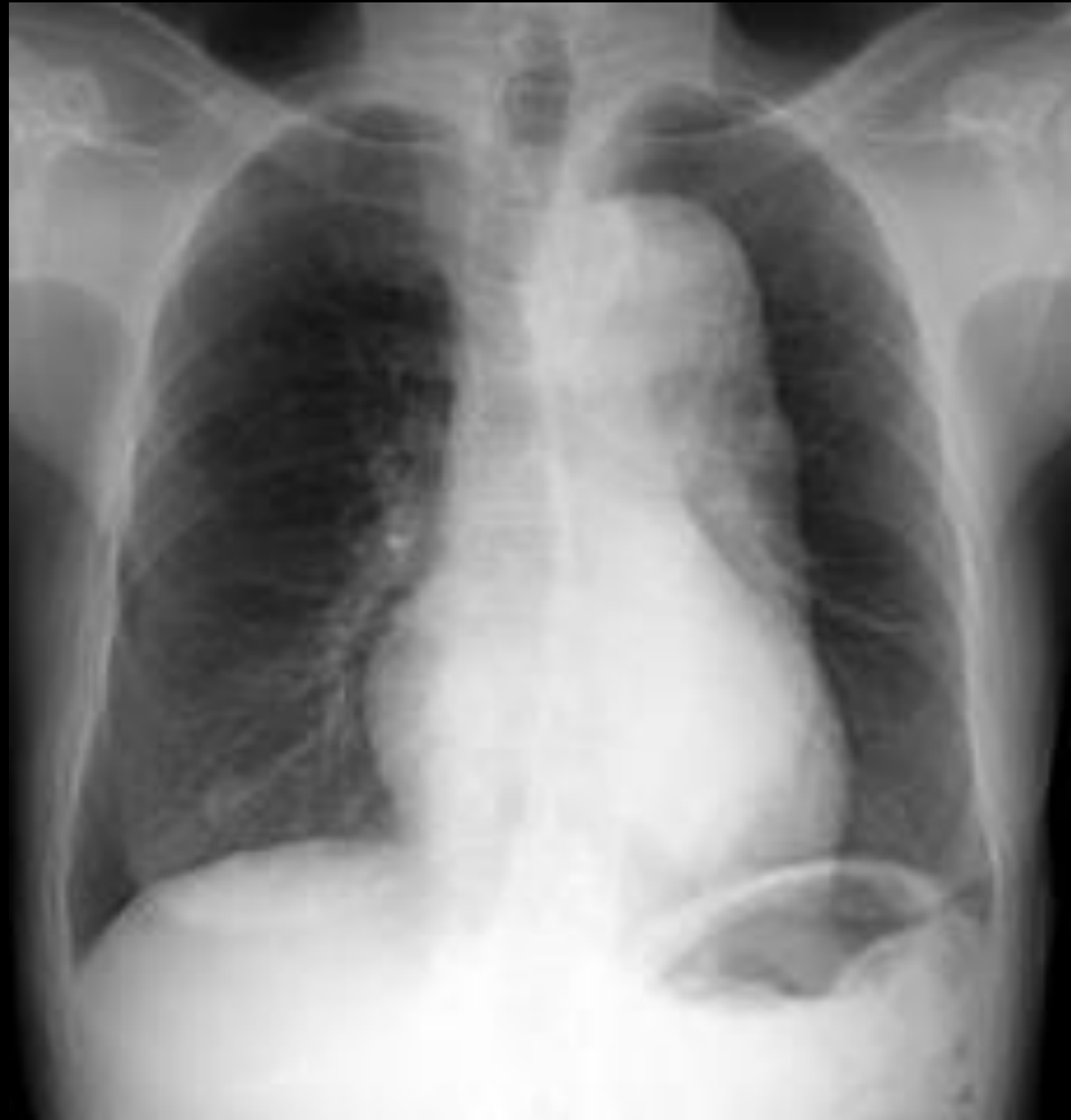

Right lower lobe collapse



50 year-old with
severe chest pain.

What is abnormal?



50 year-old with
severe chest pain.

What is abnormal?

➤ The aorta is enlarged.

What will you do next?



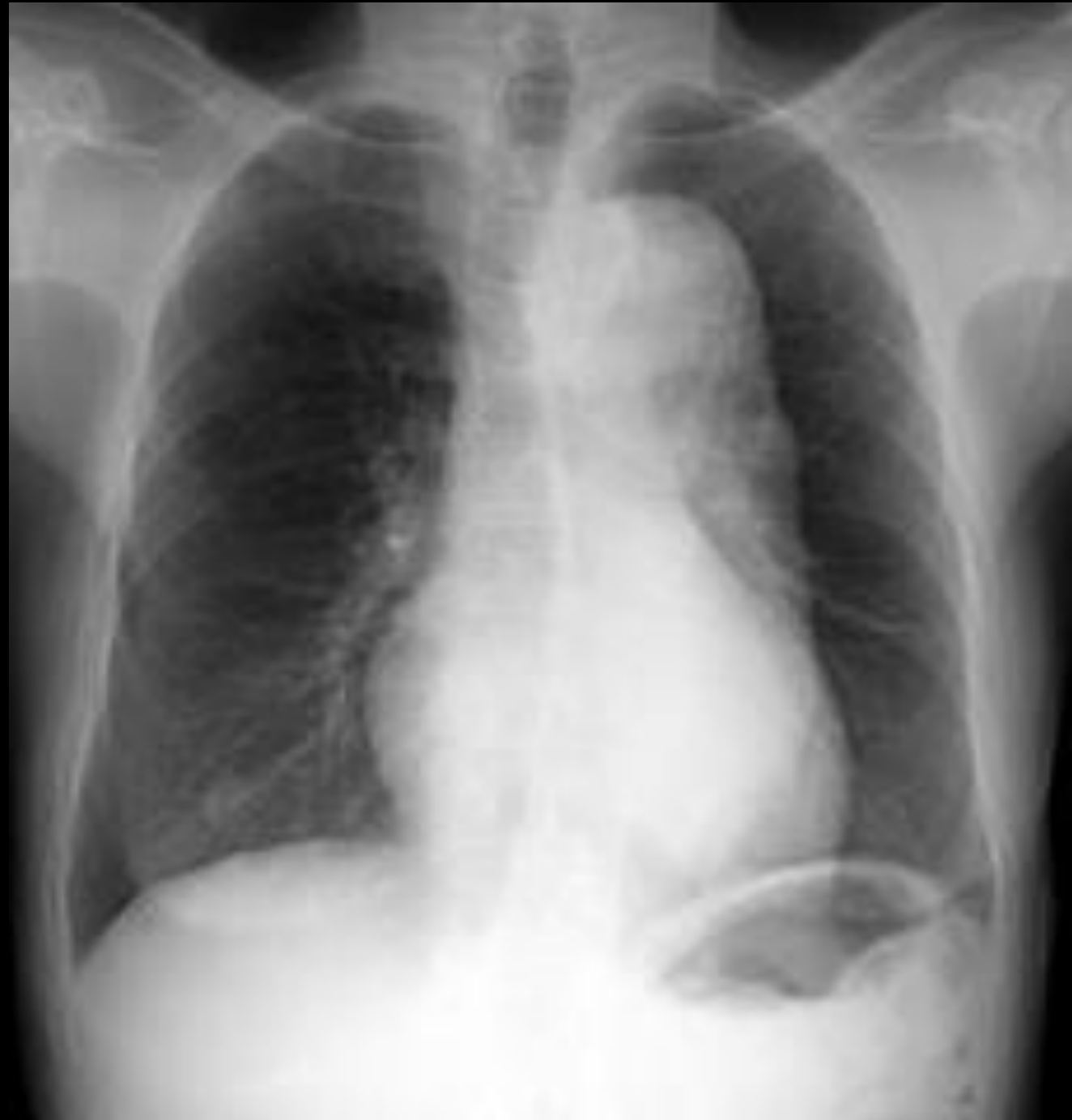50 year-old with
severe chest pain.

What is abnormal?

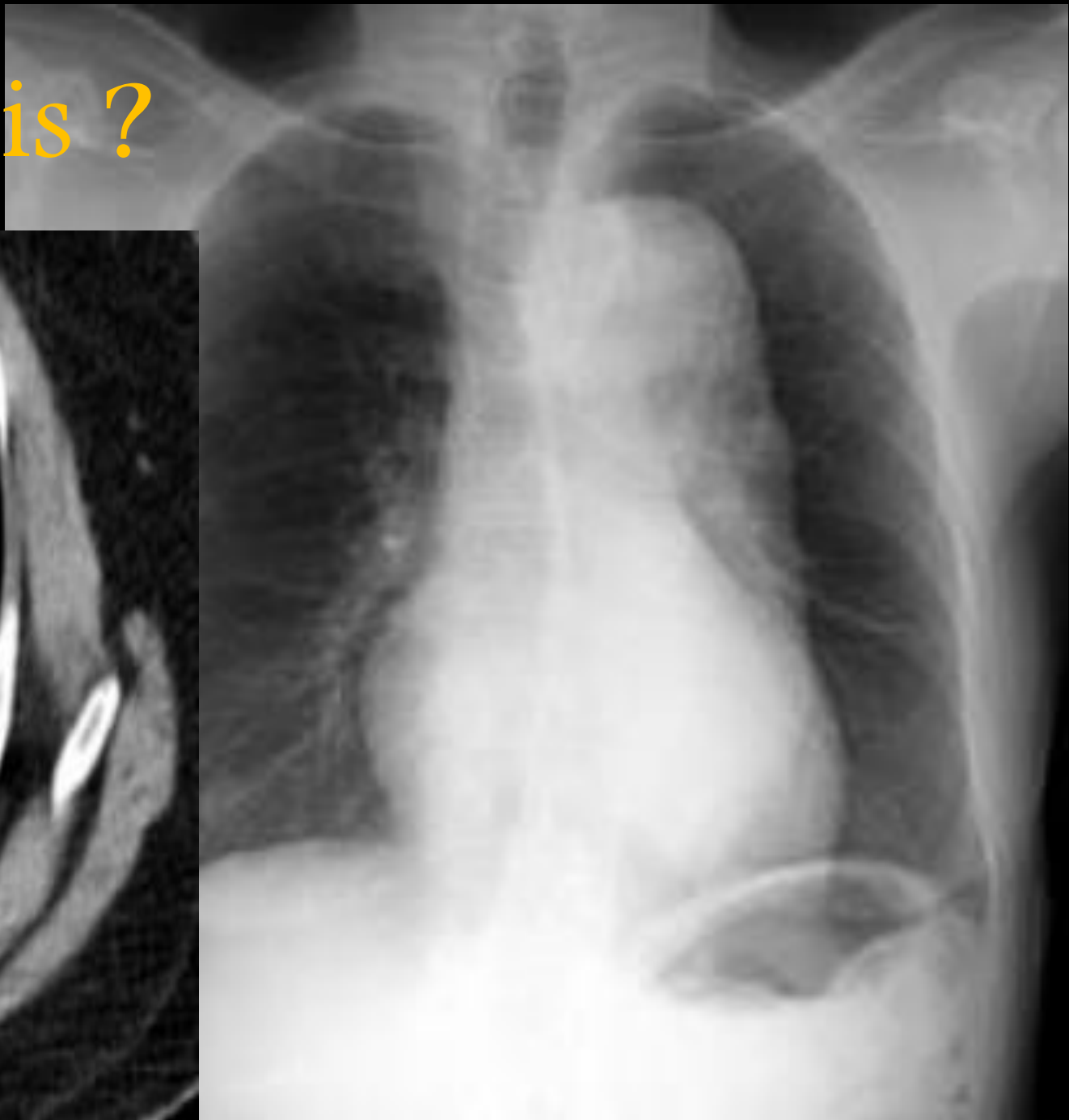
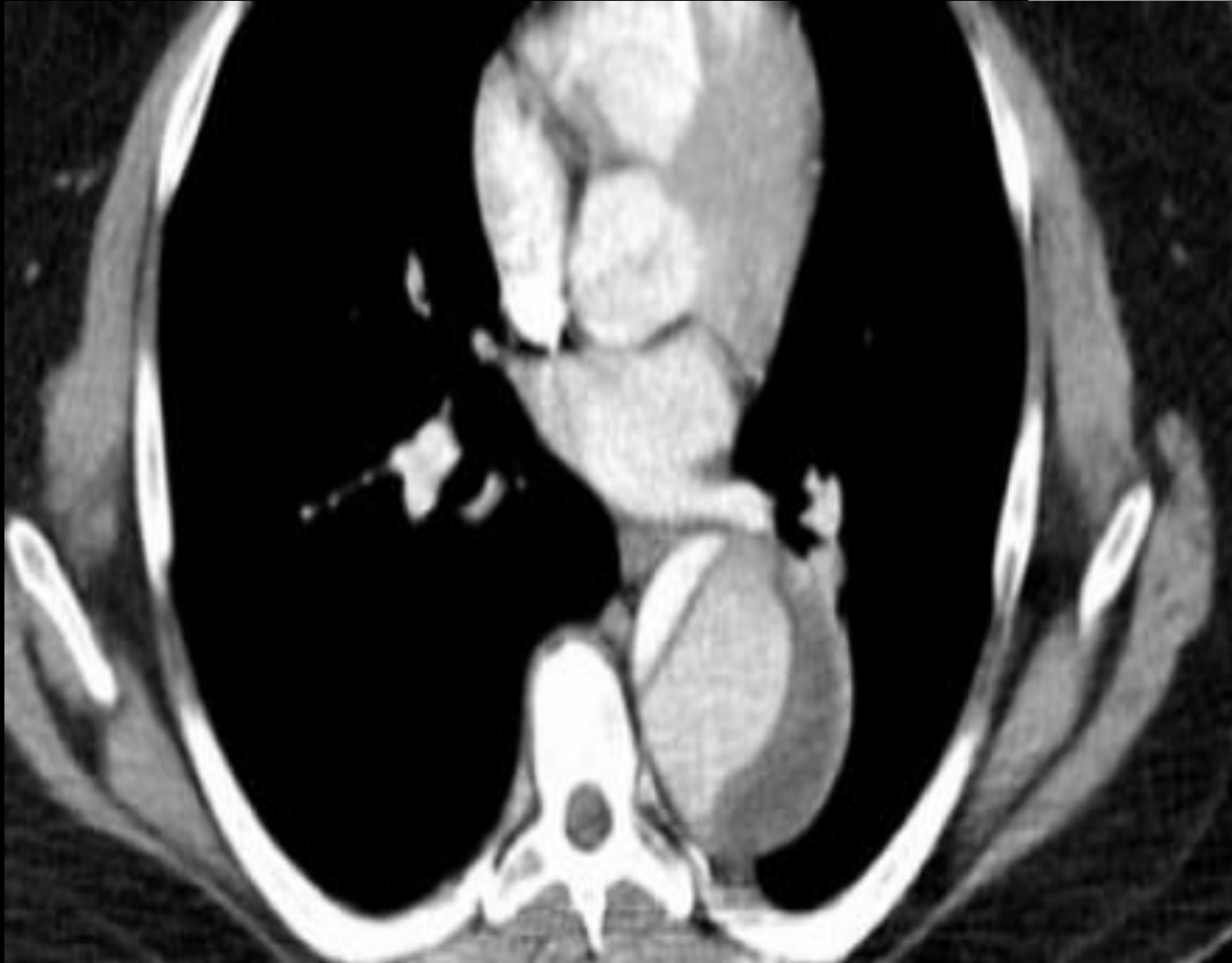➤ The aorta is enlarged.

What will you do next?

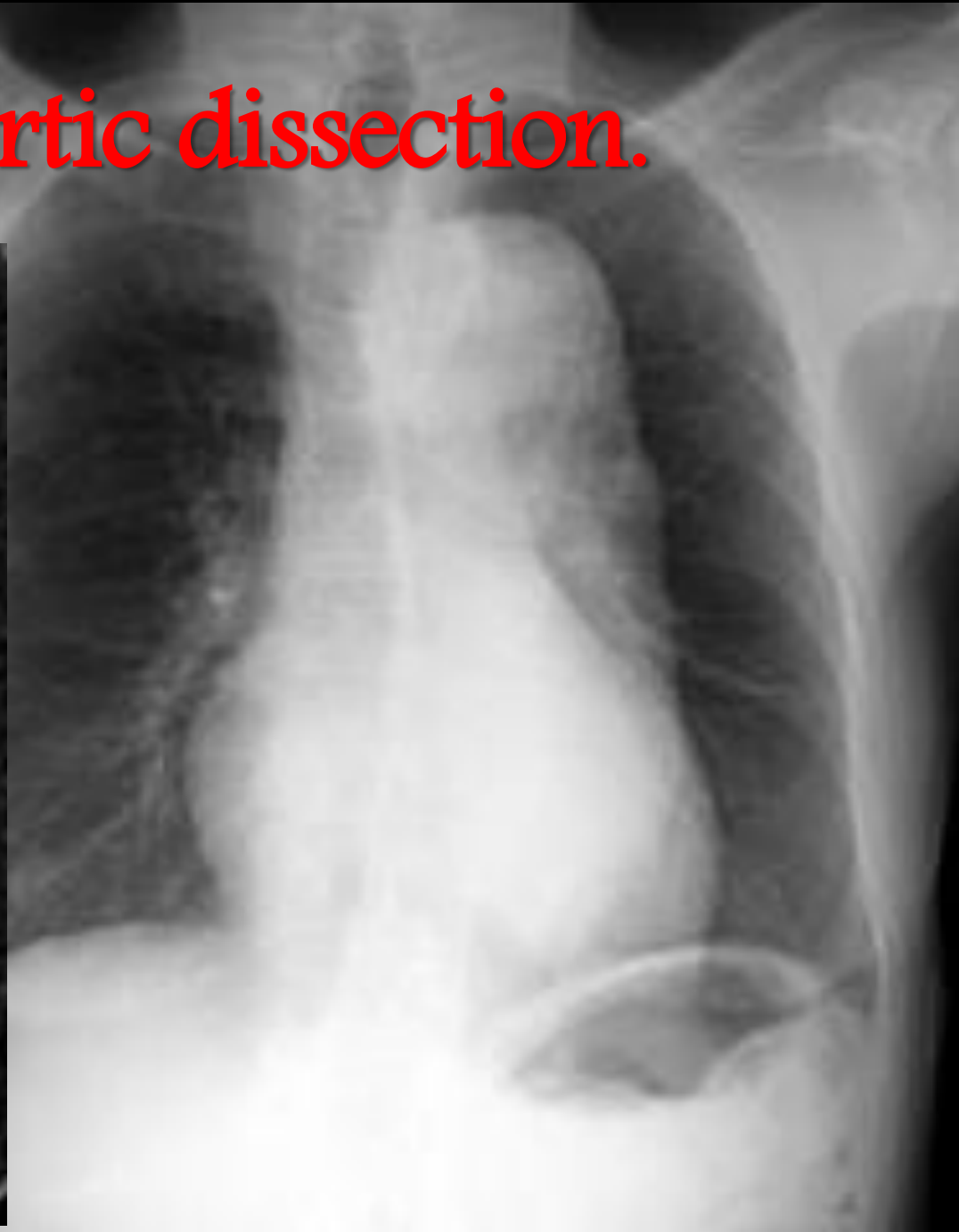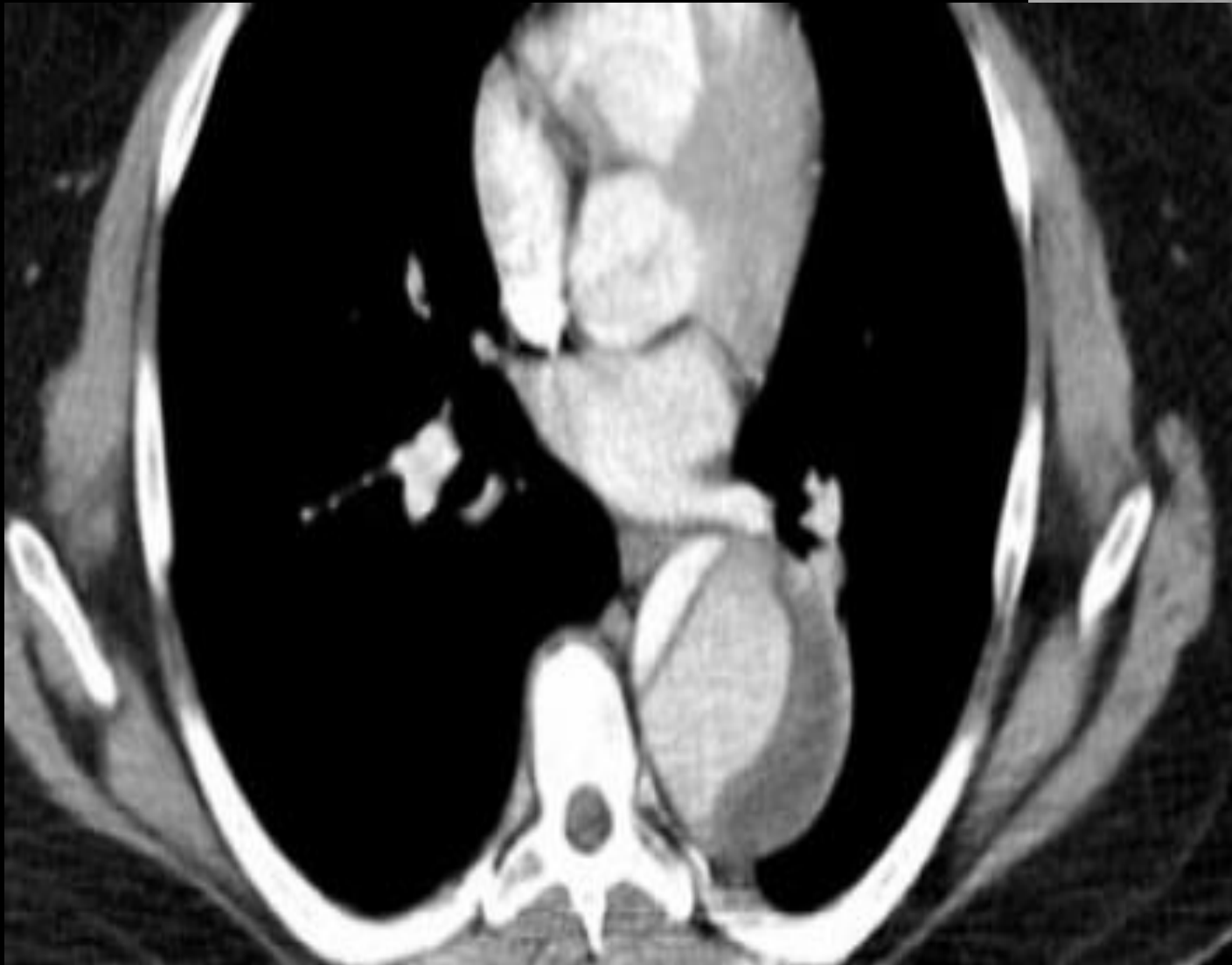
➤ CT scan (CT
aortogram)



What is the diagnosis ?

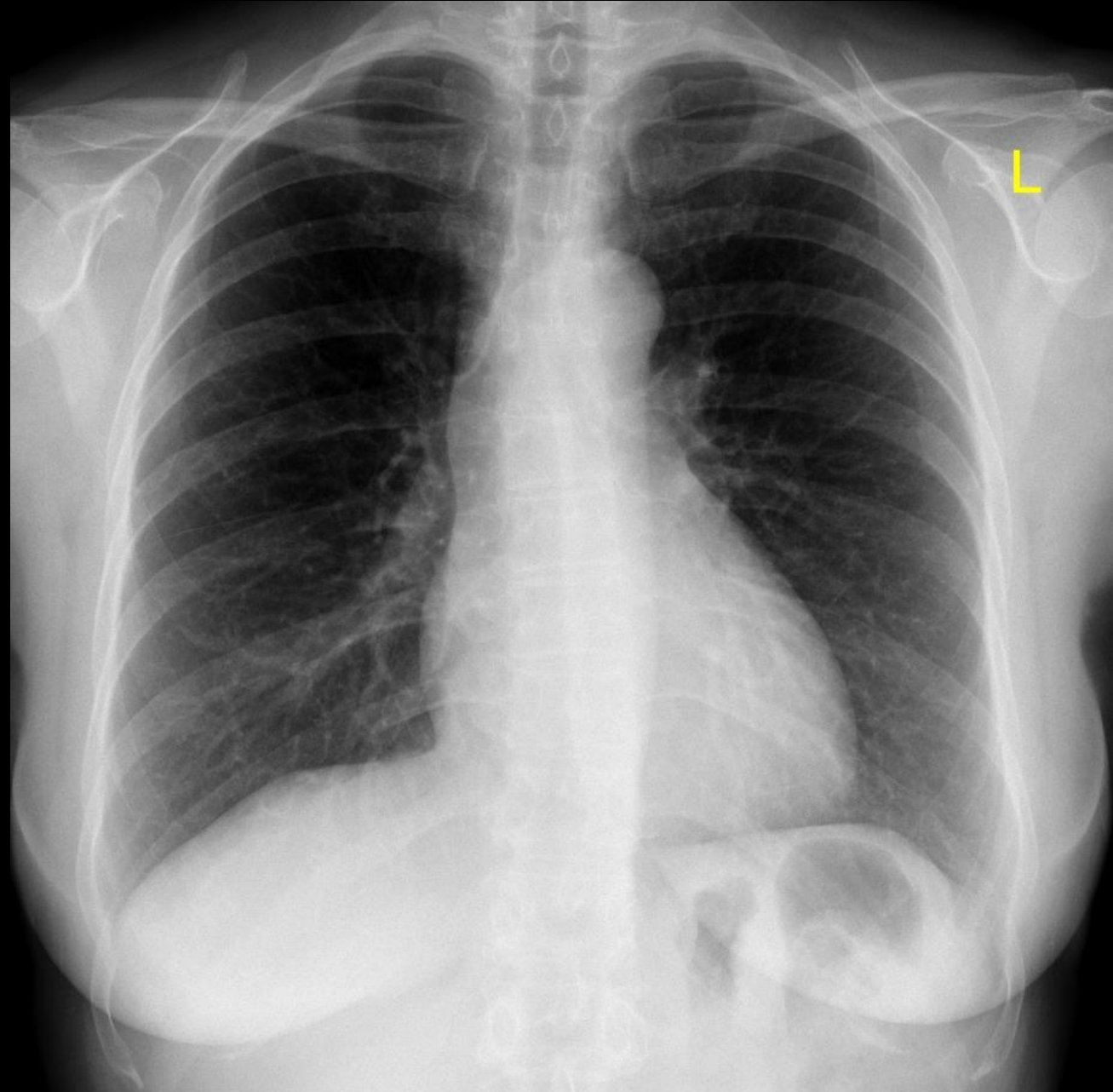


What is the diagnosis ? **Aortic dissection.**



40 year-old female with chest pain after a 7 hours flight. She had previous deep vein thrombosis in her lower limbs.

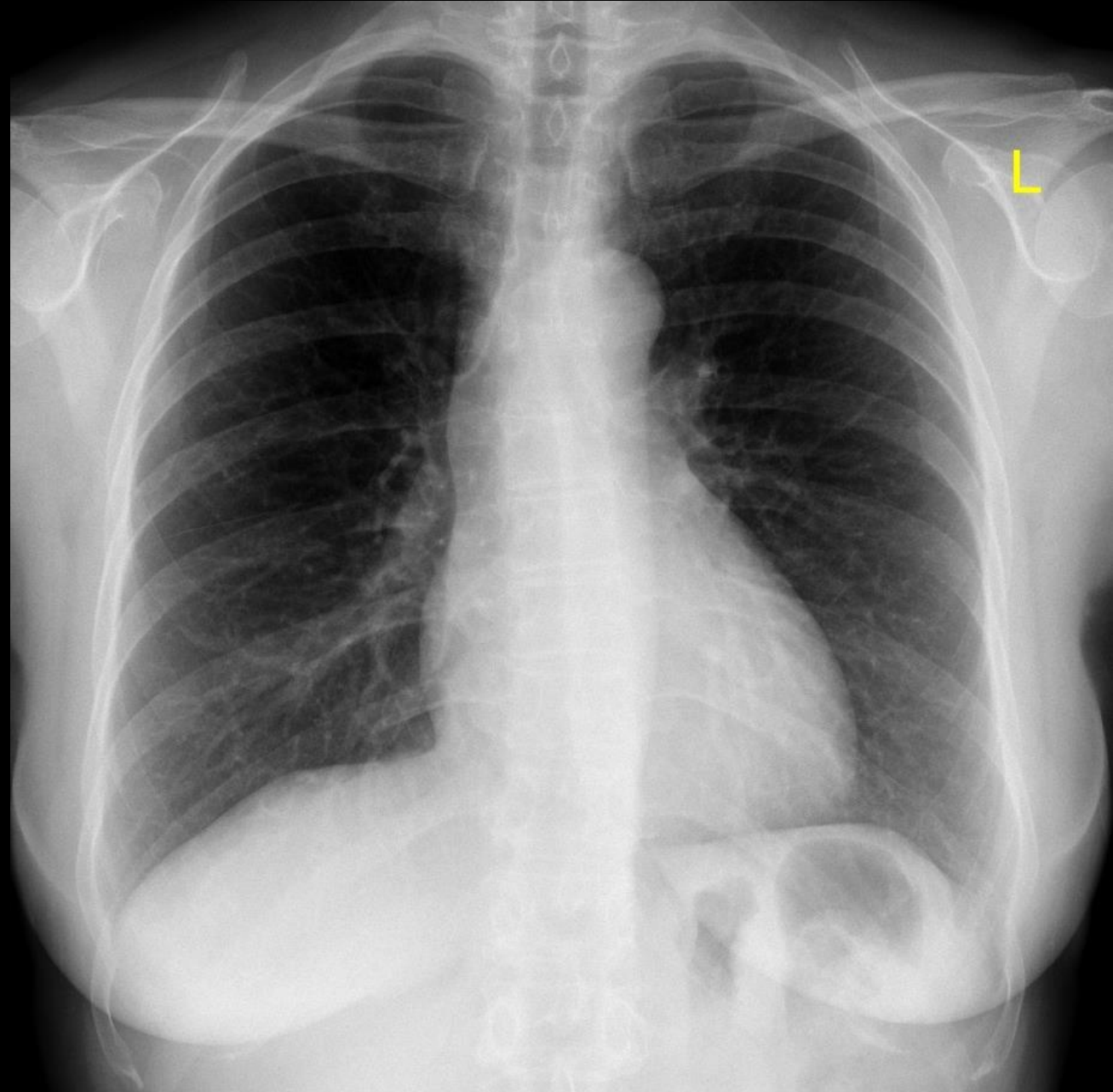
What are you suspecting this patient has?



40 year-old female with chest pain after a 7 hours flight. She had previous deep vein thrombosis in her lower limbs.

What are you suspecting this patient has?

➤ Pulmonary embolism

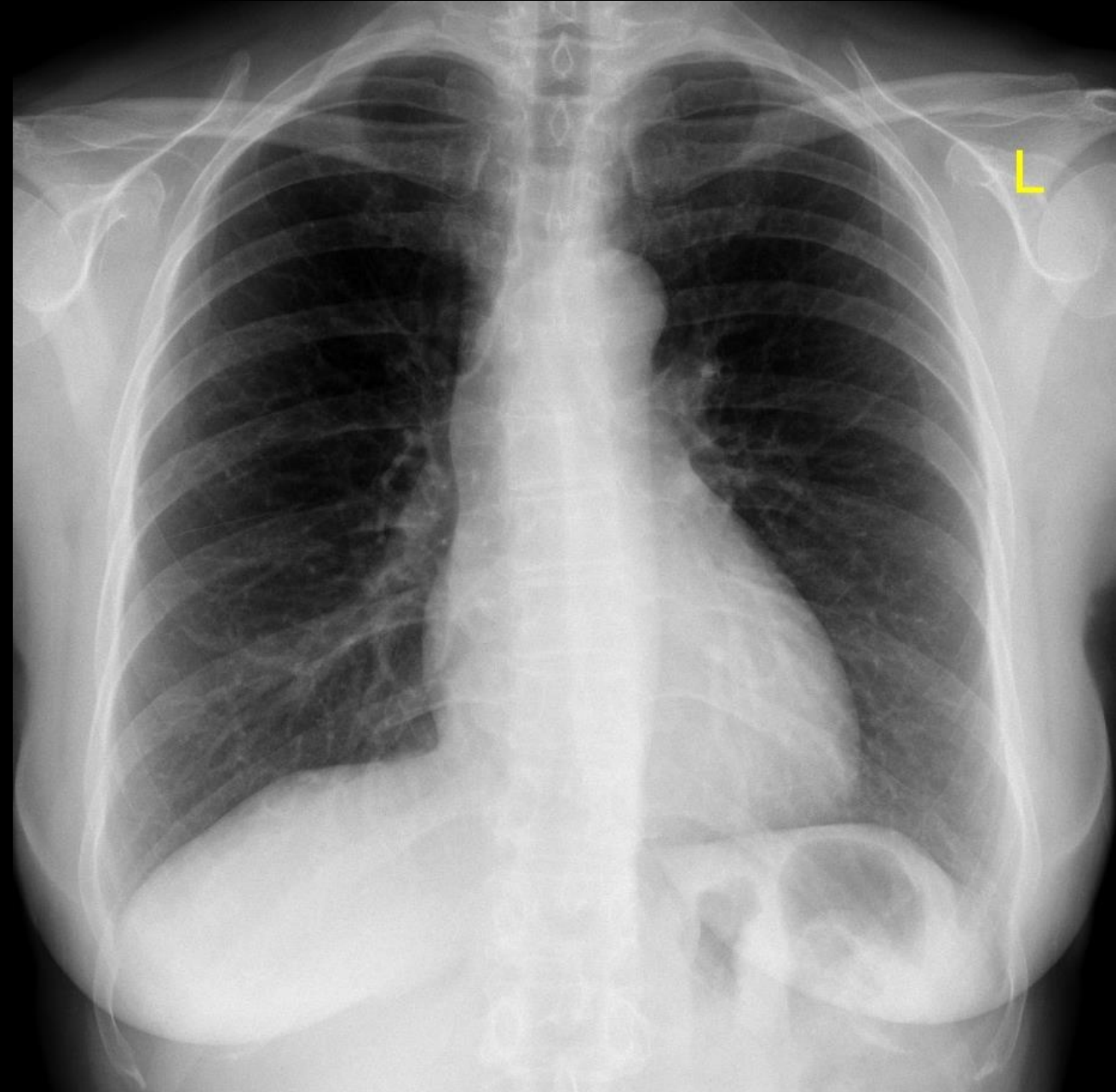


40 year-old female with chest pain after a 7 hours flight. She had previous deep vein thrombosis in her lower limbs.

What are you suspecting this patient has?

➤ Pulmonary embolism

Do you see any abnormality in this chest x ray?



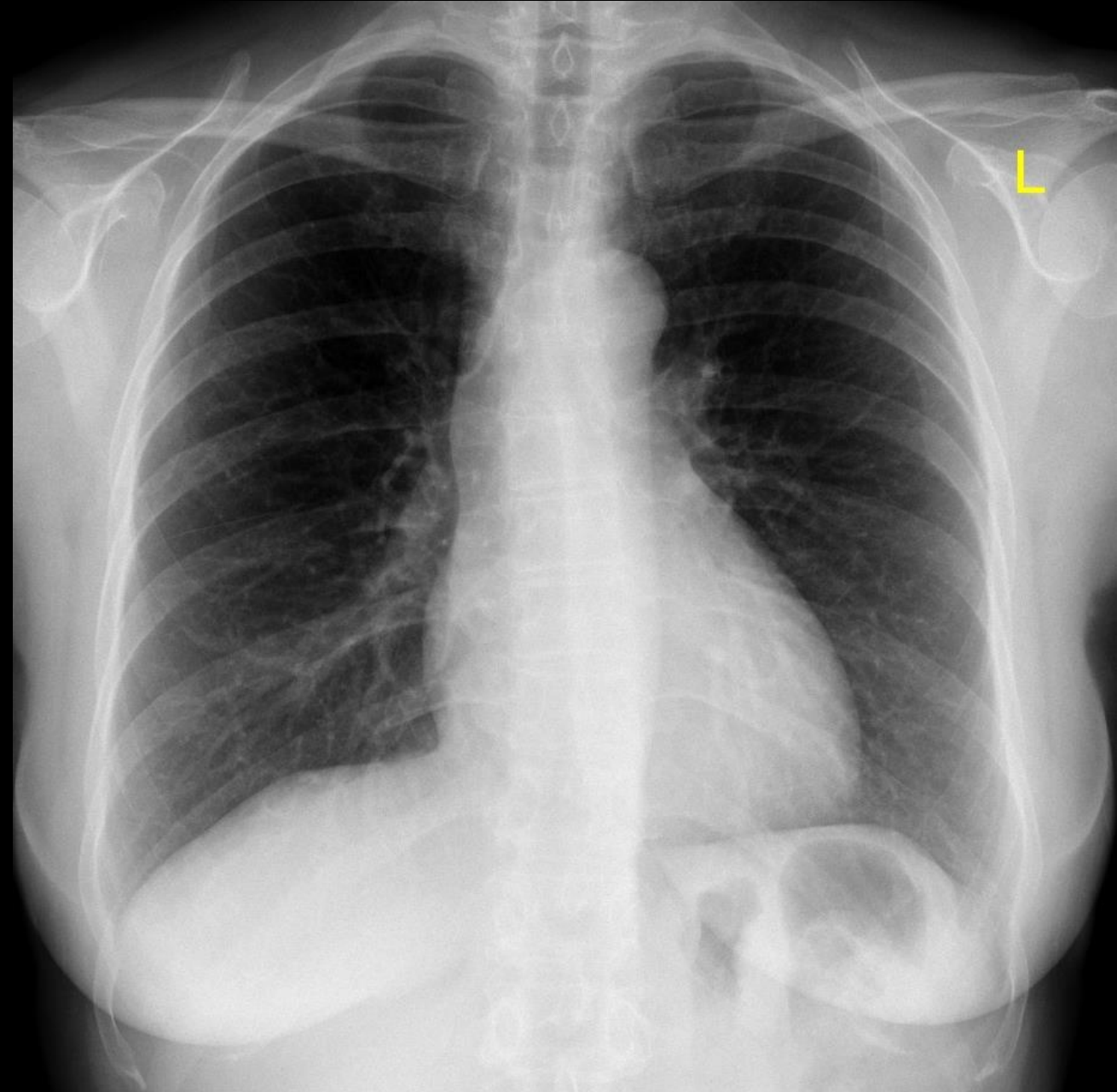
40 year-old female with chest pain after a 7 hours flight. She had previous deep vein thrombosis in her lower limbs.

What are you suspecting this patient has?

➤ Pulmonary embolism

Do you see any abnormality in this chest x ray?

➤ No



40 year-old female with chest pain after a 7 hours flight. She had previous deep vein thrombosis in her lower limbs.

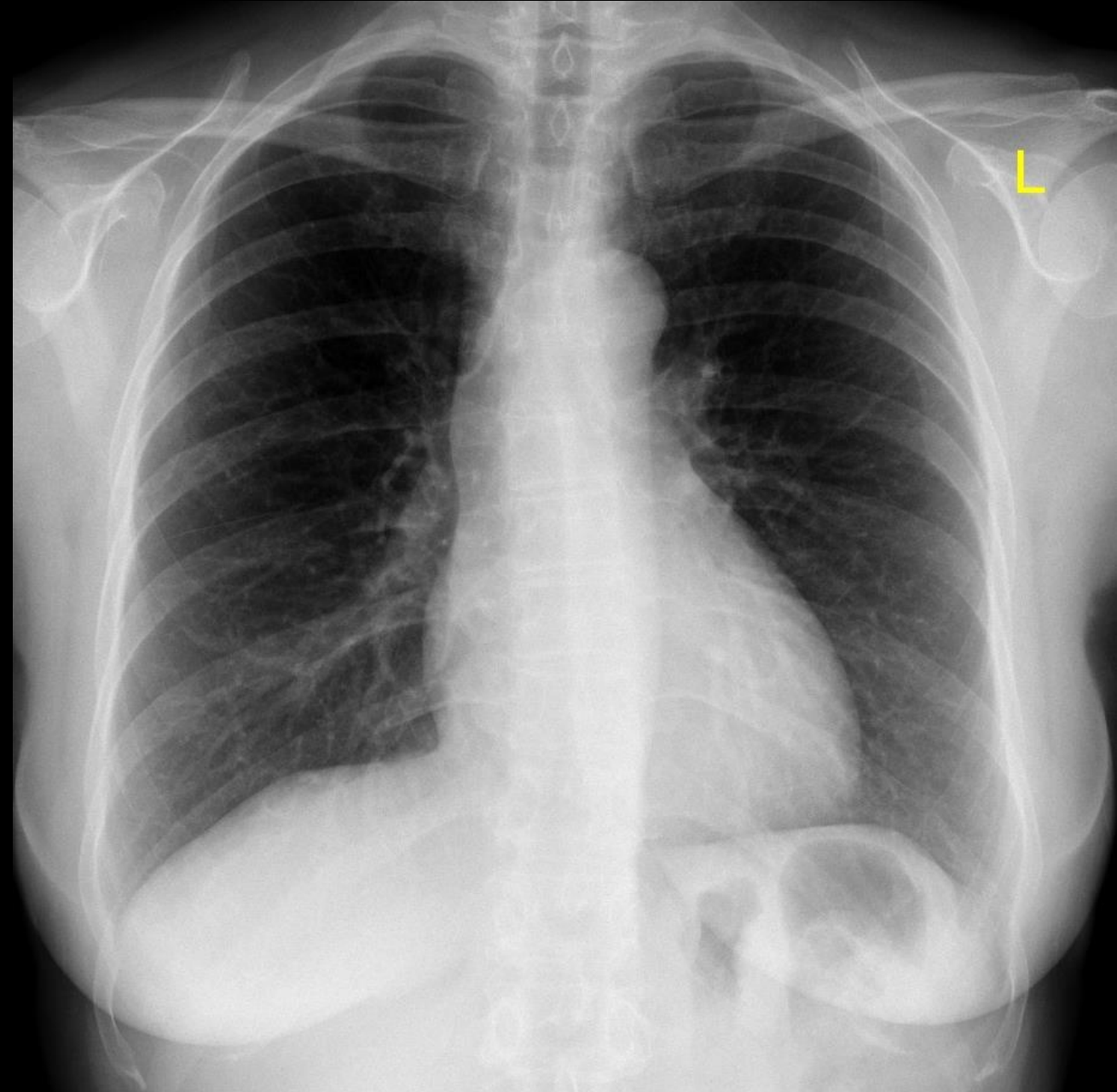
What are you suspecting this patient has?

➤ Pulmonary embolism

Do you see any abnormality in this chest x ray?

➤ No

What to do next ?



40 year-old female with chest pain after a 7 hours flight. She had previous deep vein thrombosis in her lower limbs.

What are you suspecting this patient has?

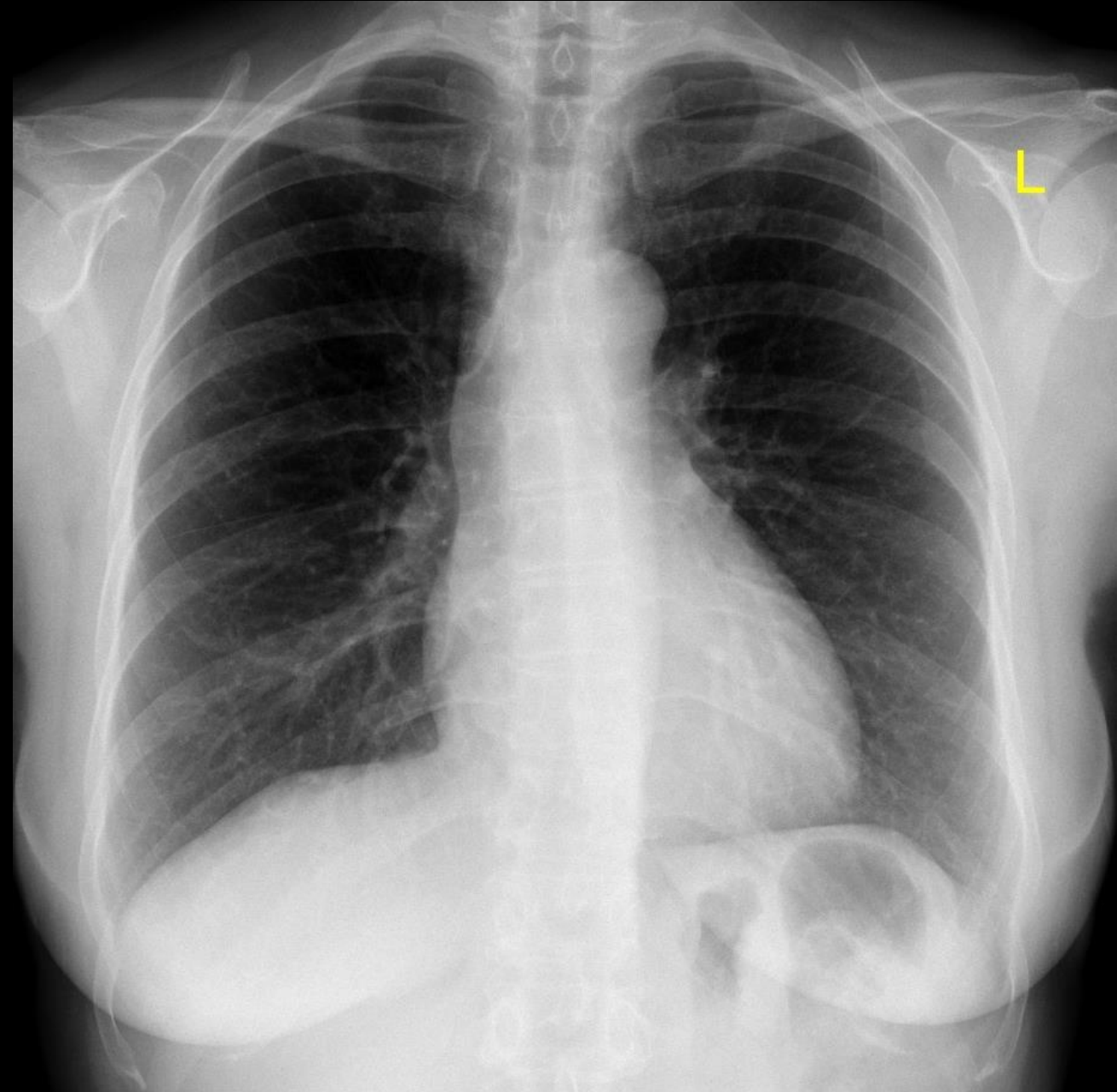
➤ Pulmonary embolism

Do you see any abnormality in this chest x ray?

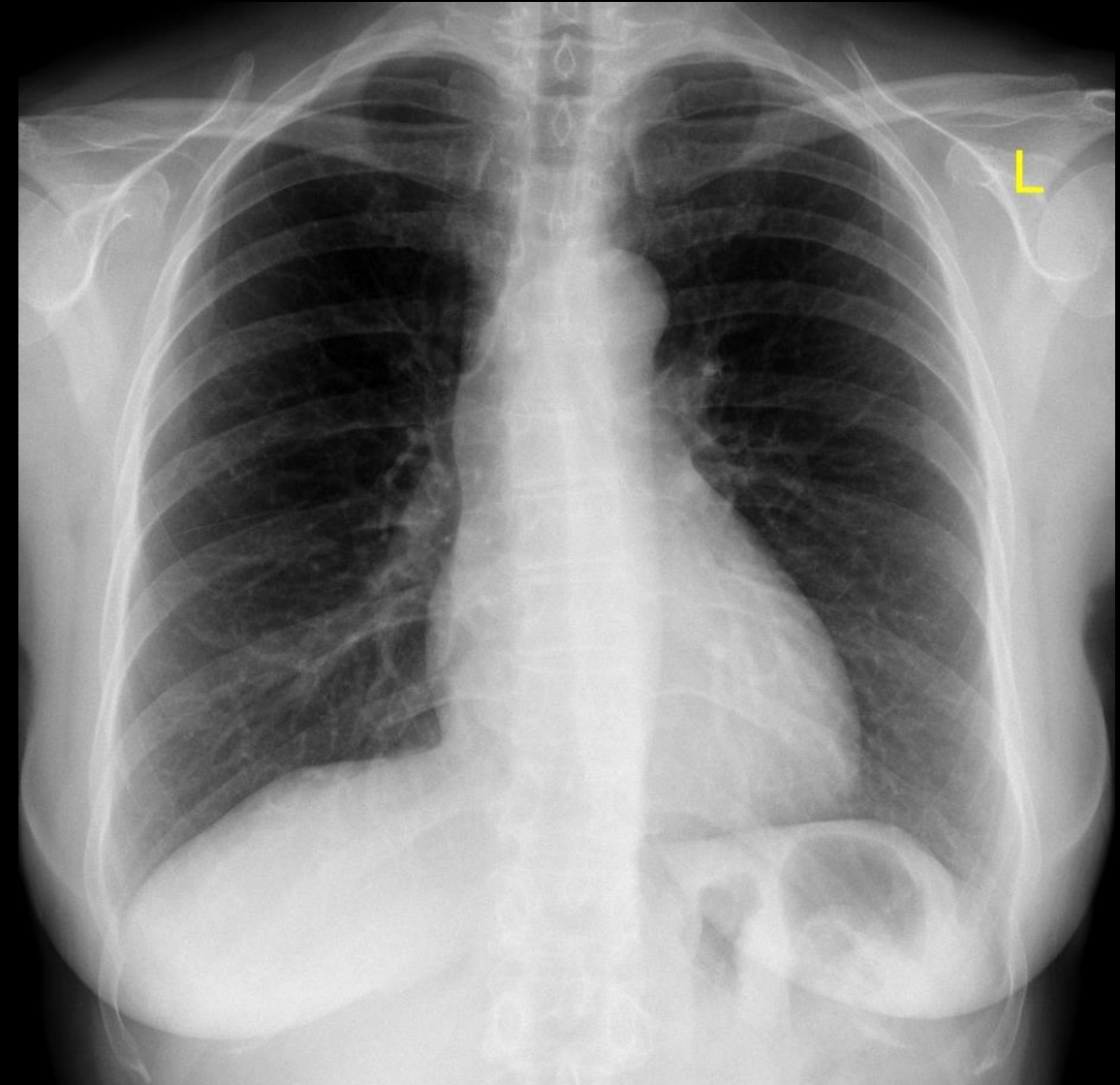
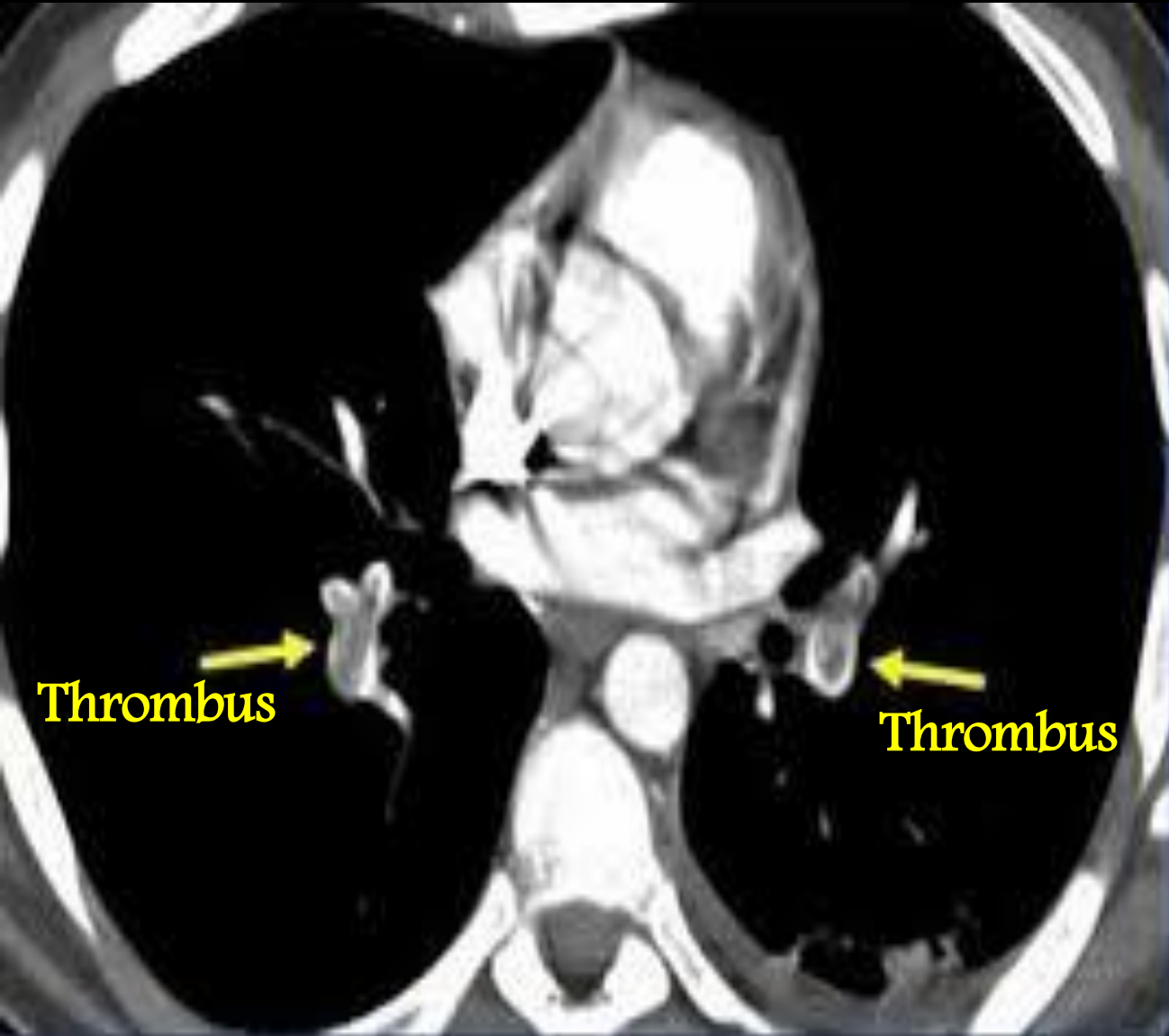
➤ No

What to do next ?

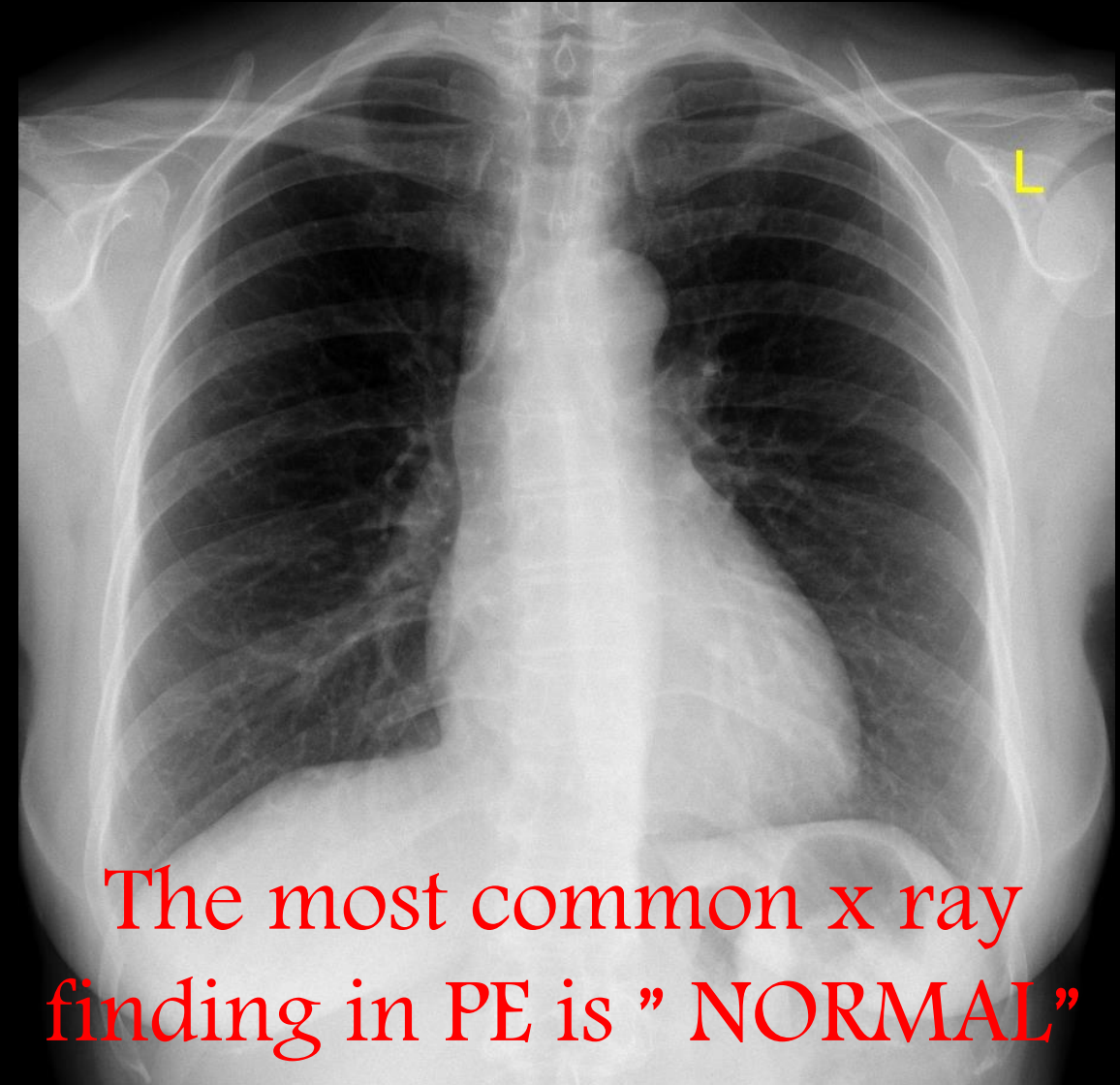
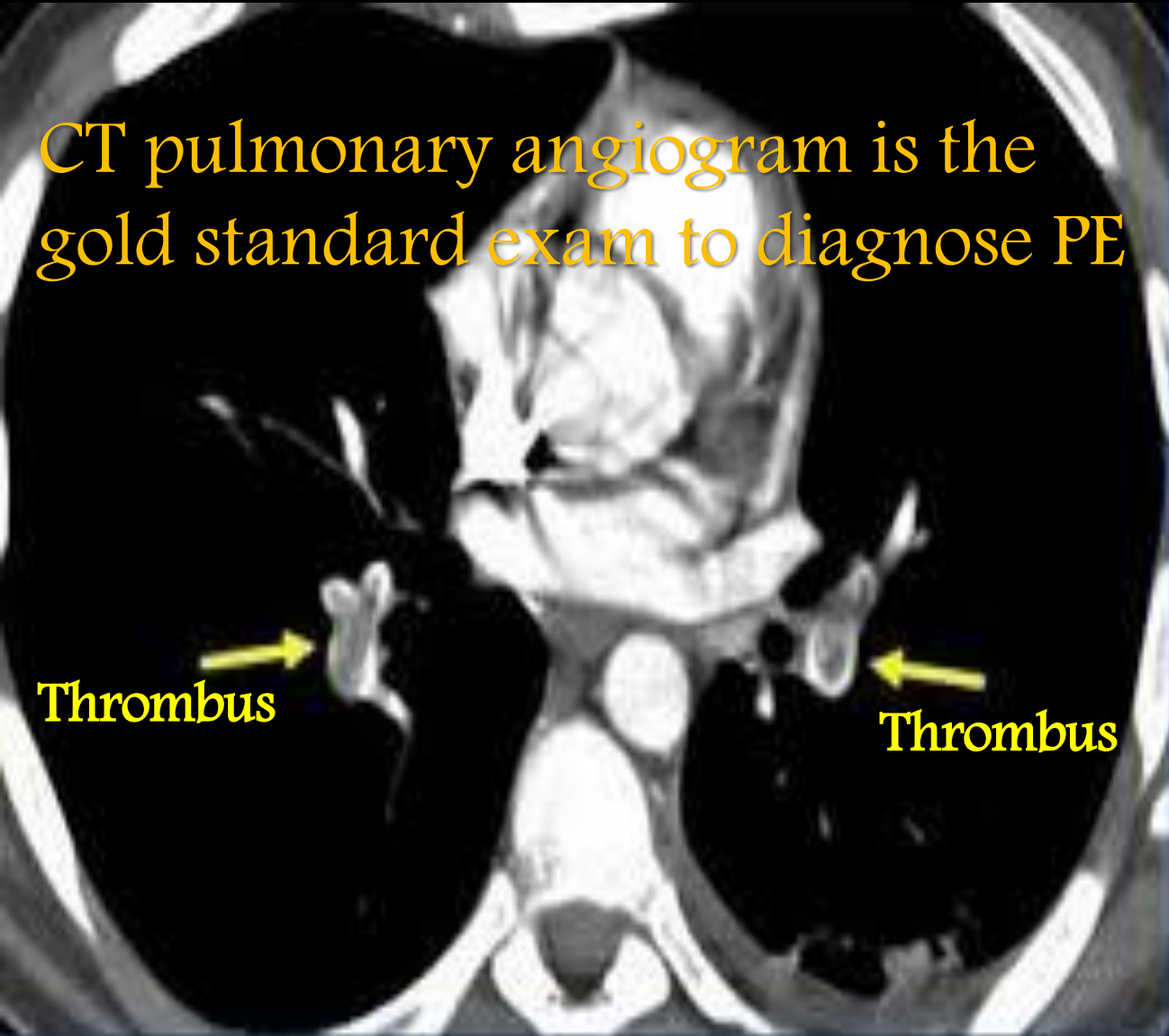
➤ CT pulmonary angiogram.



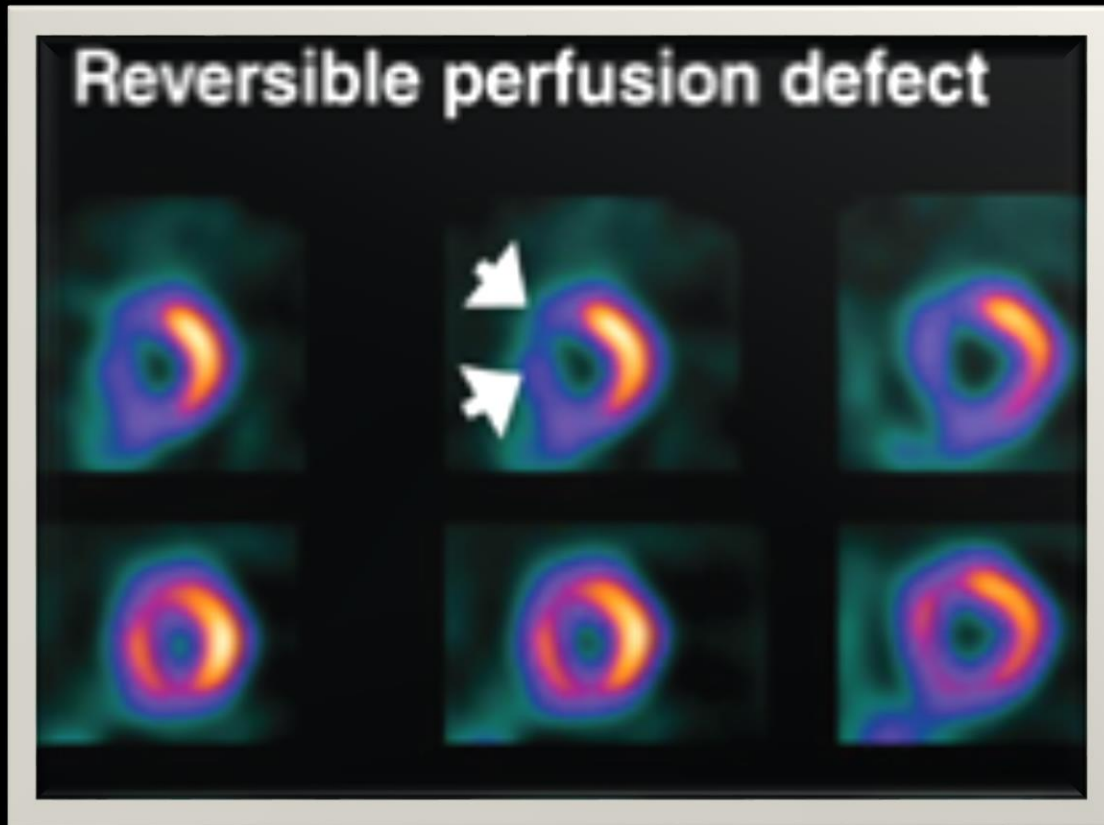
Pulmonary embolism



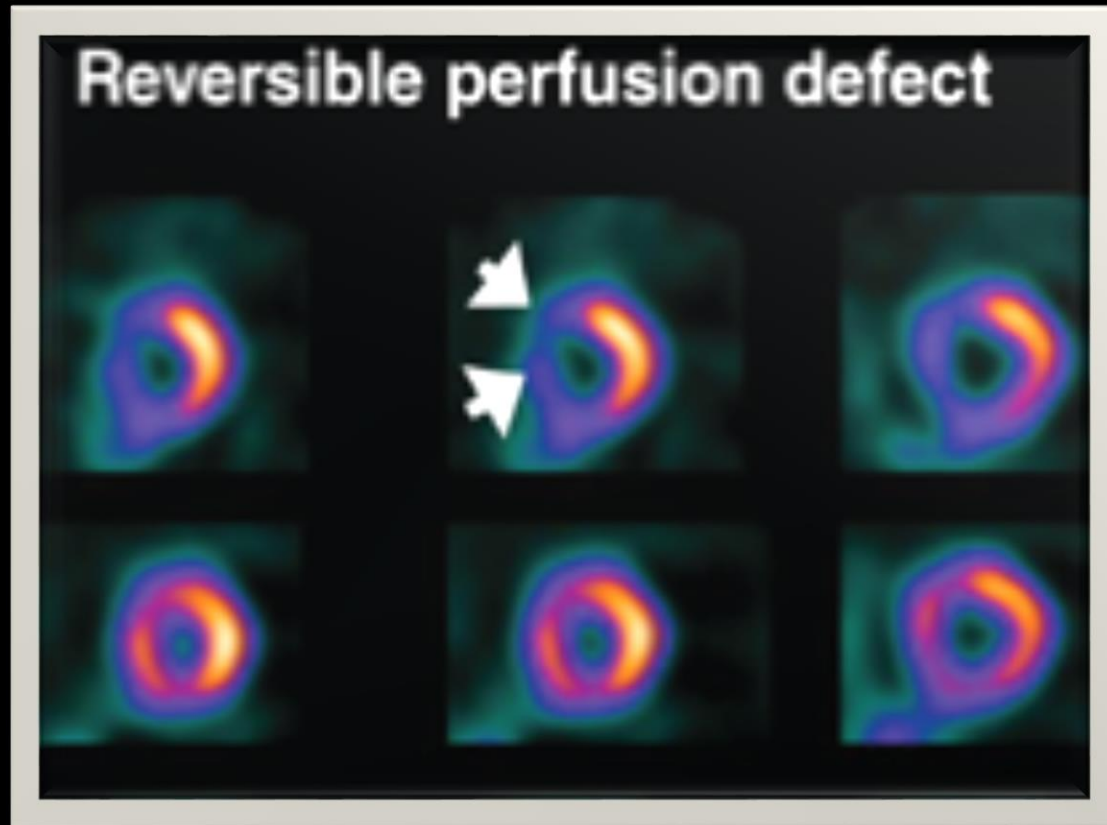
Pulmonary embolism



What is the diagnosis ?



What is the diagnosis ?



Myocardial ischemia



Myocardial infarction

Thank you