



# **Presentation & Management Of Common Thoracic Diseases**

Dr. Waseem HAJJAR MD, FRCS, FCCP.

Associate Professor &

Consultant thoracic surgeon

# The Lung

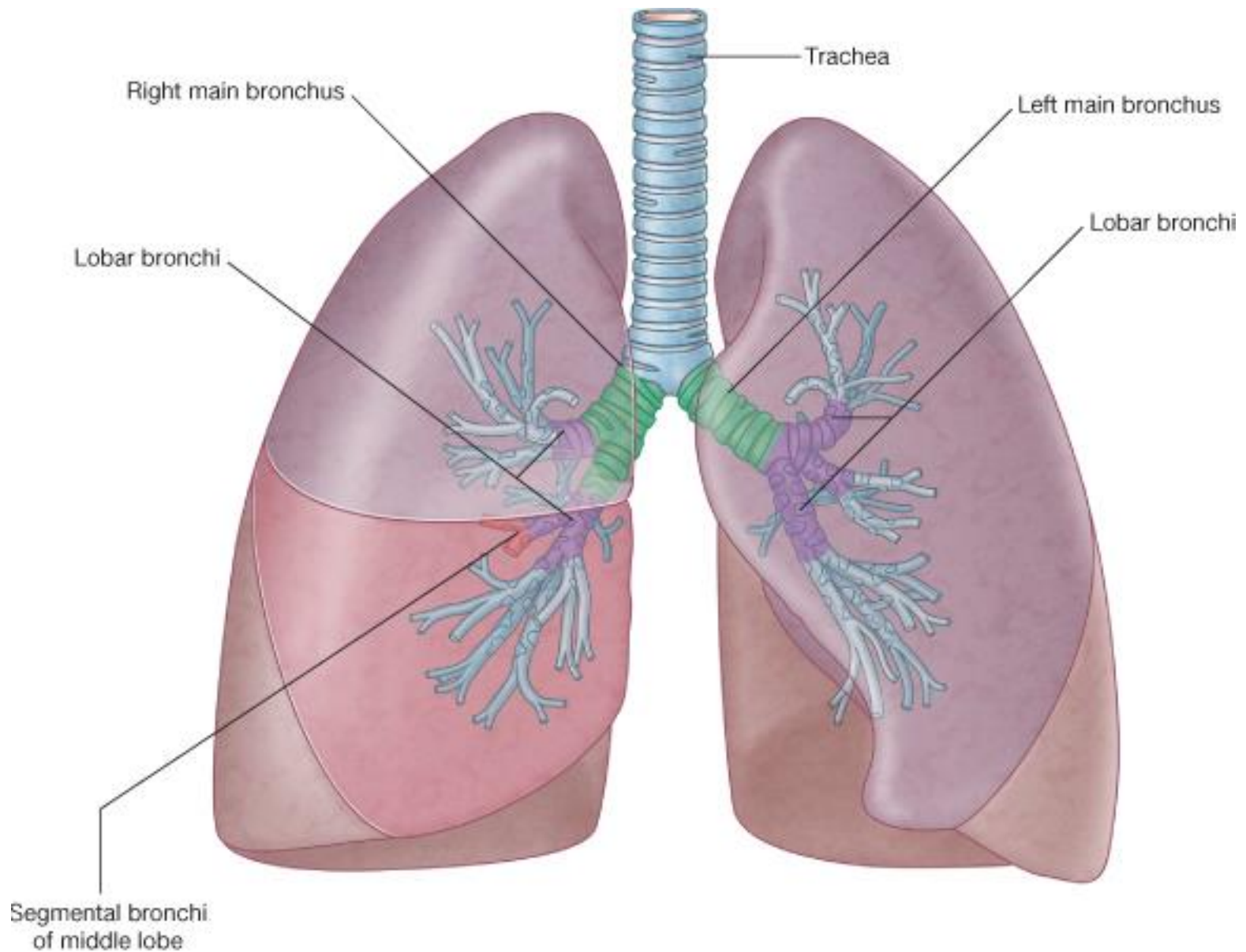
## ➤ Embryology

- **Bronchial system**
- **Alveolar system**

## ➤ Anatomy

- **Lobes**
- **Fissures**
- **Segments**
- **Blood supply**

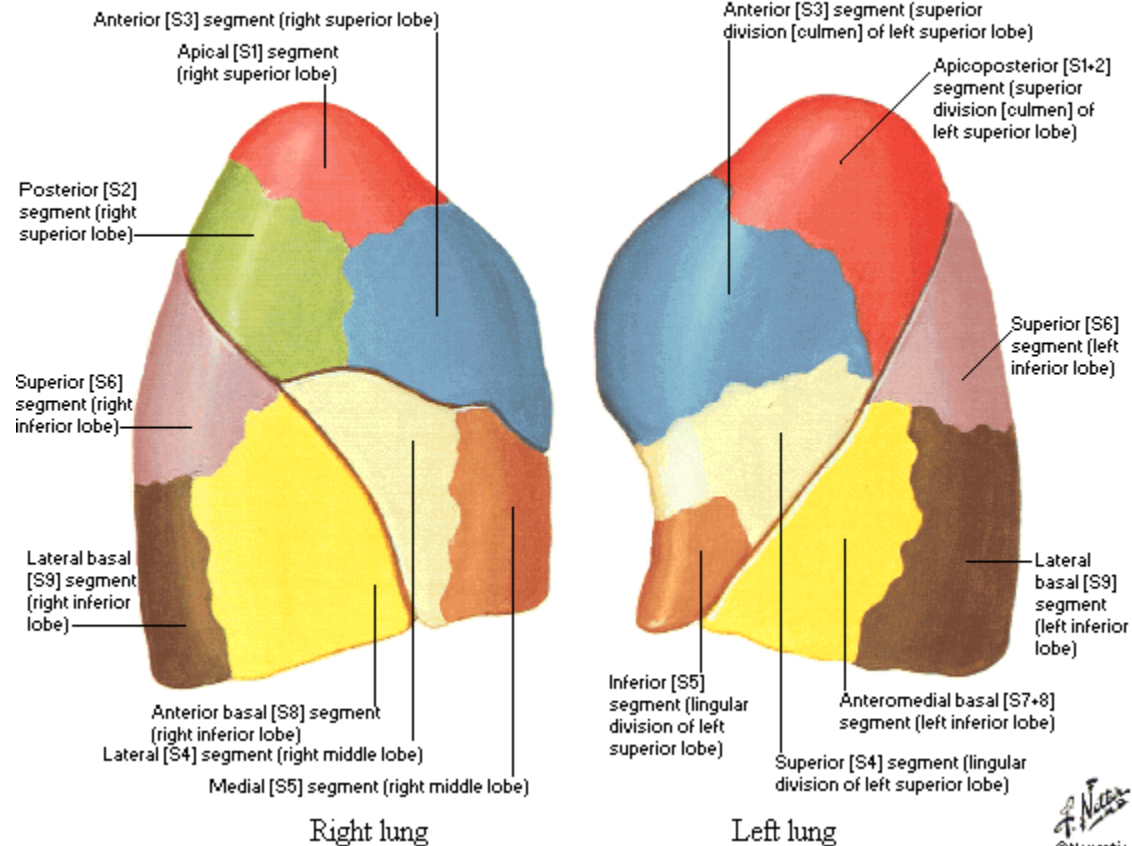
# Airways



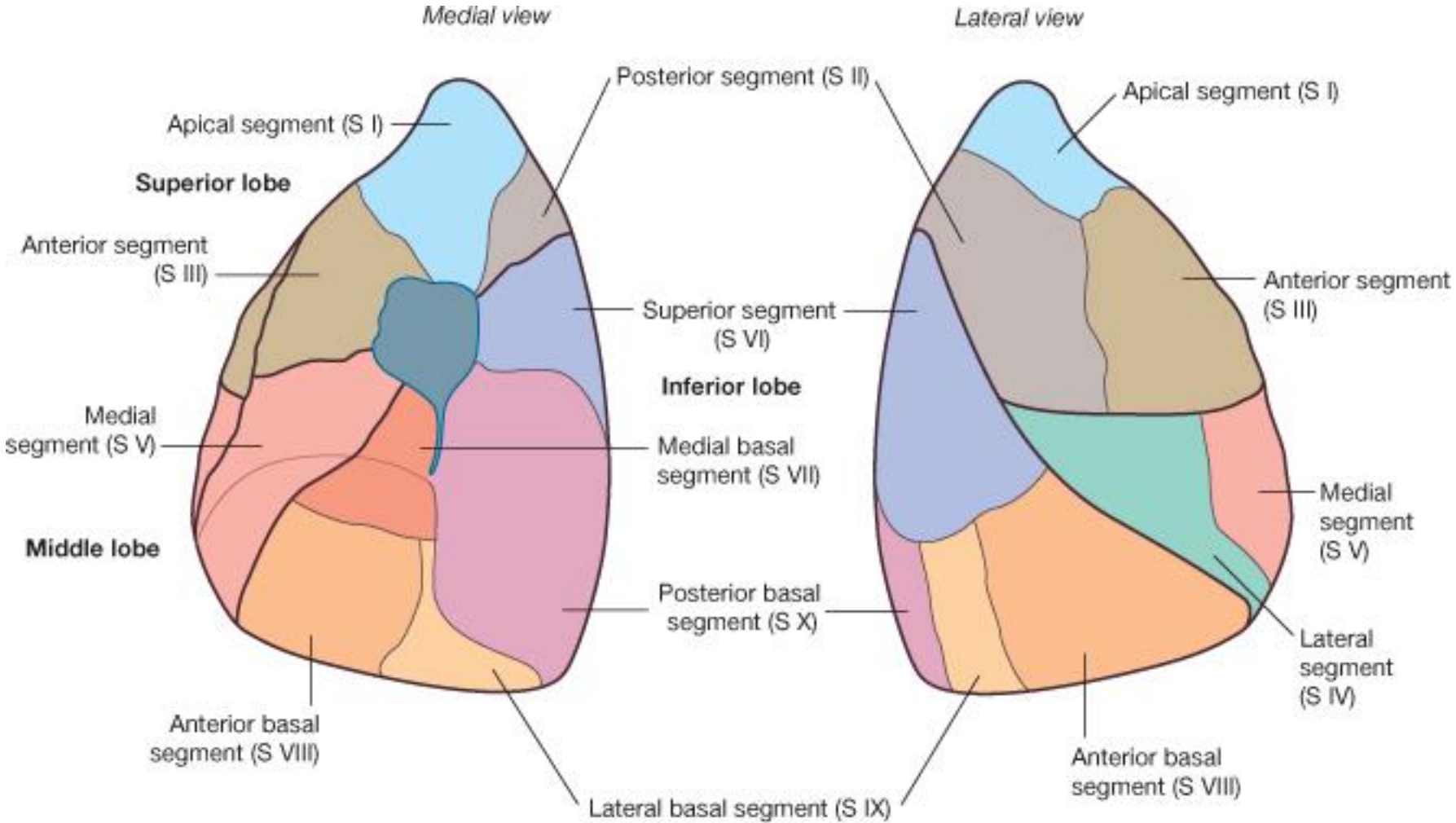
# Bronchopulmonary Segments

## Bronchopulmonary Segments

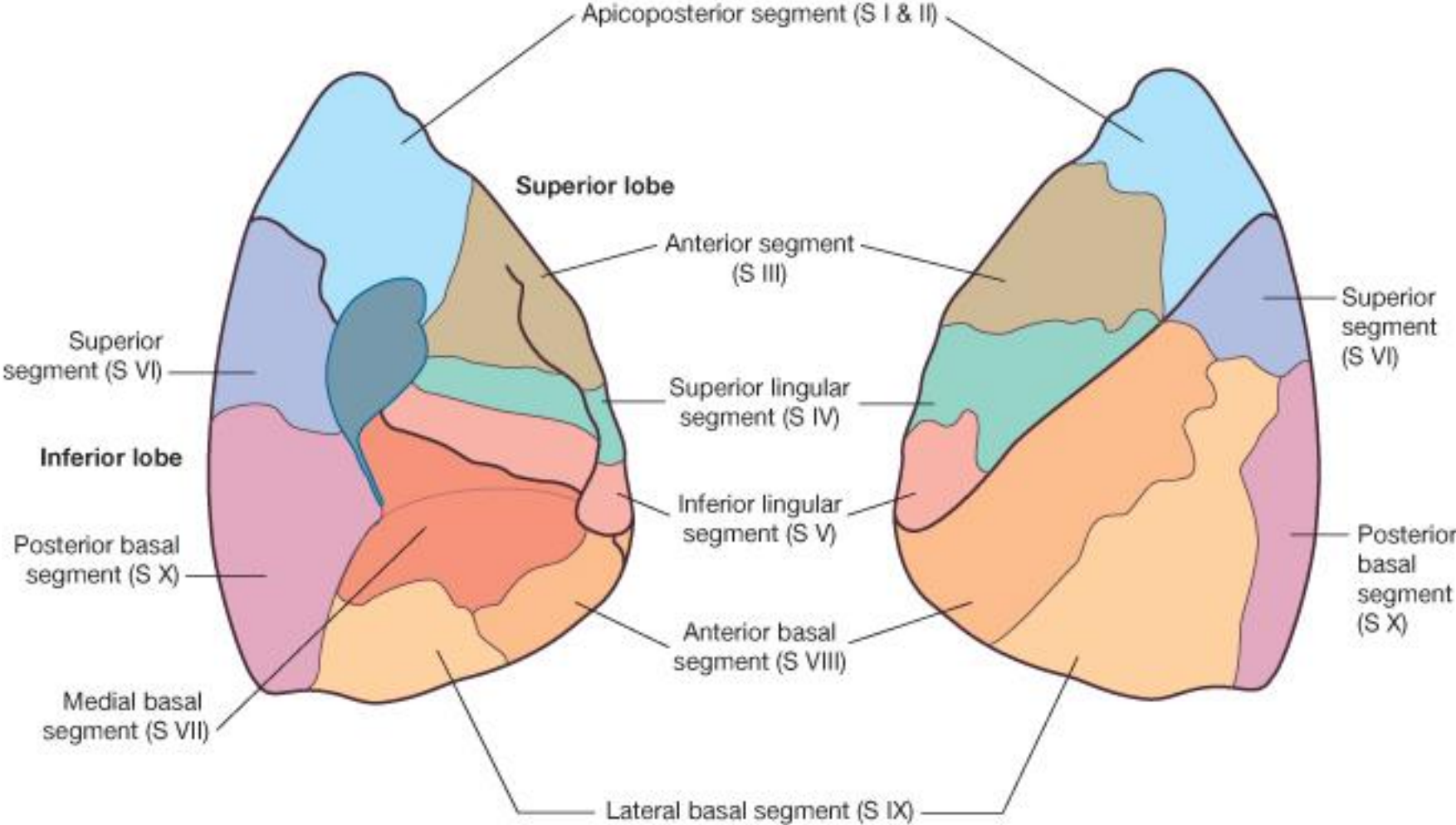
### Lateral Views



# Bronchopulmonary Segments



# Bronchopulmonary Segments

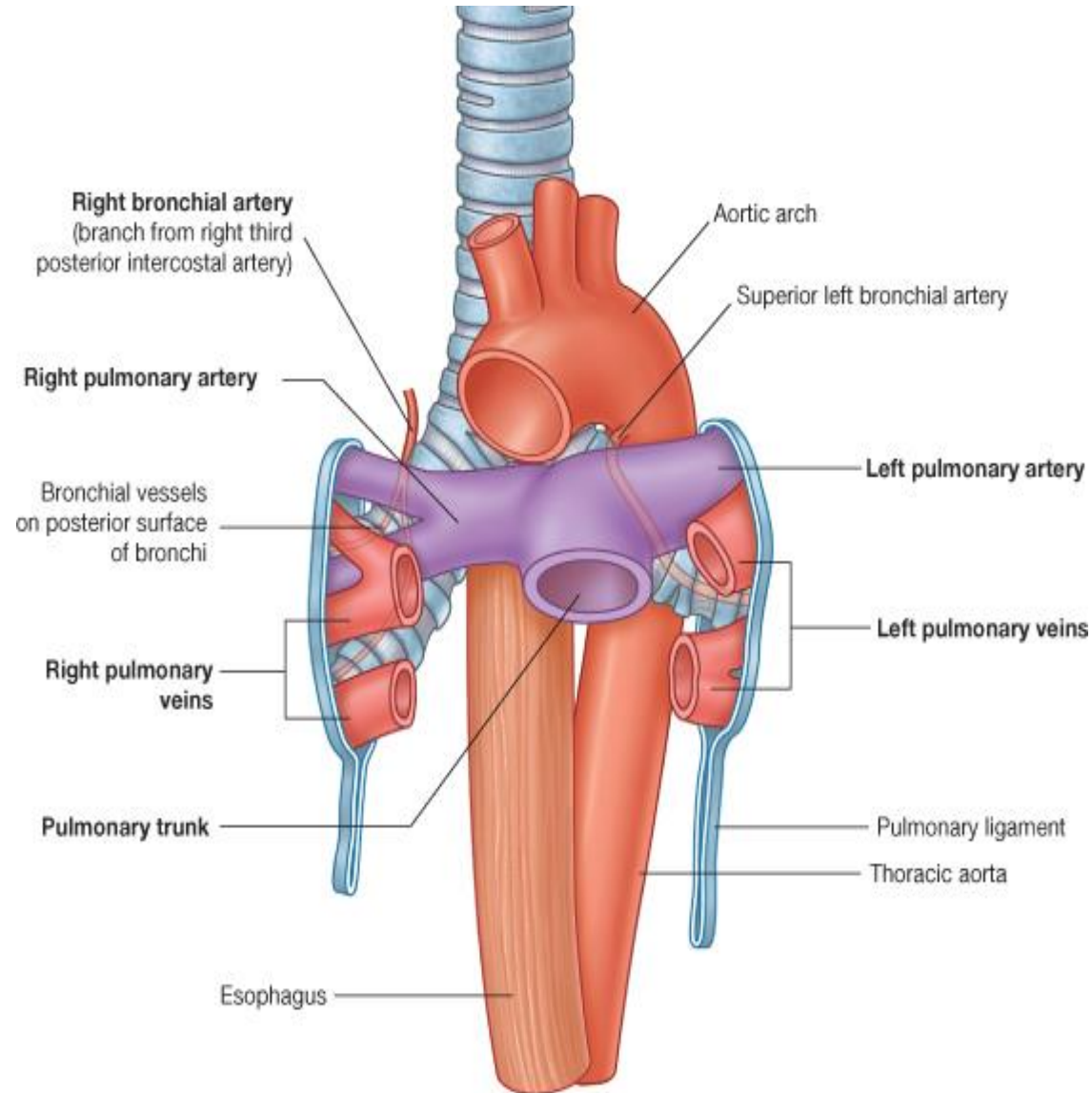


# Blood Supply

- Lungs do not receive any vascular supply from the pulmonary vessels (pulmonary aa. or veins).
- Blood delivered to lung tissue via the bronchiole arteries.
- Vessels evolve from aortic arch.
- Travel along the bronchial tree.

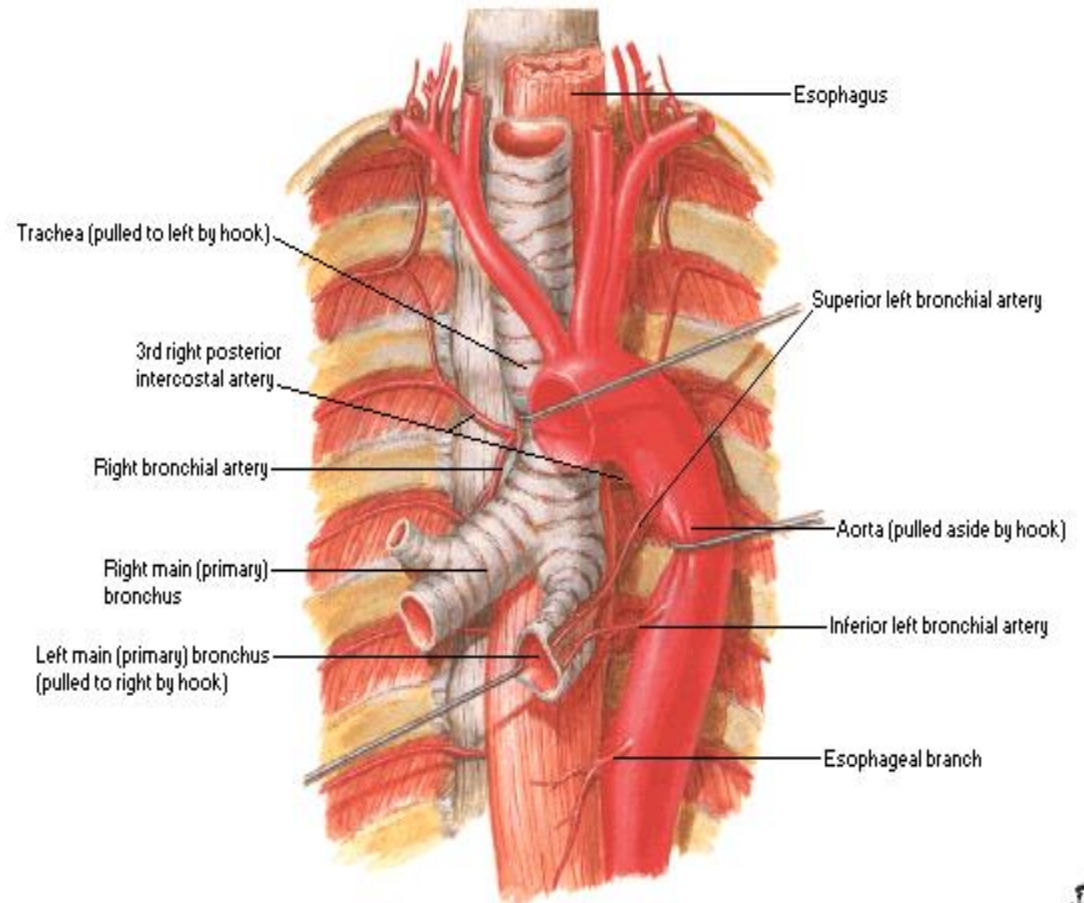


# Blood Supply



# Blood Supply

## Bronchial Arteries

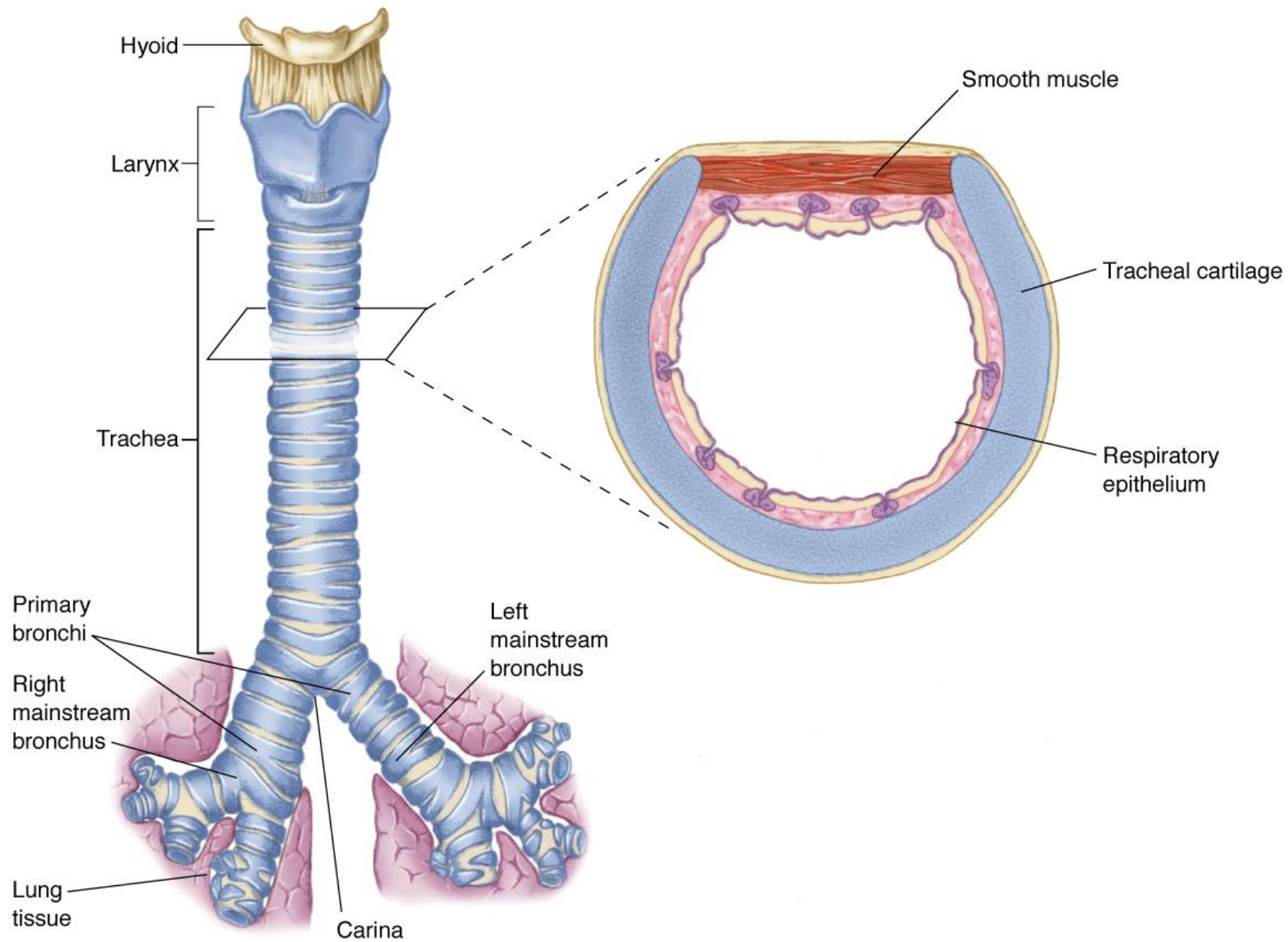


# Airways

- Trachea, primary bronchi, secondary bronchi, tertiary bronchi out to 25 generations
- All comprised of hyaline cartilage
- Trachea
  - Begins where larynx ends (about C6)
  - 10 cm long, half in neck, half in mediastinum
  - 20 U-Shaped rings of hyaline cartilage – keeps lumen intact but not as brittle as bone
  - Lined with epithelium and cilia which work to keep foreign bodies/irritants away from lungs

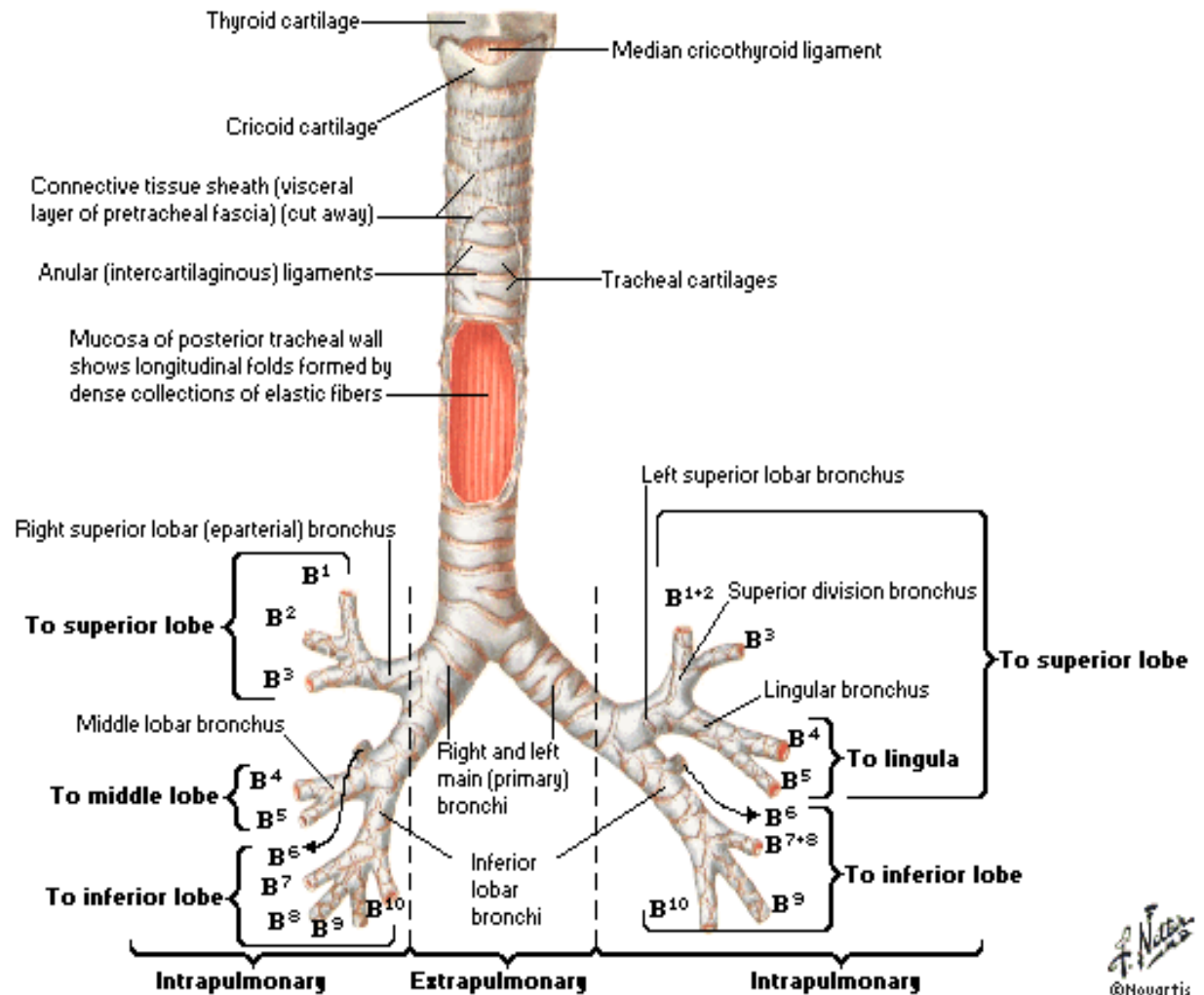
# Bronchioles

- First level of airway surrounded by smooth muscle; therefore can change diameter as in broncho-constriction and broncho-dilation
- Terminal
- Respiratory
- 3-8 orders
- alveoli

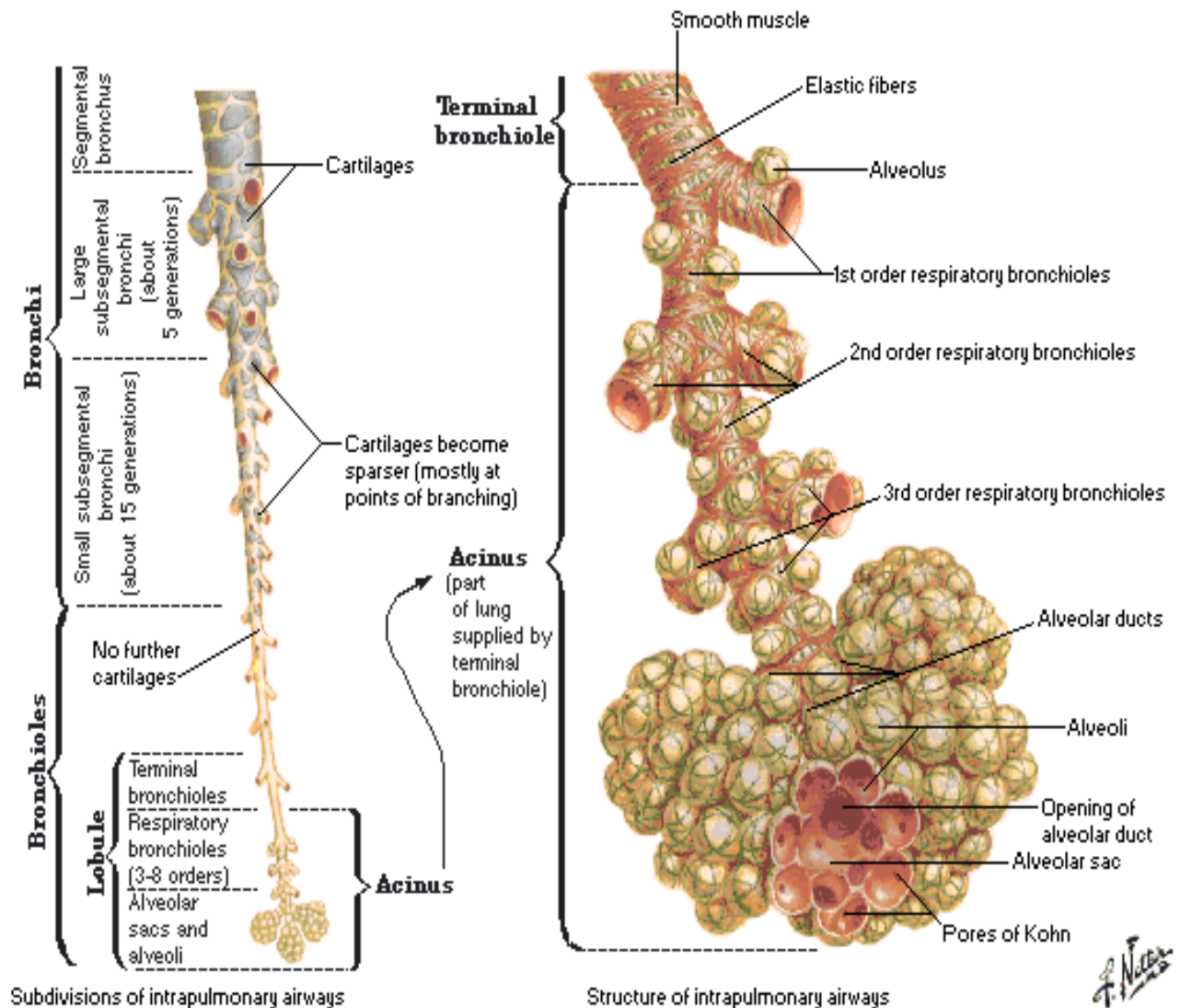


# Trachea and Major Bronchi

## Anterior View



# Intrapulmonary Airways Schema

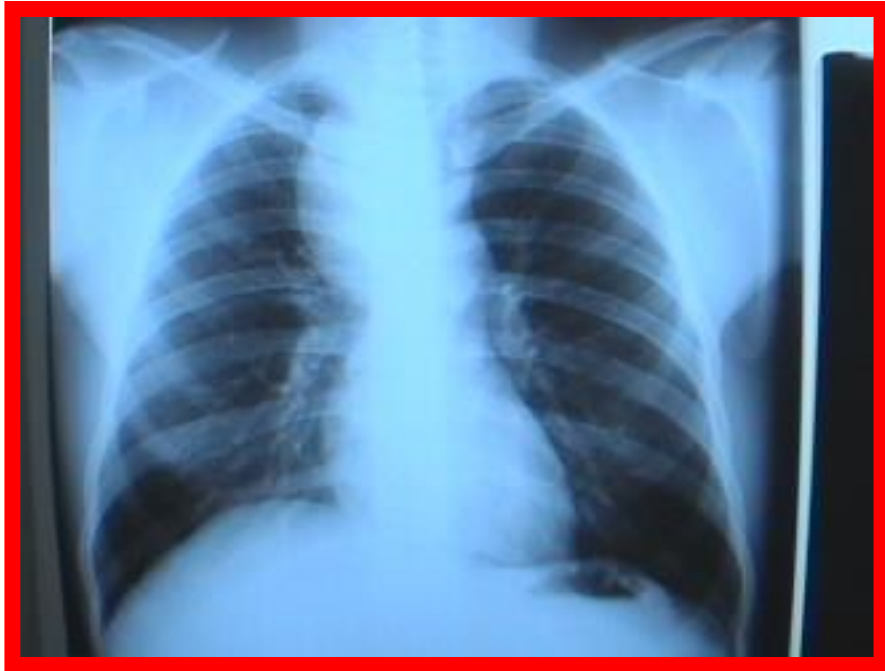

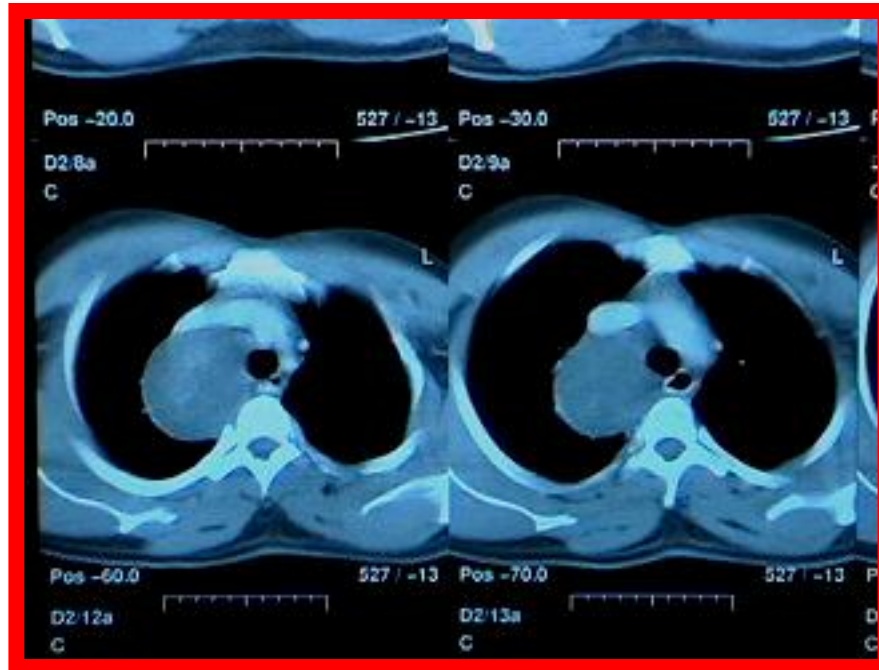
# **DISEASES OF THE LUNG**

## ➤ **Congenital**

- **Agenesis**
- **Hypoplasia**
- **Cystic adenomatoid malformation**
- **Pulmonary sequestration**
- **Lobar emphysema**
- **Bronchogenic cyst**



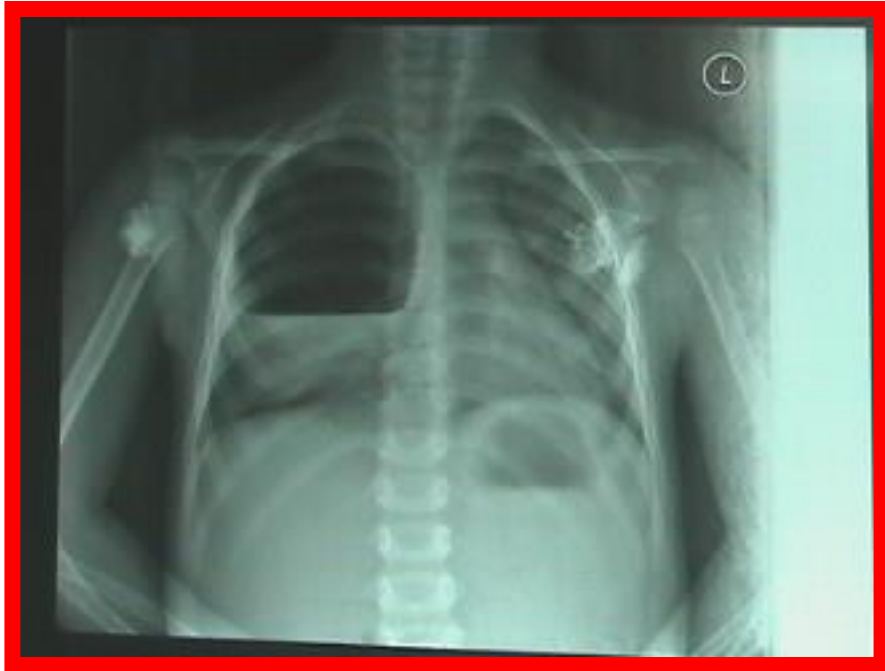



## ➤ Infectious

### A. Lung Abscess

- **Causes**
- **Clinical Features**
  - **Copious production of foul smelling sputum**
- **Investigation**
  - **C X R**





## **Treatment**

- **Antibiotics**
- **Drainage**
  - Internal
  - External
- **Pulmonary resection**
- **Indications**
  1. Failure of medical RX
  2. Giant abscess ( >6cm)
  3. Hemorrhage
  4. Inability to R. /Out carcinoma
  5. Rupture with resulting empyema
- **Type of Resection**
  - Lobectomy

## **B. Bronchiectasis**

### **Definition**

**Bronchial dilatation**

### **Causes**

- **Congenital**
- **Infection**
- **Obstruction**

### **Clinical Features**

- **Cough**
- **Dyspnea**
- **Haemoptysis (50%)**
- **Clubbing**

## Investigation

- **Bronchogram**
- **CT**
- **Bronchoscopy**

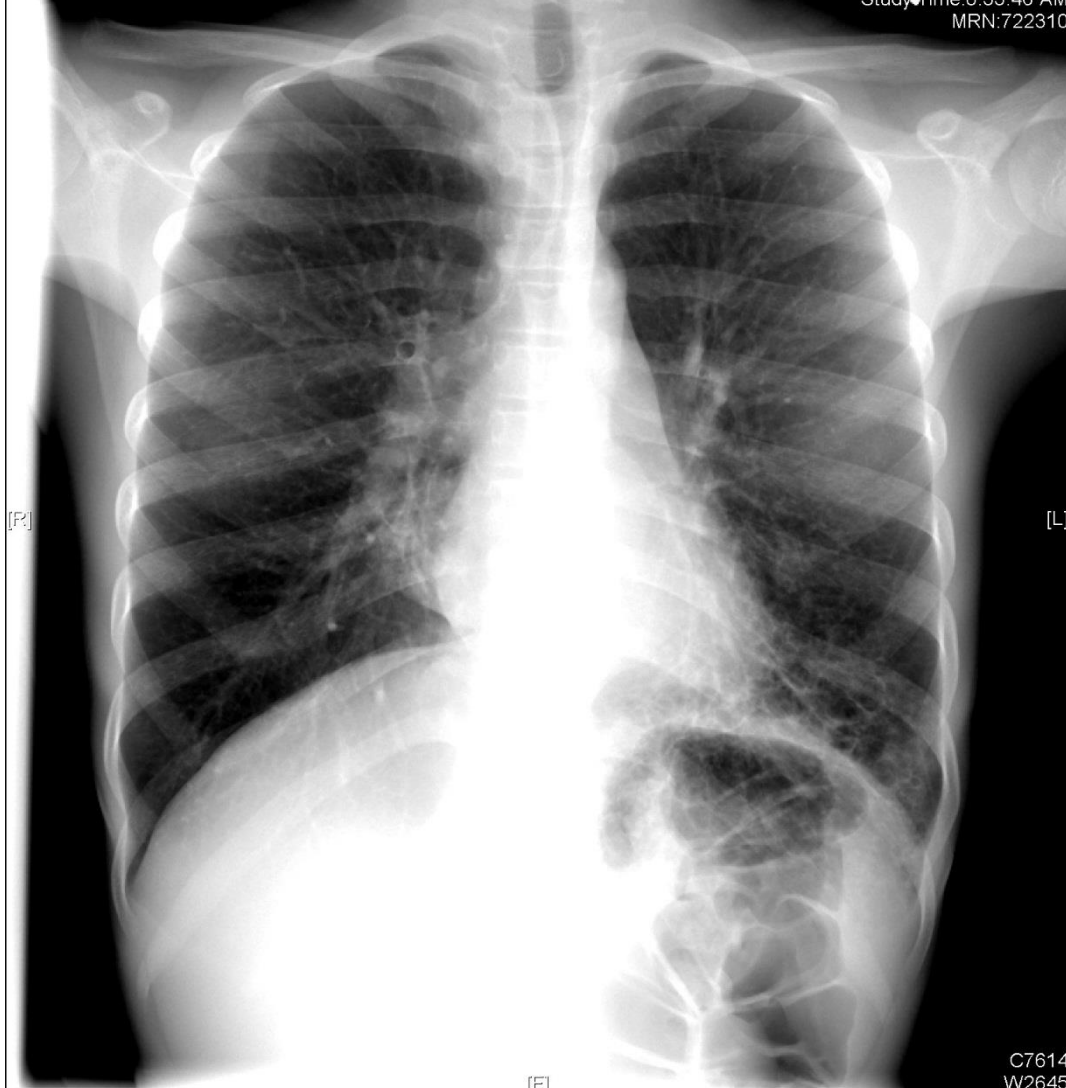
## Treatment

- **Medical**
  - **Resolve most cases**
- **Surgical**
  - **Failure of medical Rx**
  - **Patient with localized disease**
  - **Cystic type**

Series: 10542  
Image: 1

[H]

ALANAZI, ASHWAG, SALEEM, MOHAMMED  
Study Date: 12/3/2003  
Study Time: 8:33:46 AM  
MRN: 722310



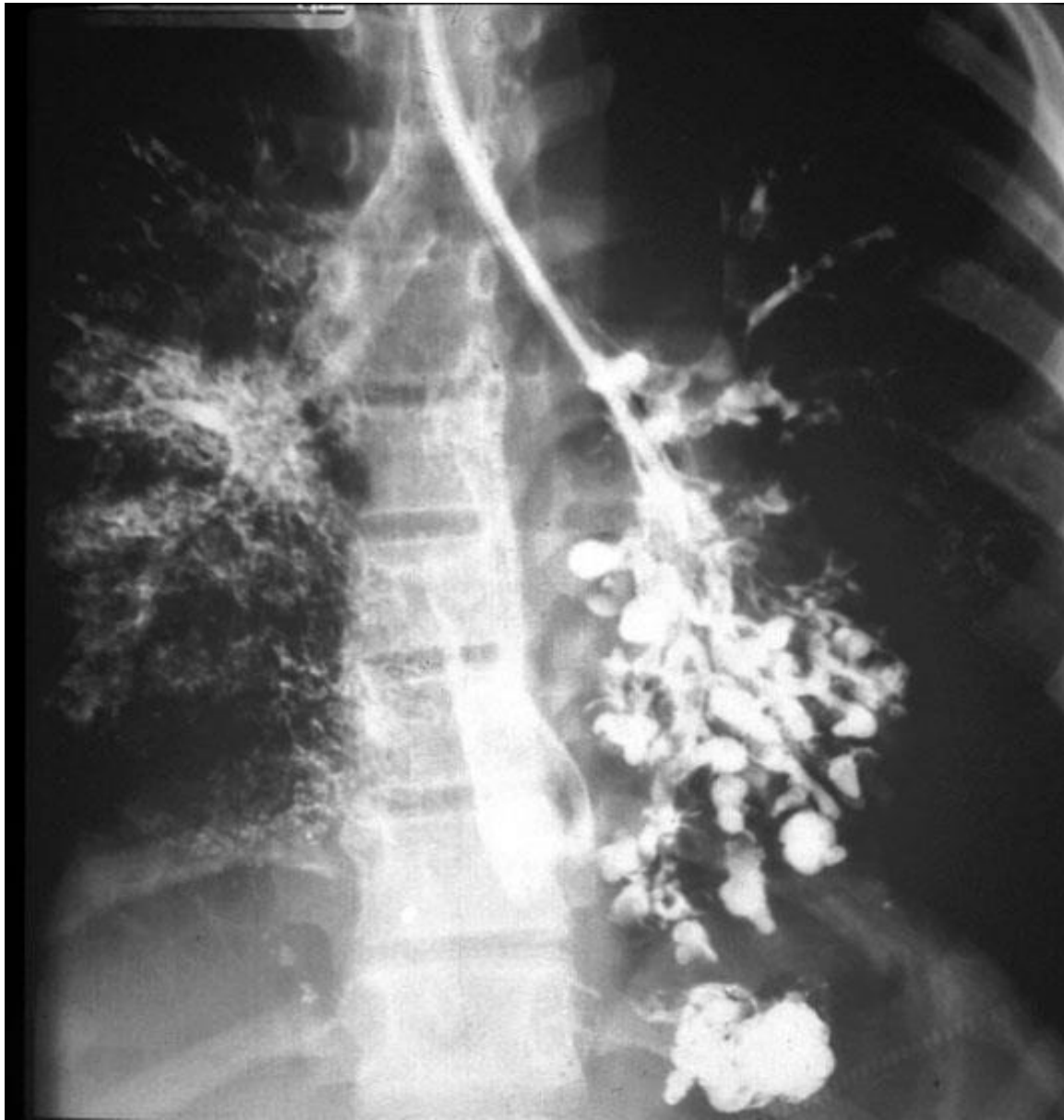[R]

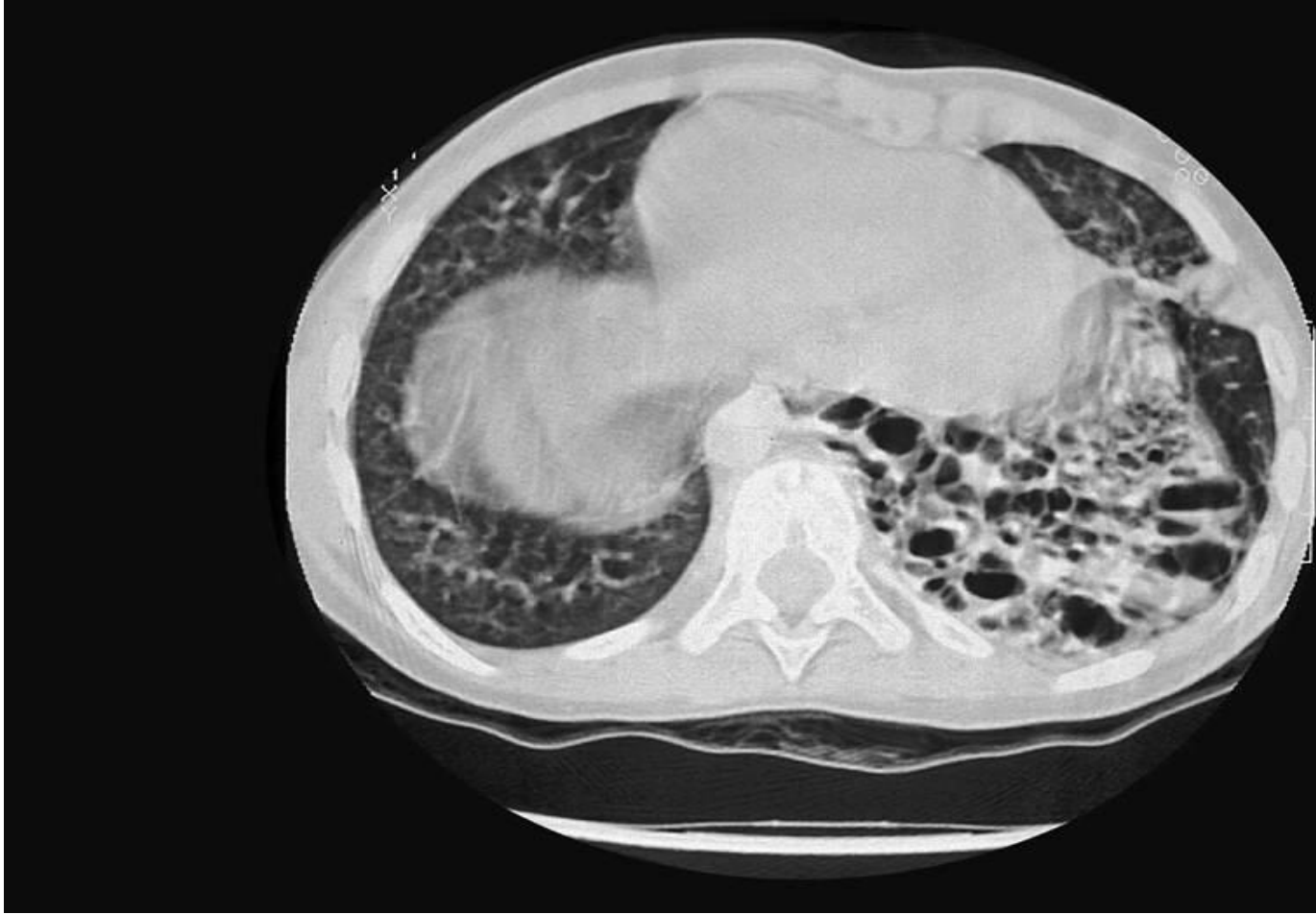[L]

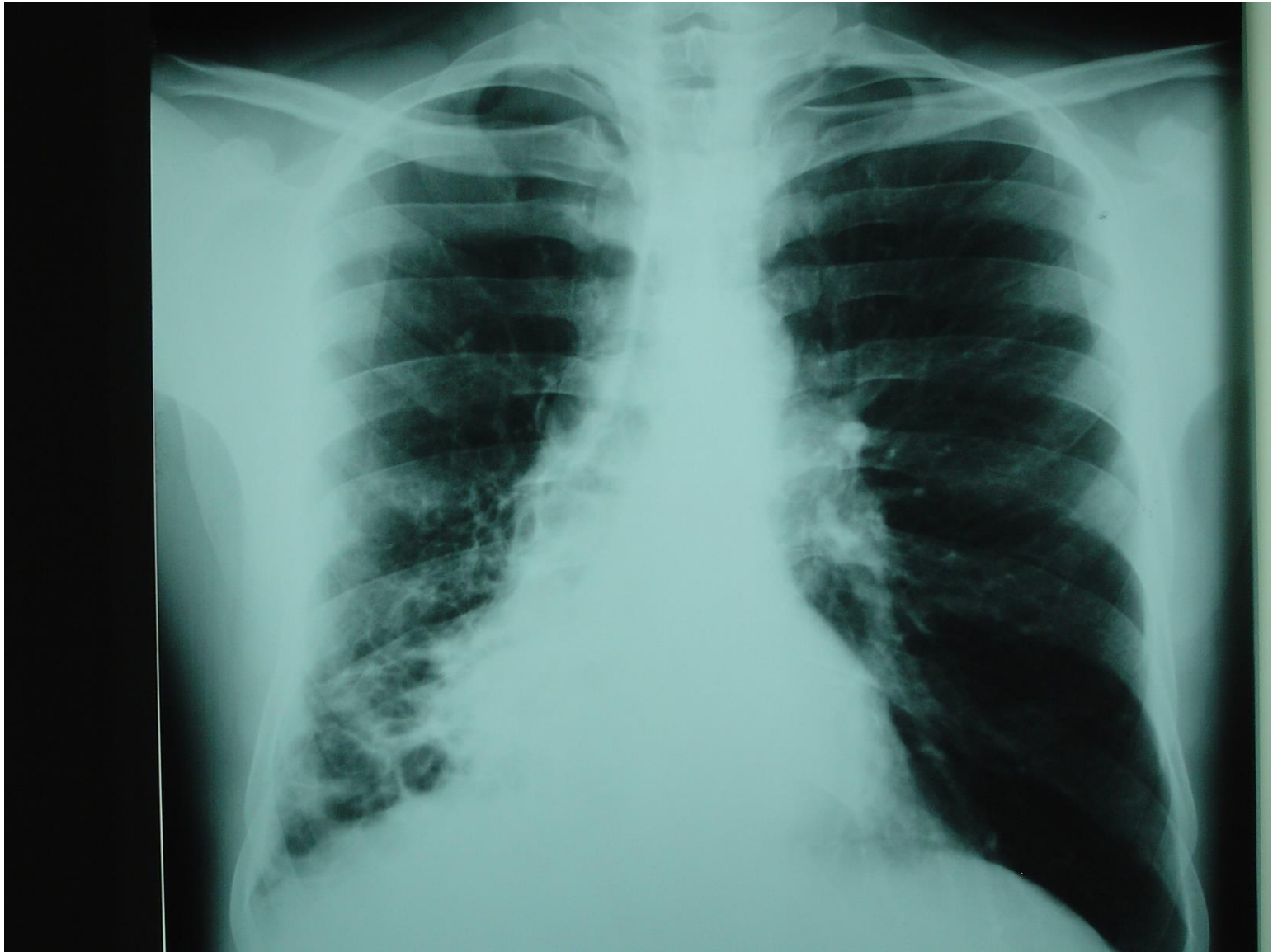[F]

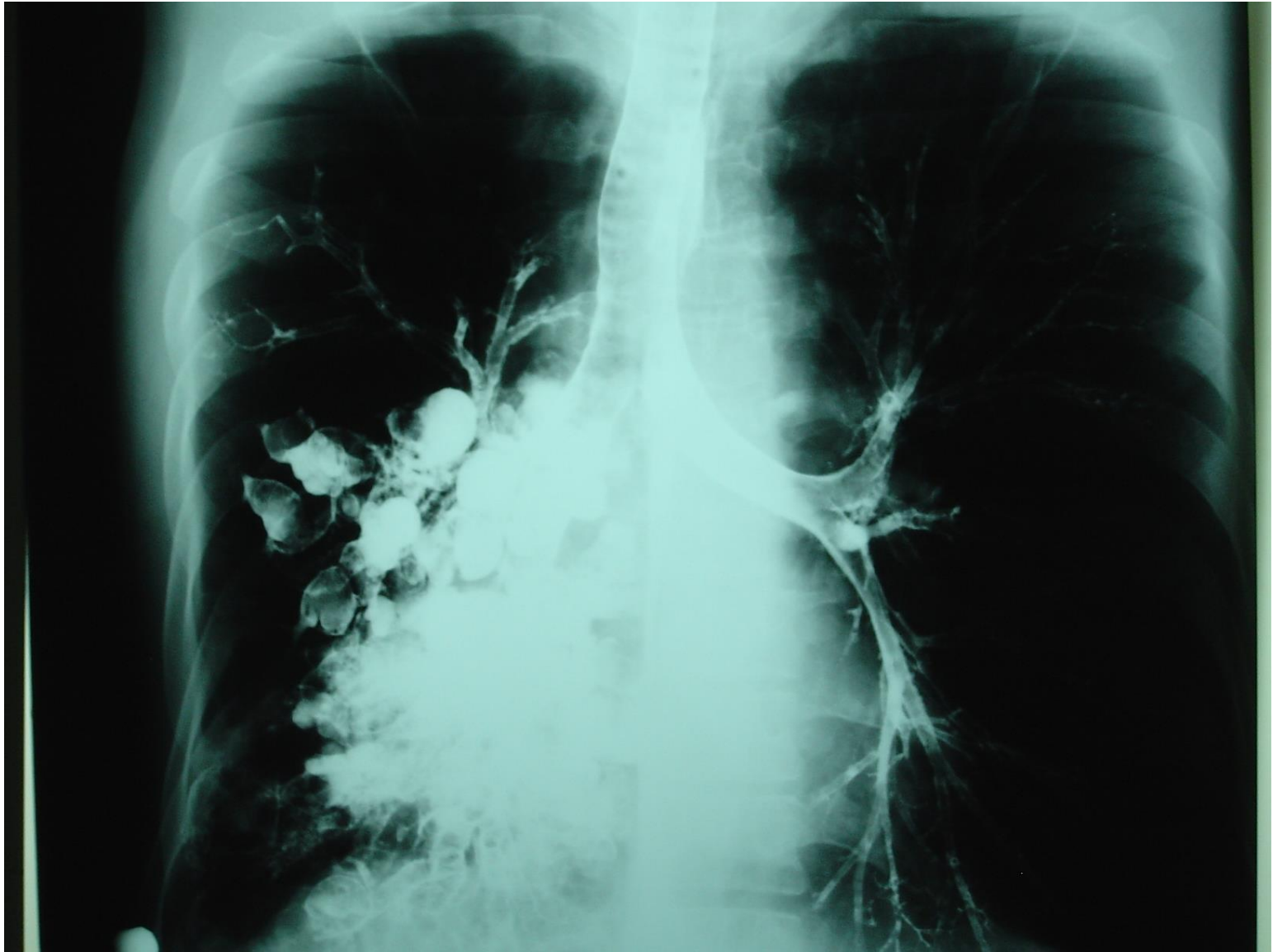C7614  
W2645





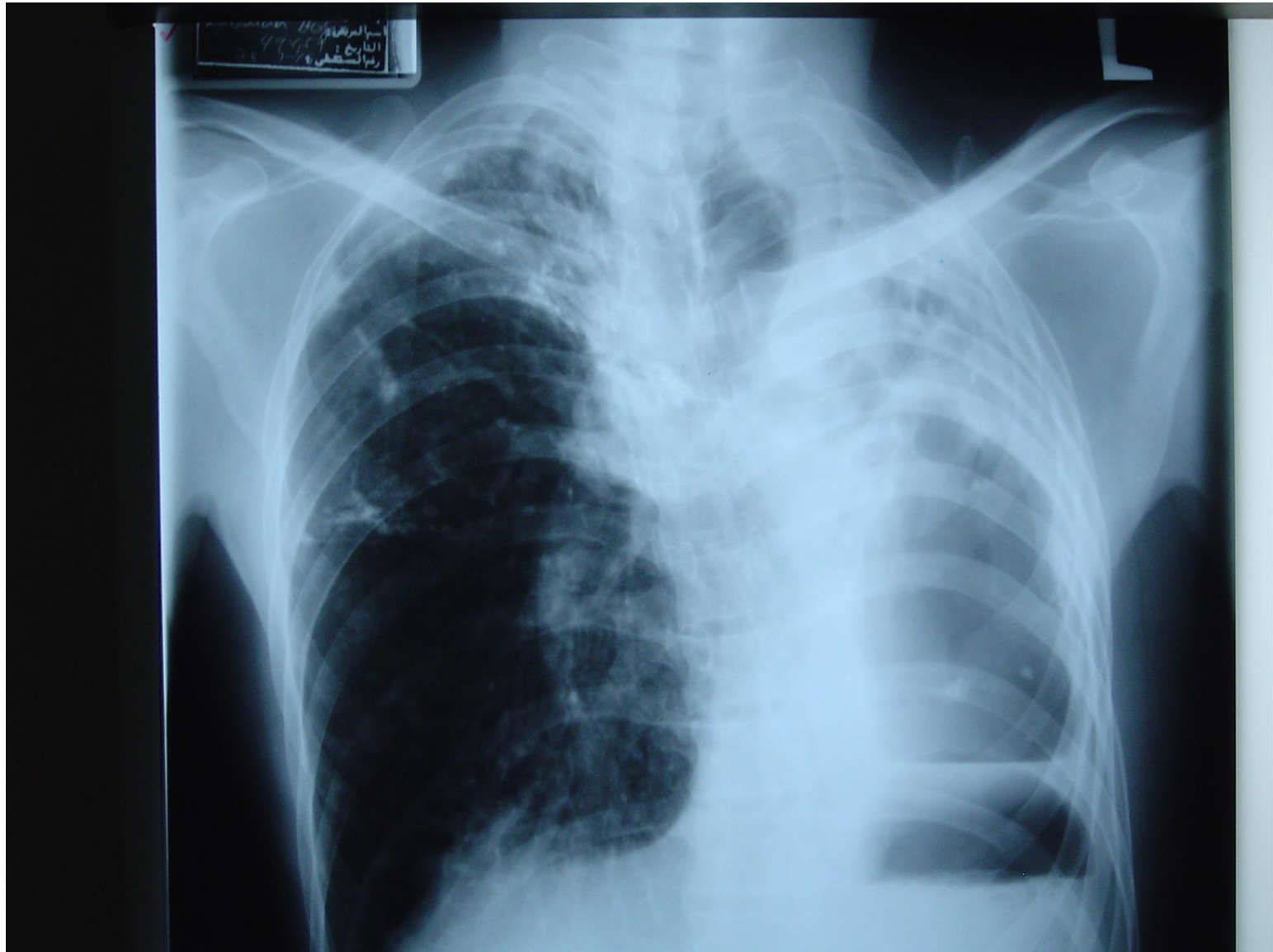






## **C. Tuberculosis**

- \* **30,000 new cases occur annually in U.S.A**
- **Cause**
  - **Pulmonary**
  - **Extra-pulmonary**
- **Investigation**
  - **C X R**

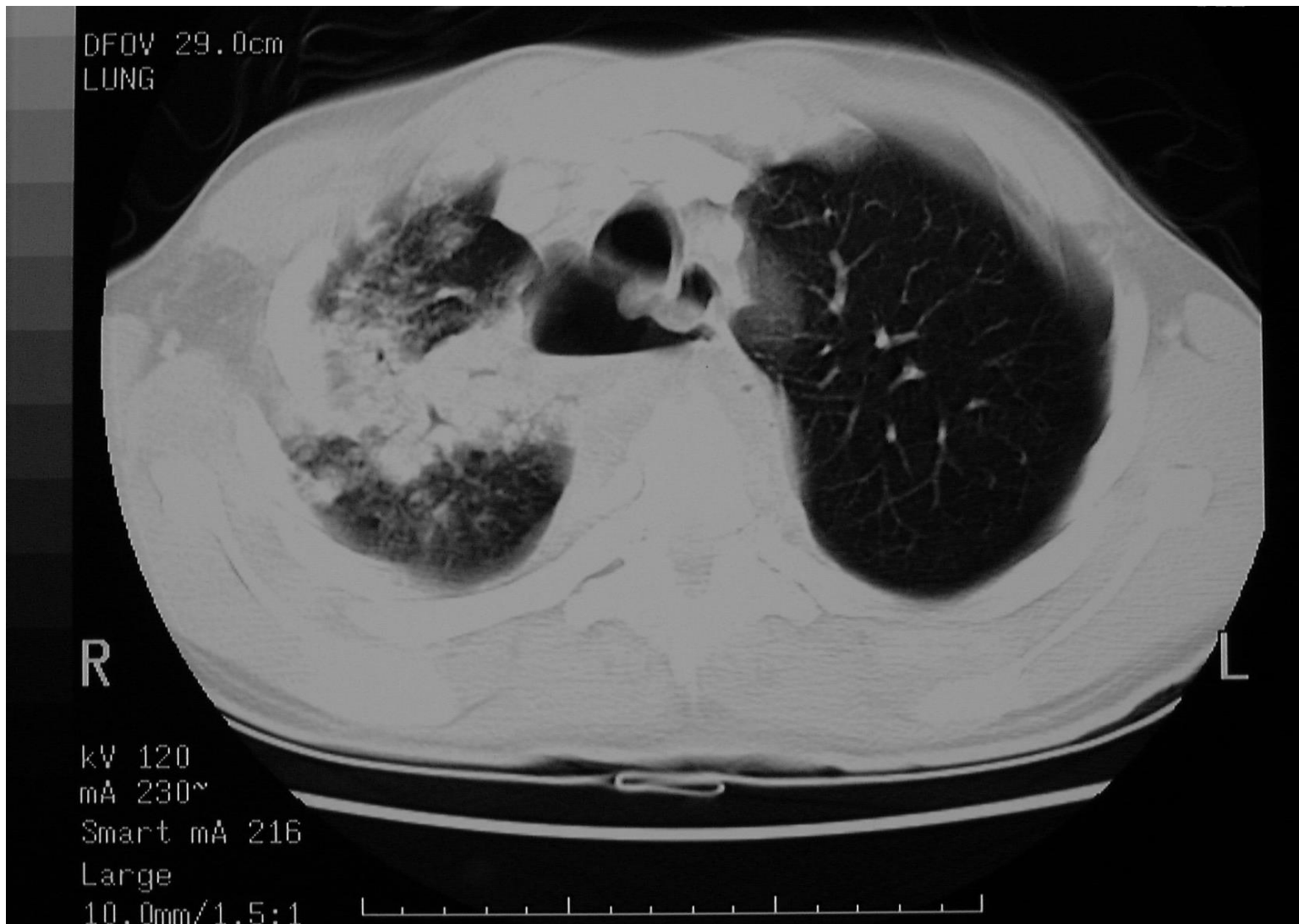

DFOV 29.0cm  
LUNG

R

L

kV 120  
mA 230~  
Smart mA 216  
Large  
10.0mm/1.5:1



- **Treatment**

- **Medical**

- **Surgical**

- ✓ **Failure of medical Rx**

- ✓ **Destroyed lobe or lung**

- ✓ **Pulmonary haemorrhage**

- ✓ **Persistent open cavity with + ve sputum**

- ✓ **Persistent broncho pulmonary fistula**



## **D. Aspergillosis**

- **Cause**
  - **Aspergillus fumigatus, A. niger**
- **Mode of Transmission**
- **Forms**
  - **Allergic**
  - **Saprophytic**
  - **Invasive**
- **Saprophytic form**
- **C-F**
  - **Aspergilloma**
  - **Chronic productive cough**
  - **Haemoptysis (patient with preexisting Disease).**

- **Investigations**

- Skin test
- Sputum
- Biopsy (Invasive)
- C X R

- **Treatment**

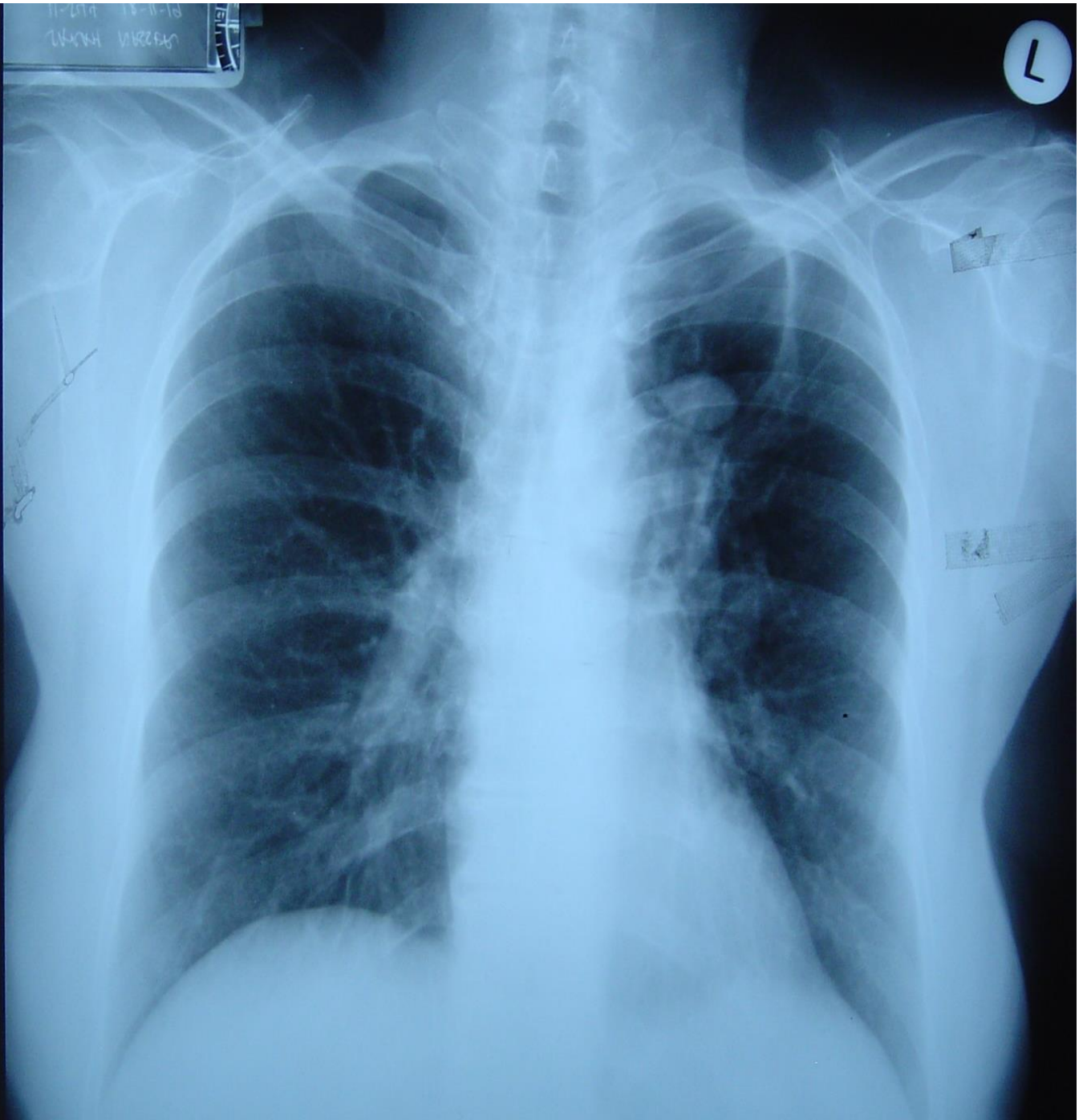
- Medical
- Surgical

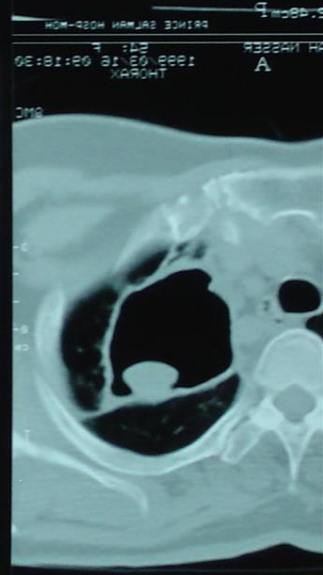
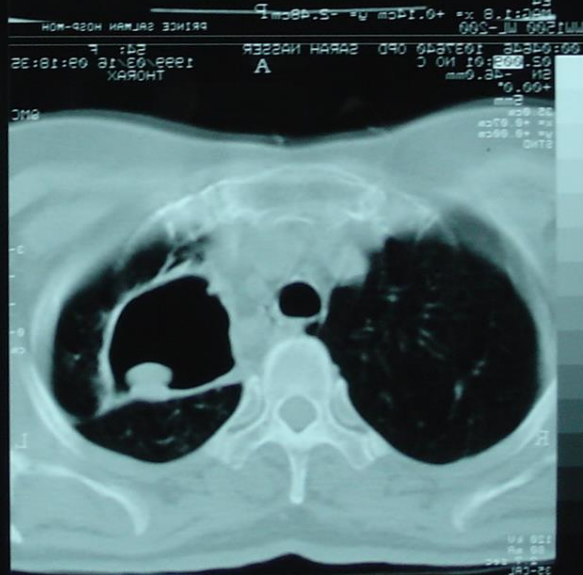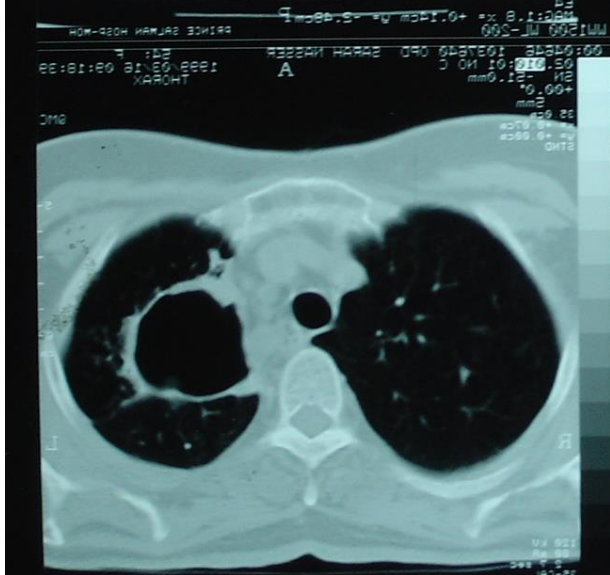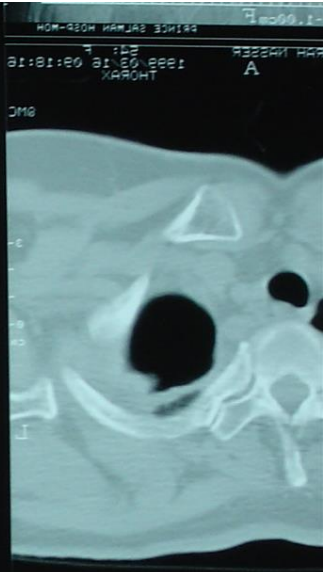
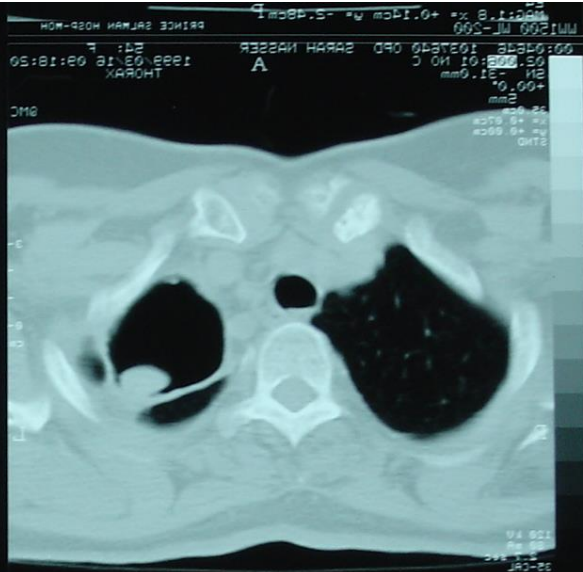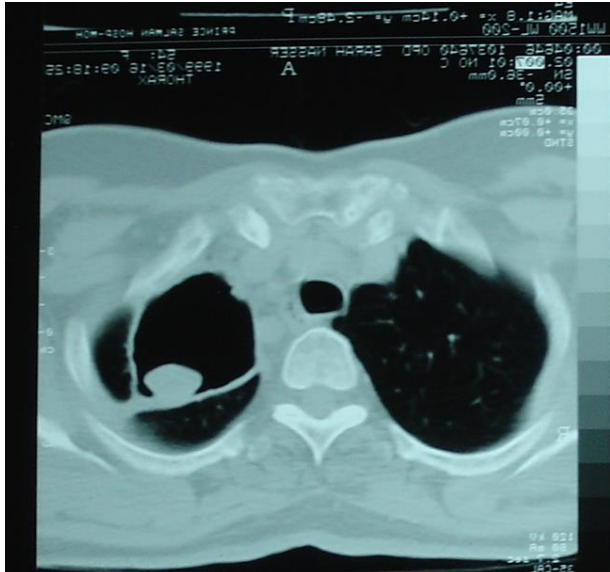- **Indications**

- A significant aspergilloma
- Haemoptysis

- **Type of resection**

- Segmentectomy
- Lobectomy
- Pneumonectomy





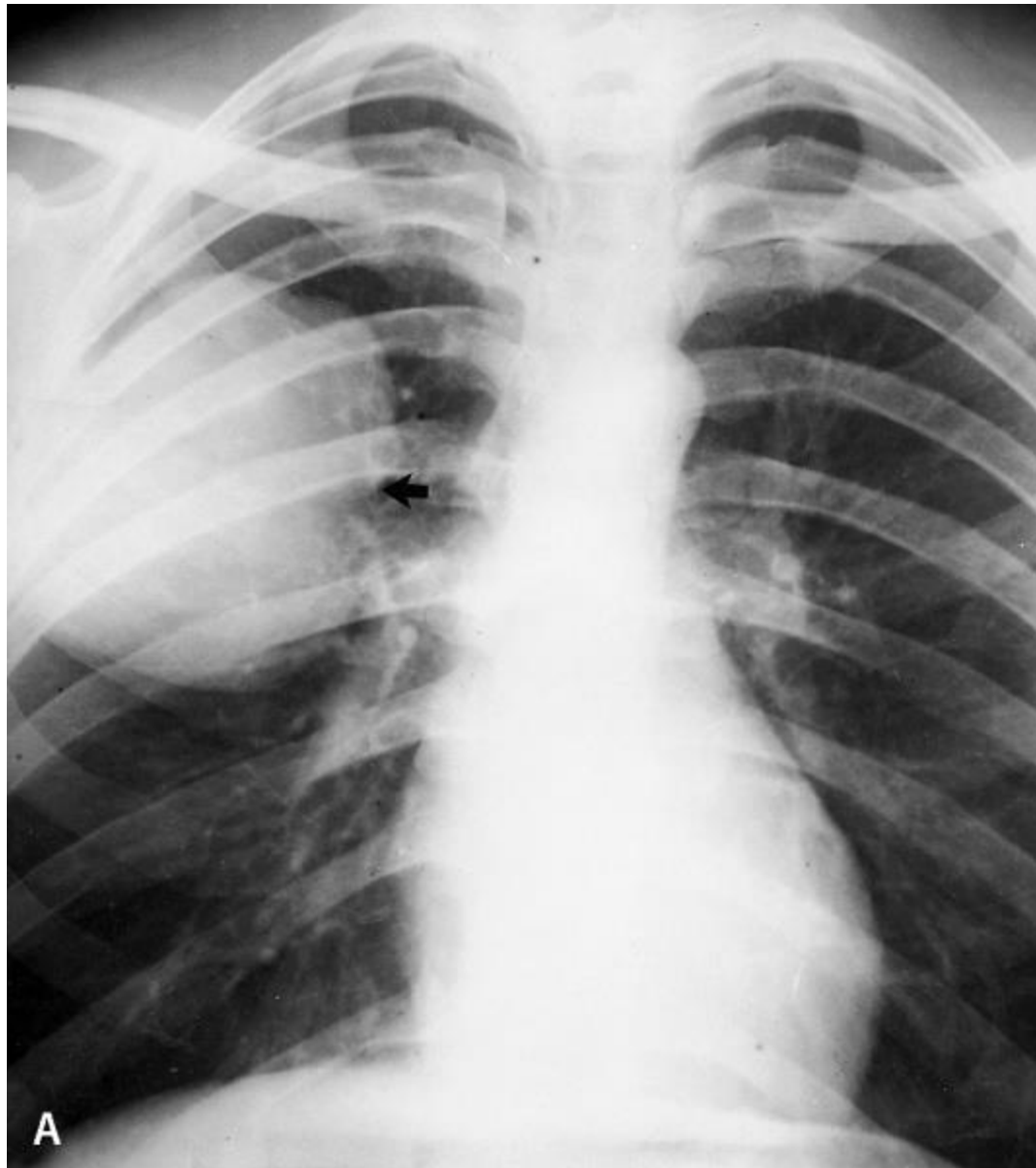## **E. Hydatid cyst**

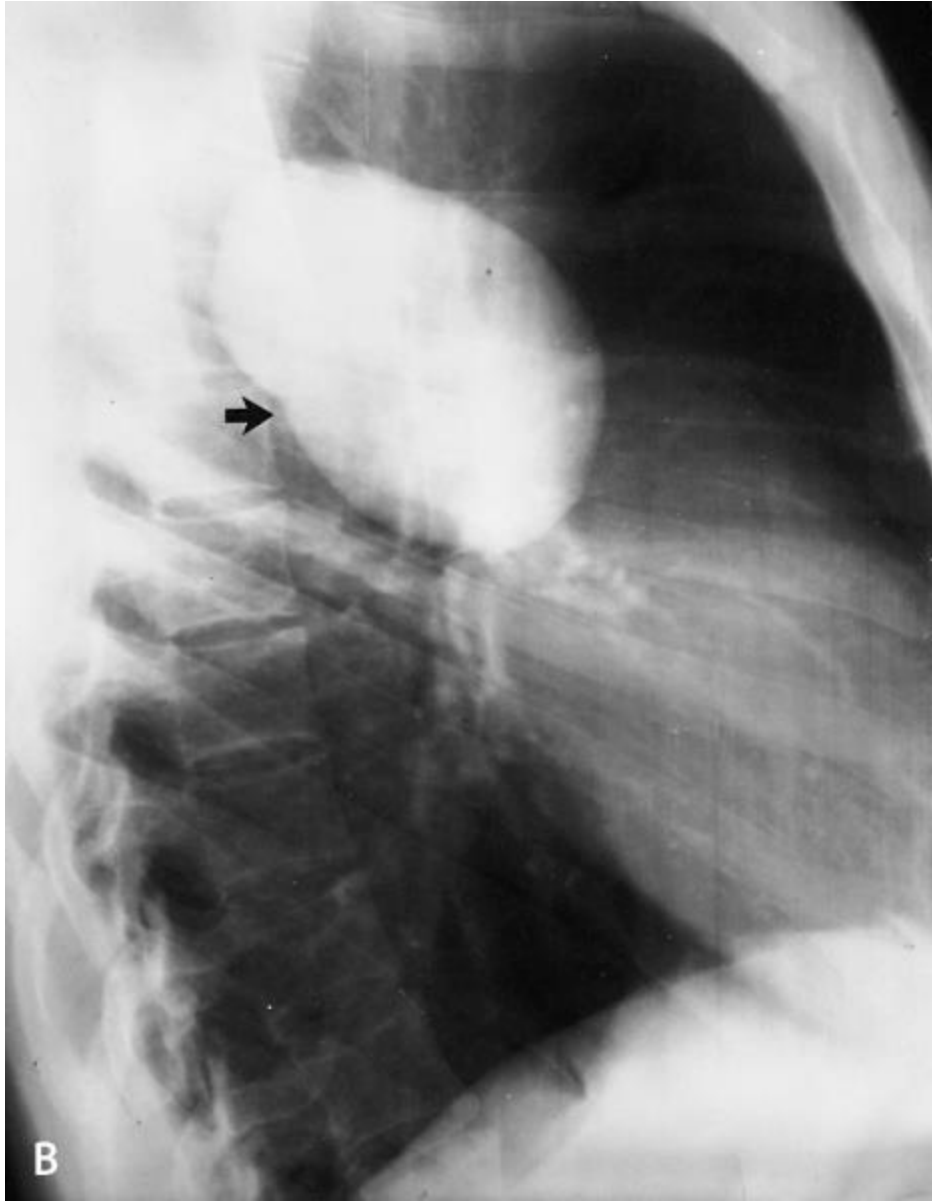### **Cause**

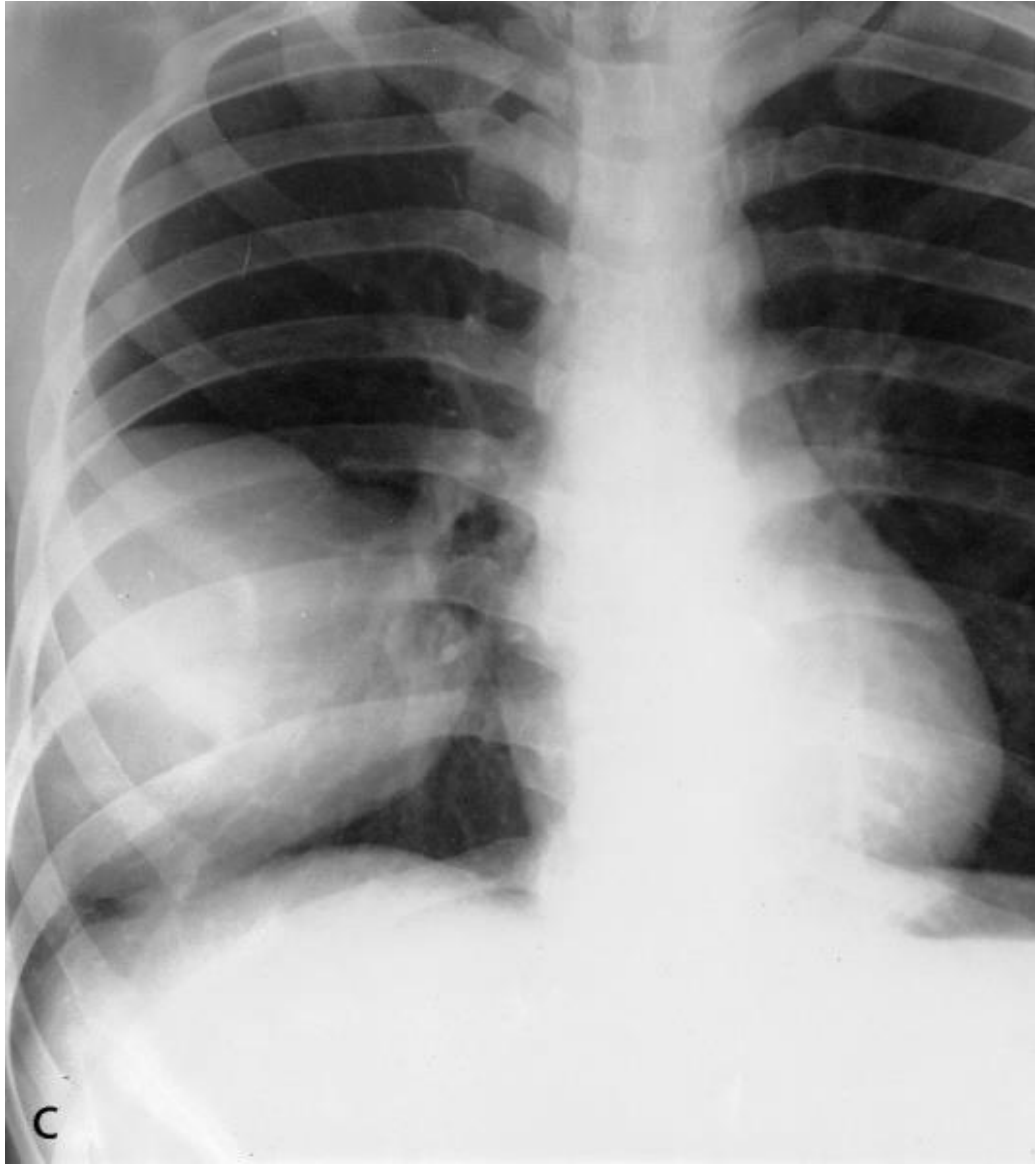
- **Echinococcus granulosus**

### **Diagnosis**

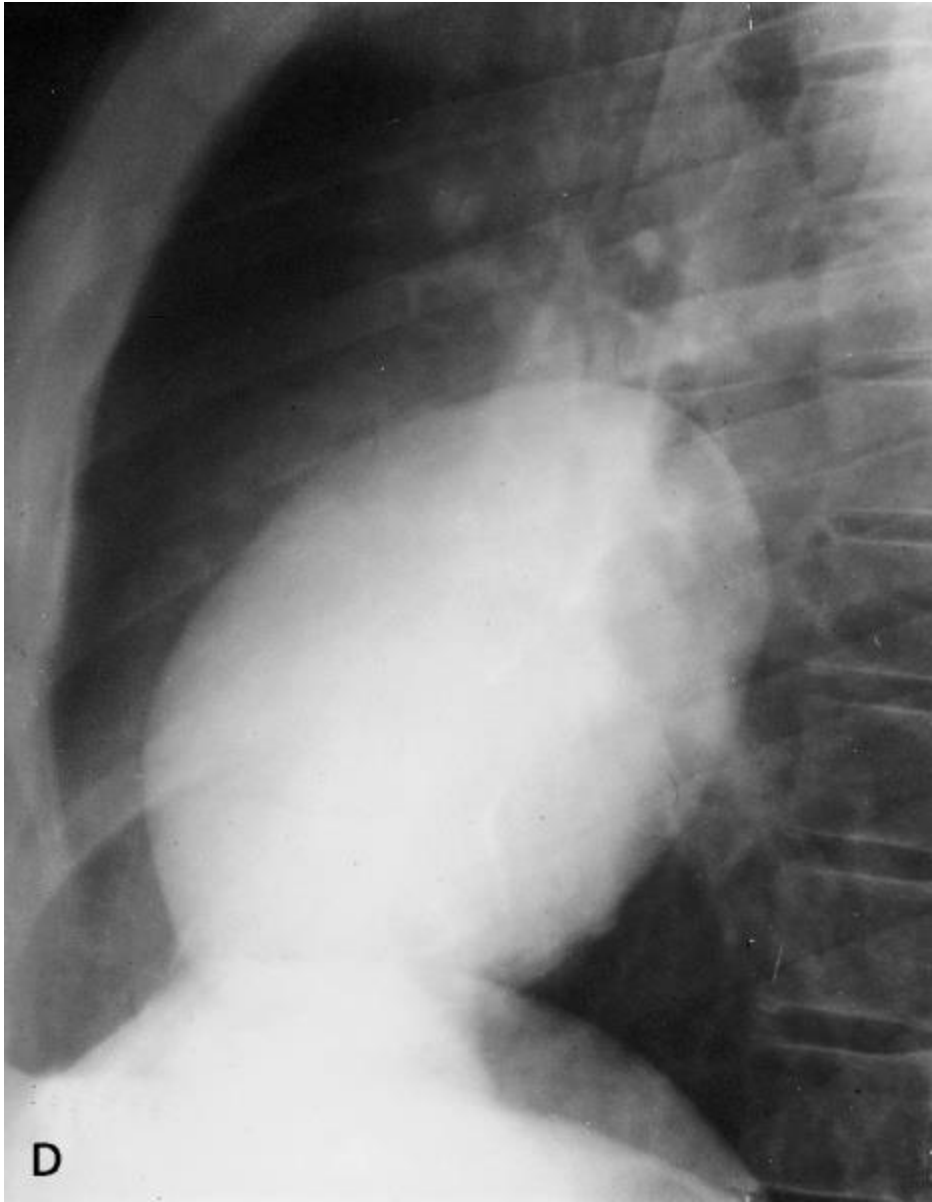### **Treatment**



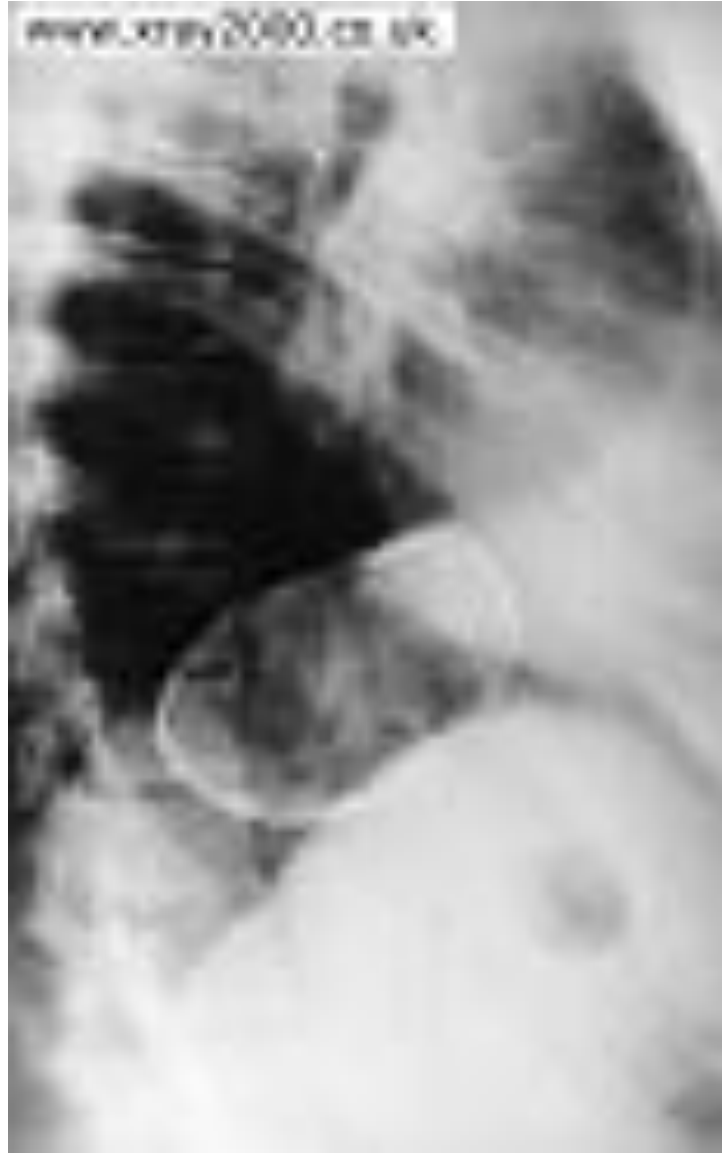

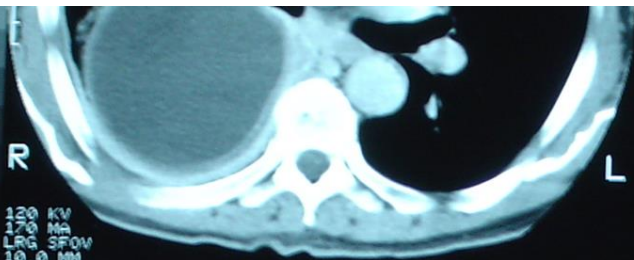






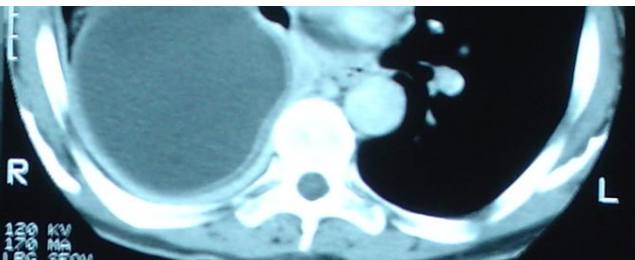
[www.xrfy2000.com.uk](http://www.xrfy2000.com.uk)





120 KV  
170 MA  
LRG SFOV  
10.0 MM  
0.0 TILT  
2.0 SEC 15:24:41

L= +35 M= 500

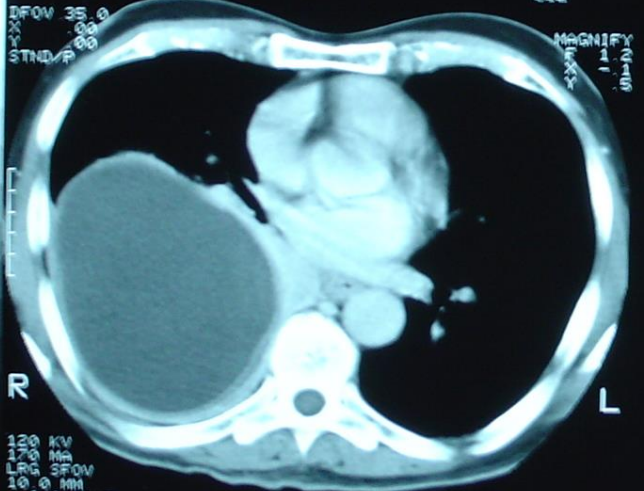

120 KV  
170 MA  
LRG SFOV  
10.0 MM  
0.0 TILT  
2.0 SEC 15:24:19

L= +35 M= 500

EXAM 17534  
PRS 1  
KING KHALID UNIV. HOSP.  
NASER MOUSARANI  
40-42-50 MB1  
02 JUN 98  
S12

DFOV 35.0  
X 00  
Y 00  
STND/P 00  
MAGNIFY 1.1  
0.0

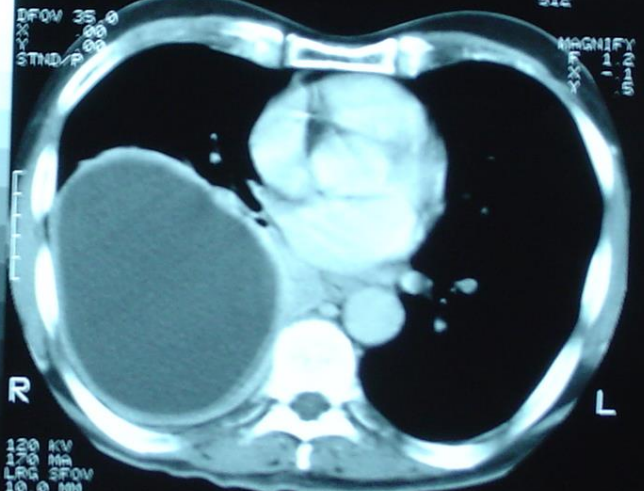


120 KV  
170 MA  
LRG SFOV  
10.0 MM  
0.0 TILT  
2.0 SEC 15:23:32

L= +35 M= 500

EXAM 17534  
PRS 1  
KING KHALID UNIV. HOSP.  
NASER MOUSARANI  
40-42-50 MB1  
02 JUN 98  
S12

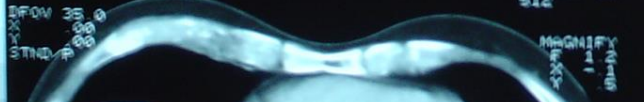DFOV 35.0  
X 00  
Y 00  
STND/P 00  
MAGNIFY 1.1  
0.0



120 KV  
170 MA  
LRG SFOV  
10.0 MM  
0.0 TILT  
2.0 SEC 15:23:08

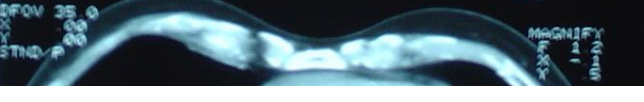
L= +35 M= 500

EXAM 17534  
PRS 1  
KING KHALID UNIV. HOSP.  
NASER MOUSARANI  
40-42-50 MB1  
02 JUN 98  
S12

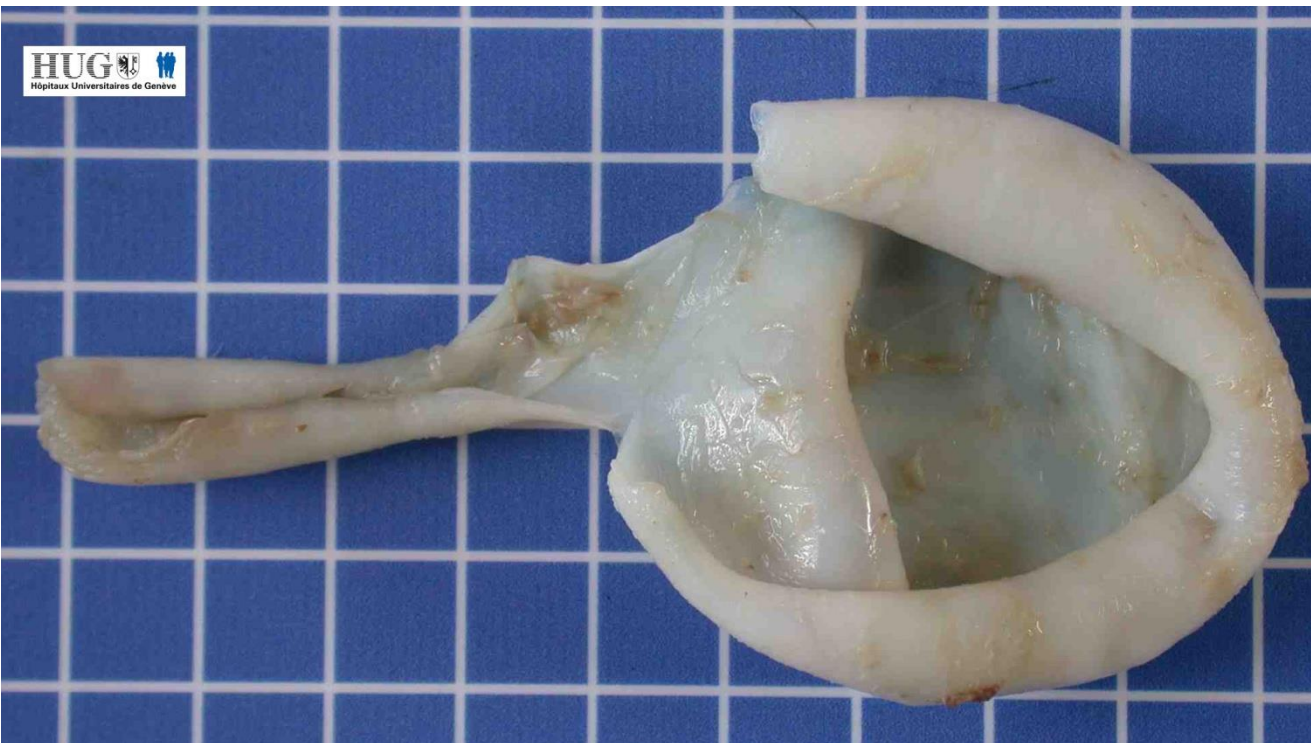

DFOV 35.0  
X 00  
Y 00  
STND/P 00  
MAGNIFY 1.1  
0.0

EXAM 17534  
PRS 1  
KING KHALID UNIV. HOSP.  
NASER MOUSARANI  
40-42-50 MB1  
02 JUN 98  
S12



DFOV 35.0  
X 00  
Y 00  
STND/P 00  
MAGNIFY 1.1  
0.0



# Tumor

➤ Benign

➤ Malignant

- Primary
- Secondary

# **A. Primary lung carcinoma**

## **Incidence**

## **Risk Factor**

- **Smoking**
- **Others**

## **Pathology**

- 1. Adenocarcinoma**
  - 2. Squamous cell carcinoma**
  - 3. Large cell carcinoma**
  - 4. Small cell carcinoma**
- **NSCLC vs. SCLC**

## **Clinical Features**

- **Asymptomatic**
- **Symptomatic**
  - **Lung**
  - **Surrounding structures**
  - **Rec. L. nerve**
  - **Oesophagus**
  - **C<sub>8</sub>, T<sub>1</sub> nerve**
  - **Sympathetic**
  - **Pleura**
  - **SVC**

- distal (para-neoplastic syndrome)
  - PTH
  - ADH
  - ACTH
  - Hypertrophic pulmonary osteoarthropathy

## Investigations

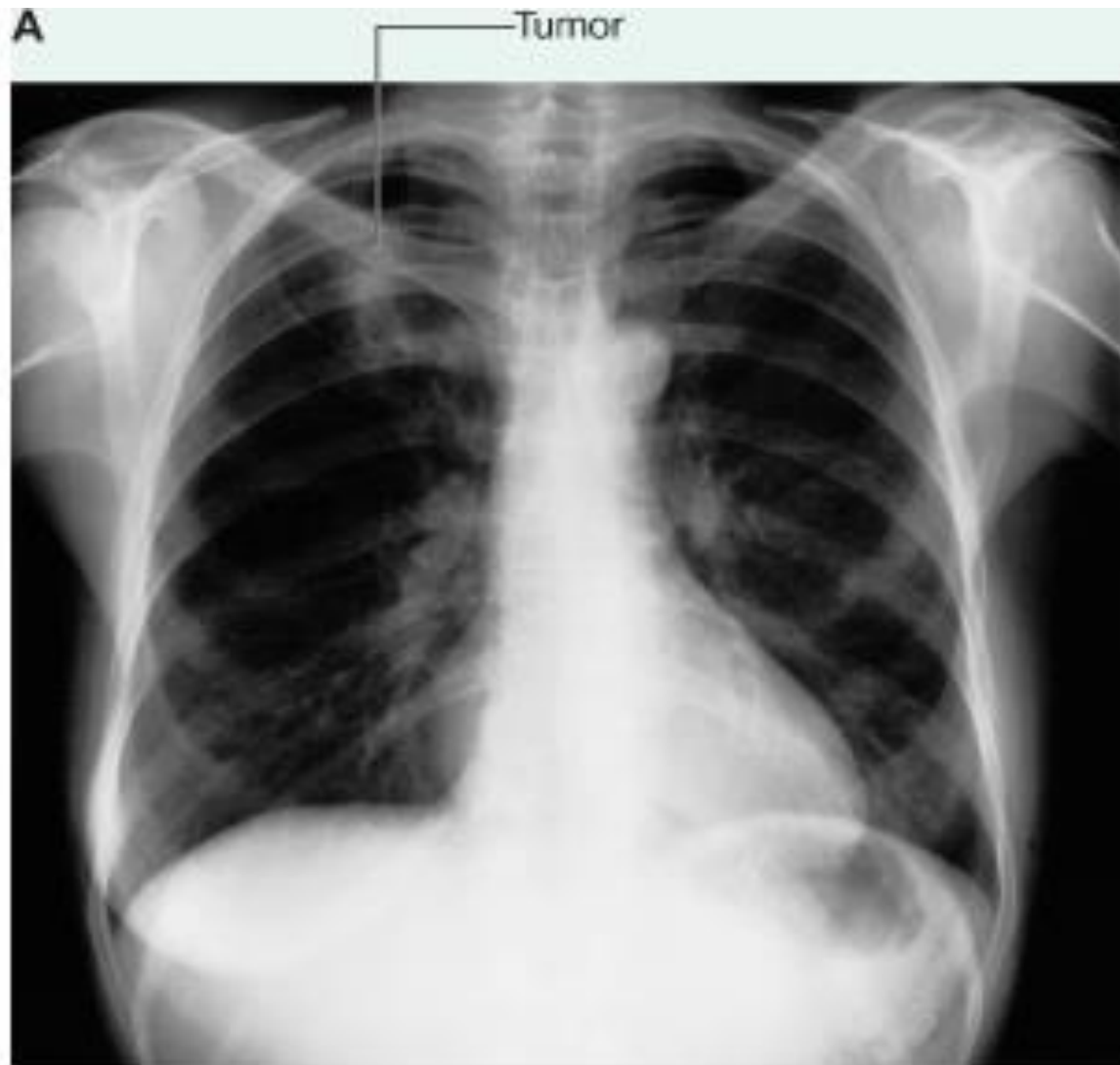- C X R
- Bronchoscopy
- Trans-thoracic needle aspiration
- CT Scan
- MRI

## Staging

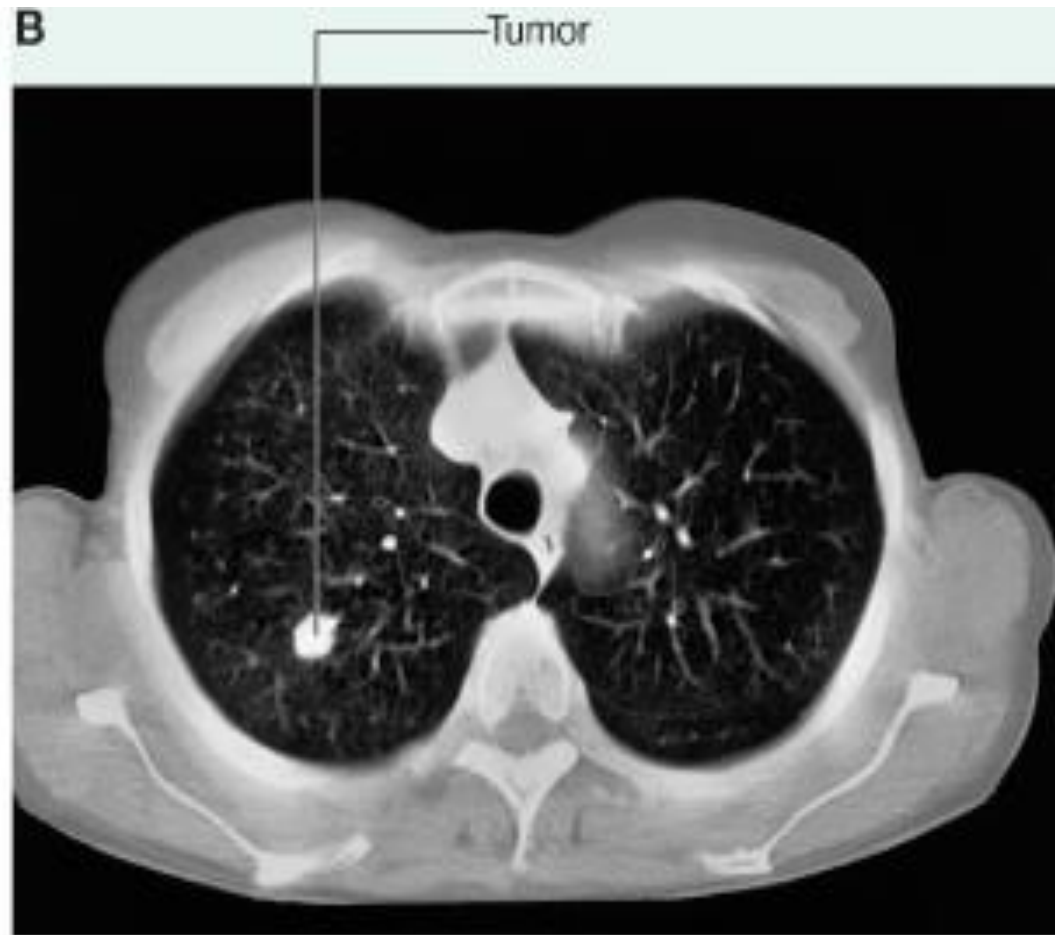
(see table)

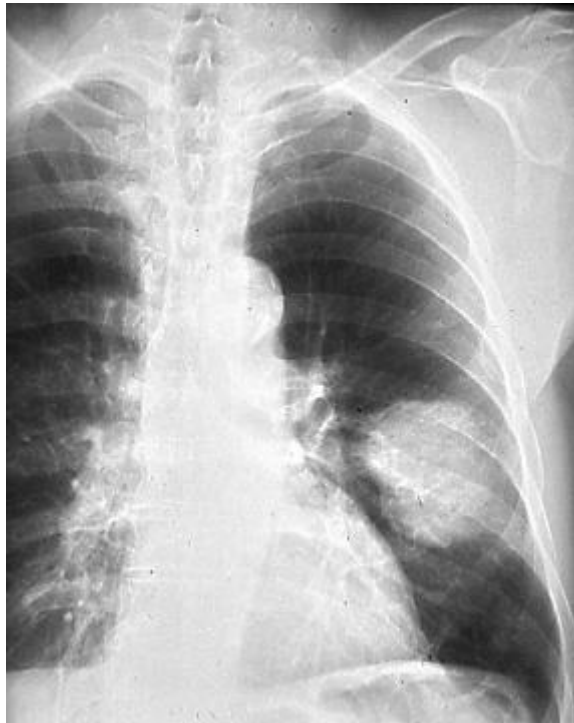

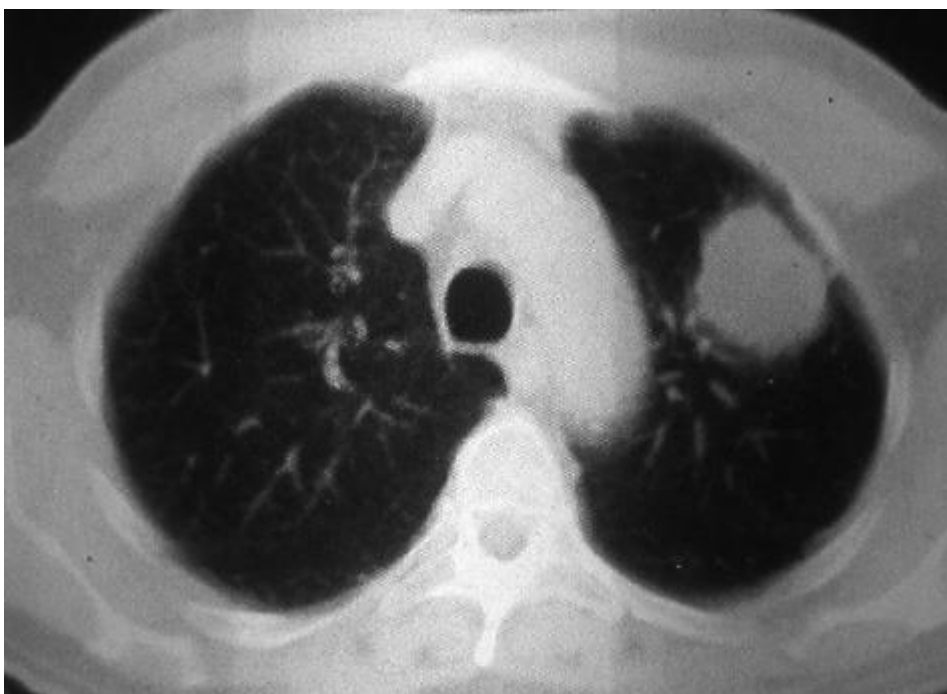
# Tumor



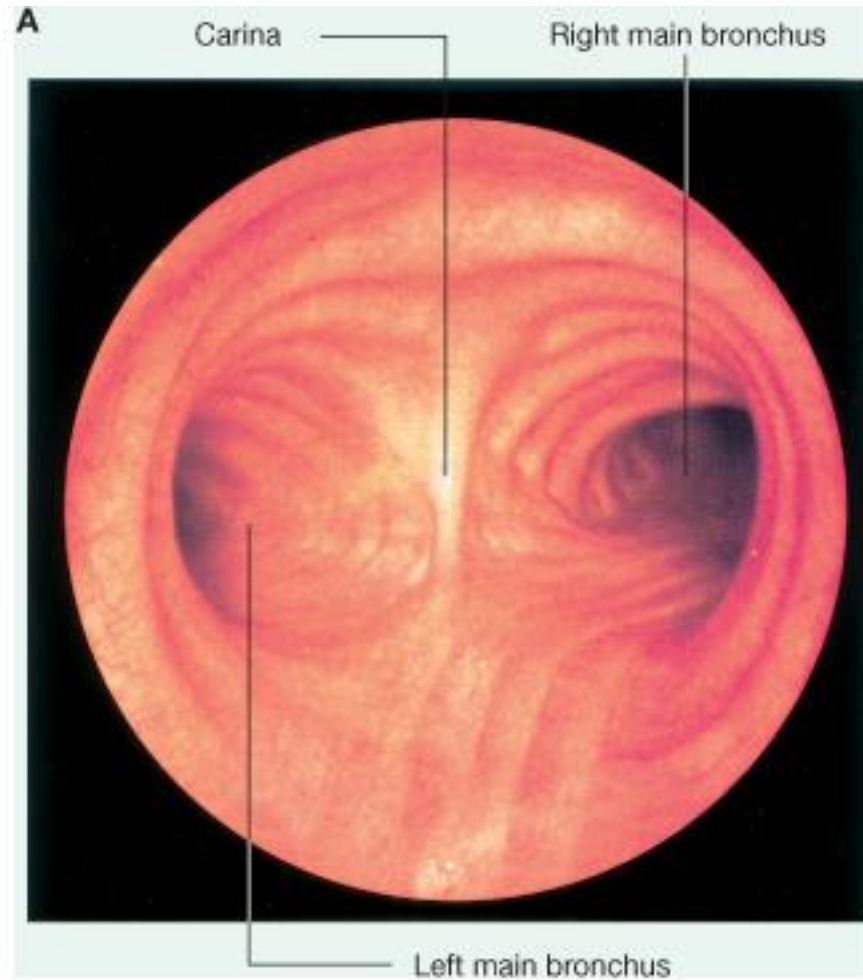
# Tumor



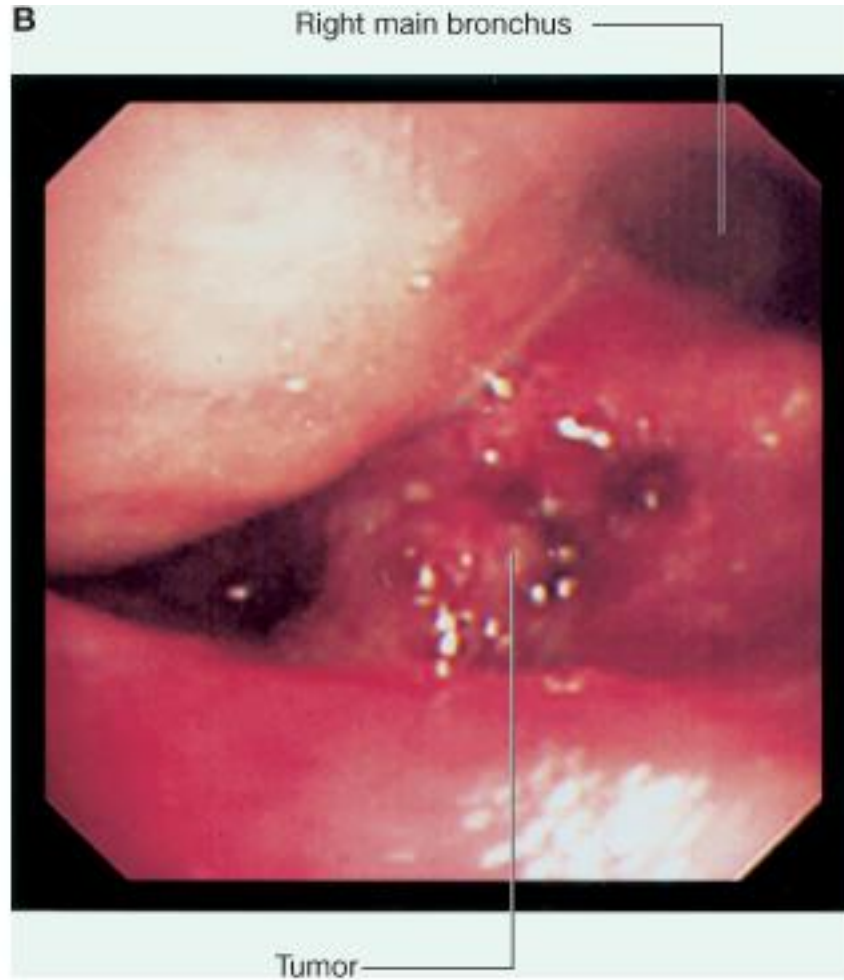

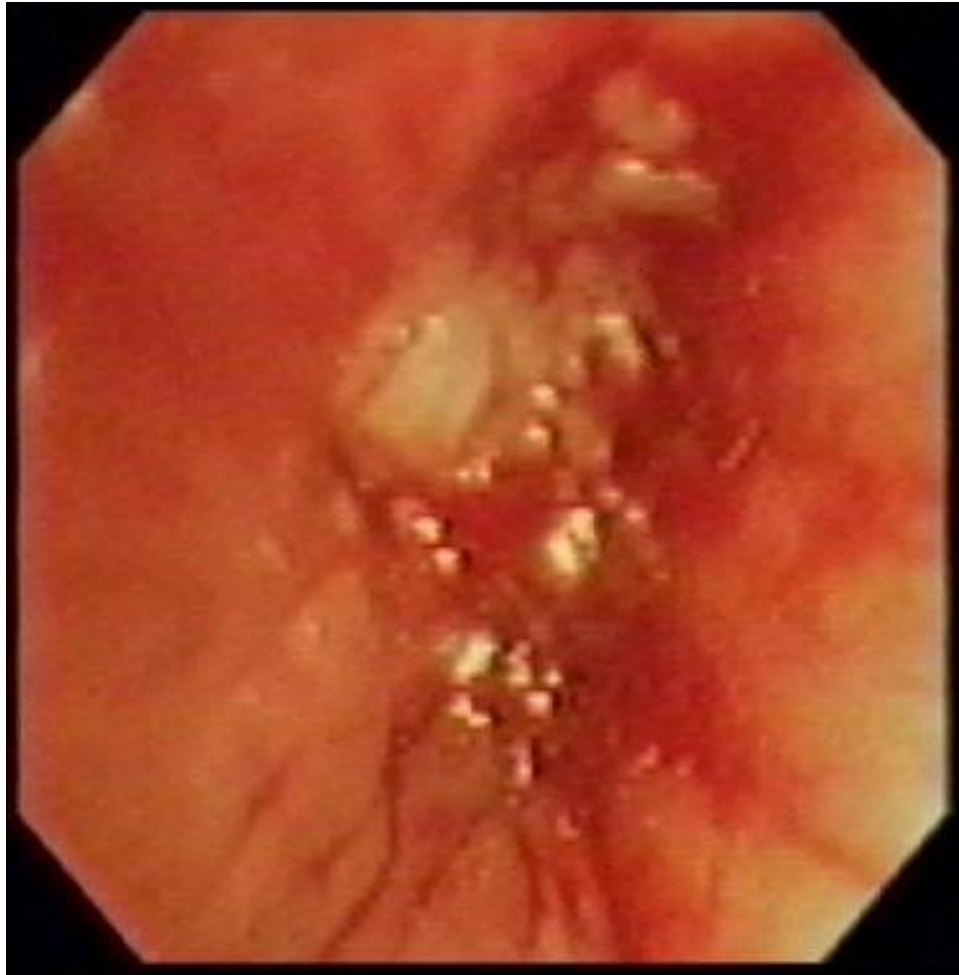


# Bronchoscope



# Tumor





lung-cancer-upper-lobe

# **Management**

## **Depends on:**

- **Stage**
- **Cell Type**
- **Patient Physical fitness**

## **NSCLC**

- **Surgical**
- **Radiotherapy**
- **Chemotherapy**

## **SCLC**

- **Chemotherapy**
- **Radiotherapy**

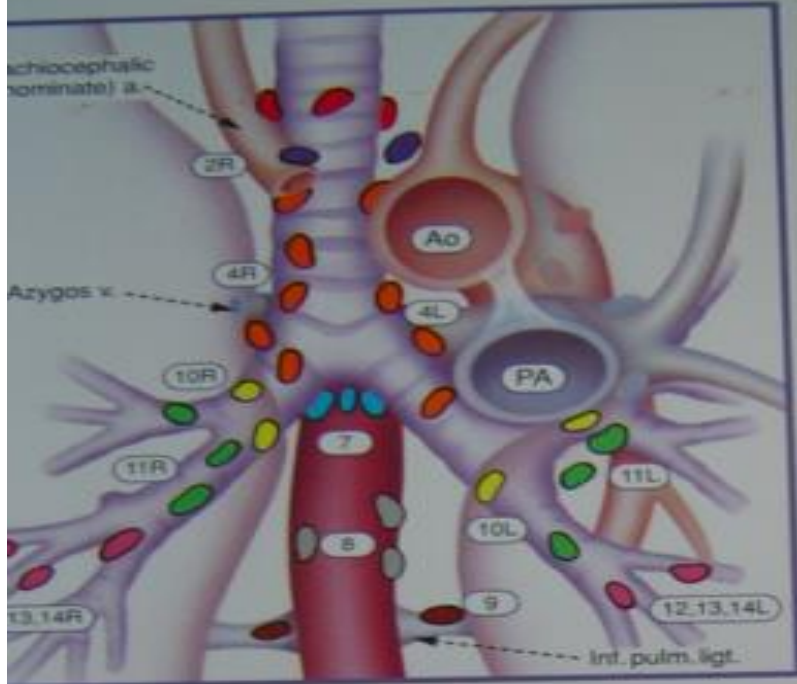


## NEW INTERNATIONAL REVISED STAGE GROUPING

---

|            |                  |
|------------|------------------|
| Stage 0    | TIS              |
| Stage IA   | T1, NO, MO       |
| Stage IB   | T2, NO, MO       |
| Stage IIA  | T1, N1, MO       |
| Stage IIB  | T2, N1, MO       |
|            | T3, NO, MO       |
| Stage IIIA | T1-3, N2, MO     |
|            | T3, N1, MO       |
| Stage IIIB | T4, Any N, MO    |
|            | Any T, N3, MO    |
| Stage IV   | Any T, Any N, M1 |

---



### Superior Mediastinal Nodes

- 1 Highest Mediastinal
- 2 Upper Paratracheal
- 3 Pre-vascular and Retrotracheal
- 4 Lower Paratracheal (including Azygos Nodes)

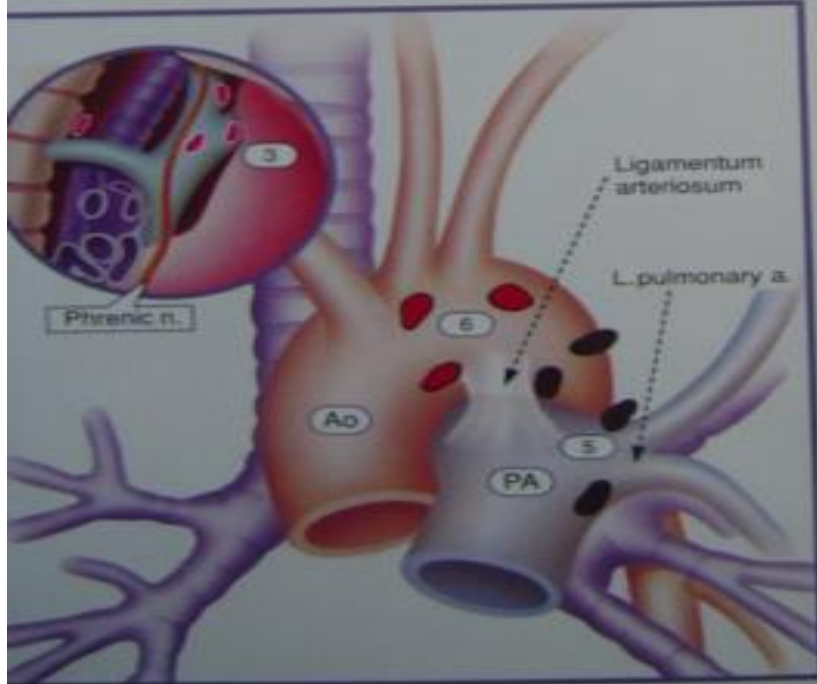
N<sub>1</sub> = single digit, ipsilateral  
 N<sub>2</sub> = single digit, contralateral or supraclavicular

### Aortic Nodes

- 5 Subaortic (A-P window)
- 6 Para-aortic (ascending aorta or phrenic)

### Inferior Mediastinal Nodes

- 7 Subcarinal
- 8 Paraesophageal (below carina)
- 9 Pulmonary Ligament



### N<sub>1</sub> Nodes

- 10 Hilar
- 11 Interlobar
- 12 Lobar
- 13 Segmental
- 14 Subsegmental

## **B. Secondary Lung Carcinoma**

### **Solitary Lung Nodule**

- **Primary Carcinoma**
- **Tuberculous Granuloma**
- **Mixed tumor**
- **°2 Carcinoma**
- **Miscellaneous**

### **Benign Vs. Malignant** **Hamartoma-Carcinoid**

- **Age**
- **Sex**
- **X-ray**
  - **Size**
  - **Time**
  - **Calcification**

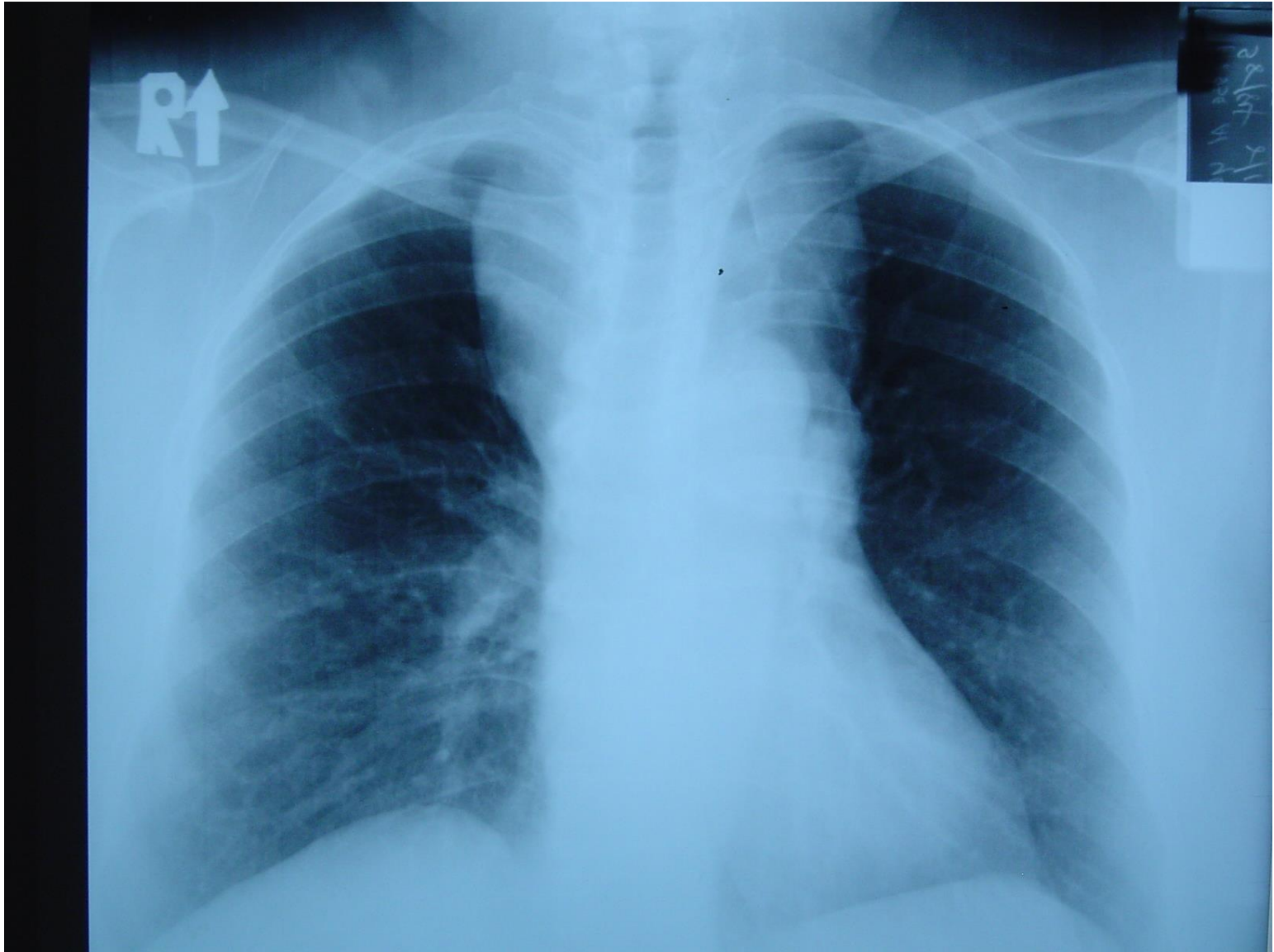
# **THE MEDIASTINUM**

## ➤ **Anatomy**

- **Boundaries**
- **Divisions**
  - **Traditional**
  - **Clinical**
- **Access: Mediastenoscopy, mediastenotomy**

## ➤ **Mediastinal mass lesions**

- A. Anterior mediastinum(5 T's)**
- B. Middle Mediastinum(Cyst)**
- C. Posterior mediastinum(Neurogenic)**



1999/02/18 10:01:19  
THORAX

02.008:01 NO C  
SN -23.0mm  
+00.0°  
10mm  
33.0cm  
x= +0.00cm  
y= +0.00cm  
STND

HESSA AL TARAG  
A

1999/02/18 10:01:24  
THORAX

GMC

GMC

3-  
0-  
cm

3-  
0-  
cm

R

L

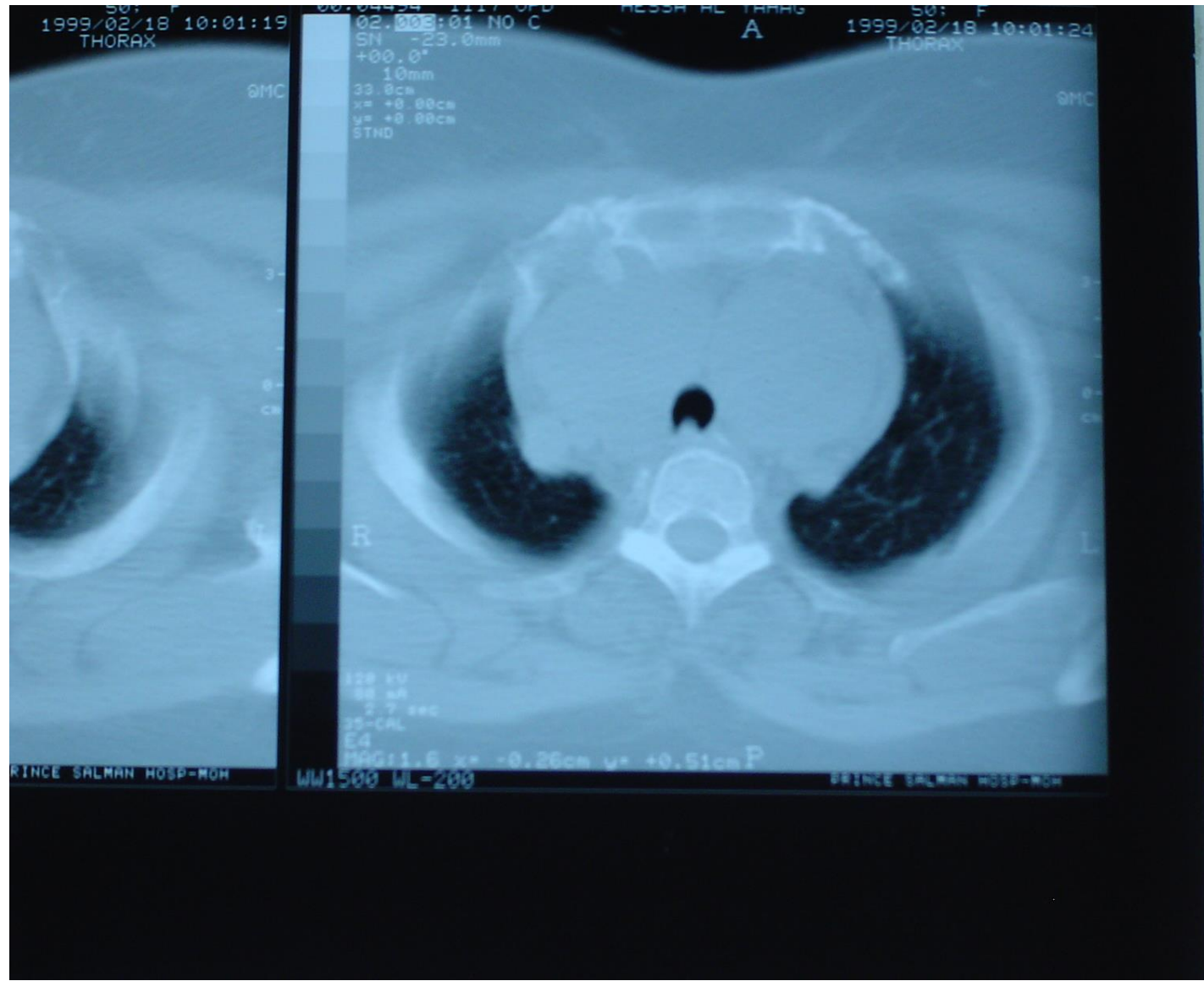
128 kV  
88 mA  
2.7 sec  
35-CAL  
E4

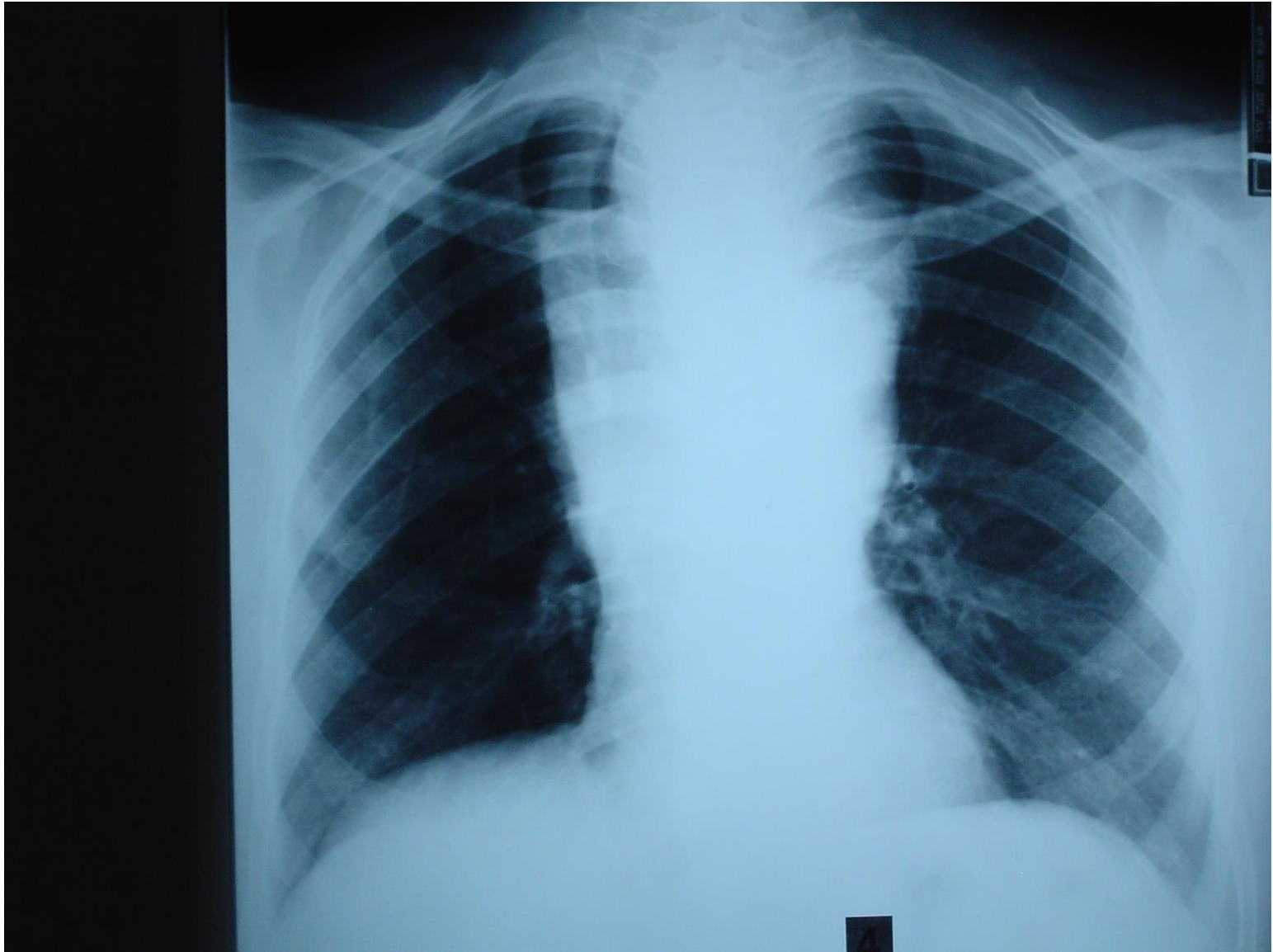
MAG:1.6 x= -0.26cm y= +0.51cm P

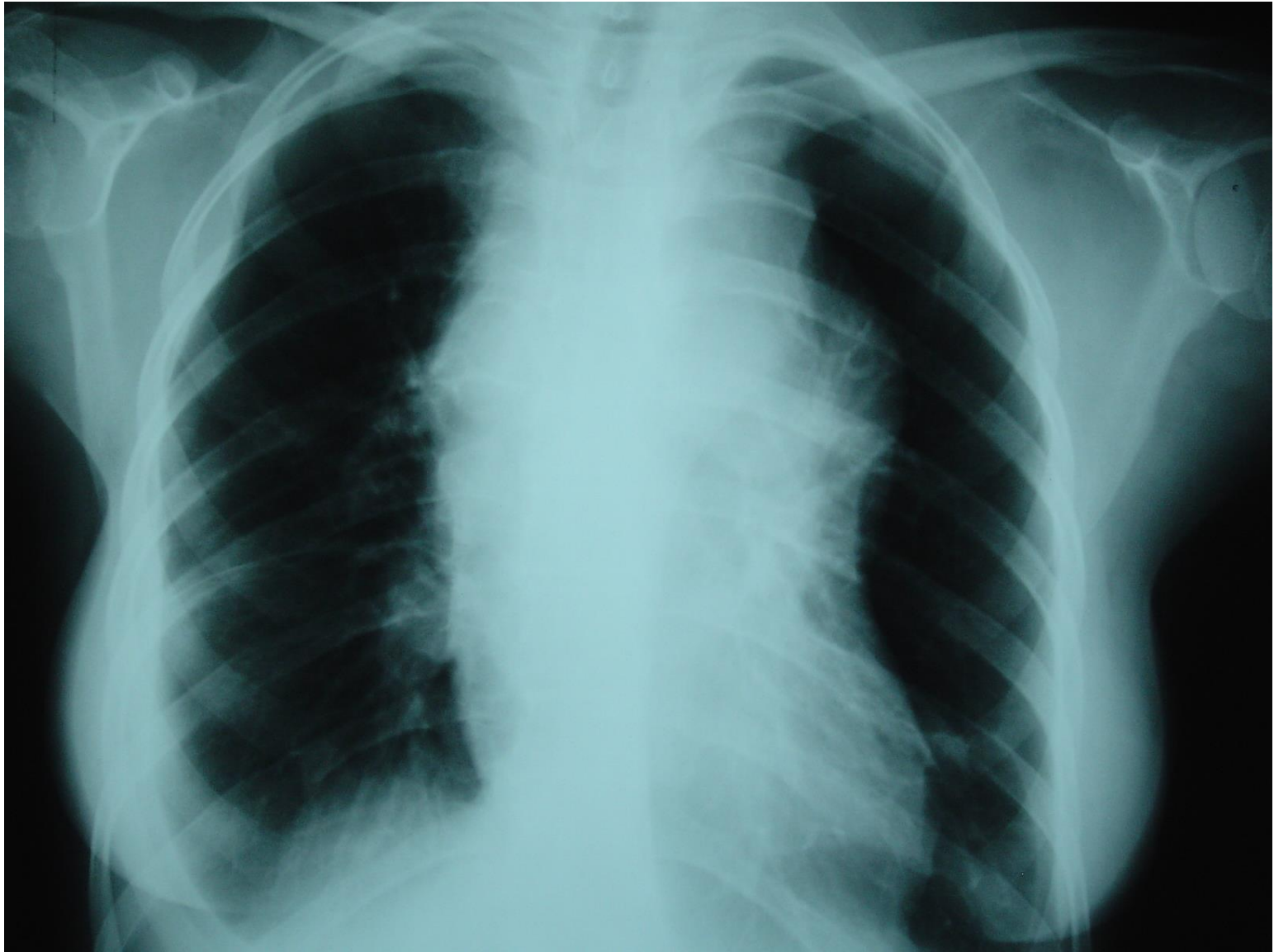PRINCE SALMAN HOSP-MOH

WW1500 WL-200

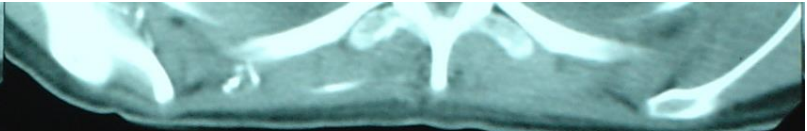
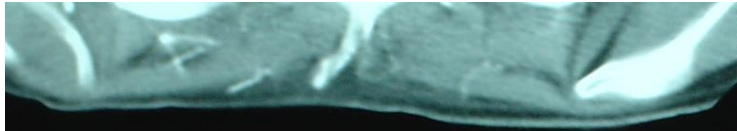
PRINCE SALMAN HOSP-MOH











s 123.5

436 / 22

Pos 113.5

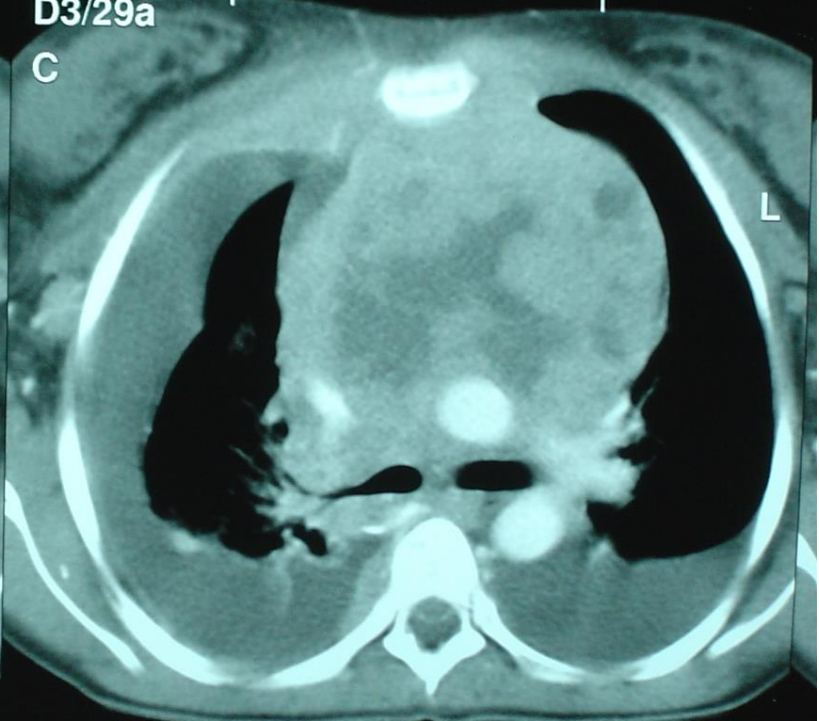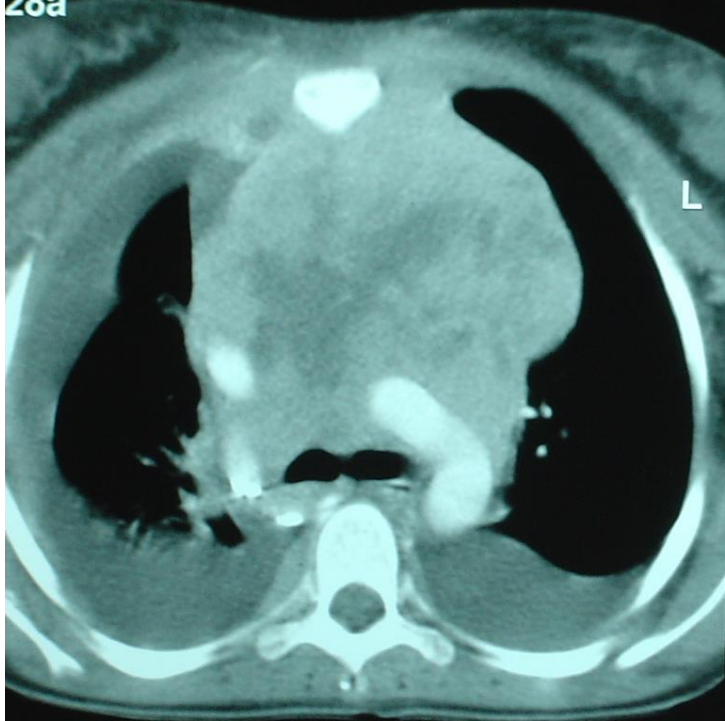
436 / 22

28a



D3/29a

C



s 83.5

436 / 22

Pos 73.5

436 / 22

F

# THYMOMA

## ➤ Incidence

- The commonest tumor of A.M.
- Peak 40-60 y.
- M : F (1 : 1)

## ➤ Pathology

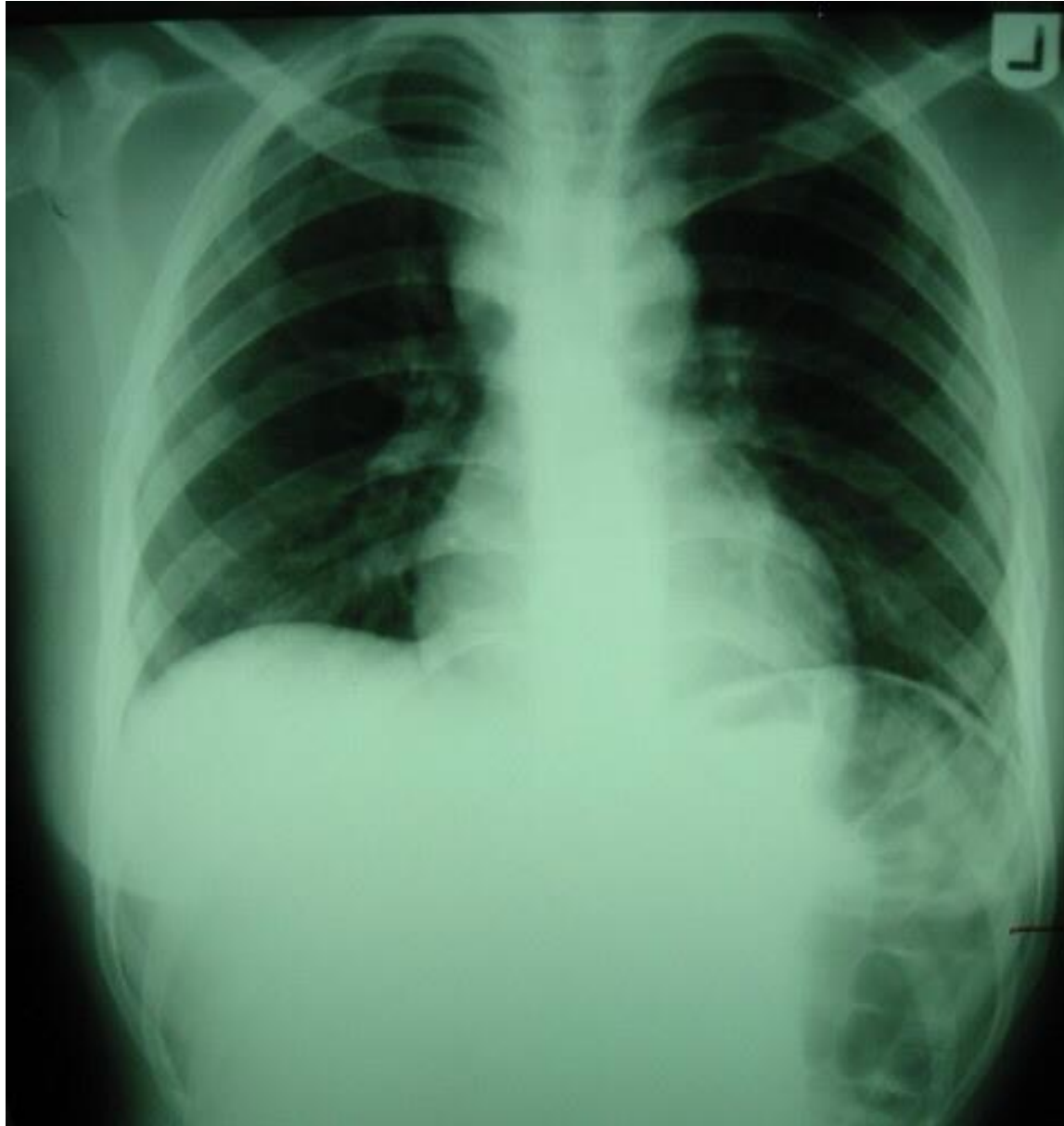
- **Classification**
  - **Epithelial**
  - **Lymphocystic**
  - **Lymphoepithelial**
  - **Spindle cell**
- **Benign vs. malignant**
- **Stages**
  - I, II, III, IV**

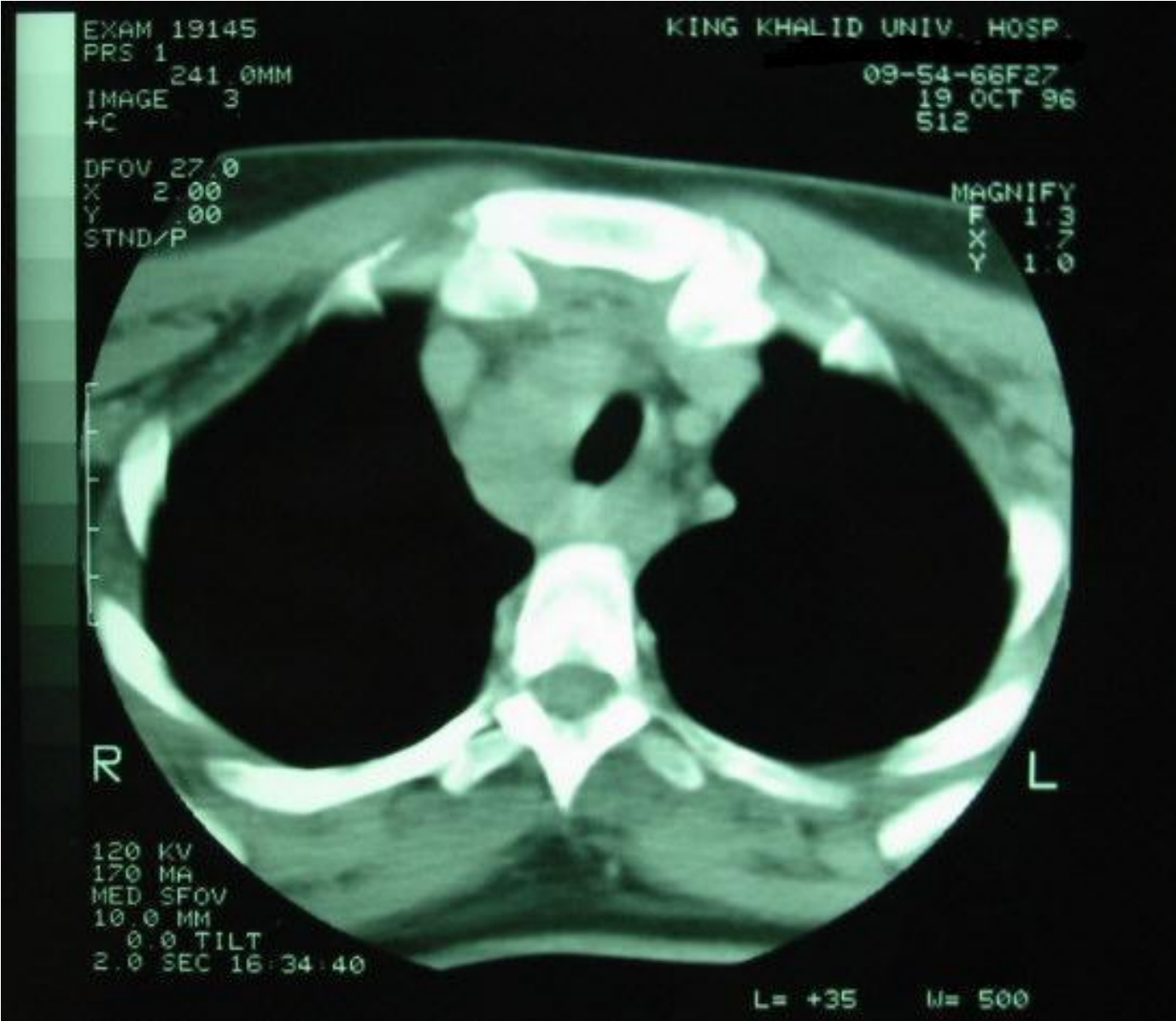
## Clinical Features

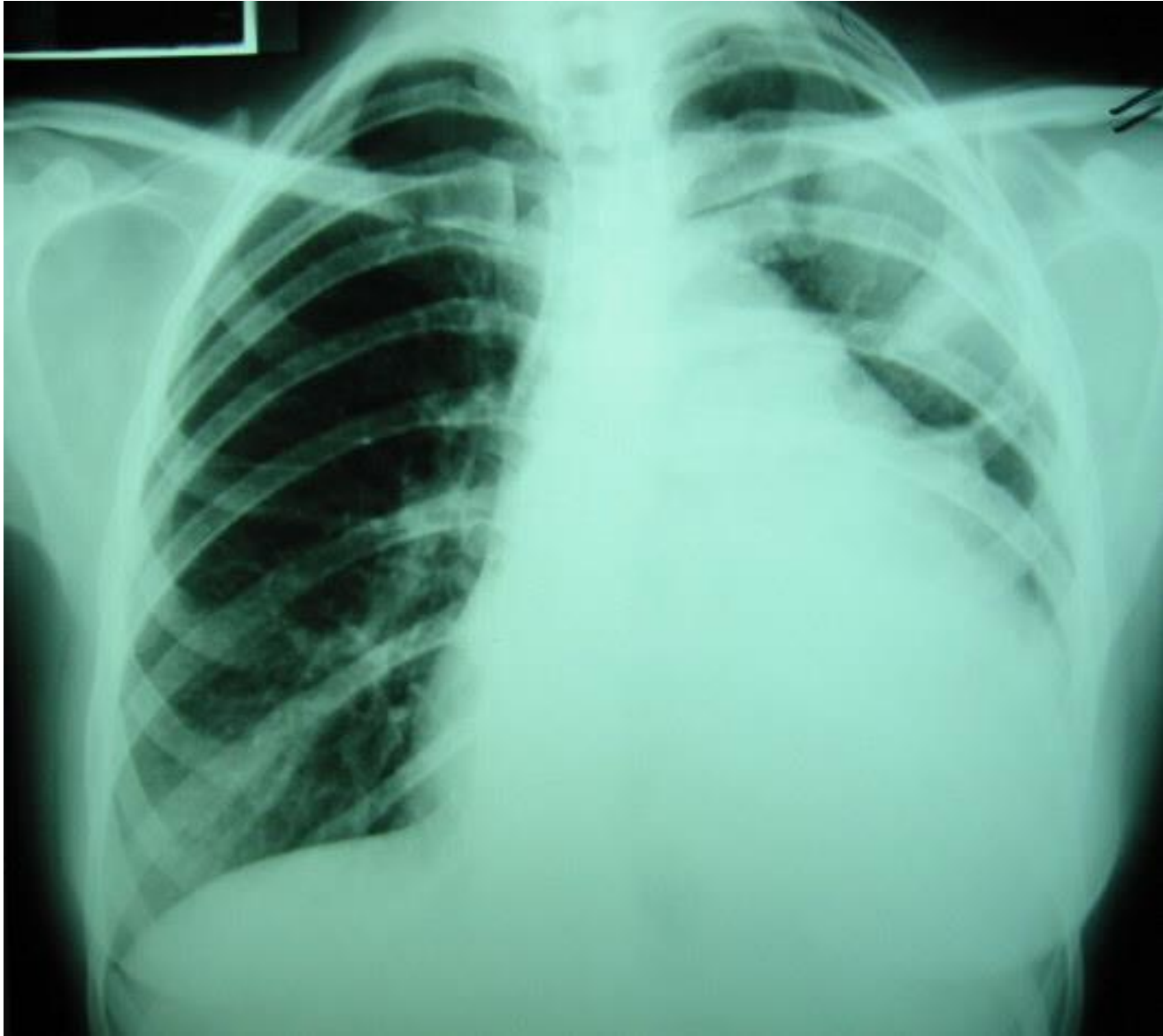- **Asymptomatic**
- **Symptomatic**
  - **Mass effect**
  - **Systemic effect**
    - **M.G. is the commonest 40-50%**

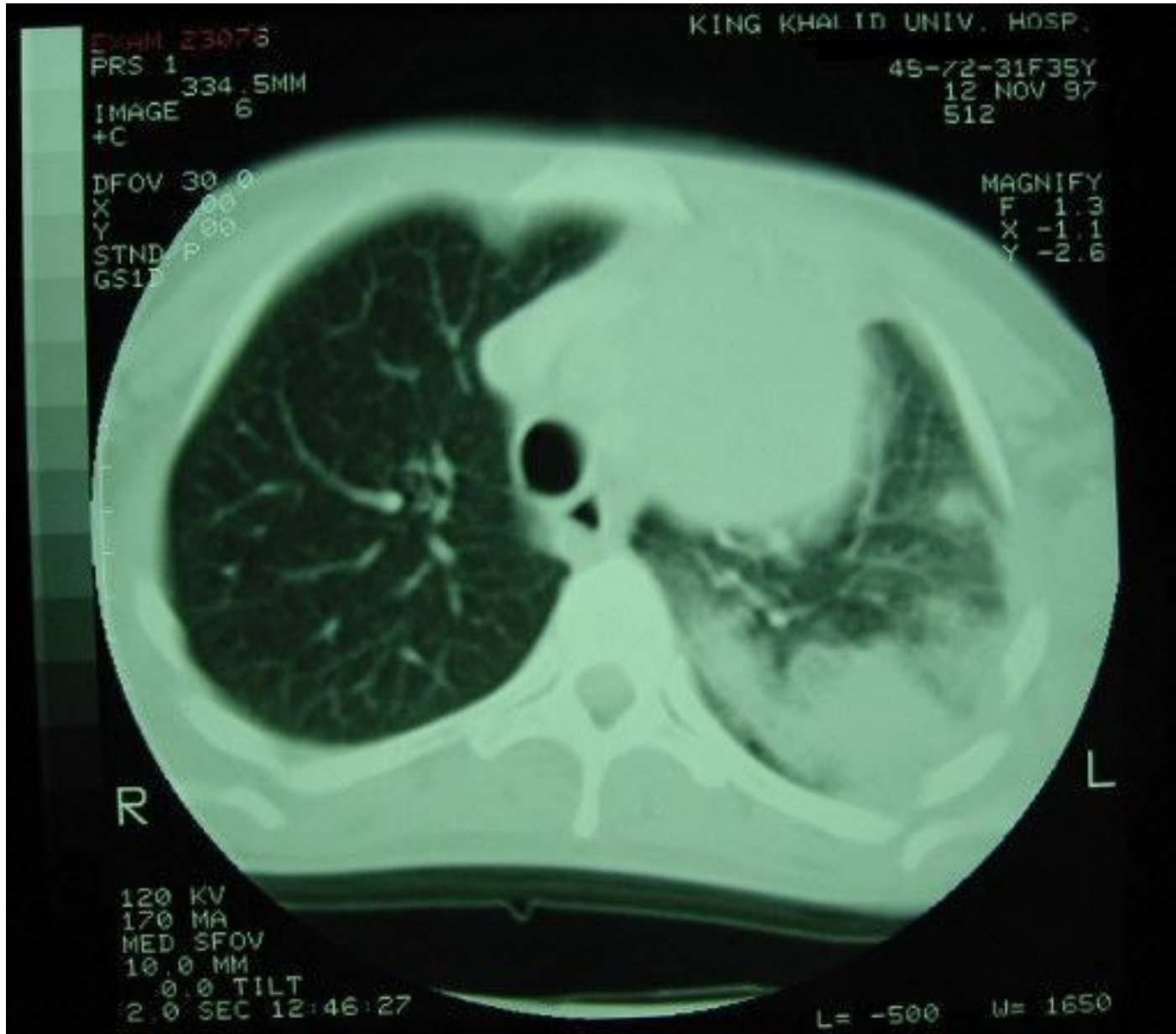## Investigation

- **C X R**
- **CT Scan**
- **Biopsy**
- **Bronchoscopy**        }
- **Esophagoscopy**       }       **Selected**
- cases**
- **Angiogram**         }











## ➤ Treatment

- **Benign** → complete excision
- **Malignant** → complete excision if possible

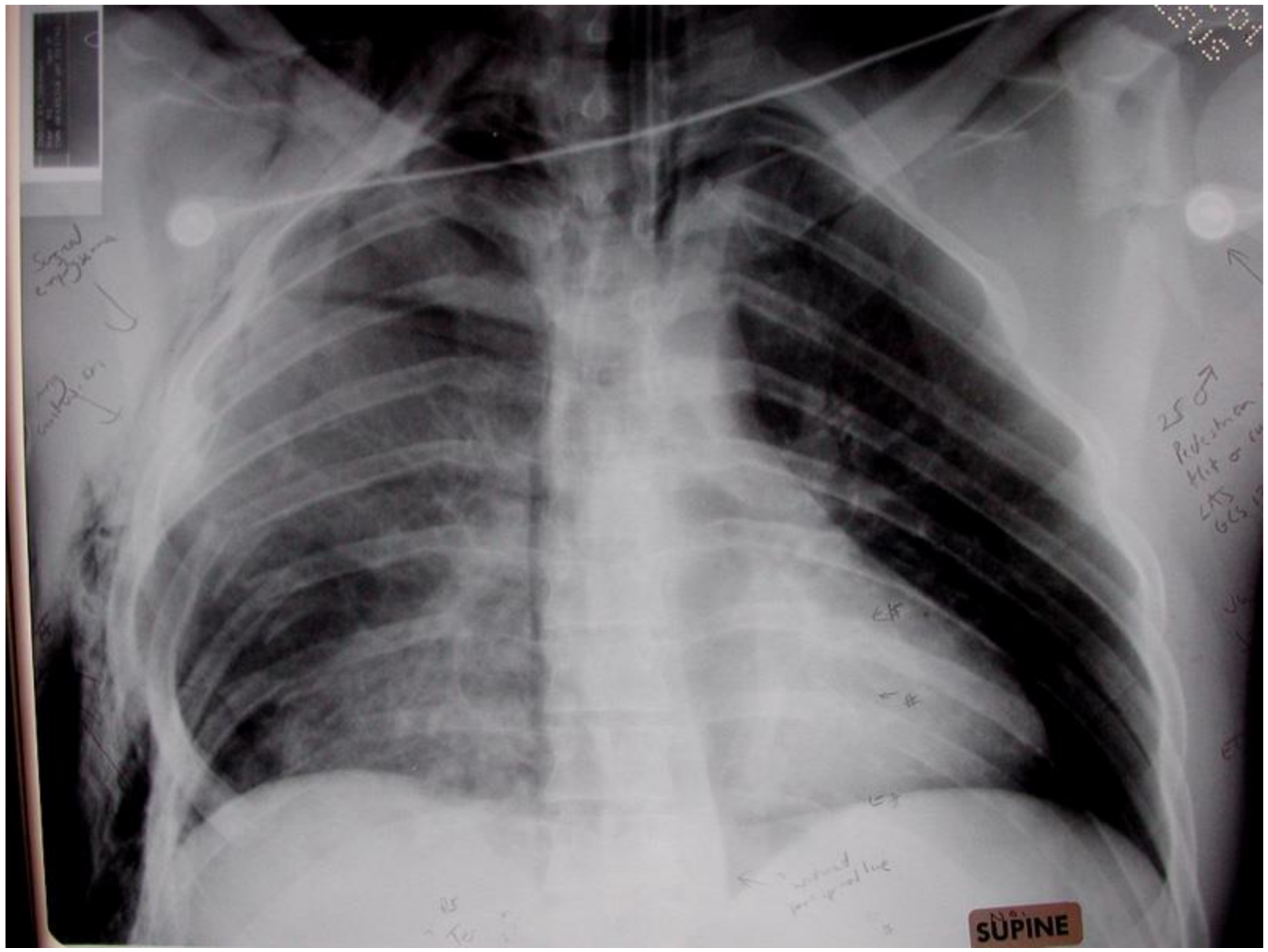
**If non-resectable } post-op**

**Or } Radiotherapy**

**Resection incomplete }**

# Trauma

- **RTA**
- **Fracture Ribs Simple – Complicated**
- **Haemothorax**
- **Pneumothorax**
- **Flail chest**
- **Lung Contusion and ARDS**



AP CHEST X-RAY

25 07

Spinal cord injury ✓  
Fracture on ✓

25 07  
Pulmonary Hlt or  
LTS  
6/5

Fracture

↑

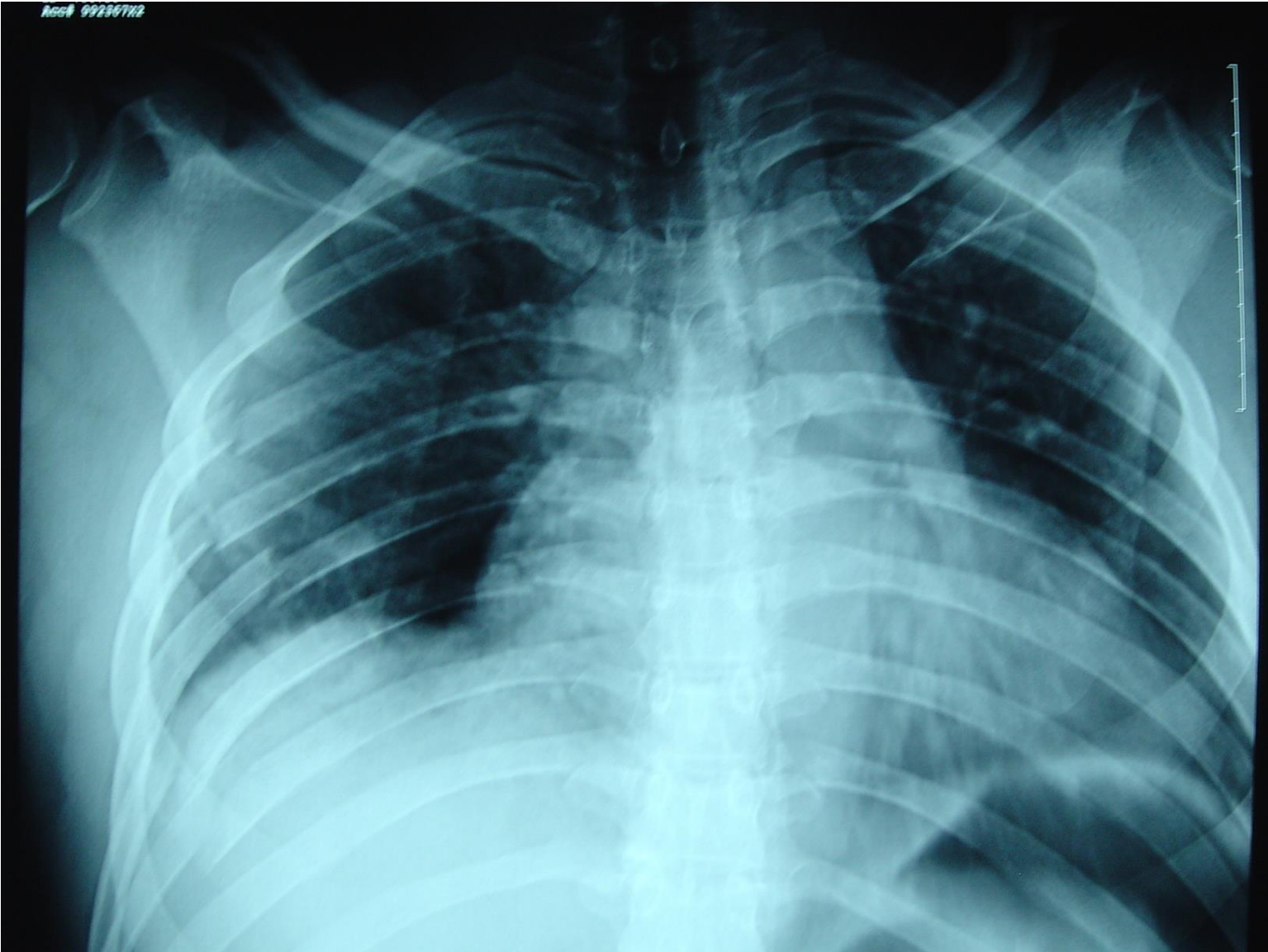
↑

↑  
Fracture

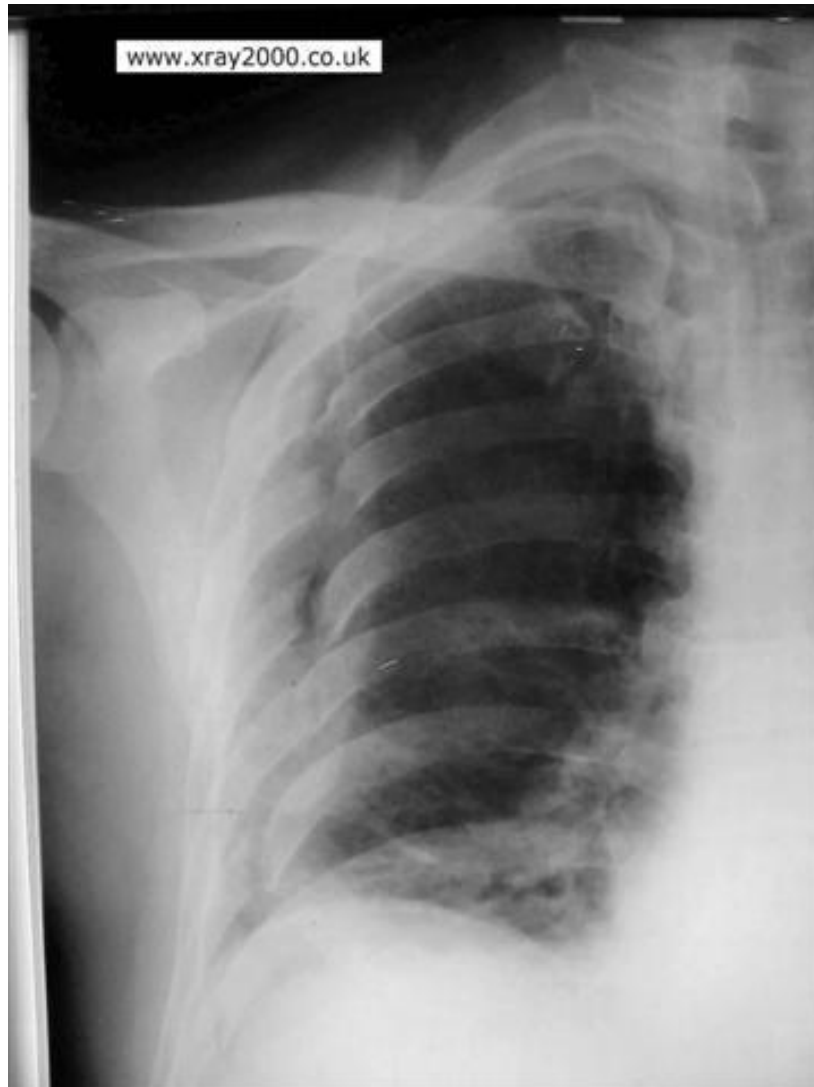R5  
Ker

No SUPINE

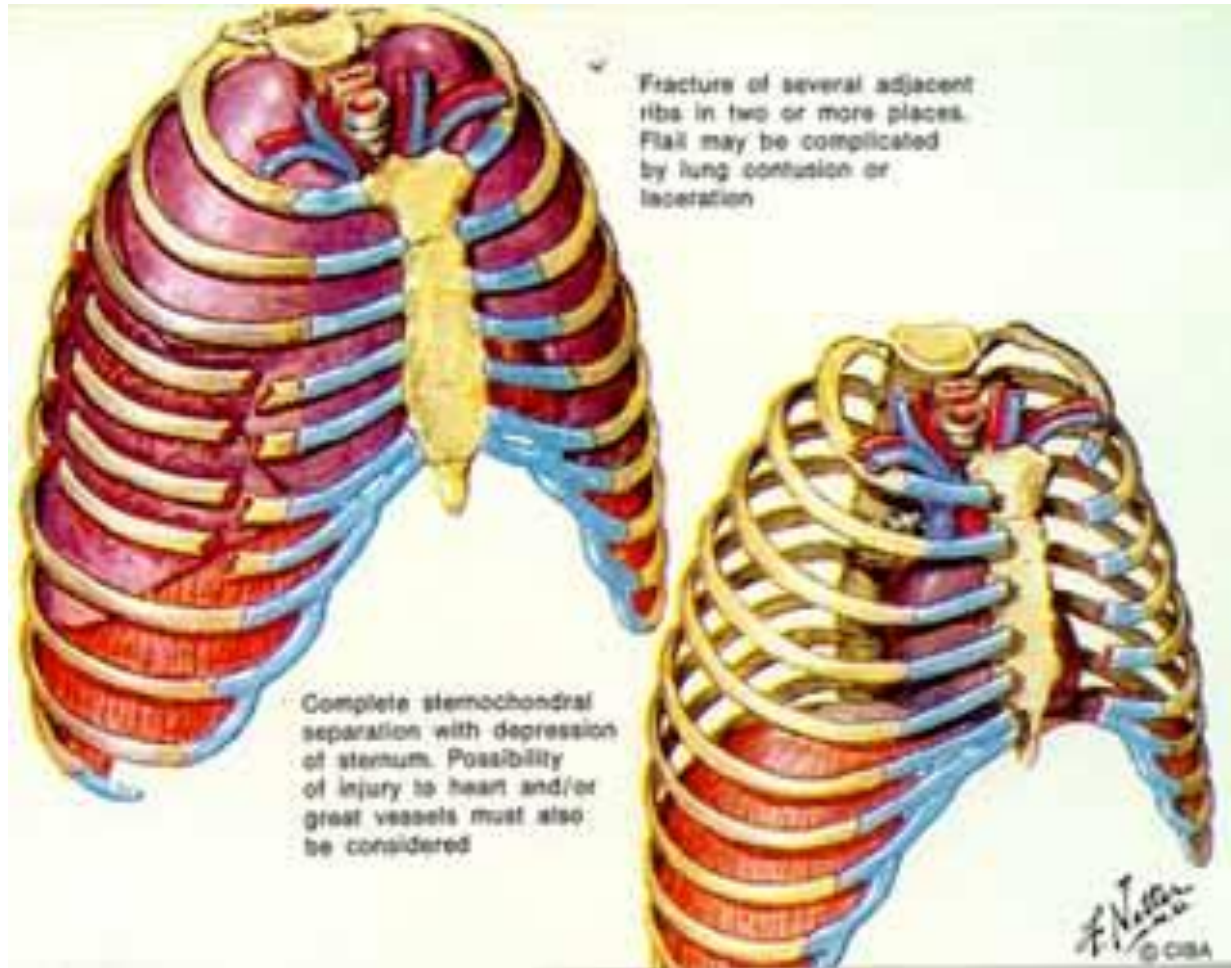
Acad 09296712

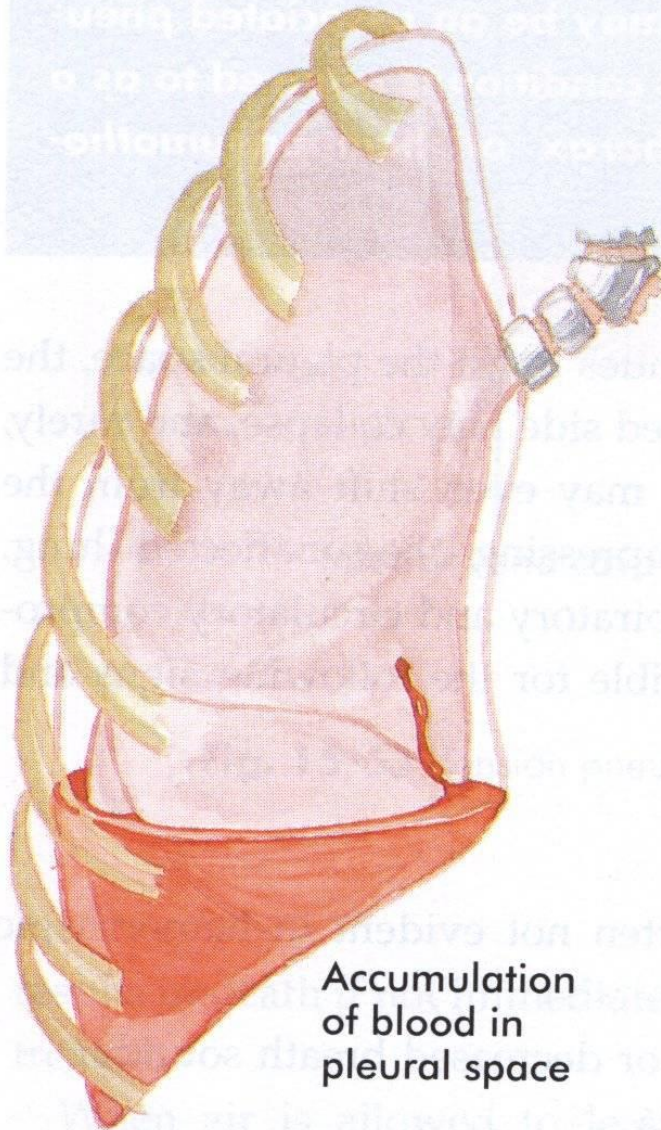

[www.xray2000.co.uk](http://www.xray2000.co.uk)



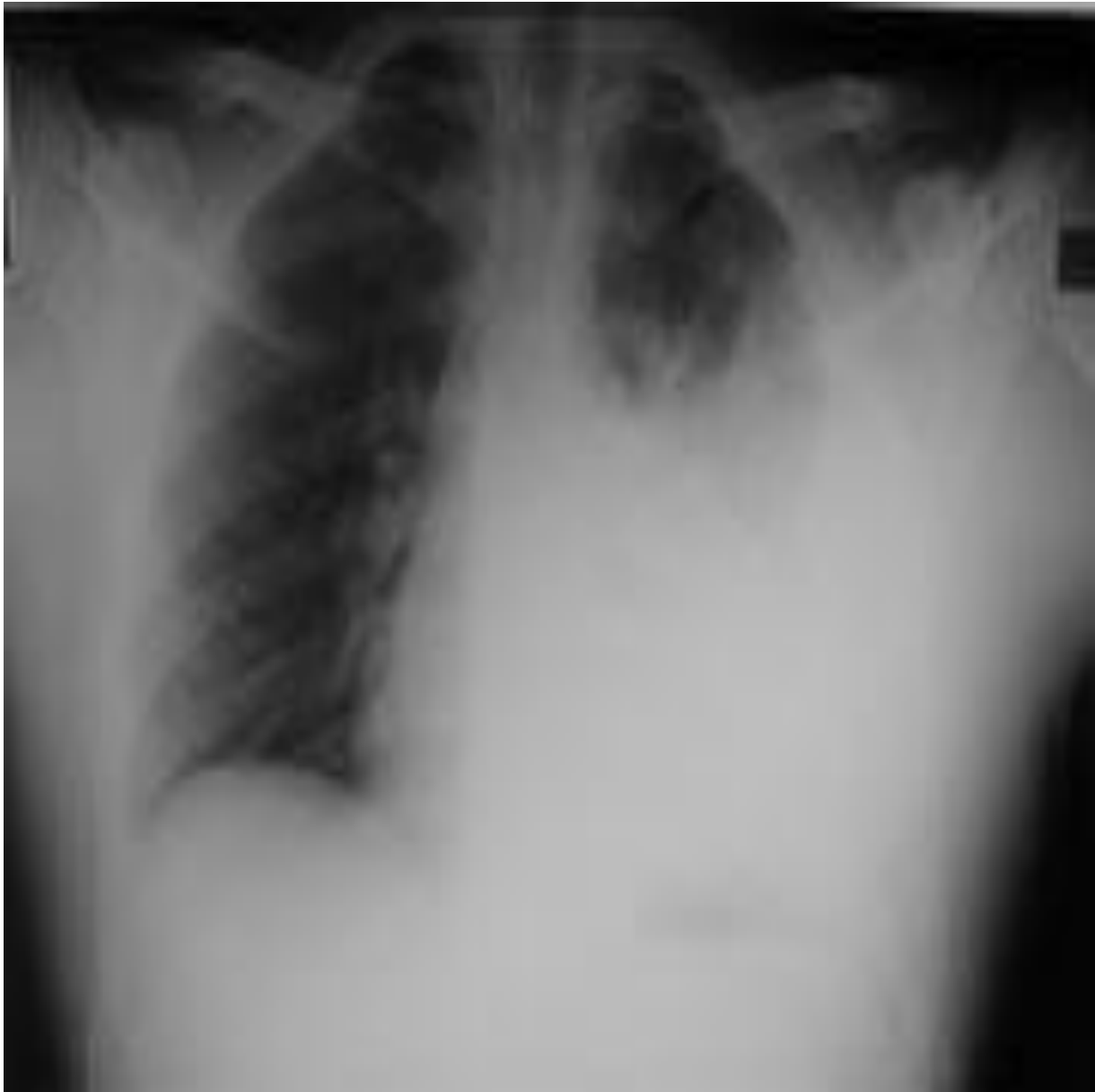# Flail Chest



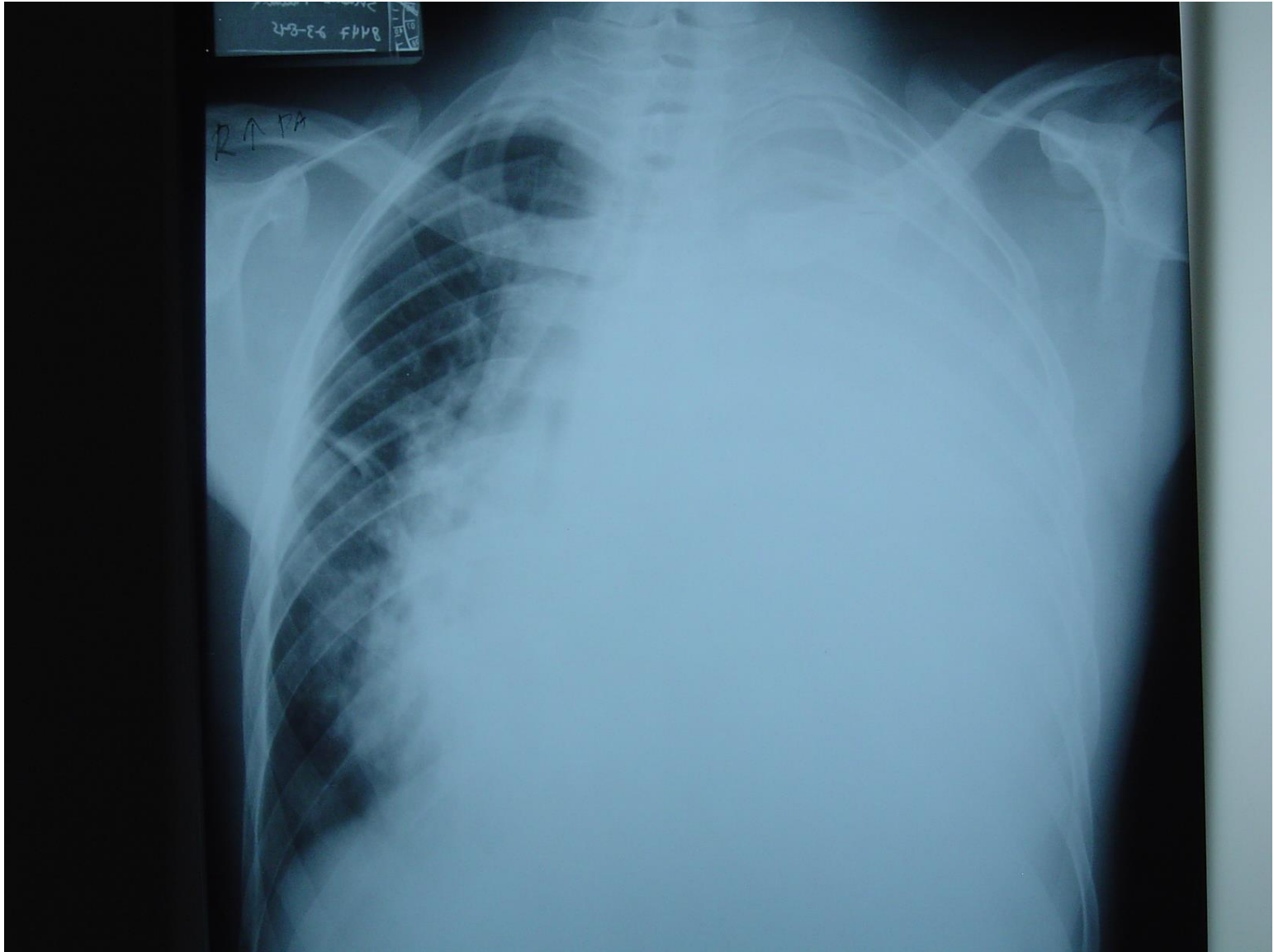


Accumulation  
of blood in  
pleural space

Hemothorax.







16:39:15.00

TP -608.5

IMA 22

SPI 2

R

+C

kV 120

mA 130

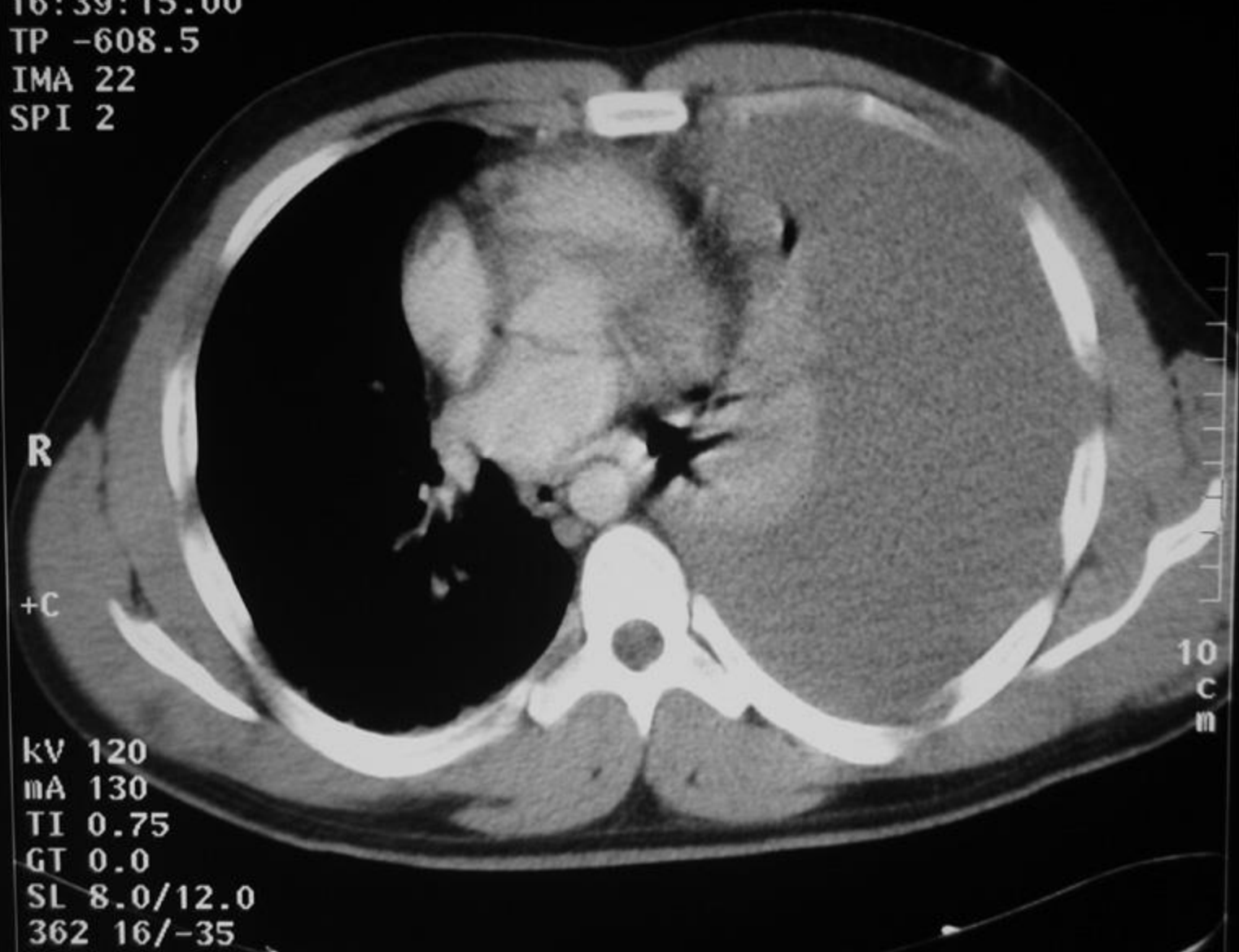TI 0.75

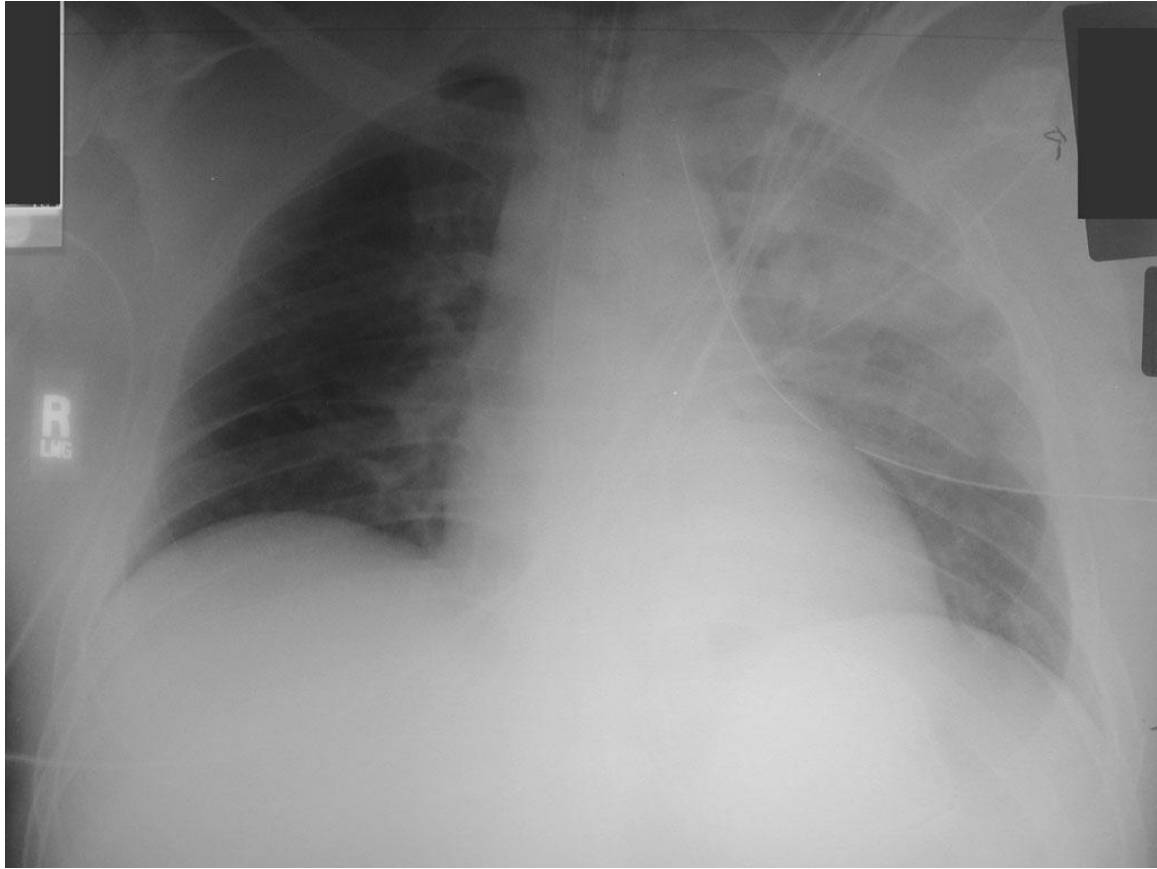
GT 0.0

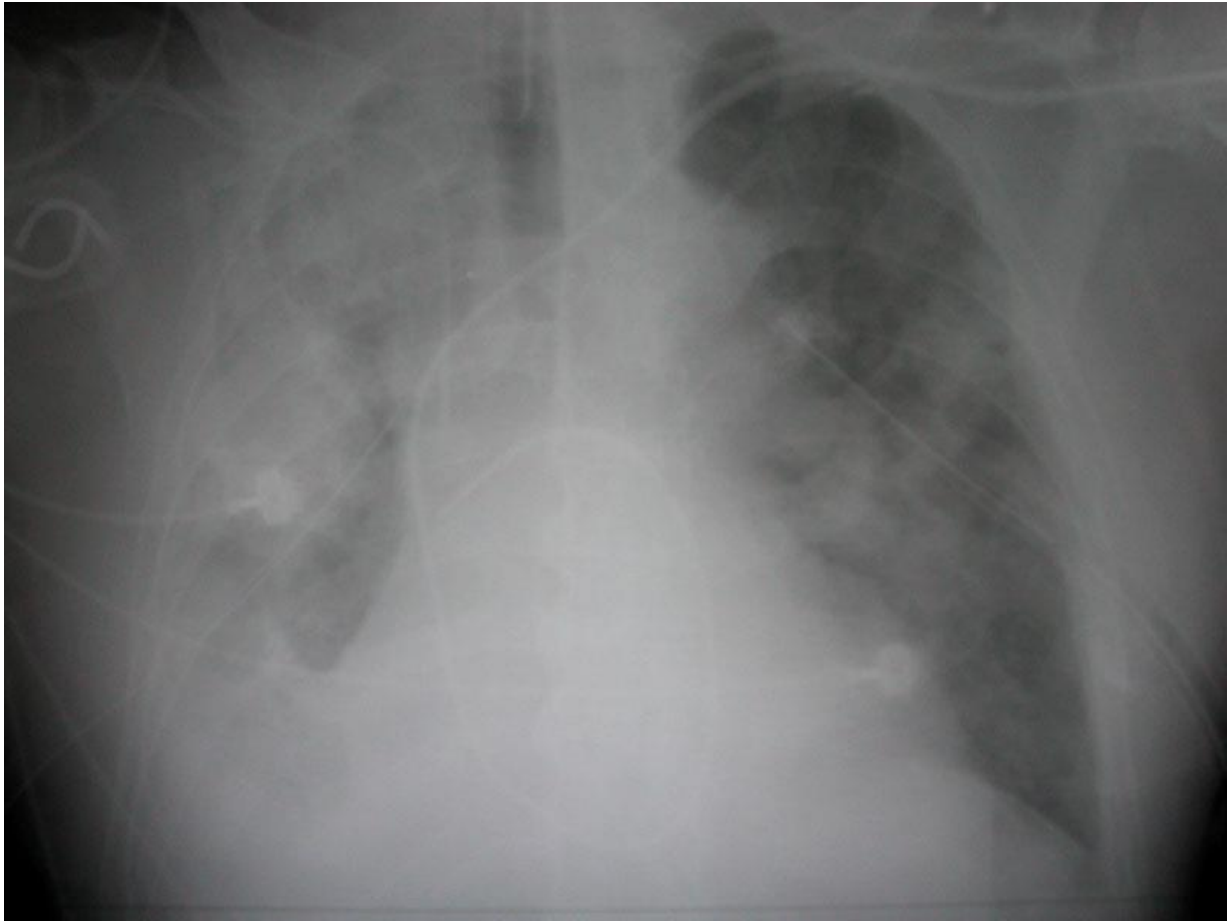
SL 8.0/12.0

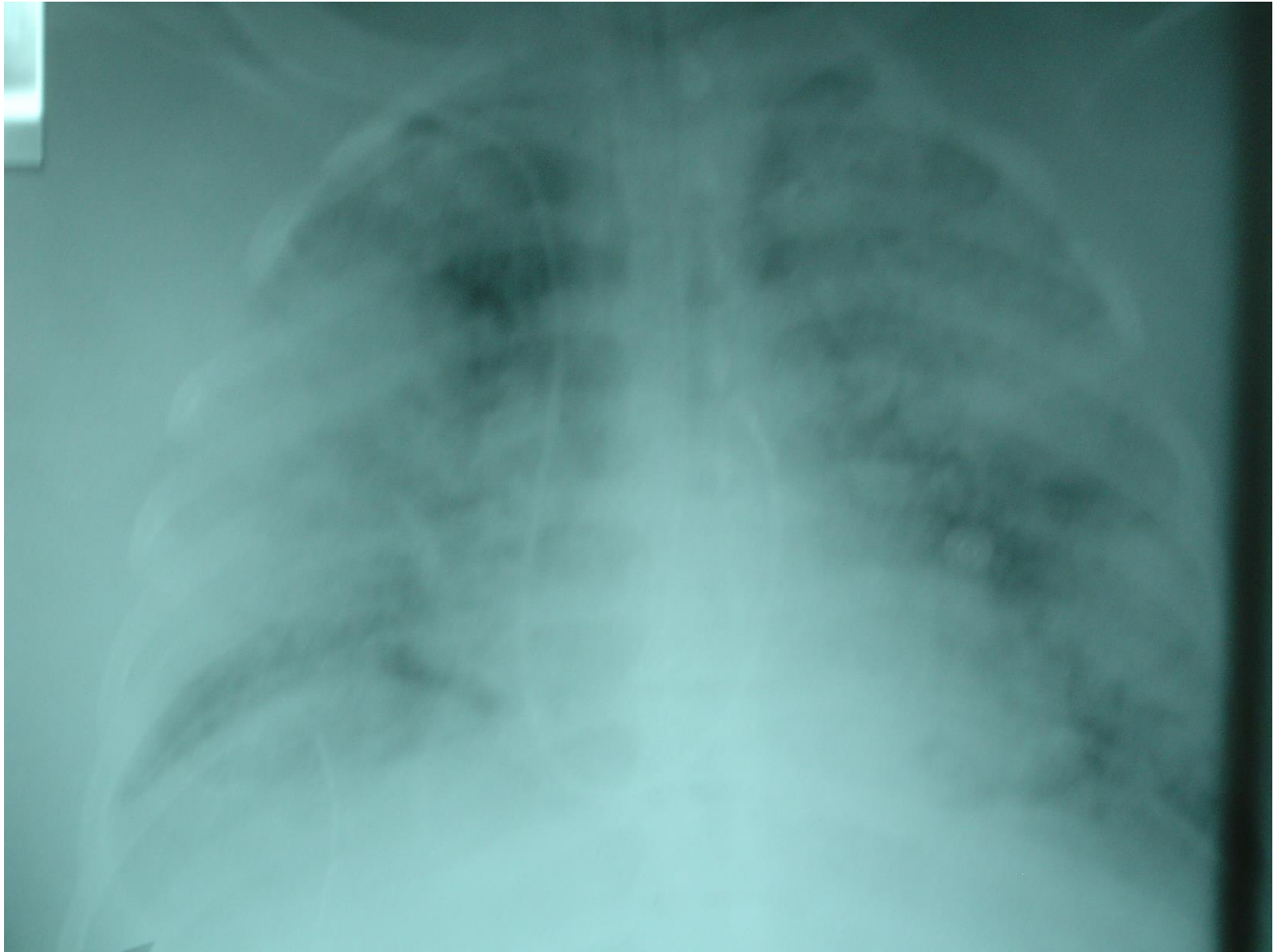362 16/-35

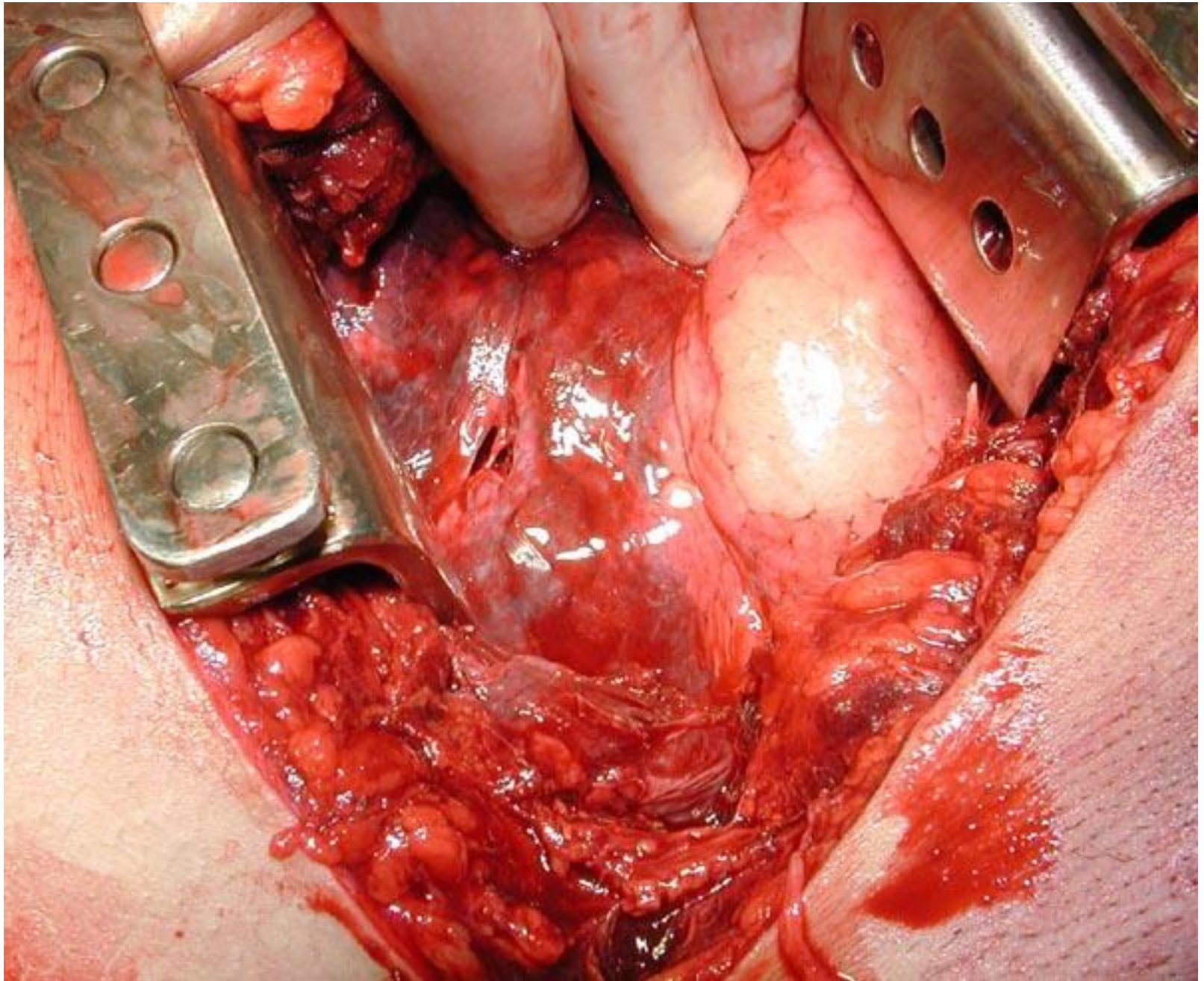
10  
C  
M





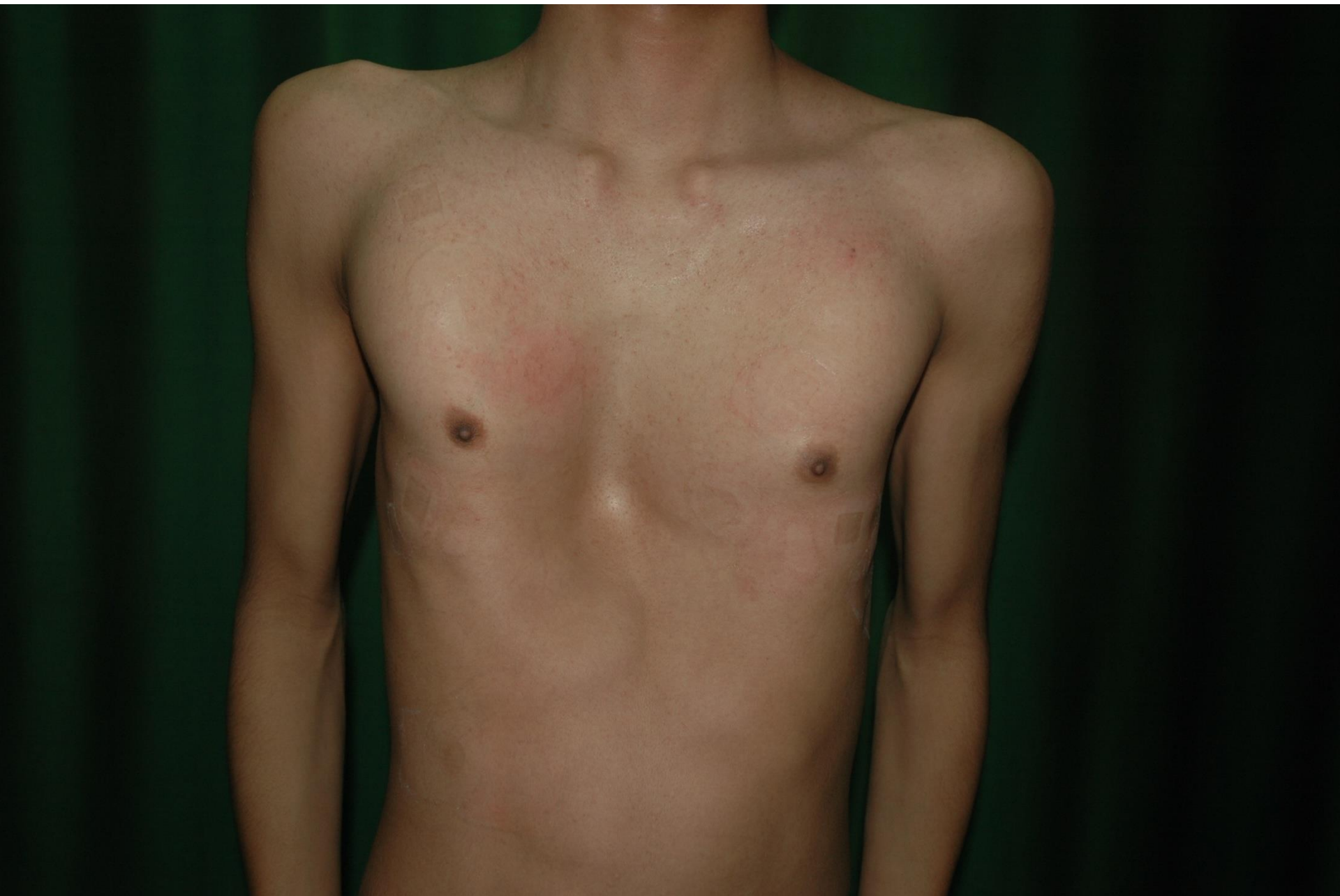




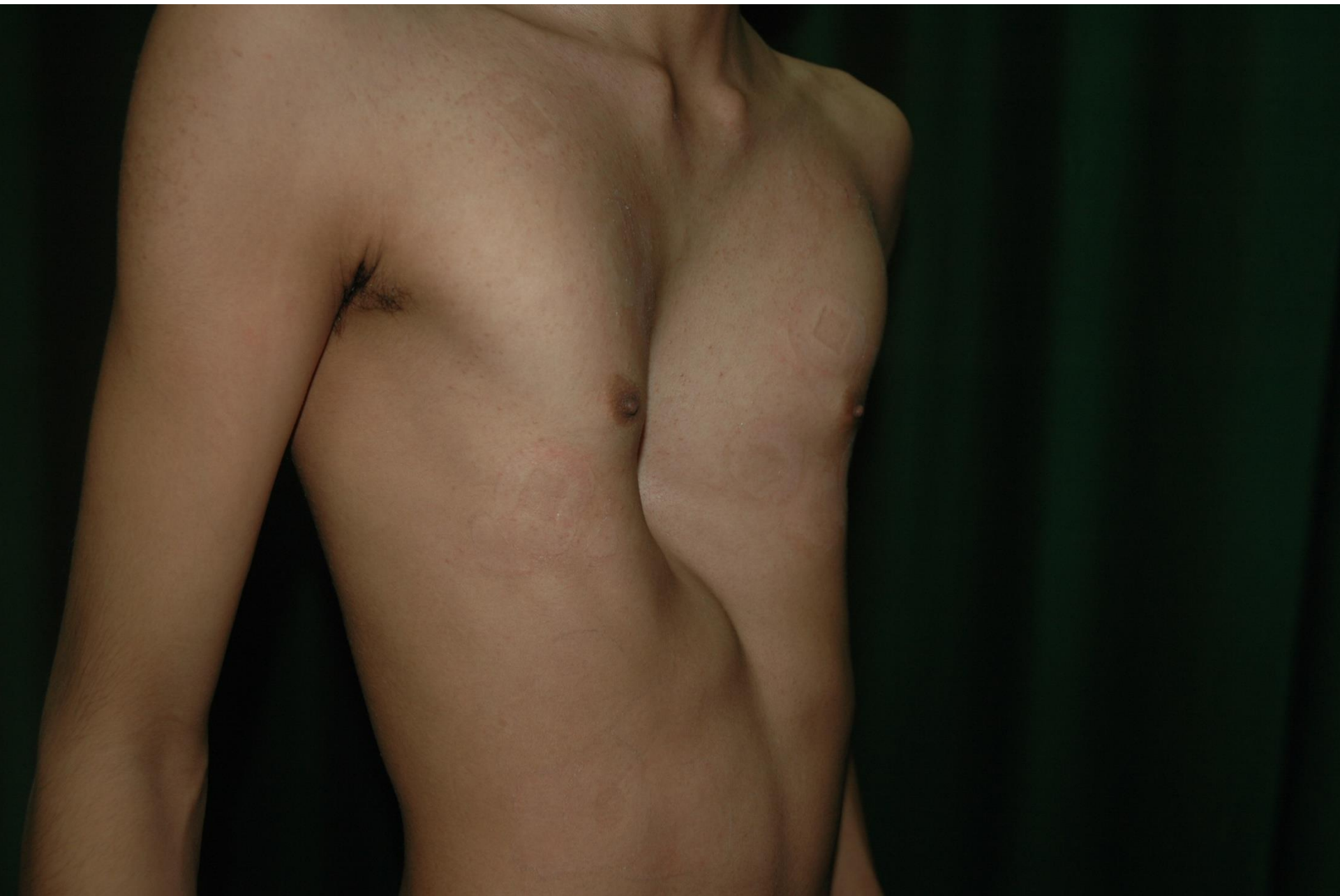
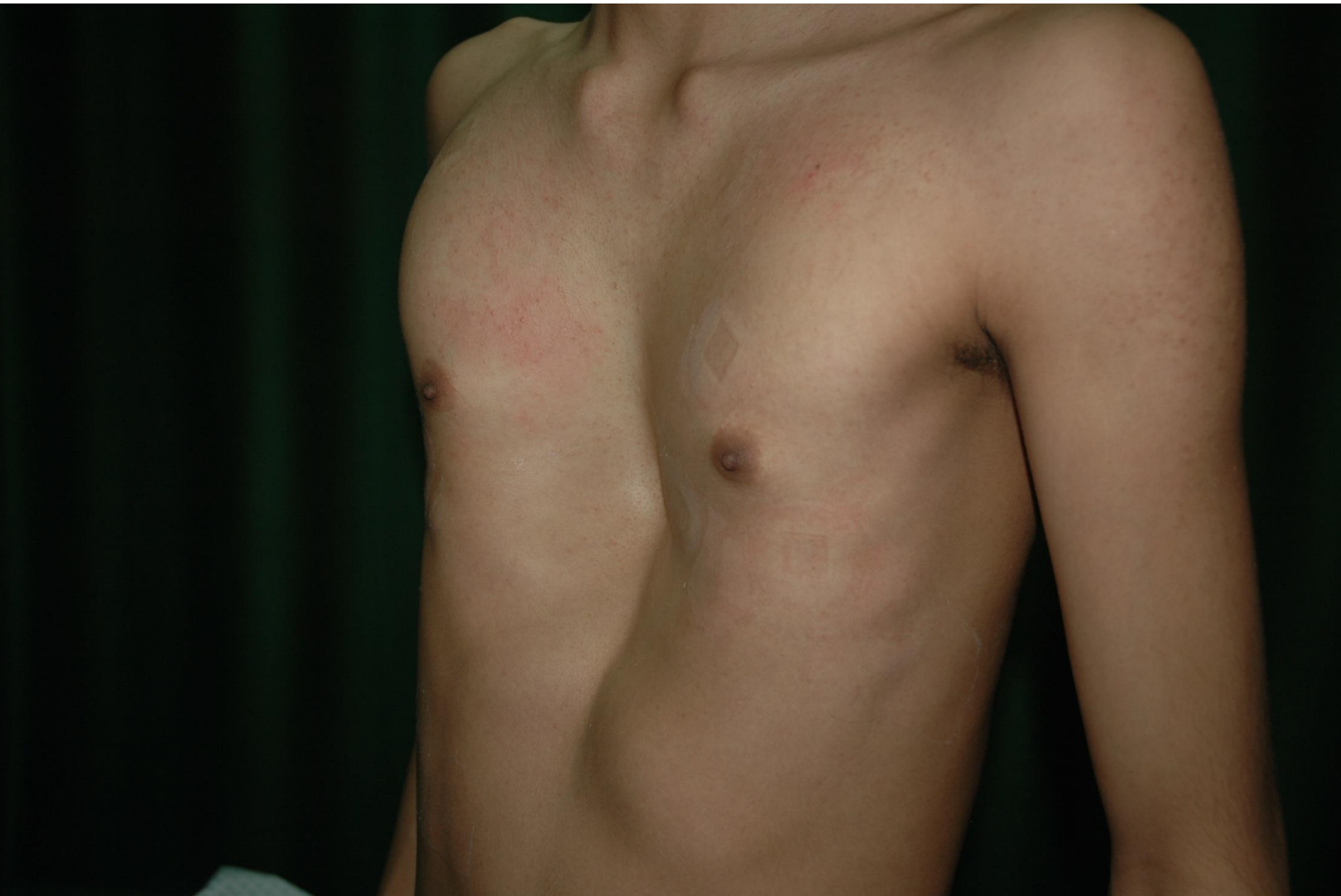# Chest Wall

- **Deformity:**
  - **Pectus excavatum**
  - **Pectus Carniatum**
- **Infection**
- **Chest wall tumor**
- **Thoracic outlet Syndrome.**



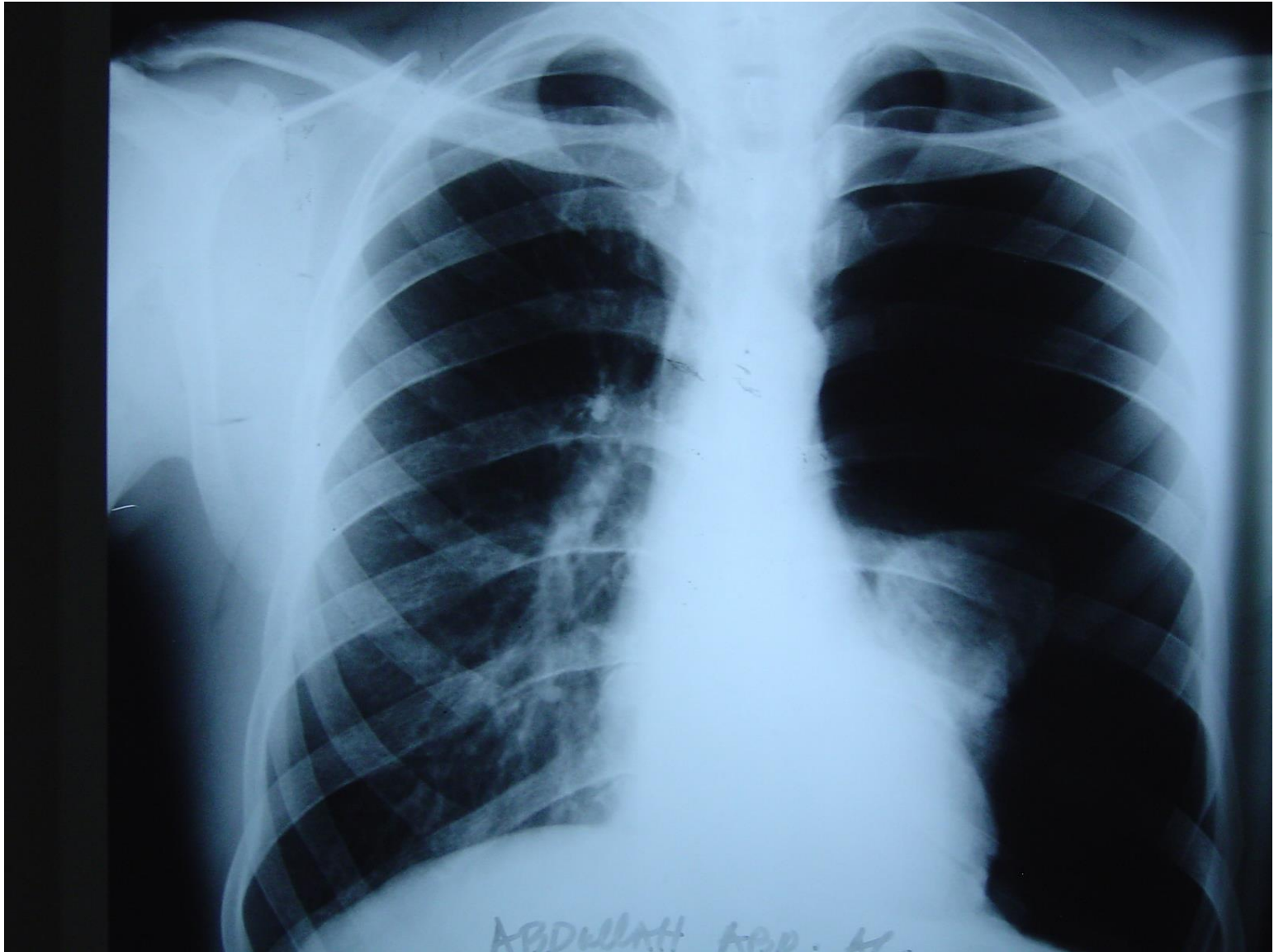

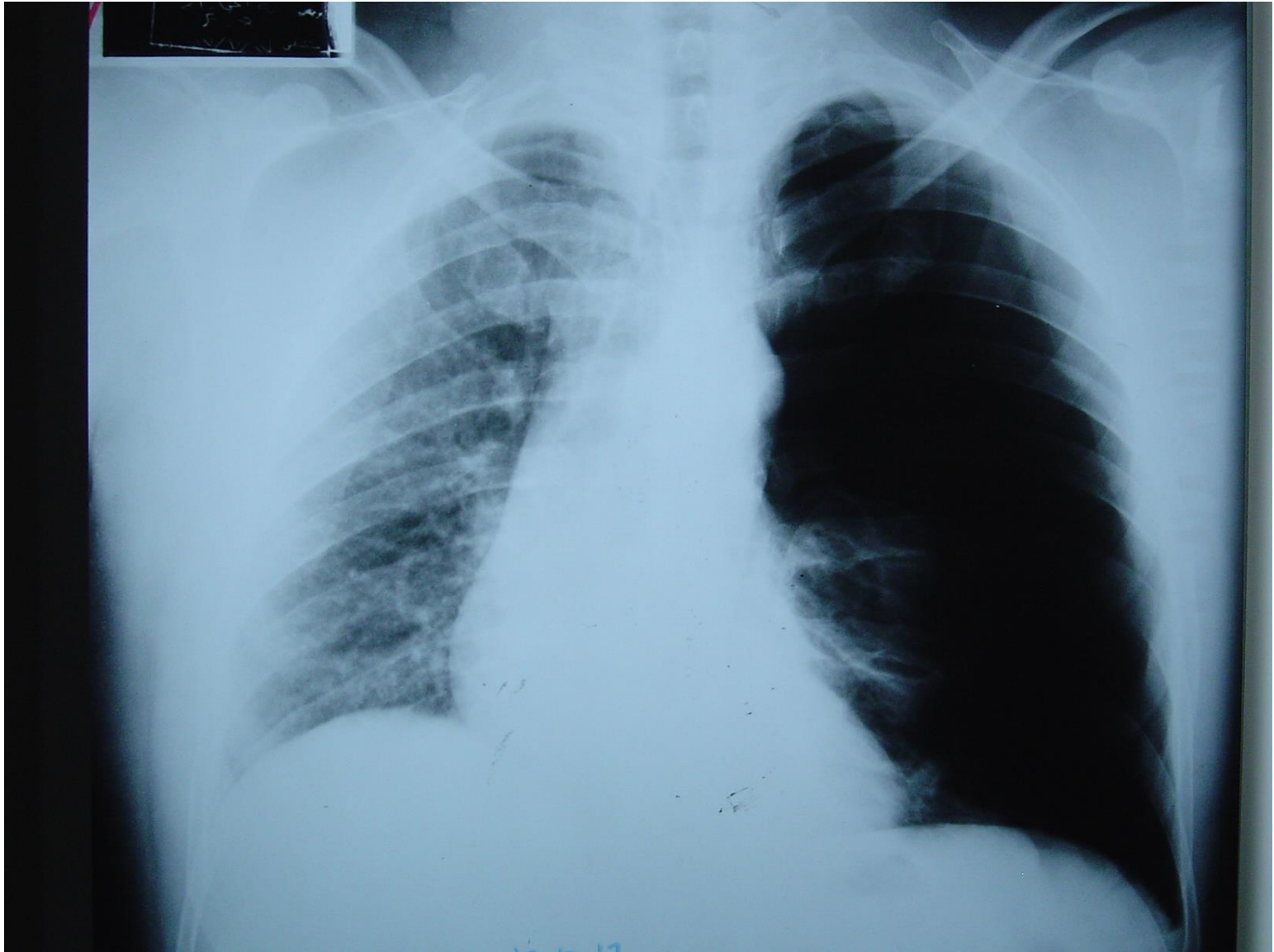


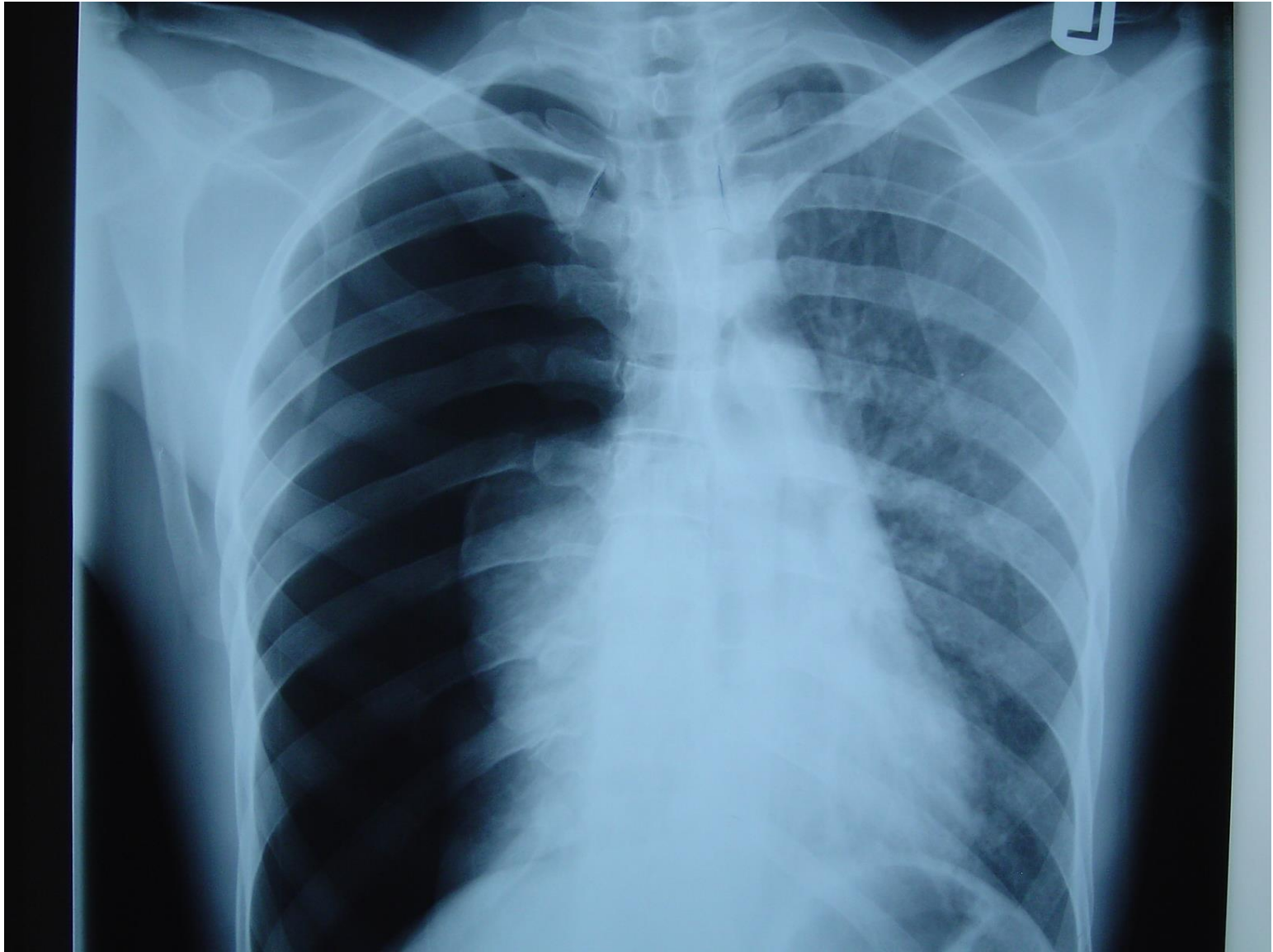


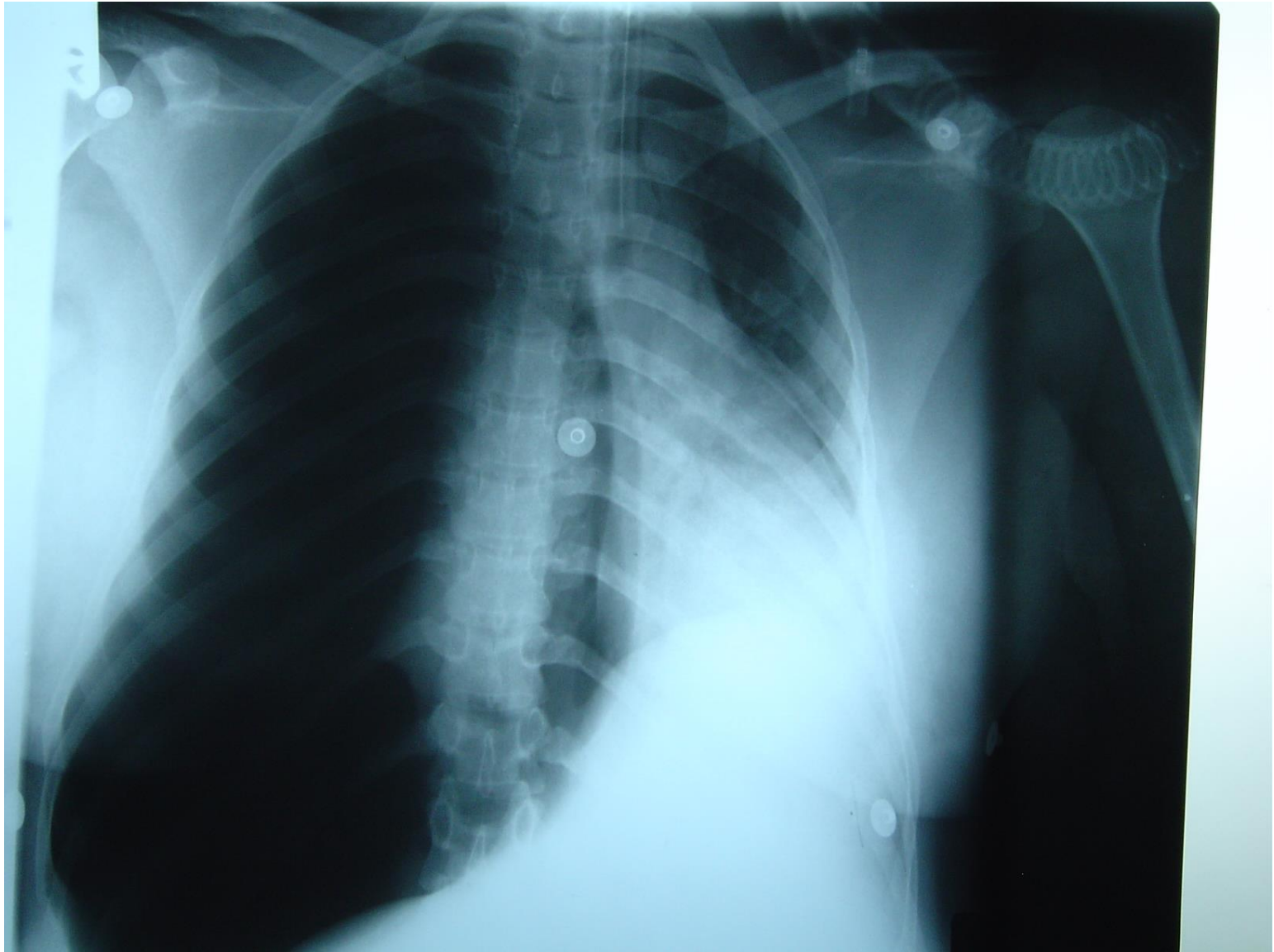
# Pleura

- **Spontaneous pneumothorax**
- **Pleural effusion**
- **Empyema**
- **Mesothelioma .**









Se:44499  
Im:1

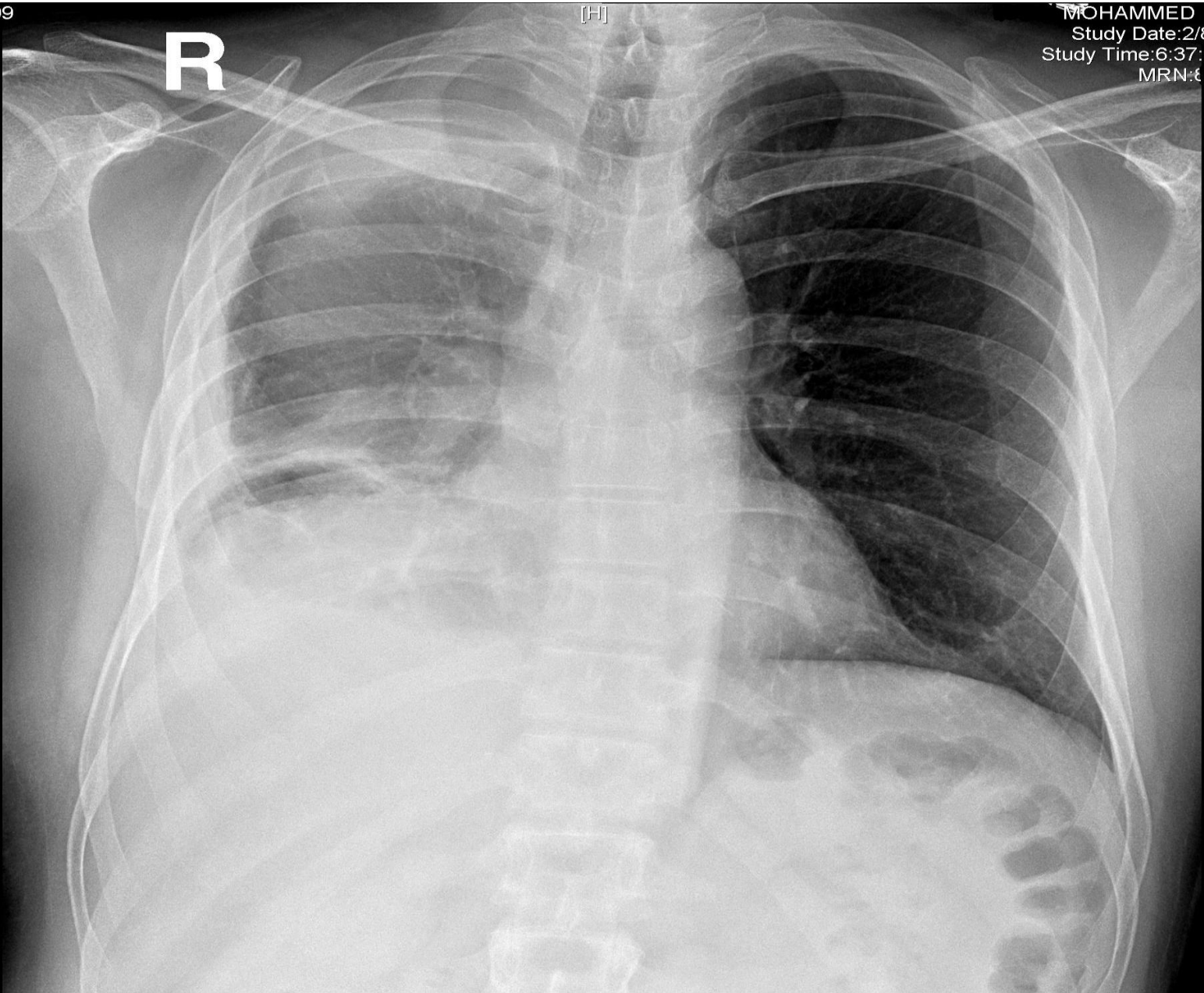
[H]

MOHAMMED  
Study Date:2/8/2007  
Study Time:6:37:10 AM  
MRN:6

R

[R]

[L]



[F]

C5411  
W2859

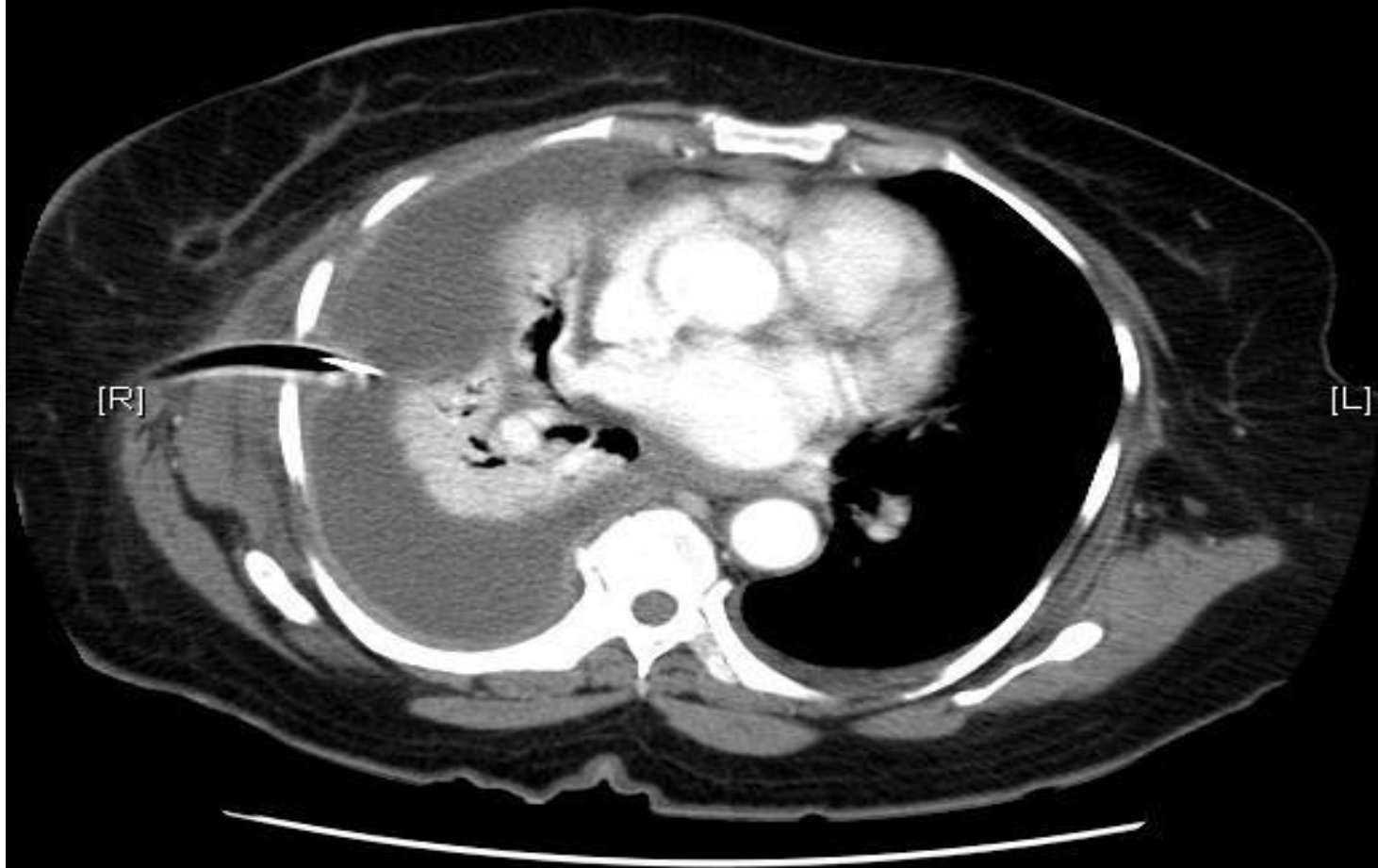




Se:2  
Im:27

[A]

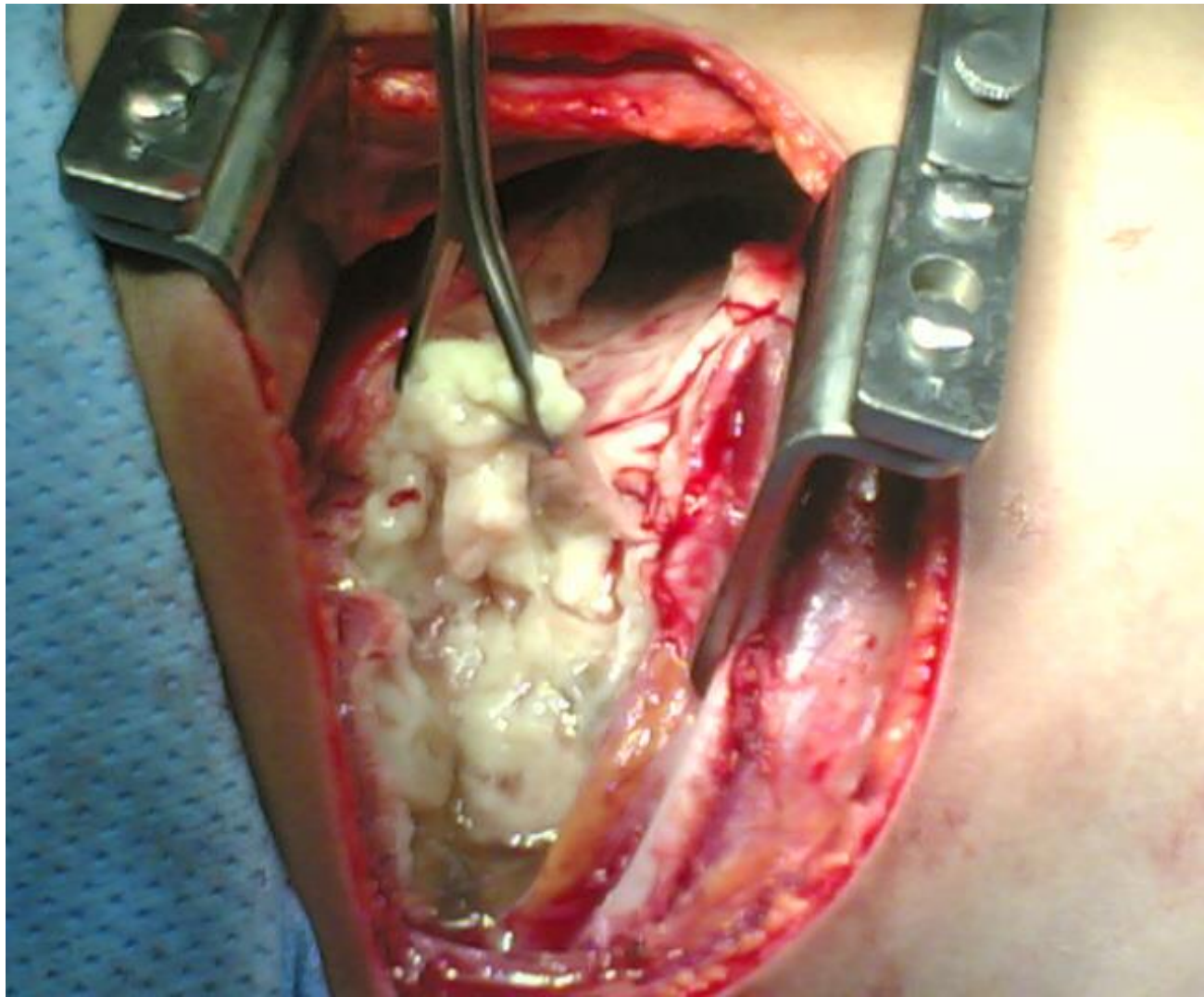
SALMA  
Study Date: 2/3/2007  
Study Time: 10:35:08 AM  
MRN:

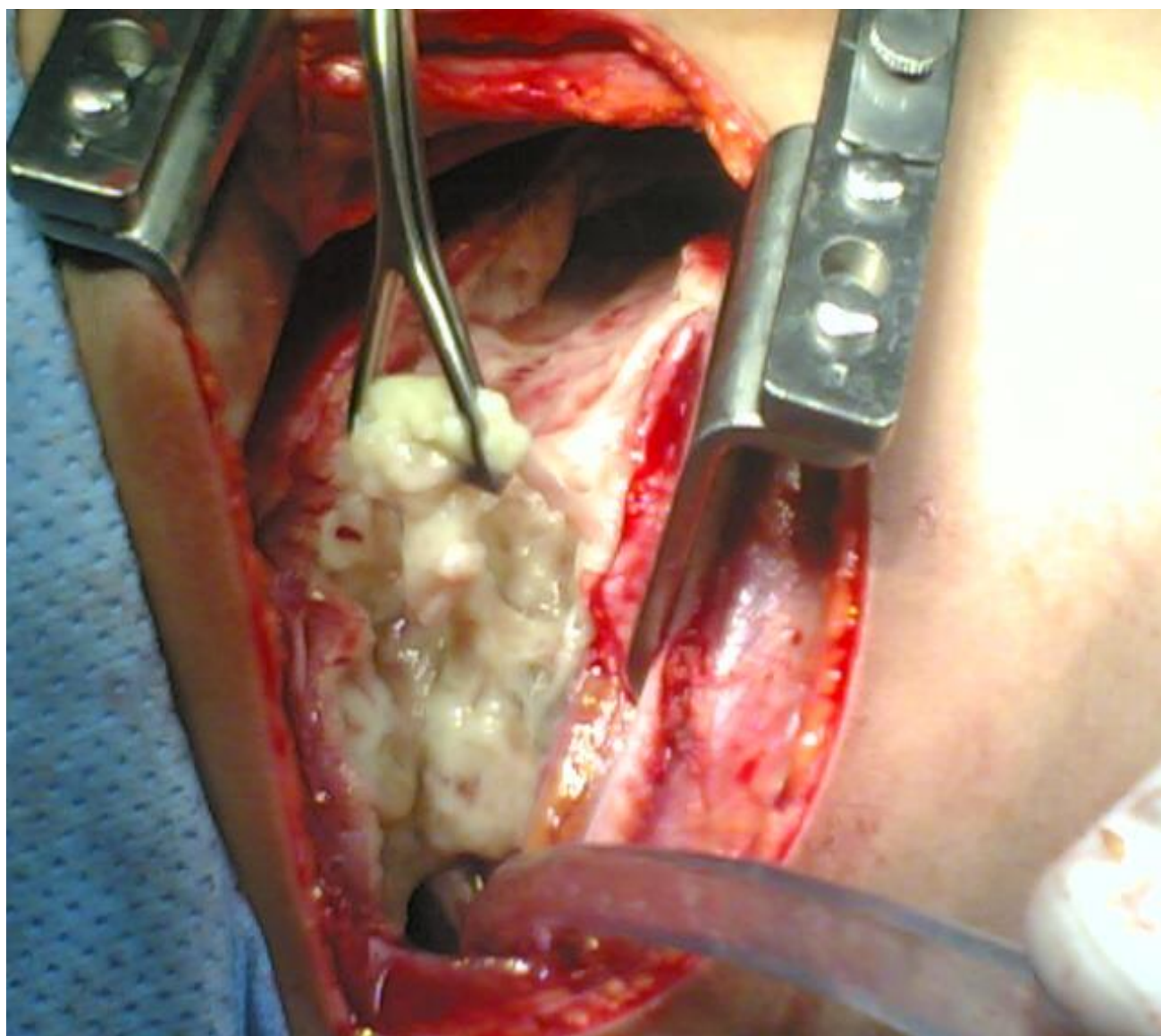


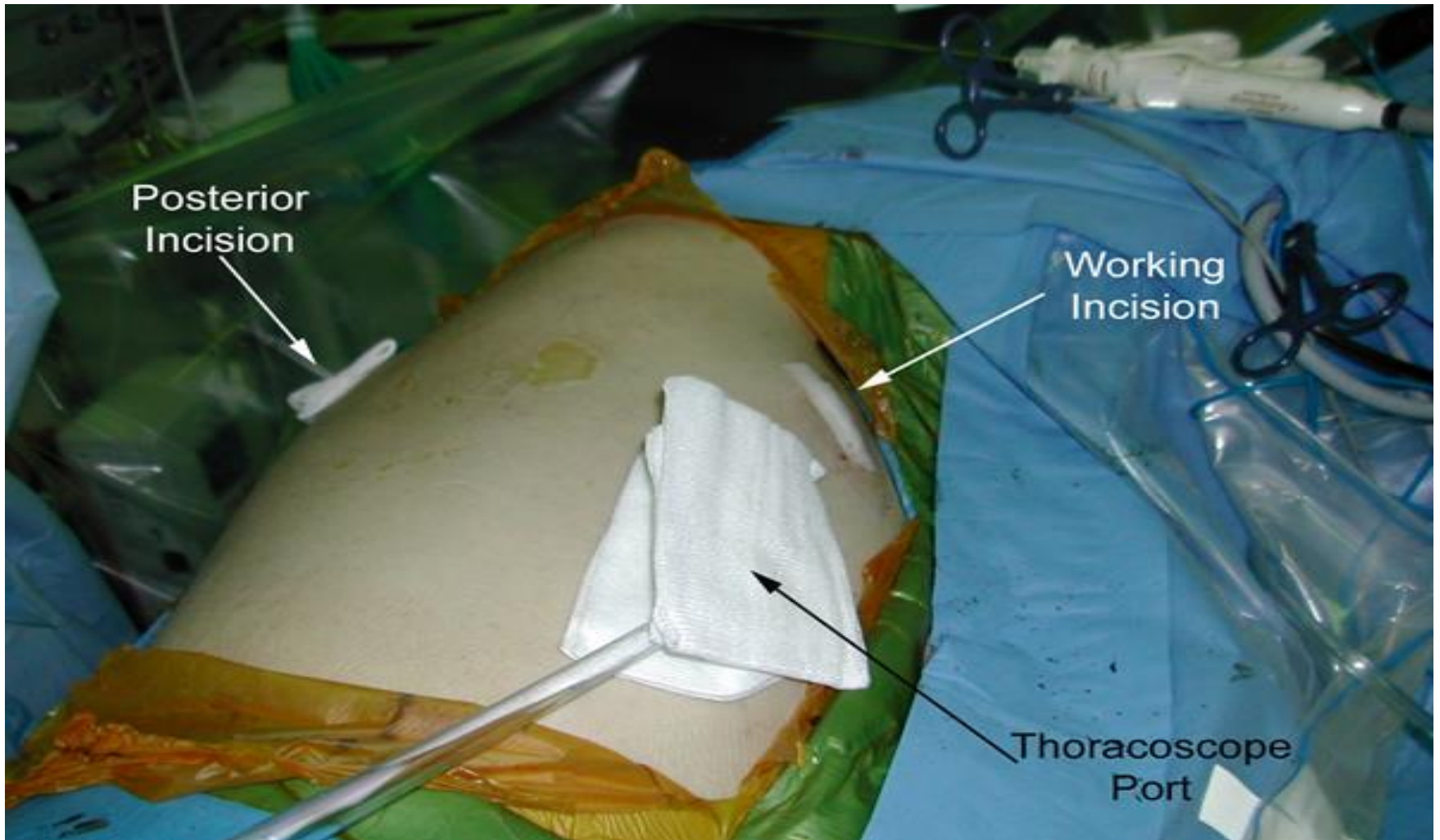
ROUTIN CHEST 5X5  
100ML OMNIP 300

[P]

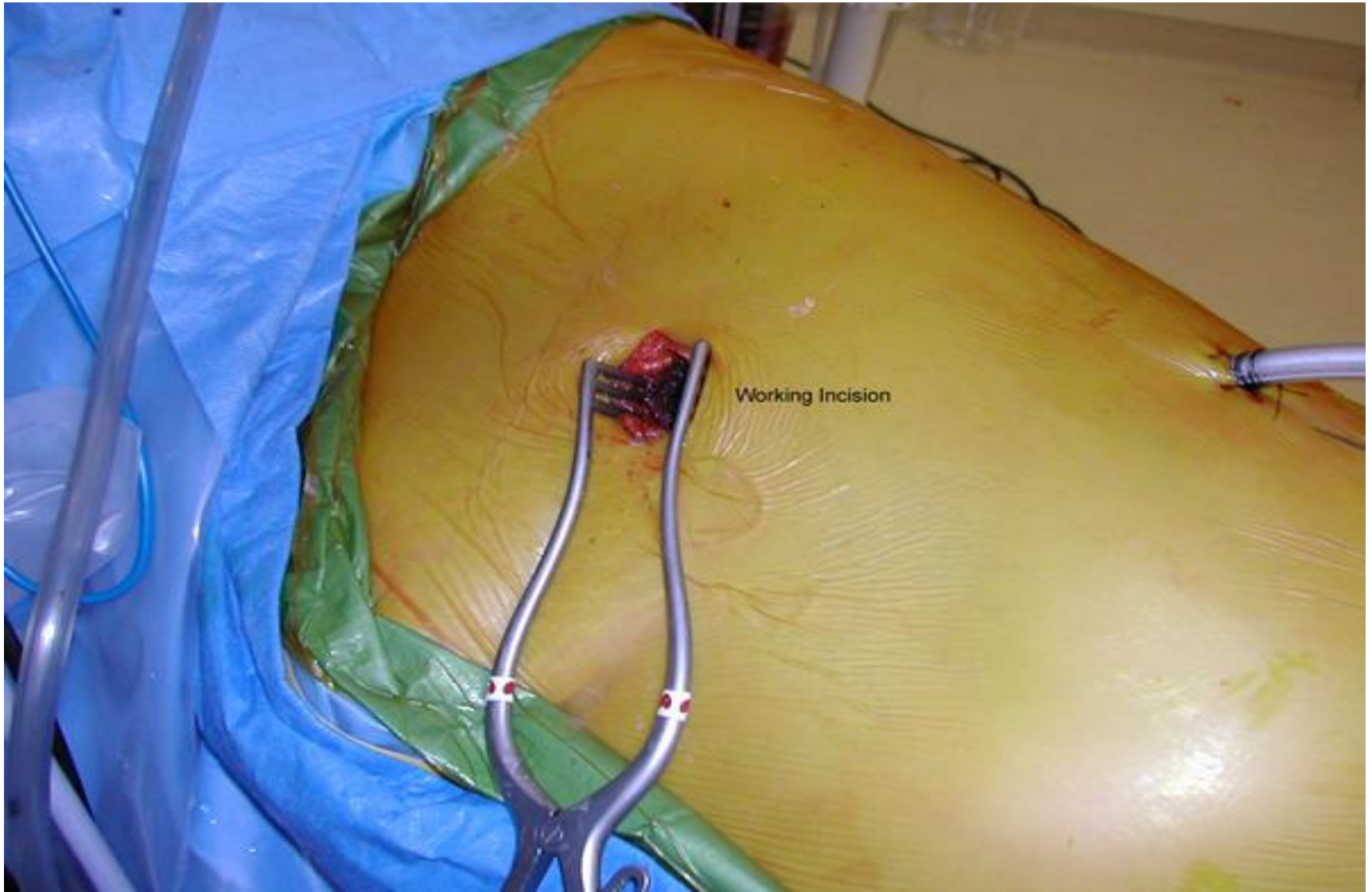C52  
W354







Position of skin incisions, showing camera port and working port anteriorly



Use of a retractor to hold open the working port.

